

## Durham E-Theses

---

*"The effect of the administration of mepivacaine hydrochloride on the histological and electronmicroscopical appearance of the rat testis "*

Rashed Mourad Ahmed Rashed

### How to cite:

---

Rashed, Rashed Mourad Ahmed (1979) "The effect of the administration of mepivacaine hydrochloride on the histological and electronmicroscopical appearance of the rat testis ". Masters thesis, Durham University.

### Use policy


---

The full-text may be used and/or reproduced, and given to third parties in any format or medium, without prior permission or charge, for personal research or study, educational, or not-for-profit purposes provided that:

- a full bibliographic reference is made to the original source
- a <https://etheses.durham.ac.uk/id/eprint/9134/> is made to the metadata record in Durham E-Theses
- the full-text is not changed in any way

The full-text must not be sold in any format or medium without the formal permission of the copyright holders.

Please consult the [full Durham E-Theses policy](#) for further details.



**" THE EFFECT OF THE ADMINISTRATION OF MEPIVACAINE HYDROCHLORIDE  
ON THE HISTOLOGICAL AND ELECTRONMICROSCOPICAL APPEARANCE OF  
THE RAT TESTIS "**

**Being a thesis submitted for the degree  
of M.Sc. at the University of Durham**

**BY**

**Rashed Mourad Ahmed Rashed**

**B.Sc.**

**1979**

The copyright of this thesis rests with the author.  
No quotation from it should be published without  
his prior written consent and information derived  
from it should be acknowledged.

STATEMENT OF COPYRIGHT

" The copyright of this thesis rests with the author . No quotation from it should be published without his prior written consent and information derived from it should be acknowledged . "

CANDIDATE'S DECLARATION

I hereby declare that the work recorded in this Thesis has been carried out by me except where stated, and that it is of my own composition.

I further declare that it has not been submitted in any previous application for a higher degree.

R.M.A. Rashed

*R.M.A. Rashed*

## ACKNOWLEDGMENTS

-----

I wish to express my gratitude to Dr. K. Bowler for the expert advice and the unfailing encouragement that he has given me throughout the course of this work .

I am greatly indebted to Dr. M. J. Stacy for his advice and help in the preparation of the EM work .

I also wish to express my thanks to Professor D. Barker and the staff of the Department of Zoology for their help and advice during my time in their department .

My thanks are also due to Mr. D. Hutchinson for the excellent photographic assistance .

Finally , heartfelt thanks to Miss. Eman A. Ibrahim for her help in preparing the final manuscript .

C O N T E N T S

ABSTRACT

CHAPTER 1 :	GENERAL INTRODUCTION .....	1
CHAPTER 2 :	MATERIAL AND METHODS .....	18
	1- Animals .....	18
	2- Reagents .....	18
	3- Administration of Mepivacaine-HCl .....	19
	4- Testes Histology : .....	20
	- Haematoxylin-eosin technique .....	21
	- PA-FSA-haematoxylin technique .....	21
	5- Testes Histochemistry .....	21
	6- Testes Electron microscopy .....	22
CHAPTER 3 :	THE EFFECT OF MEPIVACAINE-HCL AT THREE DIFFERENT HIGHER DOSES ON THE HISTOLOGICAL APPEARANCE OF THE TESTES . ....	23
	1- Introduction . .....	23
	2- Methods .....	24
	3- The doses chosen .....	25
	4- Results :	25
	(a) " Slightly " damaged tubules .....	27
	(b) " Partially " damaged tubules .....	31
	(c) " Severely " damaged tubules .....	31
	(d) Relation between dose of Mepivacaine-HCl , time after treatment and testicular damage .....	39
	(e) Histochemistry .....	42
	5- Discussion .....	44

CHAPTER 4 :	EFFECT OF SINGLE LOW DOSES OF MEPIVACAINE-HCl ON THE HISTOLOGY OF THE TESTIS :	53
1-	Introduction	53
2-	Methods	53
3-	Results	53
4-	Discussion	59
CHAPTER 5 :	EFFECT OF REPEATED DOSES OF MEPIVACAINE-HCl ON TESTES ....	61
1-	Introduction	61
2-	Methods	61
3-	Results	62
4-	Discussion	72
CHAPTER 6 :	THE EFFECT OF SINGLE DOSES OF 0.1 , 0.25 & 0.5 cm <sup>3</sup> OF 4% MEPIVACAINE-HCl ON THE ELECTRON MICROSCOPICAL APPEARANCE OF THE TESTIS :	76
1-	Introduction	76
2-	Methods	76
3-	Results :	77
-	The boundary tissue	77
-	The spermatogonia	82
-	The spermatocytes	90
-	The spermatids	105
-	The Sertoli cells	127
4-	Discussion	137
GENERAL DISCUSSION		145
BIBLIOGRAPHY		158

# Summary

## S U M M A R Y

---

In this investigation the histology and histochemistry of the testes of albino rats receiving Mepivacaine-HCl solution of different doses and concentrations were studied using both light and electron microscopes .

The testes of treated animals showed different degrees of damage . The severity of the damage was classified into "slightly" , "partially" and "severely" damaged tubules . Vacuolation was seen in the "slightly" damaged tubules by many investigators who gave different explanations about how and what causes vacuole formation. In this study , a new hypothesis was introduced.

The late spermatids were readily damaged after Mepivacaine-HCl administration . Then , the early spermatids showed different degrees of damage and degeneration ; the mitochondria appeared extremely electron dense and scattered in the cytoplasm instead of being close to the cell membranes .

The primary spermatocytes were the next in order of sensitivity. A marked morphological elongation of the cytoplasm of these cells was usually seen . Their mitochondria showed a distinct swelling and cup-shaped mitochondria were also found. These were not typical of germinal cells of control testes .

The secondary spermatocytes showed marked destruction in some parts of the cytoplasm and the nuclear membrane appeared bulging into the cytoplasm . Their mitochondria showed disruption and fusion of the membranes .

The light microscope did not determine the extent of damage of spermatogonia . However , the electron microscope showed slight changes of the Golgi apparatus and mitochondria after administration of Mepivacaine-HCl . The mitochondria of spermatogonia were frequently swollen and their cristae were

disintegrating and coalescing together forming a condensed electron dense bodies .

Sertoli cells were the cell type most resistant to drug administration .

The boundary tissue of tubules , "partially" and "severely" damaged , showed a marked increase in thickness at the light microscope level . At the electron microscope level , the boundary tissue could be resolved into the four layers which became highly folded .

The seminal vesicle weight from the experimental rats did not differ significantly from those of normal rats .

Many extremely large lipid droplets were present in the seminiferous epithelium of the treated animals as well as in the interstitial cells .

Since Mepivacaine-HCl has a vasoconstrictor effect and spermatogenesis is very sensitive to reduced blood flow , it could be concluded that the injurious effect of the administration of Mepivacaine-HCl intraperitoneally is probably due to reduced blood flow to the testes .

# Chapter 1


## General Introduction

## Chapter 1

### General Introduction

The deleterious effects of many agents , both physical and chemical , on testes structure and function have been studied . The purpose of this earlier work was to aid the understanding of such conditions as natural cryptorchidism and aspermia , and also to work towards the possible control of spermatogenesis and so develop an effective male contraceptive . The possible harmful effects of exposure to noxious agents and radioactivity also demanded that the effect of administration of drugs and irradiation on the testes be a subject of a study .

The cryptorchid condition produces an aspermic testis . Artificial cryptorchidism has been well studied in guinea pigs ( Moore , 1924 ) , rats ( Moore , 1924 ; Clegg , 1961 ; 1963a,b ; 1965a,b . ) and sheep ( Moore & Oslund , 1923 ) . Similar studies on rabbits have been made by Fukui ( 1923a,b ) and Cunningham ( 1927 ) , and it was generally agreed that , if artificial cryptorchidism was maintained for a sufficiently long time , the great majority of germ cells was lost and that reposition into the scrotum did not result in a return to normal spermatogenesis . Clegg ( 1961 ; 1963a,b ; 1965a,b ) found that , in the rat , bilateral artificial cryptorchidism resulted in degenerative changes in the seminiferous tubules that were maximal about the 15th post-operative day . Up to this stage , Clegg ( 1961 ; 1963a,b ; 1965a,b ) showed that all germ cells were reduced in number, spermatogonia being least affected and spermatids most . The spermat-



gonial mitosis and spermatocyte meiosis were also inhibited to some extent . One of the effects of artificial cryptorchidism upon the testis was an apparent increase in the amount of interstitial tissue . This change may be wholly or partly due to great shrinkage which occurred in the seminiferous tubules , with consequent aggregation of the interstitial tissue into a smaller volume . Some authors considered that the effect was wholly due to this cause ( Bascom , 1923 ; Moore , 1924 , 1945 ; Moore and Oslund , 1923 ; Pace and Cabot , 1936 ) , but others considered that there was probably an actual increase in the amount of interstitial tissue ( Sand , 1921 ; Hanes and Hooker , 1937 ; Engberg , 1948 ; Lynch and Scott , 1951 ) . In the natural cryptorchid rat testis , spermatogenesis was arrested at or about the meiotic division in stage XIV ( Leblond and Clermont , 1952 ) and the interstitium and Sertoli cells appeared histologically unaffected .

This interesting effect of exposure to body temperature , as compared to the lower scrotal temperature , has led to a wider interest in the effect of heat on testis function . Many such studies have been carried out ( Young , 1927 ; William & Cunningham , 1940 ; Elfving , 1950 ; Steinberger & Dixon , 1959 ; Chowdhury & Steinberger , 1964 ; Bowler , 1967 ; 1972 ; Collins & Lacy , 1969 ; Chowdhury & Steinberger , 1970 ; Parvinen , 1973 ) . It was clear from studies where testes temperature was raised by heating the scrotum ( usually about 40 C ) for a short period , that the damage caused was more severe than occurred in short-duration cryptorchidism . For example , permanent sterility could occur . The primary and secondary spermatocyte stages were thought to be the most temperature sensitive ( Collins & Lacy , 1969 ; Chowdhury &

Steinberger , 1964 ) , but it was clear that at some stages in the cycle , spermatogonia were also temperature sensitive . Few tubules were seen to be completely devoid of germ cells ( Bowler , 1972 ) . For tubules to be irreversibly damaged , stem cell spermatogonia must be killed . Indeed Dym & Clermont ( 1970 ) have shown that A-type spermatogonia were sensitive to irradiation ( 300 r ) during mitotic division in stages IX , XII , XIV and I of the cycle in the rats . Bowler ( 1972 ) suggested that stem cells were heat sensitive only at certain times in the cycle , accounting for the 7% of permanently damaged tubules observed following heat treatments . Clegg ( 1963b ) noted that spermatogonia undergoing mitosis were sensitive to artificial cryptorchidism , whilst " resting " spermatogonia were resistant . Sertoli cells were relatively insensitive and were apparently unaffected other than for occasional displacement from their normal position . The interstitial cells were also apparently unaffected by the heating ( Collins & Lacy , 1969 ) .

More recently , Dutt *et al.* ( 1977 ) showed following the exposure of the testis or the whole body of rams to elevated temperature ( 32 C ) for one week , that :-

- (a) The blood flow to the testes decreased significantly .
- (b) The spermatic wall thickened significantly , anterior to the pampiniform plexus by 21% , at the middle by 62% , and at the top of plexus by 22% . and
- (c) The arterial lumen diameter was reduced by 48% .

They concluded that the reduced blood flow to the heated testes was associated with a thickening of the wall and a reduction in size of the lumen of the spermatic artery in the pampiniform plexus .

It was observed that X-irradiation of the testes , with doses sufficient to cause depletion and / or destruction of the germinal elements , was not followed by atrophy of the accessory sex organs , or by cessation of copulatory activity ( Bourg , 1931 ; Mirskaia & Crew , 1931 ; Witschi et al. , 1932 ; Johnston , 1934 ; Hu & Frazier , 1941 ; Shaver , 1953 a ) . X-irradiation has also been shown to adversely affect spermatogenesis , ( Oakberg , 1955a,b ; 1956a,b ; 1959 ; 1964 ; Edwards & Sirlin , 1958 ; Abbott , 1959 ; Jones , 1960 ; Lacy & Rotblat , 1960 ; Nebel et al. , 1960 ; Oakberg & DiMimmo , 1960 ; Dym & Clermont , 1970 ) . Momigliano & Essenberg ( 1944 ) , using immature rats , reported that irradiation of the testes with a cumulative dose of 300 r was followed by atrophy of the accessory sex organs . Exposure of the testes to higher doses was made by Abbott ( 1959 ) . He found that rat testes exposed to 5000 or 10.000 r were hyperaemic and soft and the tunica albuginea became increasingly thickened and opaque . Extremely rapid depletion of spermatogonia and spermatocytes was observed . Two weeks after the irradiation ( 10.000 r ) , the testes were devoid of germ cells ; whereas those exposed to 5.000 r only contained occasional tubules with a few spermatids and spermatozoa . At periods varying from 2 to 25 weeks after treatment the shrunken seminiferous tubules consisted only of a thickened basement membrane enclosing a syncytium of Sertoli cells . No signs of regeneration of the germinal epithelium were seen . Most intertubular cells remained histologically normal after irradiation , but the proportion of intertubular to tubular tissues was considerably higher in irradiated than in the non irradiated animals .

The effect of vasectomy on spermatogenesis has been studied extensively . Some workers claimed a deleterious effect ( Altwein & Gittes , 1972 ; Sackler et al., 1973 ) , whereas others claimed that spermatogenesis remained normal ( Smith , 1962 ; Kar et al., 1965a; Segal , 1972 ) . Blockage of the ductus deferens has yielded impaired spermatogenesis ( Smith , 1962 ; Flickinger , 1972 b ; Segal , 1972 ) . However , Lee ( 1967 ) claimed vasectomy without ligation had no effect on the testes while Runke & Titus ( 1970 ) and Sackler et al., ( 1973 ) described that these operations produced some testis abnormalities . Recently , Neaves ( 1974 ) indicated that vasectomy by various procedures , had no effect on spermatogenesis and suggested that reconciliation of conflicting reports in the literature must involve factors other than procedural differences . He supposed that inadequate discrimination between the consequences of vasectomy and induced cryptorchidism might still be responsible for much of the disagreement surrounding vasectomy . It was of interest however that Derrick et al.( 1974 ) showed a depression and then gradual return of spermatogenesis after vasectomy .

The administration of chemicals , usually by injection , on spermatogenesis has been the subject of considerable interest . Reagents used can be grouped in three categories , hormones , pharmacological agents and compounds likely to have specific deleterious cytological or physiological action on the testis .

Lacy & Lofts ( 1965 ) showed that the treatment of male rats with oestrogen resulted in a decline of spermatogenesis , which could be reversed by administration of FSH ; they concluded that of the

germinal cells , the spermatocytes were the most sensitive to the action of oestrogens . Ericsson et al. ( 1964 ) and Ericsson & Dutt ( 1965 ) showed that progestins inhibited spermatogenesis in rabbit and ram . Normal elements of the germinal series were absent , much sloughing of immature cells occurred , causing testes atrophy . Atrophy of interstitial cells was also reported .

Recently , Turner and MacLaughlin ( 1973 ) showed that atrophy of the testes and the accessory sex glands , which occurred after prolonged treatment with progestins , was prevented by concurrent treatment of the animals with small doses of testosterone propionate. However , the androgen did not reverse the suppression of spermatogenesis .

Many different kinds of compounds have been studied for their antifertility effects in the hope that a suitable chemical male contraceptive can be found . Recently the combination of progestin and androgen has been tested with promising results ( Segal , 1973 ) , for it was reported to produce reversible infertility whilst libido and male sex characteristics were maintained ( Frick , 1973 ; Coutinho & Melo , 1973 ). The rationale behind the administration of a progestin-androgen combination was that it was thought to diminish gonadotropin release and suppress spermatogenesis ( Turner & MacLaughlin , 1973 and Kragt et al., 1973 ). However , the Leydig cells became suppressed , resulting in a decreased secretion of testosterone . Secondary sex characteristics and libido could then be maintained by the simultaneous administration of exogenous testosterone .

The histology and ultrastructure of the testis , epididymis and sex accessory glands of rats treated with medroxyprogesterone ( provera ) ( 1 mg / 100 g. body weight / day ) alone and combined with testosterone ( 15 , 30 or 100 ug / 100 g. / day ) was studied following treatment for up to 16 weeks by Flickinger ( 1977a,b ). He showed similarity of the microscopic alterations in the testes of animals administered " provera " alone or " provera " and different levels of testosterone . Spermatogonia, spermatocytes and early spermatids were abundant in treated rats and did not show ultrastructural changes . However , many degenerating or necrotic spermatids of the cap phase ( approximately stages 6-7 ( Leblond & Clermont , 1952 ) ) and later were present . Late spermatids of the acrosomal and maturation phases were rare . Some necrotic spermatids were surrounded by Sertoli cells , also many large lipid droplets were present in Sertoli cells of treated rats . Leydig cells were smaller in treated animals than in control rats . These results of Flickinger(1977a,b) suggested that with this treatment germ cells can be developed up to cap-phase spermatids , but then they undergo degeneration . These alterations in spermatogenesis might be responsible in large part for the antifertility effect of the progestin and androgen .

The antiandrogens , cyproterone and cyproterone acetate , caused reversible infertility ( Whalen & Luttage , 1969 ; Steinbeck et al.,1971; Morse et al., 1973 ) . Cyproterone acetate has been more widely used and had a greater potency , although it was said to have more progestational activity than cyproterone ( Wiechert & Neumann , 1965 ; Steinbeck et al., 1971 ) . The literature on the mechanism of action of these compounds and clinical and experimental studies with them has been reviewed

on several occasions by Neumann and his associates ( Neumann , 1966 ; 1971 ; Neumann et al., 1968 ; 1969 ; 1970 ) . The weights of the testis and the accessory sex glands of animals treated with cyproterone acetate were reduced ( Neumann et al., 1970 ) . Light microscopic studies indicated that the testes in the cyproterone or cyproterone-acetate -treated animals displayed a great reduction in the abundance of late spermatids. Necrotic cells were present in the seminiferous epithelium . Sertoli cells contained many large lipid droplets and lysosome-like structure with a content of cellular debris , including parts of spermatids . Late spermatids were absent from the lumen of the tubules ( Neumann & Von Berswordt Wallrabe , 1966 ; Mietkowski & Lukaszyk , 1969 ; Markewitz et al., 1969 ; Steinbeck et al., 1971 ; Morse et al., 1973 ) . Late spermatids were the most severely depleted stages in rats treated with cyproterone ( Mietkowski & Lukaszyk , 1969 ) or cyproterone acetate ( Neumann & Von Berswordt-Wallrabe , 1966 ; Steinbeck et al., 1971 ) and in men administered cyproterone acetate ( Morse et al., 1973 ) ; also the drug affected spermatogonia and primary spermatocytes ( Markewitz et al., 1969 ) . Different reports have been made on the effects of cyproterone acetate on Leydig cells . In studies of cyproterone acetate-treated rats , Leydig cells were reported to be unchanged for several weeks and then to undergo slight shrinkage ( Neumann et al., 1970 ) . A decrease in size of Leydig cell nuclei was observed ( Heinert & Taubert , 1973 ) . In one study Leydig cells were said to decrease in size for six weeks and then return to normal ( Steinbeck et al., 1971 ) . Others reported that rat Leydig cells remained unchanged in the presence of cyproterone acetate may reflect the use of shorter treatment periods ( Junkmann & Neumann , 1964 ; Neumann , 1966 ) . The occurrence of no , or only a few changes in Leydig cells in the

presence of cyproterone acetate has been rationalized as a balancing of the antiandrogenic and gonadotropin-suppressing action of this compound ( Steinbeck et al., 1971 ) .

Three nitrofurans ( furacin , furadroxy and furadantin ) have been studied for their effects upon reproduction ( Nelson & Steinberger , 1953 ) . The three compounds , usually administered in the diet , have been examined for their effectiveness in producing spermatogenic arrest and testicular atrophy at levels varying from 0.1 gm to 3.0 gm / Kg of diet . The minimal effective level per kg of diet in animals 30 to 35 days old initially , and treated for 30 days were : furacin , 0.2 gm , furadroxy , 0.75 gm , furadantin , 1.5 gm . At these dose levels , the testes were approximately one-third the control size , but body weights and the weight and histology of other organs were essentially the same as in untreated controls . Testicular damage was not permanent since animals maintained on the drugs for as long as 100 days have shown complete recovery , including fertile matings , on the subsequent withdrawal of the drugs ( Nelson & Steinberger , 1953 ) .

Busulfan ( Myleran or Misulban : 1,4-dimethylsulphonyl oxybutane ) is an alkylating agent possessing an inhibiting effect on the cell division of the seminiferous epithelium cells ( Gillet & Laporte , 1973 ) . Hemsworth & Jackson ( 1962 ) have studied the sterilizing effect of busulfan on the rat embryo by a dose of 10 mg / kg of the body weight and have shown that the critical period for sterilization in males was between the 12th & 20th day including the gestation . The inhibiting effects of busulfan caused a decreased in testicular volume . The small

diameter of the tubules appeared to be linked with the aspermatogenic condition of the testis ( Gillet & Laporte , 1973 ) .

The testes of mice injected with nitrogen mustards have been shown to undergo histopathologic changes ( Landing et al., 1949 ) . These changes included degeneration of tubules and cells , swelling of cells , giant cell formation and inhibition of mitosis .

Kindred ( 1952 ) showed that in the testes of rats intravenously injected with 0.6 mg/kg body weight ( sublethal dose ) of tris ( 2 chloroethyl ) amine code name HN-3 , the cells most severely damaged were the spermatids , which formed giant cells in which the nuclei were either pyknotic or undergoing karyolysis . The nuclei of the germ cells were initially swollen . Dividing spermatocytes were also abnormal with many chromosomal and spindle aberrations . A few primary spermatocytes formed giant cells . Spermatozoa were often collapsed and fused . Completely degenerated tubules contained only remnants of Sertoli cells and spermatogonia . All these changes were maximal on the third day after treatment . There were no visible morphological changes in the interstitial cells despite their exposed position . Congestion and haemorrhage were present to a slight degree in the HN-3 rats of the first day . Following this condition there seemed to be a contraction of the vasa and an ischemia .

Cadmium was shown ( Kar et al., 1965b; Kar & Kamboj , 1965 ; Parizek , 1960 ; Parizek & Zahor , 1956 ) to have a destructive effect on the testes of the rat when administered parenterally as cadmium chloride , and similar activity has been described in the mouse ( Meek , 1959 ) and monkey ( Girod & Chauvineau , 1964 ) . Intracellular

( Kar et al., 1961 ) and subcutaneous ( Cameron , 1965 ) injections in rabbits were also effective . Cadmium apparently interfered with the normal uptake of zinc by the testis ( Gunn et al., 1961 ) . It was known that zinc-deficient diets in rats resulted in irreversible testicular atrophy ( Millar et al., 1958 ) . It has been suggested ( Chiquoine, 1963 ; Gunn et al., 1963b ) that vascular factors are of great importance in the regional destruction of the testis , rather than specific sensitivity of the seminiferous tubules . Gunn et al. (1963b) suggested the presence of an enzyme system peculiar to the pampiniform plexus , sensitive to cadmium and possibly dependent on zinc . It would appear that the enzyme concerned was located in structures involved in thermal regulation of the testis , since cadmium damage did not occur in non-scrotum animals .

Recently , Suzuki & Yoshikawa ( 1971 ) showed that in male rats injected intraperitoneally with 3 mg/kg of cadmium chloride , the testicular weight did not show remarkable changes for the first 24h., but after 96 hours there was weight loss and severe atrophy .

It has been shown by several experimental techniques , that it was the testicular vasculature rather than the parenchymal cells which were initially injected by cadmium , and that generation of interstitial elements and seminiferous tubules followed as a secondary reaction ( Parizek , 1960 ; Gunn et al., 1963b ; Waites & Setchell , 1966 ) . Vascular permeability was also evident from the oedema and haemorrhage which followed cadmium administration ( Gupta et al., 1967 ) .

$\alpha$ -chlorhydrin is an active alkylating chemical , possessing the biological property of functionally inactivating epididymal sperm and

so producing temporary sterility ( Dixit & Lohiya , 1976 ) . The effect of  $\alpha$ -chlorhydrin on the testes was studied in rats ( Ericsson and Connor , 1969 ; Coppola , 1969 ; Ericsson & Baker , 1970 ; Ericsson and Youngdale , 1970 ; Gunn & Gould , 1970 ; Ericsson & Bennett , 1971 ; Hoffer et al., 1973 ) , in sheep ( Khadir & Dutt , 1969 ) , in pigs ( Johnson & Purves , 1972 ) and in monkeys ( Kirion et al., 1970 ) and proved to be an effective but reversible antifertility agent . Recent work by Dixit & Lohiya ( 1976 ) on  $\alpha$ -chlorhydrin showed that with oral administration , the relative testicular weight of the  $\alpha$ -chlorhydrin - treated rats and gerbils did decrease drastically although there was no loss in body weight . Tubule shrinkage , complete spermatogenic arrest and a noticeable decrease in the absolute weight of the epididymis occurred in rats after  $\alpha$ -chlorhydrin administration . The primary site of damage caused was in cells lying near the basement membrane ; indeed, the development of new spermatogonia was prevented for several weeks . The seminiferous epithelium became systematically depleted of spermatogonia , spermatocytes , spermatids and finally spermatozoa in that order ( Dixit & Lohiya , 1976 ) .

The growth of androgen-dependent organs i.e. seminal vesicles , ventral prostate , epididymis was also found to be suppressed ( Dixit & Lohiya , 1976 ) .

For a rapid male sterilization , Setty et al. ( 1972 ) and Malaviya et al. ( 1974 ) , occluded the vas deferens by injecting comphor, potash alum , or quinaorine in rats and monkeys . Freeman & Coffey (1973) sterilized a large number of male animals by injecting a wide variety of sclerosing chemical agents directly into the vas deferens . A single

injection of 95% ethanol into the vas deferens appeared to produce a complete sterility in a large series of animals , which was confirmed through mating exposure experiments ( Dixit et al., 1976 ) .

DMBA ( dimethylbenzanthracene ) , a carcinogenic hydrocarbon , produced a spermatogonial depletion which was reported to be accompanied by an increase in malate dehydrogenase activity ( Ford & Huggins , 1963 ; 1964 ) . However , a later report indicated that , although considerable spermatogonial depletion occurred , the apparent rise in malate dehydrogenase activity was due to loss of testis weight , since the total enzyme activity per testis did not change appreciably ( Ahlquist , 1966 ) . These appeared to be a true increase in  $\beta$ -glucuronidase activity , but this enzyme increase may have been a reflection of the increasing atrophy of the tissue .  $\alpha$ -glycerophosphate dehydrogenase activity decreased as the spermatozoa left the testis and were not replaced by new cells ( Schenkman et al., 1965 ) .

Deuterium oxide induces sterility in male mice ( Hughes & Calvin , 1958 ; Hughes et al., 1959 ) . This sterility resulted from failure of spermatozoa to fertilize the egg ( Hughes & Glass , 1965 ) . It would appear from this work that the action was due to an abnormality in acrosome formation . Cytopathologic effects of deuterium oxide on the testes of dogs and mice have been recorded ( Amarose & Czajka , 1962 ) .

Serotonin ( 5 hydroxytryptamine ) and histamine have similar pharmacological effects as seen from studies on vascular permeability ( Majno & Palade , 1961 ) and vasoconstriction ( Haddy , 1958 ; Haddy et al., 1959 ) .

A single subcutaneous injection of 5-hydroxytryptamine ( 5HT ) has been shown to cause pathological changes in the mouse testis , when examined 7 or 30 days after the injection ( O'steen , 1963 ) . Following 5HT injection in rats , Boccabella et al. ( 1962 ) observed that 50 to 90% of seminiferous tubules in a testicular cross section still appeared normal . In the damaged tubules giant multinucleated spermatids were frequently seen , along with pyknotic primary spermatocytes and spermatids. Spermatids in the acrosomal and maturation phase were absent . These marked histological changes and a significant weight decrease occurred after administration of 5HT 10 mg/kg twice daily for 5 days ( Boccabella et al., 1962 ) . Following ten day's treatment , pyknotic primary spermatocytes and spermatids were frequently encountered , and some tubules contained only Sertoli cells and spermatogonia . The limiting membrane of these tubules was markedly thickened . By the 15th day , the damage was more uniform than that seen earlier . Boccabella & Jarecki ( 1965 ) also reported that the lesions induced by 5HT in the rat testis showed poor reversibility , some tubules still remained damaged 80 days after 5HT treatment for 15 to 35 days .

Korman et al. ( 1968 ) showed that the testes of experimental animals injected with 5HT were significantly lighter than those of the controls , but the mean weights of the seminal vesicles did not differ significantly . The histological picture of the experimental testes varied greatly . In some testes only a few tubules were damaged , the other tubules being normal . In other testes , however , all tubules were damaged . Large differences were seen even between the two testes of the same animal . These pathological changes were morphologically very similar to those caused by testicular ischaemia .

Seminiferous tubules of rats injected subcutaneously with serotonin and histamine , either separately or in combination , showed degrees of degeneration ranging from minor damage , such as pyknosis of spermatogonial cells in an otherwise normal tubule , to a striking absence of all cells excepting for a single outer layer ( O'steen , 1963 ) . Intermediate stages of tubular degeneration were characterized by exfoliation of cellular debris into the lumina of tubules or by the absence of scattered , large vacuolar spaces , which possibly were the result of death and resorption of one or more spermatogenic cells . The lumen of a degenerating tubule frequently contained one to three large multinucleate cells . He also , showed that the pathological changes in the serotonin and or histamine treated testes were morphologically identical to those described by Oettle & Harrison ( 1952 ) following the occlusion of the testicular artery in rats .

Boccabella et al. ( 1962 ) also concluded that the damage they described was due to vascular effects of the drug .

Ischaemia has been produced by either temporary or permanent occlusion of the testicular artery . The seminiferous epithelium showed a progressive necrosis following permanent occlusion with the germinal elements being the first affected cell types . At this stage the Sertoli cells first showed vacuolation and cellular debris and multinucleate cells were common . Finally even the Sertoli cells appeared disintegrate and form a fibrous mass ( Oettle & Harrison , 1952 ) . Temporary ischaemia has clearly shown the relative susceptibility of the different cell types. Sertoli cells were more resistant than the germinal cells , with dividing and rapidly differentiating cells being more sensitive than resting cells ( Oettle & Harrison , 1952 ; Dixit , 1977 ) . In short term ischaemia the wholesale loss of germinal cells led to a gross vacuolation of Sertoli

cells . The testes became shrunken and the interstitium appeared to be increased ( Oettle & Harrison , 1952 ) .

In summary , many forms of insult to the testis adversely affect its function , with spermatogenesis apparently being more sensitive than the interstitium .

Exposure to harmful chemicals appeared to have a more rapid effect than did physical injury or a damaging dietary regime , but the end result was usually the same , e.g aspermic testes ; decrease in the number of spermatocytes in division ; loss of normal epithelial characteristics of the tubules , sometimes giant cell formation by fusion of spermatids and less often fusion of spermatocytes .

Indeed it would appear likely possible that number of other harmful agents exert their injurious effect on the testes through an alteration in blood flow , or in vascular permeability .

Mepivacaine-HCl , a local anaesthetic agent , has also been reported to affect blood flow in capillaries ( Pohto & Scheinin , 1960 ; duMesnil-de Rochemont & Hensel , 1960 ; Adler et al., 1969a,b ; Aberg & Adler , 1970 ; Jorfeldt et al., 1970 ) . More recently , Aberg & Wahlstrom ( 1972 ) have shown that Mepivacaine-HCl in a wide range of concentrations (  $1 \times 10^5$  -  $1 \times 10^3$  g/ml ) had a contracting effect on relaxed vascular smooth muscle in vitro , while the compound in the same concentrations had a relaxing effect on contracted vascular smooth muscle. In view of its application and the sensitivity of spermatogenesis to reduced blood flow , it was considered of interest to determine whether the administration of this drug had an effect on testis structure .

Therefore , in the present study , the histology and ultrastructure of the rat testes has been examined following injection with different doses of this local anaesthetic drug , Mepivacaine hydrochloride .

Chapter 2  
Material and Methods

## Chapter 2

### Material and Methods

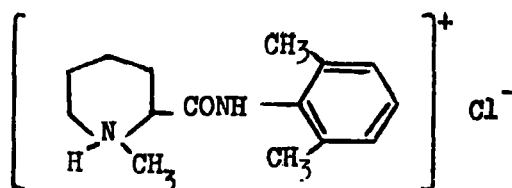
---

#### 1- Animals :

Sexually mature young male laboratory rats ( Rattus norvegicus, CFHB strain ), weighing approximately 130 - 150 g. ( 10 weeks old ), and large male rats weighing 200 - 250 g. ( 14 weeks old ), selected from a randomly mated colony , were used . They had access to water and food , and the temperature was maintained at 20 - 22 C .

#### 2- Reagents :

CARBOCAINE : Carbocaine is the hydrochloride of ( 1-methyl-DL-piperidine-2-carboxylic acid )-2,6-dimethylanilide . The generic name is Mepivacaine hydrochloride  $C_{15}H_{22}ON_2 \cdot HCl$  . It is a white crystalline powder , odourless and with a salty and bitter taste . Its molecular weight is 282.8 and the melting point is 255 - 262 C . It has the following structural formula :



Mepivacaine hydrochloride is tolerated both locally and generally. In many publications , it has been pointed out that Mepivacaine hydrochloride gives anaesthesia of remarkably long duration and that it can be used for many different operative treatments without the addition of a vasoconstrictor ( Aberg & Wahlstrom , 1969 ; Aberg & Adler , 1970 ; Aberg & Anderson , 1972 ) .

The drug was obtained from AB Bofors , Nobel-pharma , Sweden .

3- Administration of Mepivacaine hydrochloride :

a) Effect of high doses of Mepivacaine-HCl on spermatogenesis :

180 experimental rats 75 young adult ( 130-150 g.) and 105 large adult rats ( 200-250 g.) were used in total , and each received a single intraperitoneal injection of the drug .

Group " A " rats were injected with 0.1 cm<sup>3</sup> , group " B " rats with 0.25 cm<sup>3</sup> and group " C " rats with 0.5 cm<sup>3</sup> of a 4% ( 40 mg Mepivacaine-HCl , 95 mg glucose per ml ) solution of the drug .

Animals from each of the three groups were killed after 6 , 12 hours , 1 , 2 and 10 days .

b) Effect of low doses of Mepivacaine-HCl on spermatogenesis :

Thirty young adult ( 130-150 g.) rats were used in this experiment . Group " D " rats received 0.05 cm<sup>3</sup> of a 4% solution , and group " E " rats received 0.05 cm<sup>3</sup> of a 2% solution of the drug by intraperitoneal injection . The rats were killed after 24 & 48 hours .

c) Effect of repeated doses of Mepivacaine-HCl on spermatogenesis :

A further 65 young adult rats ( 130-150 g.) were used in this experiment . They received intraperitoneal injection(s) 0.1 cm<sup>3</sup> of a 4% solution of the drug daily from 1 to 5 days .

Rats were killed after 1 , 2 , 3 , 4 and 5 days .

CONTROL GROUPS :

In all cases animals were given the equivalent volumes , by intraperitoneal injection , of the carrier solution ( 95 mg glucose per cm<sup>3</sup> ) and killed and the testes taken for histological examination at the same time intervals as the experimental groups .

#### 4- Testes histology :

The rats were killed and the testes removed from each animal through an abdominal incision . One was fixed for light microscopy , the other was cut through the equator and one half was frozen for histochemistry and the other fixed for electron microscopy .

For the general histological observations , the testes were fixed in Bouin's fluid or in Zenker-formol ( Helly ) for 24 hours . The Zenker-formol specimens were washed in running water for 24 hours and were treated with 0.25% of iodine in 70% ethyl alcohol to remove mercury deposits . This was followed by a rinse in 3% sodium thiosulphate and a wash for 3 minutes in running water , followed by distilled water . Specimens fixed in Bouin's fluid were washed using several changes of 70% ethyl alcohol to remove the picric acid . Bouin's fixative proved to be the best for the rat testes . The tissues were dehydrated using ascending grades of ethyl alcohol , cleared in two changes of chloroform and embedded in paraffin wax ( m.p. 58 - 60 C ) ; this processing was carried out using an Elliott tissue processor .

Five micron sections were cut using a Spencer 820 rotary microtome . The sections used were selected from different regions of the testes rather than from the region of the equatorial plane , which might have been damaged during cutting and processing . After sectioning , the sections were affixed on clean glass slides using distilled water plus few drops of glycerine-albumen , then left to dry in an incubator at 37C for 24 hours . The sections were stained using both haematoxylin & eosin and PA-FSA-haematoxylin ( Leblond & Clermont , 1952 ) .

**Haematoxylin - eosin technique :**

The sections were dewaxed in two changes of xylene , hydrated through descending grades of ethyl alcohol to distilled water . The sections were stained in Mayer's haematoxylin for 30 minutes , then washed with distilled water and blued under running tap water for 3 minutes . After a further distilled water wash they were counter stained in 1 % eosin in distilled water ( water and alcohol soluble eosin , Gurr) for 20 seconds . The stained sections were dehydrated in n-butyl alcohol, two changes directly after staining with eosin for at least 5 minutes each , then clearing in two changes of xylene and the slides mounted with D.P.X. ( Gurr ) and left to dry in the incubator at 37 °C .

**PA-FSA-haematoxylin technique :**

The sections were dewaxed and hydrated through descending grades of ethyl alcohol and then oxidized in periodic acid , 0.5 % for five minutes . Following a distilled water rinse they were stained with Schiff's reagent for 15 minutes . This was followed by three two minute changes of sulphurous acid , and a three minute wash in running water . The sections were counter-stained with Mayer's haematoxylin for 10 minutes and blued in running tap water . They were dehydrated with n-butyl alcohol , cleared in xylene and mounted in D.P.X.

**5- Testes histochemistry :**

-----  
To demonstrate testes lipids , the testes were frozen , using a freezing medium of iso-pentane cooled to -160 °C by liquid nitrogen , the testes were mounted on chucks and left in SLEE Cryostat , to allow temperature equilibrium to occur .

Ten micron thick sections were cut , and placed on glass microscope slides and the slides fixed in formol - saline for 10 minutes , washed in distilled water and stained in Sudan Black B ( saturated solution in propylene glycol ) for 10 minutes . They were then drained and immersed in 85 % propylene glycol , 50 % propylene glycol with agitation for 3 minutes each , washed with tap water , drained and mounted in glycerine .

6- Testes electron microscopy :

-----  
For electron microscopy , testes were excised and placed in cacodylate buffered glutaraldehyde fixative ( 10 % glutaraldehyde + 0.2 M sodium cacodylate 1:1 ) . After removing the tunica albuginea , the tubules were dissected and rapidly separated , divided into small pieces with a sharp razor or a pair of scissors , and placed directly into fresh fixative for 4 hours at 4 °C . They were washed in 0.1 M cacodylate buffer overnight ; this was followed by post-fixation with 1 % osmium tetroxide in 0.1 M sodium cacodylate for 24 hours . After this they were washed in 0.1 M cacodylate buffer for ½ hour , dehydrated in ascending grades of ethyl alcohol ( 70 % - 10 minutes , 95 % - 10 minutes , absolute-2 changes, 30 minutes each ) and immersed in propylene oxide , 2 changes , 10 minutes each . The tissue was infiltrated with 50/50 mix of Epon / Epoxypropane overnight , then in epon for 24 hours and embedded at 60 °C for 48 hours .

Sections were cut on a Reichert OMU3 ultratome and were stained with uranyl acetate and lead citrate . They were examined with an AEI EM801 electron microscope at an accelerating voltage of 80 kv.

# Chapter 3

Chapter 3

---

The effect of Mepivacaine-HCl at three different higher doses  
on the histological appearance of the testes

---

Introduction :

Mepivacaine-HCl is one of a series of new long-acting local anaesthetics . It is stressed that the drug has a rapid onset , producing deep anaesthesia , and that it has a high frequency of anaesthesia and clinical safety and effectiveness ( Jorfeldt et al., 1970 ; Aberg & Adler , 1970 ) and low toxicity ( Luduena et al., 1960 ; Henn , 1960 ) .

In general , it has been found that the frequency of side-effects of Mepivacaine-HCl is significantly lower for local anaesthetics without vasoconstrictor than for those containing a vasoconstrictor ( Nordqvist & Dhuner , 1961 ; Dhuner , 1964 ) .

Mepivacaine-HCl is commercially available in several different media. It is dissolved in a saline solution at three different concentrations : 0.5% , 1% and 2% ( weight / volume ) , for a local anaesthesia , injection for infiltration or conduction anaesthesia . As a 3% solution ( weight / volume ) it is used for dental anaesthesia and as a 4% solution ( 40 mg Mepivacaine-HCl dissolved in 95 mg glucose in 1 ml sterile distilled water ) is used for hyperbaric spinal anaesthesia .

Mepivacaine-HCl , particularly its (+) isomer , has been shown to have a marked vasoconstrictor effect on the isolated rat portal vein ( Aberg & Wahlstrom , 1972 ) .

Ekenstam et al., 1956 , reported that , in a few cases , as a result of Mepivacaine-HCl injection , a fall in blood pressure occurred ; but in none of them was it severe .

In view of the evidence that spermatogenesis is adversely affected by the administration of agents that are known to affect blood flow in the testes , such as 5-HT ( Haddy , 1958 ; Haddy et al., 1959 ; Majno & Palade , 1961 ; Boccabella et al., 1962 ) , it was thought important to establish whether Mepivacaine-HCl injection would also have a similar effect on testes histology . The following work was carried out with this point in mind.

Methods :

-----  
The experimental rats of A , B and C groups were killed after 6 , 12 hours , 1 , 2 and 10 days of Mepivacaine-HCl administration as described in chapter 2 and testes removed for histological ( light and electron microscopy ) and histochemical examination . Control rats ( fifteen 130 - 150 g. and twenty-five 200 - 250 g. ) were given a single intraperitoneal injection of 0.5 ml glucose solution , and killed at the same intervals .

Each testis was cut through the equator and fixed in either Bouin's fluid or in Zenker-formol as mentioned previously in chapter 2 . The tissue was embedded in paraffin wax and sectioned at 5  $\mu$ m . The sections were stained with haematoxylin & eosin and also according to PA-FAS technique of Leblond & Clermont ( 1952 ) in which the classification of the stages of the cycle is based on the changes observed in the nucleus ( stained with haematoxylin ) and acrosomal system ( stained with PA-Schiff ) of the spermatid as it transforms into a spermatozoon , a process which was divided into 19 steps by Leblond & Clermont ( 1952 ) .

The doses chosen :

Rats were injected with three different doses ; one dose was 0.5 cm<sup>3</sup> ( 20 mg ) of Mepivacaine-HCl , 4% , ( approximately LD<sub>50</sub> ) and two lower doses of 0.25 cm<sup>3</sup> ( 10 mg ) and 0.1 cm<sup>3</sup> ( 4 mg ) of Mepivacaine-HCl , 4% , with the intention of determining if there is a relationship between the dose given and the damage caused .

Results :

The normal structure of the rat testes at both the light and electron microscopical levels is well known and a detailed description is not repeated here ( e.g Brokelmann , 1963 ; Burgos et al., 1970 ; Dym & Fawcett , 1970 ; Flickinger , 1972b ) .

As in other mammals , seminiferous tubules of rats contain Sertoli cells and combinations of germ cells in different stages of development . The interstitial tissue includes blood vessels , lymphatics , and other connective tissue elements ( Fawcett et al., 1973 ) and Leydig cells , which secrete testosterone ( Christensen & Gillim , 1969 ; Christensen , 1975 ; Neaves , 1975 ) .

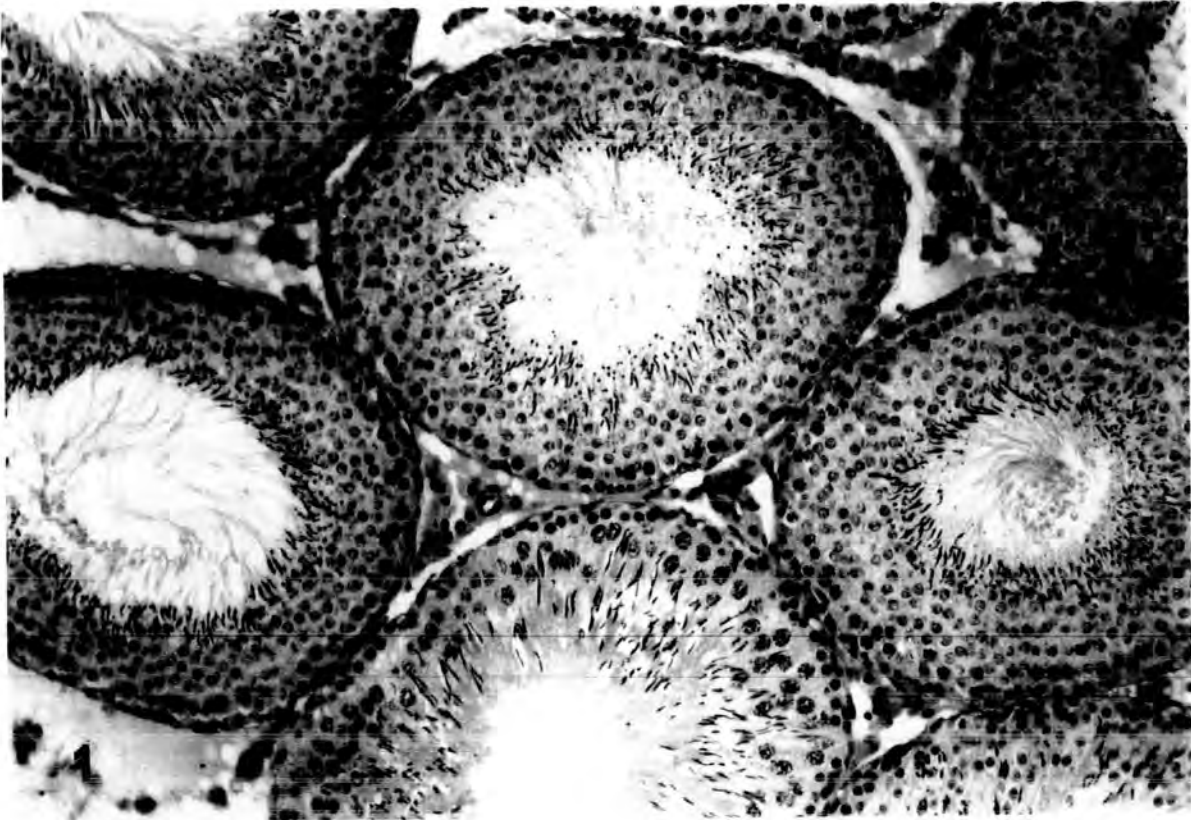
Fig.1 shows the appearance of a section from a control animal that had received 0.5 cm<sup>3</sup> of glucose carrier medium . This is a typical view of the rat testes . In no case were there any signs of damaged tubules in cross-sections from control animals .

Cross sections from 180 experimental rats were examined for evidence of histological damage to the seminiferous epithelium . It was evident that not in all animals damage was caused ( There was no effect in the large animals ( 200 - 250 g. ) ) . It was evident too that the nature of the damage is differed in different tubules . For convenience , the types of

Plate 1

Fig. 1 Light micrograph of transverse section of a testis from control animal that received 0.5 cm<sup>3</sup> of glucose carrier medium intraperitoneally . The seminiferous tubules show normal spermatogenic progression and contain all types of germinal epithelial cells .

X 180



damaged tubules observed were classified in the following manner :

1- " Slightly " damaged tubules :

These were the tubules which looked more or less normal but which showed a little damage . In the presence of that type of damage , it was possible to determine accurately the exact stage of the cycle . "Slightly" damaged tubules were subdivided into two categories :

(a) Tubules with a vacuolated appearance :

Examples of tubules showing this type of damage are shown in plate 2 , with a corresponding tubule , in the same stage of spermatogenesis ( Leblond and Clermont , 1952 ) from control animals . Often vacuolation was the only sign of damage , but in some tubules it occurred in combination with other damage ( see plate 3 ) .

What causes vacuole formation is not clear , it could equally well be through the exfoliation of damaged cells as by the accumulation of fluid forcing neighbouring cell apart . In some cases , when the vacuole was formed , it causes a small finger to project from tubule ( see plate 3 , fig.6 ). Larger vacuoles in more damaged tubules frequently resulted in an inward distortion of the boundary tissue of the tubule ( see plate 3 , fig.8 ).

The number of vacuoles seen in any one damaged tubule in cross section varied from one to seven ( see plate 3 , fig,9 ) .

(b) Absence of the late spermatid stage in spermiogenesis :

In many testes where damage was evident , a common pattern was to find tubules that were otherwise normal except that they were devoid of or had a paucity of maturing spermatids . This is shown for different tubules in different stages of the cycle in plate 5 .

Tubules with a vacuolated appearance and tubules containing no late spermatids were taken as being the least severe damage .

Plate 2

Fig.2 High power light micrograph of transverse section of a testis from an animal injected with 0.1 cm<sup>3</sup> of Mepivacaine-HCl , 4% , and killed after 6 hours, showing " slight " damage caused to a seminiferous tubule at stage IV of the spermatogenic cycle . This form of damage is the presence of vacuoles ( V ) within the seminiferous epithelium and near the boundary tissue .

X 250

Fig.3 High power light micrograph of transverse section of a testis from a control animal at stage IV showing normal spermatogenic epithelium .

X 250

Fig.4 High power light micrograph of transverse section of a testis from an animal injected with 0.5 cm<sup>3</sup> of Mepivacaine-HCl , 4% , and killed after 6 hours, showing a marked loss of late spermatids ( arrow heads ) from a seminiferous tubule at stage VII and vacuolation inside the seminiferous epithelium ( V ) . Note the slight folding of the boundary tissue ( bt ) .

X 250

Fig.5 High power light micrograph of transverse section of a testis from a control animal at stage VII showing the typical epithelium characteristic of this stage .

X 250

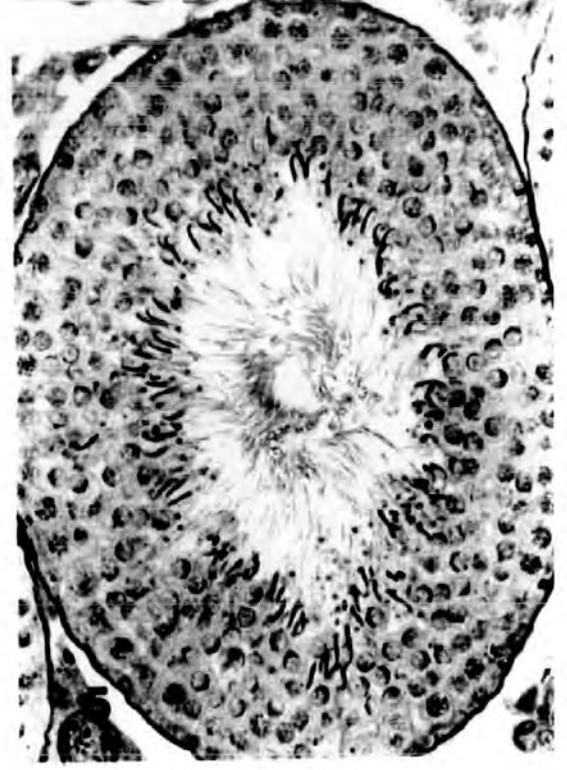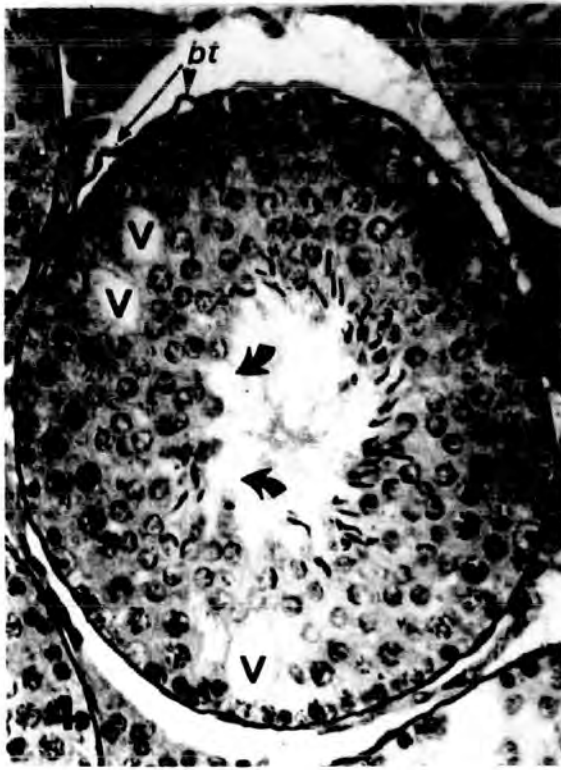
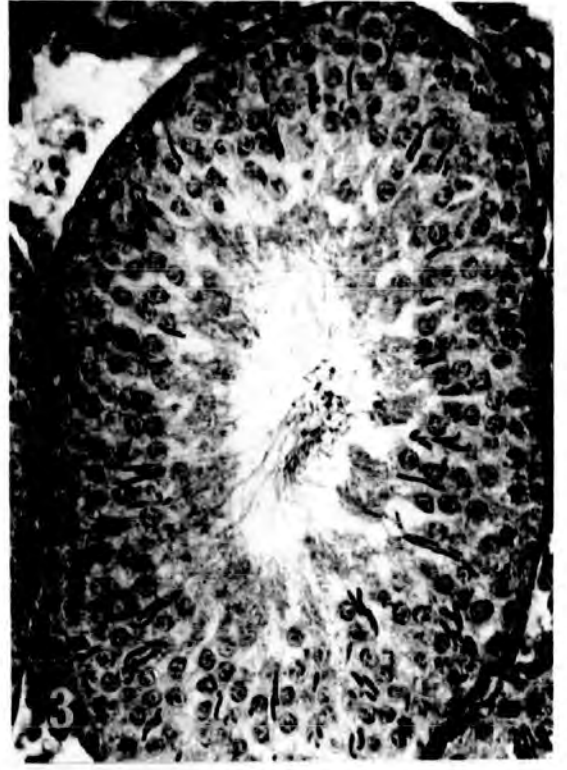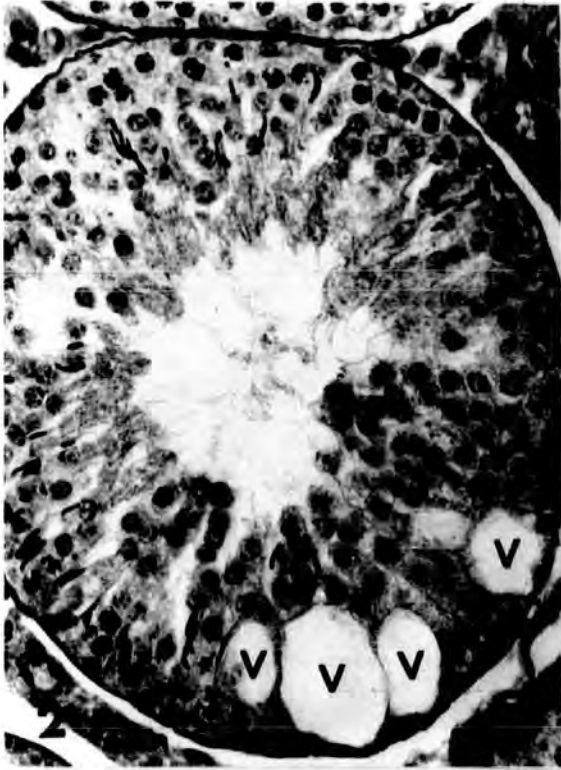


Plate 3

Fig.6 Low power light micrograph of transverse section of a testis from an animal injected with 0.1 cm<sup>3</sup> of Mepivacaine-HCl , 4% , and killed after 24 hrs. The seminiferous tubules are nearly normal but there are several peripheral vacuoles forming small finger-like projections ( arrows ) by pushing the boundary tissue with first outer layer of spermatogenic epithelium outwards .

X 100

Fig.7 Low power light micrograph of transverse section of a testis from an animal injected with 0.1 cm<sup>3</sup> of Mepivacaine-HCl , 4% , and killed after 6 hours. Completely rounded vacuoles ( V ) are seen within an otherwise typical seminiferous epithelium .

X 100

Fig.8 High power light micrograph of transverse section of a testis from an animal injected with 0.5 cm<sup>3</sup> of Mepivacaine-HCl , 4% , and killed after 12 hrs. Note the distortion of the boundary tissue of the tubule ( arrow ) .

X 100

Fig.9 Low power light micrograph of transverse section of a testis from an animal injected with 0.25 cm<sup>3</sup> of Mepivacaine-HCl , 4% , and killed after 6 hours. The number of vacuoles seen in any one damaged tubule in cross section varied from one to seven ( asterisks ) .

X 100

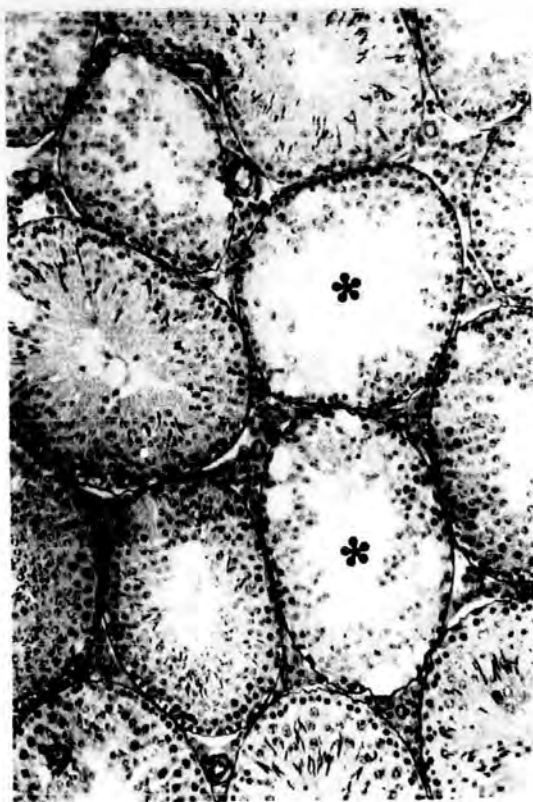
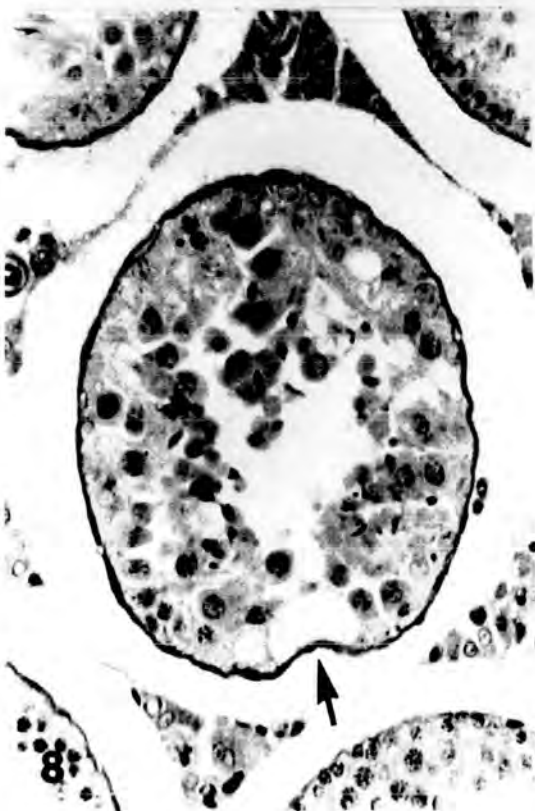
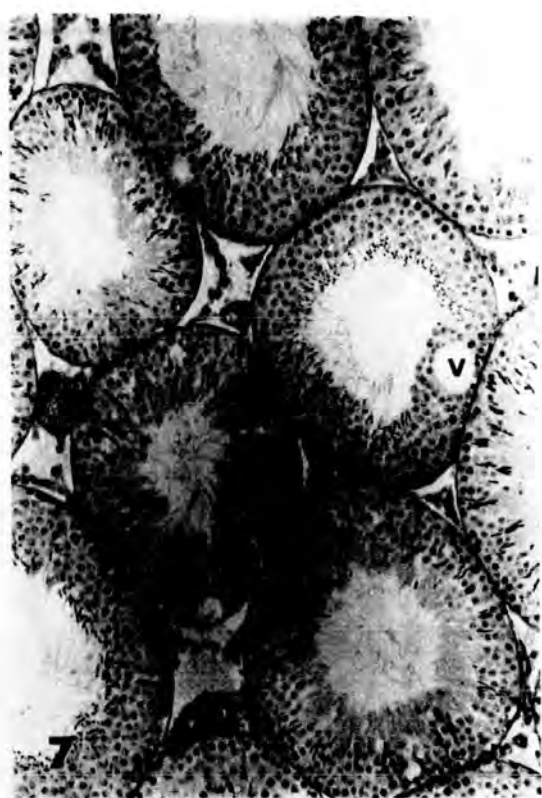
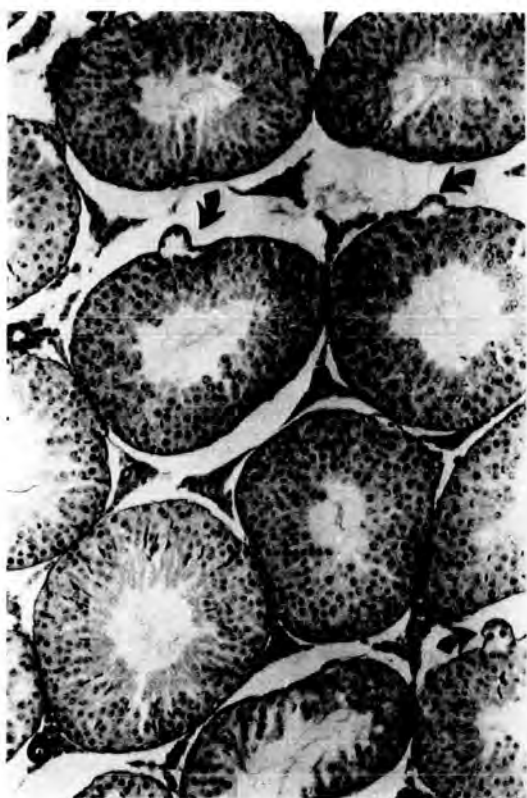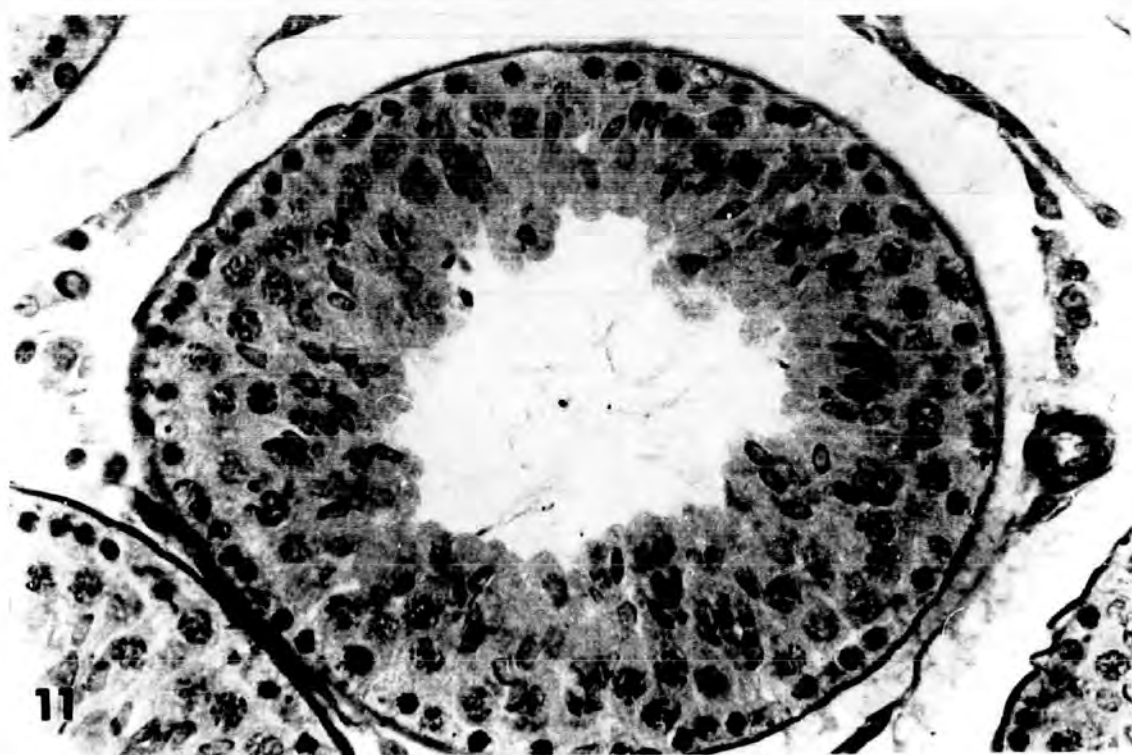
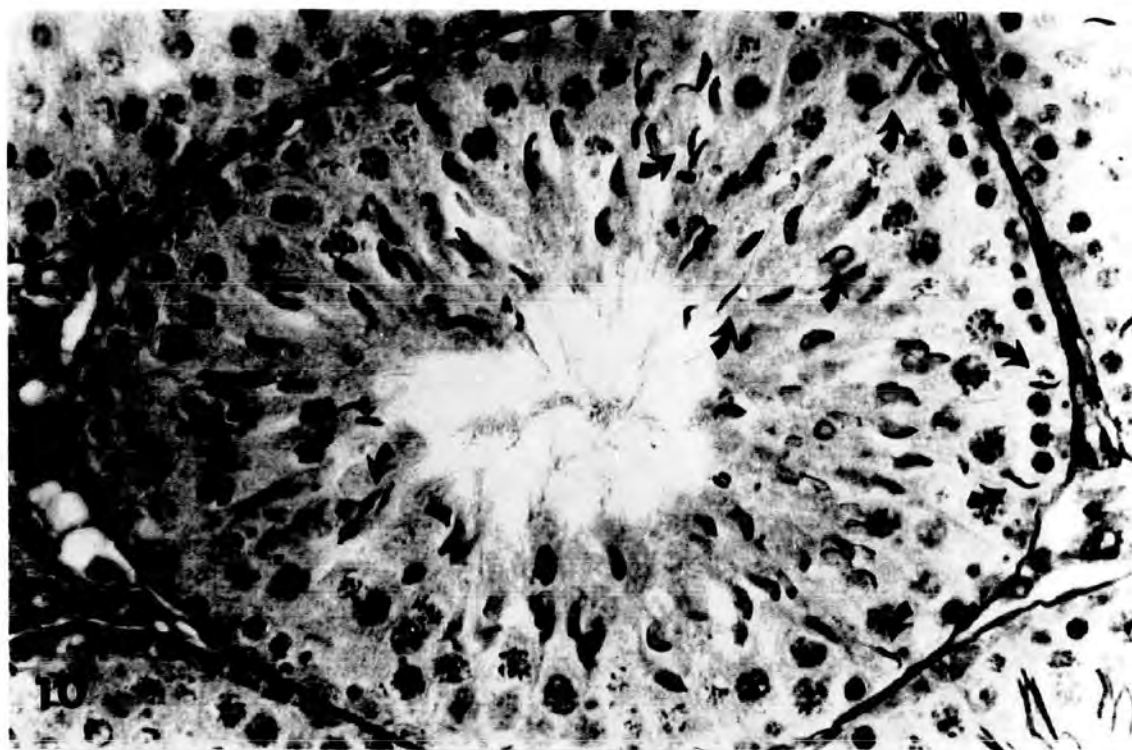
Plate 4

Fig.10 High power light micrograph of transverse section of a testis from an animal injected with 0.5 cm<sup>3</sup> of Mepivacaine-HCl , 4% , and killed after 24 hours . Late spermatids , sometimes , lose their orderly arrangement in the tubules and are not cast off , but the nuclear staining and shape are maintained . Note that there are some late spermatids and late spermatid heads ( arrows ) still attached to the basal regions of the Sertoli cells near the boundary tissue , while others hang at different levels in Sertoli cell cytoplasm .

X 500

Fig.11 High power light micrograph of transverse section of a testis from a control animal illustrating stage X with their normal , characteristically elongated , spermatids . Note this stage does not contain any late spermatids.

X 500



2- " Partially " damaged tubules :

The definition of " Partially " damaged tubules was that used by Bowler ( 1972 ) . These were tubules in which it was not possible to determine accurately the exact stage of the cycle as defined by Leblond and Clermont ( 1952 ) . These tubules contained some normal germ cells but the epithelium may be reduced almost to a ring of spermatogonia and Sertoli cells.

In the " partially " damaged tubules , exfoliation of primary spermatocytes ( especially in the diplotene stage ) and spermatids and development of a few numbers of multinucleate spermatids was seen ( plate 7, fig.21 ). The late spermatids may either be present where they would be expected , together with intermediate spermatids having irregular shaped nuclei ( plate 7, fig.19 ) or absent ( Plate 7 , figs.21 & 22 ) . The late spermatids , sometimes , loose their orderly arrangement in the tubules and are not cast off , but the nuclear staining and shape are maintained . In this case some late spermatids and late spermatid heads remain attached to the basal regions of the Sertoli cells near the boundary tissue , whilst others hang at different levels in Sertoli cell cytoplasm ( Plate 4 , fig. 10 ) .

After migration of pyknotic spheres and damaged cells to the lumen , they leave behind grossly vacuolated Sertoli cells ( Plate 5 , figs.13 & 14 ; Plate 6 , fig. 17 ) .

3- " Severely " damaged tubules :

Here again the definition suggested by Bowler ( 1972 ) has been used. These tubules were ones in which only a ring of Sertoli cells and / or damaged germ cells remained in cross section . Examples are shown in plates 8 & 9 .

The " severely " damaged tubules were shrunken and their boundary

Plate 5

Fig.12 High power light micrograph of transverse section of a testis from an animal injected with  $0.1 \text{ cm}^3$  of Mepivacaine-HCl , 4% , and killed after 6 hours , showing complete absence of late spermatids from stage VII of Leblond & Clermont's ( 1952 ) classification . The decrease in size of the tubules leads to slight shrinkage of the boundary tissue (bt), leaving a wide space ( asterisks ) between the interstitial tissue and the tubule .

X 250

Fig.13 High power light micrograph of transverse section of a testis from an animal injected with  $0.5 \text{ cm}^3$  of Mepivacaine-HCl , 4% , and killed after 6 hours . This shows a marked increase in the number of step 2 early spermatids , which may reflect the retarded spermiogenesis . Note the almost complete absence of late spermatids and fibrosis ( f ) which results from migration of the spermatogenic cells toward the lumen .

X 250

Fig.14 High power light micrograph of transverse section of a testis from an animal injected with  $0.1 \text{ cm}^3$  of Mepivacaine-HCl , 4% , and killed after 6 hours . Very few late spermatids are still found within the seminiferous epithelium .

X 250

Fig.15 High power light micrograph of transverse section of a testis from an animal injected with  $0.1 \text{ cm}^3$  of Mepivacaine-HCl , 4% , and killed after 6 hours , showing that late spermatids are missing from the seminiferous tubule .

X 250

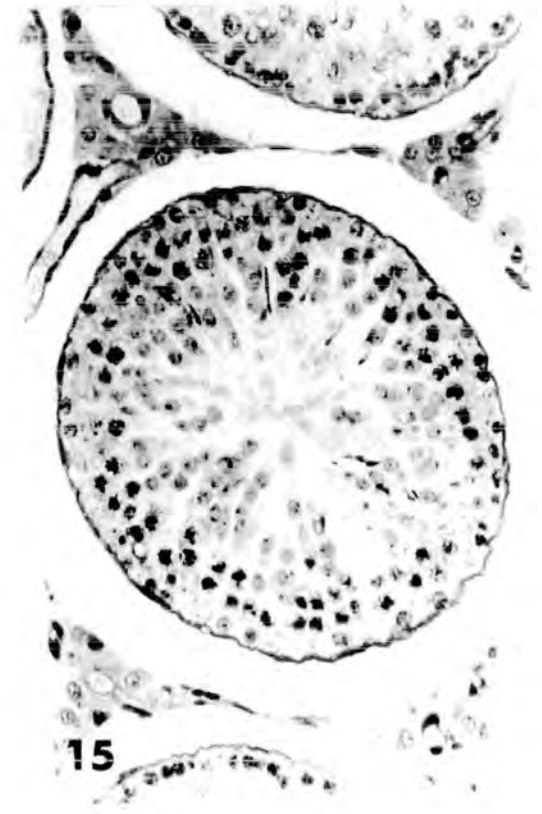
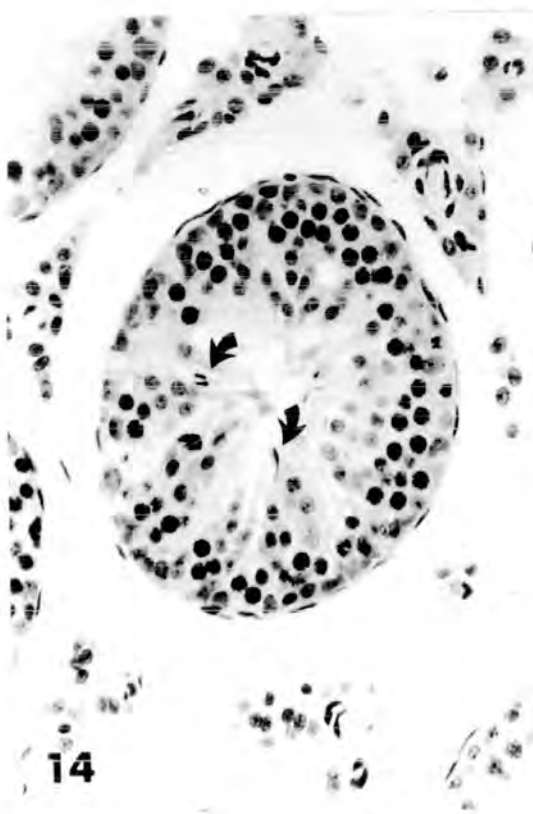
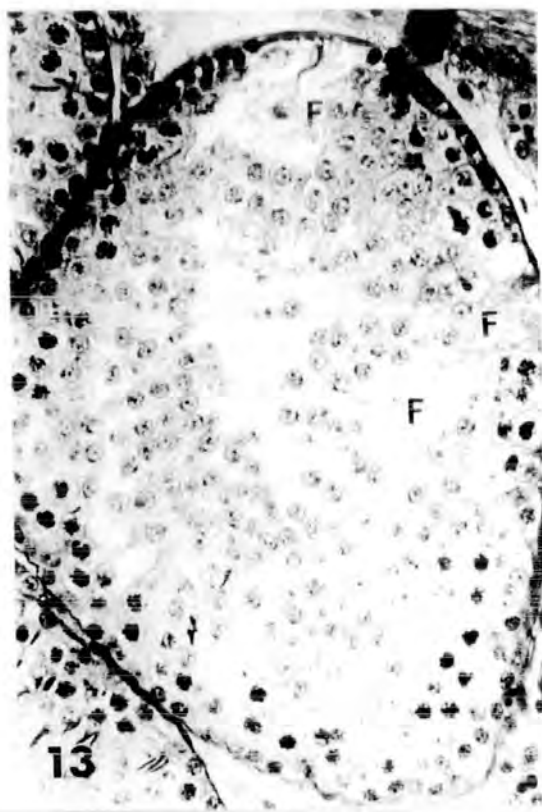
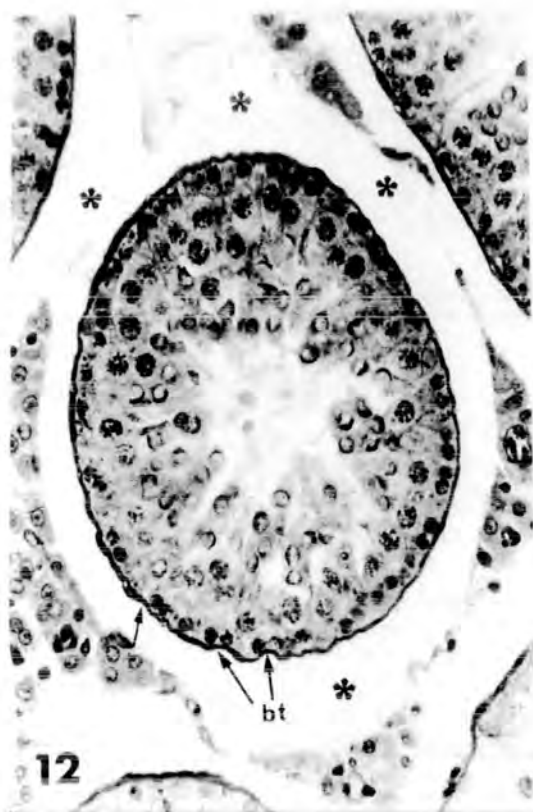

Plate 6

Fig.16 Low power light micrograph of transverse section of a testis from an animal injected with  $0.5 \text{ cm}^3$  of Mepivacaine-HCl , 4% , and killed after 6 hours . The early stages of germ cells are present , including primary spermatocytes and early spermatids , but late spermatids are virtually absent from most of the seminiferous tubules . The early spermatids ( spd ) increased in number , this increase is indicative of retarded spermiogenesis .

X 100

Fig.17 Low power light micrograph of transverse section of a testis from an animal injected with  $0.1 \text{ cm}^3$  of Mepivacaine-HCl , 4% , and killed after 6 hours . Pyknotic primary spermatocytes ( A ) , giant multinucleate spermatids ( B ) , and pyknotic young spermatids ( C ) are evident . Mature or late spermatids are absent from all the tubules .

X 100

Fig.18 Low power light micrograph of transverse section of control testis of rat showing normal spermatogenic epithelium .

X 180

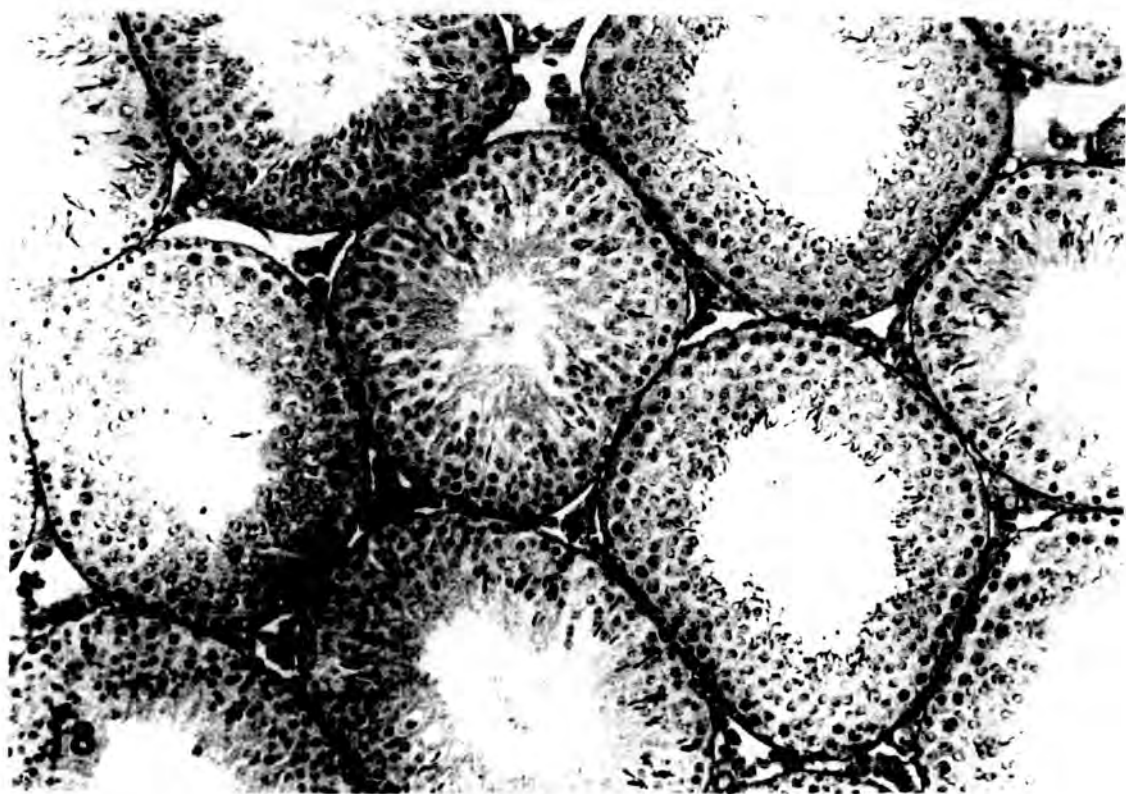
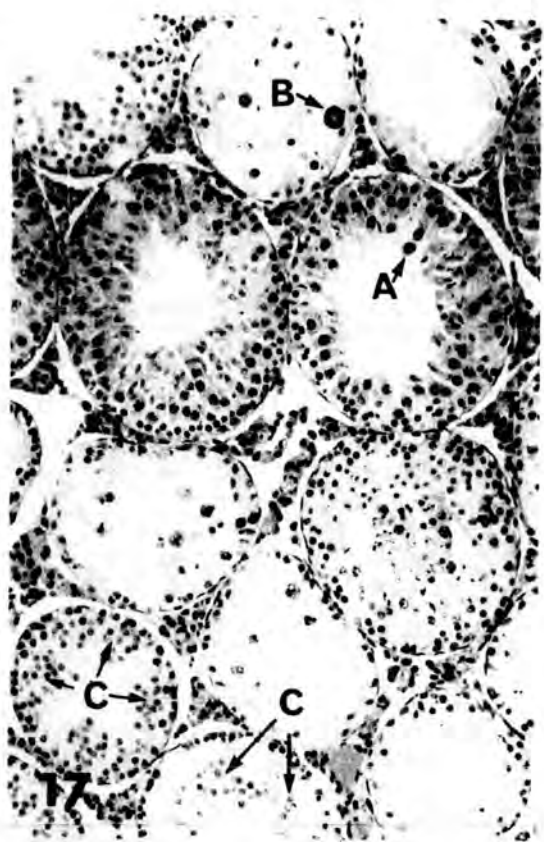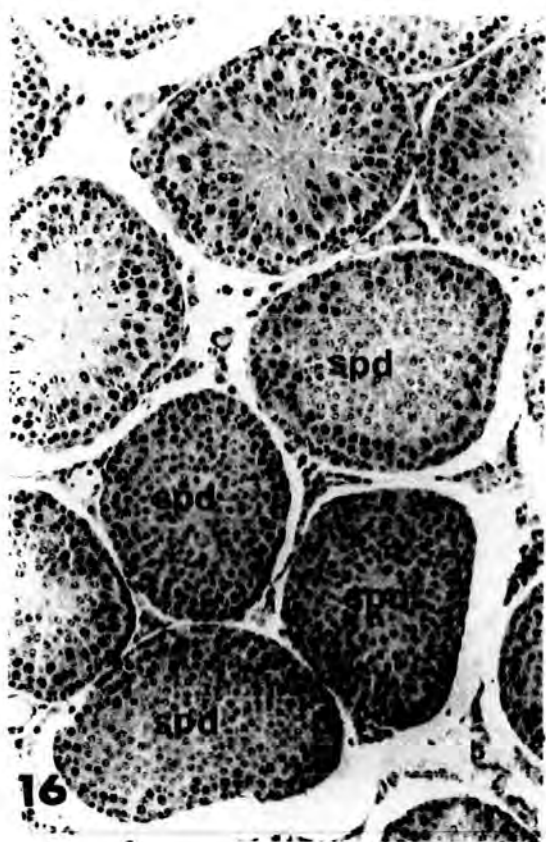


Plate 7

Fig.19 Low power light micrograph of transverse section of a testis from an animal injected with 0.25 cm<sup>3</sup> of Mepivacaine\_HCl , 4% , and killed after 24 hours , showing a moderate damage . Seminiferous tubules containing expected germinal cells for that stage of the cycle are evident . Other tubules show a reduced number ( \* ) or complete absence of late spermatids ( \* \* ) .

X 100

Fig.20 High power light micrograph of transverse section of a testis from an animal injected with 0.5 cm<sup>3</sup> of Mepivacaine\_HCl , 4% , and killed after 6 hours , showing a "partially" damaged seminiferous tubule . This tubule completely lacks spermatids but has some elongated spermatocytes ( arrows ) .

X 250

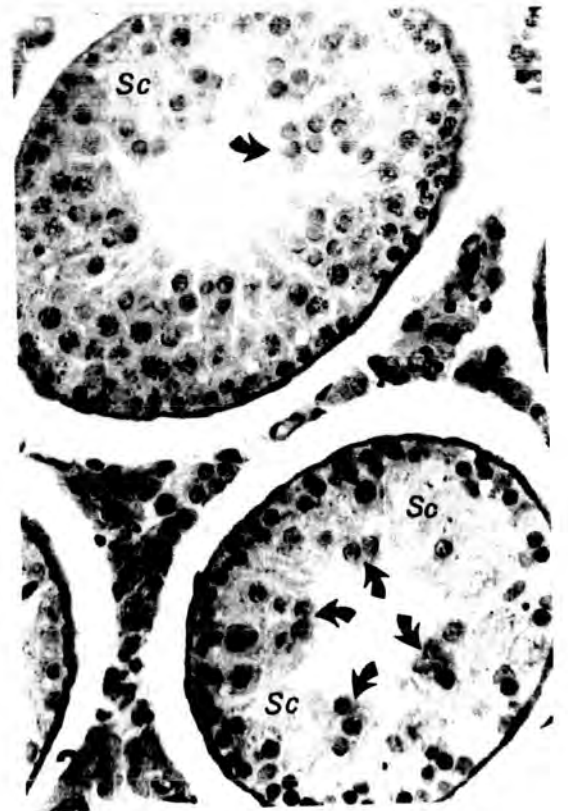
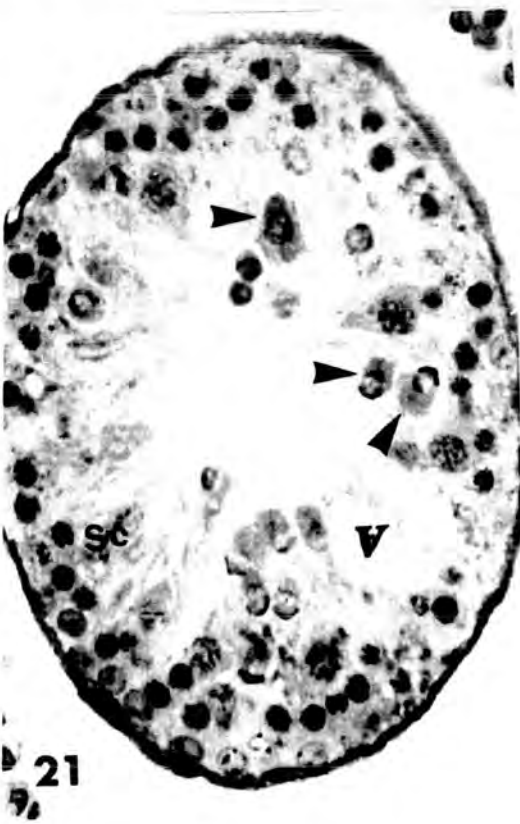
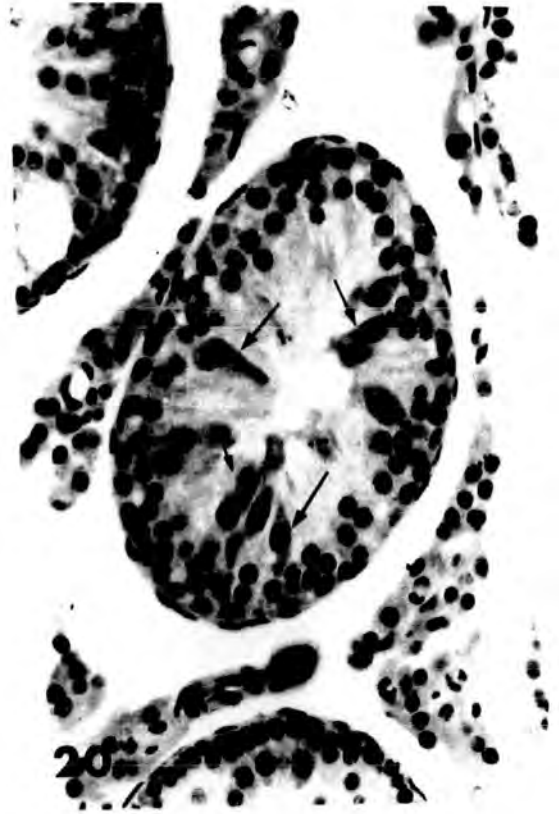
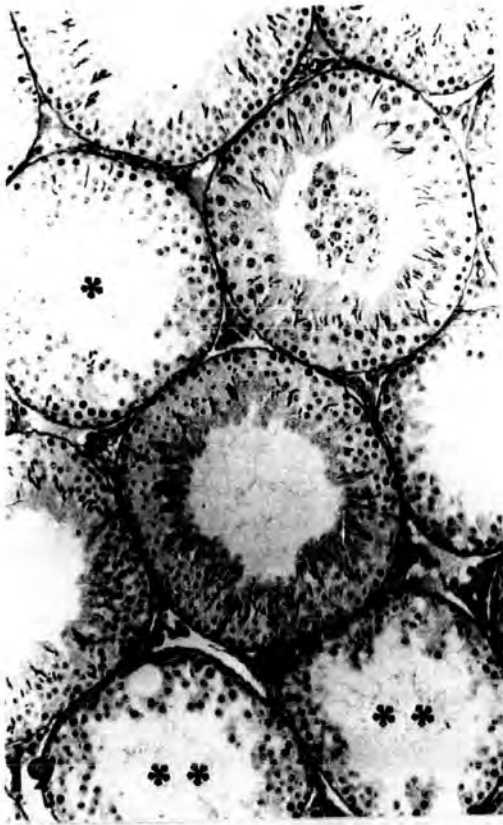
Fig.21 High power light micrograph of transverse section of a testis from an animal injected with 0.25 cm<sup>3</sup> of Mepivacaine\_HCl , 4% , and killed after 6 hours .

X 400

Fig.22 High power light micrograph of transverse section of a testis from an animal injected with 0.1 cm<sup>3</sup> of Mepivacaine\_HCl , 4% , and killed after 12 hours .

X 250

Both fig.21 , and fig.22 show "partially" damaged tubules at about stage VII of the cycle ( Leblond & Clermont , 1952 ) . In these tubules some early spermatids displayed cytoplasmic density (arrow heads) and some migrated towards the lumen(arrows) . After migration of these pyknotic and damaged cells , they leave behind grossly vacuolated(V) Sertoli cell cytoplasm (So). Note that late spermatids are completely absent from tubule in both figures .



tissue assumed a collapsed and corrugated appearance . The content of such damaged seminiferous tubules was an amorphous mass which coloured faintly pink with PAS-reaction . As can be seen in plate 8 , fig.25 , no cells remain within these damaged tubules other than Sertoli cells and few B-type spermatogonia . The degenerating spermatogenic cells became denser , with disintegration of the cytoplasm ( plate 8 , fig. 26 ) . The Sertoli cell cytoplasm appeared to be vacuolated to the extent of disintegration and in some cases the Sertoli cell cytoplasm had a fibrous appearance ( see also plate 55 , fig.101 , chapter 6 ) .

Degenerating late spermatids were occasionally seen . The heads of most of them were broken , twisted and detached from the middle piece and seen embedded in Sertoli cell cytoplasm ( Plate 9 , fig.27A ) .

During the course of damage , bi- and multinucleate spermatids ( Plate 9 , fig.27B ) were formed by fusion of their cytoplasm ( more details on the multinucleate cells in chapter 6 ) .

In one animal only , which had received  $0.5 \text{ cm}^3$  of Mepivacaine-HCl , 4% solution , and was killed after 10 days , the testes were totally hyalinized . Only damaged interstitial cells , boundary tissue and the heads of late spermatids were still positively stained ( Plate 9 , fig. 28 ) .

Thus , the testes of rats injected intraperitoneally with different doses of Mepivacaine-HCl , have been shown to undergo histopathological changes , the most dramatic of these changes occurring in the germinal cells. This damage included : giant cell formation by fusion of spermatids and less often by fusion of spermatocytes ; a decrease in the numbers of spermatocytes in division ; the loss of normal epithelial characteristics of the tubules ;

a decrease in the abundance of late spermatids , and the accumulation of cellular debris . In some cap-phase spermatids , however , the nuclear envelope had an angular profile rather than the usual round outline . The appearance of vacuoles , mostly near the boundary tissue of the seminiferous epithelium , was indicative of minor damage , but in the most seriously damaged tubules only Sertoli cells and spermatogonia were left .

Plate 8

Fig.23 Low power light micrograph of transverse section of atrophic seminiferous tubules ( asterisks ) from an animal injected with  $0.25\text{cm}^3$  of Mepivacaine.HCl , 4% , and killed after 6 hours . These tubules contain no recognizable germinal elements , but only an amorphous mass of cellular debris . The boundary tissue ( bt ) was excessively folded .

X 100

Fig.24 Low power light micrograph of transverse section of a testis from an animal injected with  $0.25\text{cm}^3$  of Mepivacaine.HCl , 4% , and killed after 6 hours ."Severely" damaged tubules ( asterisks ) incontact with tubules which show normal spermatoc progression and contain all types of germinal cells

X 100

Fig.25 High power light micrograph of transverse section of a testis from an animal injected with  $0.25\text{cm}^3$  of Mepivacaine.HCl , 4% , and killed after 24 hours . An example of the atrophic condition which persisted in many tubules . No germinal cells other than Sertoli cells and very few spermatogonia especially of B-type ( arrows ) ( upper tubule ) , while the lower tubule shows Sertoli cells scattered in a fleecy appearing synovial-like mass. Sn, Sertoli cell nuclei

X 250

Fig.26 High power light micrograph of transverse section of a testis from an animal injected with  $0.5\text{cm}^3$  of Mepivacaine.HCl , 4% , and killed after 10 days , showing a " severely " damaged tubule . This tubule is lined by a ring of Sertoli cells and damaged B-type spermatogonia (B-spg).

X 400

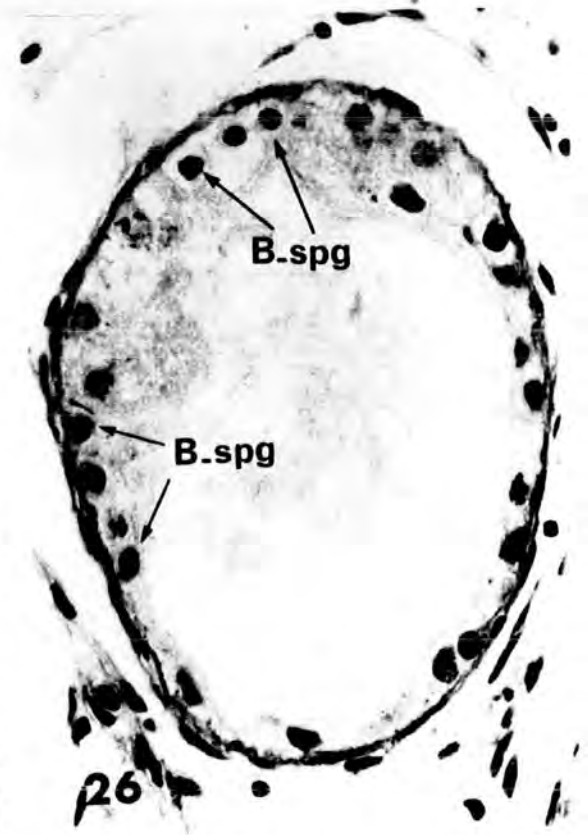
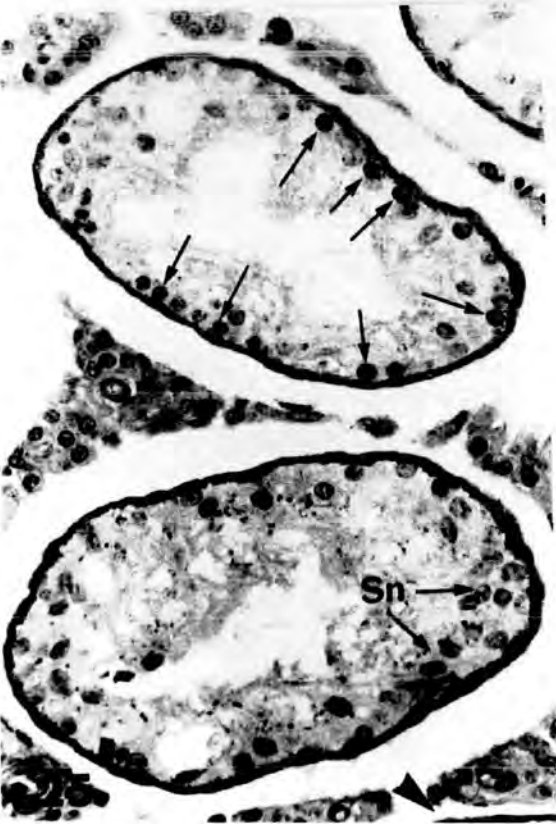
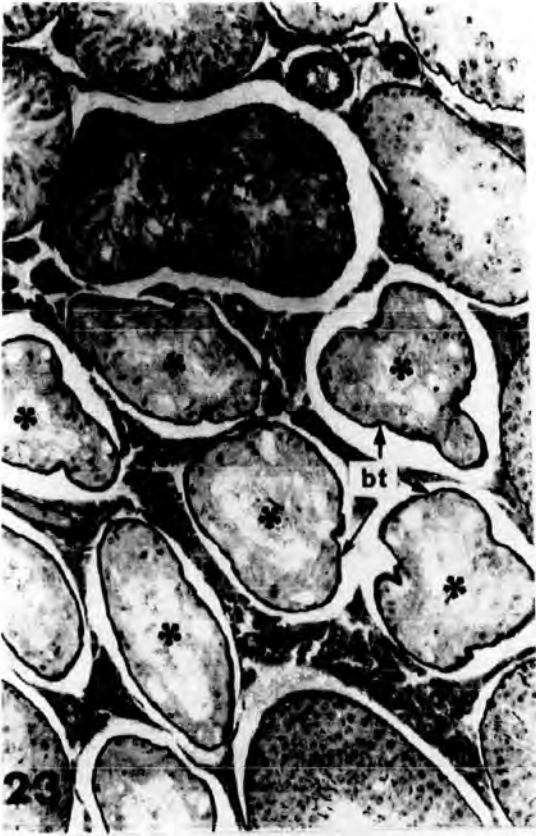


Plate 9

light  
Fig.27A Low power/micrograph of transverse section of a testis from an animal injected with 0.1 cm<sup>3</sup> of Mepivacaine\_HCl , 4% , and killed after 6 hours . Different types of cellular damage and sperm heads were detectable . The late spermatids ( arrows ) seems to be dead and are a few Sertoli cell nuclei ( Sn ) still near the boundary tissue .

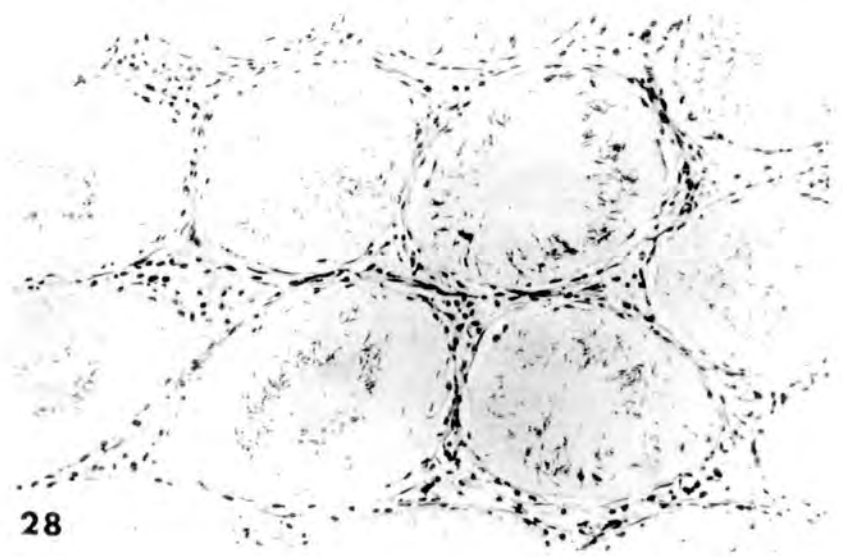
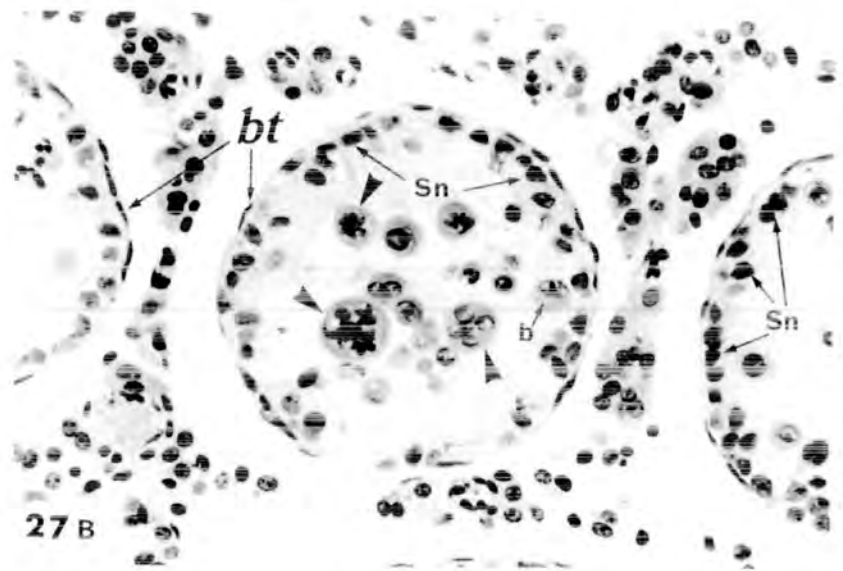
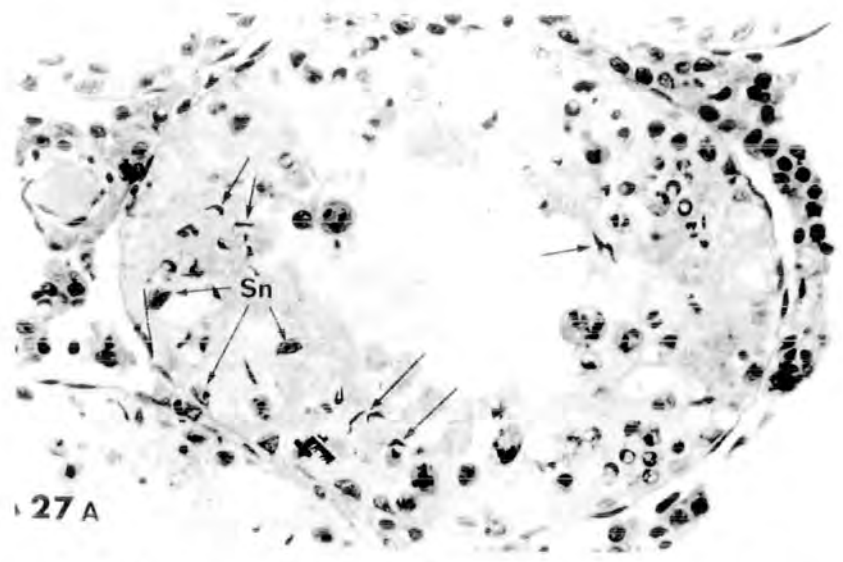
X 250

Fig.27B Low power light micrograph of transverse section of a testis from an animal injected with 0.25 cm<sup>3</sup> of Mepivacaine\_HCl , 4% , and killed after 12 hours . Binucleate ( b ) and multinucleate cells ( arrow heads ) are evident . Note the thin layer of Sertoli nuclei ( Sn ) based on the boundary tissue ( bt ) .

X 180

Fig.28 Low power light micrograph of transverse section of a testis from an animal injected with 0.5 cm<sup>3</sup> of Mepivacaine\_HCl , 4% , and killed after 10 days , showing completely hyalinized seminiferous tubules . Only interstitial nuclei , boundary tissue nuclei and heads of late spermatids were positively stained .

X 100



RELATION BETWEEN DOSE OF MEFIVACAINE-HCl , TIME AFTER TREATMENT AND TESTICULAR  
DAMAGE :

A considerable variation between animals was found within each sample group , irrespective of dose or time after injection , in the degree of damage found in a particular testis . This made the quantification of the damage caused by a particular dose difficult . Tubules were scored according to the categories of damage described earlier or as being normal .

Dose 0.1 cm<sup>3</sup> :

As can be seen from table 1 only between about 1 and 5% of tubules showed severe damage following this dose . It is not possible to argue that there was a fall in the number of severely damaged tubules after 10 days where 1.06 - 1.06% were so affected , for in the group killed after 24 hours only 1.62 - 0.95% were severely damaged . " partial " damage occurred in some 20% of tubules ( range 16.99 - 7.5% to 25.56 - 8.66% ) . Statistically significant fewer ( 5.97 - 4.39% ) tubules showed partial damage after 10 days (P=0.001). The percentage of tubules showing " slight " damage varied between 14.76 - 7.45% ( after 10 days ) and 31.36 - 9.60% ( after 24 hours ) . These percentages are not significantly different . It may be significant that the greatest number of normal tubules is seen after 10 days , this perhaps reflects some repair to the " partially " damaged tubules .

Dose 0.25 cm<sup>3</sup> :

There is an apparently progressive fall in number of tubules "severely" damaged with time , from 33.10% at 6 hours to only 8.85% after 48hours , a further fall running to 4.19% after 10 days . It is most likely this is not repair for it is not possible to repopulate a tubule with germ cells in that short time ( see Dym & Clermont , 1970 ) . This fall cannot be accounted for by the tubules regenerating to the extent of their being reclassified as

" partially " damaged tubules for those tubules show an equivalent rise in percentage numbers affected . The " partially " damaged tubules show a similar pattern to that of the  $0.1 \text{ cm}^3$  groups with 20% to 30% being found so damaged on the first four sample occasions , but only 14% after 10 days . The " slightly " damaged tubules also follow a similar pattern to the  $0.1 \text{ cm}^3$  group . Again the largest percentage of normal tubules was found in the group 10 days after the injection .

Dose  $0.5 \text{ cm}^3$  :

As in the previous group it could be seen that some decline in the percentage of " severely " damaged tubules occurs with time , for it falls progressively from 17.35% after 6 hours to only 2.52% after 10 days . However , as there is not enough time for complete repopulation to take place , nor is there a corresponding increase in the percentage of "partially" damaged tubules , so it is unlikely that this represents repair of "severely" damaged tubules . The percentage of " slightly " damaged tubules has a similar pattern to that in the  $0.1 \text{ cm}^3$  and  $0.25 \text{ cm}^3$  dose groups but otherwise no obvious pattern exists .

It would seem that the degree of damage is so variable within the 10 animals in each sample group , that no firm conclusions can be drawn of the process of repair from the original administration of the drug .

With the exception of the apparently fewer " severely " damaged tubules in the lowest dose group no obvious relationship can be seen between the amount or type of damage caused and dose rate .

When larger adult ( 200 - 250 g.) rats were injected with the three doses in no case was any testis examined that showed damage . It is concluded that this effect of Mepivacaine-HCl is body weight dependent .

Table 1

The mean number of tubules , as a percentage of the total counted ,  
 showing a form of damage or being normal.

Each sample was of 10 animals and 100 tubules from each  
 animal were scored into the four categories listed.

		Mean percentage of tubules counted showing the various categories of damage or being normal.			
Dose/time		severe	partial	slight	normal
0.1	6h.	5.50 ± 3.28	19.43 ± 7.48	17.21 ± 5.65	57.85 ± 13.73
	12h.	4.64 ± 3.37	16.99 ± 7.50	17.93 ± 4.85	60.44 ± 12.57
	24h.	1.62 ± 0.95	19.92 ± 6.43	31.36 ± 9.68	47.25 ± 14.56
	48h.	5.04 ± 2.53	25.56 ± 8.66	27.94 ± 10.78	41.44 ± 15.97
	10 days.	1.06 ± 1.06	5.97 ± 4.39	14.76 ± 7.45	78.18 ± 11.39
0.25	6h.	33.10 ± 9.77	25.32 ± 6.38	6.24 ± 2.59	35.31 ± 14.80
	12h.	19.29 ± 8.61	32.55 ± 7.93	22.64 ± 6.06	25.49 ± 10.51
	24h.	10.61 ± 5.36	21.55 ± 5.56	18.60 ± 5.61	49.22 ± 10.83
	48h.	8.86 ± 6.32	22.12 ± 6.35	26.17 ± 7.61	42.77 ± 11.45
	10 days.	4.19 ± 3.61	14.54 ± 6.00	14.66 ± 4.66	66.58 ± 10.50
0.5	6h.	17.35 ± 7.51	25.29 ± 7.27	11.64 ± 4.13	45.68 ± 13.95
	12h.	14.36 ± 6.35	25.93 ± 7.21	16.06 ± 6.35	43.66 ± 12.99
	24h.	7.60 ± 3.24	15.96 ± 7.05	12.42 ± 4.16	63.99 ± 12.94
	48h.	4.49 ± 2.67	11.63 ± 5.27	22.71 ± 8.26	61.15 ± 12.58
	10 days.	2.52 ± 1.46	30.47 ± 8.95	11.33 ± 3.58	55.67 ± 12.05

Histochemistry :

As shown in fig.29 , plate 10 , the lipids of the testicular tissue of adult rats are found in the seminiferous epithelium as well as the interstitial tissue . The lipids are found as fine granular droplets distributed through the cytoplasm of these cells .

Effect of Mepivacaine-HCl administration on lipid content :

The testes from the rats injected with different doses of Mepivacaine-HCl , 4% , showed that the lipids were present scattered within the seminiferous tubules as well as in the interstitial cells . The lipids were seen to be located both in the degenerating germ cells and in the Sertoli cells . The amount of lipids was significantly increased over that of testes from control rats . It varied from a large amount of lipid granules to large lipid droplets ( see plate 10 , fig.30 ) .

Sertoli cells of treated animals also contained many large lipid droplets . Some lipid droplets were normally present in rat Sertoli cells at certain stages of the cycle of the seminiferous epithelium ( Kerr and De Kretser , 1975 ; Fawcett , 1975 ) . The specimens from treated animals gave the impression of an increase in the amount of Sertoli-cell lipid , because droplets were present in virtually all the seminiferous tubules . Some were so closely packed in cells as to displace other organelles and indent the nucleus ( see plate 10 , fig. 30 ) .

The electron micrographs in chapter 6 will give more precise information about the increase in the amount and size of cellular lipids .

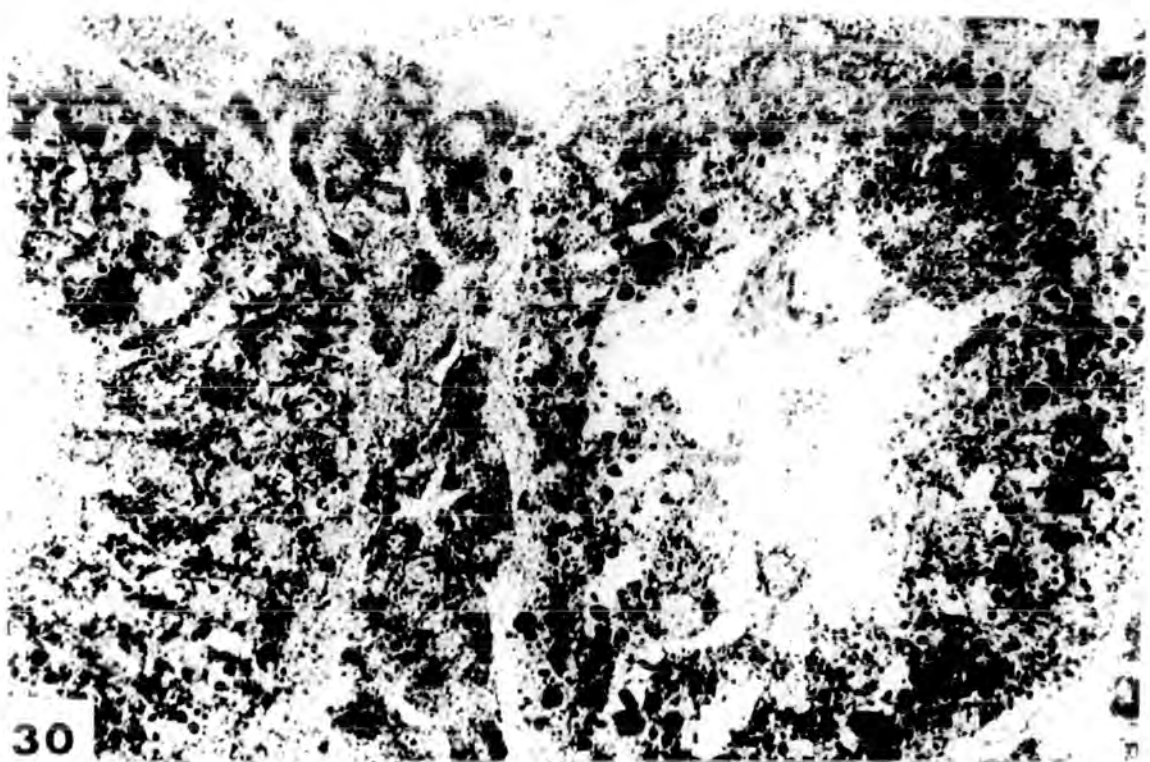

Plate 10

Fig.29 High power light micrograph of transverse section of a testis from a control animal to show the normal lipid contents in the seminiferous tubules . A small amount of finely grained lipids is distributed throughout the seminiferous epithelium and the interstitium .

Sudan Black B , X 250

Fig.30 High power light micrograph of transverse section of a testis from an animal injected with 0.5 cm<sup>3</sup> of Mepivacaine-HCl , 4% , and killed after 6 hours , showing the appearance of a large amount of lipids ranging from fine lipid granules to large lipid droplets .

Sudan Black B , X 250



Discussion :

-----

After Mepivacaine-HCl administration , especially with a high dose , 0.5 cm<sup>3</sup> ( approximately LD50 ) , deep anaesthesia occurred rapidly and some of the animals failed to recover . Very few animals succumbed at lower dose rates .

Many of the testes of the young adult treated animals appeared to be darkly discoloured . This may have resulted from the destruction of the capillaries and local haemorrhage . Bleeding and haemolysis at the site of injection was described by Ulfendahl ( 1957 ) after using 8% , 16% or 32% solution of Mepivacaine-HCl . This haemorrhagic reaction was reported also after administration of cadmium to the testis ( Gunn et al., 1963 b ) .

Morphologically , one can guess if the testis is normal or damaged by its size , because there is a marked decrease in weight in damaged testis .

The histological picture of the testes from treated animals varied greatly . In some testes only a few tubules were damaged , other tubules being normal in appearance . In other testes , however , all the seminiferous tubules were damaged to some degree . Large differences were seen even between the testes of the same animal .

Since the doses apparently did not differ in their effects ( see table 1 ) and gave more or less the same kind of damage , it was possible to classify the types of damaged tubules into : " slightly " , " partially " and " severely " damaged tubules . Vacuole formation

and the absence of late spermatids are the features of the " slightly " damaged tubules . The vacuoles appeared as prominent , large and more or less rounded . What caused vacuole formation is not clear , it could well be through the exfoliation of damaged cells , or as a result of accumulation of fluid forcing neighbouring cells apart . Thus , the formation of finger-like projections can be explained as a result of the accumulation of fluids near the boundary tissue of the tubules , exactly between the first layer of spermatogonia and Sertoli cells and the spermatocytes . As the accumulation of the fluid increases , the internal pressure at the site of fluid accumulation will increase also , this might then act to push the boundary tissue , attached spermatogonia and Sertoli cells , to form finger-like projections ( see plate 3 , fig. 6 ) . If the site of fluid accumulation is located in the middle of the epithelium , any internal pressure will act upon all the surrounding cells in all directions , giving rise to rounded vacuoles ( see plate 3 , fig. 7 ) . Finally , if the site of liquid accumulation lies near the lumen of a tubule , containing loose or detached cells , the force will push the damaged cells toward the lumen , and as a result , the boundary tissue becomes inverted inside the tubules ( see plate 3 , fig. 8 ) .

Similar large rounded vacuoles , near the boundary tissue of the seminiferous tubules of rat testis , were seen after serotonin administration by Boccabella et al. ( 1962 ) and O'steen ( 1963 ) . O'steen ( 1963 ) described these vacuoles as a result of death and resorption of

of one or more spermatogenic cells . Oettle and Harrison ( 1952 ) also reported such vacuoles formed as a result of detached cells . In the present study , it was found that , when the germ cells degenerate and exfoliate , they leave empty spaces at their normal sites . These spaces will become occupied by Sertoli cell cytoplasm which often acquires a fibrillar appearance as in plate 5 , fig. 13 . This displacement and connection of the cytoplasm of Sertoli cells is evident in plate 8 , fig.25 and plate 9 , fig.28 ( compare with the figures in plates 2 & 3 ) .

In the treated rats , the late spermatids were the cell type most readily damaged and they were frequently lost and sometimes completely absent from the tubules . Sometimes , the late spermatids lost their orderly arrangement in the tubules , were not cast off but appeared attached to the Sertoli cells cytoplasm at different levels . In these tubules the correct association of cell types , which characterises a stage , is lost . Oettle and Harrison ( 1952 ) in their studies of the histological changes produced in the testis by temporary and permanent occlusion of the testicular artery , had similar findings , and they reported that nuclear staining and shape of these late spermatids was maintained for many weeks , and , even after nuclear staining was lost , the nucleus remained distinguishable for months . Next in order of sensitivity were the early spermatids ( especially stage VII ) which showed different degrees of damage and degeneration including multinucleate cell formation . The primary spermatocytes were the next in order of sensitivity ; they showed a slight effect , mainly of morphological changes such as elongation , detachment , and exfoliation from

their normal position into the lumen of the tubules . Occasionally bi- and multinucleate cells were formed as a result of their fusion. In most instances the spermatogonia and Sertoli cells were entirely unaffected , except for slight displacement associated with tubular shrinkage . The degenerative reaction of spermatogonia appeared to be an " all or none " response , since spermatogonia in the treated testis were either entirely normal histologically or were completely absent ( especially with A-type spermatogonia ) .

These results indicated that in rats , administered Mepivacaine-HCl , germ cells developed up to early spermatid stages and then began to degenerate and die . This finding was in accord with most of the light microscopic studies , and indicated that late spermatids were the most severely depleted stages .

In both the " partially " and " severely " damaged tubules , the boundary tissue showed marked thickening and the proportion of interstitial tissue was apparently increased , probably due to the relative decrease in tubule diameters as a result of drug administration . Severe damage to the cells of interstitial tissue was seen only in one testis , which was totally hyalinized .

Many extremely large lipid droplets were present in the seminiferous epithelium of the treated animals as well as in the interstitial cells . An increase in lipid content is characteristic of conditions in which spermatogenesis is disrupted . It has been reported following cryptorchidism , hypophysectomy , local heating , and oestrogen treatment

( Hans and Rosenbloom , 1911b; Lynch and Scott , 1951 ; Iacy , 1962 ; Iacy and Lofts , 1965 ; Collins and Iacy , 1969 ) and testicular feminization syndrome ( Chung , 1974 ) .

It has been reported that when germ cell development is suppressed by treatment with oestrogenic hormones ( Iacy and Lofts , 1965 ) or when they are totally destroyed by high doses of ionizing radiation ( Iacy , 1962 ) large amounts of lipids / sterols accumulate in the Sertoli cells .

Idanpaan-Heikkila ( 1966 ) has stated that exposure to a temperature of 44 C for 20 minutes caused an increase in the lipid content of the Sertoli cells and that large lipid droplets appeared in the cells based at or near the boundary tissue . Also, / Iacy ( 1969 ) reported that there was clear evidence of degenerating germ cells , resulting from a single exposure to heat , being phagocytosed by Sertoli cells which caused an increase in the lipid content of Sertoli cells .

In general , the lipid fractions tend to increase as the testis is devoid of spermatozoa and testicular fluid ( Johnson , 1970 ) . In vas deferens ethanol injected rats , the total lipids increased significantly in the testis as it became devoid of spermatozoa and filled with degenerating germinal elements ( Dixit et al., 1976 ) .

The increase in lipid in the testes of treated animals might be acquired from the cytoplasm of ingested germ cells . This is thought to be the cause for the appearance of lipid in Sertoli cells at stage IX of the normal cycle of the seminiferous epithelium . Alternatively , the

accumulation of lipid could be due to an alteration in the metabolism of the Sertoli cells themselves in the presence of the drug , because lipid accumulation is a well known pathological change that occurs in many cells under a variety of deleterious conditions ( Robbins , 1974 ).

As already shown from the results , the damage occurring after Mepivacaine-HCl injection is clearly different from that after scrotal heating . The cells most sensitive to heating were the primary spermatocytes ( stage IX and XIV ) and step 1 spermatids ; while older spermatids were more resistant ( Steinberger and Dixon , 1959 ; Collins and Iacy , 1969 ; Chowdhury and Steinberger , 1970 ; Parvinen , 1973 ) . In the present study primary spermatocytes were lost from some tubules and sometimes their cytoplasm showed marked elongation , but there was no evidence for the loss of step 1 spermatids . It was , instead , the older generation of spermatids that was most frequently lost , particularly in tubules III - V of the cycle . In this respect the damage also differs from that following ischaemia ( Steinberger and Tjioe , 1969 ) .

Glucose is an essential requirement for the proper functioning of the testicular tissue ( Setchell and Waites , 1964 ) and its depletion in the blood supply together with a decrease in the availability of oxygen has been suggested as one of the main causes of testicular failure when the testis is exposed to elevated temperatures .

Dutt et al. ( 1977 ) , reported that , after exposure of rams to elevated temperature for 7 days , blood flow to the testes decreased significantly ; the wall of the spermatic artery in the middle region of the pampiniform plexus was 62 per cent thicker , and the area of the

lumen was reduced by 48 per cent . They concluded that the reduced blood flow to the heated testis was associated with a thickening of the wall and a reduction in size of the lumen of the spermatic artery in the pampiniform plexus , this reduction of blood flow to the testis being responsible for impaired spermatogenic function .

Some pathological changes in the testis due to injection of progestin and androgen into rats ( Flickinger , 1977 a ) were similar to damage caused by Mepivacaine-HCl injection , while others were different . The similarity in damage of the two agents is that in both of them many degenerating or necrotic spermatids of the cap-phase ( approximately stages 6 - 7 ) and later were present . Late spermatids of the acrosome and maturation phases were rare . Some necrotic spermatids were surrounded by Sertoli cells , and parts of spermatids lay within the cytoplasm of Sertoli cells . Many large lipid droplets were also present in Sertoli cells of both treated rats .

On the other hand , Flickinger ( 1977 a ) reported that in the progestin and androgen injected rats , spermatogonia , spermatocytes and early spermatids were abundant and did not show ultrastructural changes , while in Mepivacaine-HCl injected rats , it was found in this study that spermatogonia , spermatocytes and early spermatids ( until step 5 ) were slightly affected mainly in the cytoplasmic organelles such as mitochondria and Golgi apparatus ( see chapter 6 ) .

The injurious effect of 5-hydroxytryptamine ( Boccabella et al., 1962 ; O'steen , 1963 ; Korman et al., 1968 ) and histamine

( O'steen , 1963 ) on rat testes has been reported . These authors found that the seminiferous tubules showed degrees of degeneration ranging from a rather minor change , such as pyknosis of spermatogonial cells in an otherwise normal tubule , to a striking absence of all cells , excepting a single outer layer . Also , there was sloughing of the spermatogenic epithelium and formation of degenerated multinucleate giant cells . They pointed out that these degenerative changes did not occur at any specific step of spermatogenesis , but in some tubules it was the cap phase spermatids that were degenerated . The spermatogonia seemed to be the germ cells most resistant . The boundary tissue of the tubules was thickened and the proportion of interstitial tissue was increased . Severe damage to the cells of interstitial tissue was seen only in one testis , which was totally hyalinized .

The result of the present investigation shows that the injurious effect of Mepivacaine-HCl is similar to that of 5-hydroxytryptamine and histamine . Also , the pathological changes in the testis of Mepivacaine-HCl treated rats are morphologically identical to those described following the occlusion of the testicular artery in rats ( Oettle and Harrison , 1952 ) .

Boccabella et al. ( 1962 ) concluded that 5-hydroxytryptamine injury to the testis resulted from reduced blood flow , because the simultaneous administration of vasodilator prevented the testis damage . The result of Kormanó et al. ( 1968 ) supported this hypothesis as they found no evidence for 5-hydroxytryptamine penetration into testicular tissue and they also concluded that temporary ischaemia was the most likely cause of the injury .

O'steen ( 1963 ) considered that such agents as 5-hydroxytryptamine and histamine would be too rapidly metabolized to have a long enough effect on blood flow through the testes to cause injury . Instead he suggested that such drugs may act indirectly through a neurotoxic effect on the endocrine system .

On the other hand , 5-hydroxytryptamine and histamine are classified as hormones , frequently have similar pharmacological effects as evidenced by studies on vascular permeability ( Majno and Palade , 1961 ; Majno et al., 1961 ) and vasoconstriction ( Haddy , 1958 ; Haddy et al., 1959 ) .

Cross and Silver ( 1962 ) and Waites and Setchell ( 1966 ) have drawn attention to the extreme sensitivity of spermatogenesis to reduced blood flow . Mepivacaine-HCl is reported to have vasoconstrictor effects ( Aberg and Adler , 1970 ; Aberg and Anderson , 1972 ; Aberg and Wahlstrom , 1972 ; Dhuner et al., 1972 ) , and it may therefore cause sufficient ischaemia to impair spermatogenesis . However , although the effects of temporary ischaemia , as reported by Oettle and Harrison ( 1952 ) , apparently resemble those caused by Mepivacaine-HCl injection, the more detailed account of the response to ischaemia by Steinberger and Tjioe ( 1969 ) differs significantly from the effect of Mepivacaine-HCl described here .

According to the findings of Cross and Silver ( 1962 ) ; Waites and Setchell ( 1966 ) and Dutt et al.( 1977 ) , beside our knowledge that Mepivacaine-HCl has vasoconstrictor effects , we can report that the injurious effect of the administration of Mepivacaine-HCl , 4% , intraperitoneally is probably due to reduced blood flow to the testis .

# Chapter 4

Chapter 4

Effect of single low doses of Mepivacaine-HCl on  
the histology of the testis

---

Introduction :

Since the three high doses of Mepivacaine-HCl used in chapter 3 ( 0.1 , 0.25 & 0.5 cm<sup>3</sup> ) were not different in their effects on the testes , it was decided to look at lower doses to try to determine the minimum dose at which Mepivacaine-HCl causes damage to the testis .

Methods :

Both control and experimental rats ( groups D & E ) were killed after 24 and 48 hours . The testes were removed , fixed in Bouin's fixative, embedded in paraffin wax and sectioned at 5µm . The sections were stained with Mayer's haematoxylin and eosin , as was described in chapter 2 .

Results :

HISTOLOGICAL APPEARANCE OF THE TESTIS :

1- 0.05 cm<sup>3</sup> , Mepivacaine-HCl , 4% , injected group :

The animals killed 24 hours after receiving 0.05 cm<sup>3</sup> of Mepivacaine-HCl ( 4% solution ) showed testis damage which was mainly of the " slight " type . Some tubules contained clear rounded vacuoles based near the boundary tissues , others showed that late spermatids were either absent or few in number . Tubules with a complete spermatogenic epithelium were found together with these slightly damaged tubules ( see plate 11 , fig.31 ) .

Forty-eight hours after a single injection with  $0.05 \text{ cm}^3$  of Mepivacaine-HCl , 4% solution , exfoliated degenerating spermatocytes and late spermatids appeared in the lumen of some tubules which were otherwise more or less normal . " Slightly " damaged tubules similar to those described after 24 hours were also evident ( see plate 11 , figs.32A & 32B ) .

2-  $0.05 \text{ cm}^3$  , Mepivacaine-HCl , 2% , injected group :

Most the seminiferous tubules of the testes from the animals which received  $0.05 \text{ cm}^3$  Mepivacaine-HCl , 2% solution , and were killed after 24 hours showed " slight " damage . This mainly took the form of tubules with normal appearance except that late spermatids were missing . In some tubules also young spermatids tended to exfoliate . There were also some normal tubules present ( see plate 12 , figs. 33 & 34 ) .

" Slightly " and " partially " damaged tubules incontact with normal tubules could be found 48 hours after a single injection with  $0.05 \text{ cm}^3$  Mepivacaine-HCl , 2% solution . In both " slightly " and " partially " damaged tubules , vacuoles arose close to the boundary tissue , and some slightly damaged tubules showed marked exfoliation of the early spermatids ( see plate 13 , figs. 36 & 37 ) .

The effect of these single low doses of Mepivacaine-HCl on testes was quantified in table 2 . In no case any " severely " damage tubules were seen .

The " slight " damage caused to the testes after intraperitoneal administration of Mepivacaine-HCl , 2% with a dose of  $0.05 \text{ cm}^3$  can be seen by the fall in numbers of normal tubules from 70.83 - 2.51% after 24 hours to 61.16 - 3.89% after 48 hours . Also , the percentage of tubules

Plate 11

Fig.31 Low power light micrograph of transverse section of a testis from an animal injected with  $0.05 \text{ cm}^3$  of Mepivacaine-HCl , 4% , and killed after 24 hours . The damage is restricted to the " slight " type only , which comprises both vacuolation ( v ) and tubules where late spermatids are absent ( \* \* ) . Also normal tubules are evident ( \* ) . X 100

Fig.32A Low power light micrograph of transverse section of a testis from an animal injected with  $0.05 \text{ cm}^3$  of Mepivacaine-HCl , 4% , and killed after 48 hours. Tubules without late spermatids ( \* \* ) and seminiferous tubules containing exfoliated degenerating cells in the lumen , are the most characteristic feature of the sections . X 100

Fig.32B High power light micrograph of transverse section of a testis from an animal injected with  $0.05 \text{ cm}^3$  of Mepivacaine-HCl , 4% , and killed after 48 hours . The lumen of a seminiferous tubule is full of exfoliated pyknotic cells . Note a small vacuole inside the seminiferous epithelium.

X 250

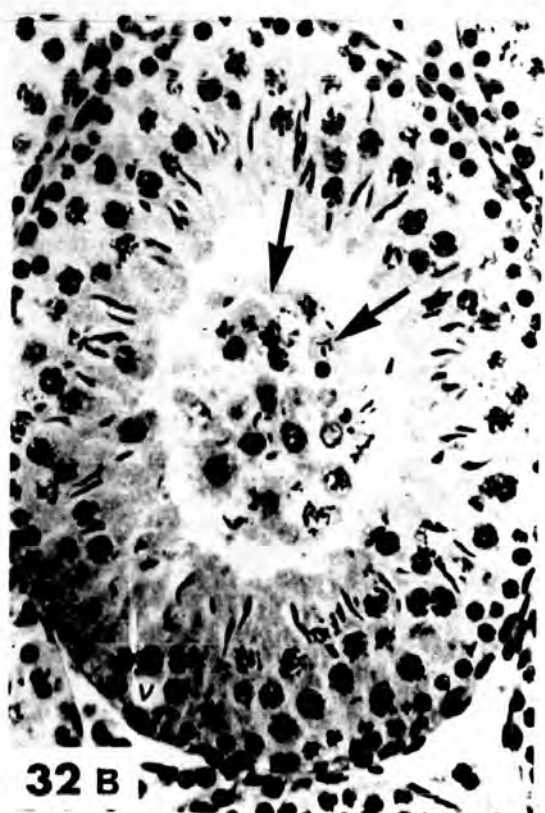
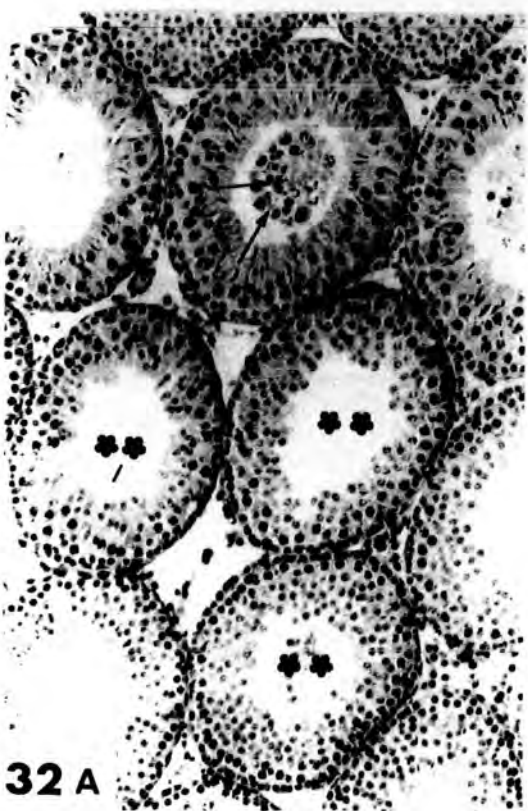
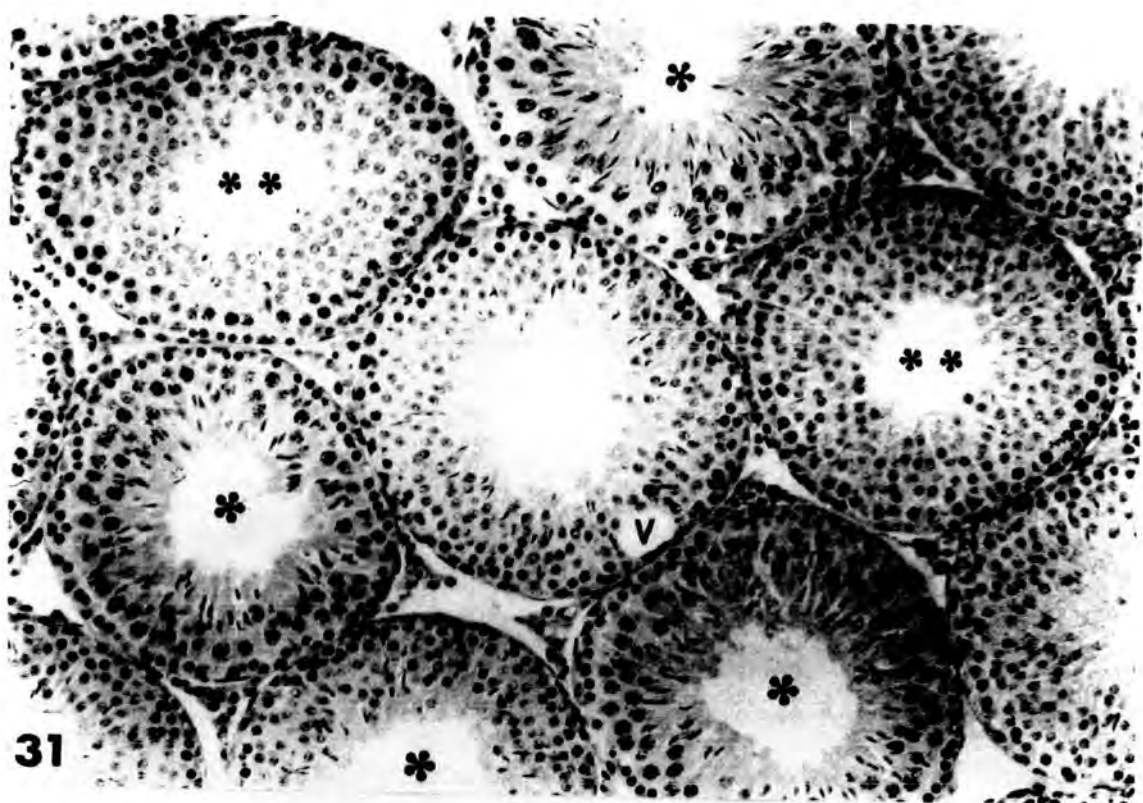


Plate 12

Fig.33 Low power light micrograph of transverse section of a testis from an animal injected with 0.05 cm<sup>3</sup> of Mepivacaine-HCl , 2% , and killed after 24 hours . All the seminiferous tubules show " slight " damage , mainly the absence of late spermatids .

X 100

Fig.34 High power light micrograph of transverse section of a testis from an animal injected with 0.05 cm<sup>3</sup> of Mepivacaine-HCl , 2% , and killed after 24 hours . A seminiferous tubule illustrating relatively few late spermatids with a few exfoliated young spermatids ( arrows ) .

X 100

Fig.35 High power light micrograph of transverse section of a testis from<sup>a</sup> control animal injected with 0.05 cm<sup>3</sup> of glucose carrier medium intraperitoneally and killed after 24 hours . The seminiferous tubules show normal spermatogenic progression and contain all types of germinal epithelial cells .

X 400

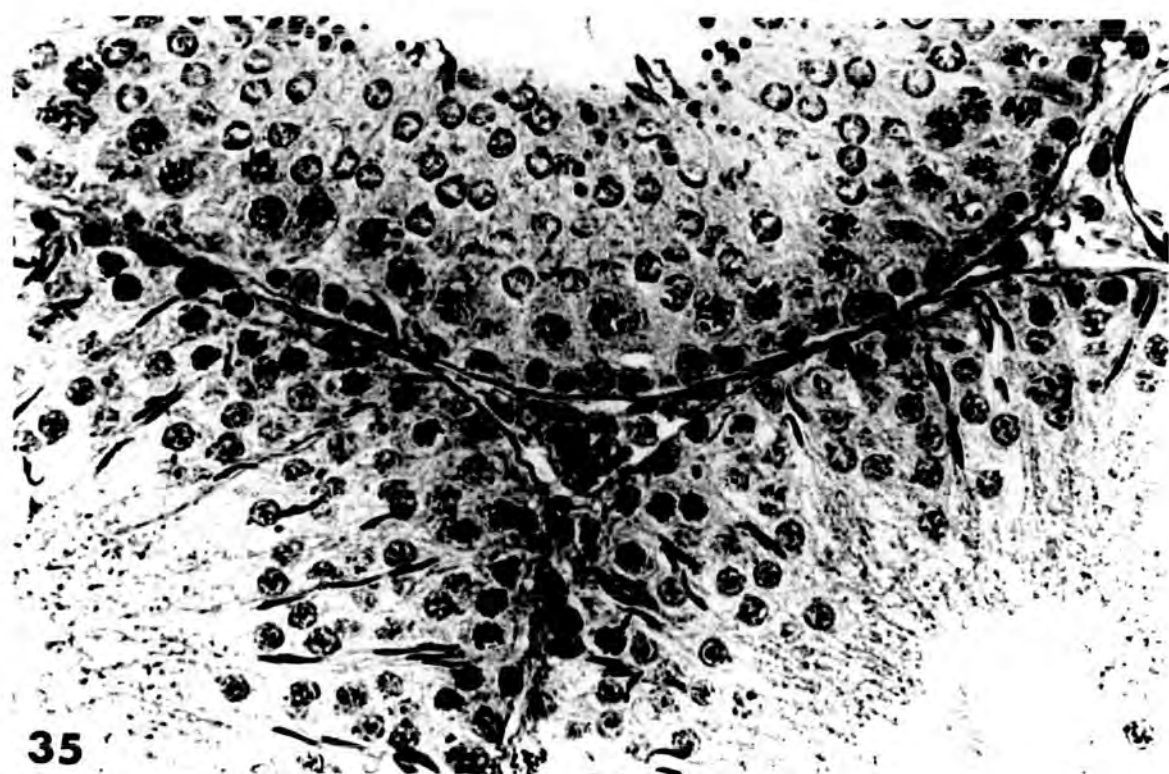
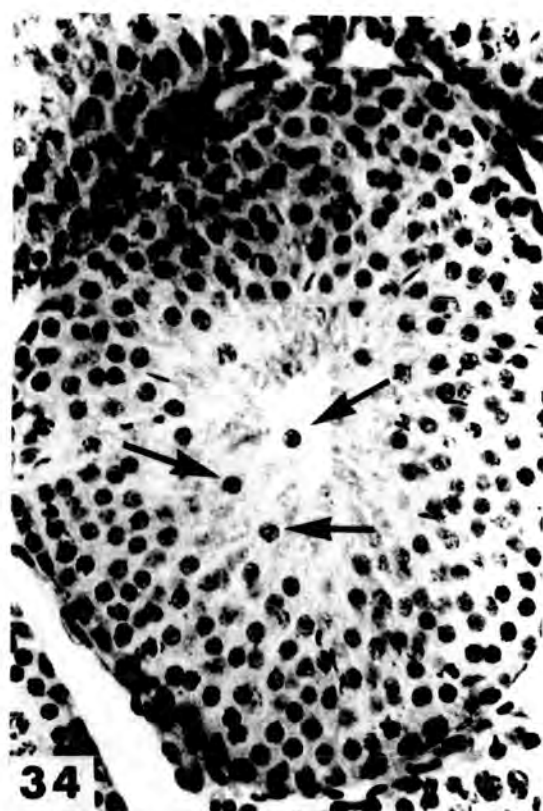
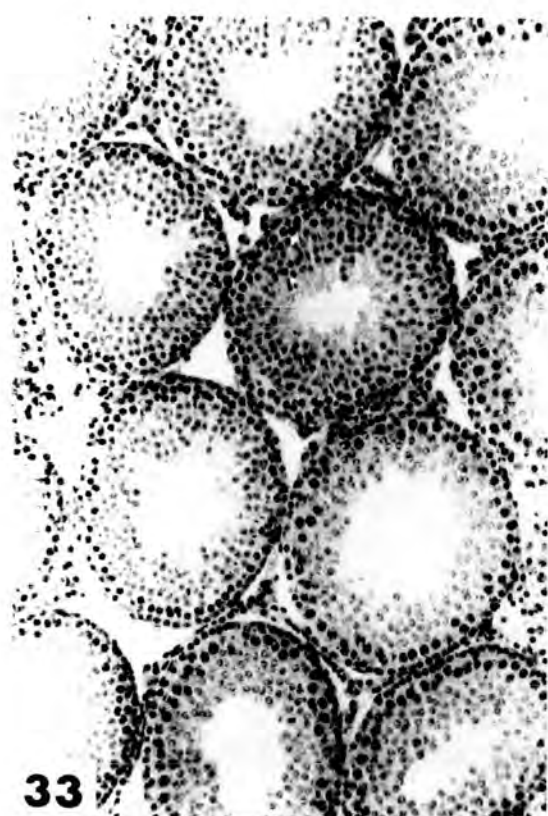

Plate 13

Fig.36 Low power light micrograph of transverse section of a testis from an animal injected with  $0.05 \text{ cm}^3$  of Mepivacaine-HCl, 2%, and killed after 48 hours. Note that "slightly" <sup>(S)</sup> damaged tubule(s) are found adjacent to normal tubules (N). The "slight" damage is mainly of tubules with only the late spermatids missing with very few exfoliated cells (arrows).

X 180

Fig.37 Low power light micrograph of transverse section of a testis from an animal injected with  $0.05 \text{ cm}^3$  of Mepivacaine-HCl, 2%, and killed after 48 hours. Both "partially" (P) and "slightly" (S) damaged tubules are evident. Note the vacuolation (V) near the boundary tissue in the slightly damaged tubules.

X 180

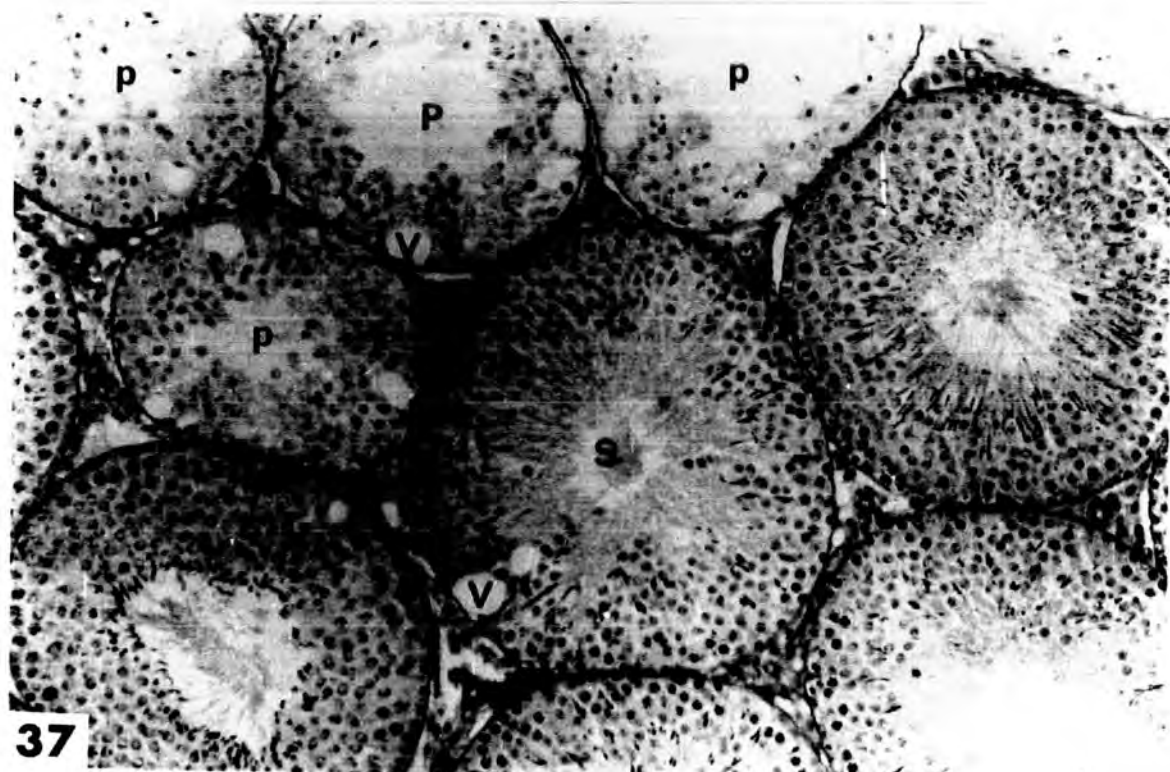
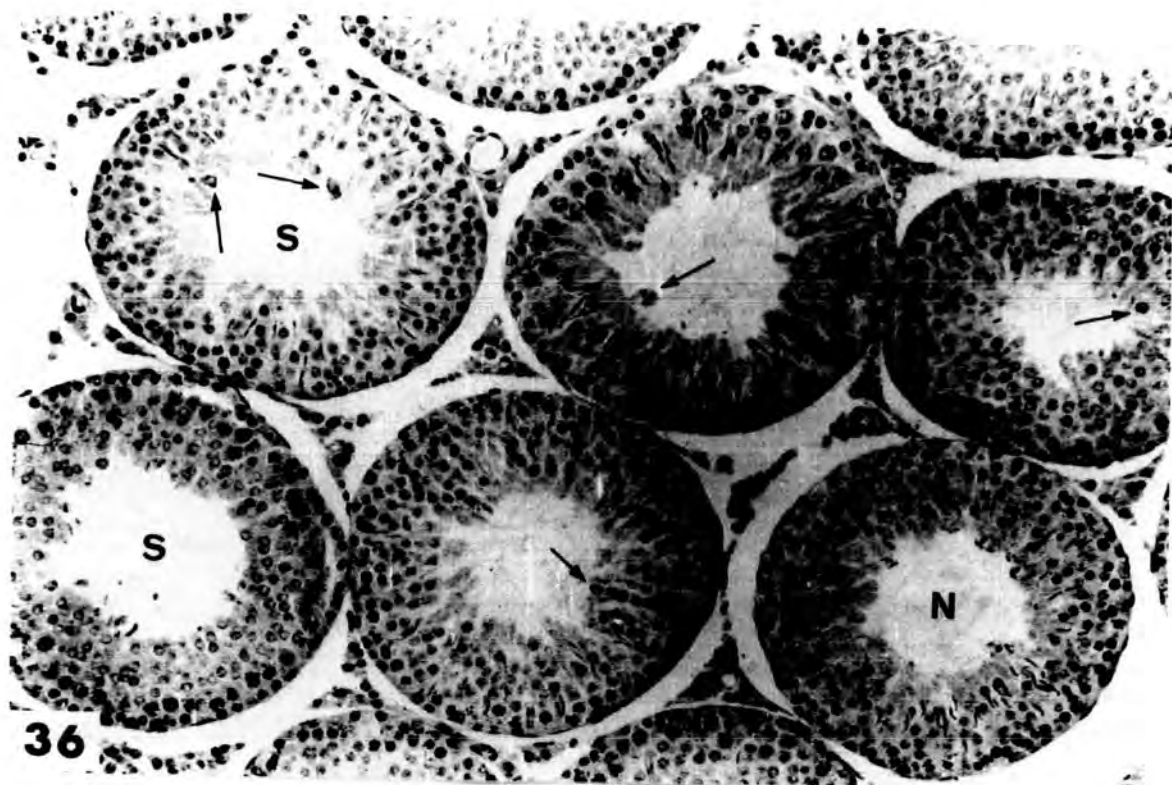


Table 2

Effect of a single low dose of Mepivacaine-HCl

The mean number of tubules , as percentage of the total counted ,  
showing a form of damage or being normal.

( Each sample was of 5 animals and 100 tubules were scored into the )  
( four categories listed . )

iiiiiiiiiii

Dose	severe	partial	slight	normal
0.05cm <sup>3</sup> 2% 24h.	-----	-----	37.69 ± 4.55	62.29 ± 4.23
0.05cm <sup>3</sup> 2% 48h.	-----	12.25 ± 2.00	41.33 ± 5.22	46.42 ± 4.83
0.05cm <sup>3</sup> 4% 24h.	-----	-----	29.16 ± 2.52	70.83 ± 2.51
0.05cm <sup>3</sup> 4% 48h.	-----	-----	39.22 ± 2.82	61.16 ± 3.89

" slightly " damaged increased from 29.16 - 2.52% after 24 hours to 39.22 - 2.82% after 48 hours .

The animals receiving 0.05 cm<sup>3</sup> of Mepivacaine-HCl , 2% solution , showed a slight increase in the degree of damage over those receiving 0.05 cm<sup>3</sup> , 4% solution . The number of the slightly damaged tubules were not significantly different at 37.69 - 4.55% after 24 hours and 41.33 - 5.22% after 48 hours . Also , the number of normal tubules showed a slight decline to 46.42 - 4.83% after 48 hours from 62.29 - 4.23% after 24 hours. On the other hand , 12.25 - 2.00% " partially " damaged tubules appeared after 48 hours of intraperitoneal injection with 0.05 cm<sup>3</sup> of Mepivacaine-HCl , 2% solution .

Also , in case of the 4% solution , the damage appeared to increase with time , there being 29.16 - 2.52% " slightly " damaged tubules 24 hours after treatment as compared to 39.22 - 2.82% after 48 hours .

#### Discussion :

The damage caused after intraperitoneal administration of 0.05 cm<sup>3</sup> of Mepivacaine-HCl , 2% and 4% solution was mainly of " slight " type . This form of damage included both vacuolation and tubules in which the late spermatid stage was absent . This damage represented the least damage caused to the seminiferous tubules of the treated animals by Mepivacaine-HCl injection .

Vacuolation also occurred after the administration of a single dose at three higher doses as described in chapter 3 , but the vacuoles were larger in size and found with greater numbers than appeared in the tubules described in this chapter .

The quantitative data show that the " slightly " damaged tubules in animals which received  $0.05 \text{ cm}^3$  Mepivacaine-HCl , 2% solution , increased from 37.69 - 4.55% after 24 hours to 41.33 - 5.22% after 48 hours , whilst the normal tubules decreased in number to 46.42 - 4.83% after 48 hours and from 62.29 - 4.23% 24 hours after injection . Another type of damage , the " partial " type , was found only in the 48 hours group .

In the other group of animals which received  $0.05 \text{ cm}^3$  of Mepivacaine - HCl , 4% solution , the " slightly " damaged tubules increased from 29.16 - 2.52% after 24 hours to 39.22 - 2.82% after 48 hours , whilst the mean percentage of normal tubules fell from 70.83 - 2.51% after 24 hours to 61.16 - 3.89% after 48 hours . No " partially " damaged tubules were found. The increase in the number of " slightly " damaged tubules may reflect a delay in the appearance of damage as a result of drug administration .

# Chapter 5

## Chapter 5

### Effect of repeated doses of Mepivacaine-HCl on testes

#### Introduction :

The effect of Mepivacaine-HCl at three different high doses and at a single low dose on the histological appearance of the rat testes has been investigated in this study , using both the light ( chapter 3 & 4 ) and electron ( chapter 6 ) microscope . This study shows that the testes undergo histopathological changes .

A few workers have shown that repeated insults to the testes result in an accumulation of the damage . e.g. Bowler ( 1972 ) .

The aim of these experiments was to see if repeated doses of Mepivacaine-HCl caused an accumulation of damage at each dose and / or if a different type of damage occurred .

#### Methods :

The experimental rats were injected from one to five times with Mepivacaine-HCl . A twenty-four hour period was allowed between each successive injection . Both experimental and control rats were killed 24 hours after the first , second , third , fourth and fifth injection .

The left testis was removed , freed from connective tissue and blood vessels and weighed . The right testis from each animal was cut into half through the equator and fixed in Bouin's fixative . The tissue was embedded in paraffin wax and sectioned at 5 $\mu$ m . The sections were stained with haematoxylin ( Mayers ) and eosin , as was described in chapter 2 .

Results :

ORGAN WEIGHTS :

The changes which occurred in the testis and seminal vesicle weights in response to Mepivacaine-HCl administration are shown in table 3 and 4 .

In the case of the testes , only the left testis / <sup>was</sup> weighed and its weight expressed as gram testis / 100 g. body weight .

As can be seen , a significant and progressive increase in body weight occurred in the experimental animals as compared with the control animals during the course of the experiment .

The effect of the drug on the testis can be seen by a progressive fall in testis weight / 100 g. body weight ; after 5 doses of Mepivacaine-HCl this had fallen to 0.3296 - 0.0308 from 0.5093 - 0.0242 g./100g. body weight (  $p = 0.001$  ) . During this period the testis of control rats had remained at about 0.5 g./100 g. body weight .

In both control and experimental animals the seminal vesicle weights ( g./100 g. body weight ) were variable and showed no overall pattern . In the experimental group there was a tendency for seminal vesicle weight to increase during the treatment ; this was also apparent in the control animals but the increase was not so marked , and the values obtained were more variable .

It was concluded from the results obtained in this chapter , that Mepivacaine-HCl injection had no obvious effect on seminal vesicle function.

Table 3

The effect of application of repeated low doses of Mepivacaine-HCl on mean body and mean left testis weight and standard error of young adult male rats weighing 120-130 g. at the beginning of the experiment ( Dose rate 0.1 cm<sup>3</sup> of a 4% Carbocaine solution )

\*\*\*\*\*

	Body weight of control animals g.	Body weight of experimental animals g.	Actual testis wt. of control animals. g.	Actual testis wt. of experimental animals g.	testis weight of control animals g./100g. b.wt.	testis weight of experimental animals g./100g. b.wt.
1 dose	129.33 ± 1.97	128.21 ± 2.61	0.7727 ± 0.029	0.6530 ± 0.032	0.5975 ± 0.022	0.5093 ± 0.0242
2 doses	132.84 ± 3.33	138.84 ± 2.46	0.7472 ± 0.053	0.6467 ± 0.049	0.5625 ± 0.051	0.4658 ± 0.0426
3 doses	133.01 ± 3.95	143.67 ± 3.09	0.7192 ± 0.045	0.5926 ± 0.047	0.5407 ± 0.070	0.4125 ± 0.0310
4 doses	137.42 ± 4.05	170.41 ± 4.02	0.7109 ± 0.048	0.6269 ± 0.059	0.5173 ± 0.042	0.3679 ± 0.0434
5 doses	142.66 ± 4.22	162.12 ± 3.03	0.7006 ± 0.098	0.5343 ± 0.070	0.4911 ± 0.048	0.3296 ± 0.0308



HISTOLOGICAL APPEARANCE OF THE TESTES :

1- One dose group :

Twenty-four hours after administration of  $0.1 \text{ cm}^3$  Mepi-  
vacaine-HCl ( 4% ) , the seminiferous tubules did not show any changes in  
the tubule size ( diameter ) and their boundary tissue was apparently  
normal without any shrinkage or damage ( plate 14 , fig.38 ) . The tubules  
contained a small number of pyknotic late spermatids , some of which fused  
together to form multinucleate giant cells . The heads of these pyknotic  
late spermatids became more or less rounded or shrank into a clumped mass  
of chromatin instead of having their normal sickle-shape appearance ( plate  
14 , fig. 39 ) . The primary spermatocytes showed detachment from each  
other and tended to exfoliate together with early spermatids . Both sperm-  
atogonia and Sertoli cells appeared unaffected ( plate 14 , figs.38 & 39 ) .

2- Two dose group :

As in the previous group of animals , the seminiferous  
tubules did not show any changes in the tubule size or in the appearance of  
the boundary tissue . The main characteristic feature of damage in these  
tubules was the complete absence of late spermatids . Also , some early  
spermatids had central vesicles , with an increased concentration of chro-  
matin on the nuclear membranes ; others became denser , rounded-off and  
detached , whilst a few of them were fused to form multinucleate cells  
( see plate 14 , figs. 40 & 41 ) . Also , very few primary spermatocyte  
multinucleates were present . The tubules acquired some vacuoles near the  
boundary tissue ( plate 14 , fig. 40 ) . The spermatogonia and the Sertoli  
cells appeared unaffected and the interstitium showed no obvious changes.

3- Three dose group :

The changes described in the previous two groups occurred here also , but were more obvious . The multinucleate cells increased markedly in number after three successive injections . Some of them were obviously derived from fused early spermatids . These cells sometimes appeared to have a dark or ragged cytoplasm , and these early spermatids had chromatin crescents in their nuclei ( see plate 15 , fig. 44 ) . Some seminiferous tubules were filled with necrotic exfoliated cells ( see plate 15 , fig.42 ) . Many tubules of the testes appeared to be " partially " damaged .

4- Four dose group :

The seminiferous tubules showed a marked increase in numbers of " partially " damaged tubules ( see table 5 ) . Furthermore , some " severely " damaged tubules were found . In " partially " damaged tubules , which were most prominent , there was a marked increase in the numbers of tubules with preleptotene spermatocytes and a complete loss of both early and late spermatids ( see plate 16 , figs. 45 & 46 ) . The tubule diameter decreased slightly , and all tubules were free of debris . The primary spermatocyte layer tended to exfoliate , and as a result complete portions of the seminiferous tubules appeared empty from all the spermatogenic epithelium , except for spermatogonia and Sertoli cells ( see plate 16 , fig. 46 ) . The Sertoli cells appeared with ragged cytoplasm and occasionally contained large vacuoles .

Few seminiferous tubules showed " severe " damage , in these tubules only Sertoli cells and spermatogonia remained ( see plate 16 , fig. 46 ) .

Plate 14

Fig. 38 , fig.39      Low power and high power light micrographs of transverse section of a testis from an animal injected with  $0.1 \text{ cm}^3$  of Mepivacaine-HCl , 4% , and killed after 24 hours . Note the slight decrease in the number of early spermatids ( spd ) . The pyknotic late spermatids fuse together to form multinucleate cells ( LSM ) . The primary spermatocytes ( arrows ) detach from one another and tend to exfoliate .

Fig.38 : X 100 ;

Fig.39 : X 250 .

Fig.40      Low power light micrograph of transverse section of a testis from an animal injected with two successive  $0.1 \text{ cm}^3$  injections of Mepivacaine-HCl , 4% , 24 hours apart and killed 24 hours after the last injection . Few multinucleate cells are formed , mainly from early spermatids ( arrow heads ) . Tubules with vacuoles (V) near the boundary tissue are evident . There is also a marked lack of late spermatids in almost all the tubules .

X 100

Fig.41      Light micrograph of transverse section of a testis from an animal injected with two successive  $0.1 \text{ cm}^3$  injections of Mepivacaine-HCl , 4% , 24 hours apart and killed 24 hours after the last injection . Note the absence of late spermatids , exfoliated cells ( arrow heads ) and the marked decrease in the number of early spermatids in the seminiferous tubules ( arrows ) .

X 100

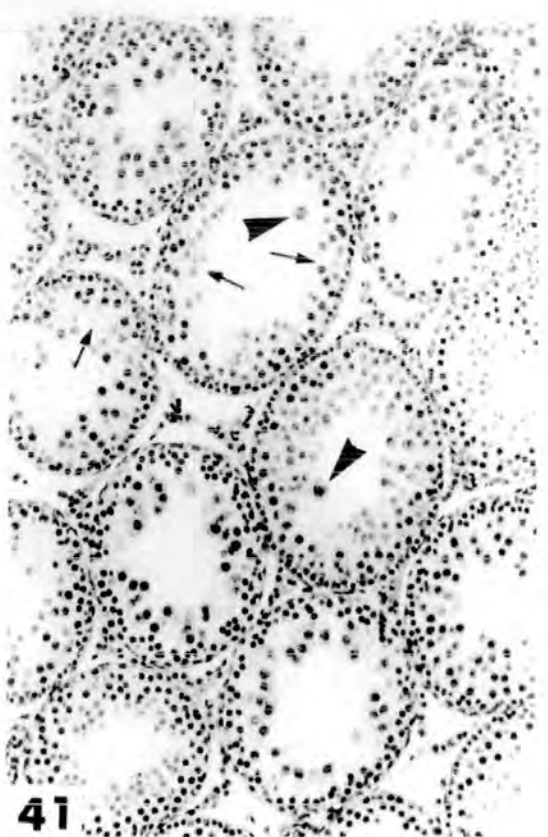
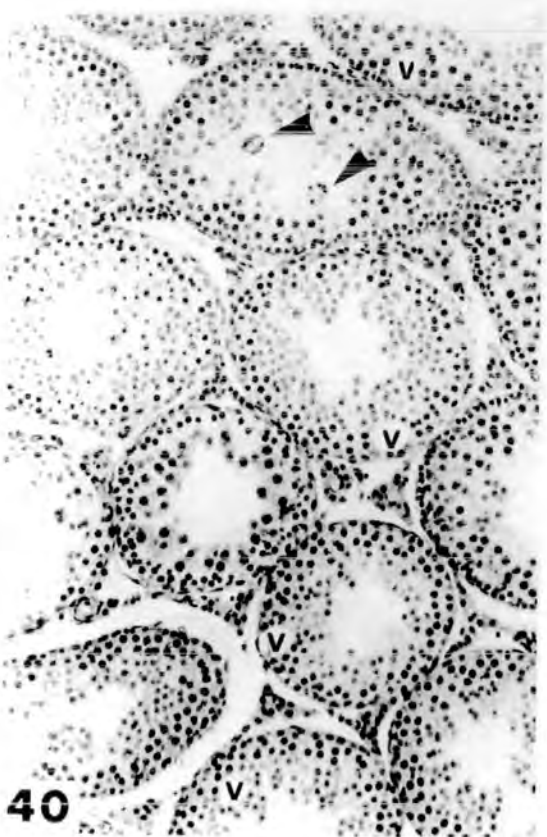
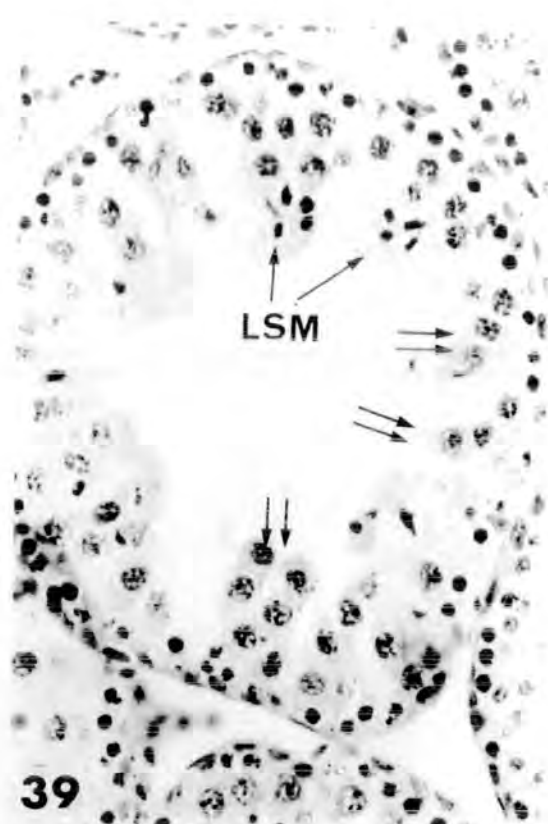
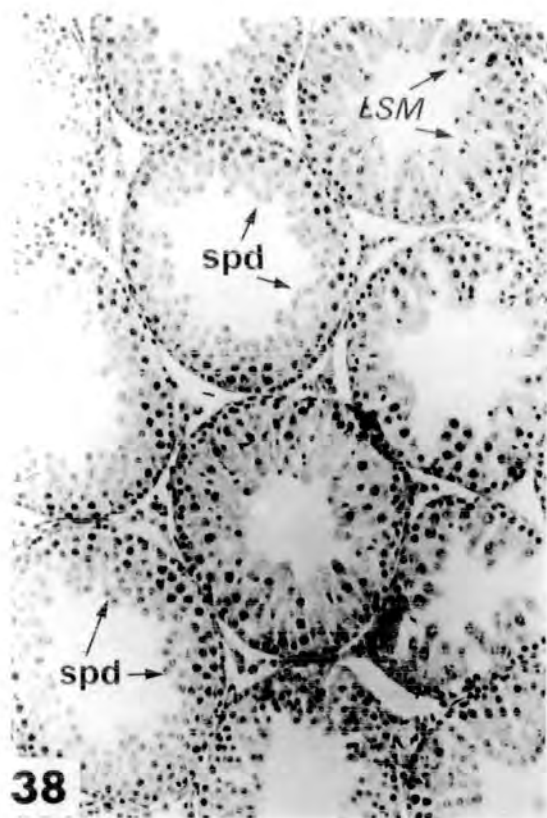


Plate 15

Fig.42 Low power light micrograph of transverse section of a testis from an animal injected with  $0.1 \text{ cm}^3$  of Mepivacaine-HCl , 4% , 3 successive injections , 24 hours apart and killed 24 hours after the last injection . Almost all the seminiferous tubules show "partial" damage (p) and some of them are filled with necrotic exfoliated cells ( arrow heads ) .

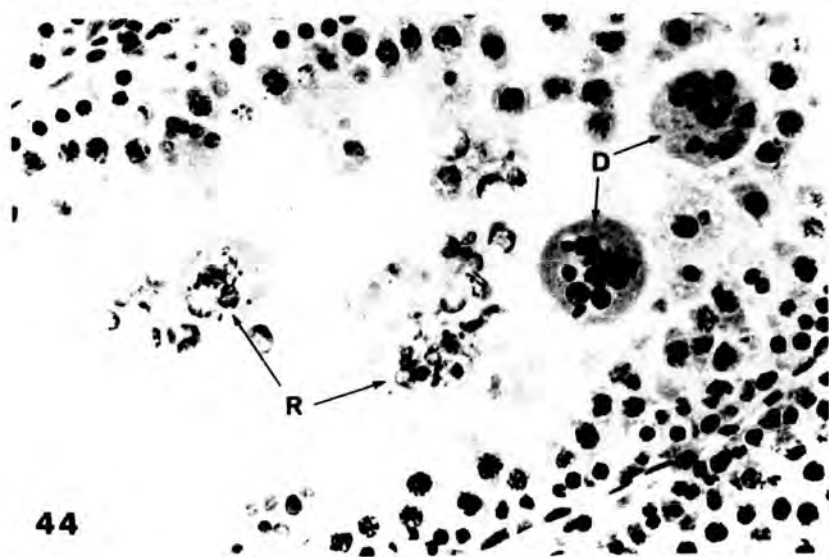
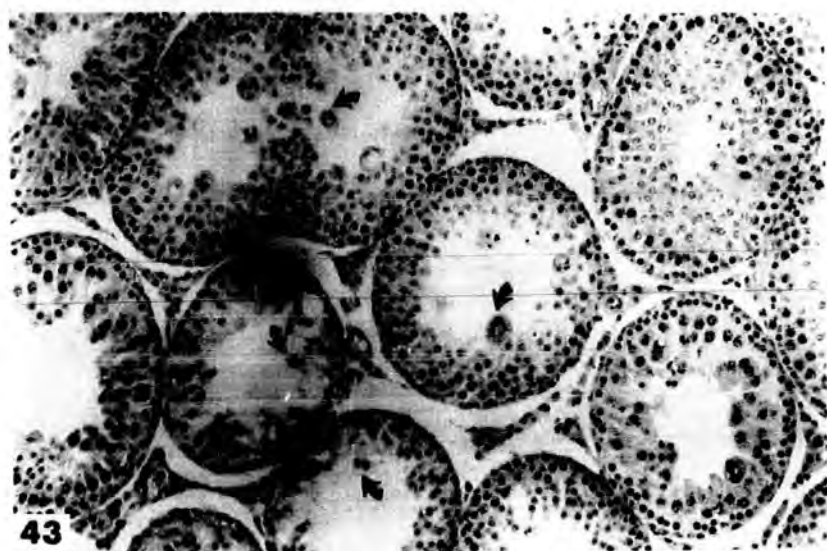
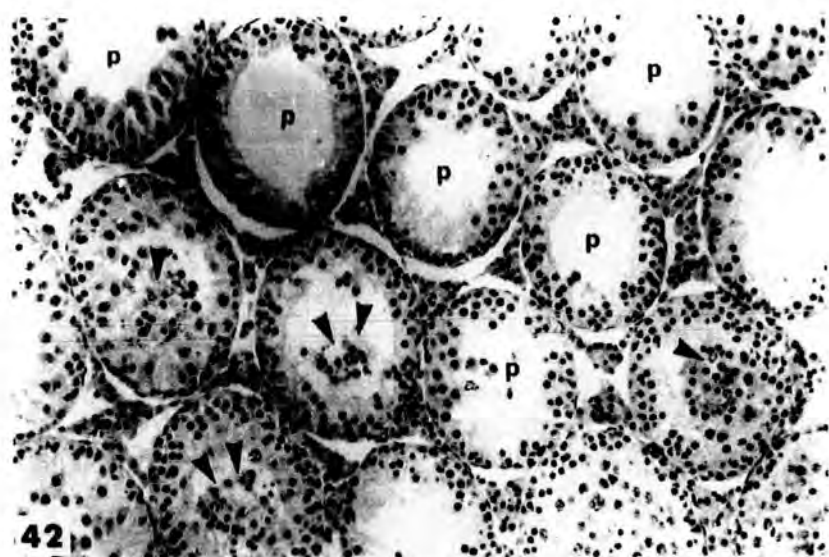
X 100

Fig.43 Low power light micrograph of transverse section of a testis from an animal injected with  $0.1 \text{ cm}^3$  of Mepivacaine-HCl , 4% , 3 successive injections , 24 hours apart and killed 24 hours after the last injection . Some multinucleate cells ( arrows ) appear to be formed by fusion of early spermatids , others of late spermatids . Note complete loss of late spermatids from all the tubules .

X 100

Fig.44 High power light micrograph of transverse section of a testis from an animal injected with  $0.1 \text{ cm}^3$  of Mepivacaine-HCl , 4% , 3 successive injections , 24 hours apart and killed 24 hours after the last injection . Note the fusion of early spermatids leading to the formation of multinucleate cells which sometimes have a dark ( D ) or a 'ragged' cytoplasm ( R ) .

X 400



5- Five dose group :

The seminiferous tubules of rats receiving five injections of  $0.1 \text{ cm}^3$  of Mepivacaine-HCl , 4% , 24 hours after the last dose showed still more severe damage . These tubules contained different types of tubule damage ; the " partially " damaged tubules appeared to have a larger number of multimoleate cells mainly formed by the fusion groups of up to 15 early spermatids ( see plate 16 , fig. 48 ) . Also , a marked increase in the number of preleptotene spermatocytes was evident ( see plate 16 , figs. 47 & 48 ) . The primary spermatocytes tended to exfoliate and , as a result of this exfoliation , a " severely " damaged tubule remained , which showed a well-marked single layer of Sertoli cells and pyknotic germ cells mainly of spermatogonia . The Sertoli cell cytoplasm acquired vacuoles and had a fibrous appearance ( see plate 16 , fig. 47 ) .

The effect of these repeated doses of Mepivacaine-HCl on the testes was quantified in table 5 .

The accumulative nature of the damage incurred is obvious . The mean percentage of tubules " severely " damaged rose from 0.57 - 0.57% after one dose to 45.01 - 9.19% after 5 doses . The percentage of tubules " partially " damaged increased dramatically from 19.9 - 5.75% after one dose to 46.39 - 6.45% after 3 doses and remained at about that level with the two successive doses . In contrast the numbers of " slightly " damaged tubules fell with each successive dose from about 30% after each of the first three doses to be only 3.03 - 1.8% after the final dose . The numbers of normal tubules showed a similar decline so that only 2.02 - 2.01% were normal after the fourth dose and no normal tubules were evident after the fifth dose .

Plate 16

Fig.45 Low power light micrograph of transverse section of a testis from an animal injected with 4 successive 0.1 cm<sup>3</sup> injections of Mepivacaine-HCl , 4% , 24 hours apart and killed 24 hours after the last injection . Note the marked increase in the numbers of the preleptotene spermatocytes ( arrows ) . The primary spermatocytes ( asterisks ) tend to exfoliate .

X 100

Fig.46 Low power light micrograph of transverse section of a testis from an animal injected with 4 successive 0.1 cm<sup>3</sup> injections of Mepivacaine-HCl , 4% , 24 hours apart and killed 24 hours after the last injection . This figure also shows the increased number of preleptotene spermatocytes ( arrows ) and that the primary spermatocytes tend to exfoliate . Some tubules show " severe " damage (SV) , in these tubules only Sertoli cells and pyknotic spermatogonia are left .

X 100

Fig.47 Low power light micrograph of transverse section of a testis from an animal injected with five successive injections of Mepivacaine-HCl , 4% , 24 hours apart and killed 24 hours after the last injection. Most tubules show "severe" damage (SV) and a few of them still show a marked increase in the number of preleptotene spermatocytes ( arrows ) . The Sertoli cell cytoplasm contains vacuoles and has a fibrous appearance (f) .

X 100

Fig.48 Low power light micrograph of transverse section of a testis from an animal injected with five successive 0.1 cm<sup>3</sup> injections of Mepivacaine-HCl, 4% , 24 hours apart and killed 24 hours after the last injection. Note a marked accumulation of early spermatid multinucleates (arrows) and vacuolation (v) and the seminiferous epithelium reduced to only 2 or 3 layers of cells .

X 100

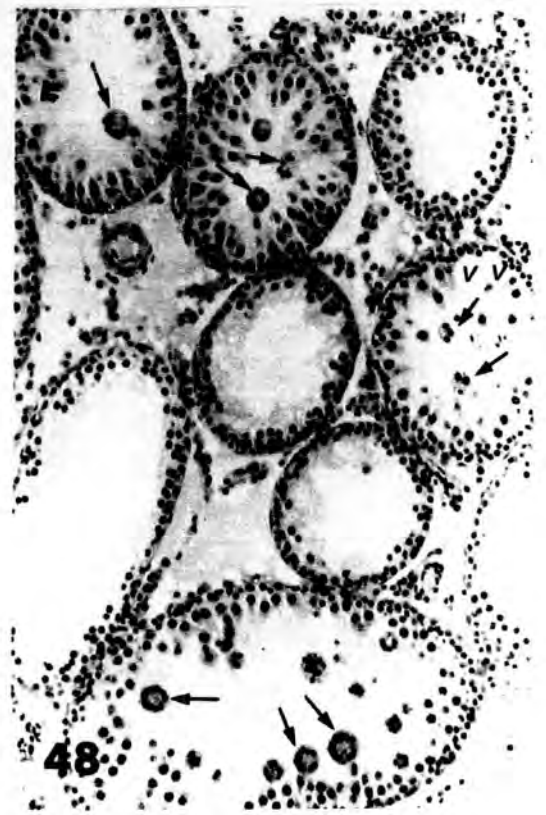
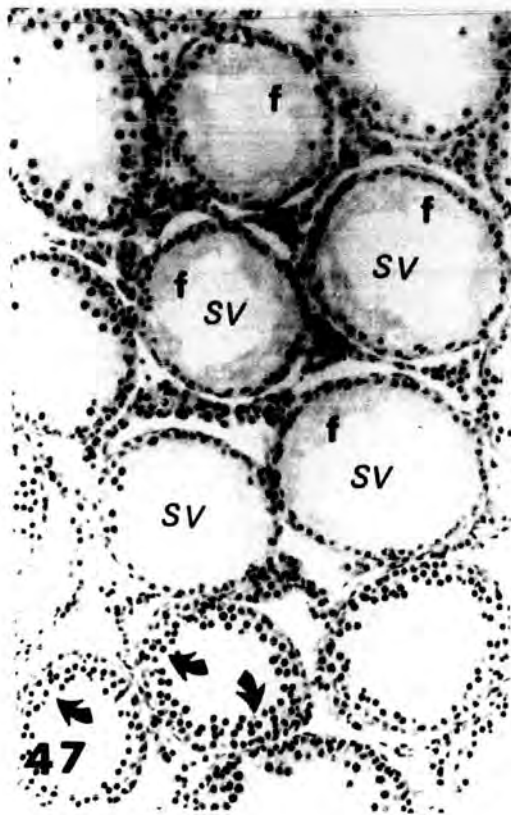
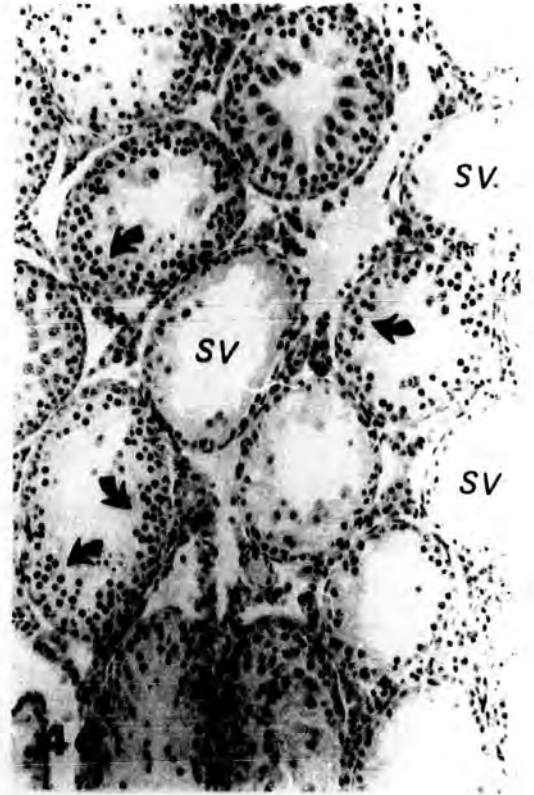
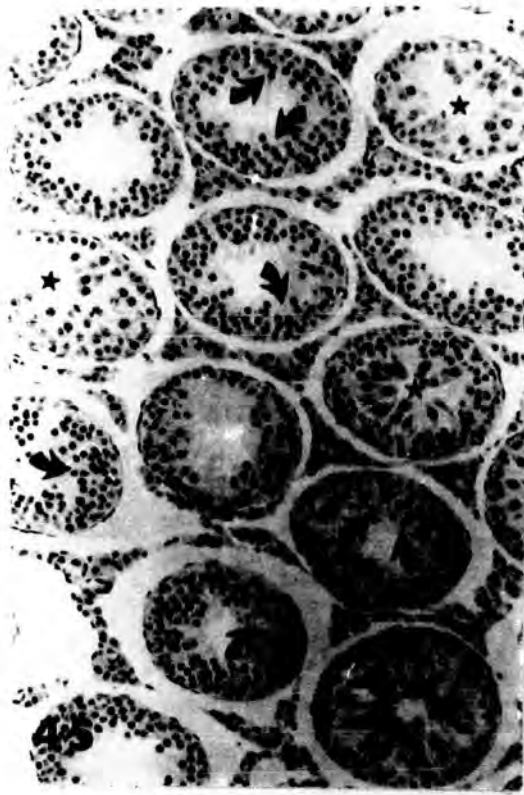


Table 5

Effect of repeated doses of Mepivacaine-HCl

The mean number of tubules showing a form of damage or being normal, expressed as a percentage of total number counted and standard error .

100 tubules were counted for each of the eight animals in the control and experimental groups .

Dose	severe	partial	slight	normal
0.1 1 dose	0.57 ± 0.32	19.90 ± 5.75	30.08 ± 8.13	49.43 ± 12.43
2 doses	2.63 ± 1.58	30.91 ± 9.48	30.02 ± 6.66	28.42 ± 5.49
3 doses	15.47 ± 4.94	46.39 ± 6.45	28.54 ± 7.65	8.57 ± 3.54
4 doses	28.47 ± 5.56	56.84 ± 6.07	12.20 ± 4.69	2.02 ± 2.01
5 doses	45.01 ± 9.19	43.05 ± 7.46	3.03 ± 1.80	0 ± 0

Discussion :

**BODY AND ORGAN WEIGHTS :**

The body weight of the animals receiving successive injections of 0.1 cm<sup>3</sup> of Mepivacaine-HCl , 4% , showed a significant increase from 128.21 - 2.61 g. in the one dose group to 162.12 - 3.03 g. in the five dose group . This increase in the animals ' body weight could be due to the marked increase in their appetite after drug administration .

The fall in the testis weight of the experimental animals ( table 3 ) was clearly the result of the repeated Mepivacaine-HCl injections and was caused by the rise in the proportion of tubules " severely " or " partially " damaged ( table 5 ) .

Seminal vesicle weight has been widely used as an indicator of the level of androgen output and therefore of the level of interstitial cell function . The fact that , in the present study , the seminal vesicle weights did not differ significantly from controls , even in the rats receiving five successive injections of Mepivacaine-HCl , suggested that interstitial , function was unaffected by administration of Mepivacaine-HCl . This was confirmed by the observation that experimental animals showed no loss of libido and displayed normal sexual behaviour with females .

**HISTOLOGICAL APPEARANCE OF THE TESTES :**

It is clear from table 5 , that there was a marked increase in number of both " partially " and " severely " damaged tubules with the repeated application of Mepivacaine-HCl . The corresponding decline in the numbers of both normal and " slightly " damaged tubules means that the " severely " damaged tubules were recruited from the less damaged group

following each application . Thus the marked increase in " severely " damaged tubules was due to extensive loss of germ cells from both "slightly" and " partially " damaged tubules and the increase in " partially " damaged tubules resulted from the loss of germ cells from both normal and "slightly" damaged tubules .

The appearance of the few numbers of late spermatids with their tendency to form multinucleate giant cells after a single dose ; the presence of only few late spermatid multinucleates after the second dose and the absence of both late spermatids and their multinucleate bodies after the third and successive doses , to the conclusion that the multinucleate giant cells were mainly formed after 2 doses and were derived from late spermatids which were still found in the tubules after one dose . The complete disappearance of late spermatids after that could be due to the failure of early spermatids to develop further .

Early spermatids were still present in tubules after one dose . They became less abundant and had the tendency to form multinucleate giant cells after the second and third dose . By the fourth dose , very few early spermatids remained . After five doses , there was a marked increase in multinucleate bodies formed from early spermatids . Thus the depletion of early spermatids seen to occur with successive doses resulted from the formation of multinucleate bodies as well as from exfoliation . Moreover , most probably their formation from division of secondary spermatocytes was also impaired .

Some primary spermatocytes were seen to be detached from each other following the first dose . The number of primary spermatocytes so affected increased with the second dose and these cells were seen to exfoliate .

After the third dose , most of the primary spermatocytes were lost from the tubules , and at the same time there was a marked increase in the preleptotene spermatocytes were found after the fourth dose . After the fifth dose , some tubules showed marked loss of these preleptotene spermatocytes , but in others these cells remained together with both Sertoli cells and spermatogonia . The marked decrease in the number of primary spermatocytes in third and subsequent dose groups reflected the detachment and subsequent exfoliation of these cells after one and two doses . The small increase in the numbers of preleptotene spermatocytes in the tubules of the third dose group and the marked increase of the same cells in fourth dose group may have resulted from an increase in spermatogonial mitoses . The presence of large numbers of preleptotene spermatocytes in both four and five dose groups suggested that they did not develop further .

The spermatogonia and Sertoli cells proved to be the most resistant cells to the accumulative action of Mepivacaine-HCl administration . Also , the interstitial tissue did not show any obvious histological changes .

Tubule boundary tissue did not show any thickening or wrinkling as was shown to occur after a single injection of higher doses of Mepivacaine-HCl reported in chapter 3 and chapter 6 .

The results obtained after one dose in this experiment confirmed the results shown by administration of  $0.1 \text{ cm}^3$  of Mepivacaine-HCl and killed after 24 hours discussed in chapter 3 , table 1 .

Bowler ( 1972 ) , in his histological study of the effect of repeated application of heat on spermatogenesis in the rat , reported that the histological appearance of the testis was very much the same in all groups

except for the increase in " severely " atrophic tubules . Also , he showed that the final type of damaged tubules were the " severely " atrophic ones , in which no recovery of spermatogenesis was evident .

# Chapter 6

## Chapter 6

The effect of single doses of 0.1, 0.25 & 0.5 cm<sup>3</sup> of 4% Mepivacaine-HCl  
on the electron microscopical appearance of the testis

---

### Introduction :

As has already been shown from the light microscope work , the testes of rats underwent gross histopathological changes following the administration of Mepivacaine-HCl . These changes included degeneration of tubules , giant cell formation , loss of normal epithelial characteristics of the tubules , and accumulation of cell debris and large lipid droplets in Sertoli cells .

Such obvious pathological changes as these can be followed using electron microscope techniques to enable a more detailed examination of the cellular damage caused by administration of Mepivacaine-HCl .

Fortunately , the normal appearance of the rat testis at both the light and electron microscopic levels is very well known ( e.g Brokelmann , 1963 ; Burgos et al., 1970 ; Dym and Fawcett , 1970 and Flickinger , 1972b ), which provided a good basis for this comparative study .

### Methods :

Testes were fixed in buffered glutaraldehyde and post-fixed with osmium tetroxide , washed , dehydrated and embedded in epon as was described in chapter 2 . The sections were stained with uranyl acetate and lead nitrate .

Results :

1- BOUNDARY TISSUE

(a) Normal boundary tissue :

The clearest observation on boundary tissue structure was made by Lacy ( 1960 ) in his description of tissue from the rat , using both histochemical and electron microscopical techniques . He showed that the tissue surrounding individual seminiferous tubules of the rat was composed of four principal layers , of which two were non-cellular and two cellular . The fine structure of the boundary tissue from control rats is shown in fig.49. It consisted of four layers :

i- Inner non-cellular layer :

This layer was approximately 0.2 - 0.3  $\mu$  thick and corresponded to the basement membrane of Stieve ( 1930 ) . Internally it was bounded by the plasma membranes of the cells lying within the tubules . This non-cellular layer consisted of two layers of dense material, separated by a comparatively clear zone ( a & b, fig.49 ) . Within the clear zone , Lacy ( 1960 ) reported that occasional groups or bundles of fine fibrils were seen in cross section or when cut obliquely . The fibrils had a weakly defined cross banding ; these fibrils were reticular fibres rather than elastic fibres .

ii- Inner cellular layer :

As already revealed by light microscopy , this layer was composed of extremely elongated cells , it varied in thickness from about 0.2  $\mu$  to 0.5  $\mu$  . The cellular membranes appeared very thin in parts and varied much in thickness , such that they appeared discontinuous in places . The membranes also appeared to be nipped off to produce distinct vesicular bodies . The cytoplasmic organelles of these cells were oriented along the long axis of the cell ,

and within the cytoplasm were fine filaments ( see plate 17 , figs.49 , layer 2 ) . They appeared to be typical , smooth muscle cells .

The nuclei of these cells possessed the usual double nuclear membrane and the karyoplasm contained many dense granules .

Mostly , the inner cellular layer , as seen in cross section , was only one cell thick .

iii- Outer non-cellular layer :

This was generally thinner (  $0.1 \mu$  wide ) than the inner non-cellular layer . The dense material was usually only a single layer around which occurred a 'clear' component . Groups of fibrils were seen only rarely within the clear component . The layer was bounded by the plasma membranes of the cells of the inner and outer cellular layer ( see plate 17, figs.49A , 49B & 49C , layer 3 ) .

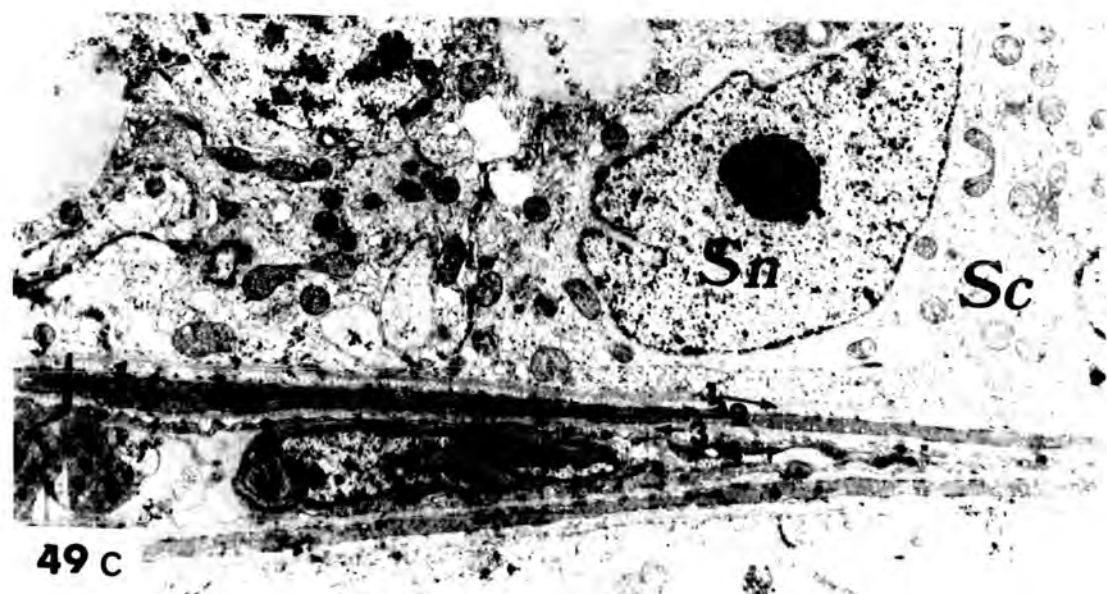
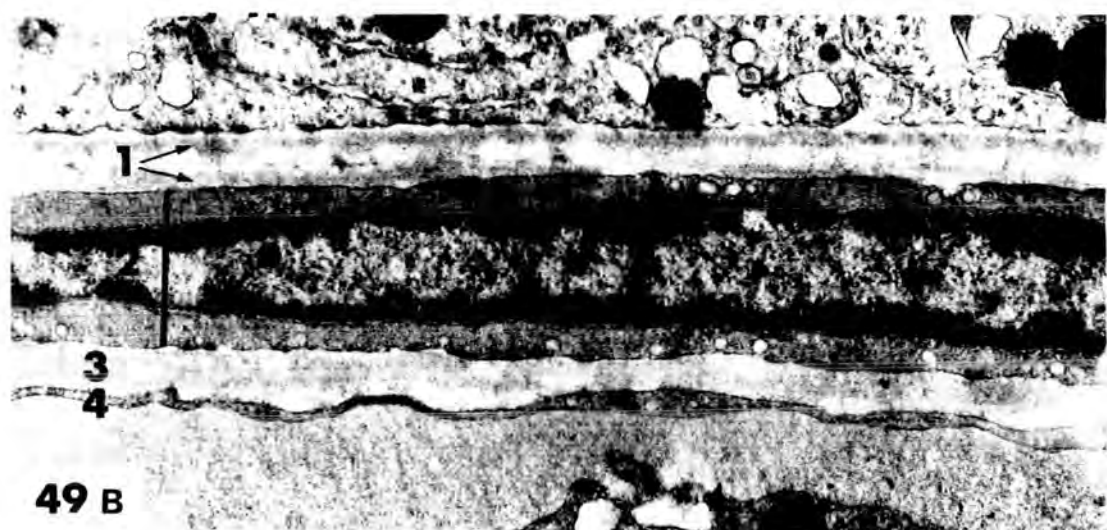
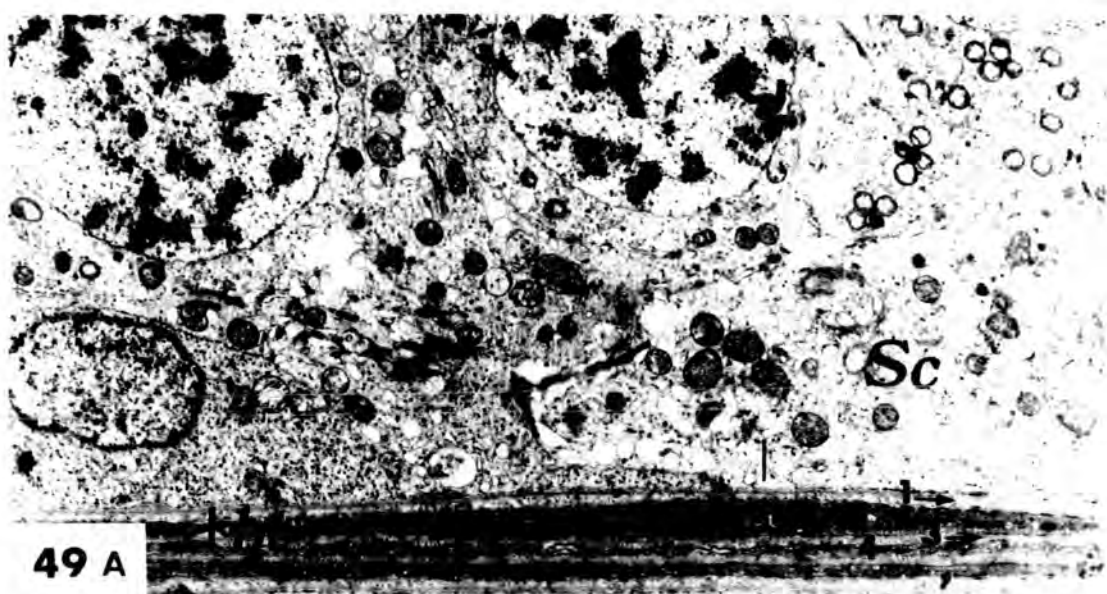
iv- Outer cellular layer :

This was a very thin layer of about  $0.06 \mu$  to  $0.08 \mu$  thick , in which occurred occasional small gaps (  $0.2 \mu$  to  $1.7 \mu$  long ) . Such gaps may have been spaces between adjacent cells , or fenestrations within cells , or a combination of both . The surface of these cells was markedly irregular . The cell membranes showed some invaginations which , as in cells of the inner cellular layer , appeared to be nipped off to produce discrete vesicular bodies . The nuclei were elongate , spindle shaped elements within which a dense nucleolus , located approximately centrally, could be seen ( see plate 17 , figs. 49A , 49B & 49C ) .

Plate 17  
-----

Figs. 49 A , B & C      An electron micrograph of normal ( control ) testis , showing the four principal layers of the boundary tissue . An inner non-cellular layer (1) which corresponds with the basement membrane seen by light microscopy . It consists of two dense regions , separated from each other by a comparatively clear layer . The inner cellular layer (2) . The outer non-cellular layer (3) . Unlike the inner non-cellular layer , this layer usually contains only one dense region . The outer cellular layer (4) .      bt , boundary tissue ; Sc , Sertoli cell cytoplasm ; Sn , Sertoli cell nucleus .

Fig.49A : X 5000      ; Fig.49B : X 40000      ; Fig.49C : X 5000 .



(b) Boundary tissue of Mepivacaine-HCl - treated rats :

The boundary tissue of tubules 'partially' and 'severely' damaged , caused by an intraperitoneal injection of the local anaesthetic agent , Mepivacaine-HCl , was typically like that of X-irradiated boundary tissue of rat seminiferous tubules ( Lacy & Rotblat , 1960 ) . The folding of the boundary tissue , obvious in light microscopy ( see plate 18 , fig.51 ) , suggested its electron microscopic appearance would also be abnormal ( see plate 18 ) .

In " partially " and / or " severely " damaged tubules , the following changes of the boundary tissue were observed :

i- Inner non-cellular layer :

In many tubules the two layers of dense material , seen in normal tissue , had been thrown into folds which were much smaller and more numerous than those shown by the boundary tissue as a whole ( see plate 18 , fig.52 ) .

ii- Inner cellular layer :

Elongated cells of the inner cellular layer appeared also folded and their nuclei became lobed or highly folded . The karyoplasm contained some vacuoles ( see plate 18 , fig.53 ) .

iii- Outer non-cellular layer :

Like that of the inner non-cellular layer , the outer non-cellular layer had become markedly folded . The folds of the dense material were , again , more numerous than those shown by the boundary tissue as a whole ( see plate 18 , fig.52 , layer 3 ) .

iv- Outer cellular layer :

The cells of this layer appeared normal ( see plate 18 , figs.50 & 52 ) .

Plate 18

Fig.50 Low power electron micrograph of transverse section of a seminiferous tubule from an animal injected with  $0.5 \text{ cm}^3$  of Mepivacaine-HCl , 4% , and killed after 24 hours , showing the slightly wavy appearance of part of the boundary tissue . In other respects the tissue appears normal .

X 6300

Fig.51 High power light micrograph of transverse section of a testis from an animal injected with  $0.25 \text{ cm}^3$  of Mepivacaine-HCl , 4% , and killed after 10 days , showing " slightly " damaged ( $\uparrow$ ) and " severely " damaged ( $\uparrow\uparrow$ ) tubules . In the " severely " damaged tubules the boundary tissue is more thickened and folded than in the less damaged tubules .

X 250

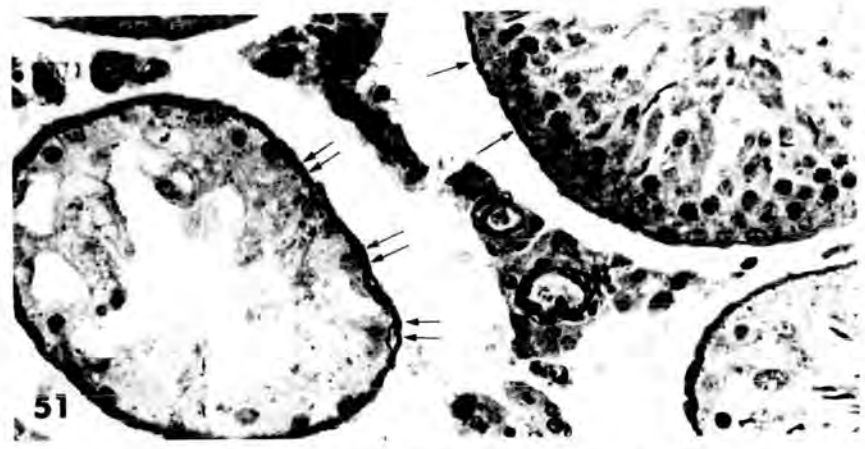
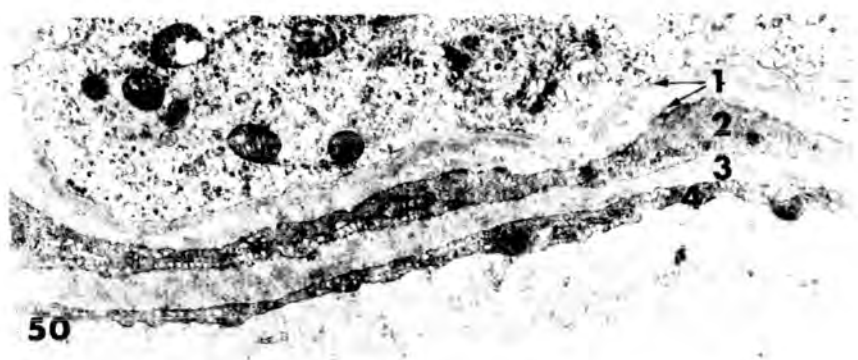
Fig.52 Low power electron micrograph of part of the boundary tissue of a " severely " damaged seminiferous tubule from an animal injected with  $0.25 \text{ cm}^3$  of Mepivacaine-HCl , 4% , and killed after 6 hours . The dense layer (a) of the non-cellular layer shows the most extensive folding . This is followed by the dense layer (b) . The inner cellular layer is irregular in outline . The dense material of the outer non-cellular layer is excessively folded .

X 6300

Fig.53 Low power electron micrograph of transverse section of a seminiferous tubule from a testis from an animal injected with  $0.25 \text{ cm}^3$  of Mepivacaine-HCl , 4% , and killed after 6 hours , showing the wavy appearance of the nucleus ( N ) in the cell of the inner cellular layer , and the vacuoles contained in the nucleoplasm ( V ) .

- (1) The inner non-cellular layer.
- (2) The inner cellular layer .

- (3) The outer non-cellular layer .
- (4) The inner cellular layer .



## 2- SPERMATOGONIA

### (a) Appearance of spermatogonia in tubules of control rat testis :

All spermatogonia made contact with the inner non-cellular layer of the boundary tissue . Their number in the seminiferous tubules was relatively small when compared with the number of spermatocytes and spermatids. The different types of spermatogonia had a rather similar cytoplasmic structure and differed mainly in their volume , and the size and structure of the nucleus . Two main types of spermatogonia were known , A-type and B-type .

#### i- A-type spermatogonia :

Clermont and Bustos-obregon (.1968 ) showed five distinct classes of A-type spermatogonia present at different stages of the cycle of the seminiferous epithelium , the largest or A-type spermatogonia being best seen early in the cycle . They were generally oriented along the boundary tissue . The nucleus was slightly elongated with a loose chromatin structure and a large nucleolus , which might appear homogeneous but generally showed a prominent nucleonema . The nuclear envelope had numerous pores . The cytoplasm contained many free ribosomes , the endoplasmic reticulum was vesicular and mainly smooth surfaced ( see plate 19 , fig.54 ) .

#### ii- B-type spermatogonia :

B-type spermatogonia had a more rounded or slightly ovoid nucleus , with a nucleoplasmic matrix somewhat more electron dense than that of the A-type . Chromatin clumps were more numerous and centrally placed and their distribution was indicative of mitotic activity . Other cytoplasmic components were similar to those described in A-type spermatogonia .

The mitochondria of spermatogonia were rather large and rounded or

elongated. They sometimes formed small clusters with the individual mitochondria separated by a homogeneous, electron dense material, which heavily stained with numerous fine particles, and occasionally a few internal bodies. The cristae of the mitochondria were regularly arranged.

The appearance of normal A-type and B-type spermatogonia can be seen in plate 19, fig-54 & plate 21, figs. 56a & 56b, where these various features are evident.

(b) Spermatogonia of Mepivacaine-HCl - treated rats ;

As has already been shown in chapter 3, at the light microscopic level, the spermatogonia were apparently unaffected in both "slightly" and "partially" damaged tubules, but in "severely" damaged tubules, the A-type spermatogonia appeared to be lost from the tubules whilst the B-type, the more resistant, were still attached to the boundary tissue and the Sertoli cell cytoplasm, together with the Sertoli cells.

At the electron microscopic level, A-type spermatogonia showed little evident response to Mepivacaine-HCl administration with different doses. The minor effects that could be observed were that the chromatin was more homogeneous and the nucleolus seemed less prominent as compared with normal spermatogonia (see plate 20, fig.55).

B-type spermatogonia showed a greater response to Mepivacaine-HCl, most of them were found within the Sertoli cell cytoplasm, but others had moved from their normal position on the inner non-cellular layer of the boundary tissue, into the cytoplasm of Sertoli cells (plate 22, fig.57). The B-type spermatogonia / <sup>were</sup> often surrounded by large vacuolated spaces, which almost completely separated the cell from the Sertoli cell cytoplasm.

The mitochondria of spermatogonia appeared to be affected . They showed different degree of swelling , some being very swollen . In some cases mitochondria lost their electron dense matrix and became lighter , the cristae began to disintegrate , and coalesced together forming condensed electron dense bodies , which accumulated at one side of the outer membranes . Some mitochondria also lost their regular shape , became wrinkled and were distributed throughout the cytoplasm , instead of forming small clusters ( see figs. 55 , 57 & 58 ) .

Plate 19

Fig.54 An electron micrograph showing a normal A-type spermatogonium with its characteristic large oval nucleus , and fine granular nucleoplasm containing a large nucleolus with a prominent nucleonema . The cytoplasm is scanty and contains spherical and ovoid mitochondria (m) , located near the Golgi apparatus ( G ) . Note that the basal edge of the cell membrane is closely opposed to the boundary tissue of the tubule .

X 12600

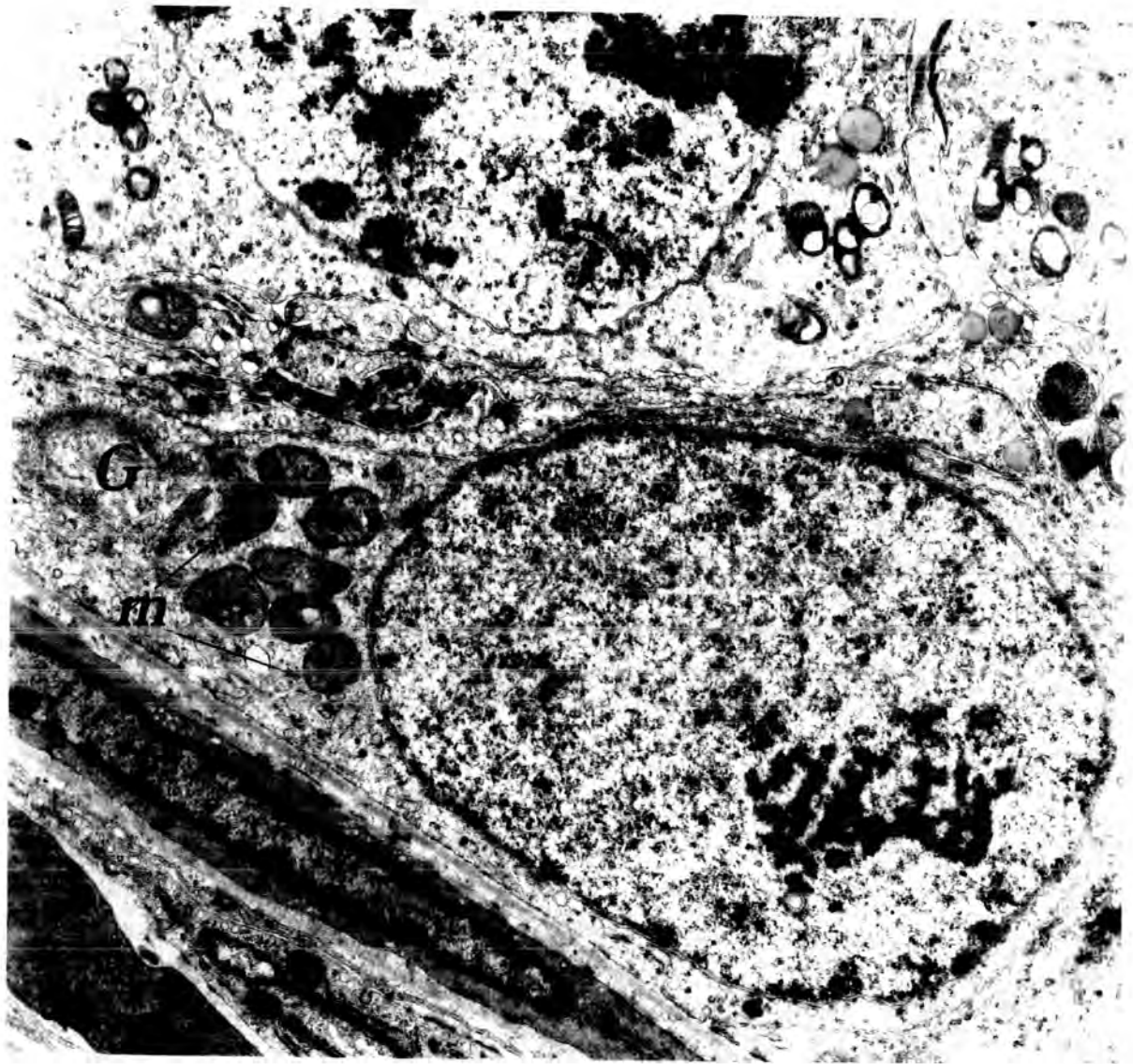


Plate 20

Fig.55 An electron micrograph showing an A-type spermatogonium from a testis of an animal that received 0.5 cm<sup>3</sup> of Mepivacaine-HCl , 4% , and killed 24 hours later . The Golgi apparatus ( G ) is abnormally vesicular compared with the normal lamellar structure illustrated in the previous figure . The mitochondria ( m ) are markedly swollen and the boundary tissue ( bt ) is slightly folded .

X 12600

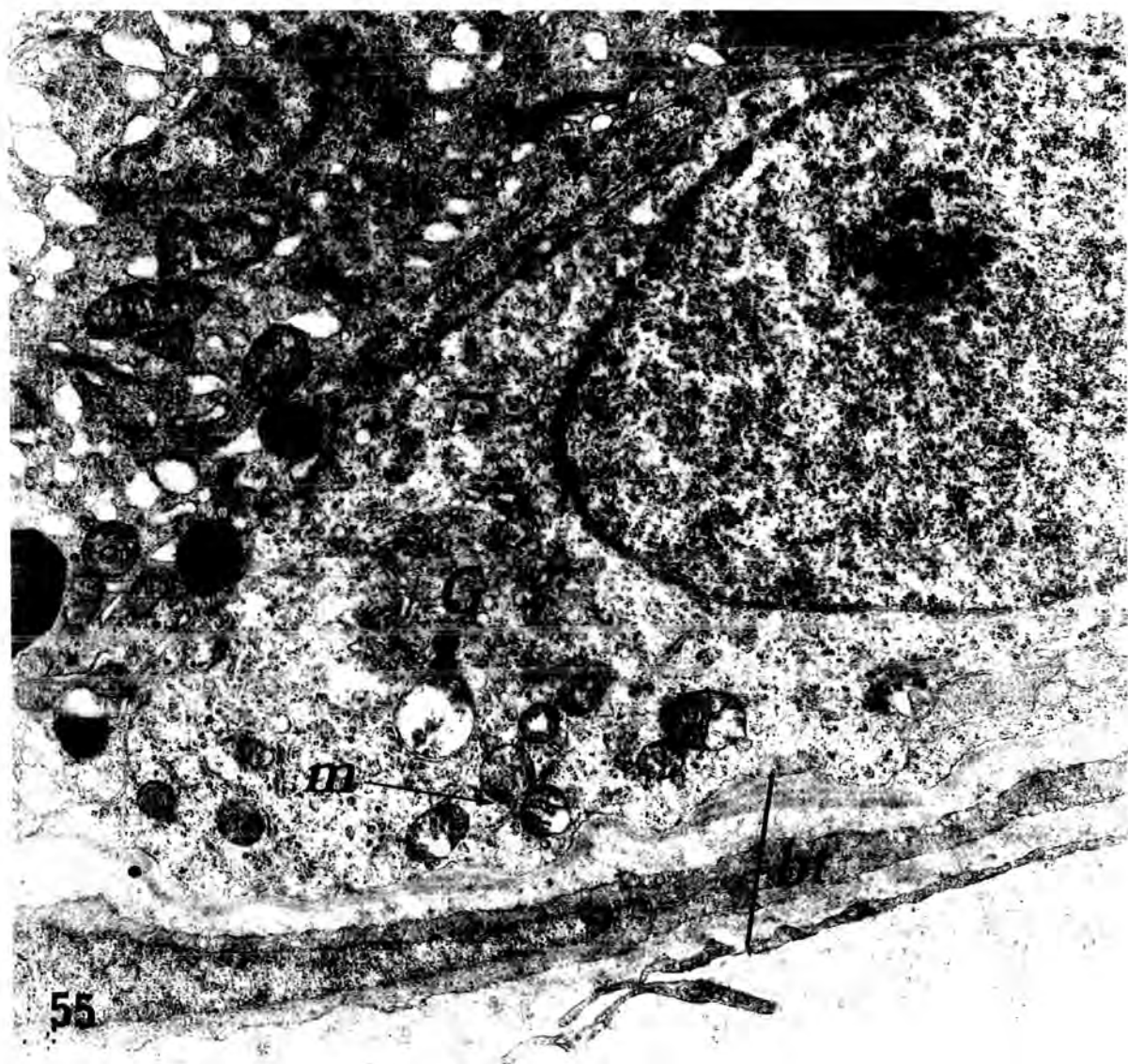


Plate 21

Fig.56A & B    An electron micrographs of a typical B-type spermatogonia ( B-spg ) from a normal ( control ) animal . Note the clumped chromatin ( ch ) on the nuclear membrane , and relatively electron dense cytoplasm. bt , boundary tissue .

Fig.56A : X 8000

;

Fig.56B : X 8000 .

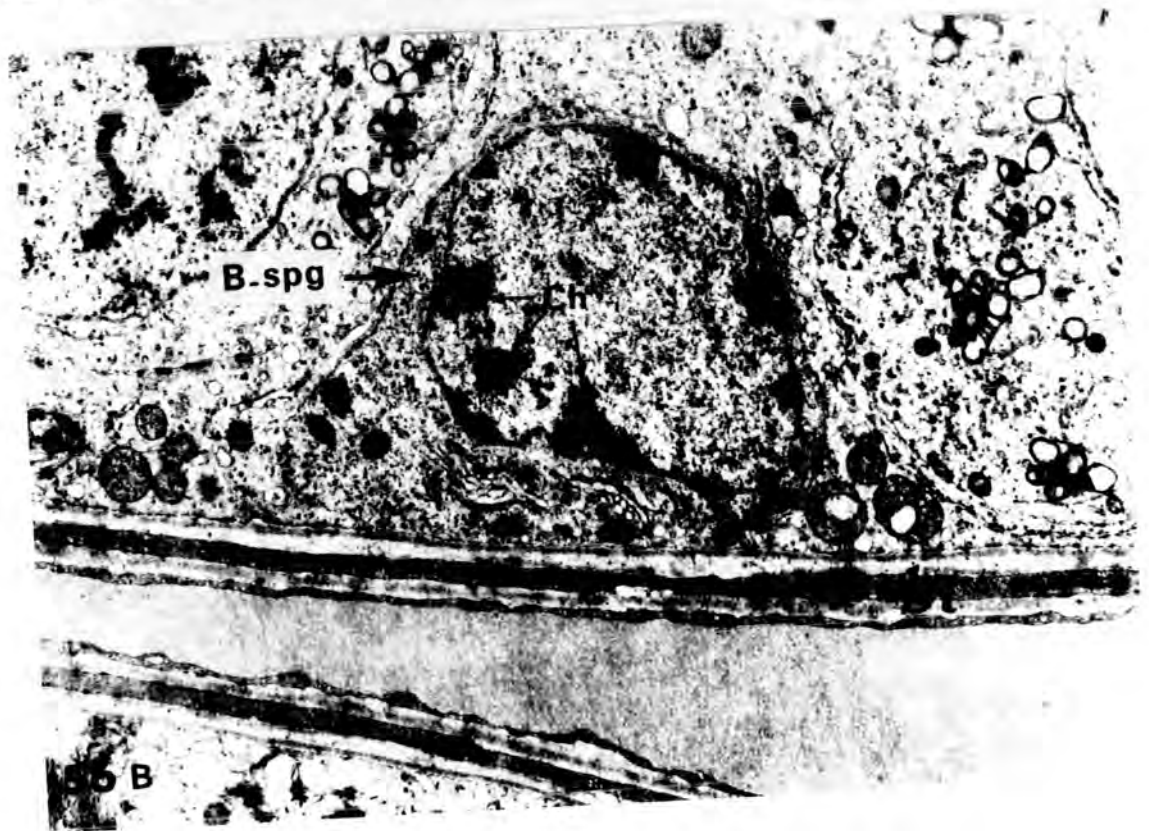
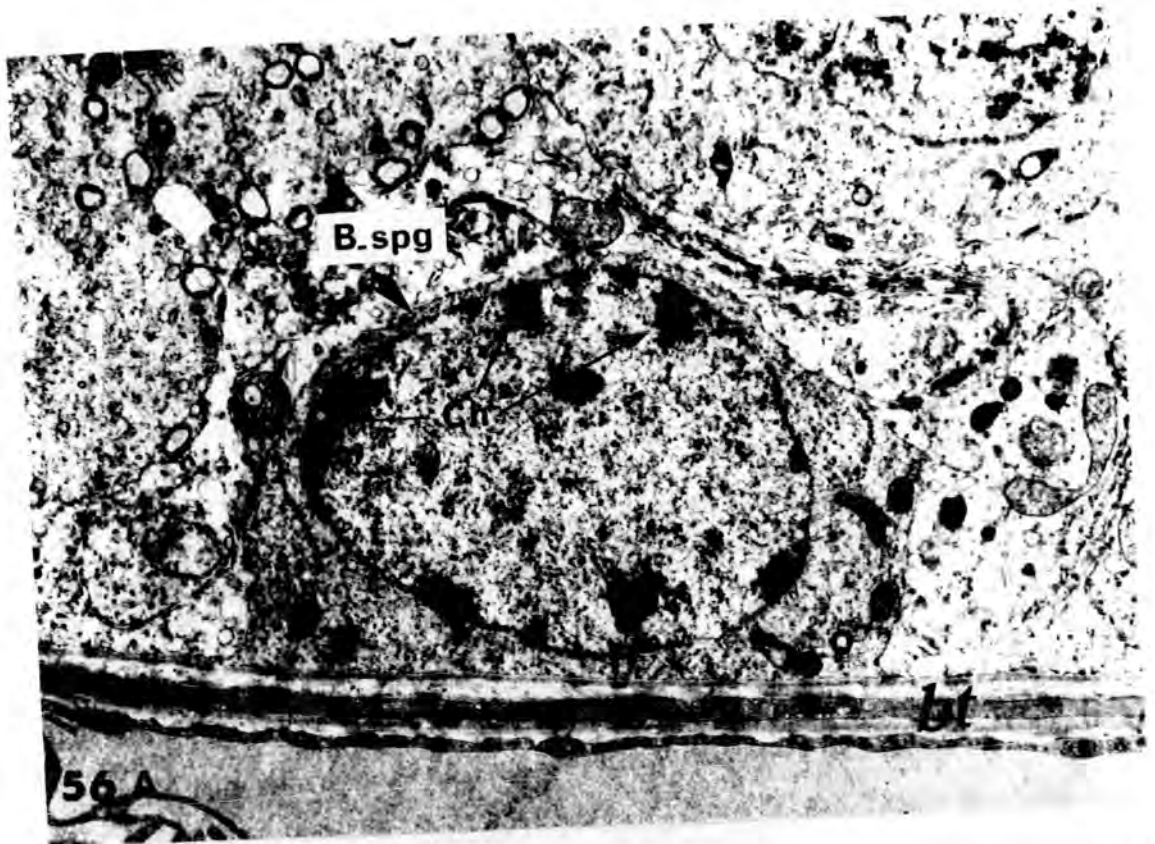


Plate 22  
-----

Fig.57 An electron micrograph of transverse section of a seminiferous tubule of a testis from an animal injected with 0.1 cm<sup>3</sup> of Mepivacaine.HCl, 4% , and killed after 12 hours , showing a degenerating B-type spermatogonium . Vacuolated spaces ( asterisks ) separate the cell from the Sertoli cell cytoplasm .

C , spermatogonium cytoplasm ; m , spermatogonium mitochondria ;  
N , spermatogonium nucleus ; So , Sertoli cell cytoplasm ;  
Sm , Sertoli cell mitochondria ; Sn , Sertoli cell nucleus .

X 8000

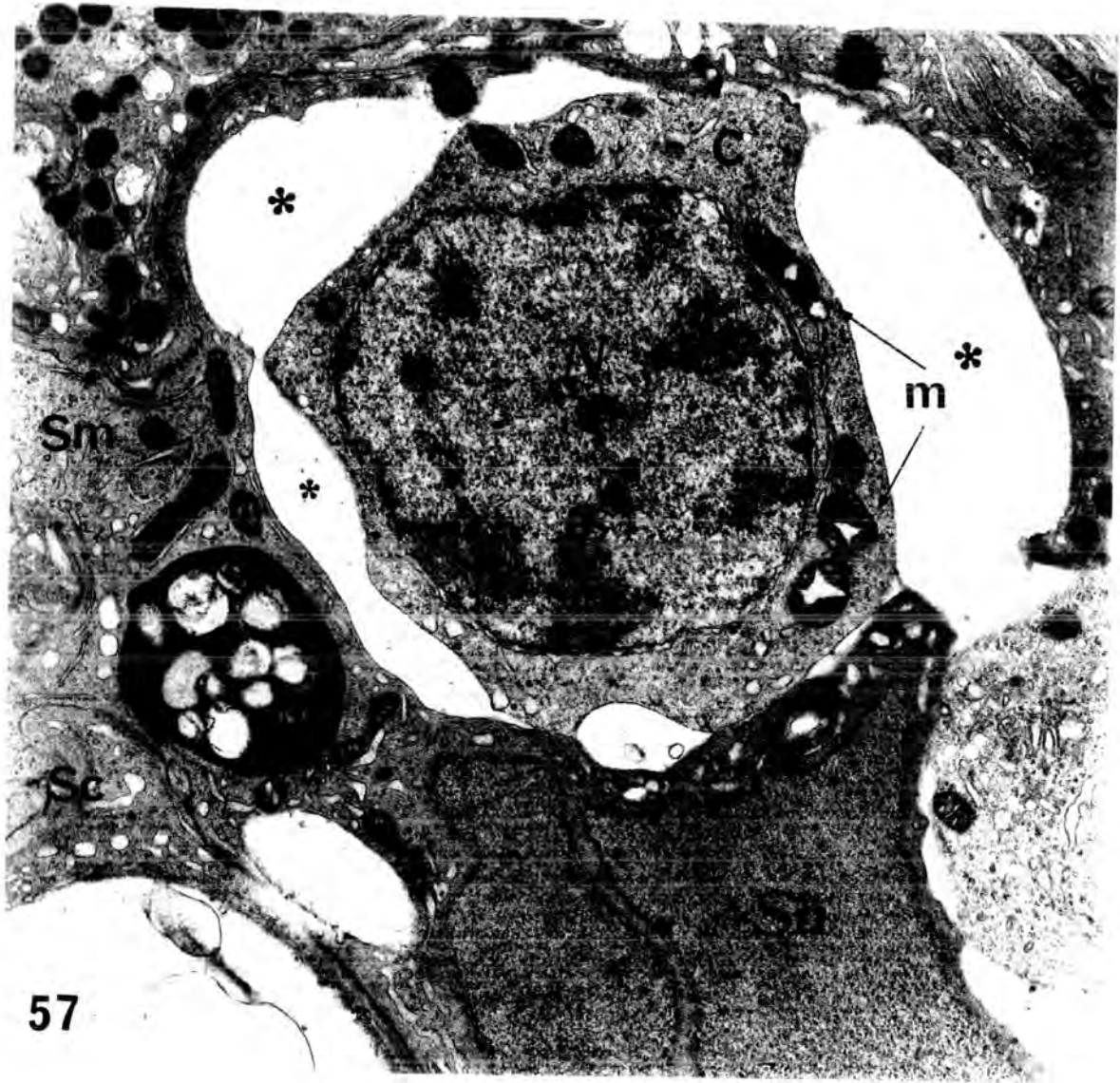
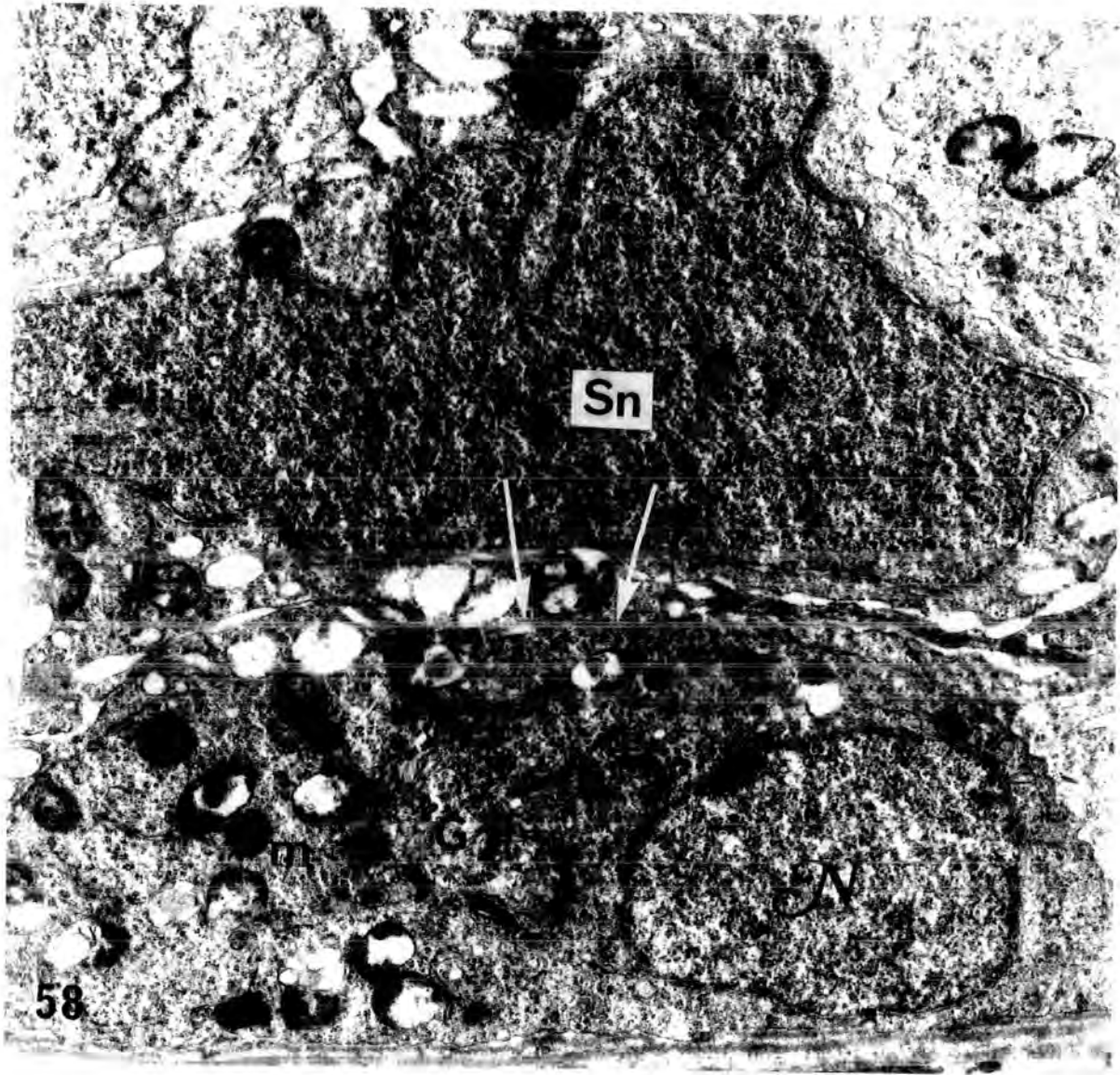


Plate 23

Fig.58 An electron micrograph of a transverse section of a seminiferous tubule from a testis of an animal injected with 0.5 cm<sup>3</sup> of Mepivacaine\_HCl , 4% , and killed after 12 hours , showing damage in the mitochondria of an A-type spermatogonium . Note the disintegration of internal cristae and accumulation of material close to the mitochondrial membrane . It appears that the cytoplasm of the spermatogonium has become continuous with that of the Sertoli cell cytoplasm as a result of disintegration of both cell membranes ( arrows ) .

G , Golgi apparatus ; m , mitochondria ; N , spermatogonium nucleus ; Sn , Sertoli cell nucleus .

X 12600



### 3- SPERMATOCYTES

#### (a) Normal primary spermatocytes :

The nuclei of interphasic primary spermatocytes showed coarse flakes of chromatin associated with the nuclear membrane . They were separated from the boundary tissue by narrow strands of Sertoli cell cytoplasm . The cytoplasm of the primary spermatocytes was scanty , with little demonstrable endoplasmic reticulum , but small clumps of ribosomes were evenly distributed throughout it .

Typical intercellular bridges are common between primary spermatocytes in all stages of meiosis . These intercellular bridges and intranuclear synaptonemal complexes characterize the primary spermatocytes . Along the margins of the bridge , the cytoplasmic membrane appears to be thickened . This thickening was suggested to be a condensation of RNA along the membranes ( Gardner and Holyoke , 1964 ) . The intercellular bridges represent an incomplete cleavage of B-type spermatogonium into the primary spermatocytes . The synaptonemal complexes or chromosome "cores" , characteristic of this stage , were seen regularly in these preparations . In longitudinal section these structures appeared as three electron-dense parallel lines , often extending to the nuclear membrane .

Older primary spermatocytes showed an increase in the size of both the nucleus and cytoplasm . The synaptonemal complexes persisted , and several large clumps of moderate electron dense substances were in contact with their nuclear membranes .

All these characteristic features of the primary spermatocytes are shown clearly in plate 24 , fig. 59 .

The mitochondria of primary spermatocytes were generally rounded or elongated , and increased markedly in numbers ( Figs.59 & 72 ) . The mitochondria sometimes displayed marked branching , which , as suggested by Palade ( 1952a ) , were indicative of their multiplication . They tended to aggregate in groups , and an electron-dense material was present between the mitochondria within a cluster ( Figs.59 & 72 ) . André ( 1962 ) reported that these clusters occurred during the period of active formation of new mitochondria . Spermatocyte mitochondria had more regular cristae than those of spermatogonia , and in some cases dilated cristae occupied most of the mitochondria volume . The remaining matrix contained no internal granules , and appeared as light spaces ( see figs. 59 & 72 ) .

(b) Normal secondary spermatocytes :

Secondary spermatocytes tended to be smaller than late primary spermatocytes . Their nuclei were spherical and the nuclear chromatin was rather diffuse , centrally located and in large clumps ( Watson , 1952 b ) . There was no evidence of nucleolar material in these cells .

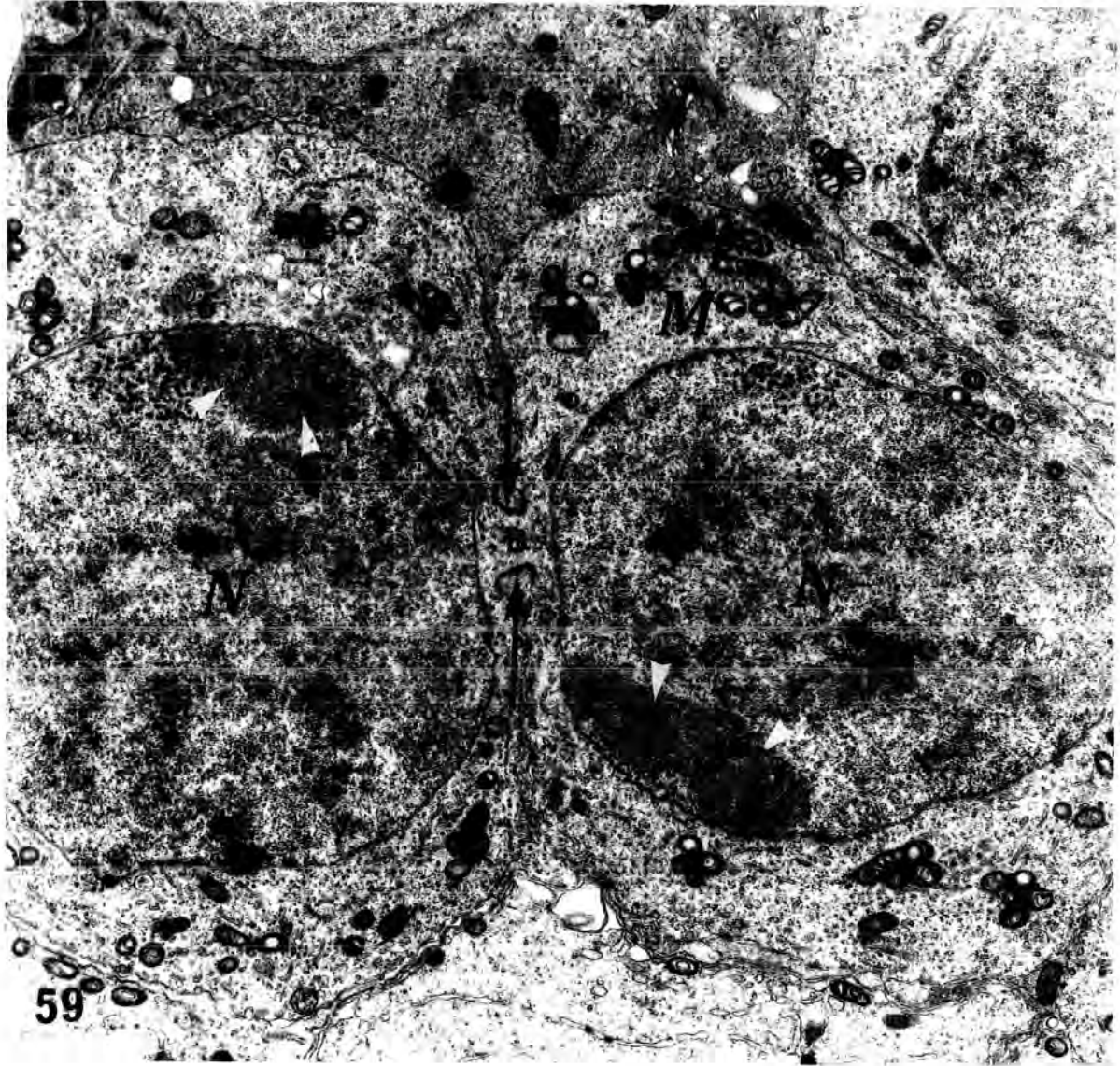
The life span of the rat secondary spermatocyte is only 2% of the spermatogenic wave , so that they are rarely seen ( Roosen-Runge and Giesel, 1950 ) .

The mitochondria of secondary spermatocytes showed great similarity with those of spermatids . At higher magnification the mitochondria had thickened membranes , owing to the cristae being arranged parallel to the outer membrane . It is unfortunate that in the many sections of normal testes examined , in no case secondary spermatocytes were observed . In consequence , the above description relies on evidence presented in the literature .

Plate 24

Fig.59 An electron micrograph of two primary spermatocytes ( from a normal control animal ) connected by an intercellular bridge ( B ) , where the cell membrane has become markedly thickened ( arrows ) . The nucleus ( N ) is large and contains clusters of chromatin granules and a typical accumulation of chromatin adjacent to the nuclear membrane ( arrow heads ) . The cytoplasm is scanty and contains both individual mitochondria and clusters of mitochondria ( M ) with related dense , intermitochondrial substance .

X 8000



(c) Spermatocytes of Mepivacaine-HCl treated rats :

Spermatocytes were abundant in the light microscopical preparations in the least abnormal tubules of treated animals ( plate 25 ) . The primary spermatocytes tended to exfoliate , sometimes extensive exfoliation of cells took place ( plate 25 , figs.60 & 61 ) ; and pyknotic and karyolysis were evident . Some of these cells separated and lay in the lumen , but , using the light microscope , it was usually difficult to differentiate between degenerating primary and secondary spermatocytes .

When primary spermatocytes were studied , both with electron and light microscopy , they showed fairly gross structural changes in their shape mainly in the elongation of their cytoplasm ( plate 26 , figs.64 & 65 ) . One of the main features of these affected spermatocytes was the formation of clear , vacuolated spaces between the cytoplasmic limit of the spermatocytes and that of the Sertoli cells ( Plate 25 , fig.62 & plate 26 , fig.65 ) .

During stage XIV of the cycle ( Leblond and Clermont , 1952 ) the primary spermatocytes and secondary spermatocytes undergo maturation division resulting in the formation of spermatids . In this stage , some dividing spermatocytes degenerated and exfoliated , resulting in a vacuolated Sertoli cells ( Plate 25 , fig. 62 ) .

In some tubules binucleate and multinucleate primary spermatocytes were seen as a result of fusion of their cytoplasm , and they appeared more or less normal when studied with the electron microscope(plate 27,figs.66, 67 and 68 ) .

Many large lipid droplets appeared in the Sertoli cells as a result of Mepivacaine-HCl administration , and sometimes they distorted the cell membrane of the spermatocytes ( Plate 30 , fig.71 and Plate 31 , fig. 72 ) .

Plate 25

Fig.60 Light micrograph of transverse section of a testis from an animal injected with 0.1 cm<sup>3</sup> of Mepivacaine-HCl , 4% , and killed after 6 hours . X 250

Fig.61 Light micrograph of transverse section of a testis from an animal injected with 0.5 cm<sup>3</sup> of Mepivacaine-HCl , 4% , and killed after 10 days . X 250

Fig.62 Light micrograph of transverse section of a testis from an animal injected with 0.5 cm<sup>3</sup> of Mepivacaine-HCl , 4% , and killed after 24 hours . X 250

Figs. 60 , 61 & 62 illustrate exfoliation of primary spermatocytes . In figs.60 & 61 , pyknotic spermatocytes ( arrows ) are migrating towards the lumen of the tubules . In fig.62 , meiotic division ( arrow heads ) can be seen in the migratory spermatocytes . Note the gross vacuolation ( v ) in the Sertoli cell cytoplasm which has occurred as a result of spermatocyte loss from the basal layer .

Fig.63 High power light micrograph of transverse section of a testis from an animal injected with 0.1 cm<sup>3</sup> of Mepivacaine-HCl , 4% , and killed after 12 hours , showing complete absence of late spermatids from the tubule . Note the thickness and wavy appearance of the boundary tissue ( arrow heads ) . X 250

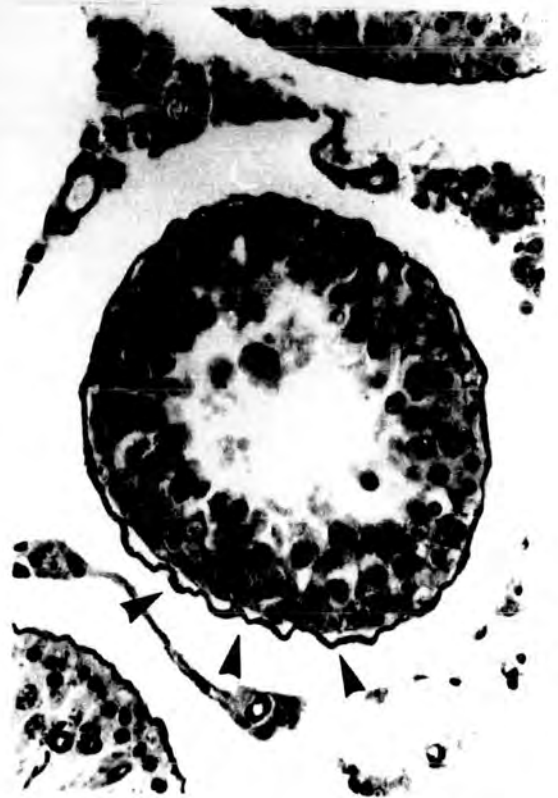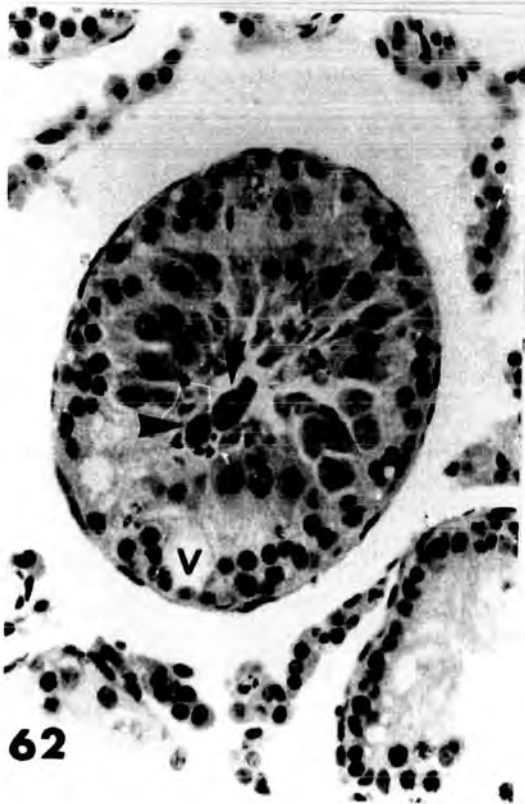
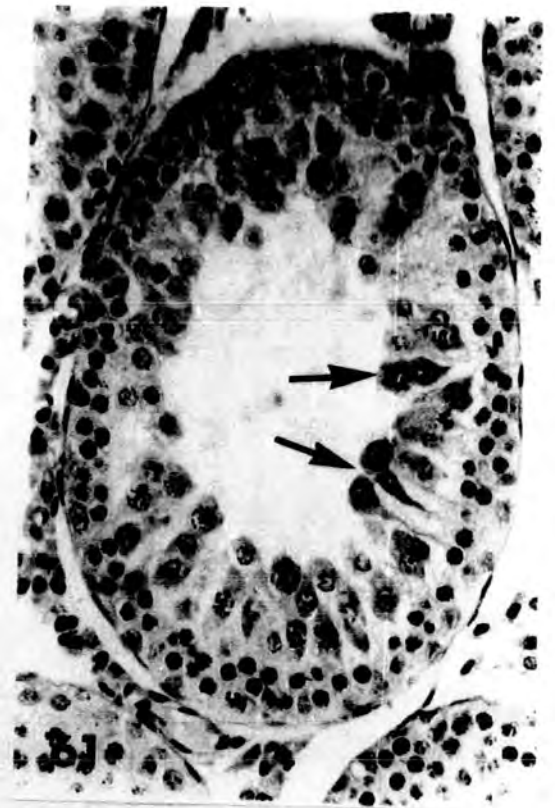
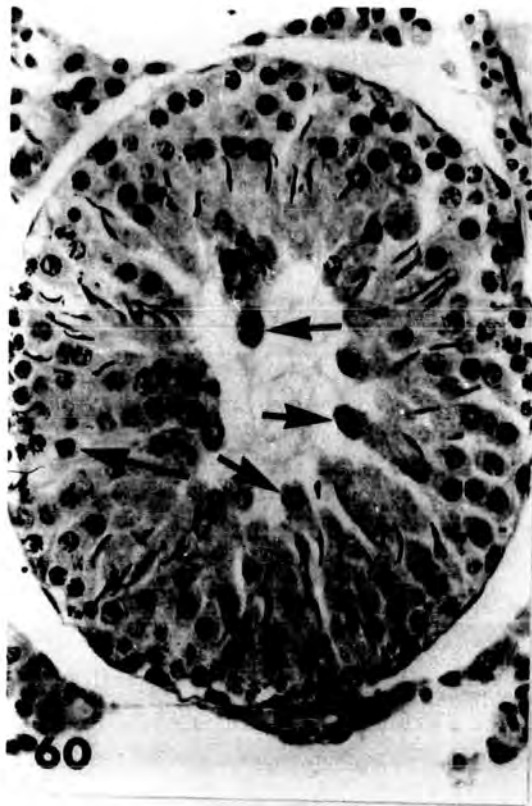


Plate 26

Fig. 64 High power light micrograph of a seminiferous tubule from transverse section of a testis from an animal injected with 0.5 cm<sup>3</sup> of Mepivacaine\_HCl , 4% , and killed after 6 hours . X 500

Fig. 65 An electron micrograph of primary spermatocytes in transverse section of a seminiferous tubule from an animal injected with 0.1 cm<sup>3</sup> of Mepivacaine\_HCl , 4% , and killed after 6 hours . X 10000

Together these figures illustrate (i) the relatively normal cytological appearance of the primary spermatocytes nucleus and cytoplasm ( fig. 65 ) i.e scanty cytoplasm ; clusters of rounded and elongated mitochondria ; rounded nucleus containing clustered chromatin ( Compare with primary spermatocyte from normal animal illustrated in fig. 59 ) (ii) Fairly gross structural changes in the shape of the primary spermatocyte , mainly the elongation of the cells ( Figs. 64 & 65 ) and the occurrence of certain cells that contain two nuclei ( Fig. 64 , arrow head ). Note the extracellular spaces ( sp ) that occur between the spermatocytes as a result of separation and elongation .

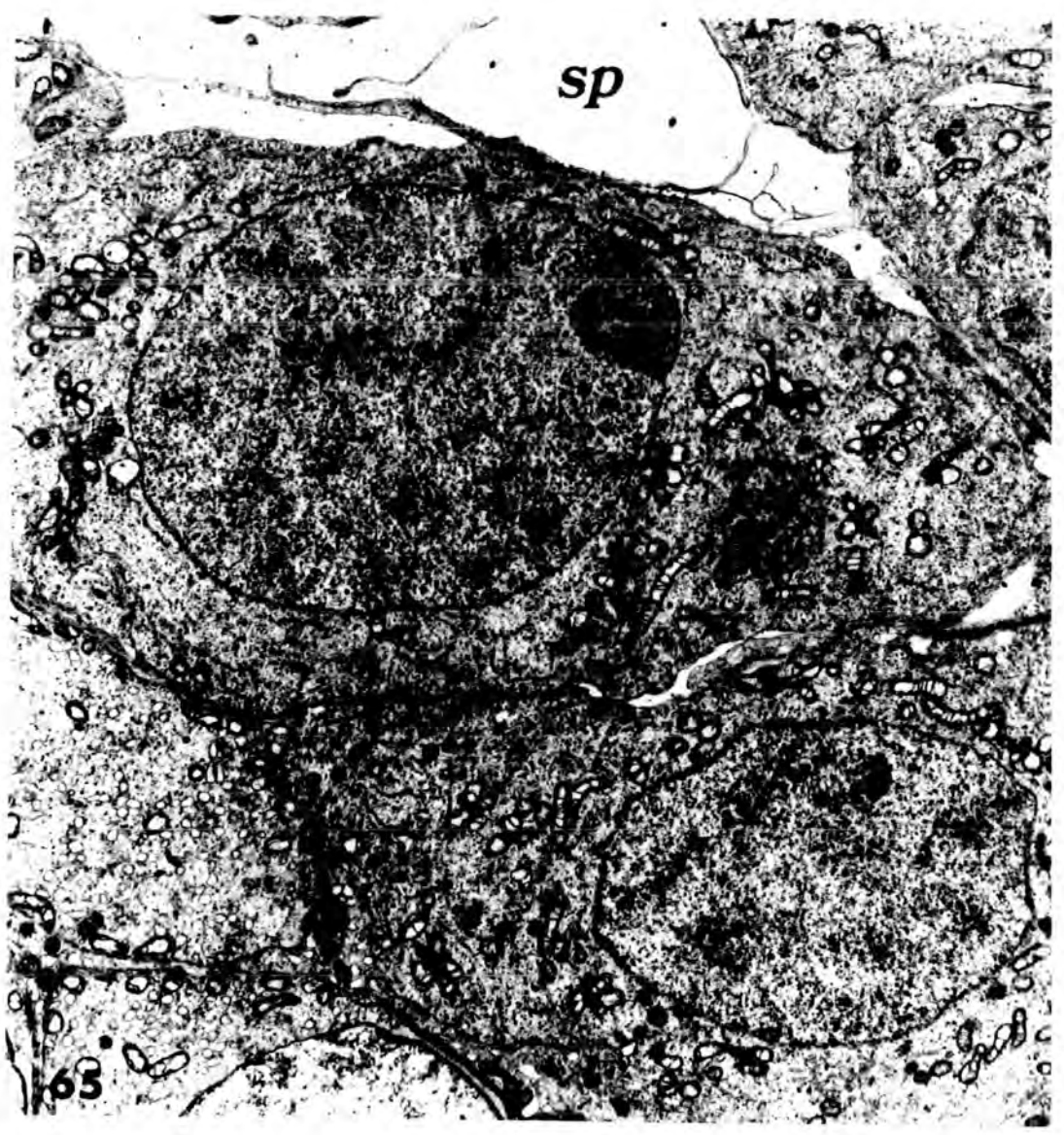
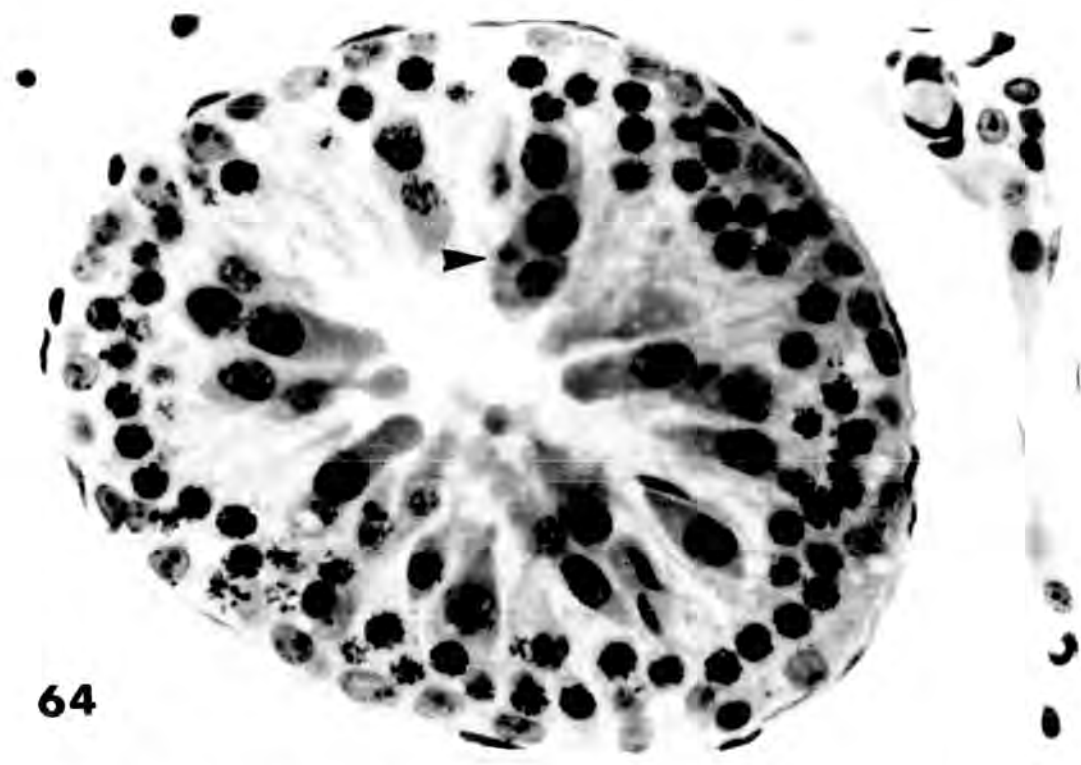


Plate 27

Fig.66 High power light micrograph of transverse section of a testis from an animal injected with 0.5 cm<sup>3</sup> of Mepivacaine\_HCl , 4% , and killed after 6 hours . X 400

Fig.67 Low power light micrograph of transverse section of a testis from an animal injected with 0.1 cm<sup>3</sup> of Mepivacaine\_HCl , 4% , and killed after 24 hours . X 100

Fig.68 An electron micrograph of a binucleate spermatocyte from an animal injected with 0.1 cm<sup>3</sup> of Mepivacaine\_HCl , 4% , and killed after 12 hours . X 8000

These figures illustrate the formation of multinucleate cells from primary spermatocytes . Figs. 66 and 68 show the binucleate condition ( b ) . Fig. 67 shows examples of both bi- and trinucleate ( t ) spermatocytes . As can be seen in fig.68 , the ultrastructure of the cytoplasm appears normal .

m , mitochondria of spermatocytes ; Spt-1 , primary spermatocyte .

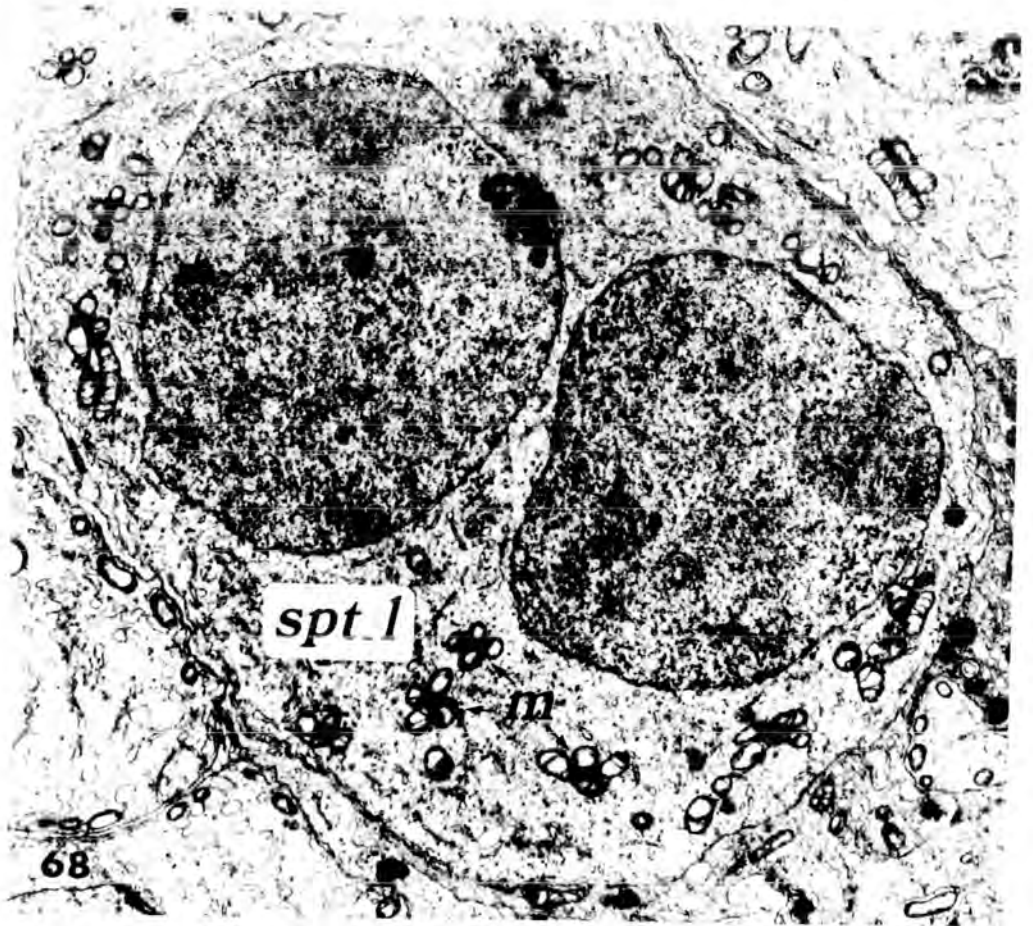
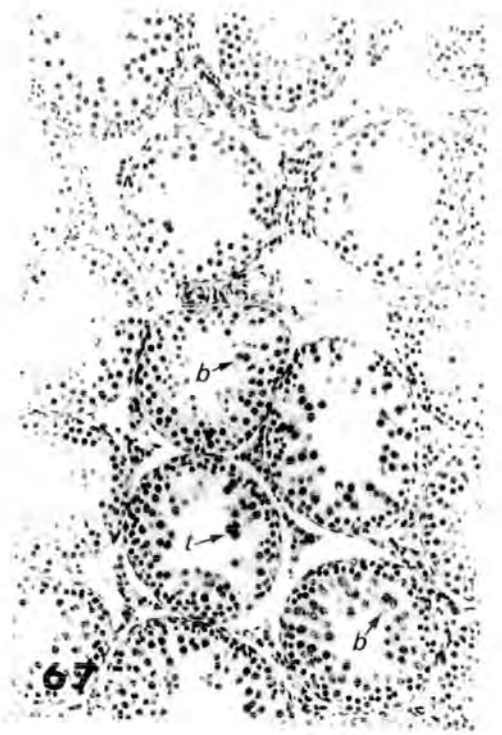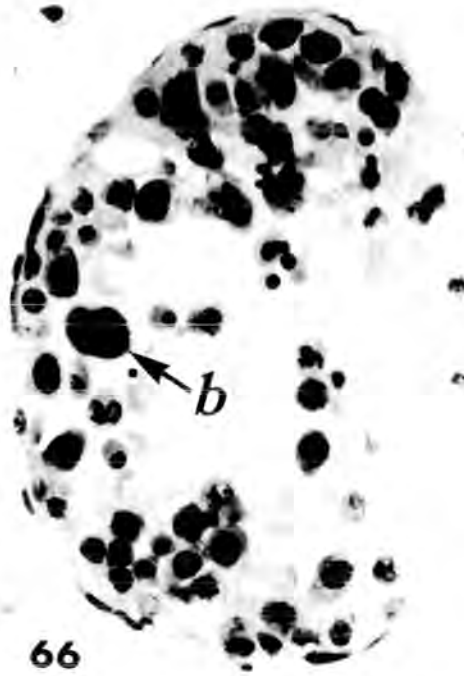


Plate 28

**Fig.69** An electron micrograph of a secondary spermatocyte from a transverse section of a seminiferous tubule from an animal injected with 0.5 cm<sup>3</sup> of Mepivacaine-HCl , 4% , and killed after 12 hours . The nucleus appeared irregular , and the nuclear membrane bulged outside toward the cytoplasm ( arrows ) . Note the elongated dark bodies which lie inside the cytoplasm ( arrow heads ) .

X 8000

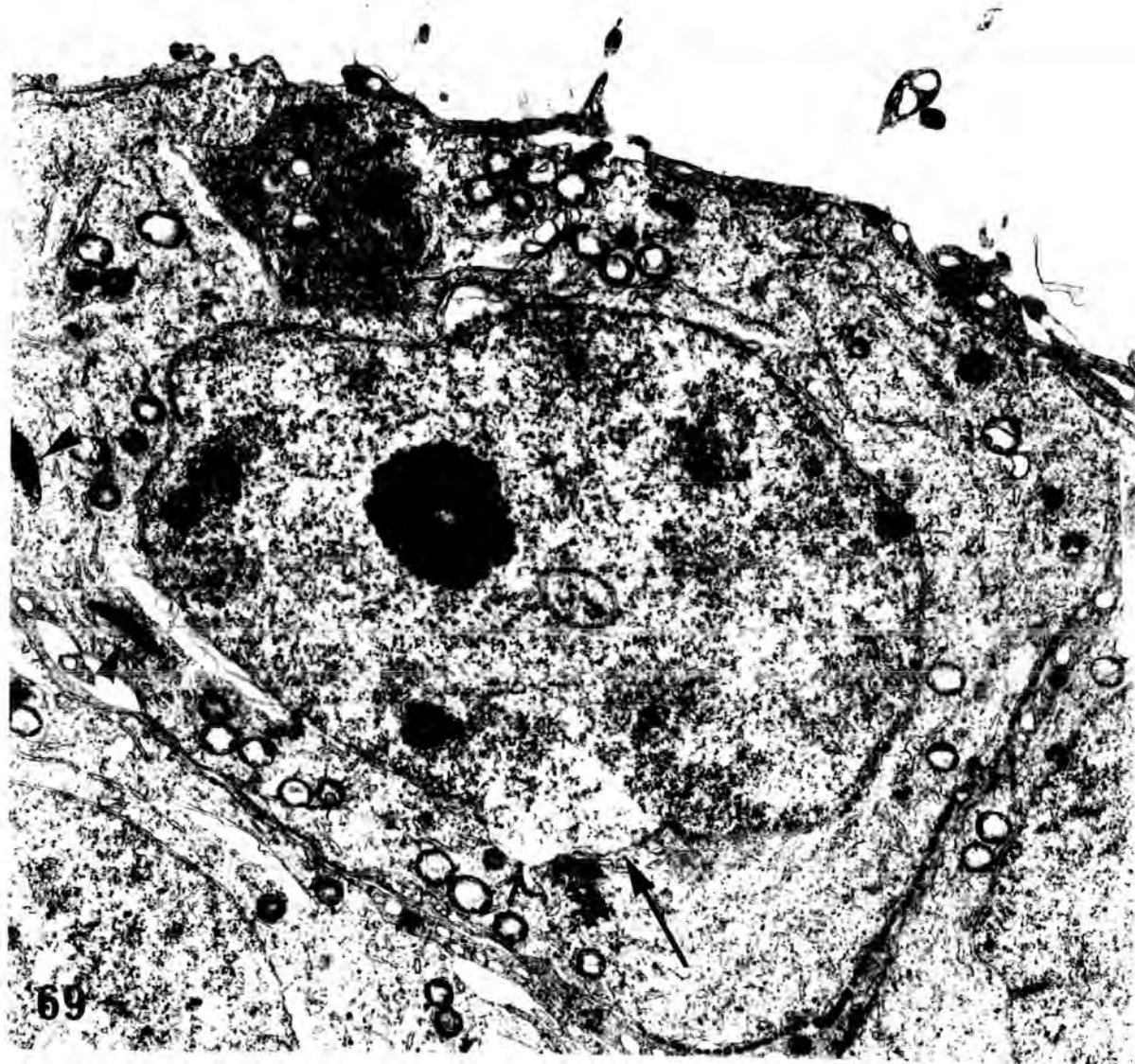


Plate 29

Fig.70 An electron micrograph of a secondary spermatocyte from transverse section of a seminiferous tubule from an animal injected with 0.1 cm<sup>3</sup> of Mepivacaine-HCl , 4% , and killed after 24 hours . A large lipid droplet , formed by fusion of fine lipid granules , is found inside the cytoplasm of the cell

L , lipid droplet ; Sc , Sertoli cell cytoplasm ;

Spt-2, secondary spermatocyte .

X 12600

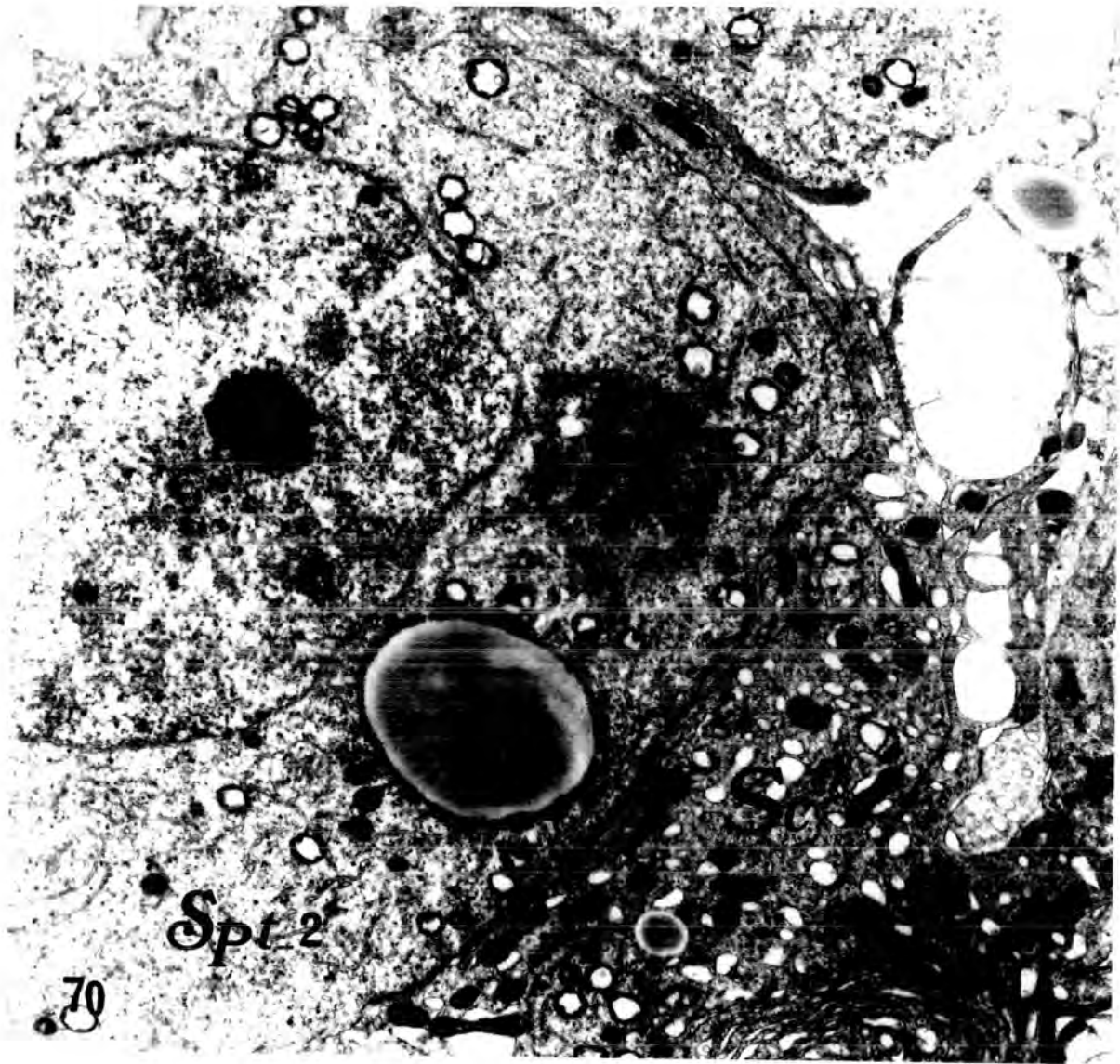


Plate 30

Fig.71 An electron micrograph of a primary spermatocyte , from an animal injected with 0.25 cm<sup>3</sup> of Mepivacaine\_HCl , 4% , and killed after 6 hours . The nuclear membrane is abnormally convoluted and the mitochondria are vacuolated and electron-dense . The cristae of the mitochondria are not clearly differentiated . Note the presence of large lipid droplets ( L ) in the Sertoli cell cytoplasm , which appear to be distorting the cell membrane of the primary spermatocyte by pushing in the direction of its nucleus .

X 12600

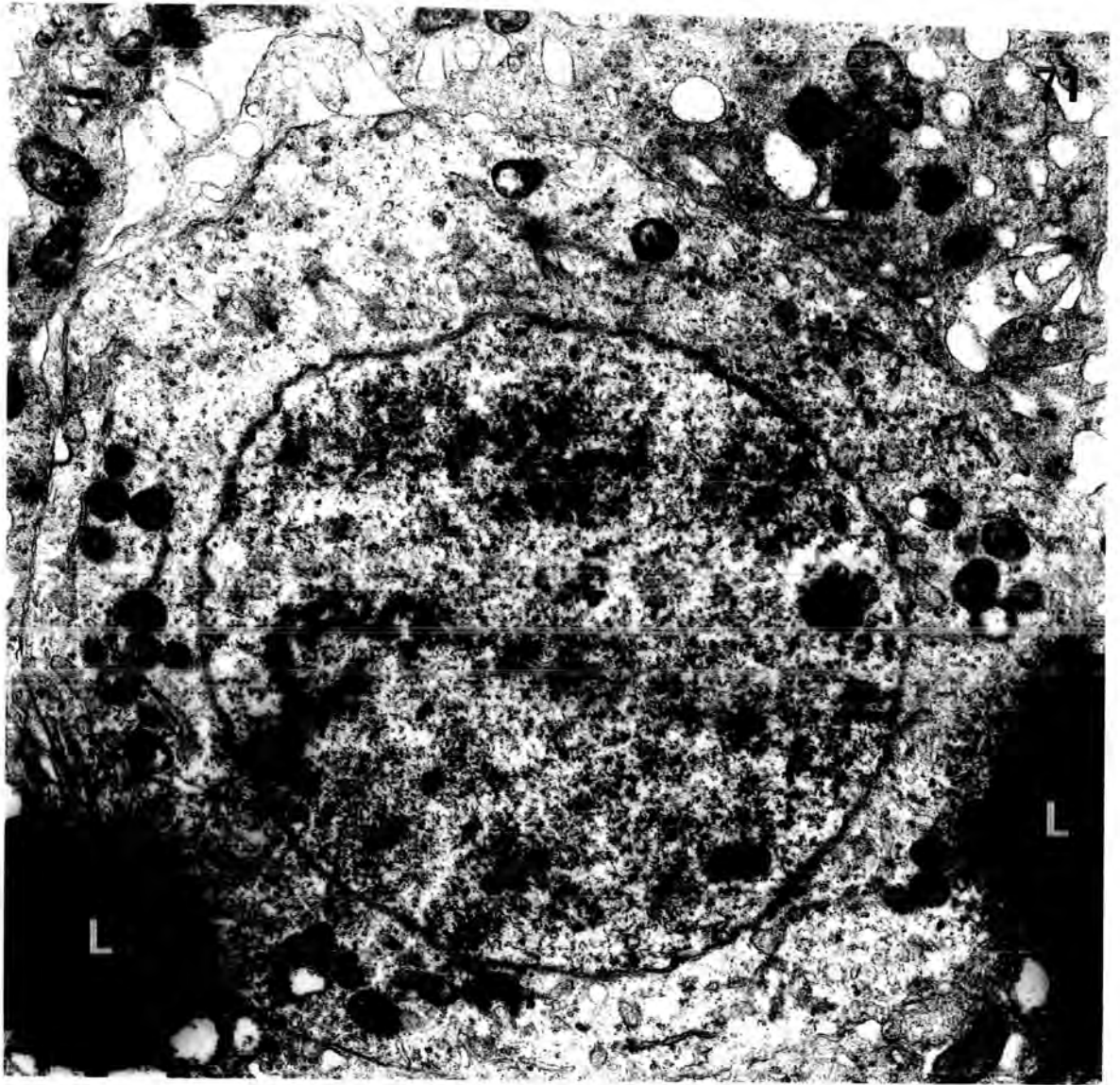


Plate 31

**Fig.72** An electron micrograph showing lipids in close contact with the affected spermatocyte . Note the lipid droplet ( L ) pushing the cell membrane towards the nucleus . The lipid droplet looks as if it is found within the cytoplasm of this primary spermatocyte .

X 8000

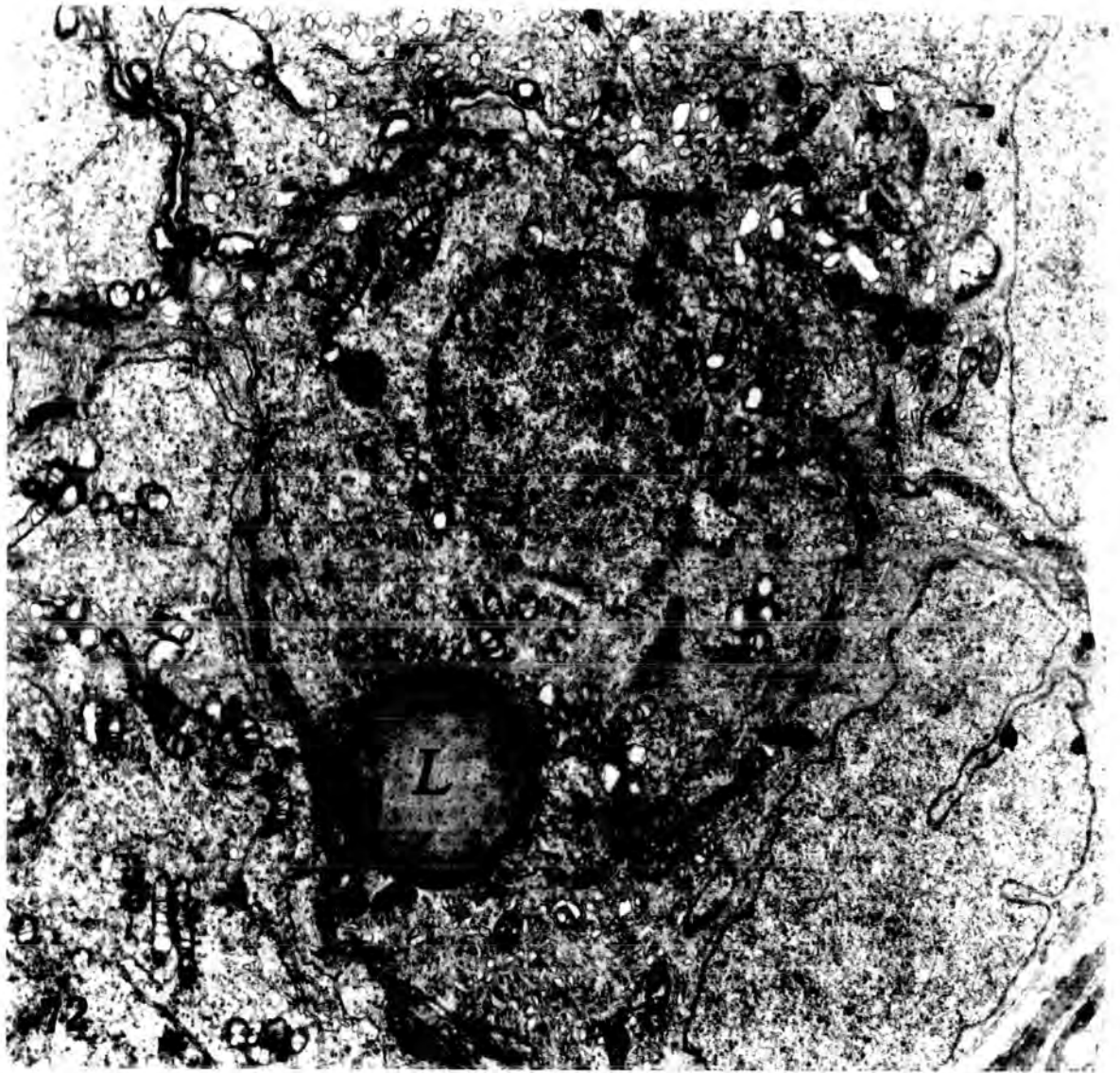


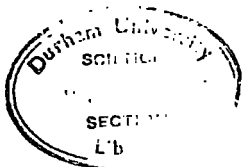
Plate 32

Fig.73 High power electron micrograph of mitochondria ( m ) of a normal primary spermatocyte ( spt ) . They may appear as short rods or spheres with a matrix of low density and internal membranes which are oriented irregularly , but mostly perpendicular to the mitochondrial surface . Note the presence of the dense intermitochondrial substance ( arrows ) .

X 20000

Fig.74 High power electron micrograph of mitochondria ( m ) of the primary spermatocyte ( spt ) from an animal injected with 0.25 cm<sup>3</sup> of Mepivacaine\_HCl , 4% , and killed after 24 hours . Note the disruption and fusion of the membranes , which give an electron-dense appearance .

X 28000



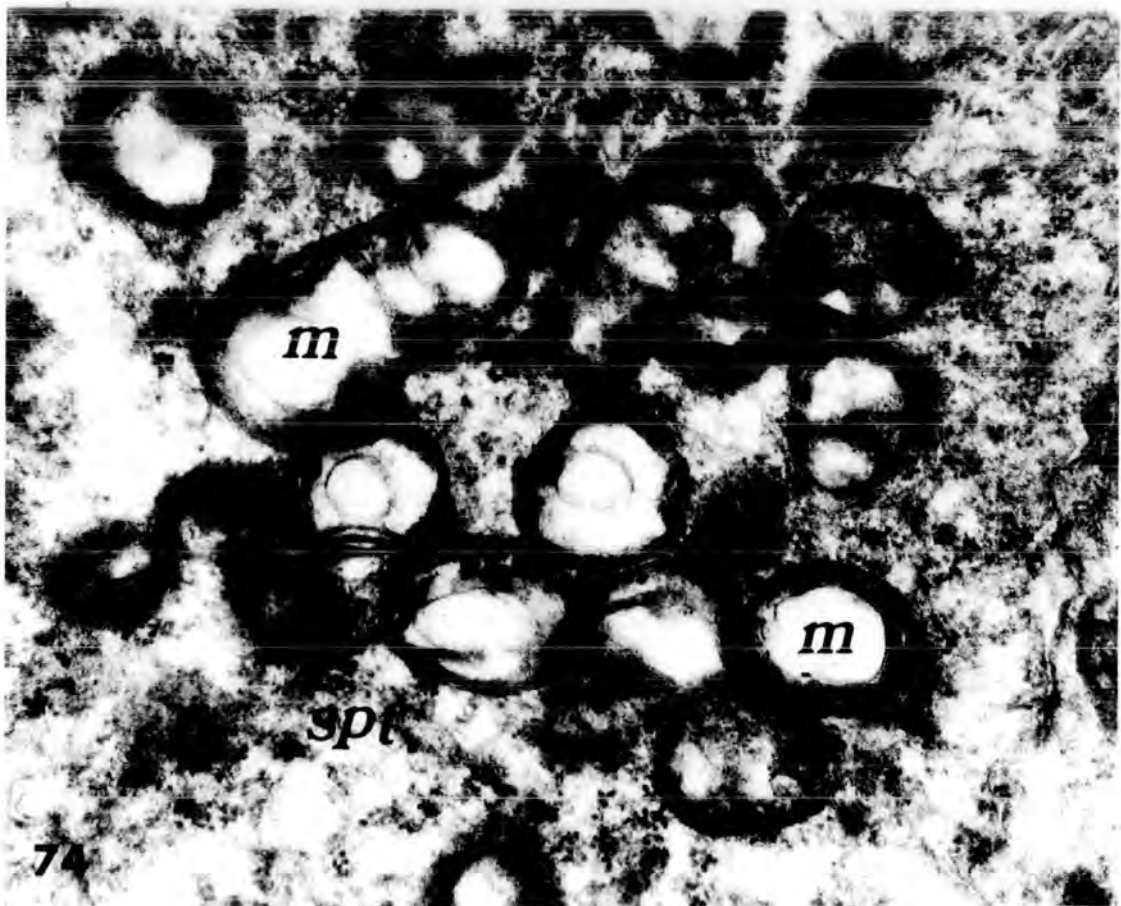
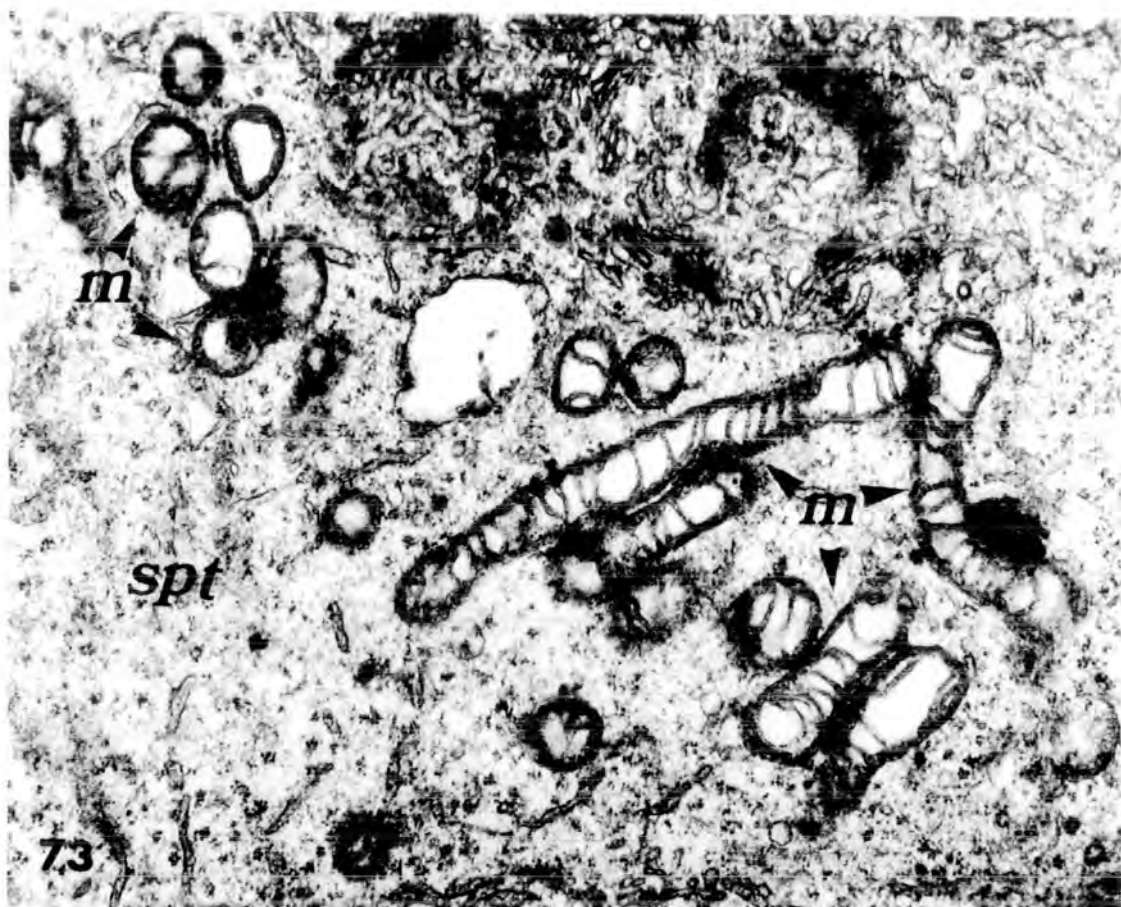
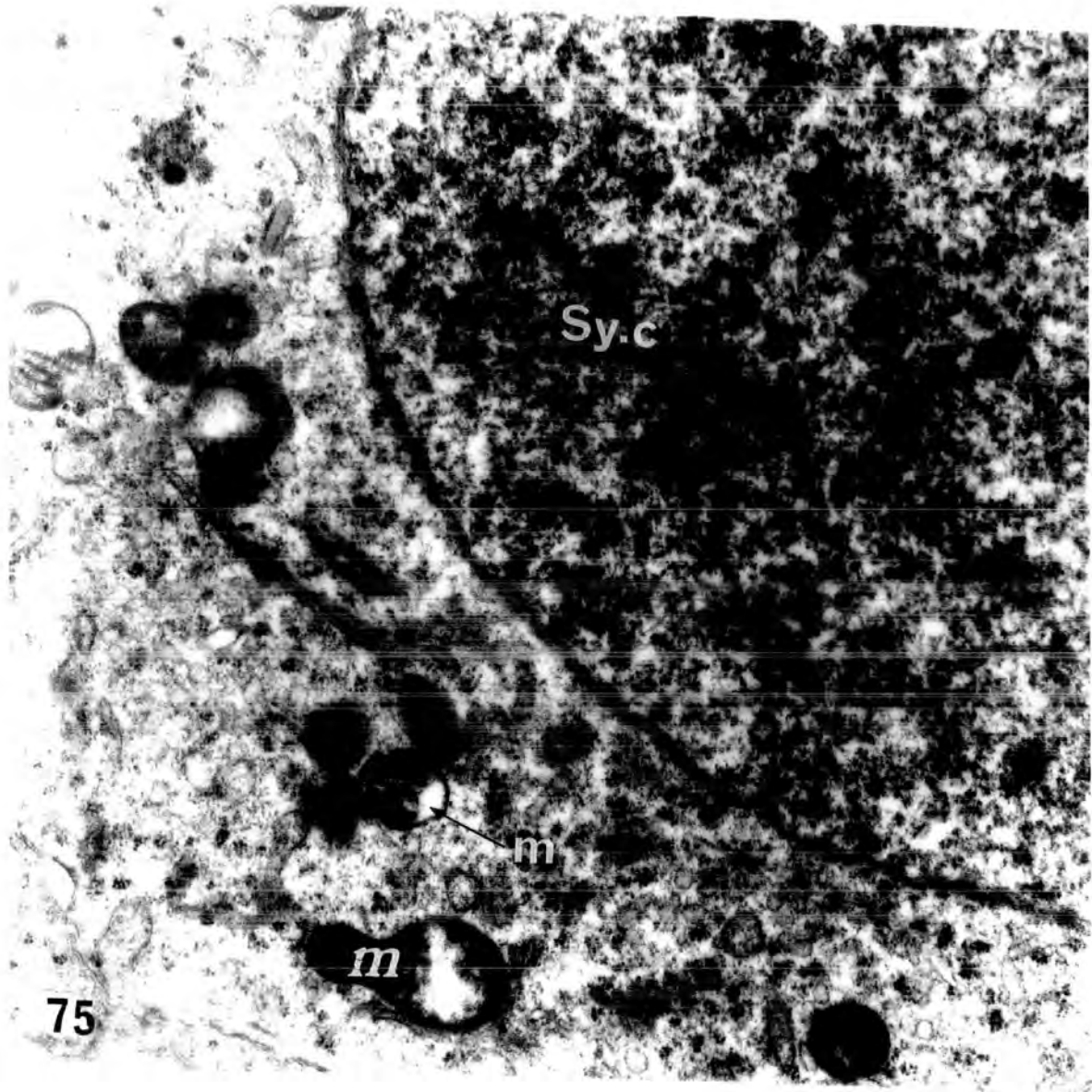


Plate 33

**Fig.75** An electron micrograph of a spermatocyte from an animal injected with 0.25 cm<sup>3</sup> of Mepivacaine-HCl , 4% , and killed after 6 hours . The cytoplasm contains several swollen mitochondria ( m ) with grossly disrupted cristae .

The presence of a synaptonemal complex ( Sy.C. ) in the nucleus of this primary spermatocyte suggests that prophase of the first meiotic division has proceeded in the presence of the drug.

X 20 000



Although the secondary spermatocytes are very rare owing to their very short life span , some appeared in the preparations of the treated rats. The secondary spermatocytes showed marked destruction in some parts of the cytoplasm , also the nuclear membrane appeared to bulge into the cytoplasm , suggesting a tendency to lysis ( Fig.69 ) . Large lipid droplets could be formed inside the cytoplasm of the secondary spermatocytes ( Fig.70 ) . The appearance of such lipid droplets inside the cells , and the presence of large vacuoles in the Sertoli cell cytoplasm , reflected the damage caused to the cell itself and to the tissue .

The mitochondria of the spermatocytes showed disruption and fusion of the membranes , which resulted in an electron dense appearance , ( Plate 32 , fig. 74 ) . In some spermatocytes , several swollen mitochondria with grossly disrupted cristae were evident ( Plate 33 , fig.75 ) .

Cup-shaped mitochondria in primary spermatocytes :

Christensen and Chapman , ( 1959 ) , observed in the course of an electron microscope study of rat testicular interstitial cells ( Leydig cells ) , mitochondria that seemed to have a shape resembling that of a shallow cup or bowl .

Similar shaped mitochondria have been observed in Mepivacaine-HCl treated animals . Meridian , oblique and horizontal sections through cup-shaped mitochondria are seen shown in plate 34 , fig.76 , and also dramatically in plate 34 .

Plate 34

Fig.76 An electron micrograph of a primary spermatocyte from an animal injected with 0.5 cm<sup>3</sup> of Mepivacaine-HCl , 4% , and killed after 12 hours . The mitochondria are cup- or bowl-shaped but appear as various configuration in the electron micrograph as a result of the mode of sectioning of each organelle .

X 12600

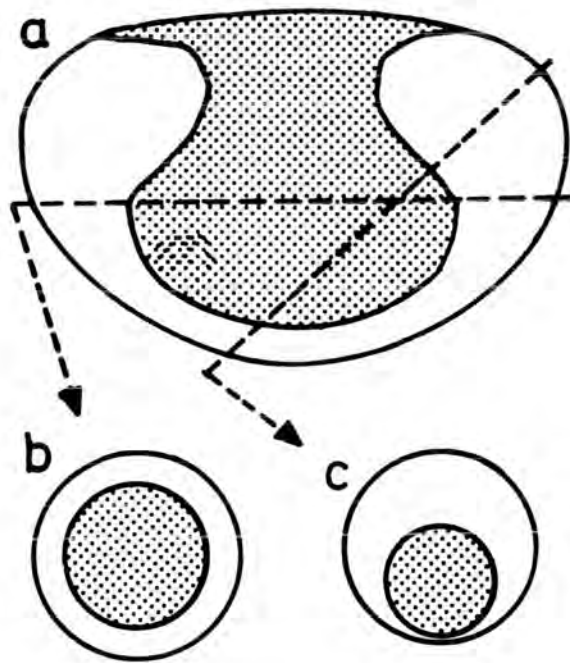
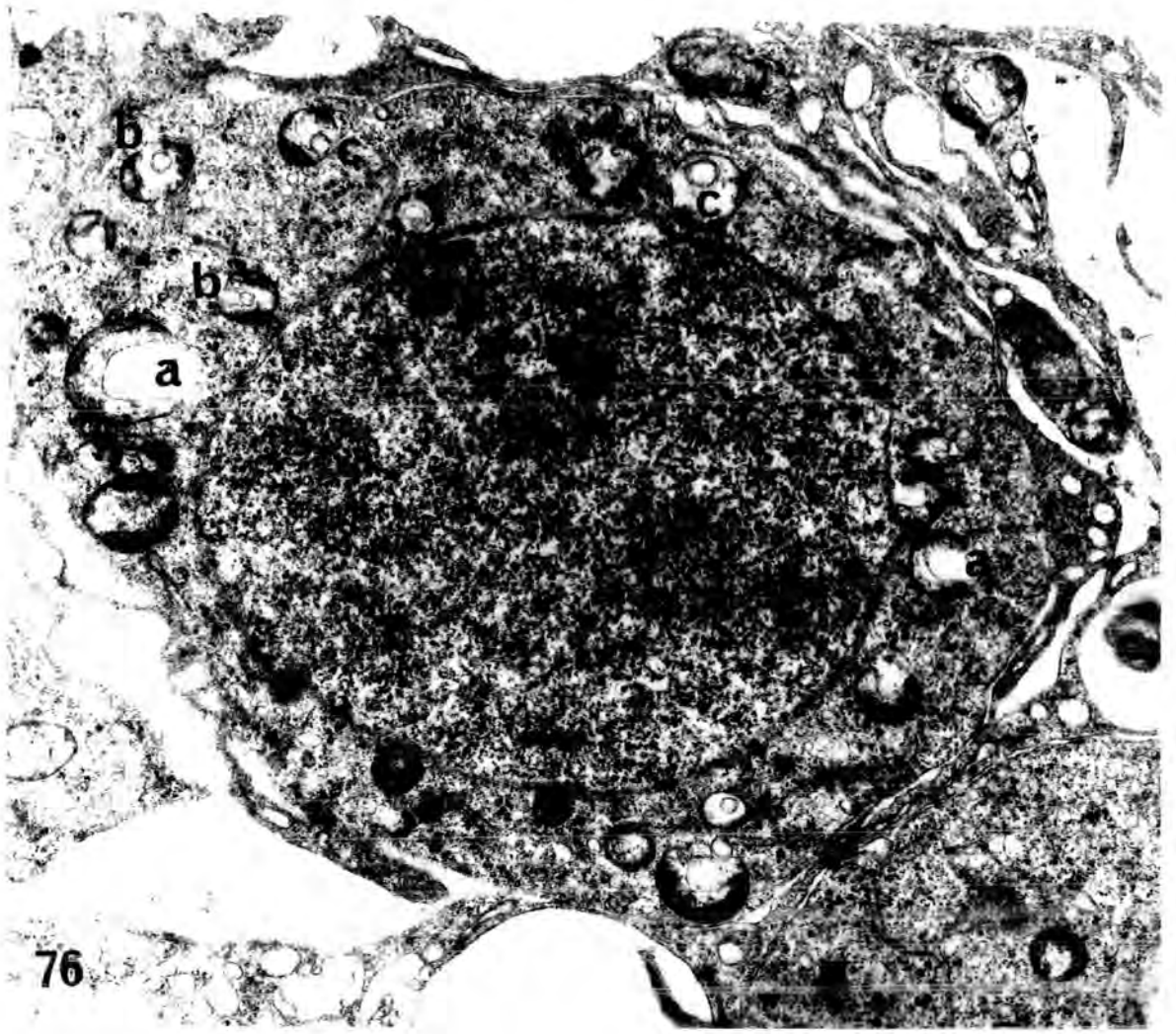
The diagram below illustrates some of the two dimensional shapes that can be obtained from the 3 dimention cup-shaped organelle .

(a) Section through the meridian .

(b) Horizontal section .

(c) Oblique section .

( After Christensen & Chapman , 1959 )



#### 4- SPERMATIDS

---

According to the nuclear morphology , spermiogenesis can be divided into three main periods : round spermatids , nuclear elongation , and elongated spermatids . The nuclei of the young spermatids are normally spherical ; they become elongated during the middle of spermiogenesis and then assume a form which will be that of the head of the spermatozoa .

The nuclear membrane of young spermatids is made of two sheets with a space between . The space becomes a uniformly narrow region of contact with the acrosomic vacuole . There are few/no nuclear pores in young spermatids .

PAS-staining and electron microscope techniques have permitted accurate observations of the acrosome formation of the Golgi body during spermiogenesis . From the morphological point of view , several stages are distinguishable , which were used as a basis for a precise classification of the seminiferous epithelial cycle ( Leblond & Clermont , 1952 ) .

The first or Golgi phase consists of three successive stages , leading to the formation of " the acrosomic granule " . The first of these three stages is characterized by the presence of only the moderately staining idiosome . In stage 2 , one to four granules staining a brilliant purple occur , called " the preacrosomic granules " . Later , these coalesce into a single vesicle , forming the acrosomic granule . At the end of this stage, the acrosomic granule approaches the nucleus .

The second , or Cap-phase , consists of 4 consecutive stages , during these stages the vesicle extends more and more , and the acrosomic granule develops and flattens on the nucleus of the spermatid while the Golgi apparatus separates from the acrosomic structure and migrates toward the opposite

pole of the cell with the cytoplasm .

The third , Acrosome phase : The main feature of this phase is the orientation of the head caps and acrosomic granules towards the boundary tissue of the tubules . Meanwhile , the cytoplasm of the spermatids is displaced to the opposite pole of their nuclei . Thus that third of the nucleus covered by the head cap and acrosomic granules appears bare of cytoplasm . The nucleus changes from spherical to ovoid , then a flattening , an elongation and curvature occurs and , as a result , the ovoid nucleus at the beginning of this phase becomes sickle-shaped by the end of it .

The fourth , Maturation phase : After the elongation of the nucleus, the cytoplasm slides backwards toward the posterior part of the intermediate piece of the spermatids ; cytoplasm then separates from the spermatid and forms the residual bodies when the cells are released in the form of late spermatids into the lumen of the tubules .

The residual bodies are nearly spherical with some membranal and mitochondrial residues and very numerous , free ribosomes gather into RNP spheres . They also contain lipids , glycogen , arginine and lysine . Phagocytosis of the residual bodies by the Sertoli cells has been observed by numerous authors .

#### Normal spermatid mitochondria :

In the young spermatid , the mitochondria were located peripherally, making a rim around the margin of the cell . Their cristae were extremely enlarged and some of them seemed to fuse ( Plate 35 , fig.77 ) . The central space of the cristae showed little electron-density and was still connected with interspace existing between the inner and outer mitochondrial

Plate 35

**Fig.77** An electron micrograph of a cap-phase spermatid from a normal ( control ) animal . The spermatid exhibits a rounded nucleus ( N ) , prominent Golgi apparatus ( G ) , characteristic acrosomal cap ( head cap ) ( A ) , and a rim of mitochondria around the margin of the cell ( m ) . Frequently a chromatoid body ( CB ) is visible.

X 8000

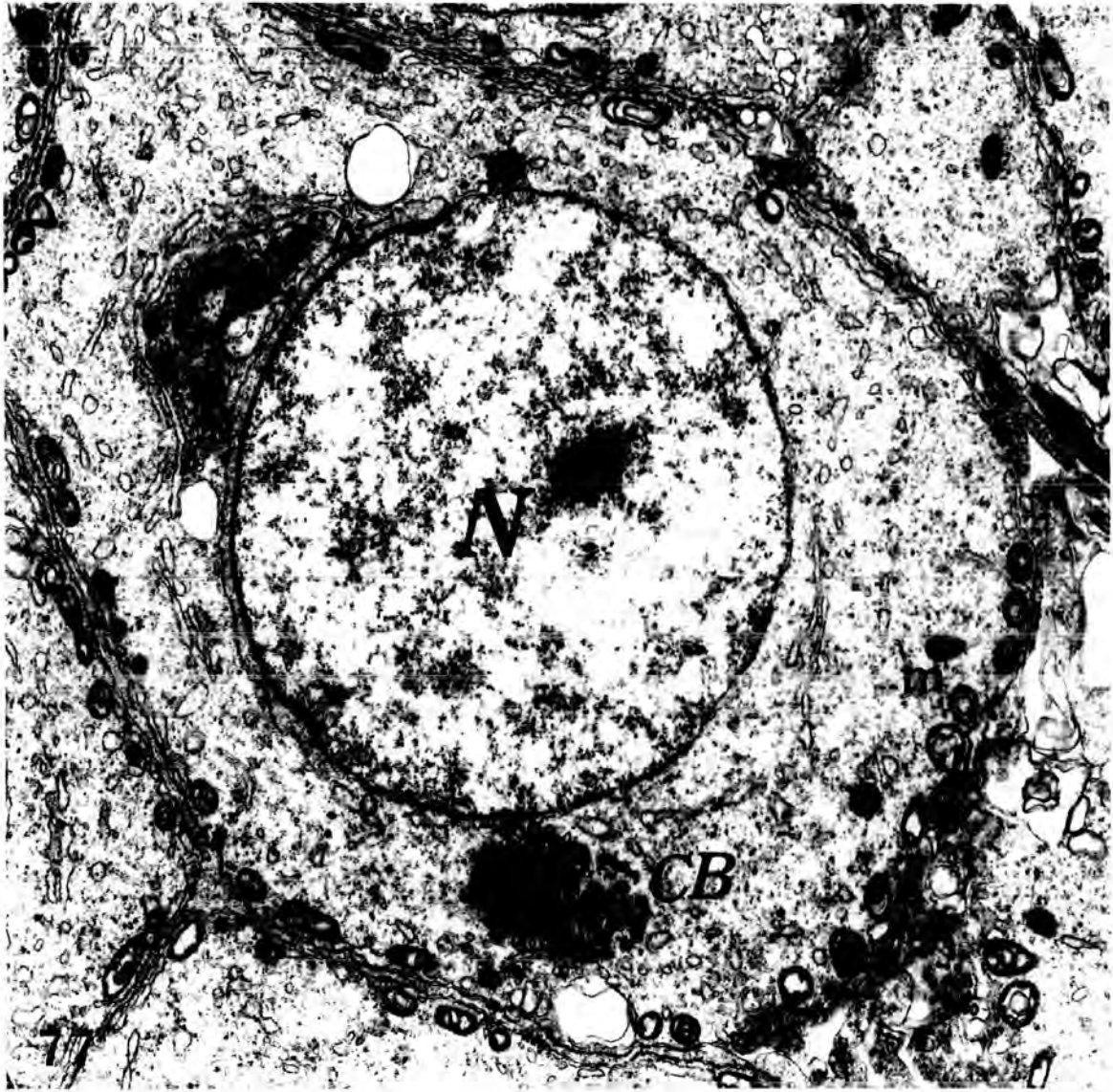



Plate 36

**Fig.78**      **Low power electron micrograph from a normal animal ,**  
**showing nuclear elongation and caudal displacement of the cytoplasm**  
**of late spermatids . Cytoplasmic tags ( t ) are formed in the late**  
**spermatids towards the end of the process of spermiogenesis .**

X 3200



membrane ( Plate 35 , fig.77 & plate 51 , fig.95 ) . This considerably increased central space giving the mitochondria the appearance of having a light "central channel" (Palade,1952a). The internal matrix of the mitochondria seemed to have decreased in volume and was found mostly at the periphery of the mitochondria as electron-dense lamellae , packed between the membranes of the enlarged cristae ( Plate 51 , fig.95 ) .

Later in spermiogenesis , when the mitochondria had formed a helical sheath around the tail filaments , the electron dense-lamellae of the internal matrix were mostly found at that side of mitochondria which faced the tail filaments . Shortly before sperm release , the swelling of the cristae seemed to have regressed , and , in cross-sections of mitochondria , the membranes of the cristae were arranged in the concentric fashion .

Spermatids , effect of Mepivacaine-HCl administration :

As shown by Kaya and Harrison ( 1976 ) , spermatids are particularly sensitive to noxious agents and are the first to show degeneration when such agents affect the seminiferous tubules .

As a result of administration of Mepivacaine-HCl to male rats , the spermatid population within the seminiferous tubules was affected . The actual damage differed at different stages of the cycle . Although degenerating step 7 spermatids were relatively rare in normal animals ( Russell & Clermont, 1977 ), necrotic young spermatids observed in stage VII of the cycle were easily identified in treated animals. The distorted nucleus displayed clumped chromatin, and parts of the acrosomic system and chromatoid body were usually visible within the cytoplasm . Sometimes , the nucleus was highly irregular ( Fig.92 ) and showed an accumulation of chromatin at its periphery (Plate 37,

fig.79 ) . The severity of the morphological changes of some spermatids ( e.g plate 48 , fig.92 & plate 49 , fig.93 ) suggested that many of the cells were irreversibly damaged and thus could be considered necrotic. Many of these cells were identified further as early spermatids , because they contained the characteristic acrosomal cap . The presence of some degenerating spermatids has been described in normal testes ( Oakberg , 1956 a ; Clermont and Bustos-Obregon , 1968 ) , but degenerating spermatids such as those seen in animals that received Mepivacaine-HCl were not observed in samples of normal control rats .

Some early spermatids displayed increased cytoplasmic density , numerous cytoplasmic vacuoles , and irregularly shaped nuclei , and these features may reflect early degenerative changes ( Plate 46 , fig.90 ) .

Degenerating late spermatids were occasionally seen in stages VII and VIII of the cycle of normal rats , but Mepivacaine-HCl administration increased markedly and significantly the number of these degenerating late spermatids . Few later spermatids of the acrosome and maturation phases remained in the seminiferous epithelium . Many of those present , however , appeared also to be undergoing degeneration and death as indicated by the presence of dense cytoplasm and alterations in the architecture of the acrosome , tail fibres , and other organelles . The heads of most late spermatids were broken , twisted , coagulated , fused and detached from the middle piece ; middle pieces were sloughed into the lumens without head. Some heads of late spermatids were embedded in Sertoli cytoplasm after sloughing of their middle pieces into the lumen ( Chapter 3 , plate 9 , fig.27 ) .

Exfoliation of cells of all types ( especially spermatids ) and the development of multinucleate cells were seen . Nuclear changes in the

exfoliated cells varied ; some appearing unaffected , other showing clumping of chromatin , vacuolation of the nucleus and pyknosis ( Plate 44 , fig.86 ).

Some early spermatids showed central vesicularity , with an increased concentration of chromatin on the nuclear membrane ( Plate 45 , figs. 87 , 88 & 89 ) .

The development of multinucleate cells has often been reported in testes exposed to damage . In this work , these were found mainly with severe, and sometimes with partial spermatogenic damage , but not with slight damage . The majority of these multinucleate cells was composed of early spermatids , whose nuclei lay centrally or peripherally in the sharply demarkated mass of cytoplasm . The multinucleate cells could be formed from fusion of 2 early normal spermatids ( Plate 41 , fig.83 ) or of 2 early spermatids showing early degenerative changes ( Plate 42 , fig.84 ) or of 5 nuclei ( Plate 43 , fig.85 ) , or sometimes up to 13 nuclei inside one cytoplasmic mass .

In necrotic spermatids , which contained disrupted cytoplasmic organelles and myelin figures , vacuolation and large lipid droplets were evident ( plate 50 , fig.94 ) .

Plate 37

Fig.79 An electron micrograph of a degenerating cell in the seminiferous tubule of an animal injected with 0.1 cm<sup>3</sup> of Mepivacaine-HCl, 4%, and killed after 6 hours. The cell is abnormally dense and its organelles are disrupted. However, the round nucleus (N) and the acrosomal cap (A) can be identified, which suggest that the cell is a late cap-phase spermatid. The degenerating cell is surrounded by Sertoli cell cytoplasm (Sc) and both cells are vacuolated (V).

X 8000

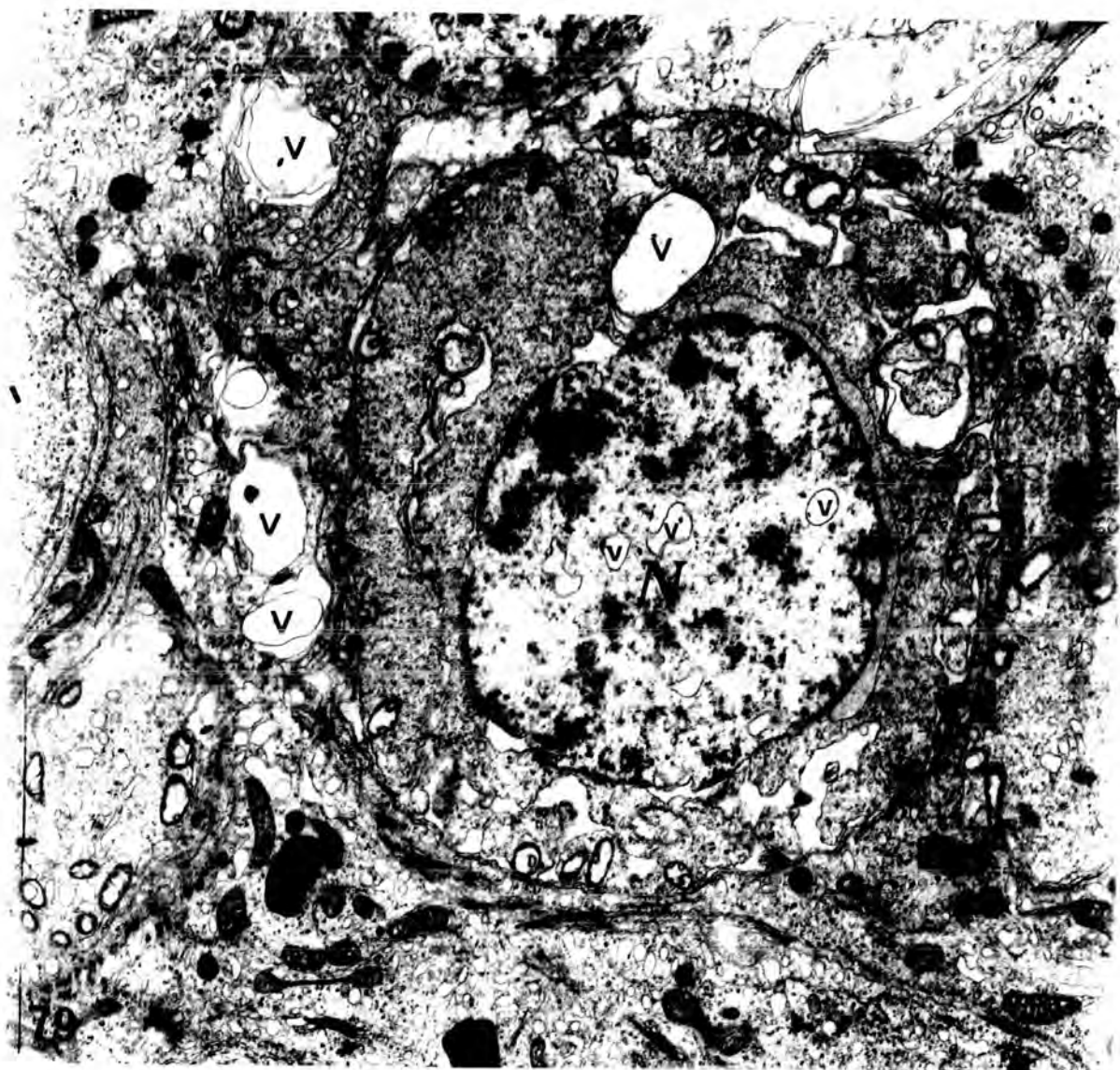


Plate 38

Fig.80 High power electron micrograph of an early spermatid ( spd ) from a normal ( control ) animal . The characteristic acrosomal granule ( AG ) is seen within a large vesicle ( V ) , which is in contact with the Golgi apparatus ( G ) . The Golgi apparatus mainly consists of groups of parallel lamellae and some vesicles .

X 12600

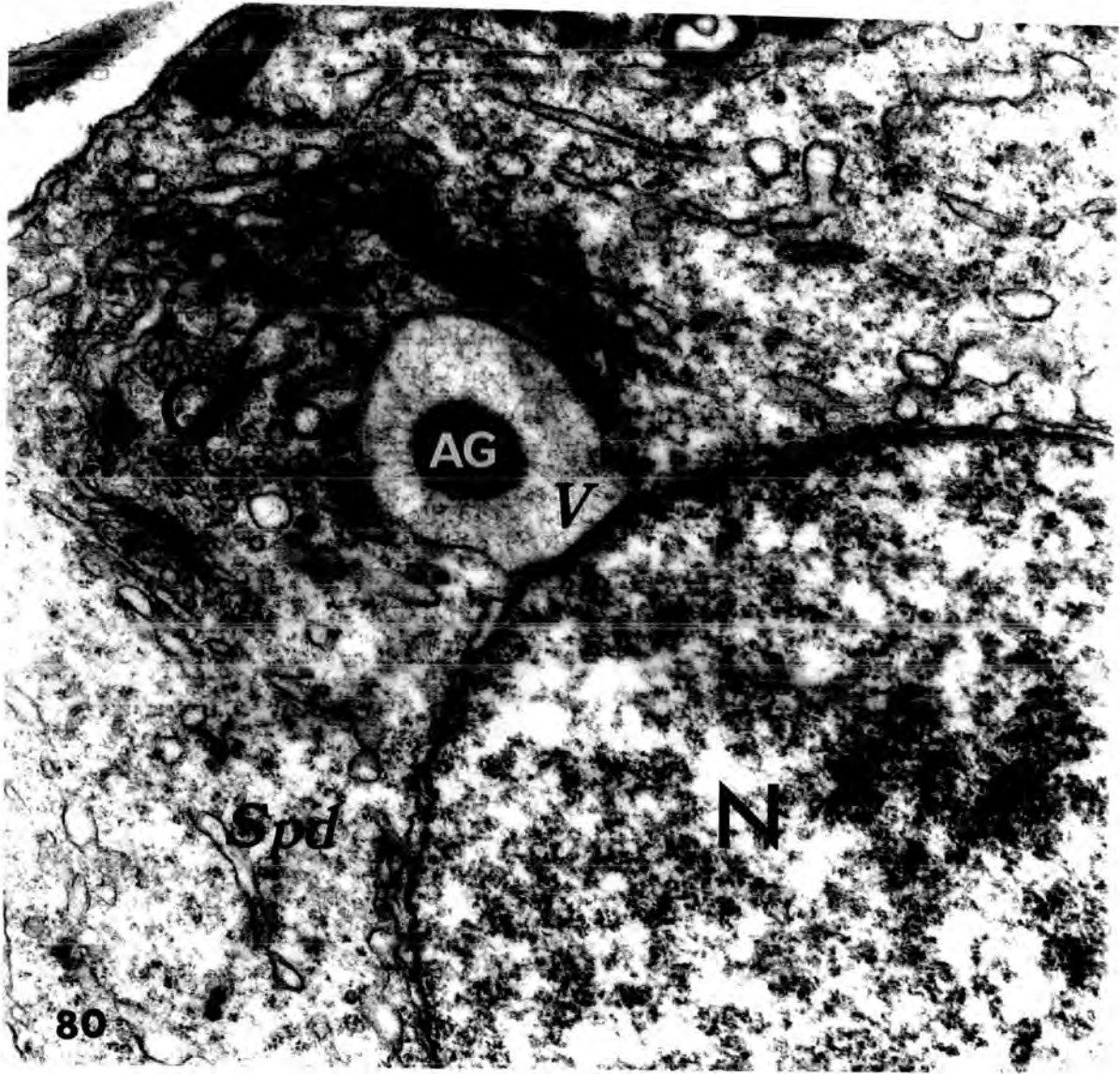


Plate 39

Fig.81 An electron micrograph of early spermatids from an animal injected with  $0.1 \text{ cm}^3$  of Mepivacaine-HCl , 4% , and killed after 12 hours . The cells are exfoliated into the lumen ( Lu ) of the tubule , and although they contain the characteristic acrosomal granules ( AG ) , certain organelles are abnormal , namely , the Golgi apparatus ( G ) , in which the lamellae are fused and dark in appearance ; and the endoplasmic reticulum which has become vesicular .

X 8000

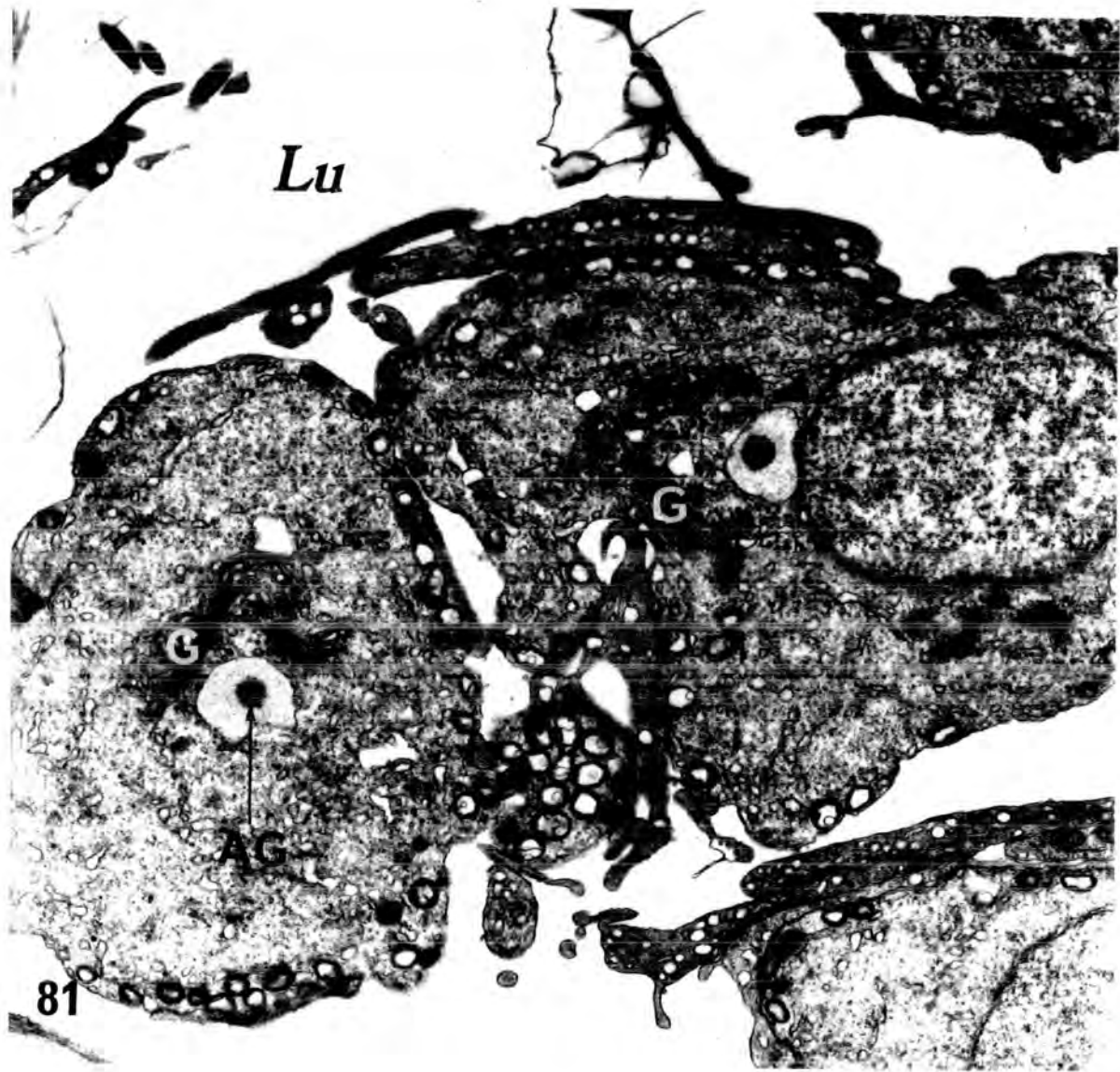

Plate 40

Fig.82 An electron micrograph of a spermatid from an animal injected with 0.5 cm<sup>3</sup> of Mepivacaine-HCl , 4% , and killed after 12 hours . The characteristic acrosomal system around the nucleus ( N ) and peripherally oriented mitochondria ( m ) in contact with the cell membrane are visible. Note that this spermatid is in contact with the boundary tissue ( bt ) of the seminiferous tubule and not in its normal position near the lumen . The surrounding Sertoli cell cytoplasm is highly vacuolated and the mitochondria are uncharacteristically rounded , devoid of cristae , and contain a matrix of low density . ( Compare with normal Sertoli cell mitochondria , illustrated in figs. 97 & 98 , which are slender in shape with the normal tubular cristae and a relatively dense matrix ) .

L : lipid droplet .

X 8000

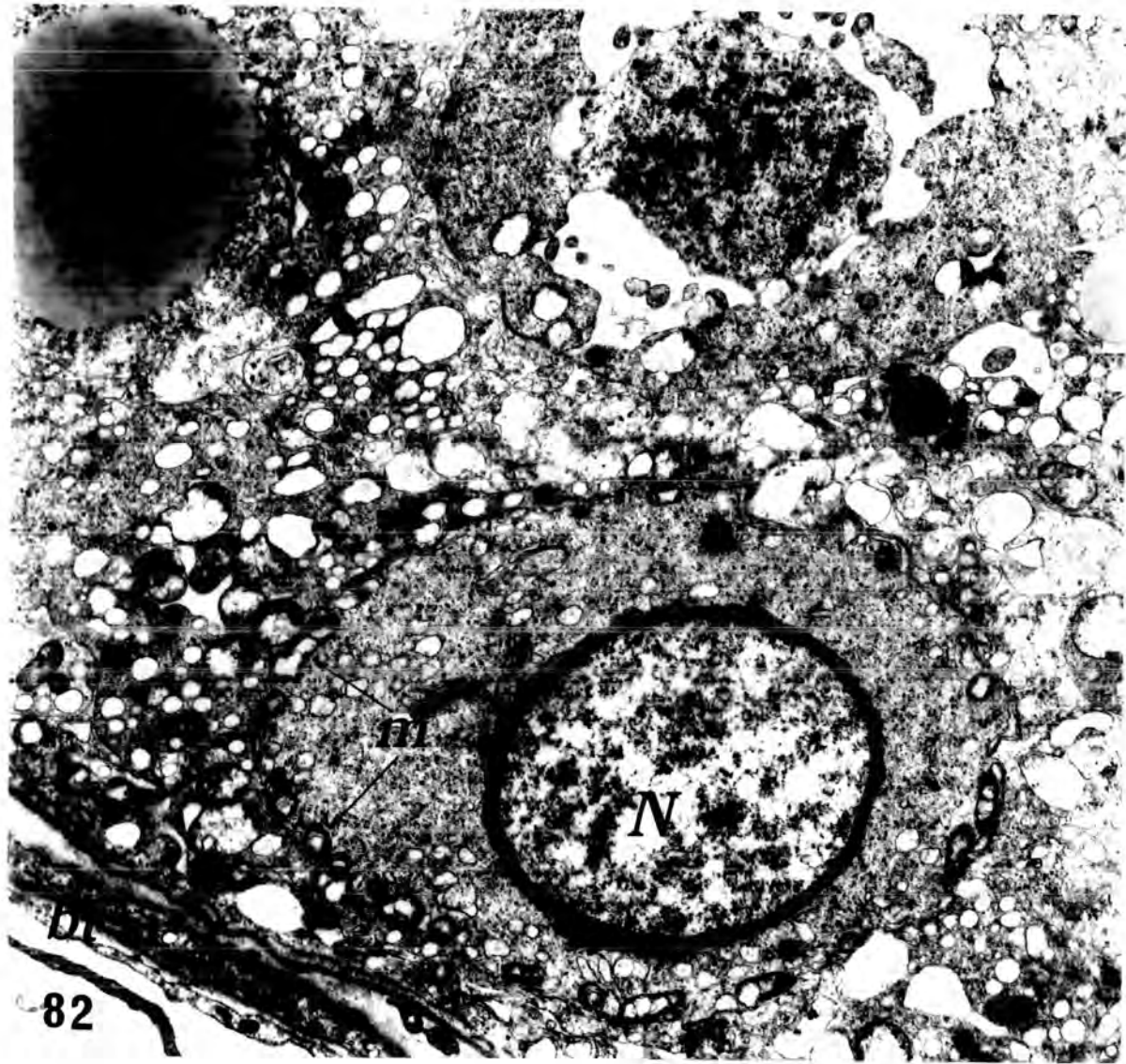

Plate 41

Fig.85 An electron micrograph from an animal injected with 0.5 cm<sup>3</sup> of Mepivacaine-HCl , 4% , and killed after 6 hours , showing an exfoliated binucleate cell formed by the fusion of two spermatids.

N , nucleus ; G , Golgi apparatus ; m , mitochondria .

X 8000

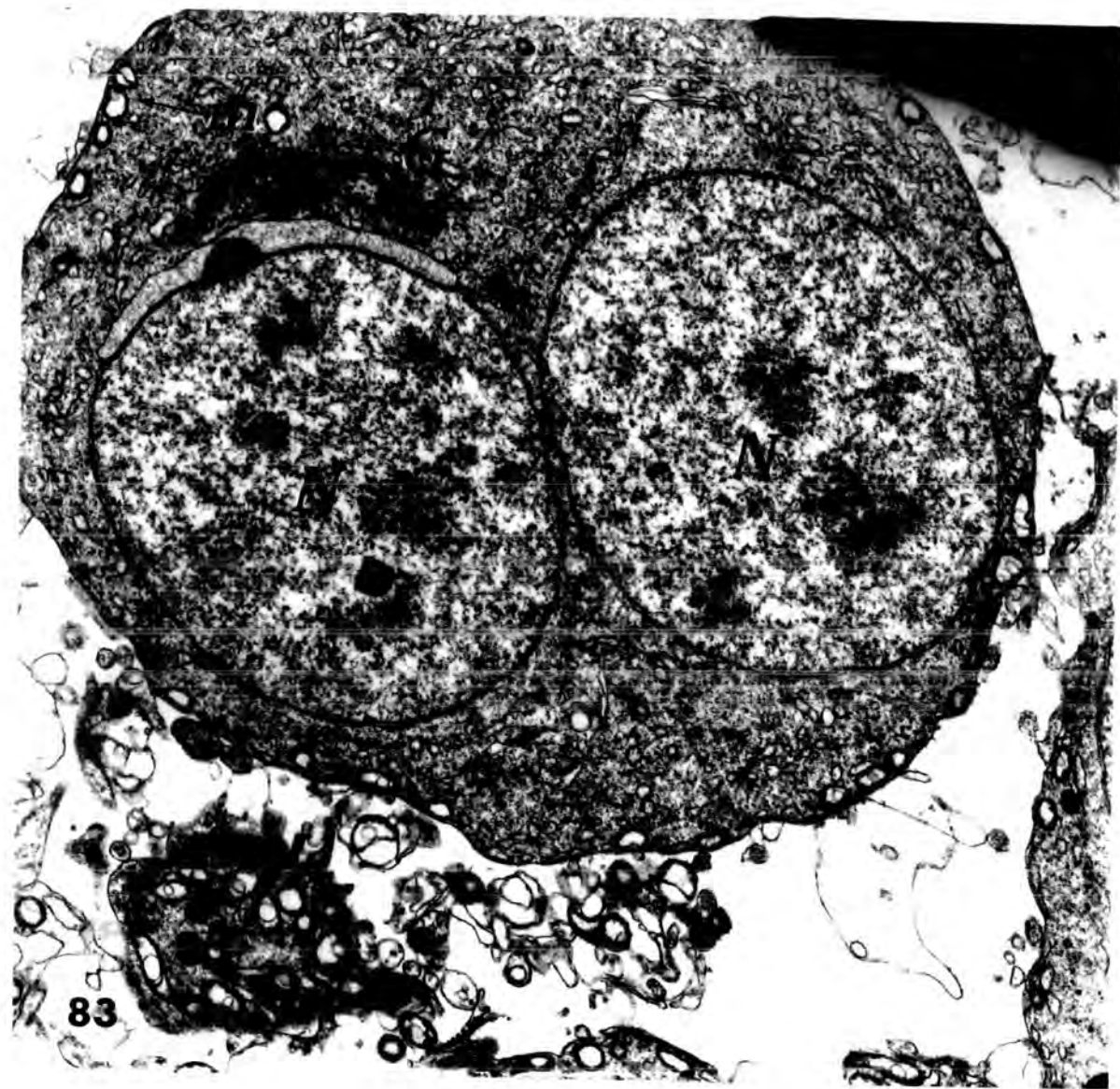

Plate 42

Fig.84 An electron micrograph from an animal injected with 0.5 cm<sup>3</sup> of Mepivacaine-HCl , 4% , and killed after 6 hours , illustrating a binucleate cell formed from the fusion of two early spermatids . One of the polar ends of each nucleus is uncharacteristically misshapen ( Compare with the smooth rounded nuclei in the previous micrograph ( Fig.83 ) ) , and the endoplasmic reticulum is vacuolated ( V ) .

m , mitochondria . ; N , nucleus .

x 8000

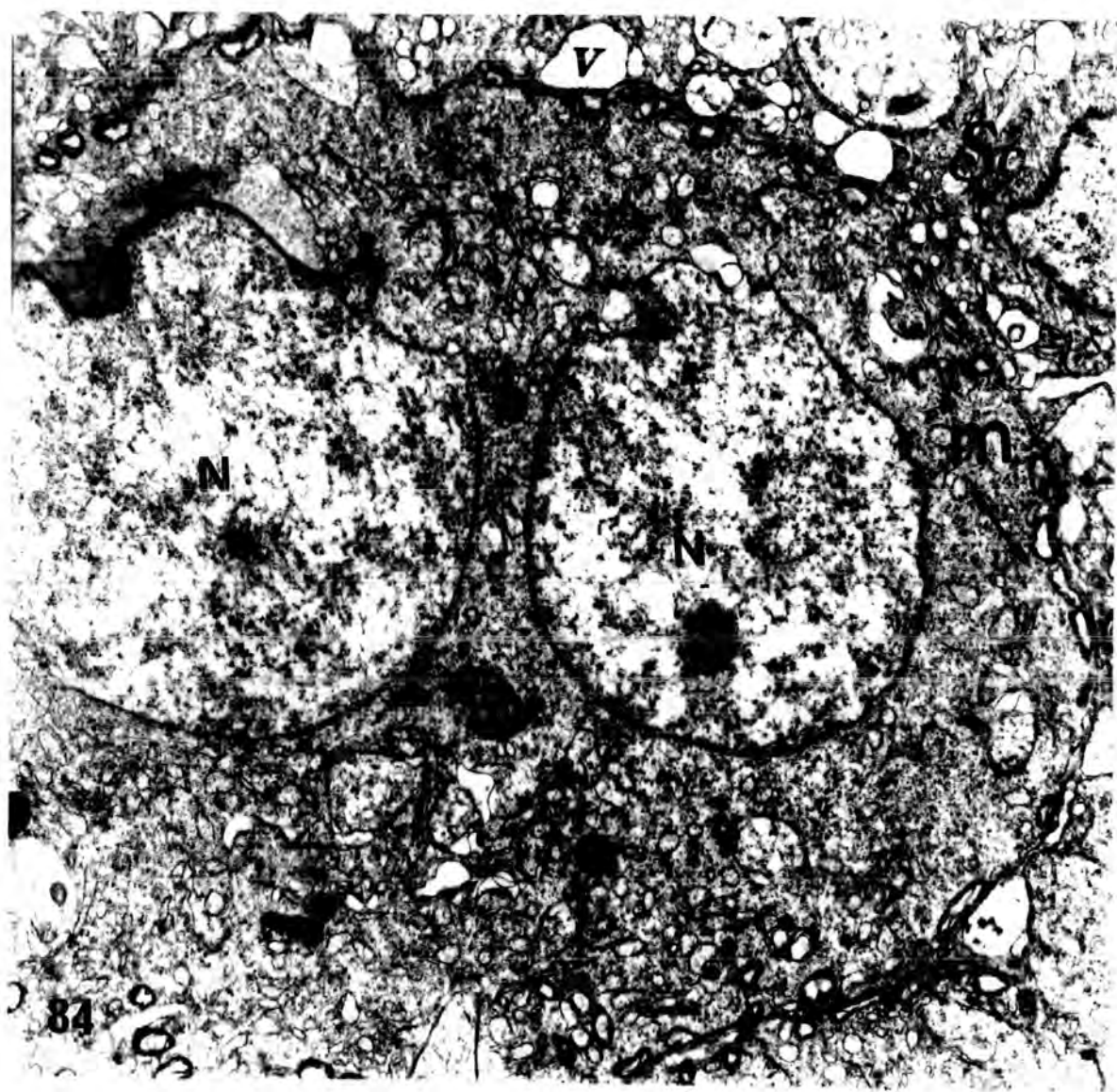


Plate 43

Fig.85 An electron micrograph of a multinucleate cell which contains 5 nuclei ( N ) ( from an animal injected with 0.1 cm<sup>3</sup> of Mepivacaine\_HCl, 4% , and killed after 12 hours ) . The presence of an acrosomic granule ( AG ) indicates that this cell was formed by the fusion of early spermatids.

X 8000

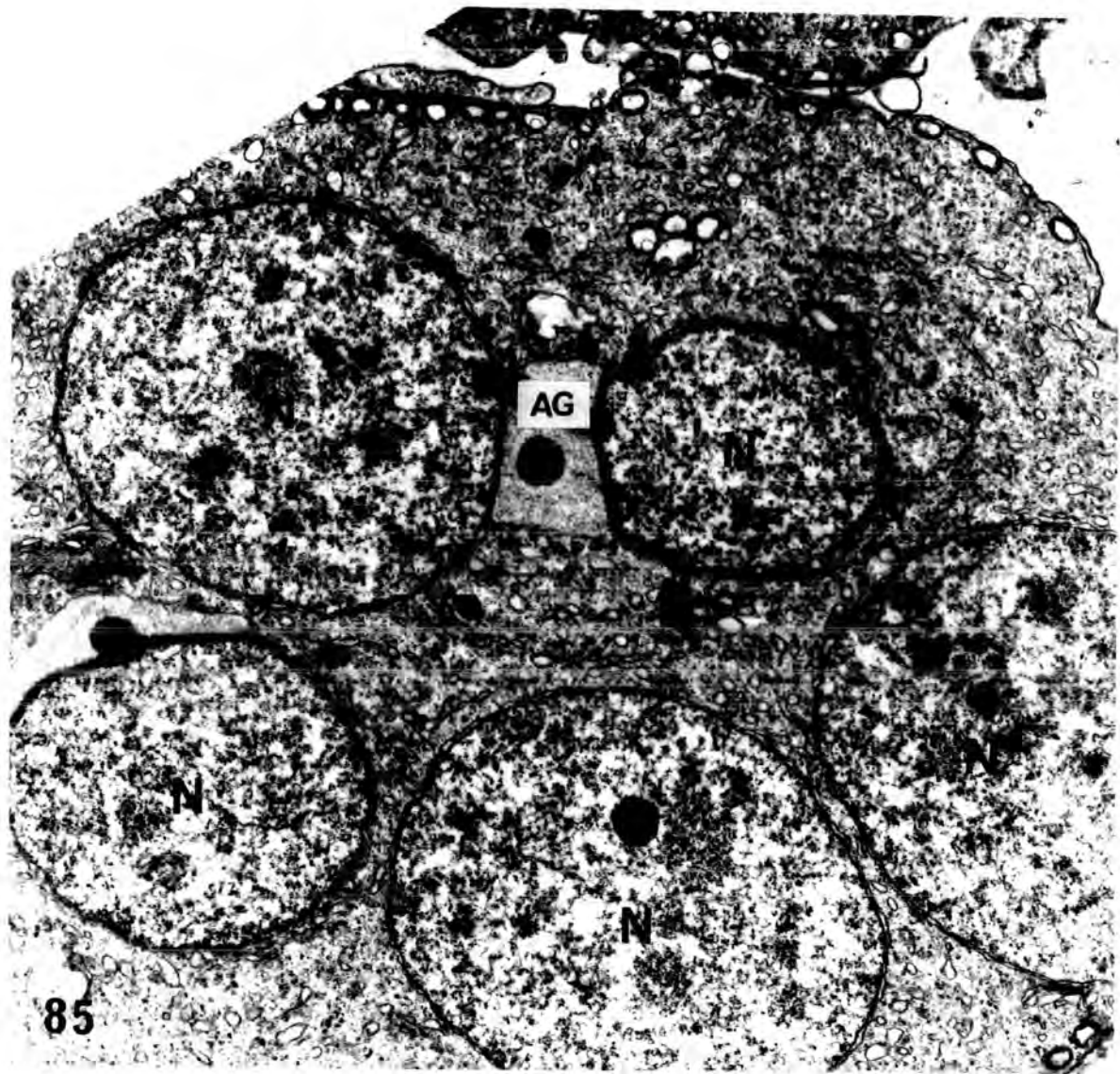


Plate 44

Fig.86 Low power electron micrograph from an animal injected with 0.25 cm<sup>3</sup> of Mepivacaine-HCl , 4% , and killed after 12 hours , illustrating the variety of changes that can occur in the nuclei of exfoliated cells . Although the spermatocytes are unaffected (1) , the spermatids show clumping of peripheral chromatin (2) and vacuolation (3) .

X 5000

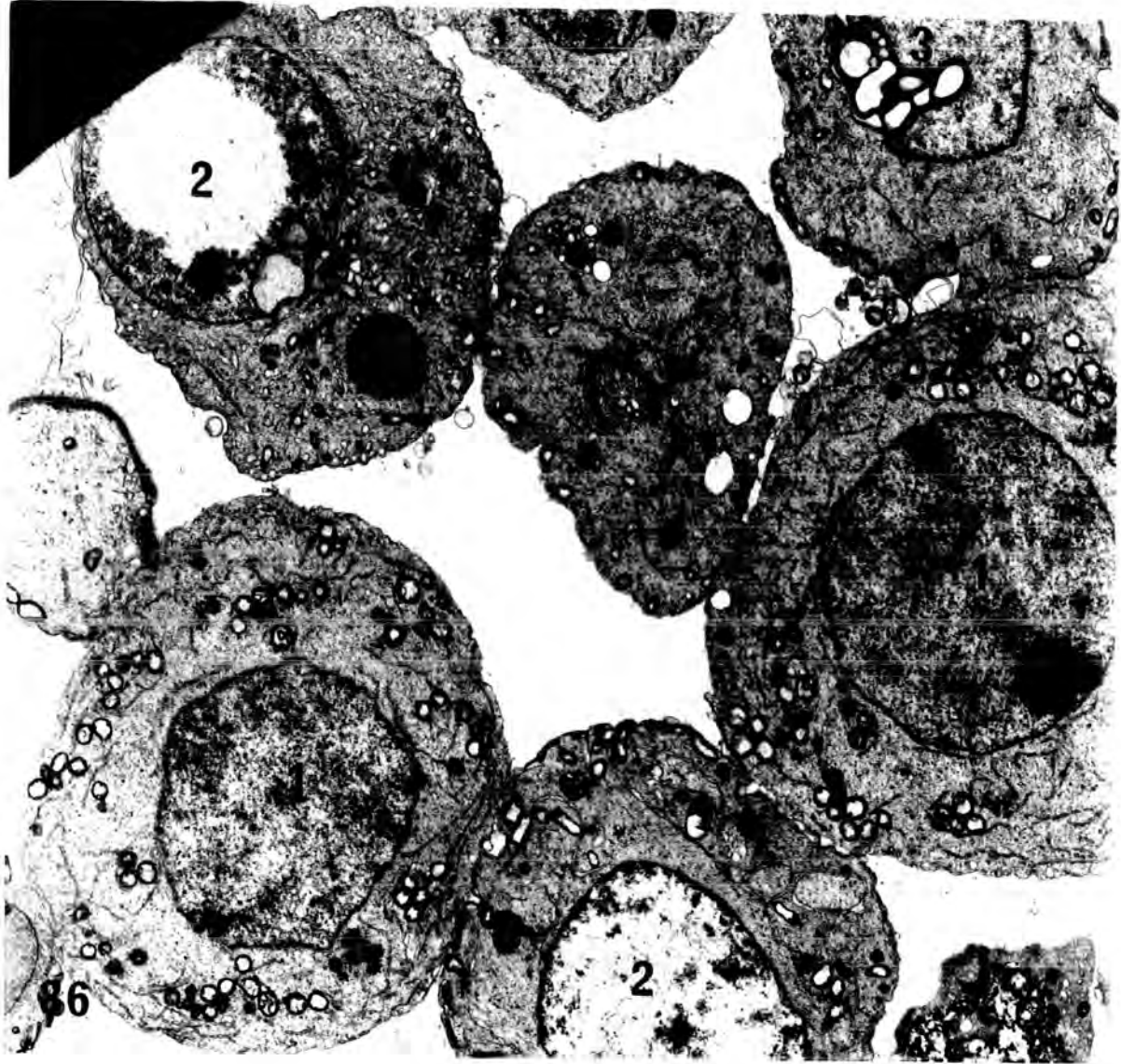


Plate 45

Figs. 87 & 88 High power light micrograph of transverse sections of testes from 2 animals injected with 0.1 cm<sup>3</sup> of Mepivacaine-HCl , 4% , and killed after 6 hours . These figures illustrate the annular dense appearance of the chromatin in nuclei of single and multinucleate spermatids ( spd ) . Note that apart from these spermatids ; the tubules contain only a peripheral lining of Sertoli cells ( S ) and a few B-type spermatogonia ( B-spg. ) .

X 250

Fig.89 An electron micrograph from an animal injected with 0.5 cm<sup>3</sup> of Mepivacaine-HCl , 4% , and killed after 12 hours , illustrating parts of two early spermatids in which the condensed chromatin ( Ch ) is aggregated near the nuclear envelope in an annular manner . Note the relatively electron-dense appearance of the cytoplasm .

AG , Acrosomal granule ; HC , Head cap ; M , Mitochondria ; N , Nucleus .

X 8000

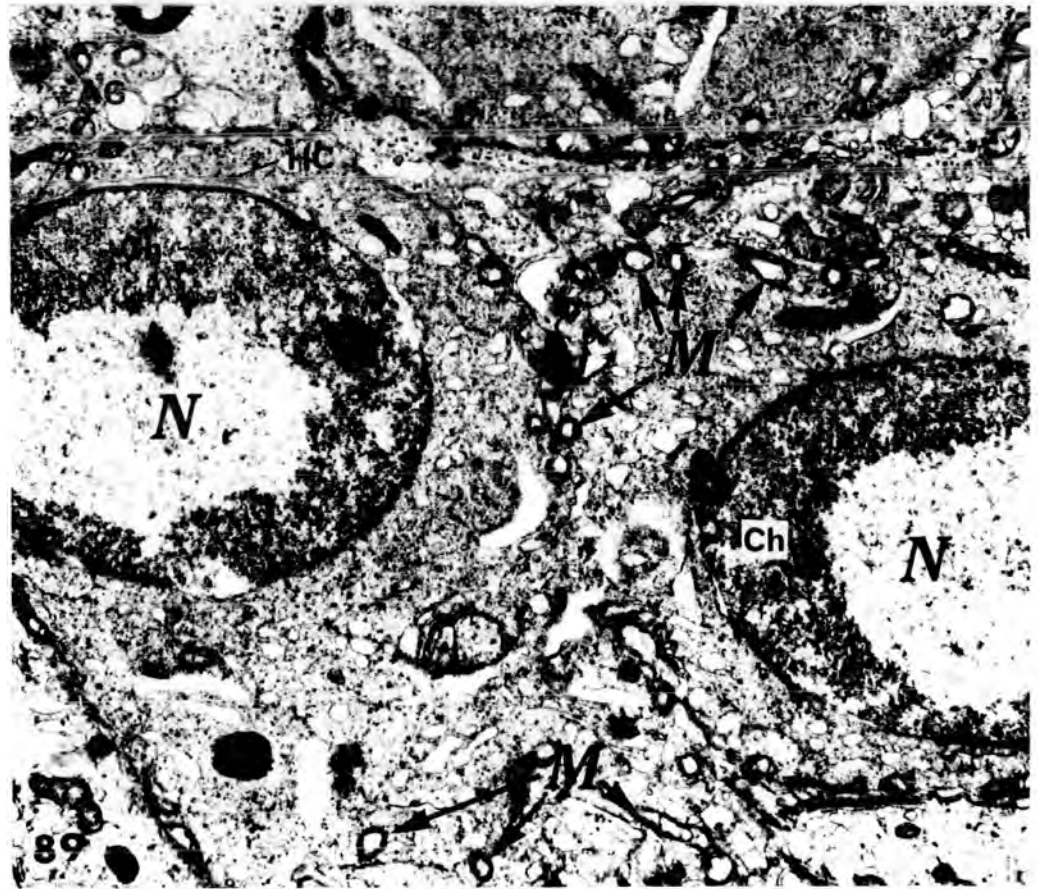
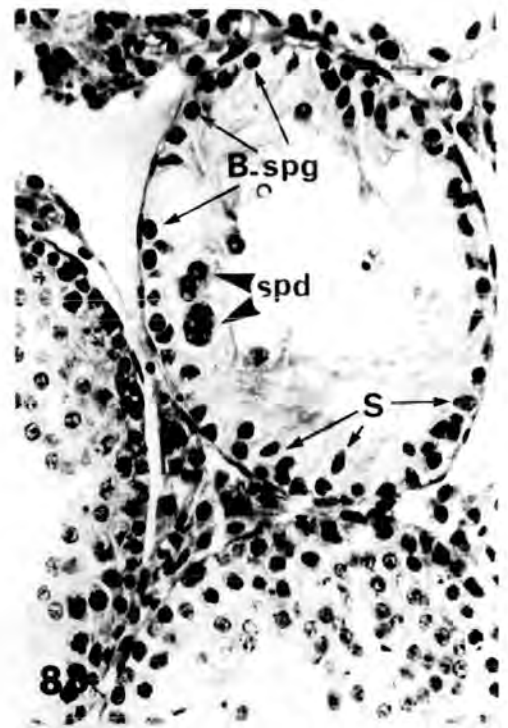
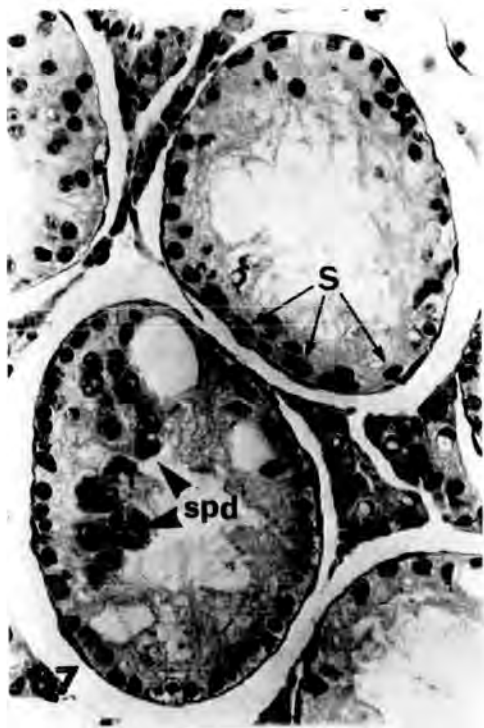

Plate 46

Fig.90 An electron microscope of degenerating step 7 spermatid from an animal injected with 0.5 cm<sup>3</sup> of Mepivacaine-HCl , 4% , and killed after 12 hours . The condensed chromatin is aggregated close to the nuclear envelope . The peripherally distributed mitochondria ( m ) and the cisternae of the endoplasmic reticulum stand out clearly against the electron-dense cytoplasm .

N : nucleus .

X 8000

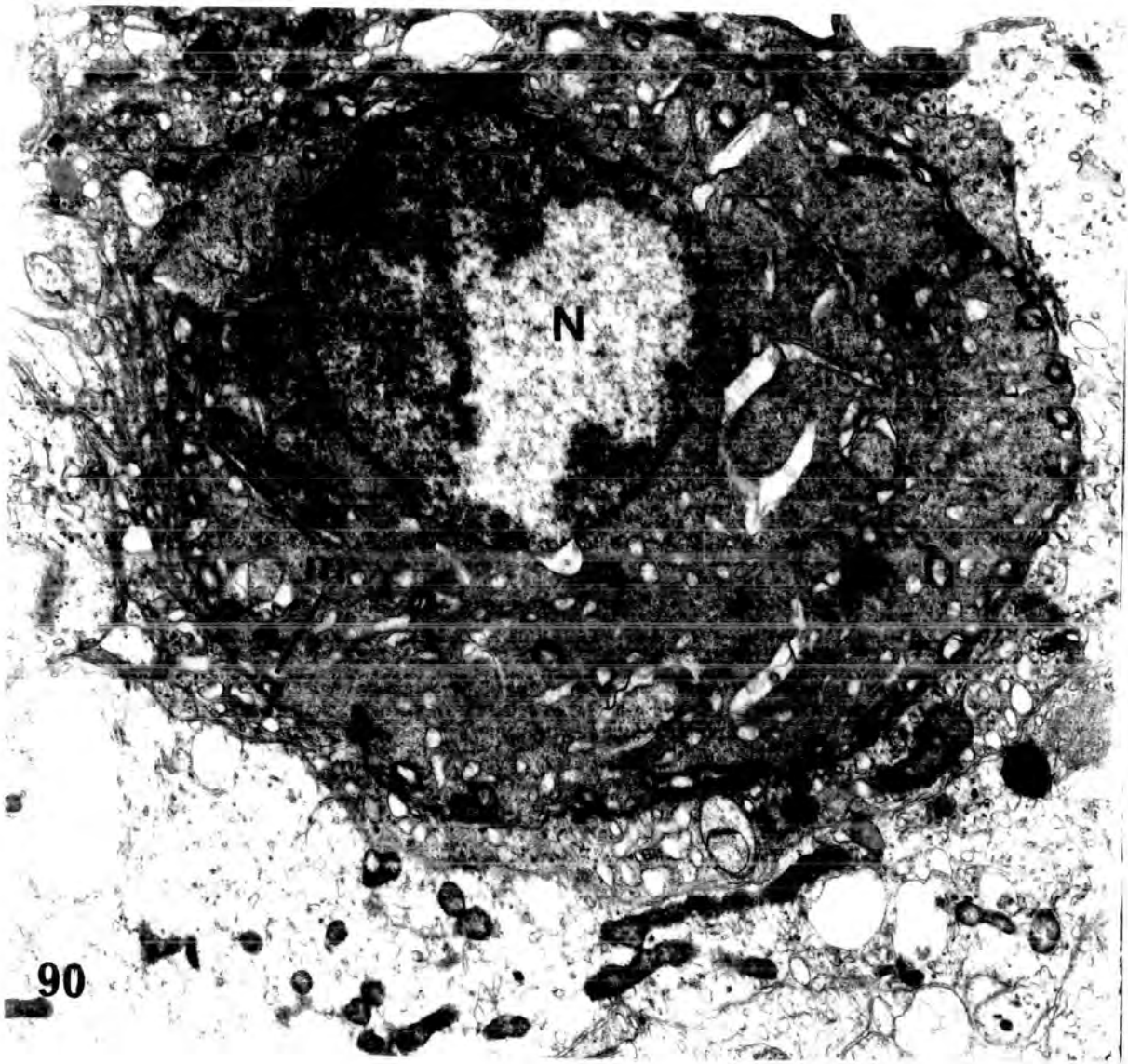


Plate 47

Fig.91 Low power electron micrograph of a seminiferous tubule from an animal injected with 0.25 cm<sup>3</sup> of Mepivacaine-HCl , 4% , and killed after 48 hours , showing the fusion between two early spermatids in the head-cap region ( arrow heads ) . The chromatoid bodies ( CB ) of the two cells also appear fused into a single structure . This binucleate fused cell is surrounded by a thin layer of electron dense Sertoli cell cytoplasm .

X 5000

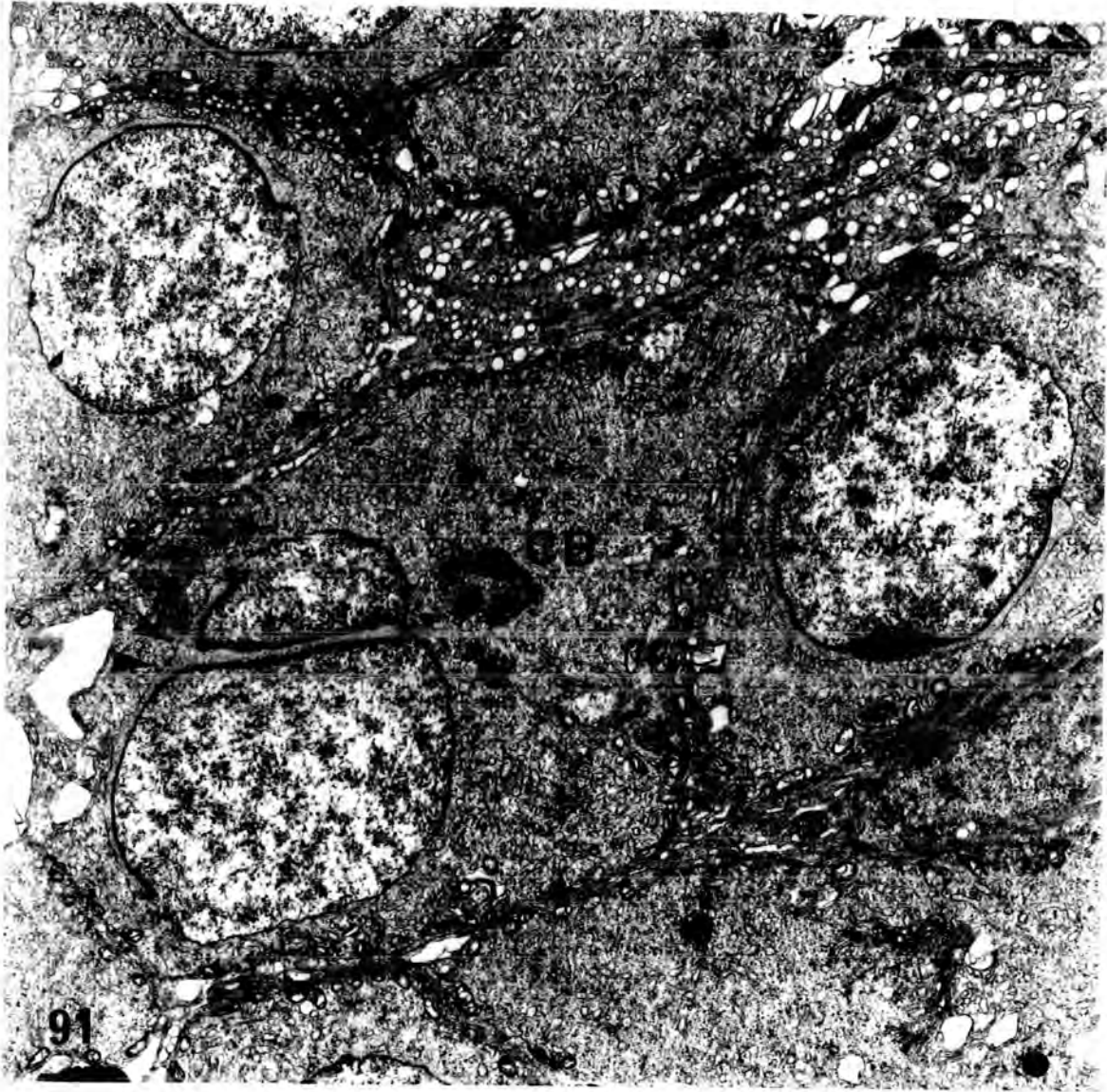


Plate 48

Fig.92      An electron micrograph of a degenerating step 7 spermatid from an animal injected with 0.25 cm<sup>3</sup> of Mepivacaine-HCl , 4% ,and killed after 24 hours . The distorted acrosomic system ( Acrosomal granule , A and head cap , HC ) is inverted into the nucleus ( N ) , instead of lying in its normal position on the surface . The cytoplasm is completely disintegrated .

X 10 000

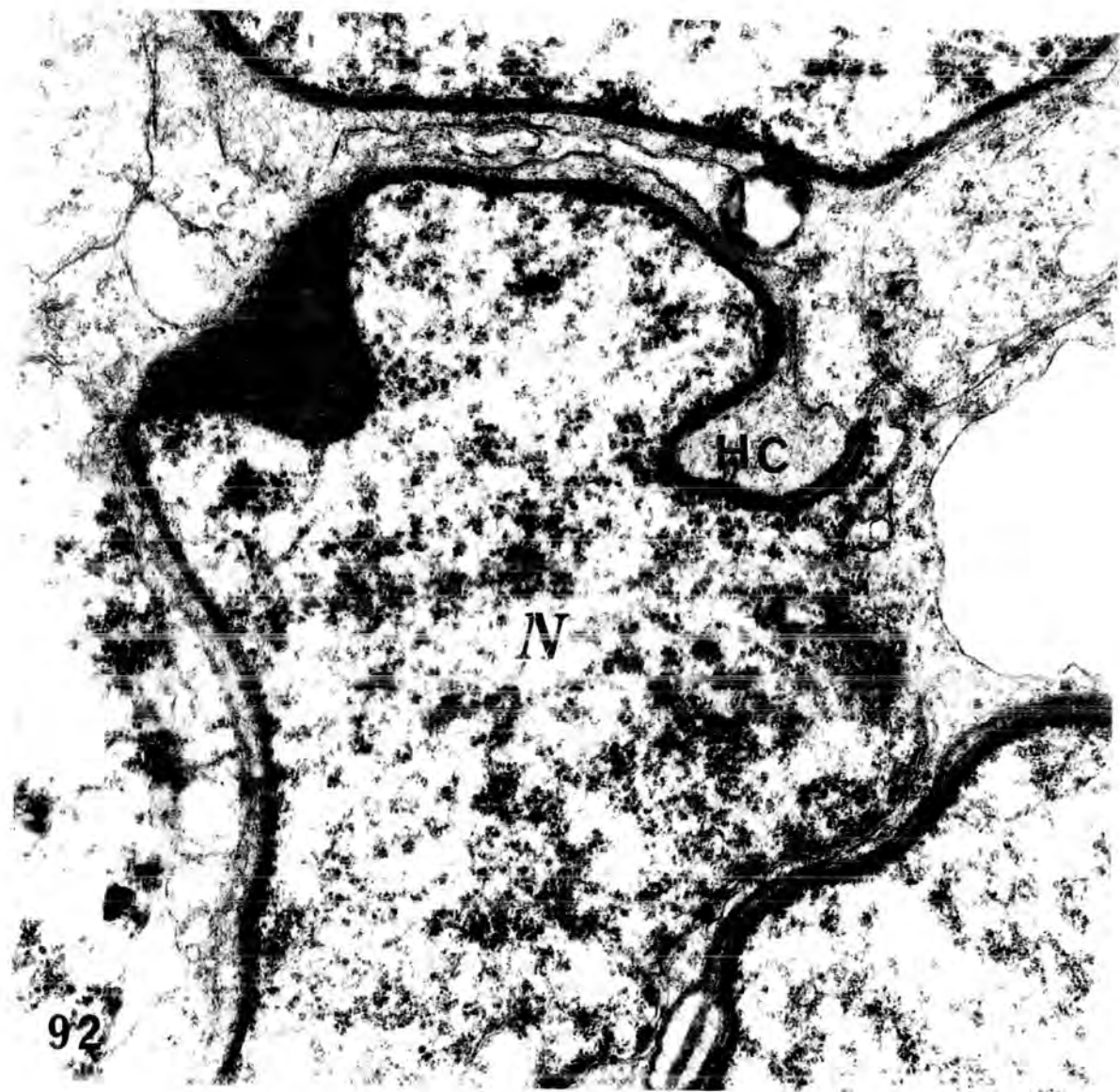


Plate 49

Fig.93 An electron micrograph of a young spermatid from an animal injected with 0.5 cm<sup>3</sup> of Mepivacaine-HCl, 4% , and killed after 6 hours. The nuclear membrane ( Nm) is very irregular and the nucleus contains non-homogeneous chromatin . Note the Golgi apparatus ( G ) , still strongly attached to the head cap ( HC ) . The cytoplasm of the cell appears almost totally degenerated .

N : nucleus .

X 8000

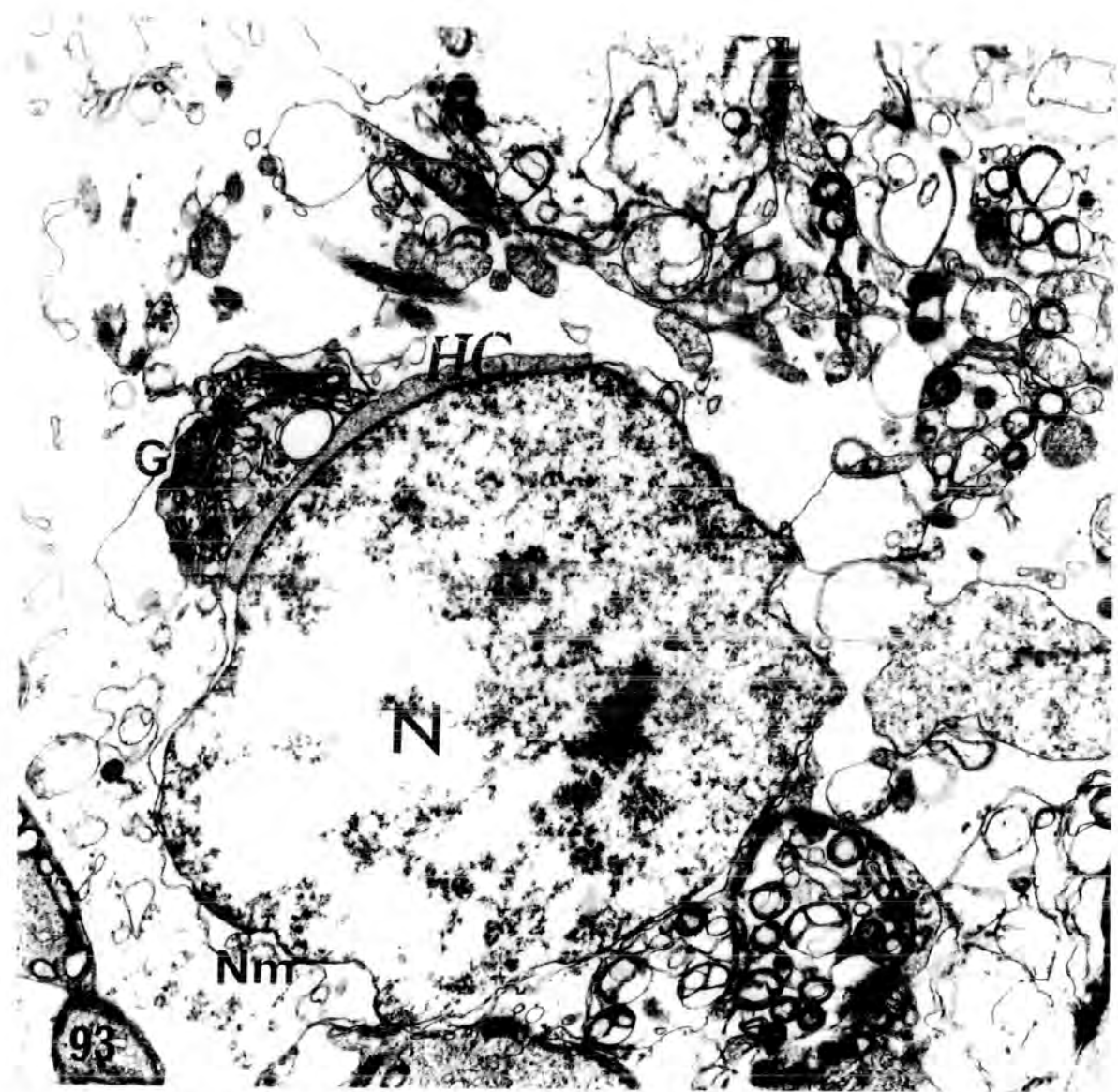


Plate 50

Fig.94      An electron micrograph of a degenerating spermatid from an animal injected with 0.25 cm<sup>3</sup> of Mepivacaine.HCl , 4% , and killed after 24 hours . The nucleus becomes more or less elongated with clumped chromatin . A large lipid droplet ( L ) lies within highly vacuolated Sertoli cell cytoplasm ( Sc ) , and is close contact with the spermatid .

X 5000

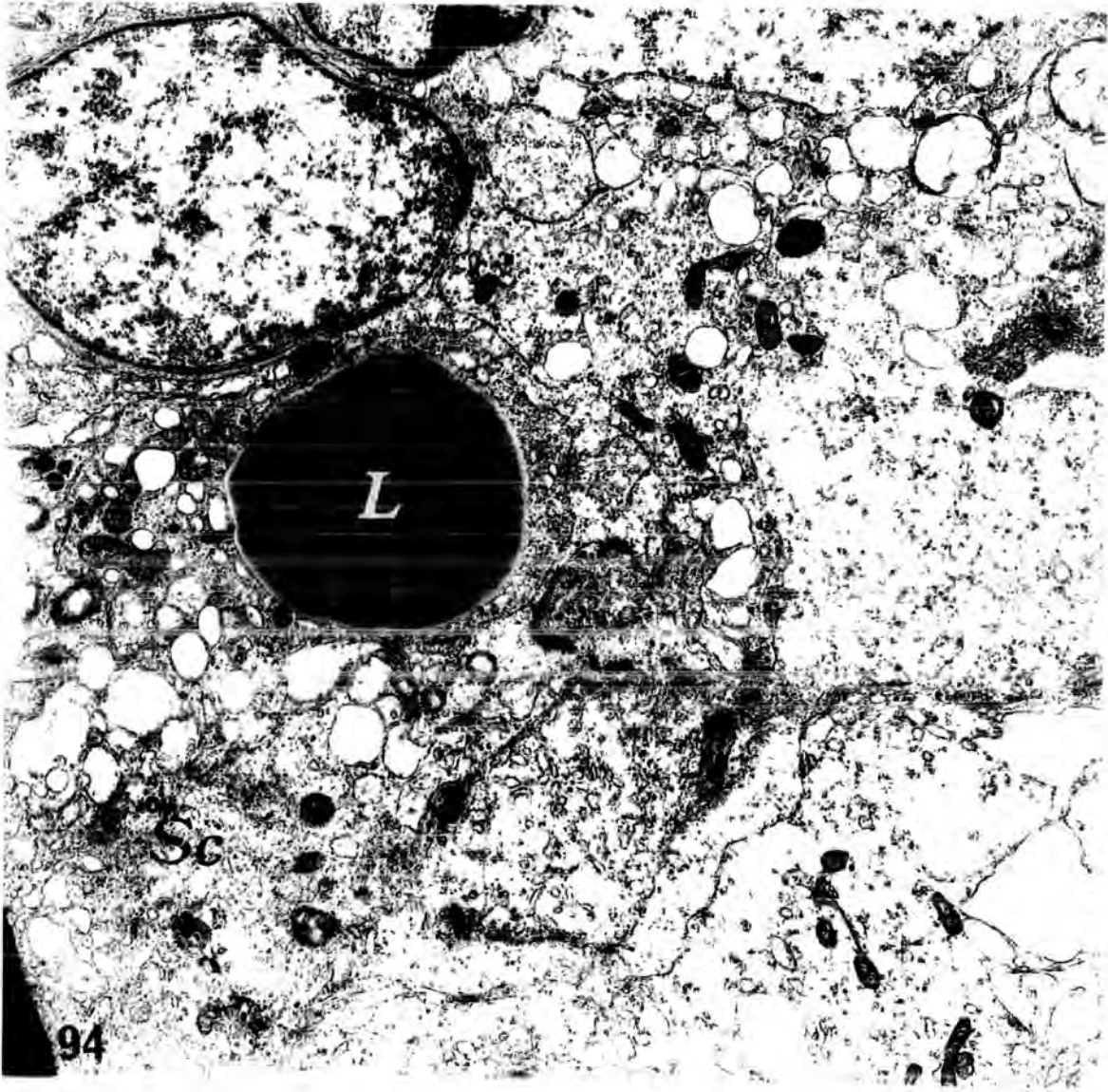


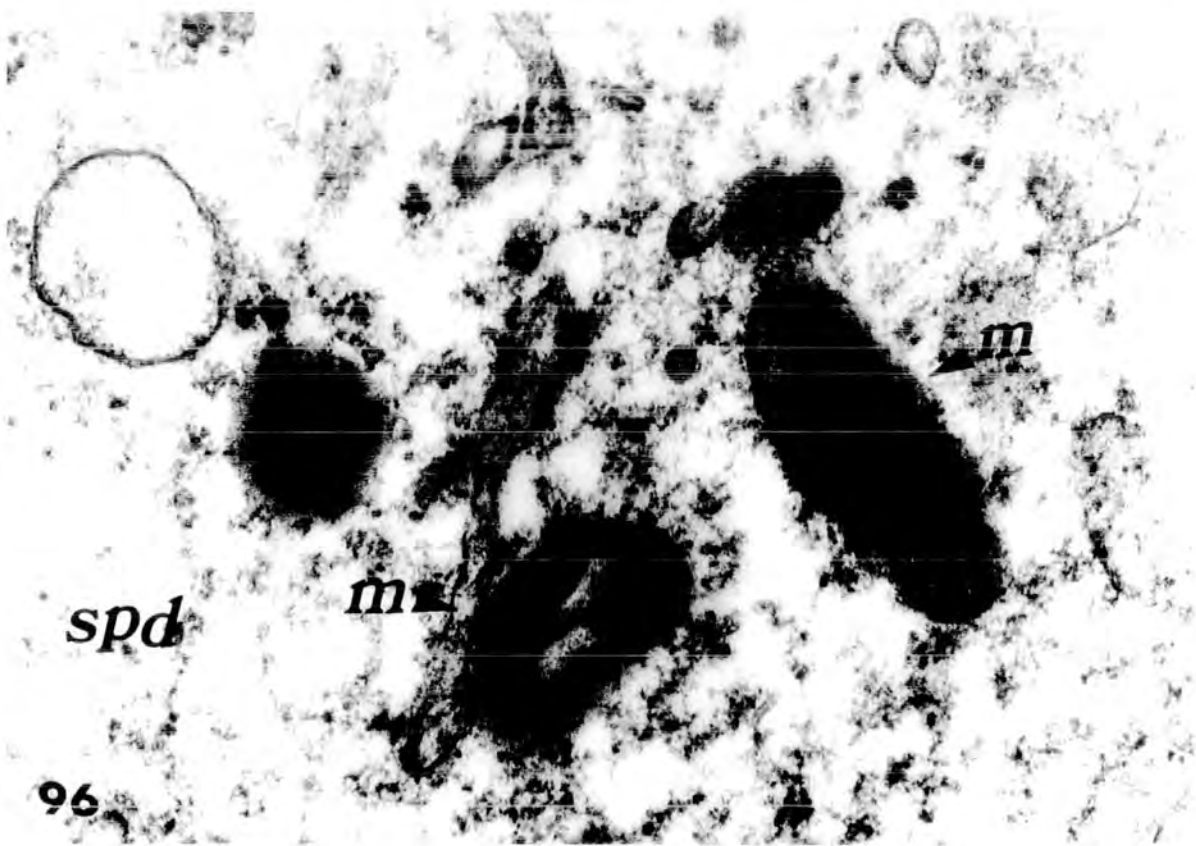
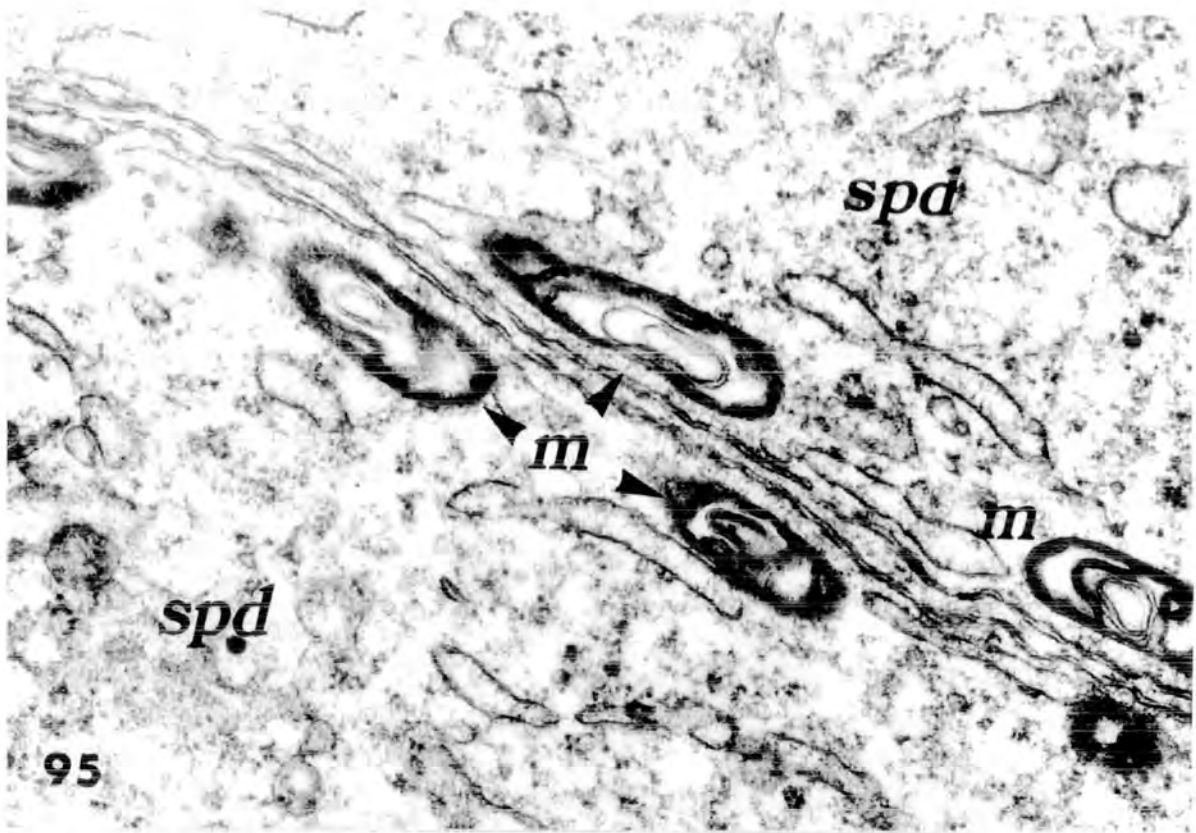
Plate 51

**Fig.95** An electron micrograph of mitochondria ( m ) from normal(control) early spermatids ( spd ) , which lie close to the cell membranes . The internal structure of these mitochondria appears less orderly than in other types of cells in the seminiferous tubules . The cristae are irregular in outline and lie parallel , instead of perpendicular , to the mitochondria surface . Thus , the centre of the organelle is often free of cristae and occupied by a matrix of relatively low density .

X 40000

**Fig.96** An electron micrograph of mitochondria ( m ) of an early spermatid ( spd ) from an animal injected with 0.5 cm<sup>3</sup> of Mepivacaine.HCl , 4% , and killed after 48 hours . The organelles are not oriented parallel with the cell membrane , but are randomly scattered in the cytoplasm . They are extremely electron dense with no visible cristae .

X 50.000



## 5- THE SERTOLI CELLS

The Sertoli cells rest upon the limiting membrane of the seminiferous tubules and occupy most of its surface . The basal portions of the Sertoli cells are recognised in sections tangential to the tubular surface by their polygonal shape .

The highly elaborate shape of the Sertoli cell is caused by its close association with the germinal cells . The outlines of the germinal cells change during differentiation ; they occupy deep recesses of conforming shape on the surface of the Sertoli cells . In the place of contact between Sertoli cells , the outline of these is smooth and frequently straight , or with some interdigitations .

In the testis of the adult rat the Sertoli cells present a particularly polymorphous appearance in both their nucleus and cytoplasm , since they undergo changes in shape and activity in relation to the seminiferous epithelium cycle .

### Morphology and structure :

(i) Cell boundaries and shape : Since it is difficult to see their boundaries in the light microscope , the Sertoli cells gave rise to a long controversy of whether they formed a syncytium or remained a group of distinct cells . Agreement was finally established through electron microscope observations which proved that the Sertoli cells were separate .

In the course of the cycle , the size of the Sertoli cells varied , being smaller after the release of the spermatozoa .

(ii) Nucleus : The nucleus of the Sertoli cells was of a very irregular shape and exhibited deep indentations . The chromatin was generally distributed in fairly fine granulations , weakly taking up the Feulgen stain . There was normally one nucleolus which appeared to consist of a sphere of interlacing electron dense-masses ( Plate 53 , fig.98 ) . The general shape and position of the nucleus varied in relation to the stage of the seminiferous epithelium cycle . From the release of the spermatozoa until the formation of the following spermatid bundles , the nucleus was rather triangular , lying along the boundary tissue ( see plate 17 , fig.49 c ) . .

(iii) Cytoplasm : The endoplasmic reticulum was abundant with a vesicular rather than lamellar appearance . There was a well-developed Golgi apparatus; ovoid , spherical or slender shaped mitochondria ( with their characteristic tubular cristae ) ; numerous ribosomes and microtubules .

The Sertoli cells had a considerable phagocytic activity ( plate 54 , fig.99 ) ; they were reported to phagocytose residual bodies in the normal rat testis ( Smith and Lacy , 1959 ) . This feature was supported by the finding of Clegg and Macmillan ( 1965 ) , that Sertoli cells take up and store vital dyes after interruption of the ductuli efferents . Also , Clegg and Macmillan ( 1965 ) , found that the Sertoli cells appeared to phagocytose Indian ink particles .

Vilar et al. ( 1962 ) suggested that these cells act as " bridge cells " to assist in the transfer of important nutrient material from the basal membrane to the developing germinal cells . Microtubules , possibly associated with such transfer activity , have been described in Sertoli cells ( Christensen , 1965 ) .

Nishida ( 1954 ) , using the light microscope , reported that mitochondria in the Sertoli cells were either short rods or spherioles in form . They were arranged generally in rows running parallel to the proximo-distal axis of the cell . The mitochondria were evenly distributed in the cytoplasm and so also in the cytoplasmic processes of the cells , where they were arranged in several rows parallel with their long axis . They were also found in the cytoplasm of the Sertoli cells between two neighbouring spermatogenic cells .

In this study , using the electron microscope , it was found that the mitochondria of Sertoli cells were ovoid , spherical or long and slender with their long axes generally perpendicular to the boundary tissue of the seminiferous tubules . In contrast to the mitochondria of spermatids , they had mostly tubular cristae and a relatively dense matrix ( see figs.97 & 98 ) .

The Sertoli cell mitochondria appeared to have the same characteristic features of the mitochondria present in steroid-secreting cells which have been extensively studied by Kadioglu and Harrison ( 1971 ) .

Sertoli cells of Mepivacaine-HCl treated rats :

Some Sertoli cells in treated rats retained many normal features . They had an irregular shape , with the nucleus and perikaryal cytoplasm being located near the basal lamina , and with long protrusions extending throughout the seminiferous epithelium into the interstices between the various germ cells . The nuclei of Sertoli cells contained much euchromatin and a large nucleolus . Their cytoplasm displayed scattered , rough endoplasmic reticulum , numerous tubules and vesicles of smooth endoplasmic

Plate 52

Fig.97 An electron micrograph of an early spermatid and Sertoli cell from a normal ( control ) animal . Typical , longitudinally oriented vesicular-type mitochondria (m) with tubular cristae are present in the Sertoli cell cytoplasm ( Sc ) .

N , nucleus of spermatid .

X 12.600

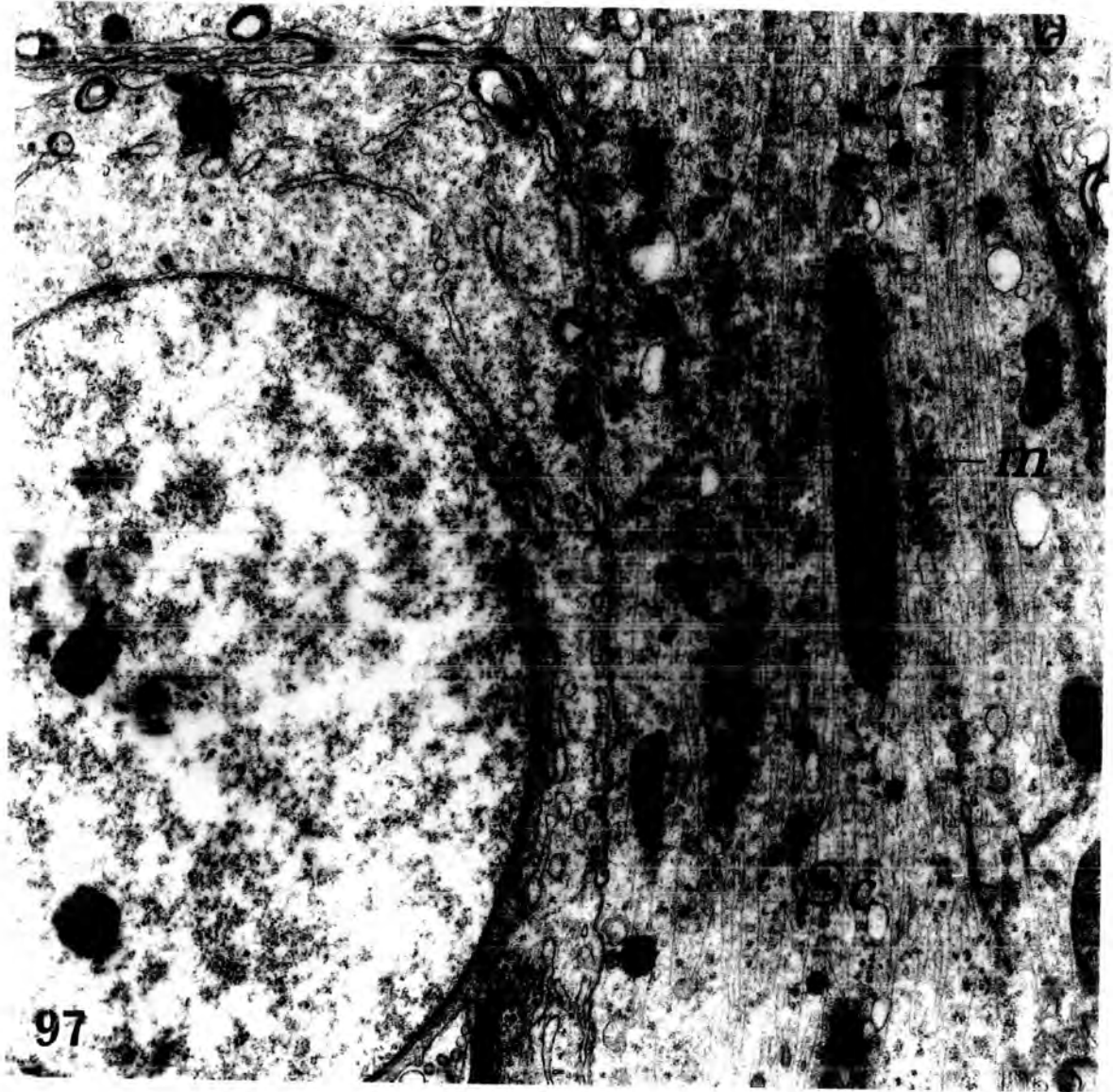
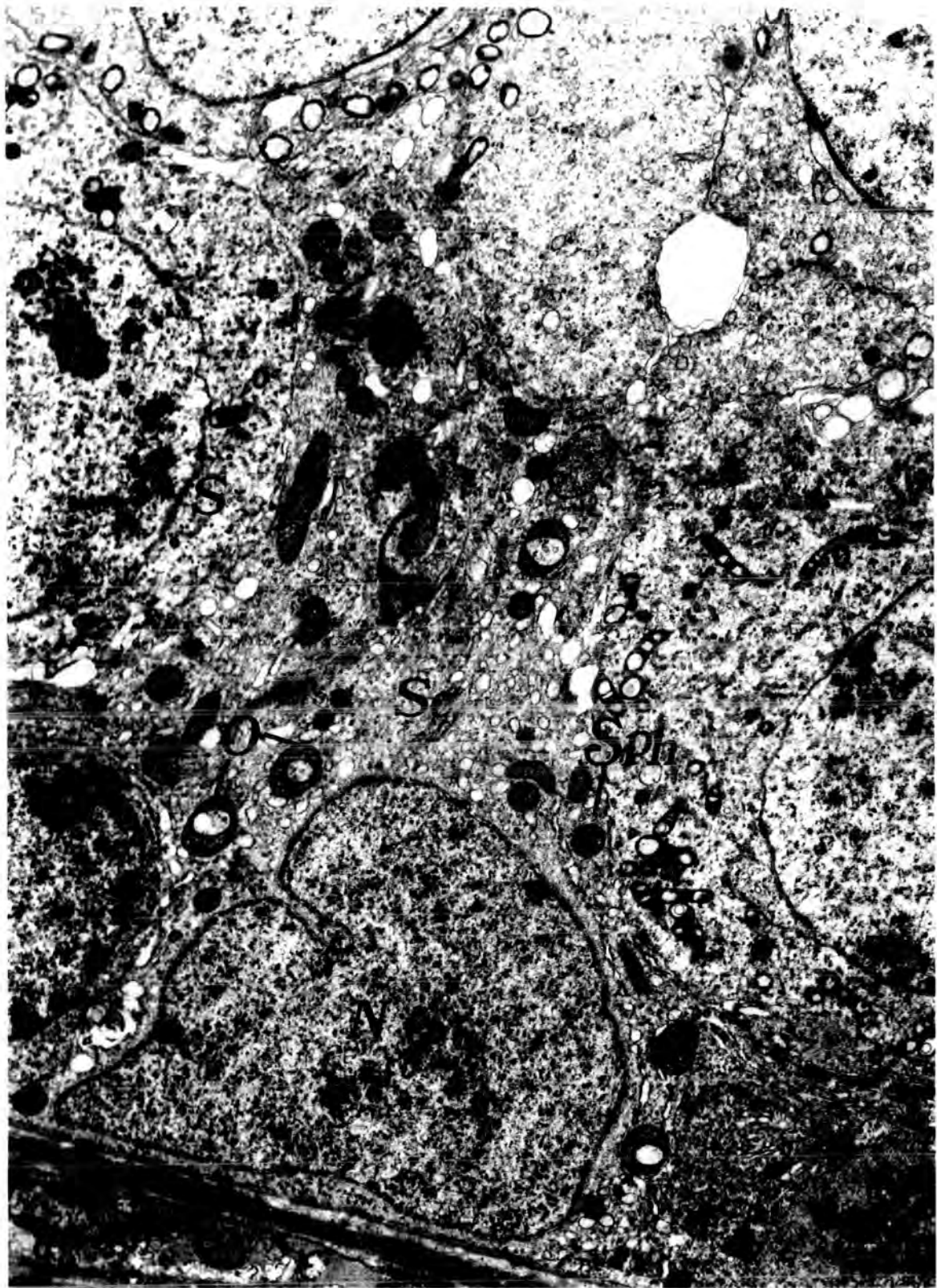


Plate 53

Fig.98 An electron micrograph of a Sertoli cell from a normal ( control ) animal . The nucleus ( N ) is irregularly shaped and exhibits a characteristic deep indentation ( asterisks ) , and the chromatin is finely granular . Ovoid ( O ) , spherical ( sph ) and slender-shaped ( S ) mitochondria are distributed throughout the cytoplasm ( Sc ) .

10.000



reticulum , and mitochondria ( Plate 54 , fig.99 ) .

Many large lipid droplets were readily visible in the cytoplasm of Sertoli cells ( Figs. 99 & 104 ) . In contrast to the lipid droplets of normal Sertoli cells , which were prominent at stage IX of the cycle of the seminiferous epithelium ( Kerr and DeKretser , 1975 ; Fawcett , 1975 ) , in treated rats the lipid droplets were numerous in almost all the profiles of seminiferous tubules . In addition , they frequently were so large in treated animals as to indent the nucleus , and sometimes they appeared to displace other organelles . Although most of the lipid droplets in the seminiferous epithelium were found in the basal cytoplasm of Sertoli cells , a few germ cells contained large lipid droplets as well ( see figs. 71 , 72 & 94 ) . Spermatid debris and necrotic cells were surrounded by the cytoplasm of Sertoli cells ( plate 54 , fig.99 ) , suggesting that they were phagocytosed and digested by the Sertoli cells .

In more "severely" damaged tubules , some Sertoli cells had a vacuolated cytoplasm , a prominent folded nuclear membrane . A small nucleolus and more abundant chromatin ; the cytoplasm of these cells had a fibrous appearance . The chromatin in these cells accumulated regularly on the internal surface of the nuclear membrane , giving a more distinct appearance ( see plate 55 , fig. 101 and plate 56 , fig. 103 ) .

In some Sertoli cells , mitochondria did not show response to drug administration ; but in other cells , particularly in more "severely" damaged tubules , the mitochondria appeared randomly arranged in the cytoplasm , instead of being arranged in rows running parallel to the proximodistal axis of the cell . Also , they became more electron-dense than in normal control animals . In the more electron-dense matrix , it was not possible to see if

Plate 54

Fig.99 Low power electron micrograph of part of the seminiferous tubule from an animal injected with 0.1 cm<sup>3</sup> of Mepivacaine\_HCl , 4% , and killed after 6 hours .

Degenerating cells ( D ) of the seminiferous epithelium are surrounded by the cytoplasm of Sertoli cells ( Sc ) . Most of the degenerating cells are electron-dense . Small lipid droplets ( L ) are present in the Sertoli cell. The primary spermatocytes ( spt-1. ) is probably in synaptinemal complex ( c ) in its nucleus .

N , Sertoli cell nucleus ; spd , Spermatid .

X 6.400

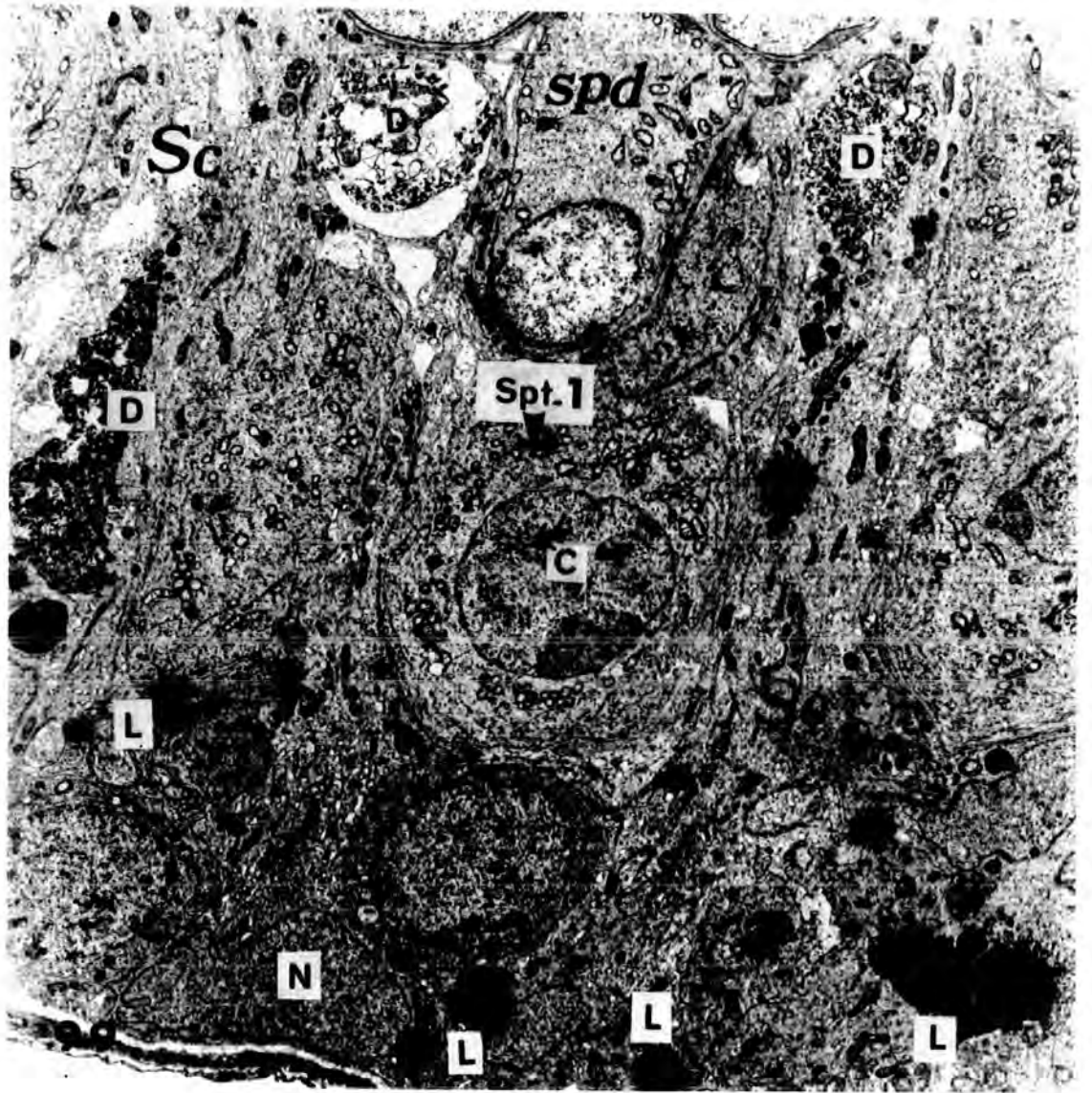


Plate 55

Fig.100 High power light micrograph of a transverse section of a testis from an animal injected with  $0.1 \text{ cm}^3$  of Mepivacaine-HCl, 4%, and killed after 6 hours, illustrating complete absence of the normal spermatogenic epithelium. The Sertoli cells show marked fibrosis ( arrow heads ).

X 400

Fig.101 An electron micrograph of part of a severely damaged seminiferous tubule from an animal injected with  $0.5 \text{ cm}^3$  of Mepivacaine-HCl, 4%, and killed after 12 hours. Marked fibrosis ( arrow heads ) appears in the cytoplasm of Sertoli cells resulting from the administration of the anaesthetic drug.

bt, boundary tissue ; L, lipid droplet ; Sc, Sertoli cell cytoplasm ; Sn, Sertoli cell nucleus .

X 5.000

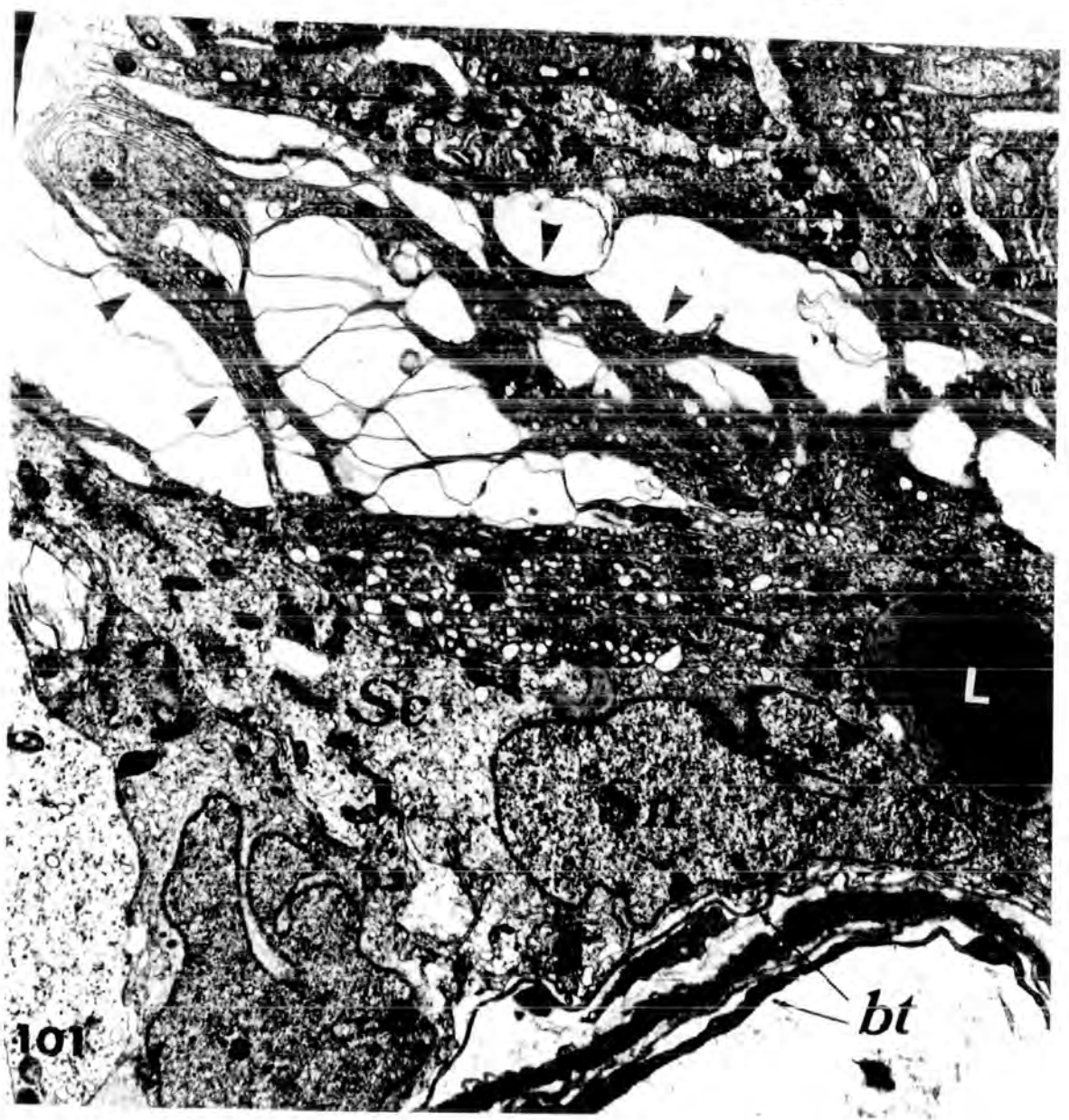
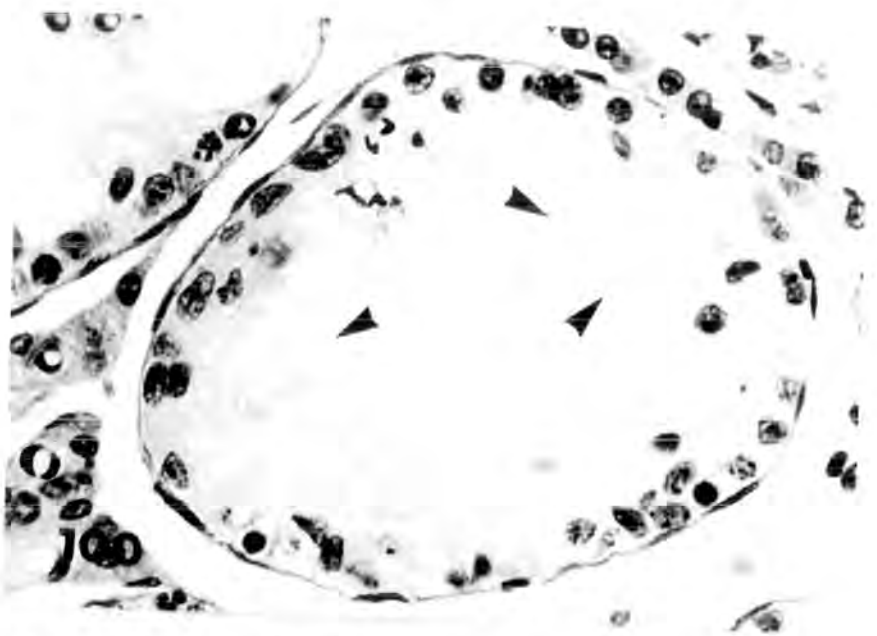


Plate 56

Fig.102 High power light micrograph of transverse section of a testis from an animal injected with 0.25 cm<sup>3</sup> of Mepivacaine\_HCl, 4% , and killed after 24 hours . X 500

Fig.103 An electron micrograph of a seminiferous tubule of a testis from an animal injected with 0.25 cm<sup>3</sup> of Mepivacaine\_HCl , 4% , and killed after 12 hours . X 5.000

Both figures :

Tubules showing migration of pycnotic and damaged Sertoli cells with grossly vacuolated cytoplasm ( arrows ) . Occasional B-type spermatogonia ( B ) can still be seen amongst the vacuolated Sertoli cells . In many tubules the Sertoli cells are displaced from their normal position along the limiting membrane and take up a more central position in the tubule .

L , Lipids ; So , Sertoli cell cytoplasm ; Sn , Sertoli cell nucleus.

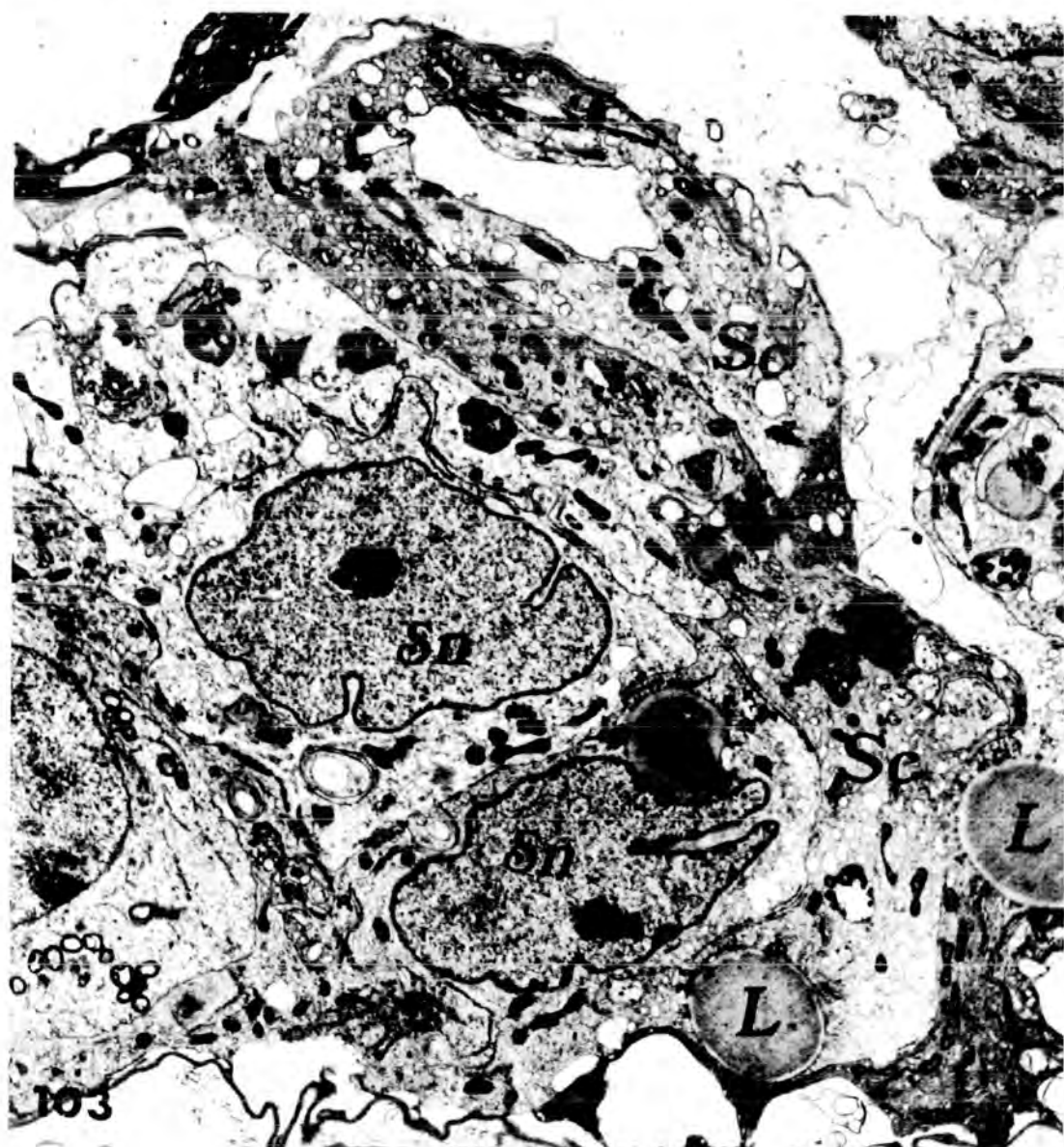
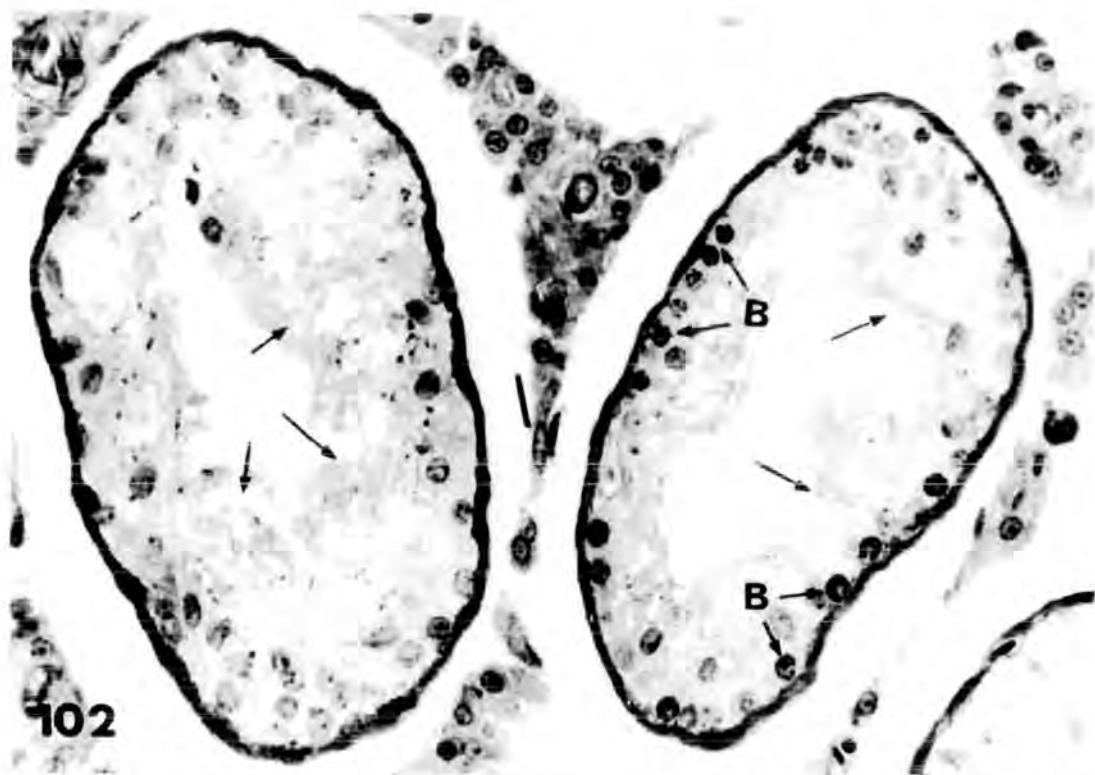
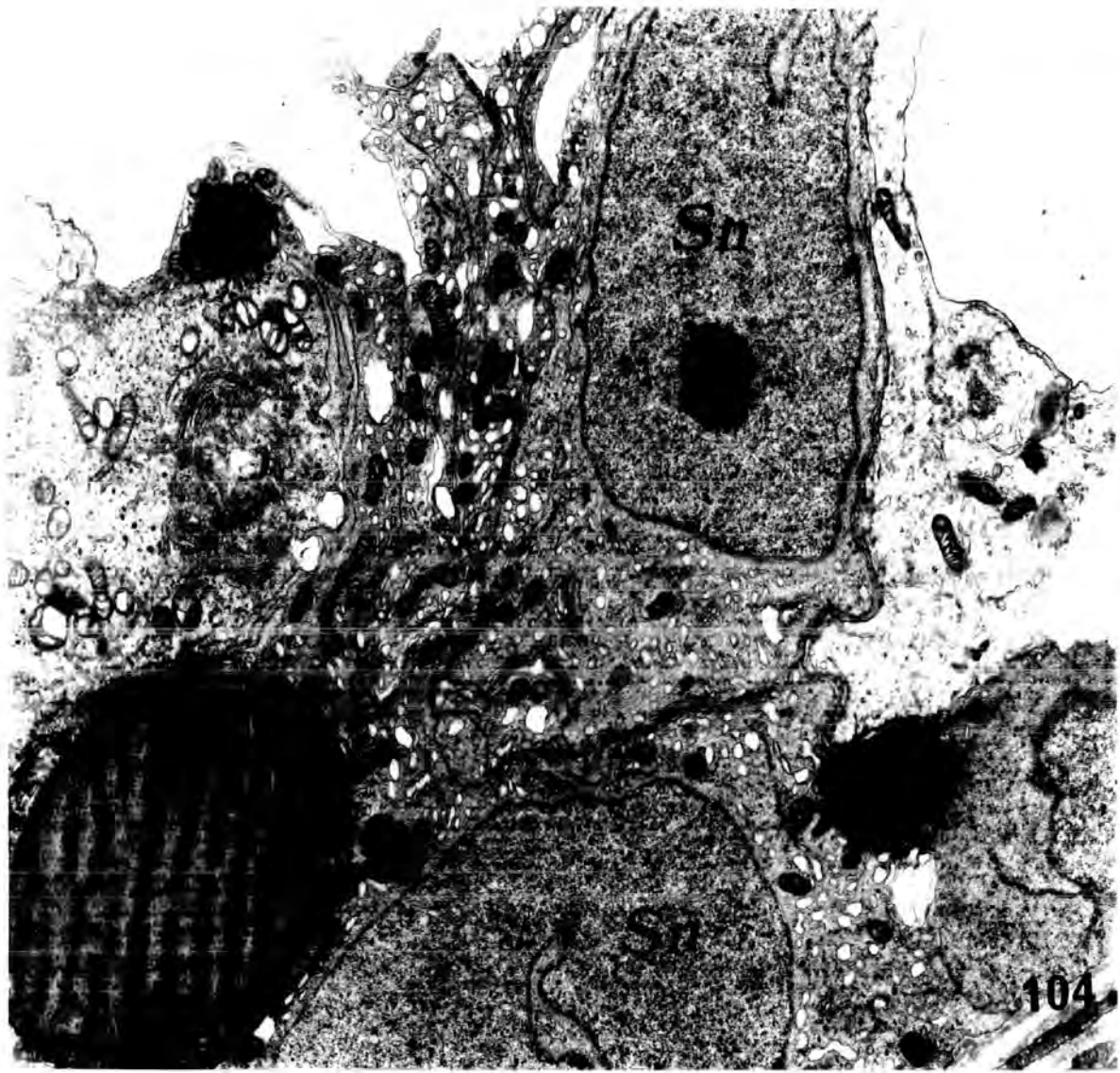

Plate 57

Fig.104 An electron micrograph showing large lipid droplets ( L ) in the cytoplasm of Sertoli cells from a rat injected with 0.1 cm<sup>3</sup> of Mepivacaine-HCl , 4% , and killed after 12 hours . Lipid droplets are very numerous in the Sertoli cells of treated animals . Some attain such a large size as to give the impression of displacing other organelles . Sn , Sertoli cell nucleus .

X 8.000



there was a change in the shape of cristae or not . Also , in some Sertoli cells which had a drastically vacuolated cytoplasm , the mitochondria were oval or spherical , devoid of cristae and showed some disintegration of the internal membranes ( see plate 40 , fig.82 ) .

Discussion :

The ultrastructural observations in the present study extend previous observations by more precisely defining the stages of the germ cells that were altered in the presence of Mepivacaine-HCl . The number of late spermatids of the acrosomal and maturation phases were greatly diminished in most sections . Cap-phase spermatids were the earliest stages to show degenerative changes and comprised the bulk of the necrotic cells that could be identified as to type .

There is little work related to the study of the boundary tissue ( Stieve , 1930 ; Clermont , 1958a ; 1958b ; Brokelmann , 1960 ; Lacy and Rotblat , 1960 ; Gardner and Holyoke , 1964 ) . The work of Lacy and Rotblat ( 1960 ) showed that the boundary tissue surrounding individual seminiferous tubules of the normal rat , is composed of four principal layers of which two are non-cellular and two cellular . The present study confirmed this . The first inner , non-cellular layer consisted of two layers of dense material . The inner cellular layer was composed of extremely elongated cells , which were typical of smooth muscle cells of the uterus ( Gansler , 1956 ) . The latter smooth muscle cells however contain many more filaments than seen in cells of the inner cellular layer . Morphologically , there is good reason to suggest that cells of the inner cellular layer may be a type of smooth muscle cell but of different level of organization from that of the uterus . The outer non-cellular layer was thin and the outer cellular

layer also thin with markedly irregular cell membranes .

In rats administered Mepivacaine-HCl , the boundary tissue of both "partially" and "severely" damaged tubules showed a marked increase in thickness at the light microscope level . At the electron microscope level, the boundary tissue split into the four layers which became highly folded . Oettle and Harrison ( 1952 ) , after occlusion of testicular artery , reported that boundary tissue in the necrotic tubules appeared to have split partly into layers .

Lacy and Rotblat ( 1960 ) , using both the light and electron microscope , reported that three weeks after a very high dose of radiation ( 10 000 r ) the average diameter of the seminiferous tubule decreased significantly from 244 u in normal to 120 u in irradiated animals . This was due to striking changes within the tubules . The boundary tissue was excessively folded . In some tubules , the nuclei of the cellular layers were crowded together . No difference was observed between the staining reactions of the boundary tissue after irradiation and normal material .

Spermatogonia and Sertoli cells were the most resistant cells in the seminiferous tubules of rats injected with Mepivacaine-HCl , A-type spermatogonia showed only slight pathological changes , mainly in their organelles , such as the Golgi apparatus and mitochondria . The B-type spermatogonia appeared still more resistant than the A-type , and population of these B-type cells together with Sertoli cells could be observed within the most severely damaged , which otherwise appeared completely empty of spermatogenic cells . Sometimes B-type spermatogonia were displaced from their normal position in contact with the boundary tissue towards the lumen .

The primary spermatocytes ( also , spermatogonia and spermatids ) are normally connected together through intercellular bridges . These intercellular bridges were interpreted as resulting from incomplete cell division ( Moens and Go , 1972 ) .

A marked elongation of primary spermatocytic cytoplasm was usually seen in the light microscopic preparations following drug administration , but the electron microscope study showed that this was only a morphological modification rather than a result of damage . Also , primary spermatocytes tended to form few bi- and multinucleate giant cells.

In rats administered Mepivacaine-HCl , marked lipid droplets were found in close contact with the primary spermatocytes , which appeared to distort the cell membranes by pushing in the direction of the nucleus . Sometimes the secondary spermatocytes had lipid droplets within their cytoplasm too .

The mitochondria , especially of primary spermatocytes , showed a distinct swelling accompanied by disintegration of the mitochondrial cristae . Also , cup-shaped mitochondria were found in Mepivacaine-HCl treated animals , which are not typical for germinal cells of control testes . Christensen and Chapman, ( 1959 ) , reported that cup-shaped mitochondria were not common , but some such mitochondrial profiles have been observed by Fawcett ( personal communication ) in the opossum Leydig cells . The cause of the cup-shape following drug administration was not clear .

Frederic and Chevremont ( 1952 ) , studying tissue culture fibroblasts viewed under phase contrast , occasionally

observed striking alterations in certain mitochondria , which shortened and diminished in overall contrast , and in which lighter areas appeared either centrally or marginally . An examination of the drawings illustrating such changes suggested that some of these mitochondria assumed a cup form .

It was difficult with the available data to ascribe any functional significance to the cup-shape . Attention may be called however to the increased surface area of cup mitochondria and to the possibility that the cytoplasm enclosed by the cup may be modified either chemically or enzymatically.

In the present study , it was clear that cap-phase spermatids were the earliest stages to show degenerative changes . Beyond this stage , a slight damage to approximately stages 2 - 3 were found . This damage consisted mainly of the exfoliation of these cells with a markedly " slight " damage to their organelles as Golgi apparatus and mitochondria . The cap-phase spermatids formed the bulk of the necrotic cells in the tubules . Sometimes the chromatin lost its granular structure , migrated to the periphery of the nucleus and coagulated into a homogeneous mass , giving the nucleus an annular appearance . In other cells , the acrosomic system became distorted and inverted into the nucleus , instead of lying in its normal position on the surface . In more severely damaged tubules , a complete destruction of the cytoplasm occurred , and the nuclear membrane became very irregular and contained non-homogeneous chromatin . Sometimes , large lipid droplets were found in a vacuolated Sertoli cell cytoplasm , in contact with degenerating spermatids . Also , young spermatids had a high susceptibility to form the multinucleate giant cells .

#### Multinucleate giant cell formation :

The development of multinucleate giant cells has often been reported

in testes exposed to damage .

In the present study the multinucleate giant cells were found within the " partially " and " severely " damaged tubules , but not in " slightly " damaged tubules . A few multinucleate cells were obviously derived from primary spermatocytes , but the bulk of multinucleate cells was derived from fused spermatids whose nuclei lay centrally or peripherally in a sharply demarkated mass of cytoplasm ; a fact which contributed to the decrease in the populations of the early spermatids in those testes with the smallest numbers of spermatids. In these multinucleate giant cells the nuclei were either pyknotic or undergoing karyolysis . Spermatogonia and Sertoli cells did not form multinucleates. The fate of the multinucleates appeared to be one of ultimate atrophy , pyknosis and detachment . The cytoplasm became more or less pyknotic and so did the nuclei which exhibited the changes common to all spermatid nuclei in the tubule . These cells were generally believed to arise by cytoplasmic fusion because, in the first place , they consisted <sup>of</sup> spermatids which are normally incapable of division , and secondly , they formed very rapidly ( Oettle and Harrison , 1952 ) . The fusion to form multinucleates requires the juxtaposition of numbers of cells with an unstable cytoplasmic membrane , a certain degree of fluidity of the cytoplasm and a final cytoplasmic stability after confluence , when surface tension has produced a spherical outline .

Kindred ( 1952 ) , in his study of the effect of the nitrogen mustards on the rat testes , similarly observed multinucleate cells , formed mainly from spermatids and few from spermatocytes . He reported that the surface barriers between the cells degenerated and the cells flowed together . Such a physical phenomenon could be attributed to changes in the surface tension of the cells .

The results of the present study proved that at least some necrotic

germ cells were taken up and digested by Sertoli cells , since recognizable parts of germ cells were found within Sertoli cytoplasm ( Plate 54 , fig.99 ). This is in accord with observations that Sertoli cells phagocytose degenerating germ cells under other conditions ( Lacy and Lofts , 1965 ; Vilar et al.,1967 ; Hugon and Borgers , 1966 ; Reddy and Svoboda , 1967 ; Roosen-Runge and Leik , 1968 ; Black , 1971 ; Flickinger and Loving , 1976 ) , as well as injected particulates ( Clegg and Macmillan , 1965 ) , and that they retain the residual bodies shed by developing spermatids ( Smith and Lacy , 1959 ; Brokelmann , 1963 ; Dietert , 1966 ) .

It is not known if phagocytosis by Sertoli cells is the fate of all the damaged germ cells . Some altered germ cells may also have been shed from the seminiferous epithelium and transported to the epididymis to accumulate in the distal part of the cauda epididymis ( Flickinger , 1977 b ) .

Fibrosis of the Sertoli cell cytoplasm appeared in Mepivacaine-HCl treated rats . Oettle and Harrison ( 1952 ) , and Dixit ( 1977 ) , in their studies on the effect of occlusion of testicular artery on the rat testis , also showed marked fibrosis in the cytoplasm of Sertoli cells .

The investigations on the distribution and fate of lipid inclusions throughout the cycle of the seminiferous epithelium of normal animals has yielded conflicting results . The lipids of the testicular tissue of adult albino rats were restricted to the seminiferous tubules only , where they occupied either a position at the limiting membrane , or in the luminal portion of the germinal epithelium (Lynch & Scott,1951). These two different localizations of lipids were thought to be connected with the maturation of the spermatogenic cells . It has been also suggested that lipids are situated entirely in the

Sertoli cells ( Lynch and Scott , 1951 ) , or both in the interstitial tissue as well as seminiferous tubules ( Sertoli cells , spermatogonia and spermatocytes ) ( Montagna , 1952 ) . Smith and Lacy ( 1959 ) reported that in old spermatids most of the lipid droplets appeared in one or two cytoplasmic protrusions at the ventral side of the sperm mid-piece . These masses of cytoplasm remained behind as residual bodies when spermatozoa were released ( they contained lipid droplets , mitochondria , accumulation of fine granules believed to be RNA granules ) . Following phagocytosis of the residual bodies at stage 9 of the spermatogenic cycle ( Leblond and Clermont , 1952 ) , large lipid inclusions appeared in the cytoplasm of the Sertoli cells . The electron microscopical study by Lacy ( 1960 ) demonstrated that the contents of phagocytosed residual bodies , with the exception of their lipid component , were gradually dispersed or absorbed . The lipid droplets of the residual bodies seemed to coalesce to form individually larger droplets , often with irregular outline . Thus , while the Sertoli cells may have synthesized some additional lipids at this period , the peripheral layer of lipids as seen by the light microscopy was probably largely derived from the residual bodies .

Also , Lacy , ( 1960 ; 1962 ) , postulated that during the final phases of meiosis ( stage X - XIV ) , the diminishing numbers of lipid inclusions in the Sertoli cells were associated with the synthesis of a Sertoli cell hormone, which in turn acted as a local stimulus for the maturation of primary spermatocytes into spermatids . Niemi and Korhano ( 1965 ) supported the finding of Lacy and his coworkers . The data of Posalaki et al. ( 1968 ) however , indicated that Sertoli cell lipid inclusions did not diminish after stage IX , but persisted at a constant level through stages X to XIV . Recently , Kerr and DeKretser , ( 1975 ) , suggested that although the phagocytosed residual bodies

probably released their lipid content into the Sertoli cells during stage IX of the cycle , the relative number of lipid inclusions within the Sertoli cells appeared to increase as spermatogenesis proceeded through the meiotic maturation phases ( stage X to XIV ) .

The increase in lipids in seminiferous tubules is a characteristic feature of the damaged tubules , and this increase in the amount and size of the lipid droplets was reported by many investigators .

The results obtained from the present study revealed the presence of the lipid granules and droplets in both the seminiferous tubules and in the interstitium .

Robbin ( 1974 ) stated that lipid accumulation is seen in a variety of cells under pathological conditions . Also , an increase in lipid in Sertoli cells has been observed in other cases in which spermatogenesis was disrupted ( Lacy , 1962 ; Lacy and Lofts , 1965 ; Collins and Lacy , 1969 ; Chung , 1974 ) .

Examination of the tubules by electron microscopy one week after irradiation by Lacy ( 1962 ) , revealed that the lipid was located within the cells , none being extracellular . A study of germ cells in a late stage of degeneration , carried out by Lacy ( 1962 ) , showed that morphologically they were similar to the residual bodies of normal rats , and they were being phagocytosed by the Sertoli cells . Finally , the contents of degenerating germ cells became dispersed in the Sertoli cells , until finally all that could be identified was their lipid .

# *General Discussion*

### General Discussion

Mepivacaine - HCl is one of a series of new long-acting local anaesthetics . It is stressed that the drug has a rapid onset , producing deep anaesthesia , and that it has a high frequency of anaesthesia and clinical safety and effectiveness ( Aberg and Adler , 1970 ; Jorfeldt et al., 1970 ) and low toxicity ( Luduena et al., 1960 ; Henn , 1960 ).

Mepivacaine-HCl is commercially available in several different media . It is dissolved in saline solution at three different concentrations ; 0.5% , 1% and 2% ( weight / volume ) , for local anaesthesia , injection for infiltration or conduction anaesthesia . As a 3% solution ( weight / volume ) it is used for dental anaesthesia and as a 4% solution for hyperbaric anaesthesia .

Mepivacaine-HCl , particularly its (+) isomer , has been shown to have a marked vasoconstrictor effect on the isolated rat portal vein ( Aberg and Wahlstrom , 1972 ) .

In the present study , the histology and histochemistry of the testes of albino rats receiving intraperitoneal injection(s) with Mepivacaine-HCl solution of different doses and concentrations ( 0.05 cm<sup>3</sup> of 2 and 4% and 0.1 , 0.25 and 0.5 cm<sup>3</sup> of a 4% solution ) , and killed after different times were examined using both light and electron microscope.

The animals that received Mepivacaine-HCl , especially the high dose , 0.5 cm<sup>3</sup> , showed convulsions accompanied by increased respiration rate ; deep anaesthesia followed rapidly and some of these animals were

unable to recover . Hiatt ( 1961 ) and Ulfendahl ( 1957 ) reported that the most severe type of local anaesthetic reaction consisted of convulsions with accompanying increase in blood pressure , pulse rate and respiration . The depression which follows may be such that the patient is unable to recover , and Hiatt ( 1961 ) concluded that death , due to a local anaesthetic reaction , is believed to be more closely related to respiratory failure than circulatory failure .

Hansson et al.( 1965 ) and Kristensen et al. ( 1965 ) reported that , within a few minutes after injecting Mepivacaine-HCl , the drug was found in a relatively high concentration in the brain , followed by an equally swift reduction , and he suggested that this rapid deposition in the brain may explain the central nervous system symptoms which are seen in connection with injection of a local anaesthetic .

A large number of the testes of the animals injected with higher doses ( 0.1 , 0.25 and 0.5 cm<sup>3</sup> ) of Mepivacaine-HCl showed local haemorrhage and appeared darkly discoloured . Similar haemorrhage in the testes was shown after cadmium administration carried out by Gunn et al.( 1963b ) and Gunn and Gould ( 1970 ) . They suggested that the primary injurious effect of cadmium might be vascular .

When young and older adult rats were injected with Mepivacaine-HCl at different higher doses ( 0.1 , 0.25 and 0.5 cm<sup>3</sup> ) , only the younger ones showed damage ; in no case was any testis examined that showed damage in the larger adult animals . This means that the pathological effect of Mepivacaine-HCl is body weight dependent . It was considered that the likely cause for this was the presence of larger amount of fats in the abdomi-

nal cavity in the larger animals , which absorbed the drug , and so lower concentrations would be present in the circulation . The body weight dependency of the effect of Mepivacaine-HCl is only one area where the effect of this drug is problematical . Large individual variations in response , as determined from testis histology ( see chapter 3 & 6 ) , to the drug were observed . It is the individual variation which made it difficult to construct any dose dependent effects . Even so it was clear that the higher dose levels ( 0.1 , 0.25 & 0.5 cm<sup>3</sup> of a 4% solution ) produced more severely damaged tubules than the lower doses ( 0.05 cm<sup>3</sup> of 2 and 4% solution ) . The cause of the individual variation , particularly in relation to the quantity of visceral fat deposits , is an area which demands further study .

Not in all animals was damage caused , and the nature of the damage differed in different tubules . Great differences were seen even between the two testes of the same animal . The histological appearance of the testes from treated animals varied greatly from a few damaged tubules in some testes to completely damaged tubules of the whole testes in other animals . The tubule damage caused a marked decrease in weight of the testes .

The high doses were apparently not quantitatively different in their effects , therefore , the severity of the damage to the testes was classified here into " slightly " , " partially " and " severely " damaged tubules . The " slightly " damaged tubules were mainly characterized by vacuolation and the paucity of late spermatids , particularly in stages I - VII of the cycle . The vacuoles appeared more or less rounded , without any evidence of cell debris , and looked as if bounded by an outer

membrane . However , Boccabella et al. ( 1962 ) and O'steen ( 1963 ) described similar vacuoles formed as a result of death and resorption of one or more spermatogenic cells or detached cells . The reasons for the appearance of these vacuoles are discussed in chapter 3 , and as they may arise from simple exfoliation of cells by the Sertoli cells , some debris might be expected . It is therefore likely that the vacuole resulted from a fluid accumulation , either within , or between Sertoli cells . It is pertinent that Dobbs and Ross ( 1961 ) reported that one local side effect of an intraperitoneal injection of Mepivacaine-HCl was oedema .

The damage caused after low doses ( 0.05 cm<sup>3</sup> , 2 and 4% solution ) of Mepivacaine-HCl intraperitoneal administration was mainly of the "slight" type , which included both vacuolation and tubules in which the late spermatid stage was absent .

The results obtained in the present study showed that repeated insults to the testes resulted in an accumulation of damage after Mepivacaine-HCl administration . There was a marked increase in number of both " partially " and " severely " damaged tubules with repeated application of Mepivacaine-HCl . This was accompanied by a corresponding decline in the numbers of both normal and " slightly " damaged tubules . The formation of multinucleate giant cells , mainly from early spermatids or sometimes from primary spermatocytes , as well as exfoliation was responsible for the marked depletion of such cells from the tubules .

The proportion of the interstitial tissue was apparently increased

following drug treatment , this probably owing to the relative decrease in tubule diameter which followed reduction in the germinal epithelium . In the testes of one animal only was severe damage to the interstitium seen when hyalinization occurred ( Plate 9 , fig. 28 ) .

Seminal vesicle weight has been widely used as an indicator of the level of androgen output , and therefore of the level of interstitial cell function . The fact that , in the present study , the seminal vesicle weights from experimental rats did not differ significantly from those of normal rats , ( even when receiving successive injections of Mepivacaine-HCl ) , suggested that seminal vesicle function was unaffected by administration of Mepivacaine-HCl . This was confirmed by the observation that experimental animals showed no loss of libido and displayed normal sexual behaviour with females .

The late spermatids were apparently the cell type most readily damaged after Mepivacaine-HCl administration , as they were frequently lost and were even sometimes completely absent from the tubules . The late spermatids were still present , they appeared attached to the Sertoli cell cytoplasm at the wrong position , and so the tubules lost their orderly and characteristic arrangement of the germinal elements . In more damaged cases , degenerating late spermatids were occasionally seen . The head of most of them was broken , twisted and detached from the middle piece .

The absence of late spermatids from the tubules was recorded after temporary and permanent occlusion of the testicular artery ( Oettle and Harrison , 1952 ) ; after treatment with cyproterone ( Mietkowski and

Lukaszyk , 1969 ) and cyproterone acetate ( Neumann and Von Berswordt-Wallrabe , 1966 ; Steinbeak et al., 1971 ; Flickinger and Loving , 1976 ) , but not after application of heat to the testes .

Next in order of sensitivity were early spermatids ( especially stage VII ) , which showed different degrees of damage and degeneration. The damage caused to early spermatids mainly concerned the exfoliation of these cells , migration of chromatin to the periphery of their nuclei , giving annular appearance , distortion and inversion of the acrosomic system into the nucleus instead of lying on the nucleus surface . In more severely damaged tubules a complete destruction of the spermatid cytoplasm occurred and the nuclear membrane became very irregular and contained non-homogeneous chromatin . In damaged tubules , early spermatids also had the tendency to form multinucleate giant cells . The early spermatid multinucleates formed the bulk of the multinucleates within the "partially" and " severely " damaged . The nuclei of cells within the multinucleates variously appeared normal , pycnotic or showed signs of undergoing karyolysis , and the cytoplasm appeared dark or ragged .

Similar multinucleate giant cells were seen by Oettle and Harrison ( 1952 ) and Kindred ( 1952 ) . Oettle and Harrison ( 1952 ) reported that these cells arose by cytoplasmic fusion and not as a result of incomplete division . They concluded this because : first the spermatids are normally incapable of division and second , the multinucleate giant cells form very rapidly . Kindred ( 1952 ) , in his study on the effect of the nitrogen mustards on the rat testes , similarly observed multinucleate cells , and he reported that they formed when the surface barriers between the cells have degenerated , causing the cells to flow together .

The primary spermatocytes were the next in order of sensitivity . A marked elongation of primary spermatocytic cytoplasm was usually seen in the light microscopic preparations following drug administration .

Spermatogonia and Sertoli cells were the most resistant cell types to drug administration , and sometimes were attached to the boundary tissue, even in the most seriously damaged tubules .

The damage caused after Mepivacaine-HCl injection was clearly different from that after scrotal heating . Work carried out by Steinberger and Dixon , 1959 ; Collins and Lacy , 1969 ; Chowdhury and Steinberger , 1970 and Parvinen , 1973 , showed that the pachytene , diakinetiic and dividing spermatocytes at stages IX to XIV , and the young step 1 and step 2 spermatids were most susceptible to heat .

Some pathological changes reported to occur in the testis due to progestin and androgen treatments in rats ( Flickinger , 1977a ) were similar to those of Mepivacaine-HCl injection , but others were different . On the other hand , the injurious effect of 5-hydroxytryptamine (Boccabella et al., 1962 ; O'steen , 1963 ; Korman et al., 1968 ) , and histamine ( O'steen , 1963 ) on rat testis was closely similar to that shown after Mepivacaine-HCl administration .

Many extremely large lipid droplets were present in the seminiferous epithelium of the treated animals , as well as in the interstitial cells . The amount of lipids inside the seminiferous tubules ranged from granules to large droplets . Most of the lipid was intracellular . In rats which received different doses of Mepivacaine-HCl , large lipid droplets were usually seen within the Sertoli cell cytoplasm or within the cytoplasm of germ cells as primary and secondary spermatocytes .

The increase in lipid content has been reported following cryptorchidism , hypophysectomy , local heating , and estrogen treatment (Hans and Rosenbloom , 1911 ; Lynch and Scott , 1951 ; Iacy , 1962 ; Iacy and Lofts , 1965 ; Collins and Iacy , 1969 ) , and testicular feminization syndrome ( Chung , 1974 ) .

Collins and Iacy ( 1969 ) reported that the degenerating germ cells which resulted from a single exposure to heat , were phagocytosed by Sertoli cells , and this caused an increase in the lipid content of Sertoli cells . Johnson ( 1970 ) reported that , in general , the testes lipid fractions tended to increase as the testis became devoid of spermatozoa and testicular fluid .

According to the results of this study , and the findings of many investigators , the increase in testicular lipids in treated animals might result as a response to injurious changes in the germ cells . On the other hand , they could be due to an alteration in the metabolism of the Sertoli cells themselves , because lipid accumulation is a well known pathological change , that occurs in many cells under a variety of deleterious conditions ( Robbins , 1974 ) .

The EM appearance of individual cell types revealed more detailed information of the pathological changes that occurred in damaged cells . However , it was also possible to identify intracellular lesions in cells ( e.g spermatogonia ) , that appeared normal in the light microscopic study . The cellular accumulation of lipid , and presence of abnormal mitochondria , were the most obvious signs of damage in those cells .

The mitochondria of the early spermatids after Mepivacaine-HCl administration appeared randomly scattered in the cytoplasm , instead of lying close to the cell membrane ; they were also extremely electron-dense with no visible cristae .

A marked elongation of primary spermatocytic cytoplasm was usually seen in the light microscopic preparations following drug administration, but the electron microscope study showed that this was only a morphological modification , rather than a result of damage . Also , primary spermatocytes tended to form bi- and multinucleate giant cells . The multinucleate spermatocytes seen in the present study contained only three nuclei .

The secondary spermatocytes showed marked destruction in some parts of the cytoplasm ; also the nuclear membrane appeared bulging into the cytoplasm .

The mitochondria of the primary spermatocytes showed a distinct swelling , accompanied by disintegration of the mitochondrial cristae . Also , cup-shaped mitochondria were found in Mepivacaine-HCl treated animals . These were not typical for germinal cells of control testes. These cup-shaped mitochondria were reported by many investigators

Fawcett ; Slautterbaek and Fawcett ( personal communication by Christensen and Chapman , 1959 ) , but have not been reported in rat spermatocyte before . Frederic and Chevremont ( 1952 ) studying tissue culture fibroblasts viewed under phase contrast , occasionally observed alterations in certain mitochondria which became cup-shaped . It was

difficult , with the available data , to decide if cup-shaped mitochondria appeared as a result of Mepivacaine-HCl administration or not . Clearly this needs an extensive study of the mitochondria of spermatocytes from many animals , both normal and treated with Mepivacaine-HCl . It was difficult to ascribe any functional significance to the cup shape . If it arises as a response to injury , then no functional cause exists . Attention may be called however to the increased surface area of cup-shaped mitochondria and also it is possible that the cytoplasm enclosed by the cup may be modified either chemically or enzymatically .

The mitochondria of the secondary spermatocytes showed disruption and fusion of the membranes , which gave an electron dense appearance .

At the light microscope level it was not possible to determine the extent of damage , if any , to spermatogonia . At EM level , A-type spermatogonia showed some changes following Mepivacaine-HCl administration . It was mainly to their organelles , such as Golgi apparatus and mitochondria , that signs of damage were recorded ; B-type spermatogonia appeared to be more resistant than A-type in this respect . So it is significant that B-type spermatogonia and Sertoli cells were the only cell types found in severely damaged tubules .

The mitochondria of spermatogonia frequently were swollen , which in some cases was a gross swelling . In other cases they lost their electron dense matrix , the cristae began to disintegrate and coalesce together , forming condensed electron dense bodies , which accumulated at one side of the outer membranes .

The boundary tissue of tubules " partially " and " severely " damaged by intraperitoneal injections of the local anaesthetic agent , Mepivacaine-HCl , showed a marked increase in thickness at the light microscope level . At the electron microscope level , the boundary tissue could be resolved into the four layer which became highly folded .

The thickened and split boundary tissue was reported after occlusion of testicular artery ( Oettle and Harrison , 1952 ) and after X-irradiation ( Lacy and Rotblat , 1960 ) . This thickening and folding of the boundary tissue resulted from the marked decrease in tubule diameter , which was obvious especially in " partially " and " severely " damaged tubules .

Sertoli cells were the most resistant to drug administration , and were still attached to the boundary tissue , even in the most seriously damaged tubules . Sertoli cells of treated rats contained many lipid droplets in their cytoplasm , and in more "severely" damaged tubules , some Sertoli cells had a vacuolated cytoplasm , a prominent folded nuclear membrane and more abundant chromatin , and the cytoplasm of these cells took on a fibrous appearance . Sertoli cell mitochondria did or did not show any response to drug administration . When they did , they became more electron dense than that of normal rats .

The phagocytic activity of the Sertoli cell is well known ( Lacy and Lofts , 1965 ; Rugon and Borgers , 1966 ; Vilar et al . , 1967 ; Reddy and Svoboda , 1967 ; Roosen-Runge and Leik , 1968 ; Black , 1971 and Flickinger and Loving , 1976 ) as well as injected particulates ( Clegg and Macmillan , 1965 ) .

It is not known if phagocytosis by Sertoli cells is the fate of all the damaged germ cells , since Flickinger ( 1977 b ) reported that some altered germ cells may also have been shed from the seminiferous epithelium and transported to the epididymis , to accumulate in the distal part of the cauda epididymis .

Little work was done on the ultrastructure of the effect of chemical and physical agents on the testes .

Flickinger and Loving ( 1976 ) reported that spermatogonia , spermatocytes and early spermatids were abundant in light microscopic preparations of animals treated with cyproterone acetate . When studied with the electron microscope , germ cells appeared to have a normal ultrastructure in stages up to cap-phase spermatids ( stages 4 - 7 , Leblond and Clermont , 1952 ) .

Also , Flickinger ( 1977 a ) , in his study of the influence of progestin and androgen on the fine structure of male reproductive tract , showed that spermatogonia , spermatocytes and early spermatids in treated rats did not show ultrastructural changes . At the same time , many necrotic cells were identified as early spermatids in the later part of the cap-phase ( approximately stages 6-7 , Leblond and Clermont , 1952 ) .

The results obtained after hypophysectomy ( Russell and Clermont , 1977 ) showed similarities in the damage caused to the cells . These damaged cells were spermatocytes , at the mid-pachytene step of meiosis , and spermatids at step 7 and 19 of spermiogenesis .

According to findings of Haddy ( 1958 ) ; Haddy et al. ( 1959 ) ;

Cross and Silver ( 1962 ) ; Waites and Setohell ( 1966 ) and Dutt et al., ( 1977 ) , and the results obtained in the present study , beside our knowledge that Mepivacaine-HCl has vasoconstrictor effects , it is considered that the injurious effects of the administration of Mepivacaine-HCl , 2 or 4% solution intraperitoneally , with different doses , were due to reduced blood flow to the testis .

It is hoped that the results obtained in this investigation will help the anaesthetists , by pointing to possible damage to the testes by this drug , during a short period of application with a wide range of doses.

It is pertinent to ask whether the damaging effects shown after intraperitoneal administration of Mepivacaine-HCl are restricted to this drug only or whether all the local anaesthetic drugs have similar effects. The answer to this question needs more extended studies with different local anaesthetic drugs . A more concentrated study of the cellular organelles after drug administration is needed to give more details about the exact mechanism of the action of this drug .

Other organs , such as liver and kidney , need to be studied after Mepivacaine-HCl administration , because they are known to be related to the metabolism of the drug .

# Bibliography

BIBLIOGRAPHY

---

- Abbott , C.R., 1959 . The effect of X-irradiation on the secretory capacity of the testis . *J. Endocrin.*, 19 : 33 - 43 .
- Aberg , G. and R. Adler , 1970 . Thermographic registrations of some vascular effects of a local anaesthetic compound . *Svensk tandlak-T.* 63 : 671 - 677 .
- and B.Wahlstrom , 1969 . Vascular effects of Mepivacaine . *Acta physiol. Scand.* ( supp.) 330 : 71 .
- and -----, 1972 . Mechanical and electrophysiological effects of some local anaesthetic agents and their isomers on the rat portal vein . *Acta pharm. Toxicol.* 31(4):255-266 .
- and R.Anderson , 1972 . Studies on mechanical actions of Mepivacaine ( Carbocaine ) and its optically active isomers on isolated smooth muscle ; role of Ca and cyclic AMP . *Acta pharmacol. et toxicol.* 31 : 321 .
- Adler , R.; G.Adler and G.Aberg , 1969a . Effects of optically active isomers and racemate of Mepivacaine ( Carbocaine ) in dental anaesthesia . *Svensk tandlak-T.* 62 : 501 .
- ; ----- and ----- , 1969b . Studies on dental blood flow in dogs . *Svensk tandlak-T.* 62 : 699 - 703 .
- Ahquist , K.A. , 1966 . Enzyme changes in rat testis produced by the administration of Busulphan and of 7 , 12-dimethylbenz(α) anthracene . *J. Reprod.Fertil.*, 12 : 377 - 379 .
- Altwein , J.E. and R.F.Gittes , 1972 . Vasektomie und Hodenfunktion . *Tierexperimentelle Untersuchungen . Aktuelle Urologie* , 3 : 235 .
- Amarose , A.P. and D.M. Czajka , 1962 . Cytopathic effects of deuterium oxide on the male gonads of the mouse and dog. *Exp.cell Res.* 26 : 43 - 61 .
- Andre , J., 1962 . Contribution a la connaissance du chondriome . Etude de ses modifications ultrastructurales pendant la spermatogenese . *J. Ultrastruct. Res. suppl.* 3 : 185 .
- Bascom , K.F., 1923 . The interstitial cells of the gonads of cattle with especial reference to their embryonic development and significance . *Amer.J.Anat.* 31 : 223 .

- Black , V.H., 1971 . Gonocytes in fetal guinea pig testes : phagocytosis of degenerating gonocytes by Sertoli cells .  
Amer. J. Anat. 131 : 415 - 426 .
- Boccabella , A.V., E.D. Salgado and E.A. Alger , 1962 . Testicular function and histology following serotonin administration.  
Endocrinology 71 : 827 - 837 .
- \_\_\_\_\_ and R. Jarecki , 1965 . Limited responsibility of testicular lesions induced by Serotonin : Evidence for a direct vascular effect . P.15 8th Internat. Congress of Anatomists , Wiesbaden . George Thieme verlag , Stuttgart.
- Bourg , R., 1931 . Recherches sur l'histophysiologie de l'ovaire , du testicule et des tractus genitaux du rat et de la souris.  
Arch. Biol., Paris , 41 : 245 - 341 .
- Bowler , K., 1967 . The effect of repeated temperature applications to testes on fertility in male rats . J. Reprod. Fertil. 14 : 171 - 173 .
- \_\_\_\_\_ , 1972 . The effect of repeated applications of heat on spermatogenesis in the rat : a histological study .  
J. Reprod. Fert. 28 : 325 - 333 .
- Brokelmann , J., 1960 . The limiting layers of the seminiferous tubule in the albino rat . J. appl. physics 31 : 1844 .
- \_\_\_\_\_ , 1963 . Fine structure of germ cells and Sertoli cells during the cycle of the seminiferous epithelium in the rat.  
Z. Zellforsch , 59 : 820 - 850 .
- Burgos , M.H.; R. Vitale-Calpe and Aoki , 1970 . A fine structure of the testis and its functional significance . In : The testis. ( Eds. A.D. Johnson ; W.R. Gomes and N.L. van Demark ) .  
Vol. I pp. 551 - 649 Academic press , New york .
- Cameron , E., 1965 . The effects of intratesticular injections of cadmium chloride in the rabbit . J. Anat. 99 : 907 - 912 .
- Chiquoine , A.D., 1963 . Studies on testicular necrosis induced by cadmium salts . Anat. Rec. 145 : 216 .
- Chowdhury , A.K. and E. Steinberger , 1964 . A quantitative study of the effect of heat on germinal epithelium of rat testes . Am. J. Anat. 115 : 509 - 524 .
- \_\_\_\_\_ and \_\_\_\_\_ , 1970 . Early changes in the germinal epithelium of rat testes following exposure to heat . J. Reprod. Fertil. 22 : 205 - 212 .

- Christensen , A.K., 1965 . The fine structure of testicular interstitial cells in guinea pigs . J. Cell Biol. 26 : 911 - 935 .
- , 1975 . Leydig cells . In : Handbook of physiology . Vol.V. Male Reproductive system . R.O.Greep and E.B.Astwood , eds. American physiological society , Washington , pp.57-94 .
- and G. B. Chapman , 1959 . Cup-shaped mitochondria in interstitial cells of the albino rat testis . Exp. Cell Res. 18 : 576 - 579 .
- and S. W. Gillim , 1969 . The correlation of fine structure and function in steroid-secreting cells , with emphasis on those of the gonads . In : The Gonads K.W. McKerns , North Holland Pub. Co., Amsterdam , pp. 415 - 488 .
- Chung , K.W., 1974 . Fine structure of Sertoli cells and myoid cells in mice with testicular feminization . Fertil. Steril., 25 : 325 - 335 .
- Clegg , E.J., 1961 . Further studies on artificial cryptorchidism : Quantitative changes in the interstitial cells of the rat testis . J. Endocrin. 21 : 433 - 441 .
- , 1963 a . Studies on artificial cryptorchidism ; Morphological and quantitative changes in the Sertoli cells of the rat testis . J. Endocrin. 26 : 567 - 574 .
- , 1963 b . Studies on artificial cryptorchidism ; Degenerative and regenerative changes in the germinal epithelium of the rat testes . J. Endocrin. 27 : 241 - 251 .
- , 1965 a . Studies on artificial cryptorchidism ; Compensatory changes in the scrotal testes of unilaterally cryptorchid rats . J. Endocrin. 33 : 259 - 268 .
- , 1965 b . Studies on artificial cryptorchidism ; The histological appearances of unilateral and bilateral abdominal testes in the rat . J. Endocrin. 33 : 269 - 278 .
- and E.W. Macmillan , 1965 . The uptake of vital dyes and particulate matter by the Sertoli cells of the rat testis . J. Anat., Lond. 99 : 219 - 229 .
- Clermont , Y., 1958 a . Contractile elements in the limiting membrane of the seminiferous tubules of the rat . Exp. Cell Res. 15 : 438 - 440 .
- , 1958 b . The fine structure of the limiting membrane of the seminiferous tubule of the rat . Vierter Internationaler Kongress fur Elektronenmikroskopie . Verhandlungen-Band II Springer- Verlag , Berlin 426 .

- Clermont , Y. and E. Bustos-Obregon , 1968 . Re-examination of spermatogonial renewal in the rat by means of seminiferous tubules mounted " in toto " . Am. J. Anat. 122 : 237 - 247 .
- Collins , P. and D. Laoy , 1969 . Studies on the structure and function of the mammalian testis . II. Cytological and histochemical observations on the testis of the rat after a single exposure to heat applied for different lengths of time . Proc. Roy. Soc. B., 172 : 17 - 38 .
- Coppola , J.A., 1969 . An extra-gonadal male anti-fertility agent . Life Sci. 8 : 43 - 48 .
- Coutinho , E.M. and J.F. Melo , 1973 . Successful inhibition of spermatogenesis in man without loss of libido ; A potential new approach to male contraception . Contraception , 8: 207-217 .
- Cross , B.A. and I. A. Silver , 1962 . Neurovascular control of oxygen tension in the testis and epididymis . J. Reprod. Fertil. 3 : 377 - 395 .
- Cunningham , J. T., 1927 . Experiments on artificial cryptorchidism and ligature of the vas deferens in mammals . Brit. J. Exper. Biol. 4 : 333 .
- Derrick , F.G.J.; W. Lloyd Glover ; Z. Kanjuparamban ; C.B.Jacobson ; M. Modougall and K. Mccowin , 1974 . Histologic changes in the seminiferous tubules after vasectomy . Fertil. Steril. 25 (8) : 649 - 658 .
- Dhuner , K.G., 1964 . Resorption of local anaesthetics and vasoconstrictors in regional anaesthesia . Proceedings the third internat. Congress of Anaesthesiology , Sao Paulo , Brazil Sept. 1964 Tomo I , p. 313 .
- \_\_\_\_\_ ; D.H. Lewis ; A. Nygvist , D. Selander and E. Stig , 1972 . Vascular effects of the isomers of Mepivacaine . Acta Anaesthesiol. Scand. ( Supp. ) 48 : 48 .
- Dietert , S. E., 1966 . Fine structure of the formation and fate of the residual bodies of mouse spermatozoa with evidence for the participation of lysosomes . J. Morph., 120 : 317-346.
- Dixit , V.P., 1977 . Histological and biochemical changes produced in the dog testis after vascular occlusion . Indian J. Med. Res. 65 : 76 - 81 .
- \_\_\_\_\_ ; M. Agrawal and N.K. Lohiya , 1976 . Effect of a single ethanol injection into the vas deferens on the testicular function of rats . Endokrinologie , Vol.67(1) : 8 - 13 .

- Dixit , V.P. and N.K. Lohiya , 1976 . Observations on the effects of  $\alpha$ -chlorhydrin on the testes and pituitary gonadotrophs of gerbil ( Meriones hurrianae ) and rat . Acta Anat. 69 (1) : 25 - 34 .
- Dobbs , E. and N. Ross ( 1961 ) . The new local anaesthetic Carbocaine. N.Y. State Dental J., 27 : 453 .
- Dutt , R.H.; R.S. Sand and B. Singh , 1977 . Changes in testes blood flow , the spermatic artery and prostaglandin F content in the testis tissue of heat-stressed rams . Int. J. Biometeorol. 21 (1) : 75 - 84 .
- Dyn , M. and Y. Clermont , 1970 . Role of spermatogonia in the repair of the seminiferous epithelium following X-irradiation of the rat testis . Am. J. Anat. 128 : 265 - 277 .
- and W. Fawcett , 1970 . The blood-testis barrier in the rat and the physiological compartmentation of the seminiferous epithelium . Biology of Reproduction 3 : 308 - 326 .
- Edwards , R.C. and J.L. Sirlin , 1958 . The effect of 200r of X-rays on the rate of spermatogenesis and spermiogenesis in the mouse . Exp. Cell Res., 15 : 522 - 528 .
- Ekenstam , B. ; B. Egner and G. Petterson , 1956 . Trials with Carbocaine. Brit. J. Anaesthesia , 28 : 503 .
- Elfving , G. , 1950 . Effects of the local application of heat on the physiology of the testis . Thesis . Helsinki .
- Engberg , H., 1948 . Testis endokrine funktion und kryptorchismus . Kobenhavn : Ejnar Munksgaard .
- Eriasson , G.L. and J.P. Bennett , 1971 . Mechanism of antifertility activity of minimal effective dose levels of  $\alpha$ - chlorhydrin in the male rat . Abstract Biol. Reprod. 5 : 98 .
- Eriasson , R.J. ; R.H. Dutt and J.W. Archdeacon , 1964 . Progesterone and 6-chloro-6,17 acetoxypregesterone as inhibitors of spermatogenesis in the rabbit . Nature , 204 : 261 - 263 .
- and ————— , 1965 . Progesterone and 6  $\alpha$ -methyl 17 - hydroxypregesterone acetate as inhibitors of spermatogenesis and accessory gland function in the ram . Endocrinology , 77 : 203 - 208 .
- and N.D. Connor , 1969 . Lesions of the rat epididymis and subsequent sterility produced by U-5897 ( 3-chloro-1,2-propanediol ) . Proc. 2nd Meet. Soc. study of Reproduction. Abstract , p.25 .

- Eriossou , R.J. and V.F. Baker , 1970 . Male antifertility compounds : biological properties of U-5897 and U-15646 . J. Reprod. Fert. 21 : 267 - 273 .
- \_\_\_\_\_ and G.A. Youngdale , 1970 . Male antifertility compounds : structure and activity relationship of U-5897 , U-15646 and related substances . J. Reprod. Fert. 21 : 263 - 266 .
- Fawcett , D.W., 1975 . Ultrastructure and function of the Sertoli cell. In: Handbook of physiology , Vol.V. Male reproductive system . R.O.Greep and E.B.Astwood , eds. American physiological Society , Washington , pp. 21 - 55 .
- \_\_\_\_\_ ; W.B. Neaves and M.N. Flores , 1973 . Comparative observations on intertubular lymphatics and organization of the interstitial tissue of the mammalian testis . Biol. Reprod., 9 : 500 - 532 .
- Flickinger , C.J., 1972 b . Ultrastructure of the rat testis after vasectomy . Anat. Rec. 174 (4) : 477 - 494 .
- \_\_\_\_\_ , 1977 a . The influence of progestin and androgen on the fine structure of the male reproductive tract of the rat . I. General effects and observations on the testis . Anat. Rec. 187 : 405 - 430 .
- \_\_\_\_\_ , 1977 b . The influence of progestin and androgen on the fine structure of the male reproductive tract of the rat . II. Epididymis and sex accessory glands . Anat. Rec., 187 : 431 - 462 .
- \_\_\_\_\_ and C.K. Loving , 1976 . Fine structure of the testis and epididymis of rat treated with cyproterone acetate . Am. J. Anat. 146(4) : 359 - 384 .
- Ford , E. and C. Huggins , 1963 . Selective destruction in testis induced by 7 , 12-dimethylbenz( $\alpha$ ) anthracene . J.exp.Med. 118 : 27 - 40 .
- \_\_\_\_\_ and \_\_\_\_\_ , 1964 . Aromatic protection against toxic effects of 7 , 12-dimethylbenz( $\alpha$ )anthracene . Proc. Amer. Ass. Cancer Res. 5 : Abst.73 .
- Frederic , J. and M. Chevremont , 1952 . Research on chondriosomes of living ceus by means of phase contrast microscopy and microcinematography . Ibid. 63 : 109 .

- Freeman , C. and D.S. Coffey , 1973 . Sterility in male animals induced by injection of chemical agents into the vas deferens . Fertil. and Steril. 24 : 884 - 890 .
- Frick , J., 1973 . Control of spermatogenesis in man by combined administration of progestin and androgen . Contraception , 8 : 191-206 .
- Fukui , N., 1923 a . On a hitherto unknown action of heat ray on testicles . Jap. Med. World , 3 : 27 - 28 .
- , 1923 b . Action of body temperature on the testicle . Jap. Med. World , 3 : 160 - 163 .
- Gansler , H., 1956 . Proc. of the Stockholm conference on Electron Microscopy . Stockholm . Almqvist and Wiksell , p. 190 .
- Gardner , P.J. and E.A. Holyoke , 1964 . The fine structure of the seminiferous tubules of the swiss mouse ; I. The limiting membrane, Sertoli cells , Spermatogonia and Spermatoocytes . Anat. Rec. 150 : 391 - 404 .
- Gillet , P.J. and P. Laporte , 1973 . The effects of busulphan and FSH on the seminiferous tubules of the rat ; morphological and cell cell changes . Archives d'Anatomie microscopique 62(4): 385 - 398 .
- Girod , C. and A. Chauvineau , 1964 . Further investigation on the influence of cadmium chloride on the testicle of the monkey Macacus irus . F. Cuv. Comp. rend. Soc.Biol. 158 : 2113 - 2119 .
- Gunn , S.A. ; T.C. Gould and W.A.D. Anderson , 1961 . Competition of cadmium for zinc in rat testes and dorsolateral prostate . Acta endocr., Copenhagen 37 : 24 - 30 .
- ; ————— and ————— , 1963 b . The selective injurious response of testicular and epididymal blood vessels to cadmium and its prevention by zinc . Amer. J. Path. 42 : 685 - 702 .
- and ————— , 1970 . Specificity of the vascular system of the male reproductive tract . J. Reprod. Fert., suppl. 10 , pp.75 - 95 .
- Gupta , R.K. ; G.W. Barnes and F.R. Skelton , 1967 . Light microscopic and immuno-pathologic observations on cadmium-induced injury in mature rat testis . Am. J. Path. 51 : 191 .
- Haddy , F.J. , 1958 . Effect of histamine upon large and small vessels of the dog forelimb . Circulation , V18 : 732 .

- Haddy , F.J. ; P. Gerdon and D.A. Emanuel , 1959 . The influence of tone upon responses of small and large vessels to serotonin . *Circulation Res.*, 7 : 123 - 132 .
- Hanes , F.M. and J. Rosenbloom , 1911 b . A histological and chemical study of the fatty matter of normal and cryptorchid testes . *J. exp. Med.* 13 : 355 - 364 .
- and G.W. Hooker , 1937 . Hormone production in the undescended testis . *Proc. soc. exp. Biol.*, N.Y., 35 : 549 - 550 .
- Hansson , E. ; P. Hoffmann and L. Kristerson , 1965 . Fate of Mepivacaine in the body : II. Excretion and biotransformation . *Acta Pharmacol. Toxicol.*, 22 : 213 - 223 .
- Heinert , G. and H.D. Taubert , 1973 . Effect of cyproterone and cyproterone acetate on testicular function in the rat : A karyometric study . *Endokrinologie* , 61 : 168 - 178 .
- Hemsworth , B.N. and H. Jackson , 1962 . Effect of Busulfan on the foetal gonad . *Nature ( London )* , 195 : 816 .
- Henn , F. , 1960 . Determination of the toxicological and pharmacological properties of Carbocaine , Lidocaine and Procaine by means of simultaneous experiments . *Acta anaesth. scandinav.* 4 : 125 .
- Hiatt , W. , 1961 . Local anaesthesia : History ; Potential toxicity ; Clinical investigation of Mepivacaine . *Dental clin.N.Am.*, 243 - 256 .
- Hoffer , A.P. ; D.W. Hamilton and D.W. Fawcett , 1973 . The ultrastructural pathology of the rat epididymis after administration of  $\alpha$ - chlorhydrin ( U-5897 ) I. Effects of a single high dose . *Anst. Rec.* 175 : 203 - 230 .
- Hu , C. K. and C. N. Frazier , 1941 . Atrophy of germinal epithelium of the rabbits testis induced by Roentgen rays. *Proc. Soc. exp. Biol.*, N.Y., 48 : 44 - 48 .
- Hughes , A.M. and M. Calvin , 1958 . Production of sterility in mice by deuterium oxide . *Science* , 127 : 1445 - 1446 .
- ; E.L. Bennett and M. Calvin , 1959 . Production of sterility in mice by deuterium oxide . *Proc. nat. Acad. Sci.*, Wash., 45 : 581 - 586 .
- and L.E. Glass , 1965 . Histological investigation of the mechanism of sterility induced by deuterium oxide in mice . *Nature ( London )* , 203 : 1119 - 1120 .

- Hugon , J. and M. Borgers , 1966 . Ultrastructural and cytochemical changes in spermatogonia and Sertoli cells of whole body irradiated mice . Anat. Rec. , 155 : 15 - 19 .
- Idanpaan-Heikkila , P. , 1966 . Effect of local heat in vivo on the structure of the basement membrane and the Sertoli cells of the rat testis . Fertil. Steril. , 17(5) : 689 .
- Jones , E. A. , 1960 . Number of spermatogonia after X-irradiation of the adult rat . Int. J. Rad. Biol. , 2 : 157 - 170 .
- Johnson , A.D. , 1970 . Testicular lipids . In: the testis II. Biochemistry Eds. A.D.Johnson ; W.R.Gomes and N.L.van Demark , Academic press , New york .
- Johnson , L.A. and V.G. Purves , 1972 . Reversible infertility in male swine fed  $\alpha$ -chlorhydrin . J. Anim. Sci. 34 : 241 - 245 .
- Johnston , R.L. , 1934 . Studies in the physiology of the prostate gland. Endocrinology , 18 : 123 - 141 .
- Jorfeldt , L. ; B. Lofstrom ; B. Pernow and J. Wahren , 1970 . The effect of Mepivacaine and Lidocaine on forearm resistance and capacitance vessels in man . Acta anaesth. Scand. , 14 ; 183 - 201 .
- Junkmann , K. and F. Neumann , 1964 . Mechanism of action of progestagens having an antimasculine effect on fetuses . Acta endoc. ( Copenhagen ) Suppl. , 90 : 139 - 154 .
- Kadioglu , D. and R.G. Harrison , 1971 . The functional relationship of mitochondria in the rat adrenal cortex . J. Anat. 110 : 283 - 296 .
- Kar , A.B. ; P.R. Dasgupta and R.P. Das , 1961 . Effect of low dose of cadmium on the genital organs and fertility of male rats . J. Sci. Ind. Res. 20 ; 322 .
- ; H. Chandra and V.P. Kamboj , 1965a. Long-term effect of vasectomy on the gonad-pituitary system of rats . Acta biol. med. germ. 15 : 381 .
- ; A.R. Chowdhury ; A. Goswami and V.P. Kamboj , 1965b. Inter-testicular distribution of cadmium in rats . Ind. J. exp. Biol. 3 : 139 - 141 .
- and V.P. Kamboj , 1965 . Cadmium damage of the rat testis and its prevention . Ind. J. exp. Biol. , 3 : 45 - 49 .
- Kaya , M. and R.C. Harrison , 1976 . The ultrastructural relationships between Sertoli cells and spermatogenic cells in the rat . J. Anat. , 121(2) : 279 - 290 .

- Kerr , J.B. and D.M DeKretser , 1975 . Cyclic variations in Sertoli cell lipid throughout the spermatogenic cycle in the rat .  
J. Reprod. Fertil., 43 : 1 - 8 .
- Kindred , J.E., 1952 . The histopathologic changes in the testes of rats intravenously injected with nitrogen mustard , tris ( beta-chloroethyl ) amine . J. exper. Zool. 121 : 225-275 .
- Kirion , K.T. ; R. J. Eriesson ; J. A. Ray and A.D. Forbes , 1970 . Male antifertility compounds ; efficacy of U-5897 in primates ( Macaca mulatta ) . J. Reprod. Fert. 21 : 275 - 278 .
- Kormanó , M. ; P. Karhunen and K. Kahanpaa , 1968 . Effect of long-term 5-hydroxytryptamine treatment on the rat testis . Annls Med. exp. Biol. Fenn. 45 : 474 - 478 .
- Kragt , C.L.; K.K. Bergstrom ; K.T. Kirton and S.E. Porteus , 1973 . Male antifertility ; an approach . Contraception , 11 : 91 - 104 .
- Krhdír , J.L. and R.H. Dutt , 1969 . Temporary induction of infertility in rams with an orally administered chlorhydrin . Abstract. J. Anim. Sci. 29 : 193 .
- Kristerson , L. ; P. Hoffmann and E. Hansson , 1965 . Fate of Mepivacaine in the body . I. Whole-body autoradiographic studies of the distribution of C-labelled Mepivacaine in mice . Acta Pharmacol. Toxicol., 22 : 205 - 212 .
- Lacy , D. , 1960 . Light and E.M. and its uses in the study of factors influencing spermatogenesis in the rat . J. Roy. Micr. Soc 79 : 209 - 225 .
- , 1962 . Certain aspects of testis structure and function . Br. med. Bull. 18(3) : 205 - 208 .
- and J. Rotblat , 1960 . Study of normal and irradiated boundary tissue of the seminiferous tubules of the rat . Exp. cell Res., 21 : 49 - 70 .
- and Lofts , 1965 . Studies on the structure and function of the mammalian testis . I. Cytological and histological observations after continuous treatment with oestrogenic hormone and the effects of FSH and LH . Proc. roy. Soc. B., 162 : 188 .
- Landing , B.H. ; A. Goldin and H.A. Noe , 1949 . Testicular lesions in mice following parenteral administration of nitrogen mustards. Cancer , 2 : 1075 - 1081 .

- Leblond , B.H. and Y. Clermont , 1952 . Definition of the stages of the cycle of the seminiferous epithelium in the rat . Ann. N. Y. Acad. Sci., 55 : 548 - 573 .
- Lee , H.Y., 1967 . Studies on vasectomy , IV. Experimental studies on biological , histologic and histochemical effects of vasectomy. J. Korean med. Ass. 10 : 893 .
- Luduenz , F.P. ; J.O. Hoppe ; F. Coulston and H.P. Drobeck , 1960 . The pharmacology and toxicology of Mepivacaine , a new local anaesthetic . Toxicol. Appl. pharmacol. 2 : 295 - 315 .
- Lynch , K.M. and W.W. Scott , 1951 . Lipid distribution in the Sertoli cell and Leydig cell of the rat testis as related to experimental alterations of the pituitary-gonad system . Endocrinology 49 : 8 - 14 .
- Majno , G. and G.E. Palade , 1961 . Studies on inflammation . I. The effect of histamine and serotonin on vascular permeability ; An Electron microscopic study . J. Biophysic. Biochem. Cytol., 11 : 571 - 605 .
- ; ----- and G.I. Schoefl , 1961 . Studies on inflammation . II. The site of Action of histamine and serotonin along the vascular tree ; A topographic study . J. Biophysic. Biochem. Cytol., 11 : 607 .
- Malaviya , B. ; H. Chandra and A.B. Kar , 1974 . Chemical occlusion of vas by quinaerine in Rhesus monkeys . Ind. J. exp. Biol. 12 : 560 - 561 .
- Markewitz , M.R. ; J. Veenema ; B. Fingerhut ; D. Nehma-Bdily and S.C. Sommers , 1969 . Cyproterone acetate effects on histology and nucleic acid synthesis in the testes of patients with prostatic carcinoma . Invest. Urol., 6 : 638 - 649 .
- Meek , E.S. , 1959 . Cellular changes induced by cadmium in mouse testes and liver . Brit. J. exp. path. 40 : 503 - 506 .
- du Mesnil de Rochemont , W. and H. Hensel , 1960 . Messung der Hautdurchblutung am Menschen bei Einwirkung verschiedener Lokalanesthetica . Arch. exp. path. pharmakol., 239 : 464 - 474 .
- Mietkiewski , K., and A. Lukaszuk , 1969 . The response of the rat testis to prolonged administration of an androgen antagonist ( Cyproterone ) . Acta Endocrinol., 60 : 561 - 570 .
- Miller , M.J. ; M.P. Fischer ; P.V. Elcoate and C.A. Mawson , 1958 . The effects of dietary zinc deficiency on reproductive cycle of male rats . Canad. J. Biochem. 36 : 557 - 569 .

- Mirskaja , L. and F.A.E. Crew , 1931 . The effect of destruction of the spermatogenic tissue by X-rays upon certain secondary gonadic characters of the cock . *Quart. J. exp. physiol.* 21 : 135 - 138 .
- Moens , P.B. and Go , 1971 . Intercellular bridges and division patterns of rat spermatogonia . *Z. Zellforsch. mikrosk. Anat.* 127 : 201 - 208 .
- Momigliano , E. and J.M.Essenberg , 1944 . Regenerative processes induced by gonadotropic hormones in irradiated testes of the albino rat . *Radiology* , 42 : 273 - 283 .
- Montagna , W., 1952 . Some cytochemical observations on human testes and epididymides. *Ann. N. Y. Acad. Sci.*, 55 : 629 - 642 .
- Moore , C.R., 1924 . Properties of the gonads as controllers of somatic and psychical characteristics . VI. Testicular reactions in experimental cryptorchidism . *Am. J. Anat.* 34 : 269 .
- , 1945 . Hormone secretion by experimental cryptorchid testes. *Yale J. Biol. Med.* 17 : 203 - 216 .
- and R. Oslund , 1923 . Experiments on the sheep testis - cryptorchidism , vasectomy and scrotal insulation . *Amer. J. physiol.* 67 : 595 .
- Morse , H.C. ; D.R. Leach ; M.J. Rowley and G.G. Heller , 1973 . Effect of cyproterone acetate on sperm concentration , seminal fluid , testicular cytology and levels of plasma and urinary ICSH , FSH , and testosterone in normal men . *J. Reprod. Fertil.*, 32 : 365 - 378 .
- Neaves , W.B. , 1974 . The rat testis after vasectomy . *J. Reprod. Fertil.* 40(1) : 39 - 44 .
- , 1975 . Leydig cells . *Contraception* , 11 : 571 - 606 .
- Nebel , B.R. ; C.J. Murphy and H.J. Linder , 1960 . Autoradiographic study with tritiated thymidine of mouse testis after 320r and after 1000r of acute localized X-irradiation . *Rad. Res.*, 13 : 126 - 136 .
- Nelson , W.O. and E. Steinberger , 1953 . Effect of nitrofurran compounds on the testis of the rat. *Amer. physiol. Soc.* p. 103 .
- Neumann , F., 1966 . Methods for evaluating antisexual hormones . In : *Methods in drug evaluation* . P. Mantegazza and F. Piccinini , eds. North Holland , Amsterdam , pp. 548 - 573 .
- , 1971 . Use of cyproterone acetate in animal and clinical trials . *Gynae. Invest.*, 2 : 150 - 179 .

Neumann , F. and R. von Berswordt-Wallrabe , 1966 . Effects of androgen antagonist cyproterone acetate on the testicular structure , spermatogenesis and accessory sexual glands of testosterone-treated adult hypophysectomized rats . J. Endocrinol., 35 : 363 - 371 .

\_\_\_\_\_ ; \_\_\_\_\_ ; S. Elger and H. Steinbeck , 1968 . Activities of antiandrogens . Experiments in prepuberal and puberal animals and in fetuses . In : Testosterone . J. Tamm , ed. Hafner , New York , pp. 134 - 143 .

\_\_\_\_\_ ; \_\_\_\_\_ ; \_\_\_\_\_ ; \_\_\_\_\_ and J.D. Hahn , 1969 . Effects of anti-androgens . Excerpta Med. Int. Cong. Ser., 184 : 823 - 836 .

\_\_\_\_\_ ; \_\_\_\_\_ ; \_\_\_\_\_ ; \_\_\_\_\_ ; \_\_\_\_\_ J.D. Hahn and M. Kramer , 1970 . Aspects of androgen-dependent events as studied by antiandrogens . Recent Prog. Hormone Res., 26 : 336 - 410 .

Nishida , T. , 1954 . Cytoplasmic cytology of the Sertoli cells of mammals. Cytologia 19 : 203 - 216 .

Nordqvist , P., K.G. Dhuner , 1961 . Influence of local anaesthetics with vasoconstrictors upon circulation and metabolism . Acta anaesth. Scandinav., 5 : 63 .

Garbuz , E.P., 1955 a . Sensitivity and time of degeneration of spermatogenic cells irradiated in various stages of maturation in the mouse . Radiation Res., 2 : 369 - 391 .

\_\_\_\_\_ , 1955 b . Degeneration of spermatogonia of the mouse following exposure to X-rays , and stages in the mitotic cycle at which cell death occurs . J. Morphol., 97 : 39 - 54 .

\_\_\_\_\_ , 1956 a . A description of spermiogenesis in the mouse and its use in the analysis of the cycle of the seminiferous epithelium and germ cell renewal . Am. J. Anat., 99 : 391 - 409 .

\_\_\_\_\_ , 1956 b . Duration of spermiogenesis in the mouse and timing of stages of the cycle of the seminiferous epithelium. Am. J. Anat. , 99 : 507 - 516 .

- Oakberg , E.F., 1959 . Initial depletion and subsequent recovery of spermatogonia of the mouse after 20r of gamma rays and 100 , 300 , and 600 r of X-rays . Rad. Res., 11 : 700 - 719 .
- , 1964 . The effects of dose , dose rate and quality of radiation on the dynamics and survival of the spermatogonial population of the mouse . In : Mechanisms of the dose rate effect of radiation at the genetic and cellular levels .
- and R.L. Dimmo , 1960 . X-ray sensitivity of primary spermatocytes of the mouse . Int. J. Rad. Biol., 2 : 196 - 209 .
- Oettle , A.G. and R.G. Harrison , 1952 . The histological changes produced in the rat testis by temporary and permanent occlusion of the testicular artery . J. Path. Bact. 64 : 273 - 297 .
- O'Steen , W.K., 1963 . Serotonin and histamine : Effects of a single injection on the mouse testis and prostate gland . Proc. Soc. exp. Biol. Med. 113 : 161 - 163 .
- Pace , J.M. and H. Cabot , 1936 . A histological study in twenty-four cases of retained testes in the adult . Surg. Gynec. Obstet. 63 : 16 - 22 .
- Palade , G.E. , 1952 a . The fine structure of mitochondria . Anat. Rec. 114 : 427 - 453 .
- Parizek , J. , 1960 . Sterilisation of the male by cadmium salts . J. Reprod. Fertil. 1 : 294 - 309 .
- and Z. Zaher , 1956 . Effect of cadmium salts on testicular tissue . Nature , Lond. 177 : 1036 .
- Parvinen , M., 1973 . Observations on freshly isolated and accurately identified spermatogenic cells of the rat . Early effects of heat and short-time experimental cryptorchidism . Virchows Arch. Zell Path. 13 : 38 .
- Pohto , M. and A. Scheinin , 1960 . Effect of local anaesthetic solutions on the circulation of the pulp in the rat incisor . Bibliotheca Anat., 1 : 46 .
- Posalaki , Z. ; D. Szabo ; E. Bacsi and I. Okros , 1968 . Hydrolytic enzymes during spermatogenesis in rat . An electron microscopic and histochemical study . J. Histochem. Cytochem. 16 : 249 - 262 .
- Reddy , J.K. and D. J. Svoboda , 1967 . Peroxidase transport by Sertoli cells of the treated rat testis . J. cell Biol. 35 : 184 .

- Robbins , S.L., 1974 . The pathologic basis of disease . Saunders , Philadelphia , pp. 32 - 36 .
- Roosen-Runge , E.C. and L.O. Giesel , 1950 . Quantitative studies on spermatogenesis in the albino rat . Am. J. Anat. 87 : 1-30 .
- \_\_\_\_\_ and J. Leik , 1968 . Gonocyte degeneration in the postnatal male rat. Am. J. Anat., 122 : 275 - 300 .
- Rumke , P. and M. Titus , 1970 . Spermagglutinin formation in male rats by subcutaneously injected syngeneic epididymal spermatozoa and by vasoligation or vasectomy . J. Reprod. Fert. 21 : 69 .
- Russell , I.D. and Y. Clermont , 1977 . Degeneration of germ cells in normal , hypophysectomized and hormone treated hypophysectomized rats . Anat. Rec. 187 : 347 .
- Sackler , A.M. ; A.S. Weltman ; V. Pandhi and R. Schwartz , 1973 . Gonadal effects of vasectomy and vasoligation . Science , N. Y. 179 : 293 .
- Sand , K. , 1921 . Etudes experimentales sur les glandes sexuelles chez les mammiferes . J. Physiol. Path. Gen. 19 : 515 .
- Schenkman , J.B. ; D.A. Richert and W.W. Westerfield , 1965 .  $\alpha$ -Glycerophosphate dehydrogenase activity in rat spermatozoa . Endocrinology , 76 : 1055 - 1061 .
- Segal , R.J. ; 1972 . Effect of vasoligation of the 14 day old and 21 day old rats on spermatogenesis . Int. J. Fertil. 17 : 33 .
- Segal , S.J. ; 1973 . Male fertility control studies : An editorial comment . Contraception , 8 : 187 - 189 .
- Setchell , B.P. and G.M.H. Waites , 1964 . Blood flow and the uptake of glucose and oxygen in the testis and epididymis of the ram. J. Physiol. 17 : 411 - 425 .
- Setty , B.S. ; P.R. Dasgupta and A.B. Kar , 1972 . Chemical occlusion of vas in rats . Contraception , 6 : 329 - 335 .
- Shaver , S.L. , 1953 a . X-radiation injury and repair in the germinal epithelium of male rats . I. Injury and repair in adult rats. Amer. J. Anat. 92 : 391 - 432 .
- Smith , B.V.K. and D. Lacy , 1959 . Residual bodies of seminiferous tubules of the rat . Nature , 184 : 249 - 251 .
- Smith , G. , 1962 . The effects of ligation of the vasa efferentia and vasectomy on testicular function in the adult rat . J. Endocr. 23 : 385 .

- Steinbeck , H. ; M. Mehring and F. Neumann , 1971 . Comparison of the effects of cyproterone , cyproterone acetate and oestradiol on testicular function , accessory sexual glands and fertility in a long-term study on rats . J. Reprod. Fertil., 26 : 65 - 76 .
- Steinberger , E. and W.J. Dixon , 1959 . Some observations on the effect of heat on the testicular germinal epithelium . Fertil. Steril., 10 (6) : 578 - 595 .
- and D.Y. Tjioe , 1969 . Spermatogenesis in rat testes after experimental ischaemia . Fertil. Steril. 20 : 639-649.
- Stieve , H., 1930 . In *Handbuch d. mikroskopischen Anatomie* , 7 (2) , p. 397 . Ed. Mollendorff. Berlin , Springer .
- Suzuki , Y. and H. Yoshikawa , 1971 . Metal shifts in the testes of experimental acute cadmium poisoned rats . Ind. Health 9 (1-2) : 77 - 79 .
- Turner , C. and J. MacLaughlin , 1973 . Effects of sex hormones on germinal cells of the rat testis ; a rationale for the use of progestin and androgen combinations in the control of male fertility. J. Reprod. Fertil., 32 : 453 - 464 .
- Ulfendahl , H.R. , 1957 . Some pharmacological and toxicological properties of a new local anaesthetic ; Carbocaine . Acta anaesth. Scandinav., 1 : 81 - 86 .
- Vilar , O. ; M.I Perez DelCerro and R.E. Mancini , 1962 . The Sertoli cell as a bridge cell between the basal membrane and the germinal cells . Histochemical and electron microscope observation . Expl. Cell Res. 27 : 158 - 161 .
- ; A. Steinberger and E. Steinberger , 1967 . An electron microscopic study of cultured rat testicular fragments . Z. Zellforsch., 78 : 221 - 233 .
- Waites , G.M.H. and B.P. Setchell , 1966 . Changes in blood flow and vascular permeability of the testis , epididymis and accessory reproductive organs of the rat after administration of cadmium chloride . J. Endocr. 34 : 329 - 342 .
- Watson , M. 1952 b. Spermatogenesis in the rat as revealed by tissue sections in the electron microscope . Univ. Rochester Atomic Energy project , Atomic Energy Report , U.R. 185 .Unclassified.
- Whalen , R.E. and W.G. Luttage , 1969 . Contraceptive properties of the anti-androgen cyproterone acetate . Nature , 223 : 633-634 .

- Wiechert , R. and F. Neumann , 1965 . Gestagene wirksamkeit von-1-Methyl- und 1,2 Methylen-Steroiden-Arzneimittel-Forsch., 15 : 244 .
- Witschi , E. ; W.T. Levine and R.T. Hill , 1932 . Endocrine reaction of X-ray sterilized males . Proc. Soc. exp. Biol. , N. Y. , 29 : 1024 - 1026 .
- Williams , W.L. and B. Cunningham , 1940 . Histological changes in the rat testis following heat treatment . Yale J. Biol. and Med., 12 : 309 - 316 .
- Young , W.C. , 1927 . The influence of high temperature on the guinea pig testes ; histological changes and effects on reproduction. J. exp. Zool. 49 : 459 - 499 .

