

Durham E-Theses

The innervation of mammalian skeletal muscle by medium and small diameter afferent nerve fibres

J. Stacey, Michael

How to cite:

Stacey, Michael, J. (1967) The innervation of mammalian skeletal muscle by medium and small diameter afferent nerve fibres. Doctoral thesis, Durham University.

Use policy

The full-text may be used and/or reproduced, and given to third parties in any format or medium, without prior permission or charge, for personal research or study, educational, or not-for-profit purposes provided that:

- a full bibliographic reference is made to the original source
- a <https://etheses.durham.ac.uk/id/eprint/8731/> is made to the metadata record in Durham E-Theses
- the full-text is not changed in any way

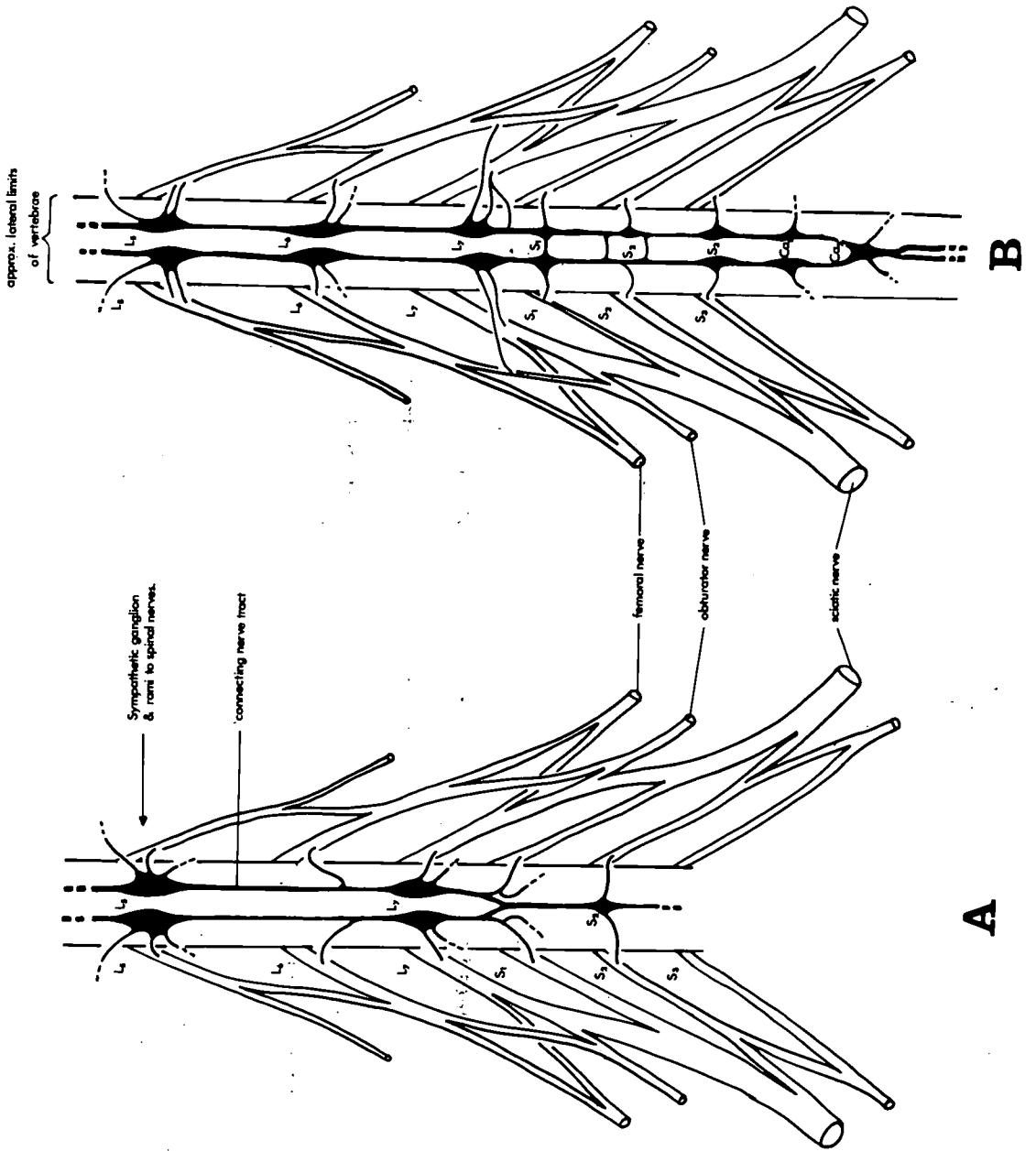
The full-text must not be sold in any format or medium without the formal permission of the copyright holders.

Please consult the [full Durham E-Theses policy](#) for further details.

Figure 1

Two diagrams illustrating the variation in structure of the lumbo-sacral sympathetic chain of the cat.

- a. The connecting nerve tracts between ganglia of succeeding levels are usually bi-lateral in nature, but in this particular animal they are fused at the S1 level, and only a single tract is present between succeeding ganglia caudad of the S1.
- b. Fusion of the paired ganglia usually occurs at the S1 or S2 levels, but in this case it occurs as far caudad as the Cal level.



DURHAM UNIVERSITY
 26 APR 1967

Figure 1 (cont.)

- c. Out of twelve animals four had L7 ganglia which produced two rami, one to the L7 spinal nerve and one to the S1 spinal nerve;
- d. seven possessed two rami only up to the L6 level and,
- e. one animal had two rami from the S2 ganglion. In this instance this ganglion was fused, there was no S1 ganglion, the L7 ganglion produced a single ramus to its equivalent spinal nerve. The L6 ganglion produced two rami, one to its equivalent spinal nerve and one to the preceding spinal nerve.

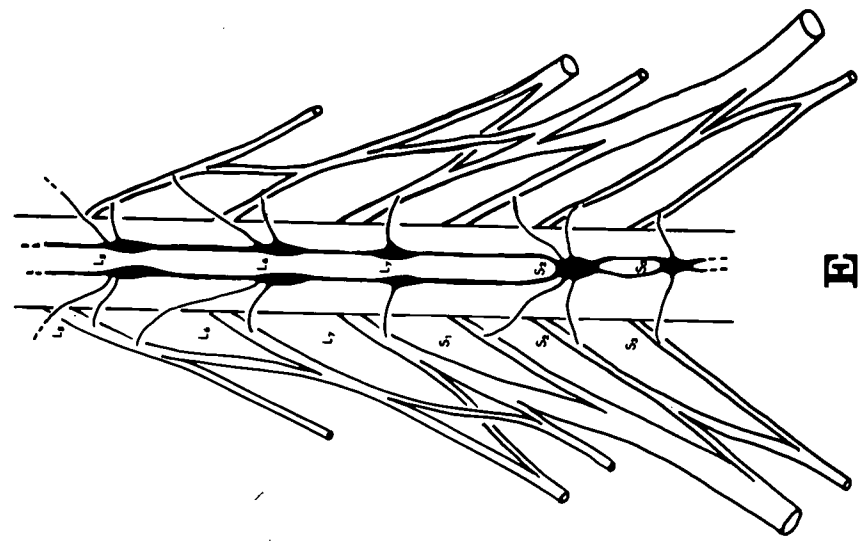
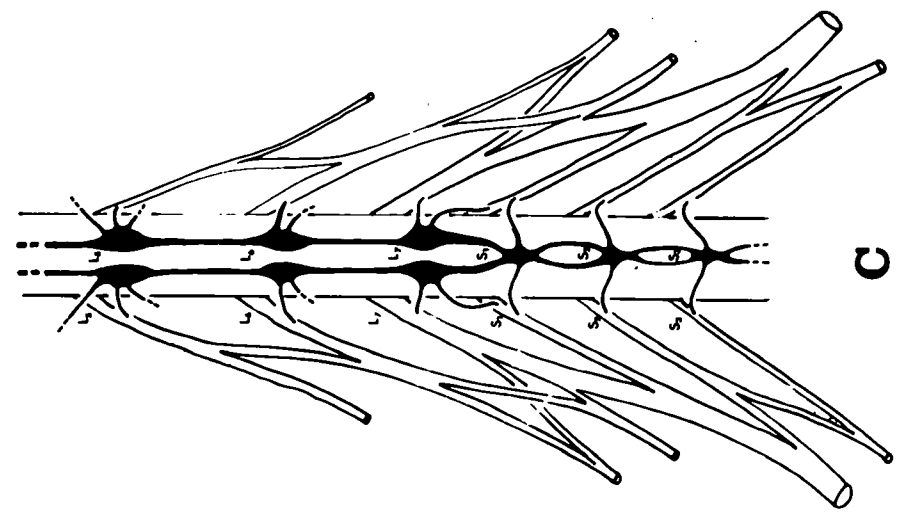
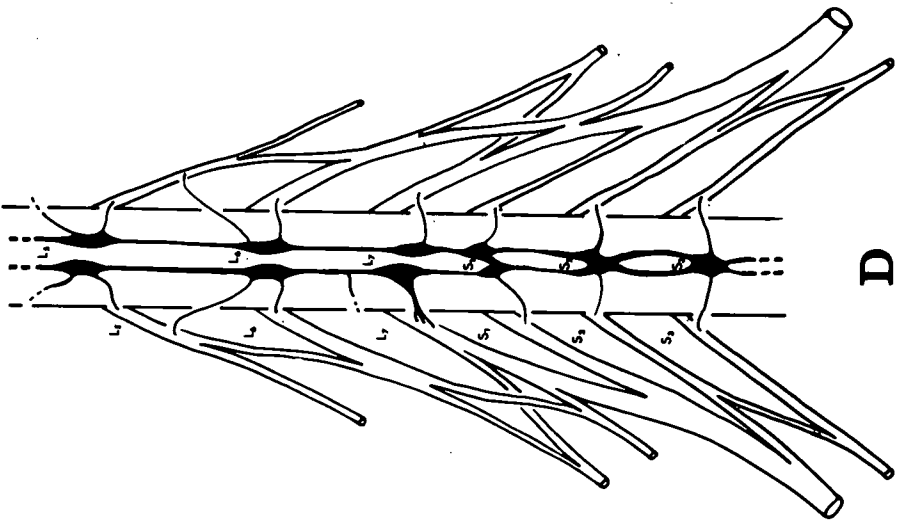


Figure 2

A diagrammatic cross-section through the lower-lumbar
region of the cat

The dotted line represents the path taken for a
retro-peritoneal approach to lumbo-sacral sympathectomy.

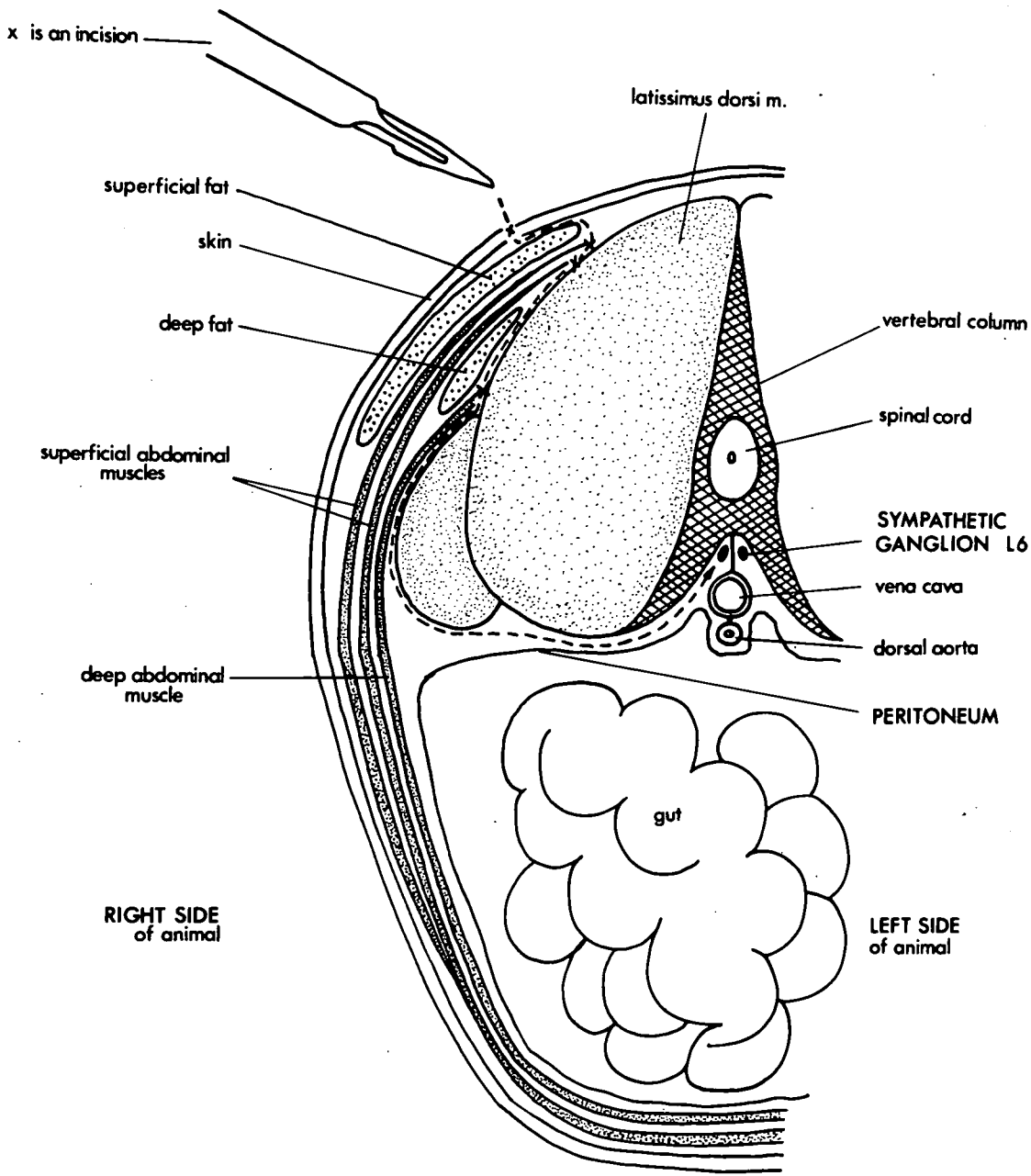


Figure 3a

Diagrammatic cross-section of a lower-lumbar
spinal nerve

The dorsal root ganglion sits in a 'gutter' formed by the ventral root. If root checks are made on longitudinal sections, uncut motor nerve fibres (dotted area) are not recognizable as such unless the roots are sectioned along the plane represented by the line A-B.

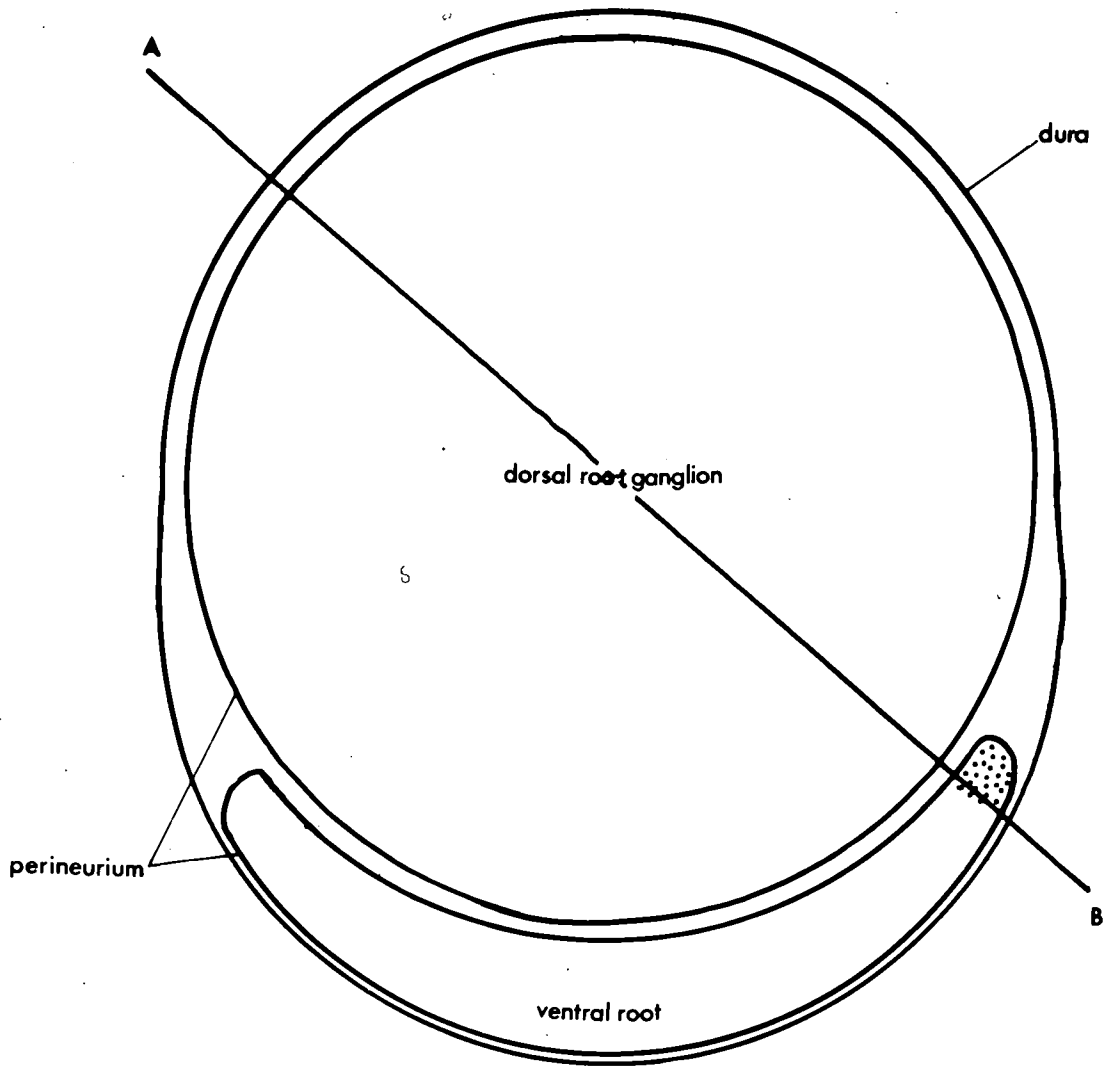
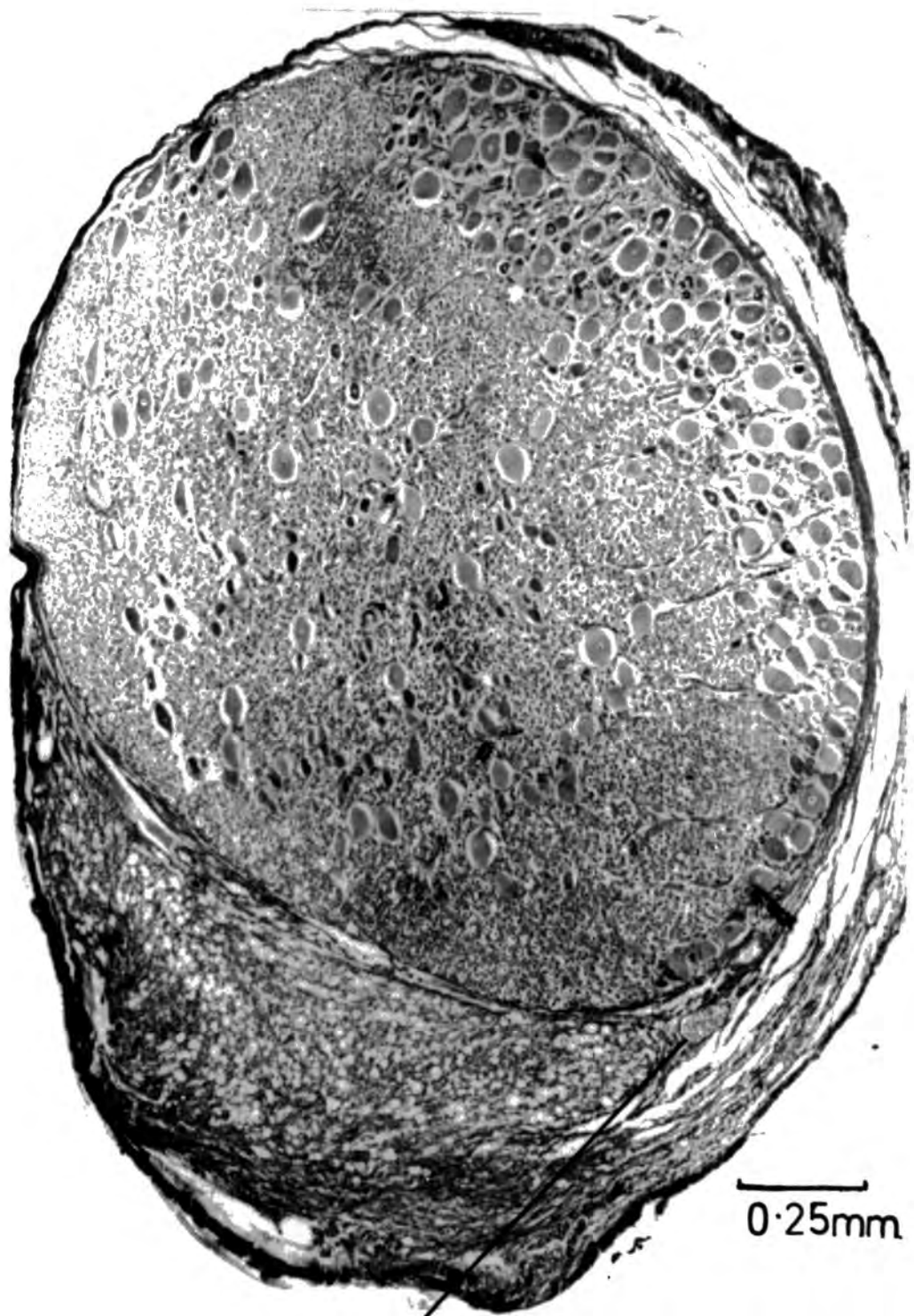


Figure 3b

Transverse section of an L7 spinal nerve of a cat

During laminectomy, a small fascicle of motor nerve fibres was left intact. In transverse section they are clearly seen outside the limits of the dorsal root perineurium (as illustrated in the diagram Fig. 3a). They can be traced throughout the serial sections of the spinal nerve, from the point at which they leave the cord, to the point at which they enter the mixed nerve.

(10 μ section : Holmes silver method)



0.25mm

small fascicle of uncut motor nerve fibres.

Figure 4

Three illustrations of dorsal-root ganglia of the
cat in transverse section

A. Deliberately damaged L7 dorsal-root ganglion (C 201).

The perineurium (peri.) of the dorsal root is broken

and an area of scar tissue (sc.t.) has formed.

Damaged and degenerating afferent nerve fibres

and cell bodies (d. aff.) can be seen within

the scar region.

in. aff. - intact afferent nerve fibres

and cell bodies.

(10 μ section : Holmes silver method)

0.25mm

peri.

sc.t.

d.aff.

in.aff.

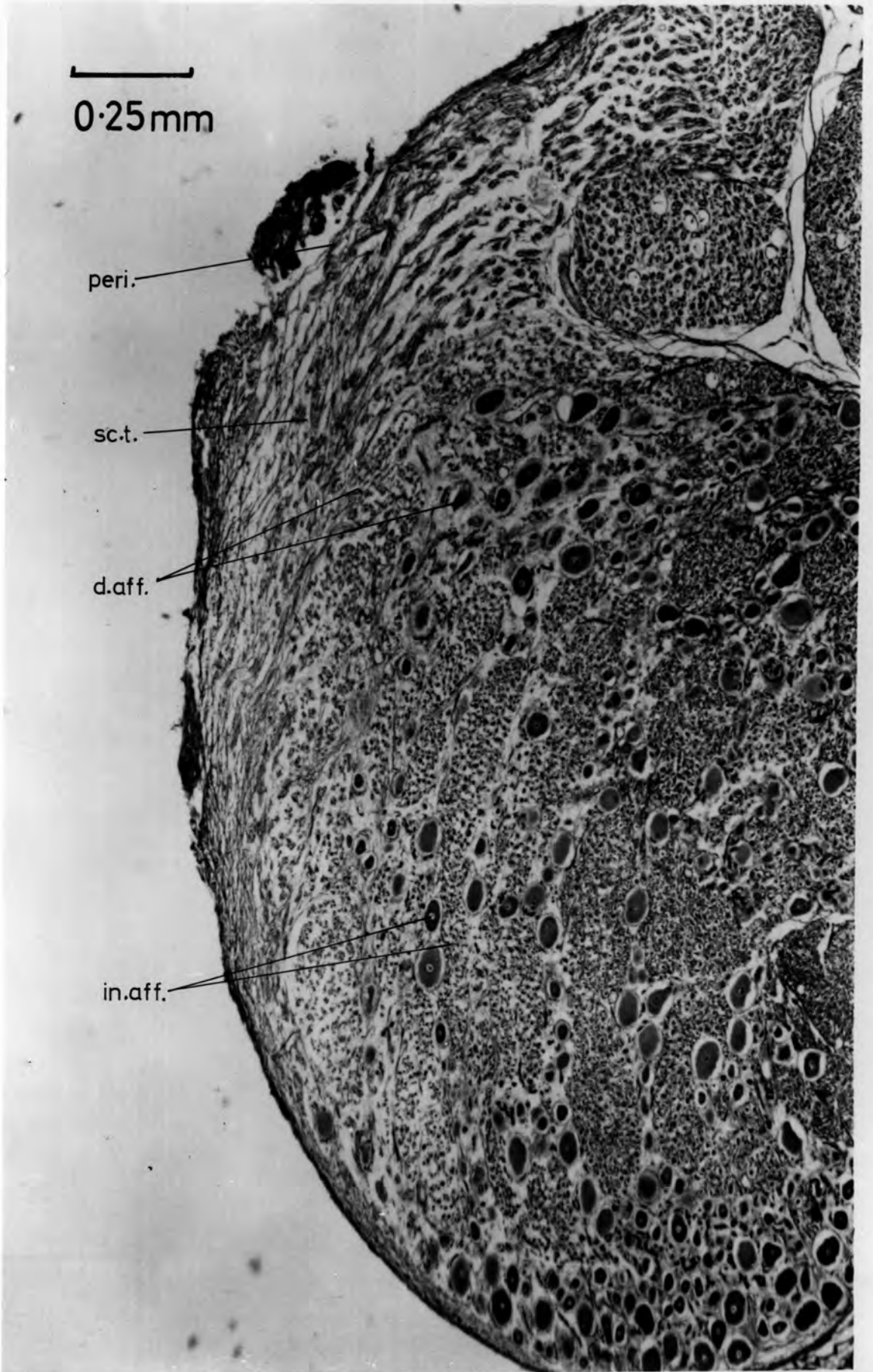
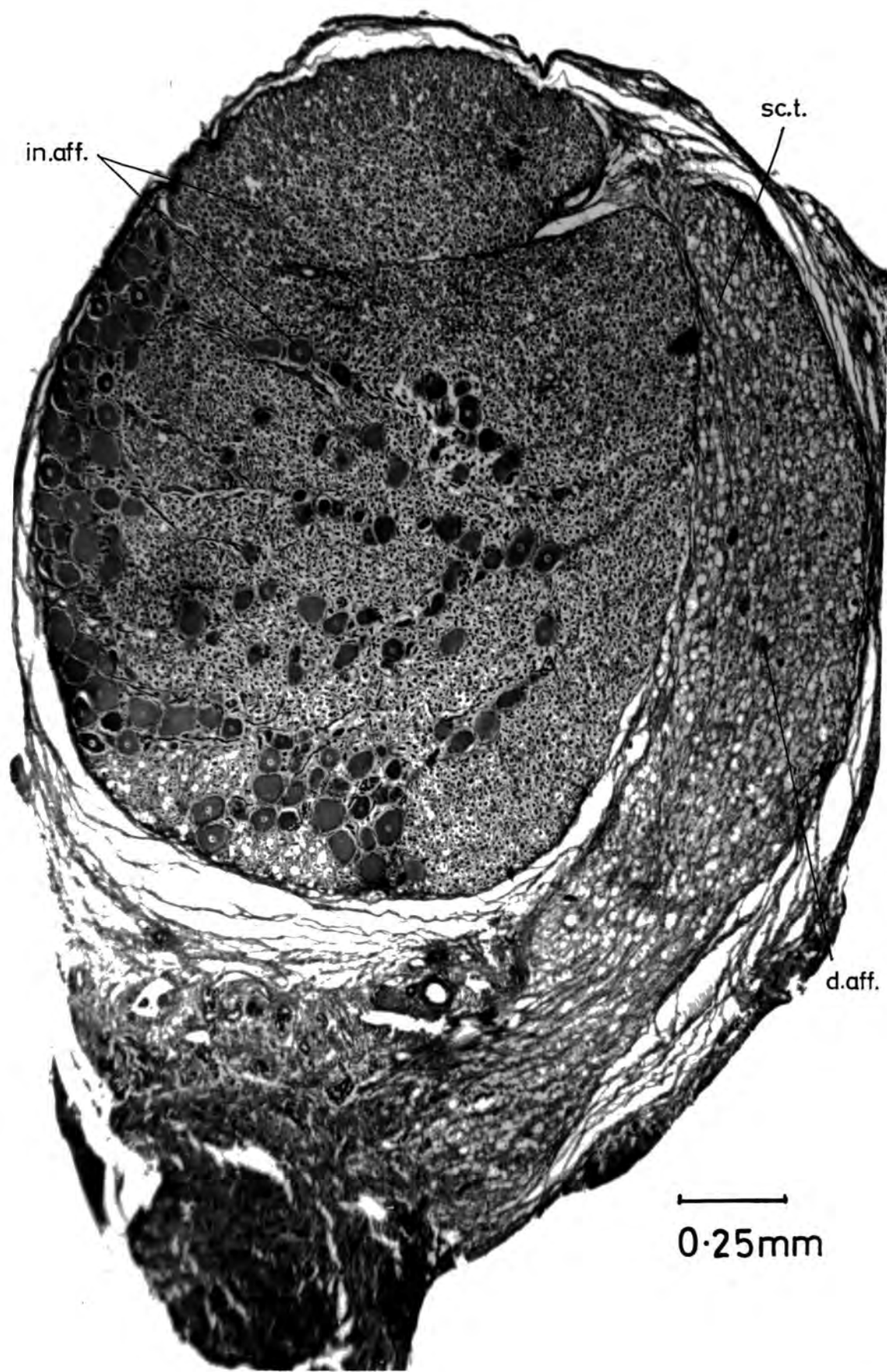


Figure 4 (cont.)

- B. An accidentally damaged S1 dorsal-root ganglion.
Scar tissue (sc.t.) and degenerating afferent
nerve fibres (d. aff.) are present at the edge
of the ganglion.

in. aff. - intact afferent nerve fibres
and cell bodies.

(10 μ section : Holmes silver method)



in.aff.

sc.t.

d.aff.

0.25mm

Figure 4 (cont.)

C. Undamaged dorsal root ganglion. All of the degenerating nerve fibres (d.f.) and scar tissue (sc.t.) are outside of the intact dorsal root perineurium (peri.), and are the result of complete motor root section.

(10 μ section : Holmes silver method)

0.25mm

peri.

sc.t.

df.

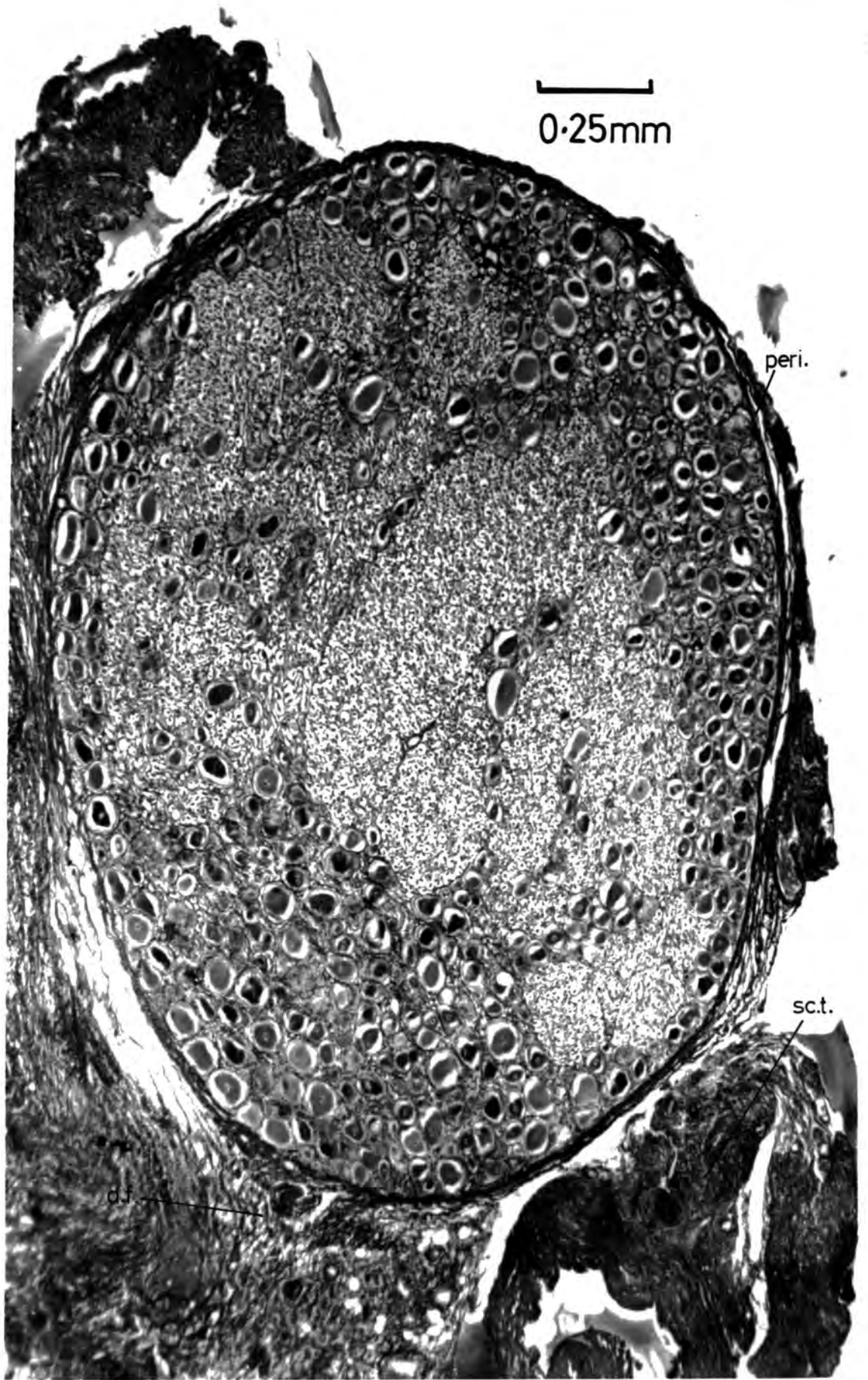
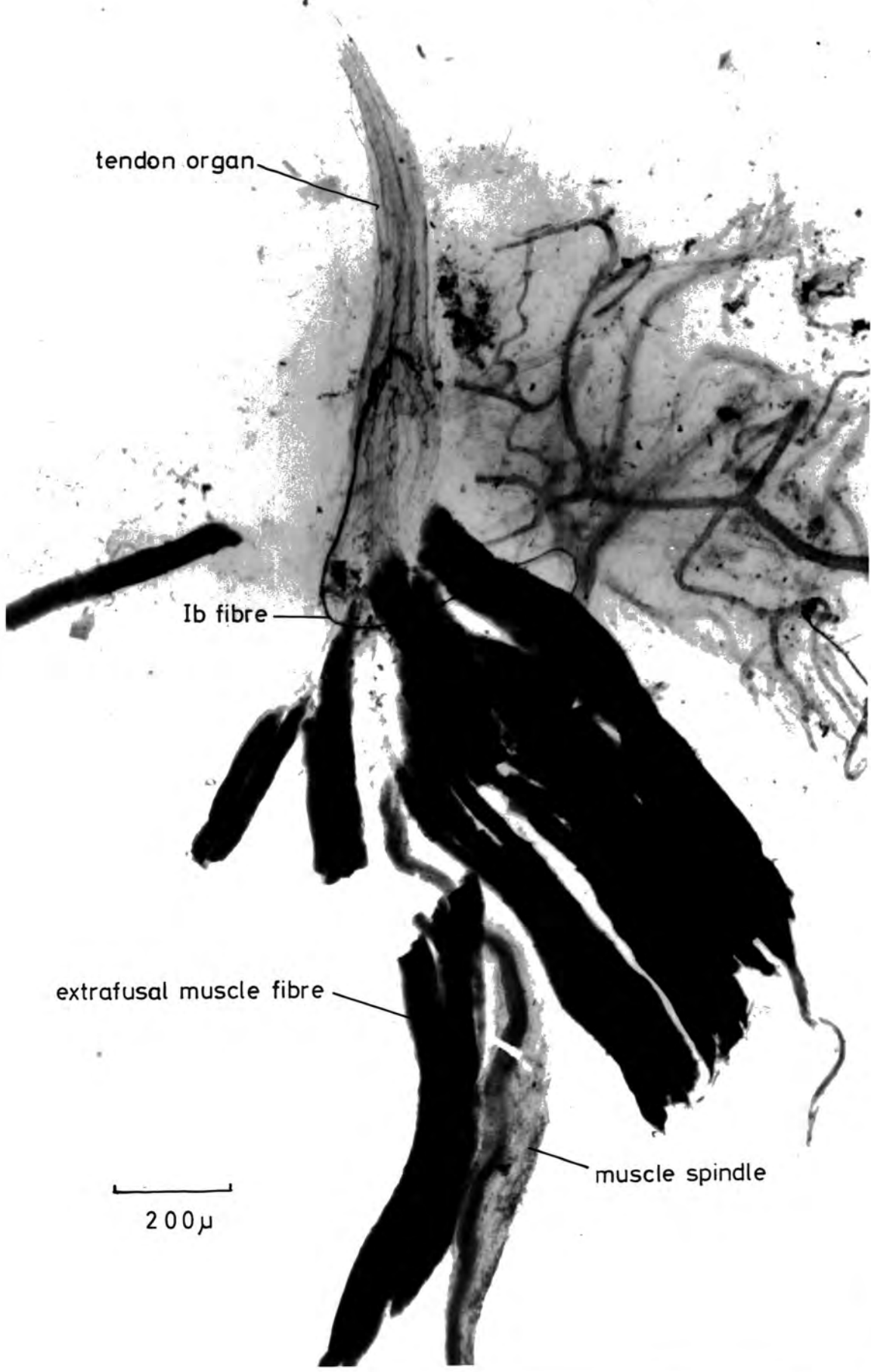
Figure 5

A muscle spindle without any nerve fibre innervation

As a result of damage during ventral root section to afferent nerve fibre cell bodies present in the ventral root, the muscle spindle is totally deprived of any nerve fibre innervation. This was the only example found in this muscle (tibialis posterior C213) of total denervation of a proprioceptor. The tendon organ is supplied by a Ib fibre (C213). De-efferentated and sympathectomized tibialis posterior muscle; modified de Castro impregnation.



tendon organ

Ib fibre

extrafusal muscle fibre

muscle spindle

200 μ

Figure 6

Longitudinal section of a normal spinal nerve illustrating afferent nerve-fibre cell bodies in the ventral root.

d.r.g. - dorsal root ganglion
v.r. - ventral root
m.n. - mixed nerve
sep. - root separation
aff.c.b. - afferent nerve fibre cell bodies

Although only six afferent nerve-fibre cell bodies are visible in the ventral root of this section, a total of 98 were counted in the complete series of sections of the ventral root and mixed nerve beyond the point of separation.

(C179) S1 spinal nerve, 10 μ section: Holmes silver method

100μ

d.r.g.

v.f.

sep.

aff.c.b.

m.n.

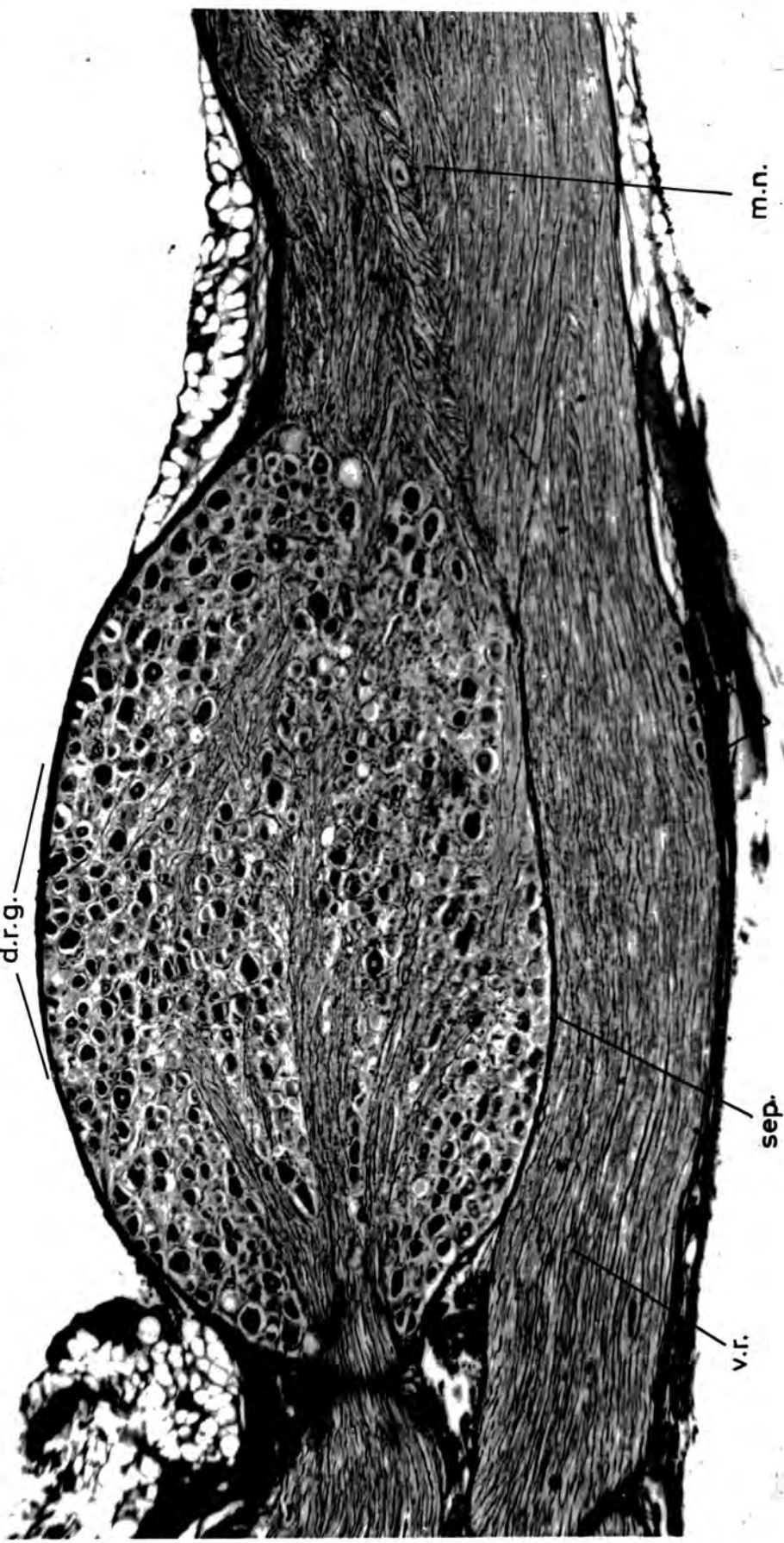

Figure 7

Comparison of nerve-fibre diameter spectra of fusimotor, secondary and primary fibres
(a) impregnated with silver (de Castro technique) and (b) stained with osmic acid

The difference between the equivalent spectra peak values varies. It is 2μ for fusimotor fibres, 4μ for secondary fibres and 2μ for primary fibres.

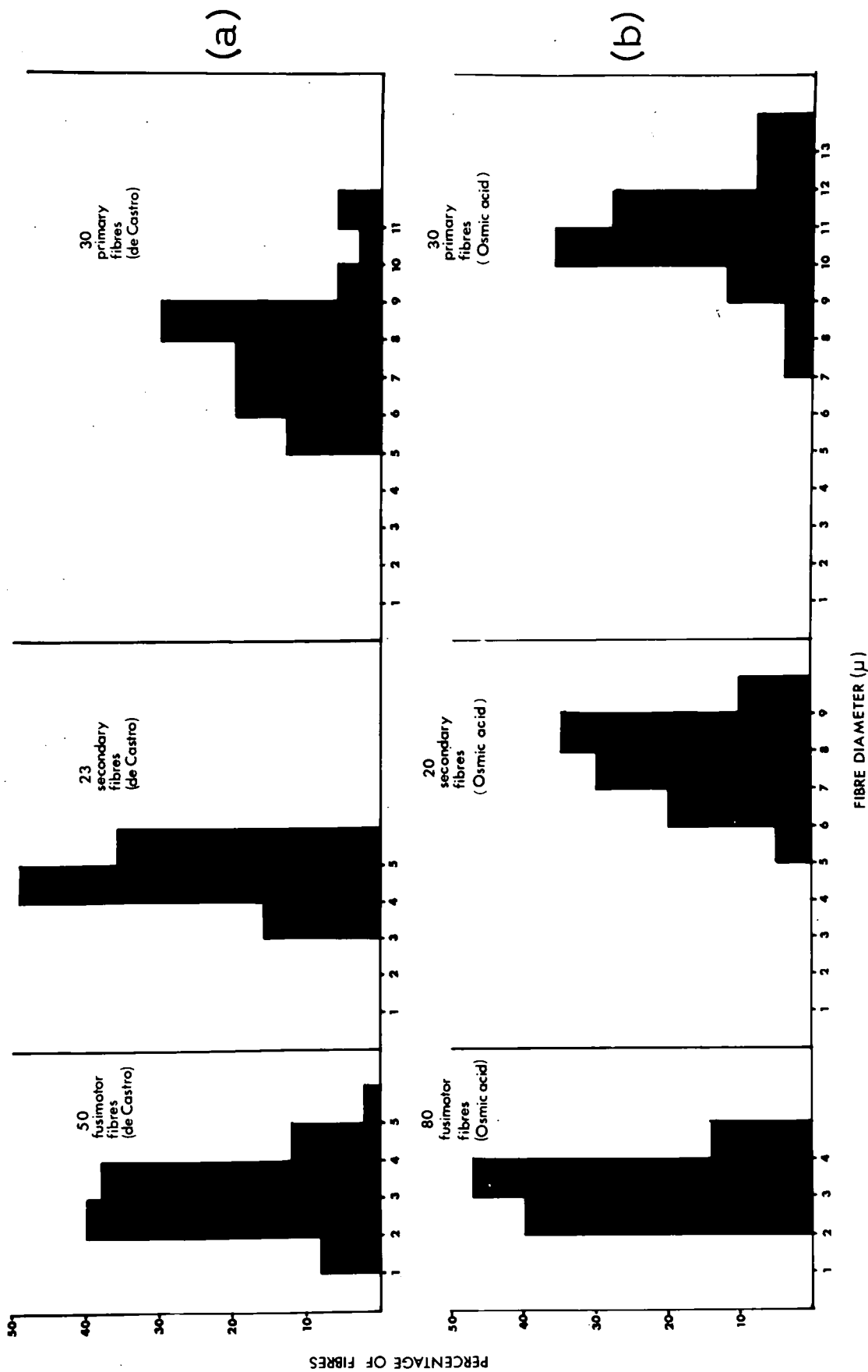


Figure 8

A graphical representation of the conversion of nerve fibre diameters from silver-impregnated material (de Castro technique) to diameters of osmic-acid stained nerves (representative of the fresh-state diameter)

Correlation coefficient (r) = 0.95

Regression of x on y
 $x = 1.5y - 0.11$

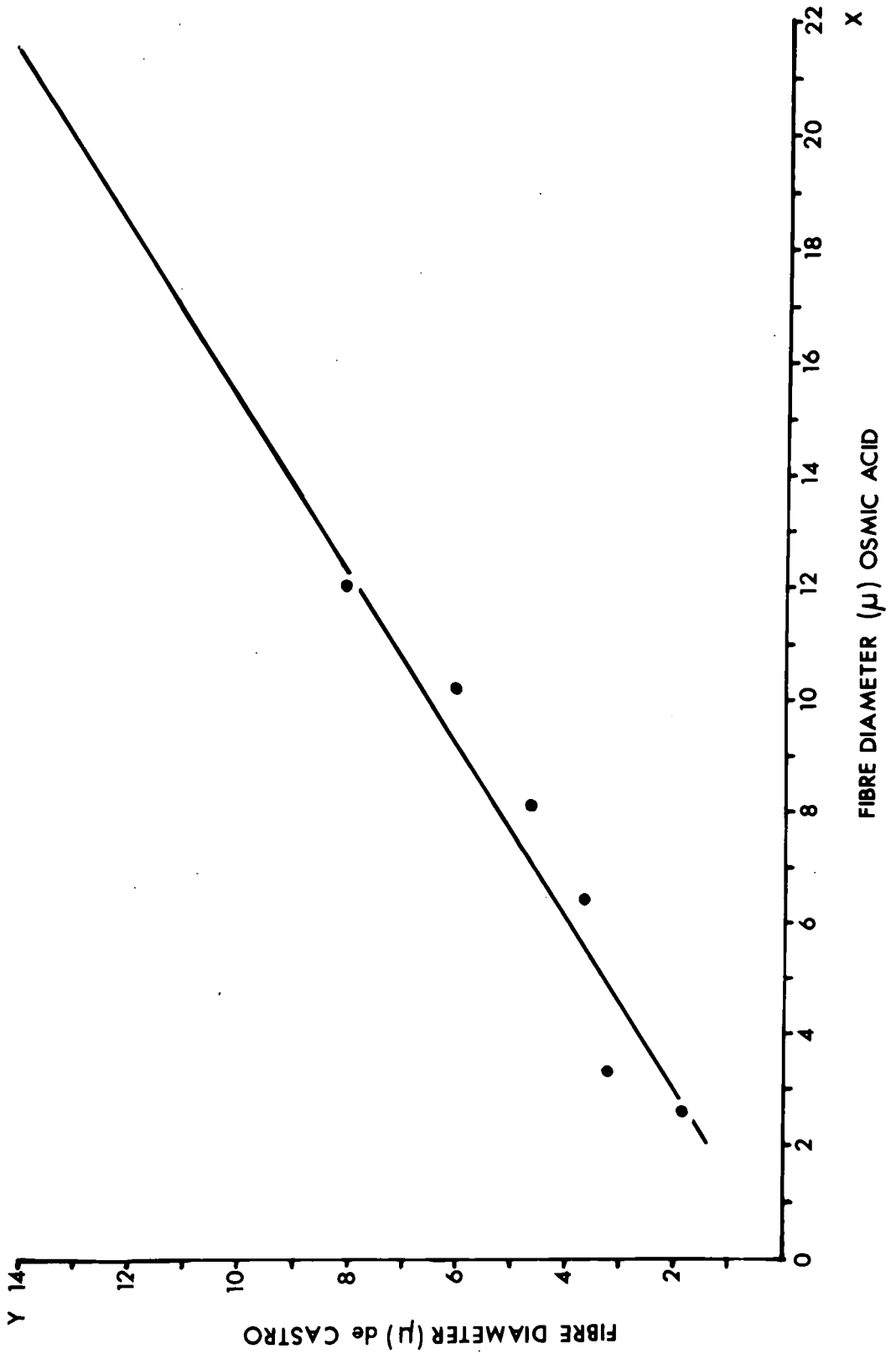


Figure 9

Nerve-fibre diameter spectrum of soleus muscle-nerve (de Castro impregnation)

Total fibre diameter (axon + myelin) measurements, of myelinated nerve fibres only, were made 1 cm prior to nerve entry in a large fascicle of the de-efferentated and sympathectomized soleus muscle-nerve of C.189.

The peak diameter values of each Group are indicated by large numerals. They are equivalent to osmic diameters of 3 μ (Group III), 7.0 μ - 8.5 μ (Group II) and 15.5 μ (Group I). The following comparisons are drawn with previous data:-

	Extrapolation of peak-diameter values silver to osmic		Lloyd & Chang (1948)	Barker, Ip & Adal (1962)
GR.III	2.0 μ	3.0 μ	3.0 μ	4.0 μ
GR.II	5 u - 6 μ	7 u - 8.5 μ	7 u - 8 μ	7 u - 8 μ
GR.I	11.0 μ	15.5 μ	15.0 μ	16.0 μ

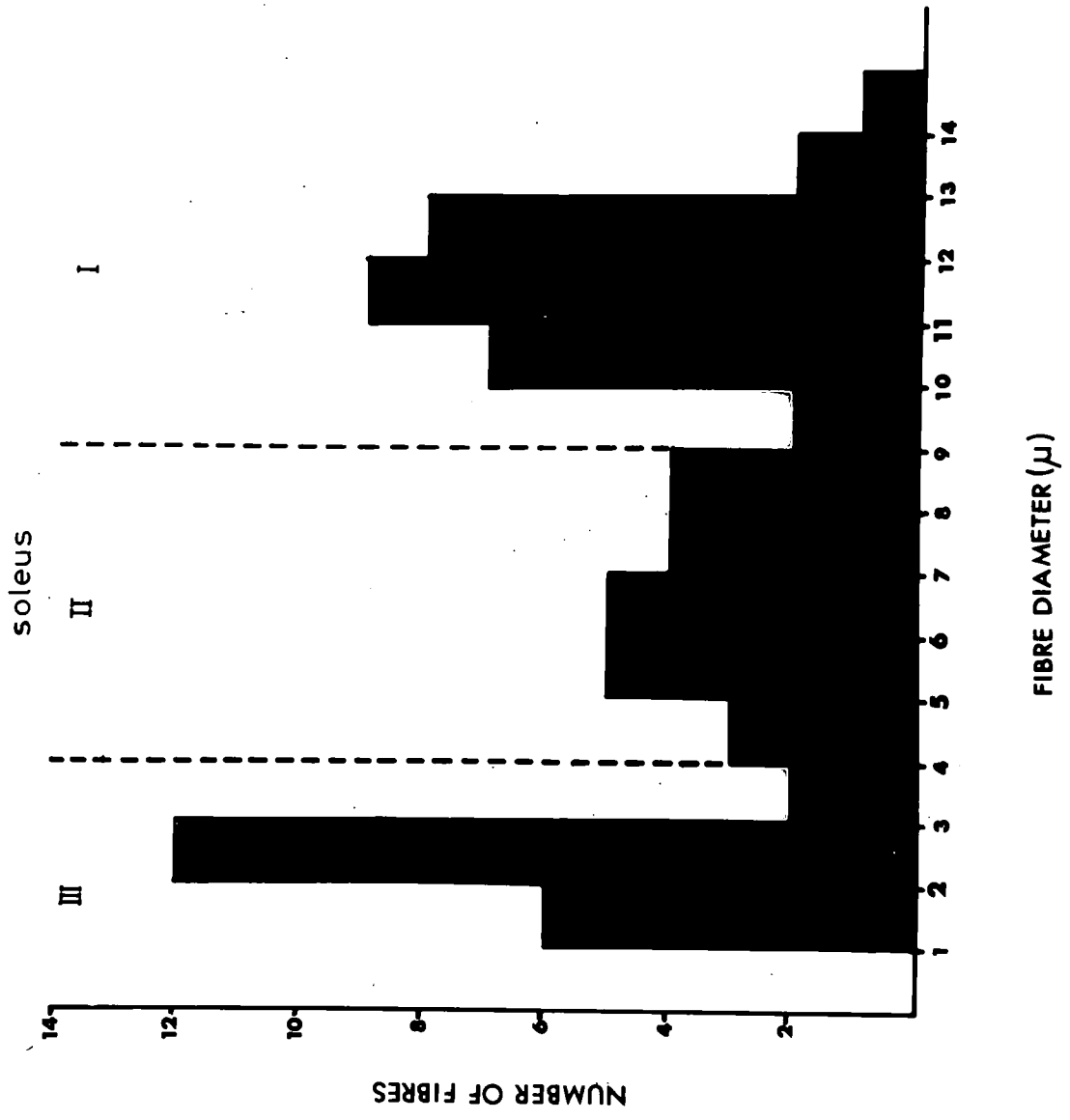


Figure 10

Myelinated nerve-fibre diameter spectra of
three muscle nerves

A. tibialis posterior - 4 nerves (cats 223, 228, 234, 235)

B. peroneus I - 3 nerves (cats 223, 228, 234)

C. peroneus III - 1 nerve (cat 234)

Weigert-Pal technique (Williams & Wendell-Smith 1960) :

5 μ sections

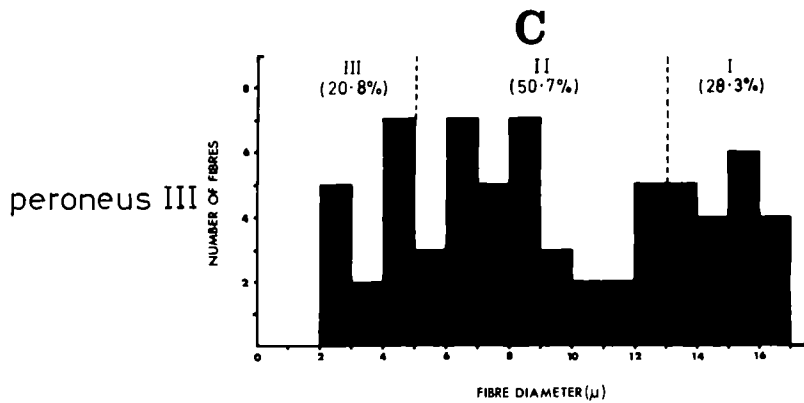
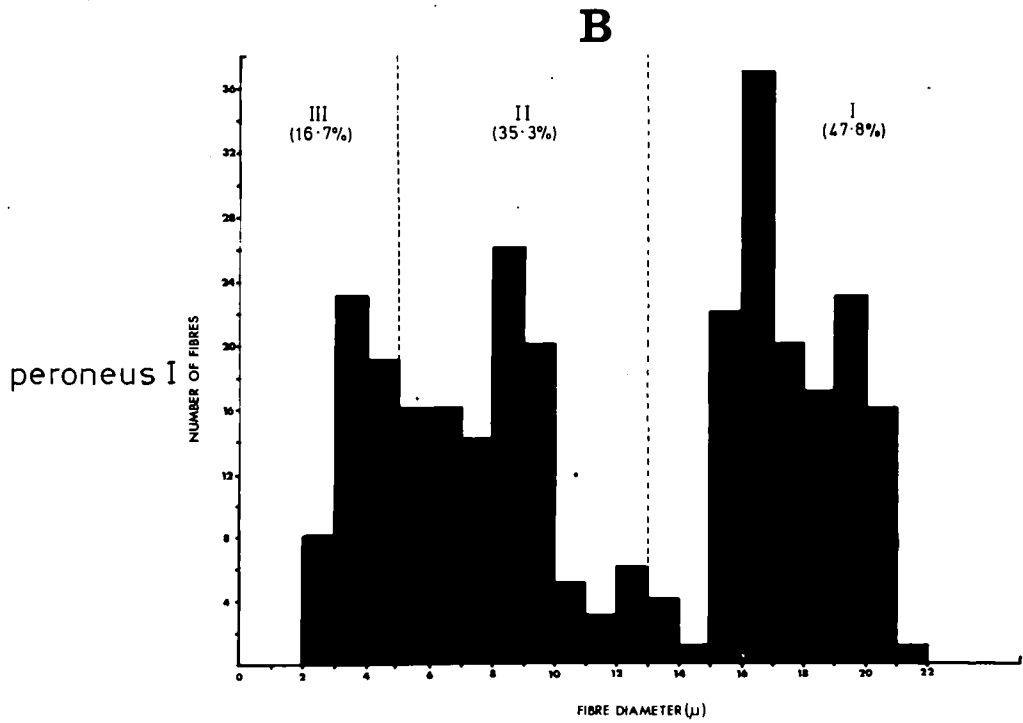
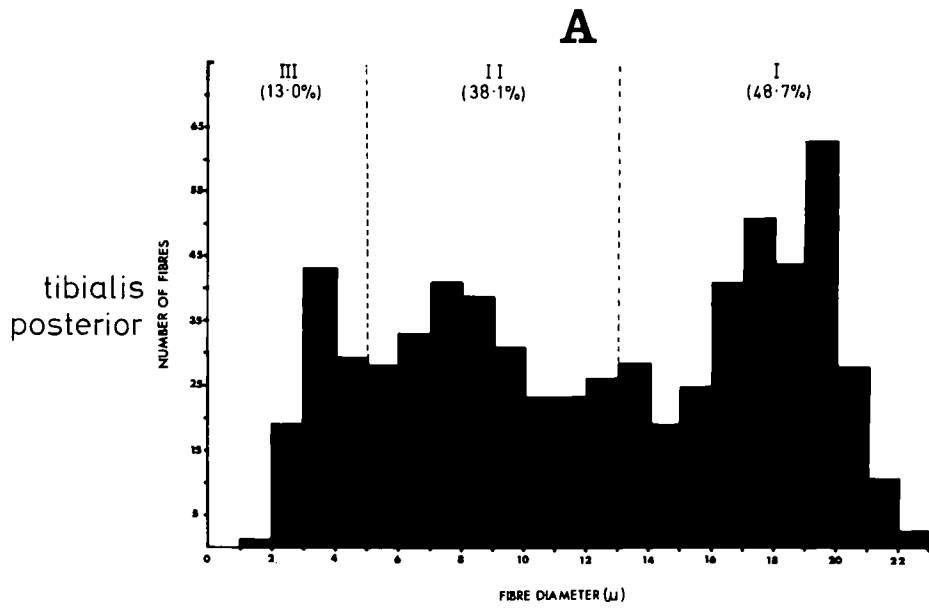


Figure 11

Transverse section of a muscle nerve impregnated
with silver (Holmes method)

n.my. - non-myelinated axons in a Schwann-cell bundle

d.d. - degenerated motor and sympathetic nerve-fibre
debris

my. - axons of myelinated nerve fibres

my.h. - myelin 'halo'

(C228 tibialis posterior nerve 8 μ transverse section)

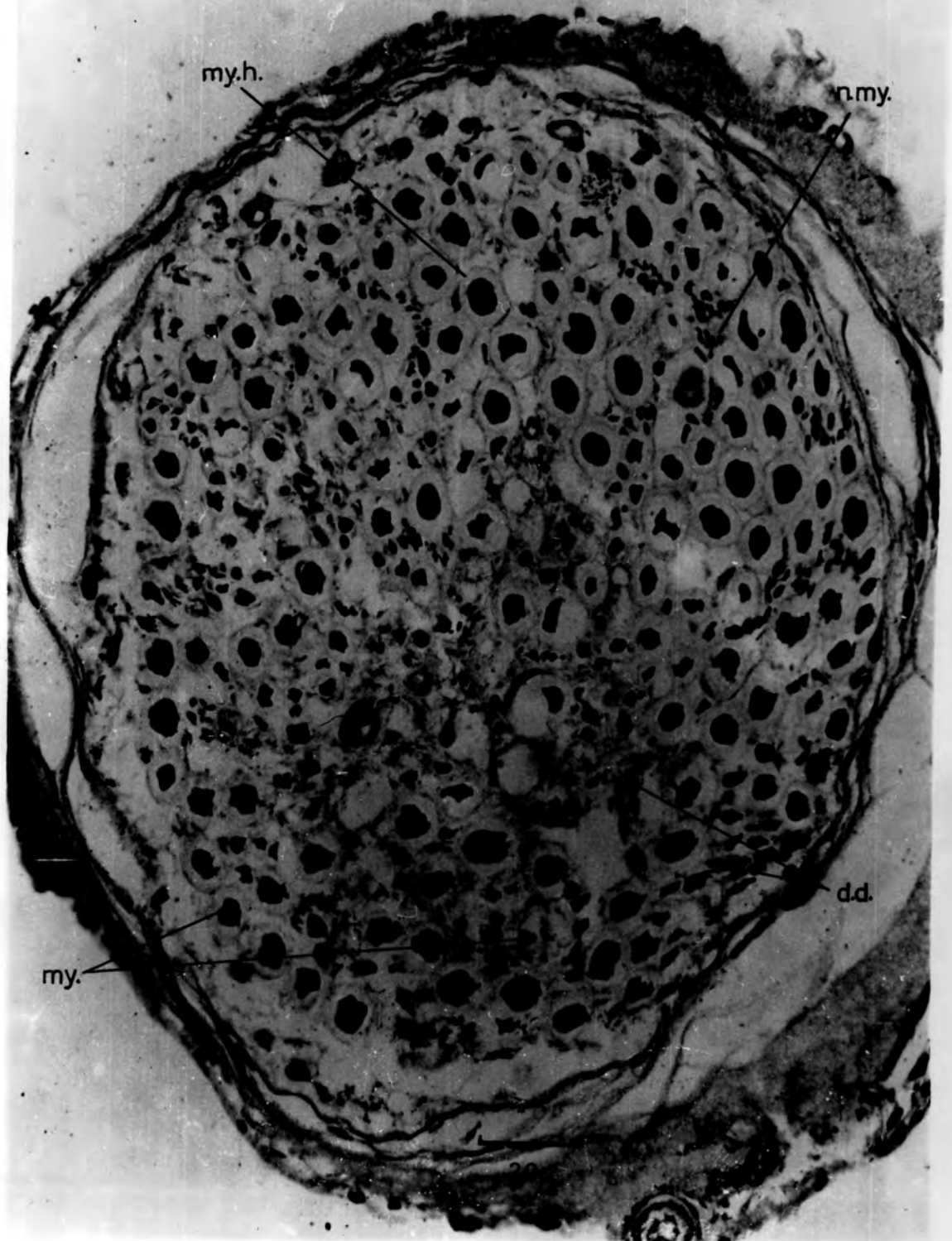

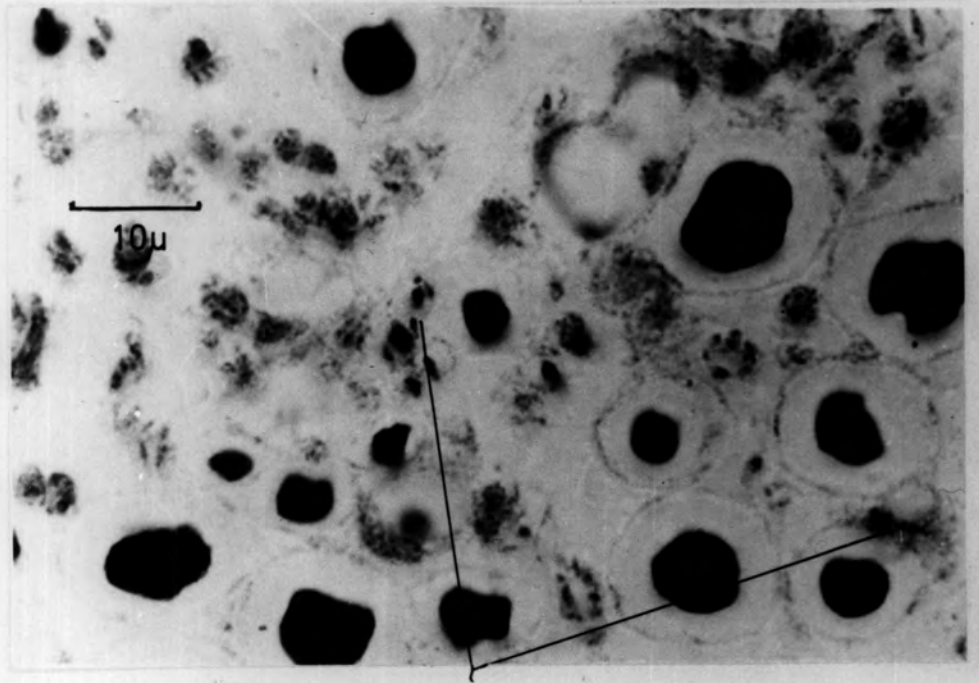
Figure 12

Non-myelinated sensory axons in Schwann-cell bundles

- a. Transverse section of a muscle nerve
(C213, de-efferentated and sympathectomized
tibialis posterior nerve, Holmes silver method,
8 μ section)

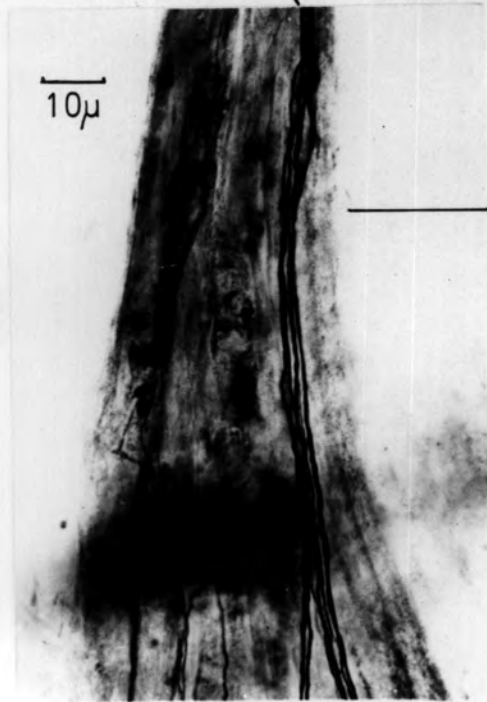
- b. Teased vascular nerve trunk
(C223, de-efferentated and sympathectomized
extensor digitorum longus muscle, de Castro
silver impregnation)

a



non-myelinated axons in a Schwann-cell
bundle

b



vascular
nerve
trunk

Figure 13

The fibre-diameter spectrum of the total sensory nerve-fibre component from skeletal muscle as determined by light microscopy

The non-myelinated sensory axons are aggregated within the 0.0μ to 1.0μ diameter range and form a large fourth group at the left-hand end of the spectrum

(The histogram is based on data obtained from the tibialis posterior nerves of de-efferentated and sympathectomized C234 and C235; Holmes silver method (Group IV), modified Weigert-Pal method (Groups III, II and I)

tibialis posterior

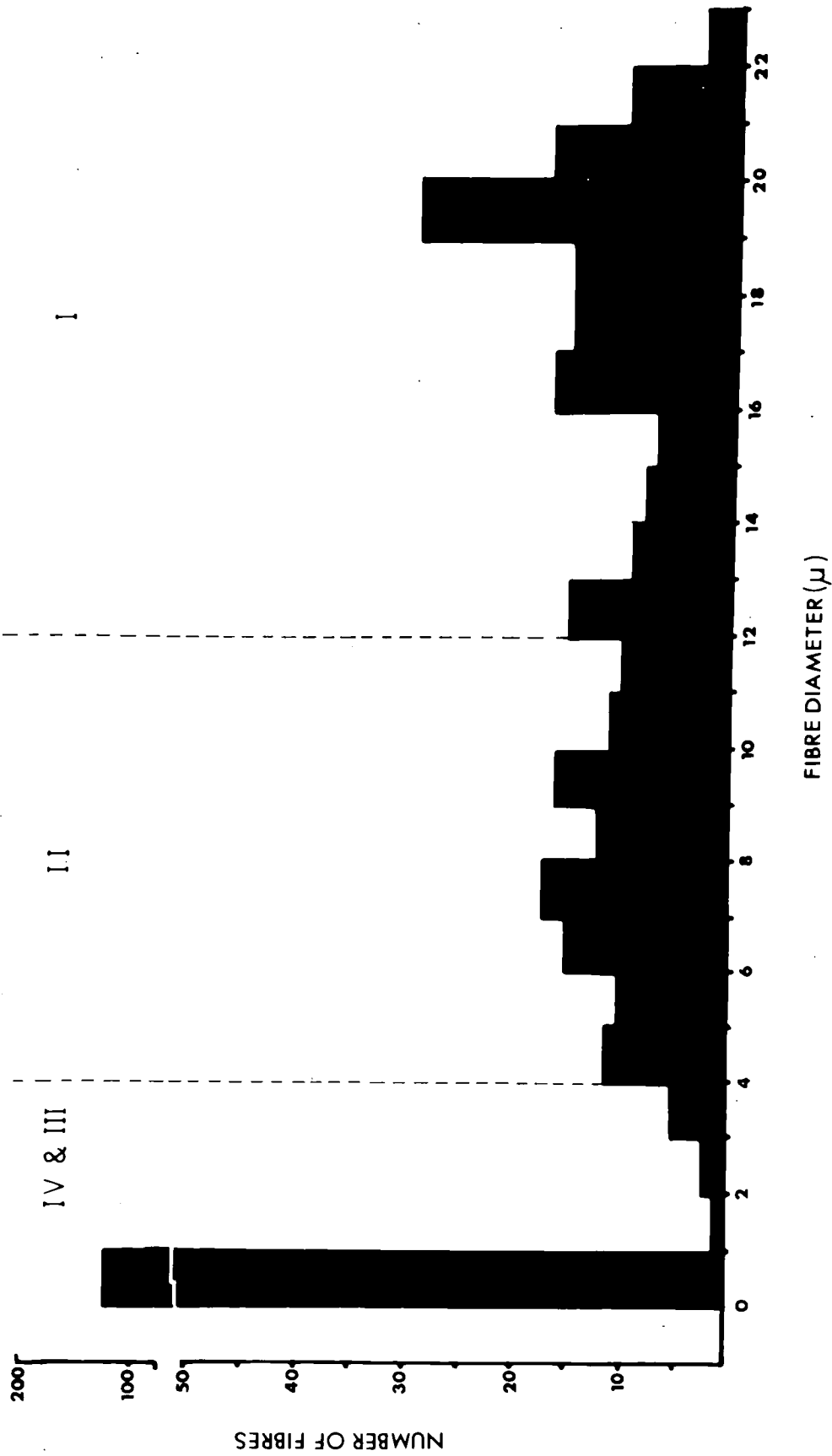


Figure 14.

An electron micrograph illustrating a Schwann cell containing non-myelinated sensory axons

- ax - non-myelinated sensory axon
- bm - basement membrane
- ct - cytoplasm of Schwann cell
- IN₁ - inflexions of the basement membrane
- IN₂
- my.ax. - axon of myelinated sensory nerve fibres
- m - mesaxon
- N - Schwann-cell nucleus

(C234, de-efferentated and sympathectomized tibialis posterior nerve,
Reynolds (1963) lead-citrate method)

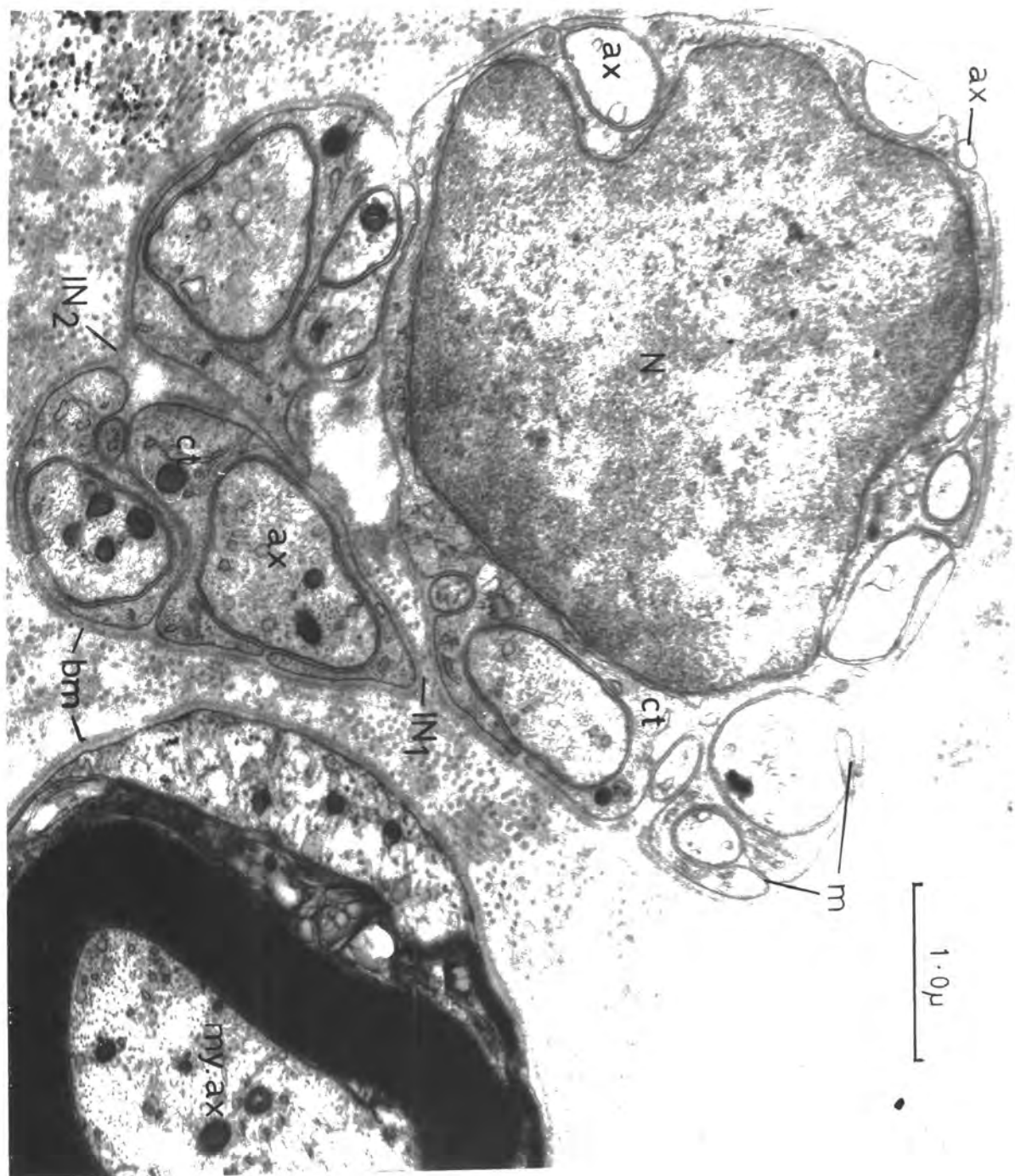


Figure 15

Schwann-cell nucleus region of a small-myelinated
(Group III) sensory nerve fibre

(C234, de-efferentated and sympathectomized
tibialis posterior nerve; Reynolds (1963)
lead-citrate method)

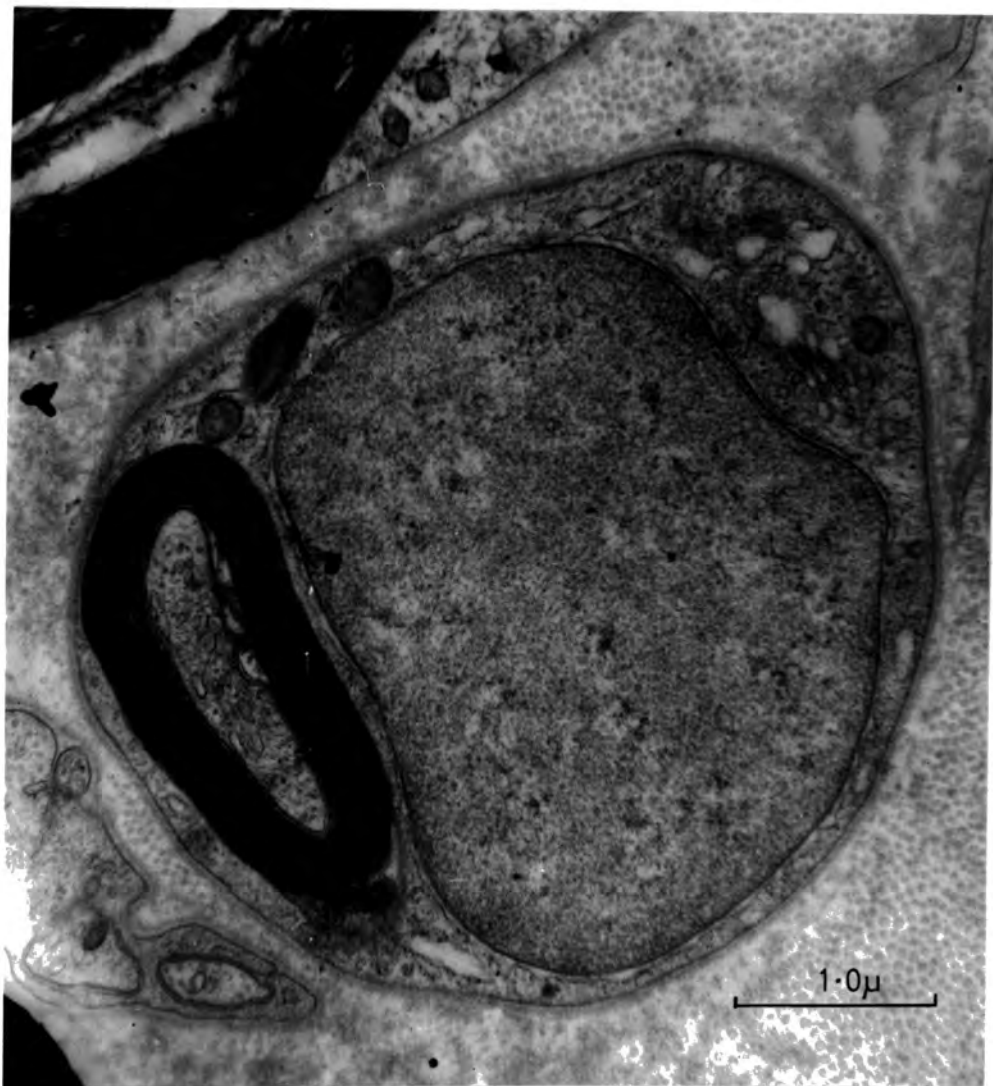

Figure 16

Non-myelinated sensory axons in Schwann-cell cytoplasm

- AX - a non-myelinated axon, which is changing course in the cytoplasm, has consequently been cut in oblique section
- ax₁ - single axons with a covering of cytoplasm
- ax₂
- n.ax. - virtually naked axons
- ct - Schwann-cell cytoplasm

(C235, de-efferentated and sympathectomized tibialis posterior nerve, Reynolds (1963) lead-citrate method)

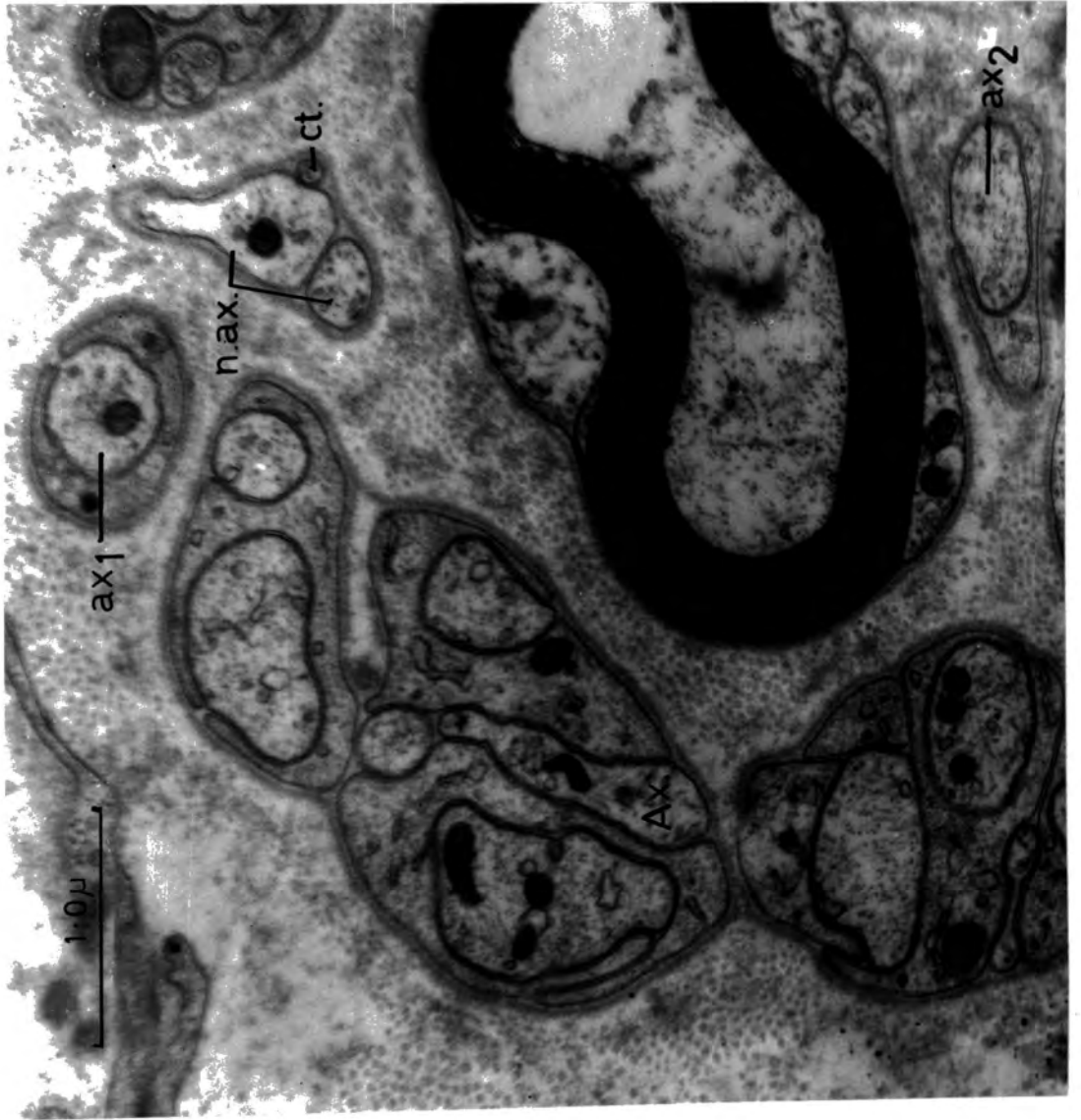


Figure 17

Illustration of various stages in the envelopment of non-myelinated sensory axons by the cytoplasm of a Schwann cell

See text for description of letters a - f

(C234, de-efferentated and sympathectomized tibialis posterior nerve,
Reynolds (1963) lead-citrate method)

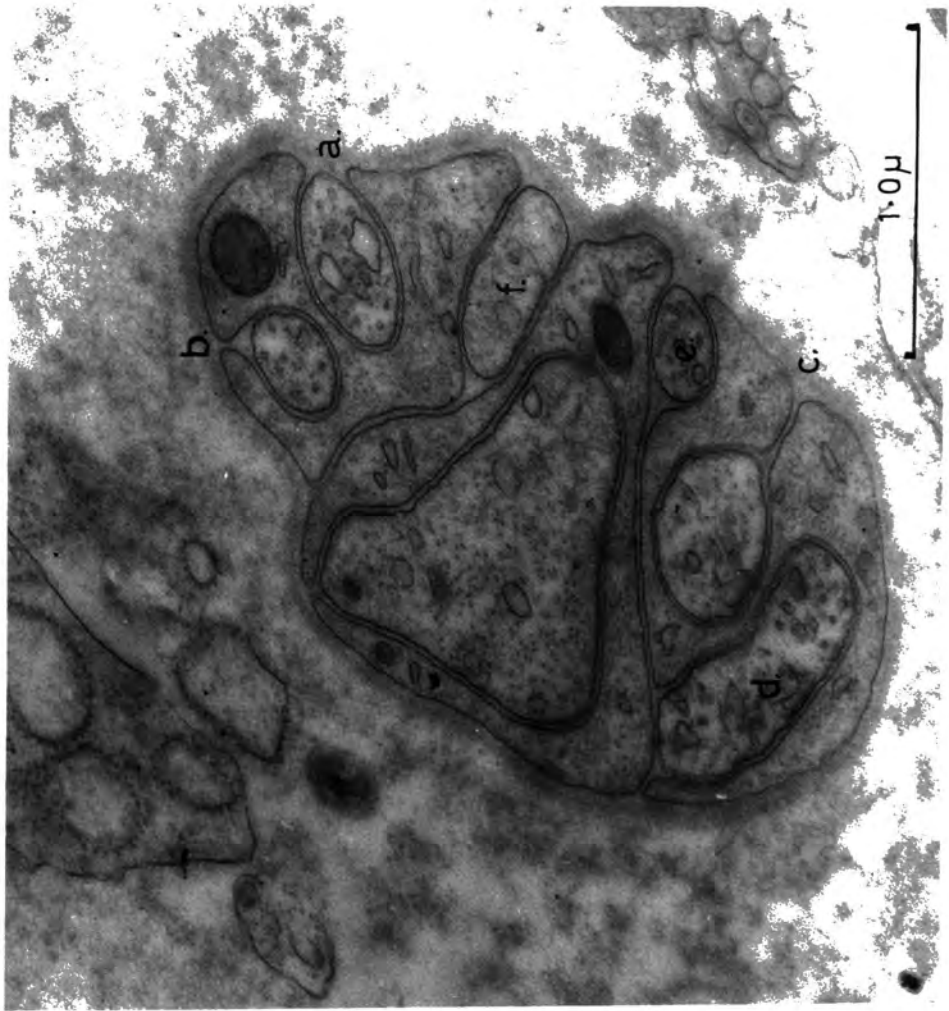


Figure 18

Non-myelinated sensory axons in Schwann-cell cytoplasm

- cf - collagen fibres
- 'Ex.b.m. - 'external' basement membrane
- 'In.b.m. - 'internal' basement membrane
- N - Schwann-cell nucleus

(C234, de-efferentated and sympathectomized tibialis posterior nerve;

Reynolds (1963) lead-citrate method)

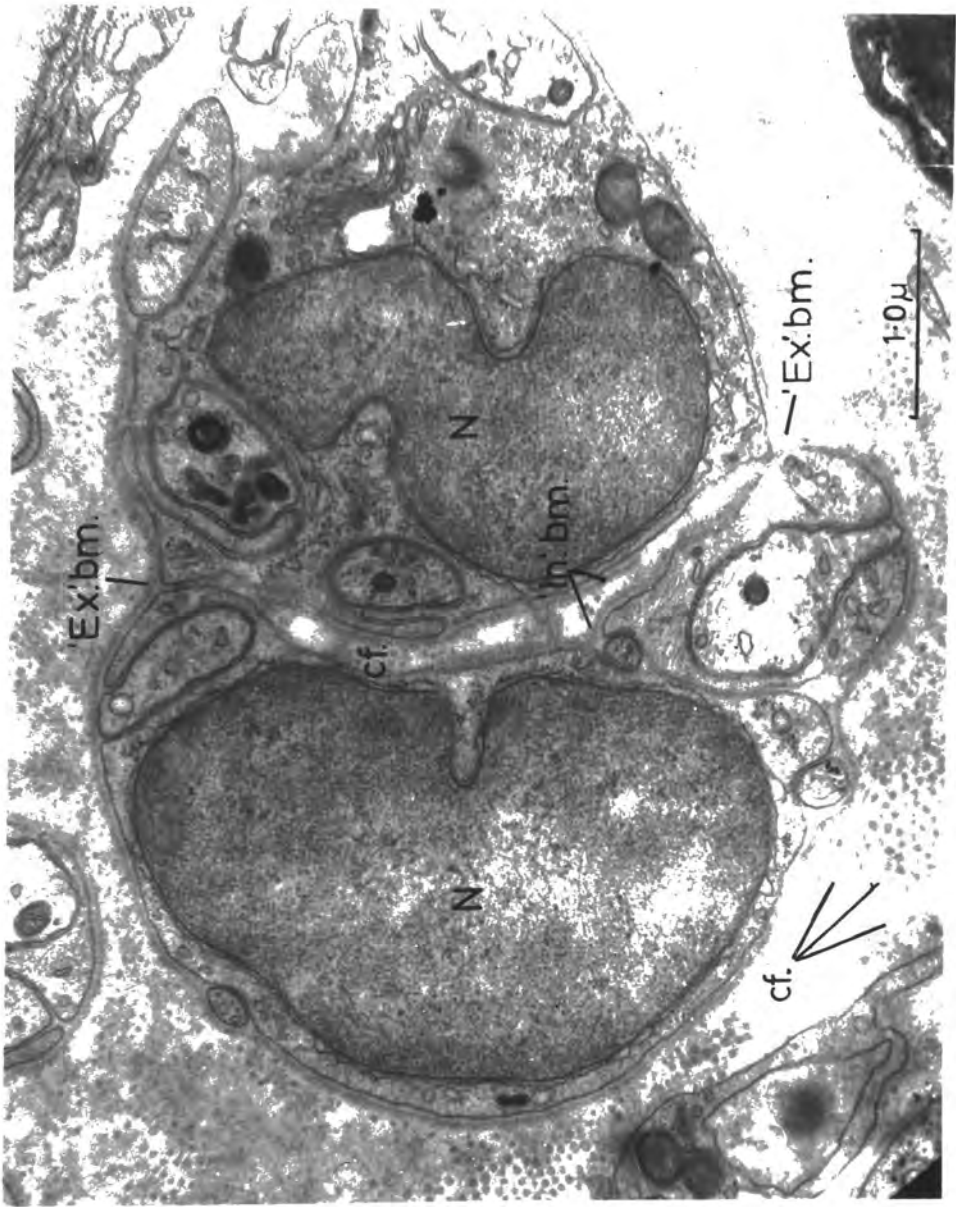
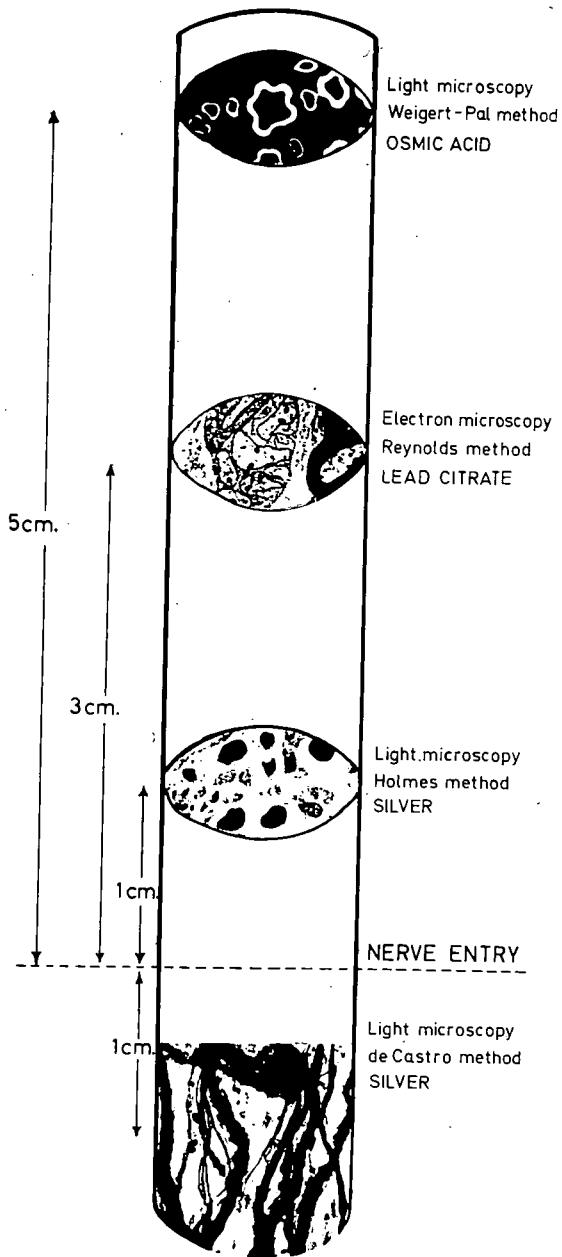


Figure 19

An illustration of the histological methods
employed to obtain quantitative data of the
sensory component of muscle nerves

The data in the illustration are from the tibialis posterior nerve of C235 (130 myelinated; 261 non-myelinated) and the peroneus III nerve of C234 (67 myelinated; the non-myelinated data in the remainder of the illustration)



myelinated fibres non-myelinated axons proportion myelinated : non-myelinated

Light microscopy
Weigert-Pal method
OSMIC ACID

67
&
130

—
—

—
—

Electron microscopy
Reynolds method
LEAD CITRATE

130

261

1 : 2.0

Light microscopy
Holmes method
SILVER

67

30

2.2 : 1

NERVE ENTRY

Light microscopy
de Castro method
SILVER

67

111

1 : 1.6

Figure 20

A comparison between sensory non-myelinated axon
diameter spectra of a muscle nerve and dorsal roots

- A. Diameter spectrum of 357 non-myelinated sensory axons from the tibialis posterior nerves of C234 and C235; 90% of the axons lie within the 0.15 μ to 0.60 μ diameter range and have a peak at 0.35 μ .
- B. Diameter spectrum of 1,941 non-myelinated sensory axons from the L7 and S₁ dorsal roots of the cat (histogram construction of Gasser's data J.gen. physiol. vol.38. 1954-55. p.721) 96% of the axons lie within the 0.15 μ to 0.65 μ diameter range and have a peak between 0.20 μ and 0.35 μ .

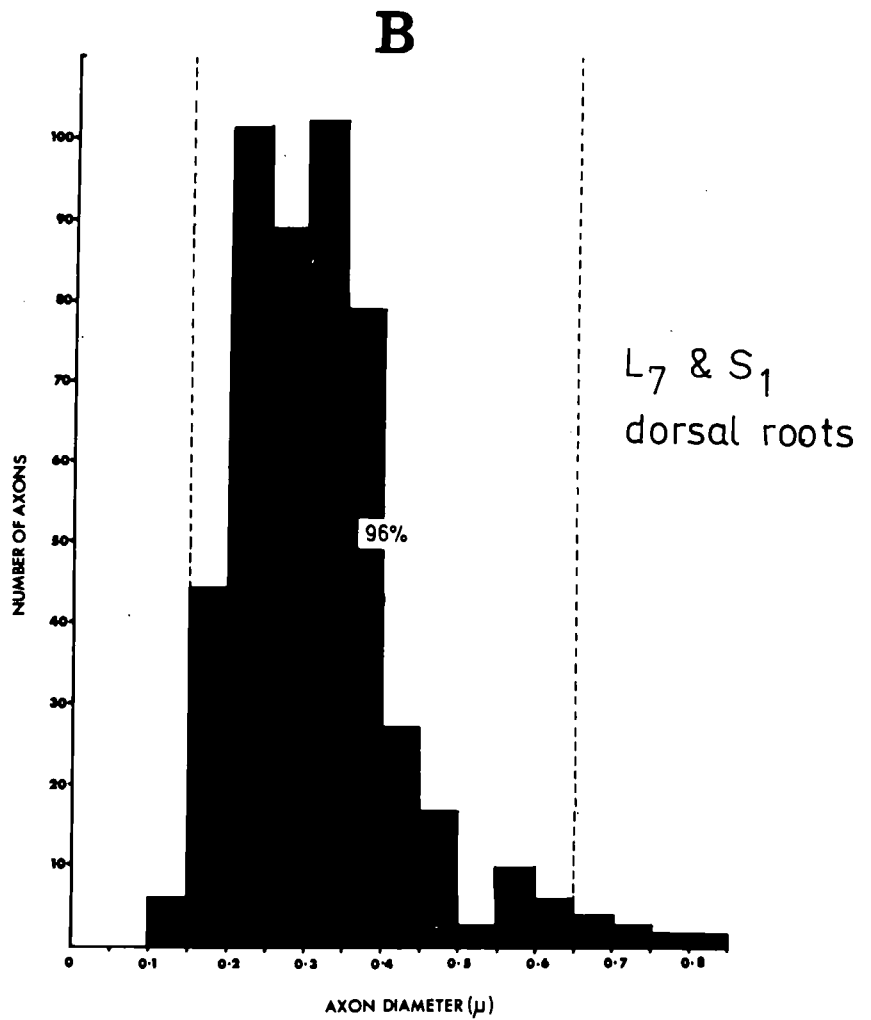
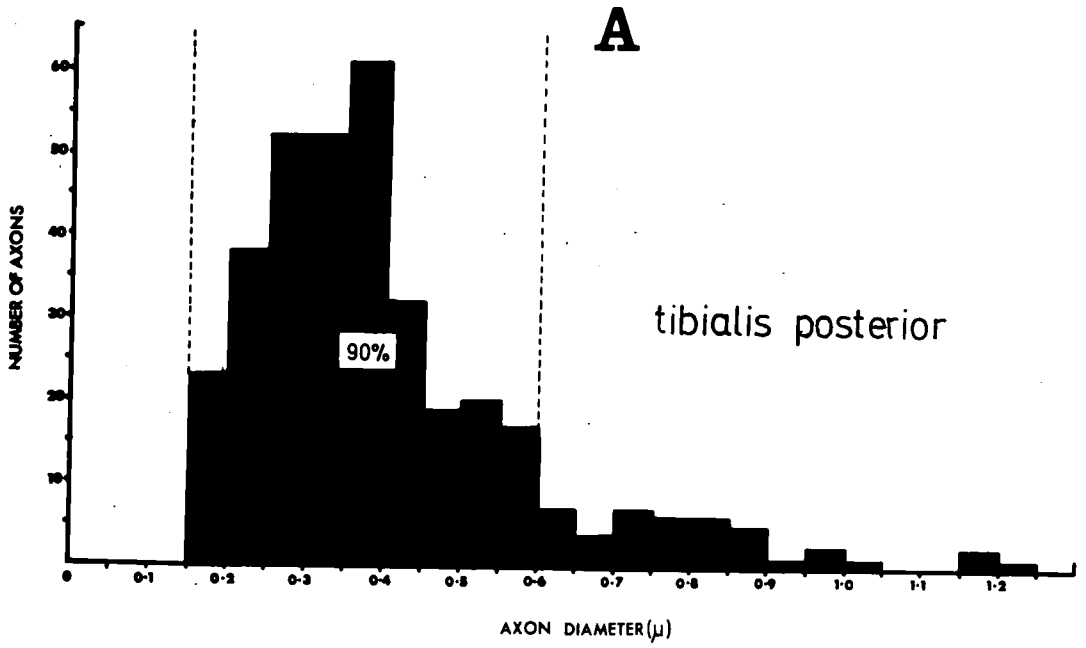


Figure 21

The fibre-diameter spectrum of the total sensory nerve-fibre
component from skeletal muscle based on light and electron
microscope observations of the tibialis posterior nerve of
the cat

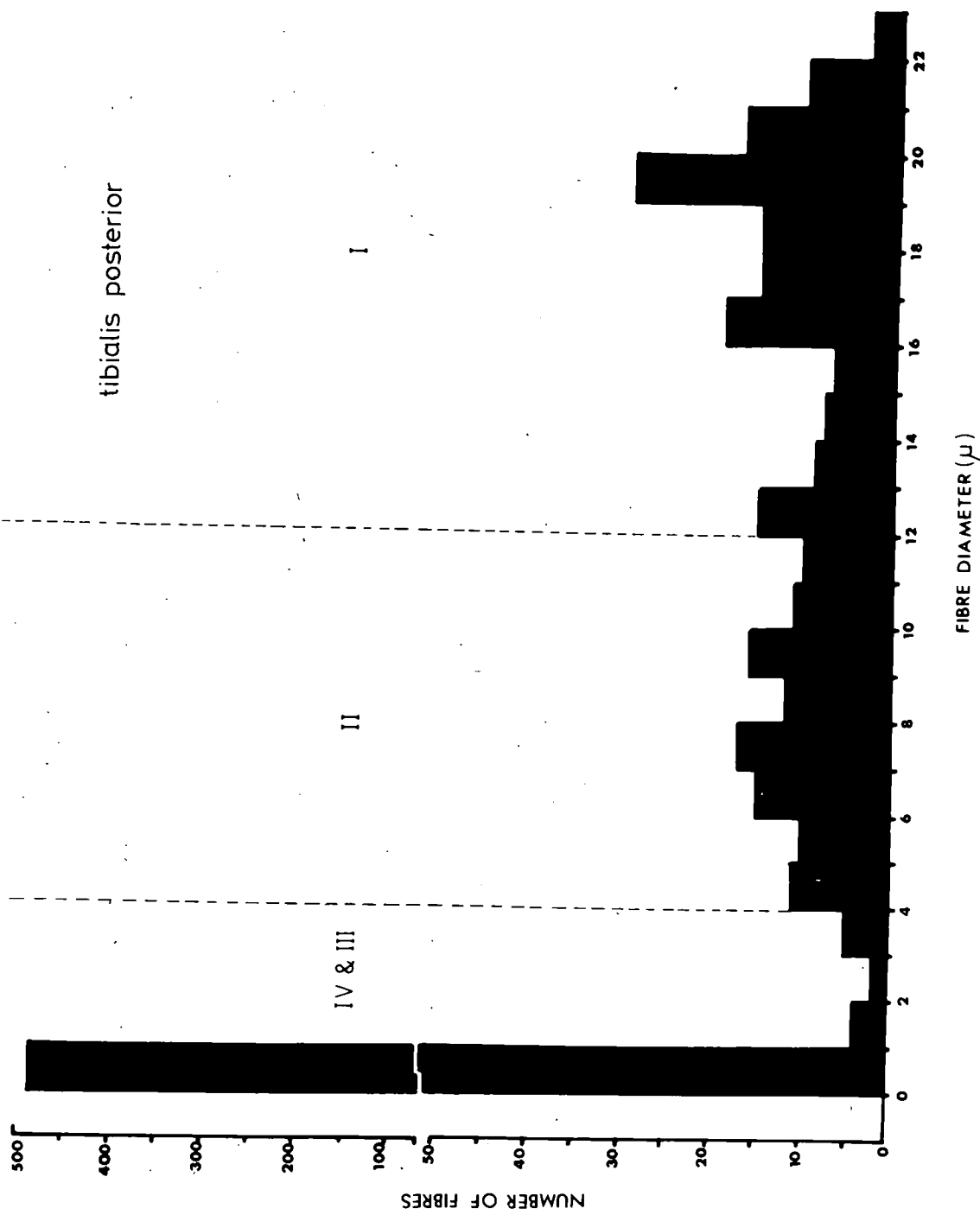


Figure 22

The deposition of fat cells along nerve
trunks and in association with the
blood system

(de Castro silver impregnation)

fat cells

capillary
network

intramuscular nerve trunk

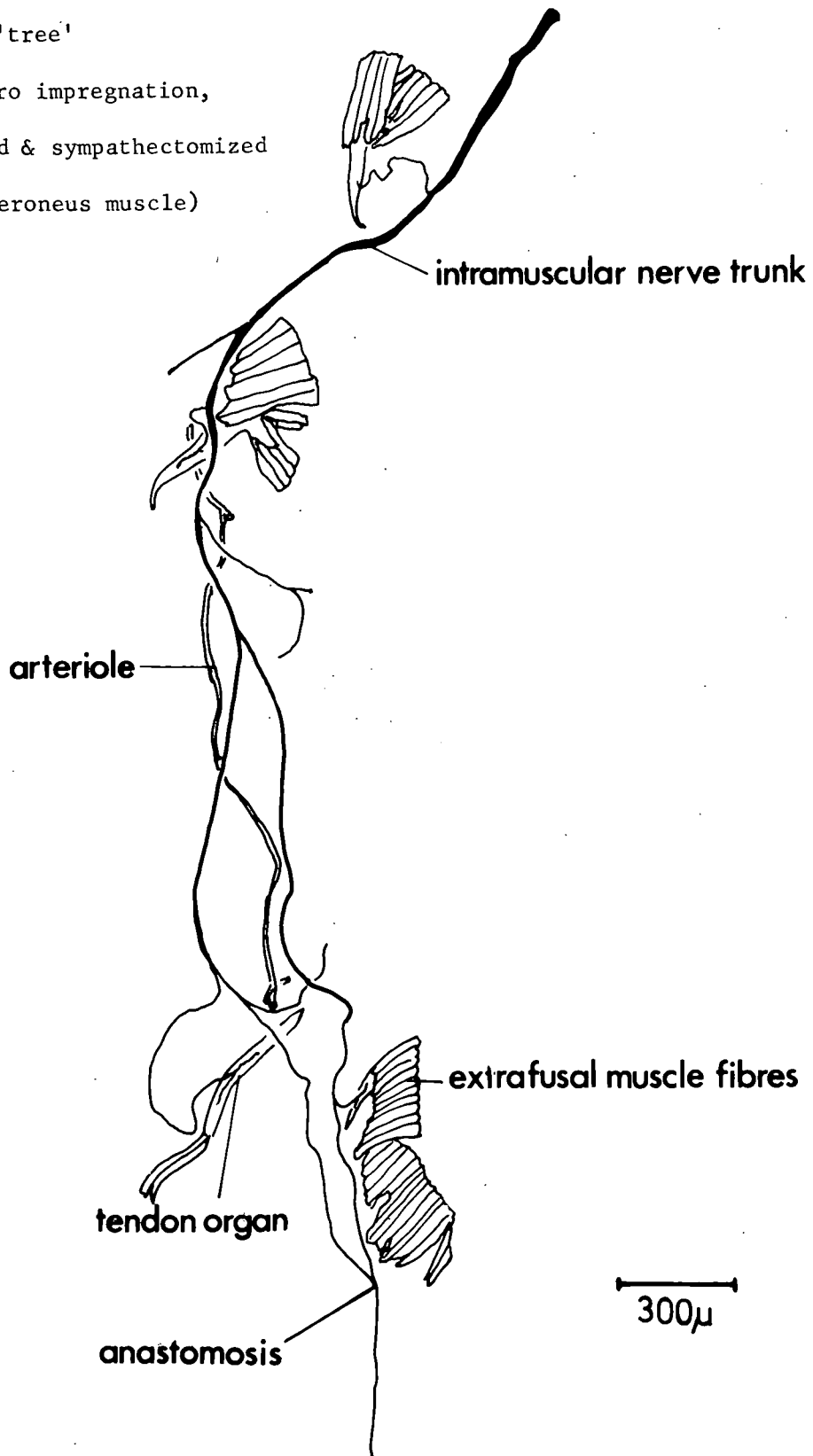


Fig. 23

Part of intramuscular nerve

'tree'

(de Castro impregnation,
de-efferentated & sympathectomized
cat peroneus muscle)



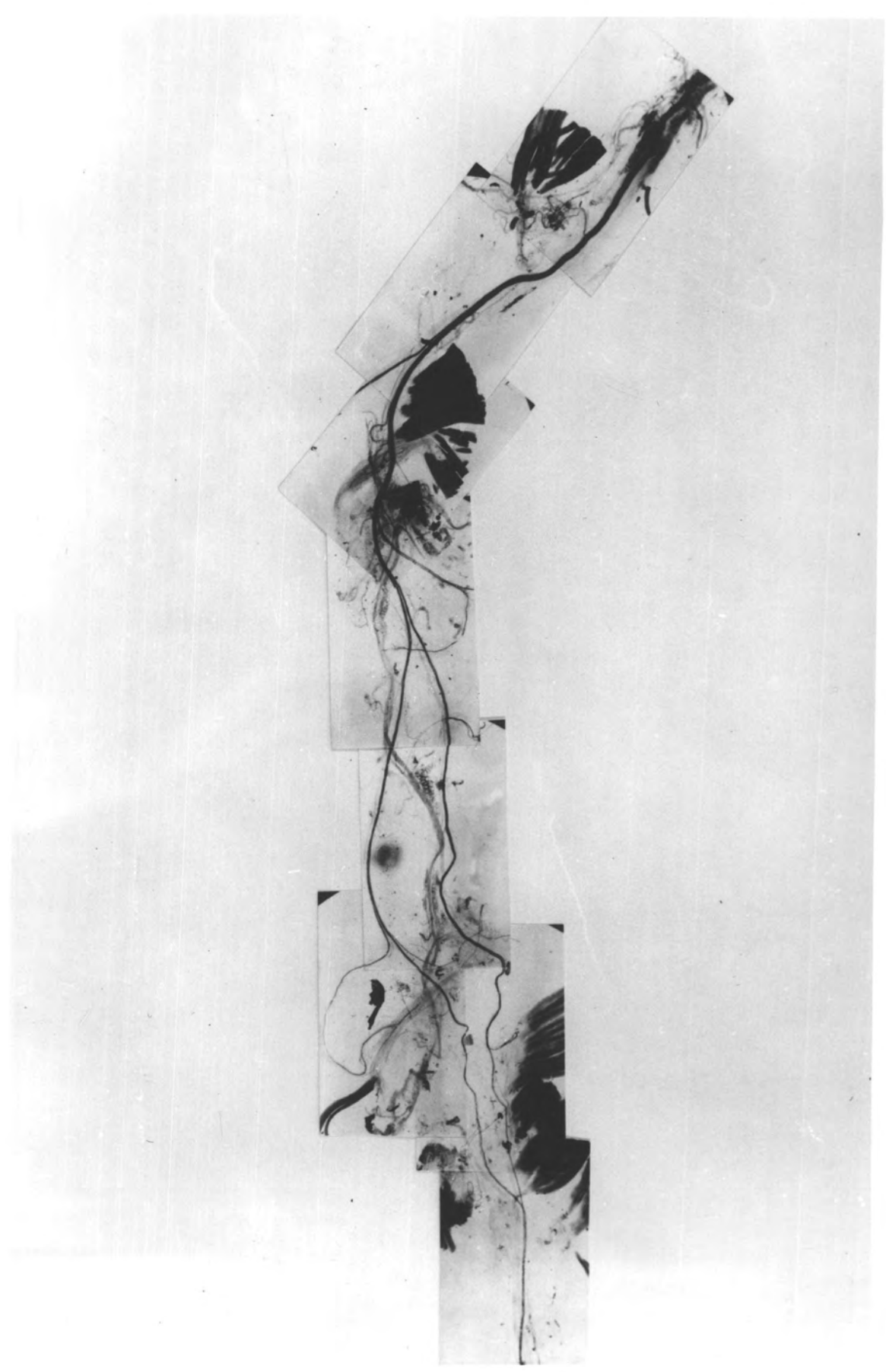
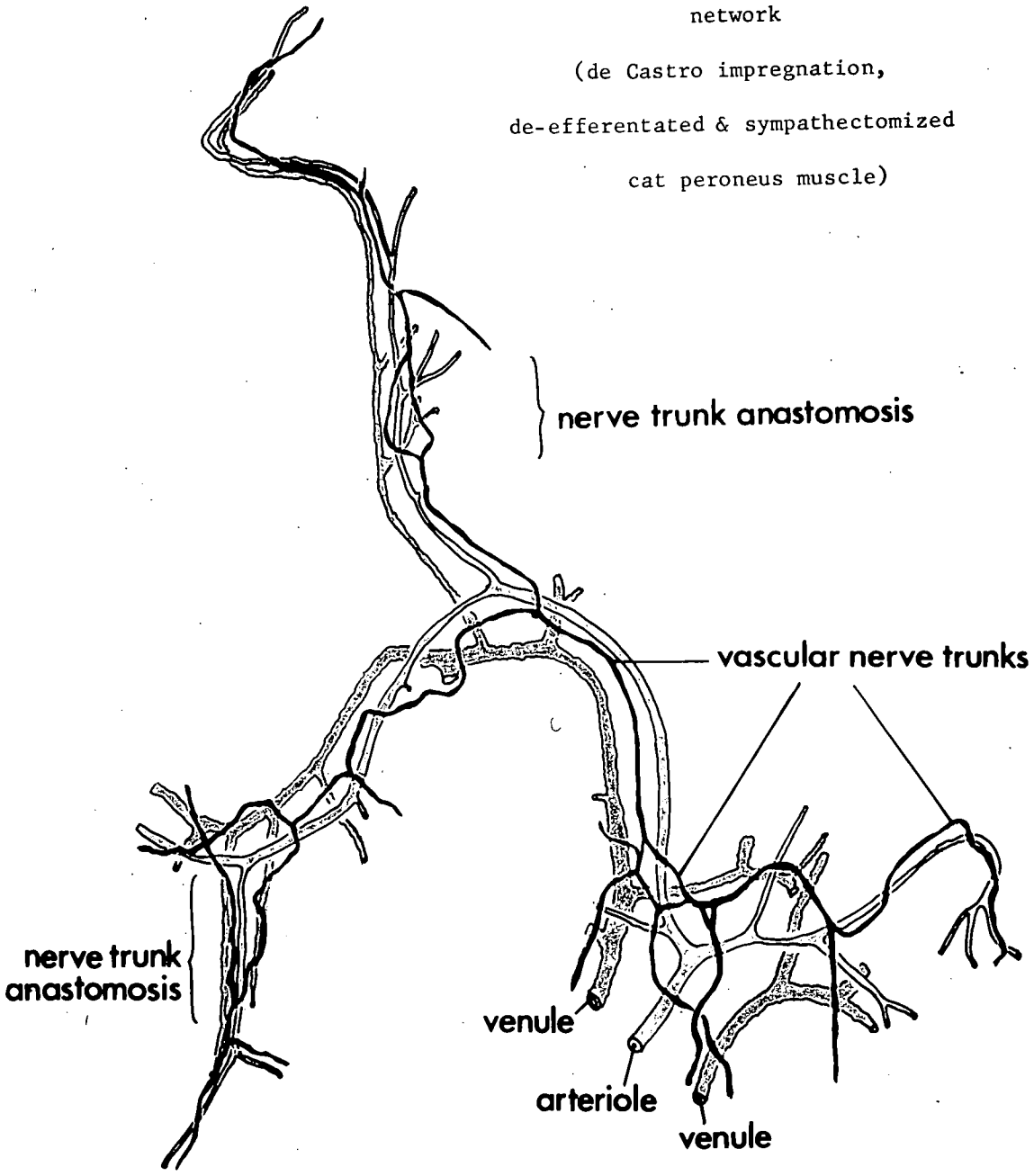


Fig. 24

Part of vascular nerve
network

(de Castro impregnation,
de-efferentated & sympathectomized
cat peroneus muscle)



300 μ

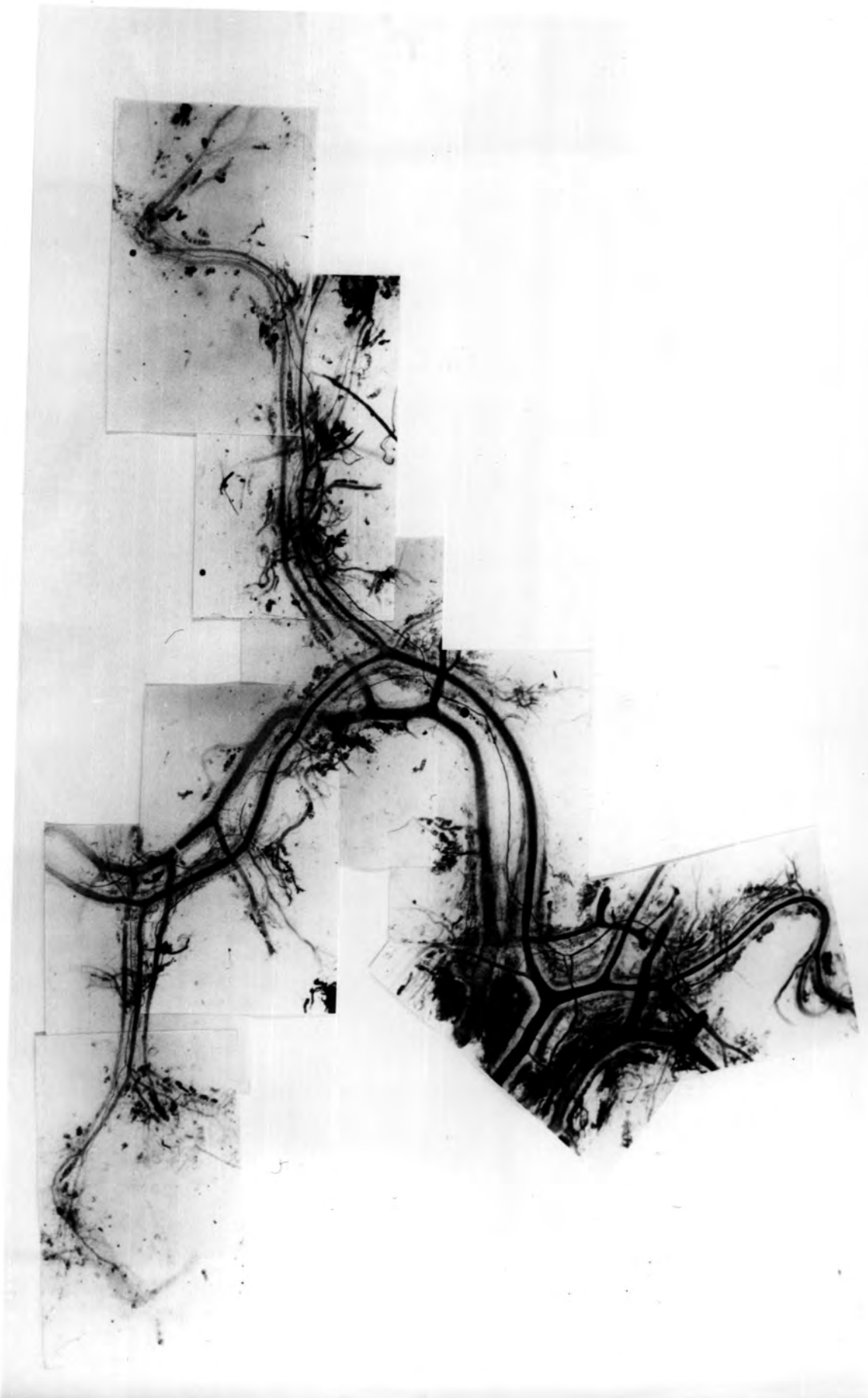


Figure 25

A diagrammatic representation of the disposition
in muscles of the nerve trunks (both intramuscular
and vascular) and blood vessels

- A. - artery
- a. - arteriole
- a.v.b. - arterio-venular bridge
- c.n. - capillary network
- e.p. - epimysium
- ex.m.f. - extrafusal muscle fibres
- f. - fat cells
- fas. - fascia
- I.n.t. - intramuscular nerve trunk
- M.n. - muscle nerve
- p. - perimysium
- t. - tendon
- V. - vein
- v. - venule
- V.n.t. - vascular nerve trunk
- V.p. - vascular plexus

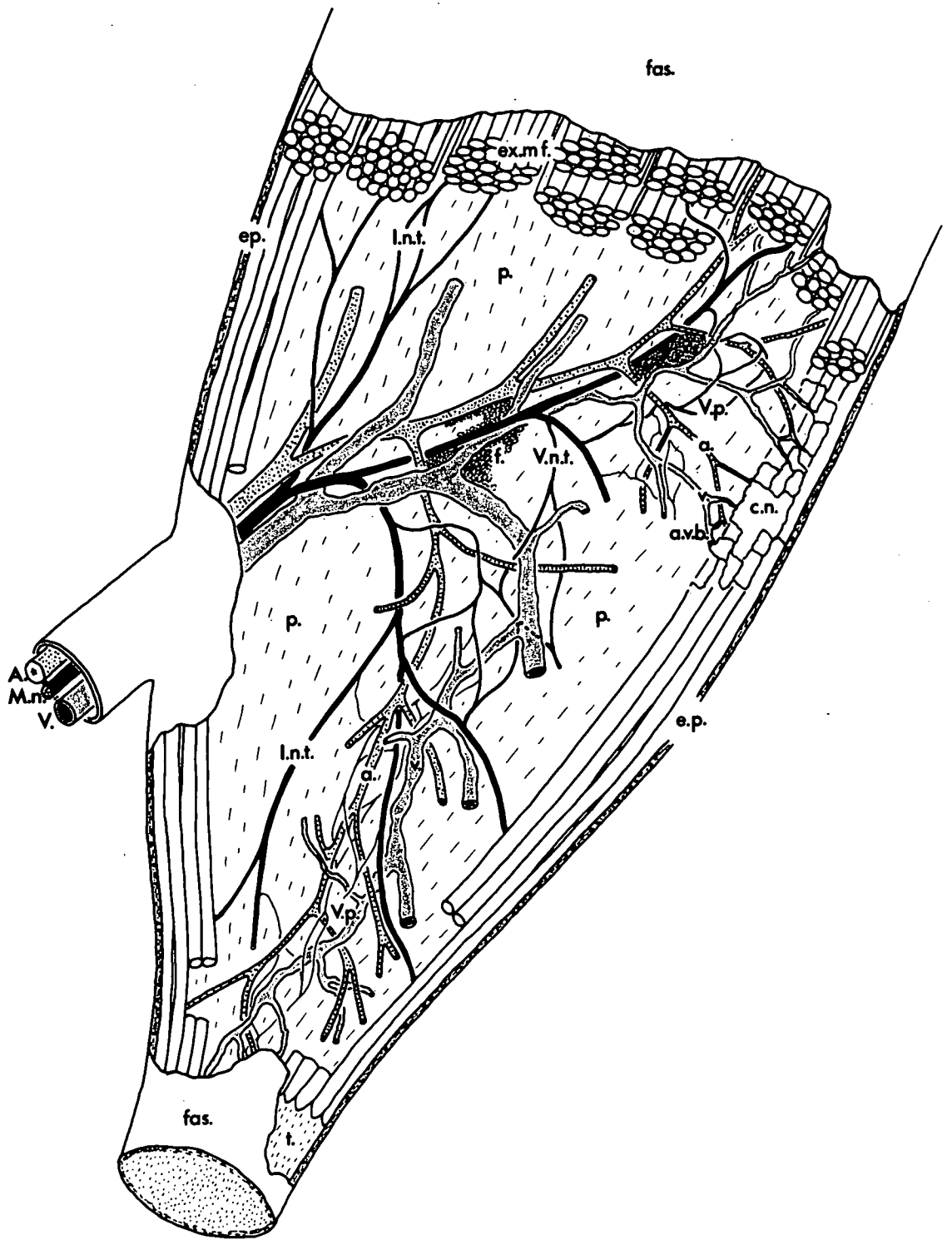


Figure 26

Muscle-spindle primary and secondary endings

- a. Tight coils of the primary ending around the intrafusal muscle fibres
 - b. S1 secondary ending with tight coils mainly around the nuclear-chain fibres
 - c. Tightly coiled S1 secondary and more loosely coiled S2 secondary
 - d. Loosely coiled S2 and S3 secondary endings
 - e. Loosely coiled S3 and S4 secondary endings
 - f. A loosely coiled S5 secondary ending with a 3.5μ (2.5μ) parent fibre
- (All spindles from teased de Castro impregnated muscles of cat hindlimb)

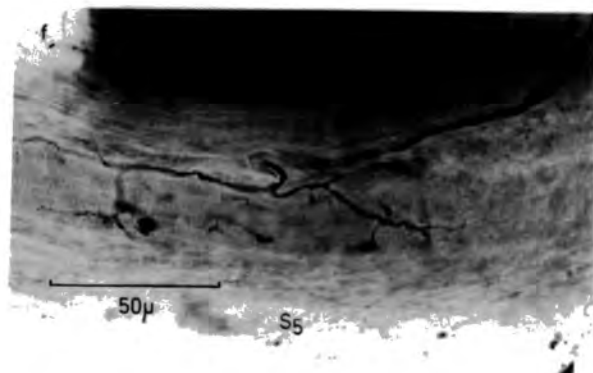
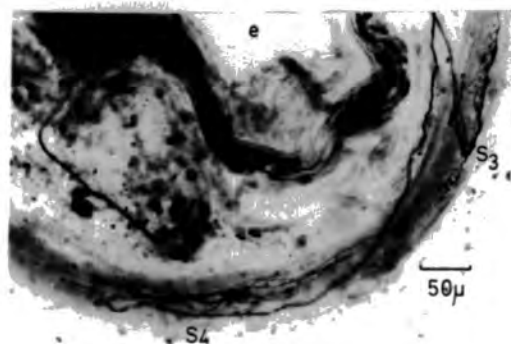
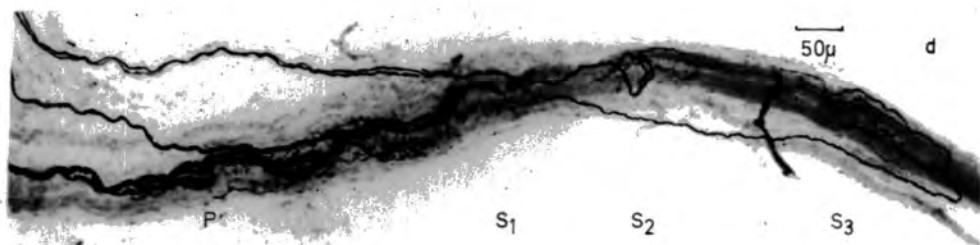

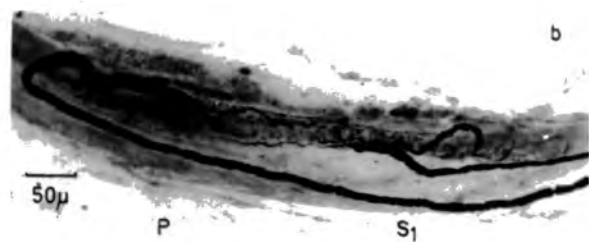


Figure 27

Ramifying free terminals in a muscle spindle and
surrounding connective tissue

The enclosed area is illustrated in the following figure in
the form of tracings

f.t. - free terminals

P. & S1 - position of primary and S1
secondary endings

(C189, de-efferentated and sympathectomized extensor digitorum
brevis muscle, de Castro silver impregnation)

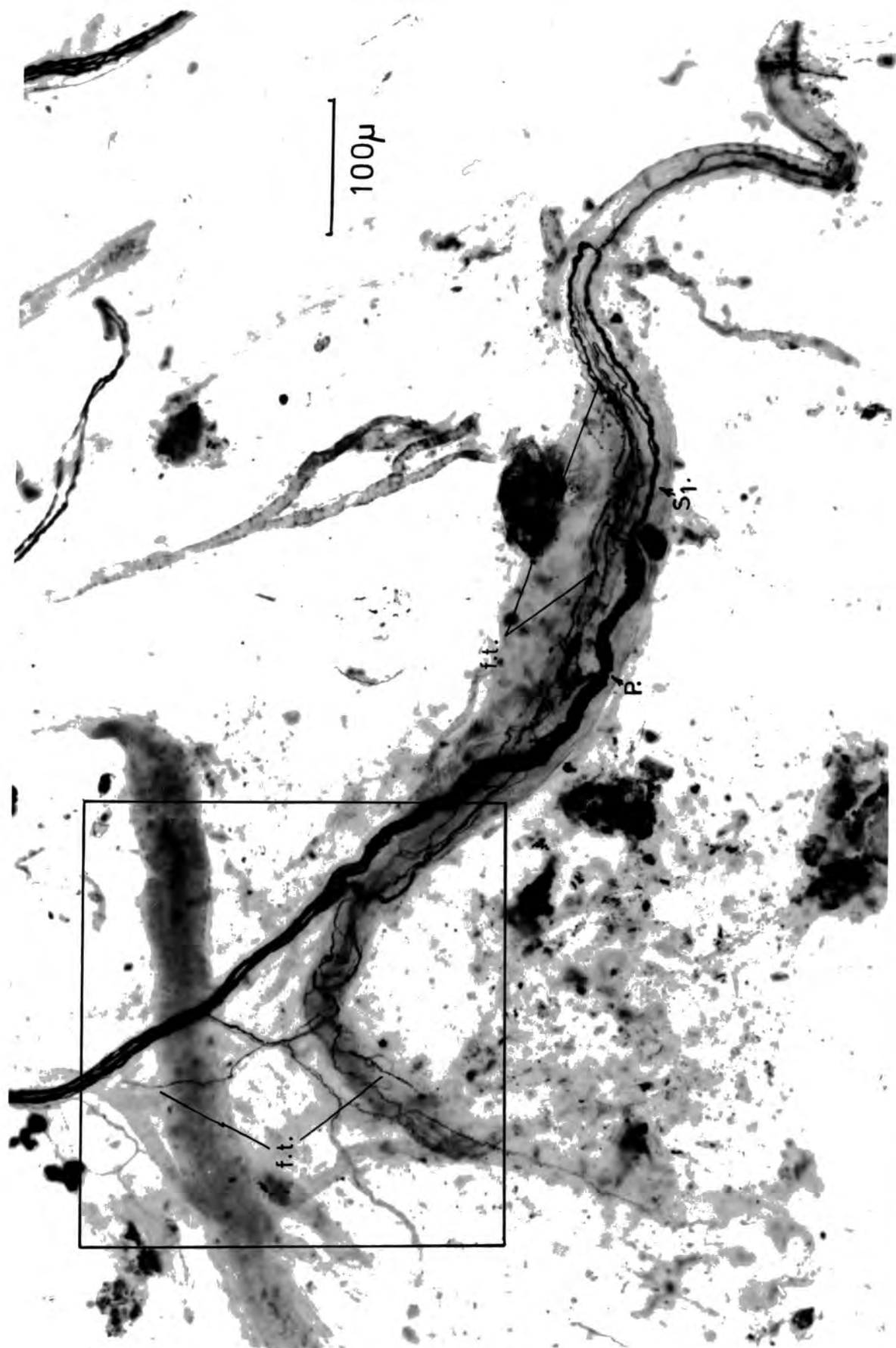


Figure 28

Tracings of the free terminal ramifications of the two free-ending parent fibres that innervate the muscle spindle of Fig. 27

Both fibres, illustrated separately in a and b also send terminals across the equatorial region to the opposite pole of the spindle

Figure 29

Tracings of free terminal ramifications in the polar regions
of two muscle spindles

- a. Extensive free ramifications among the intrafusal muscle fibres are formed from a single parent fibre 1.5μ in diameter. One of the terminals leaves the spindle and re-enters the intramuscular nerve trunk

- b. A single free terminal ramification in the connective tissue between two intrafusal muscle fibres is derived, as far as can be seen in the intramuscular nerve trunk, from a $0.5 \mu - 1.0 \mu$ parent fibre

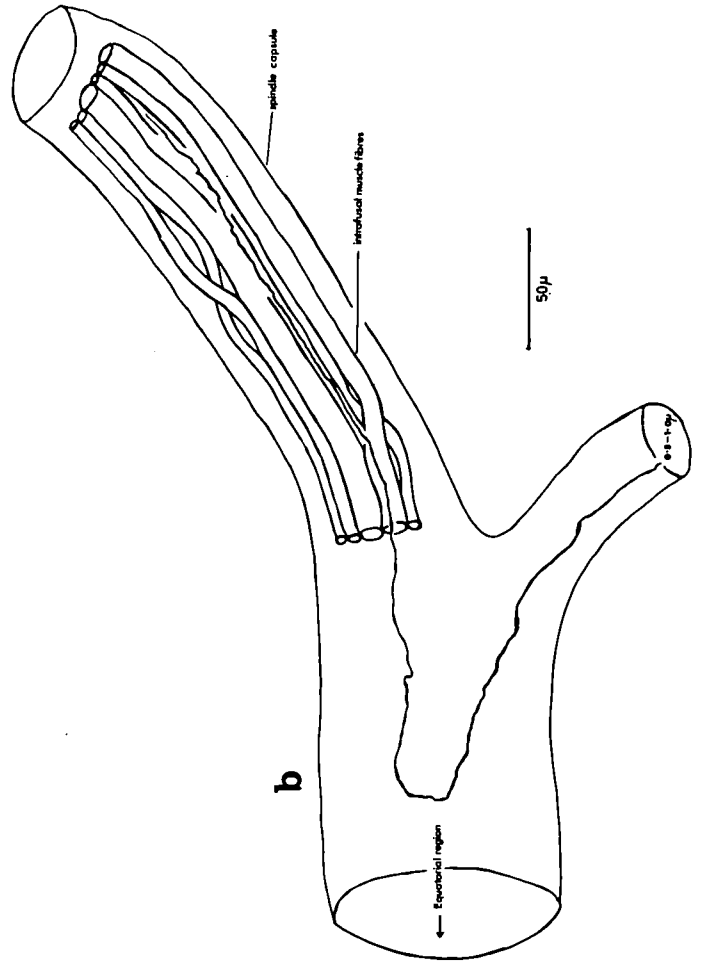
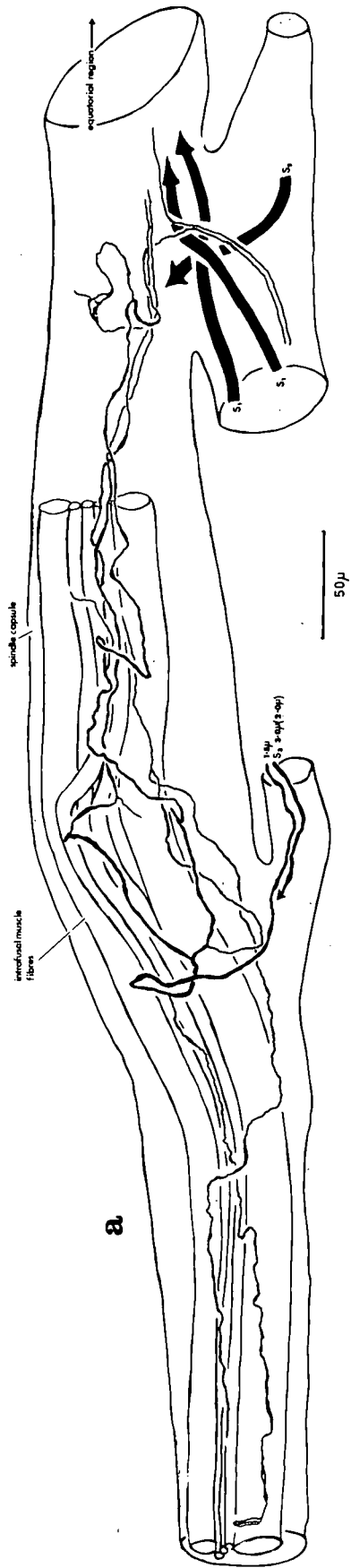


Figure 30

Ramifying free terminals in a tendon organ and surrounding

tendon tissue

- a - arteriole
- Ib - tendon organ innervation
- f1 - free-ending parent fibres referred to in the text
- f2
- f.c. - fat cells
- t. - tendon tissue
- t.n. - terminal node
- t.o. - tendon organ

(C189, de-efferentated and sympathectomized peroneus III muscle,
de Castro silver impregnation)

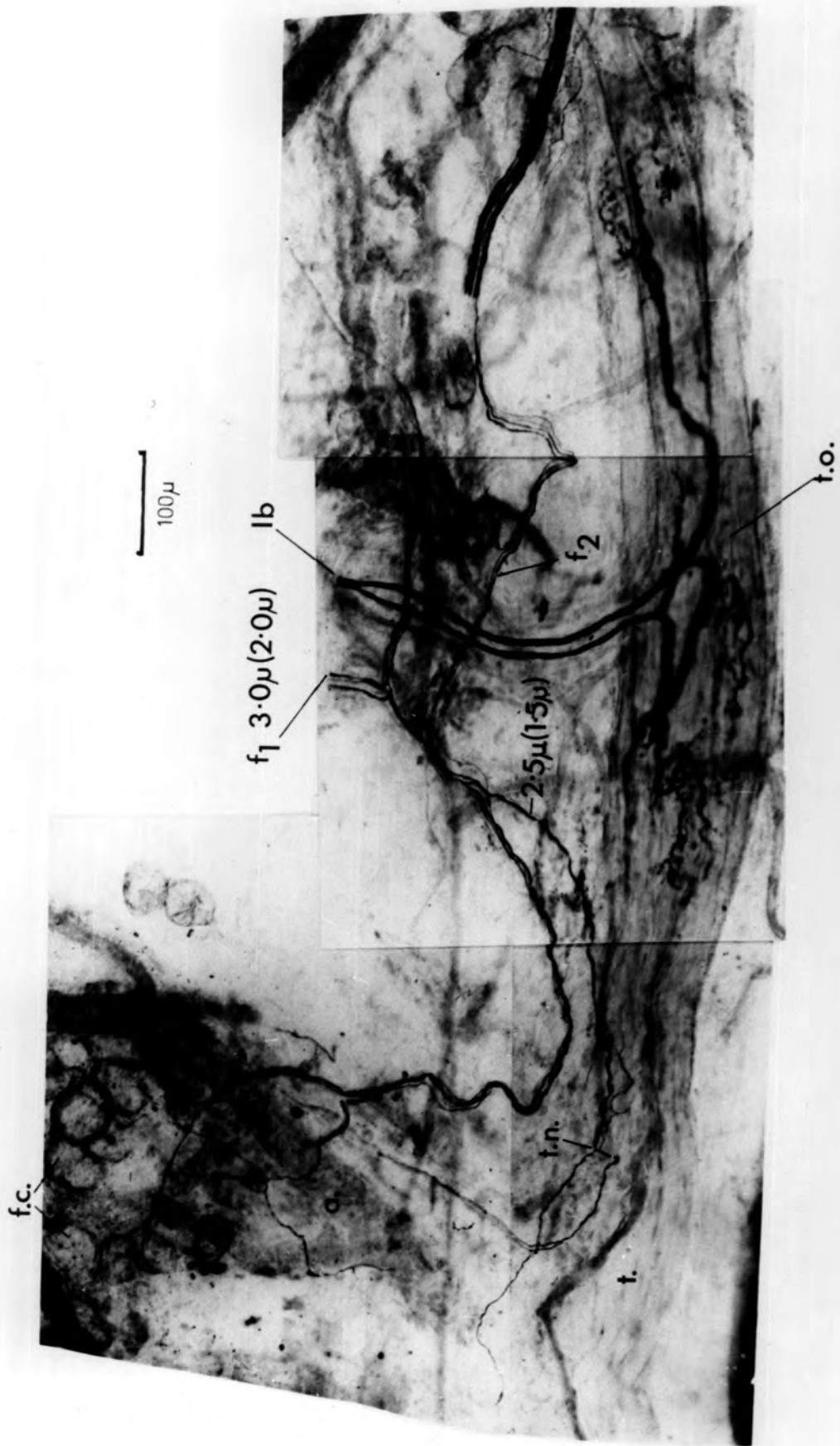


Figure 31

- a. Free ramifying terminals in the capsule of a tendon organ

(C213, de-efferentated and sympathectomized tibialis anterior muscle; de Castro silver impregnation)

- b. Free ramifying terminals in tendon tissue close to a tendon organ

The 1.5 μ fibre runs with the Ib fibre across the tendon organ and then divides repeatedly to produce free terminals in the tendon tissue (C160, normal flexor digitorum brevis muscle, de Castro impregnation)

- c. Free ramifying terminals in tendon organ capsule

(Rb. 41; normal peroneus I muscle; de Castro silver impregnation)

Ib	-	tendon organ innervation
ex.m.f.	-	extrafusal muscle fibres
f.t.	-	free terminals
int.n.t.	-	intramuscular nerve trunk
T	-	tendon
t.o.	-	tendon organ

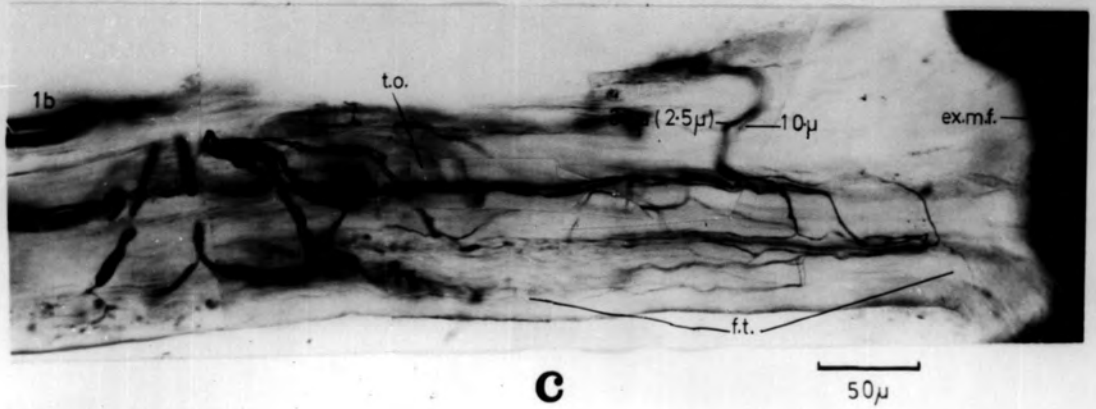
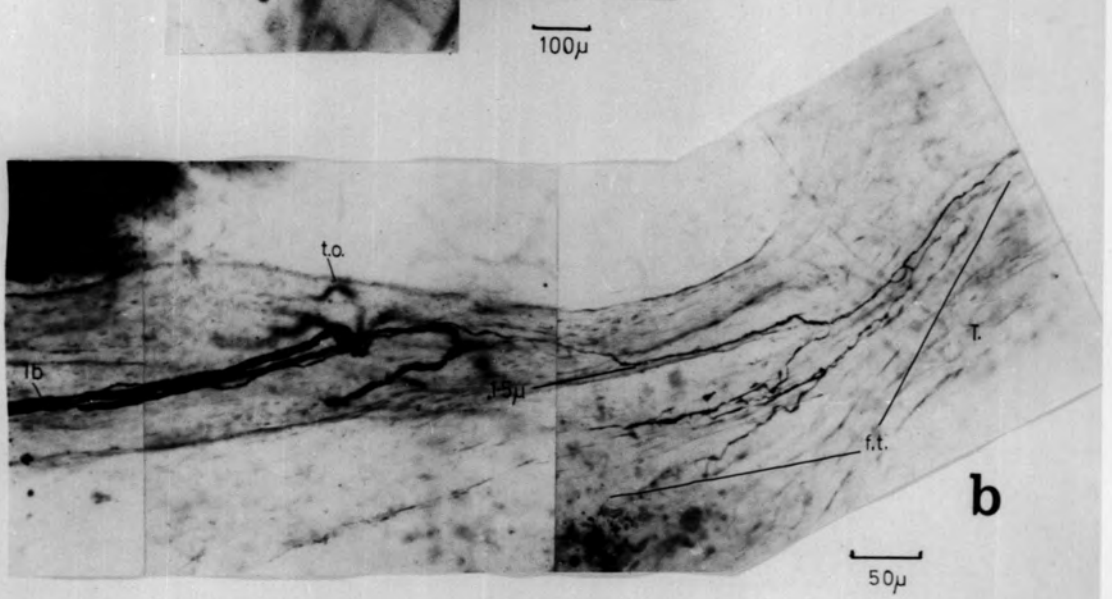
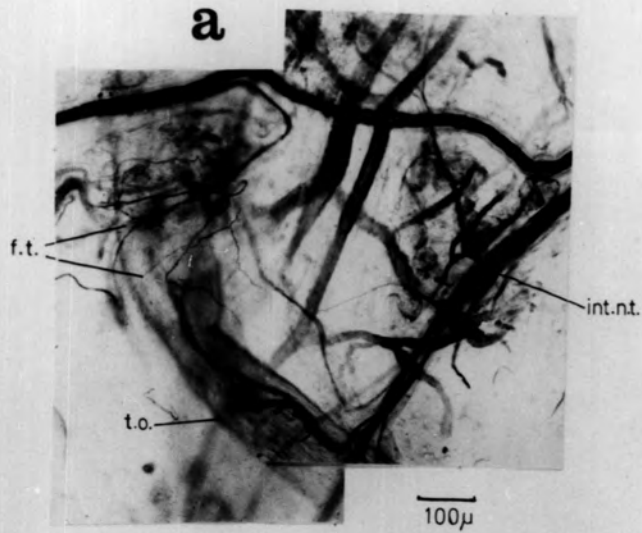


Figure 32

Paciniiform corpuscles

- a. A single corpuscle on the capsule of a tendon organ
 - b. Three corpuscles inside the capsule of a tendon organ
 - c. A single corpuscle in tendon tissue at a musculo-tendinous junction
 - d. A single corpuscle in the permysium between a blood vessel and a small vascular nerve trunk
- (de-efferentated and sympathectomized hindlimb muscle of the cat;
de Castro silver impregnation)

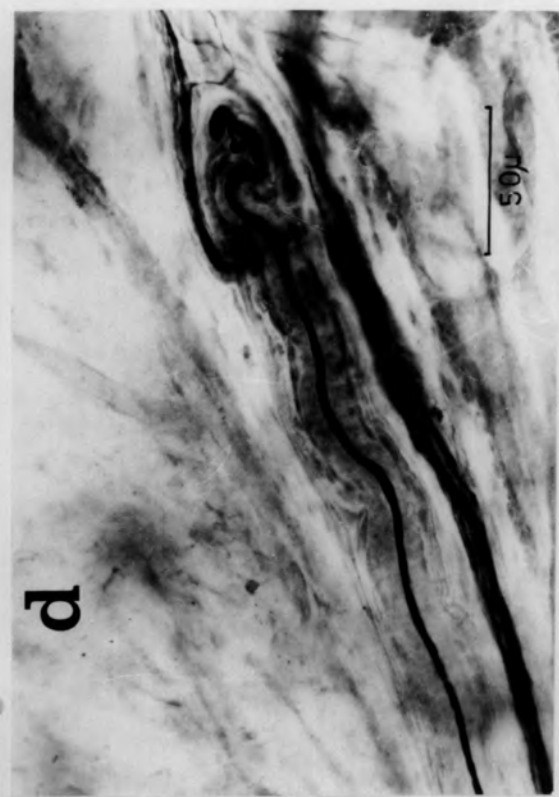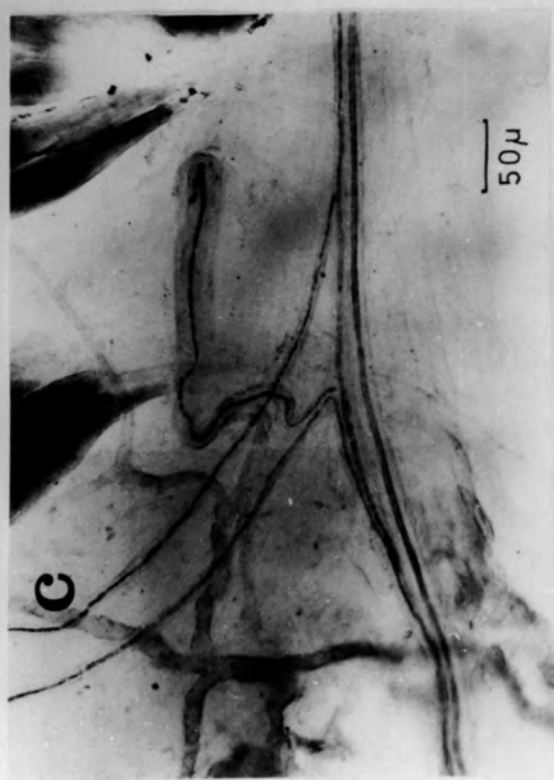
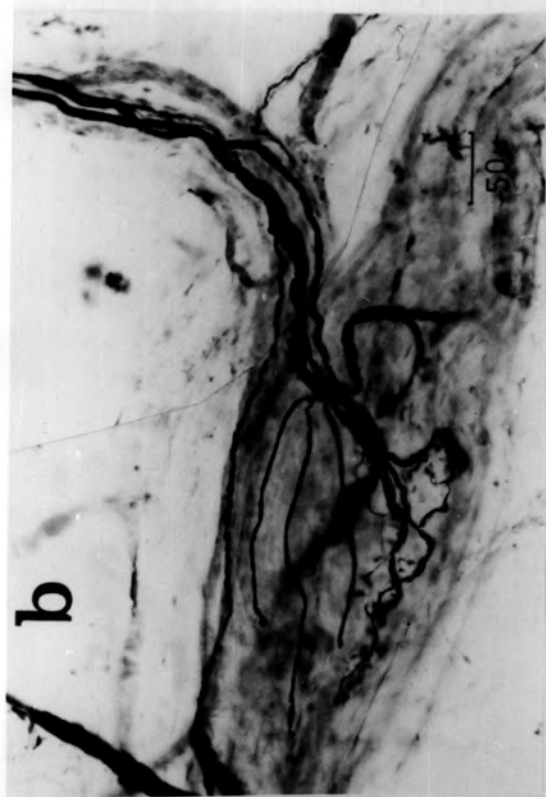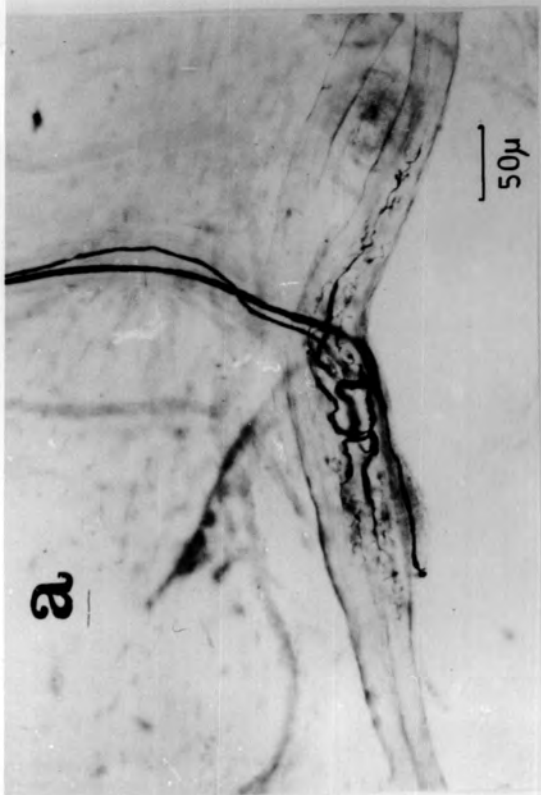


Figure 33

Paciniiform corpuscle innervation derived from Group II parent fibres

- a. Two corpuscles, one inside and one outside of a tendon organ innervated by a 7.0μ (5.0μ) parent fibre
(C178; de-efferentated peroneus III muscle; de Castro silver impregnation)
- b. Five corpuscles on the outside of a tendon organ innervated by an 11.5μ (7.5μ) parent fibre
(C160; de-efferentated extensor digitorum longus muscle; de Castro silver impregnation)

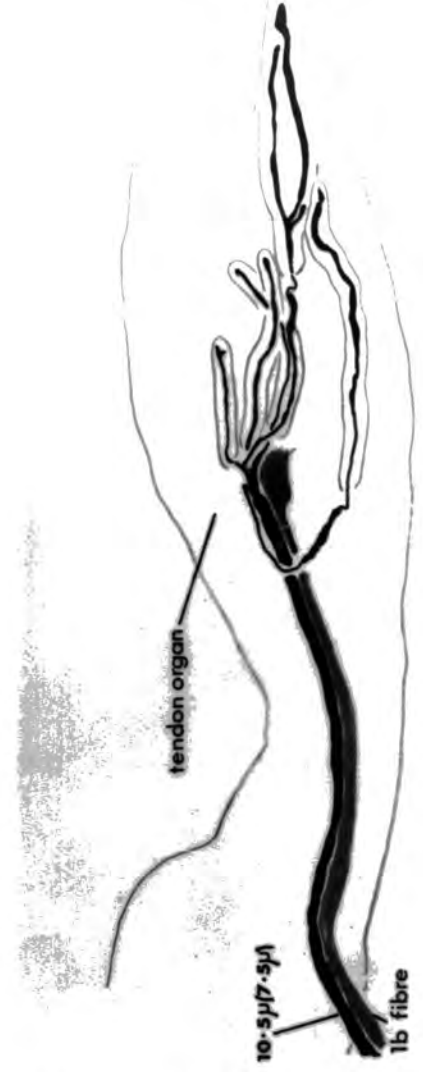
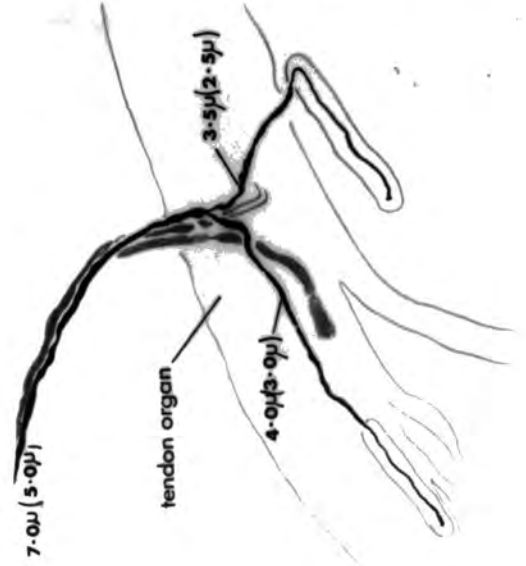
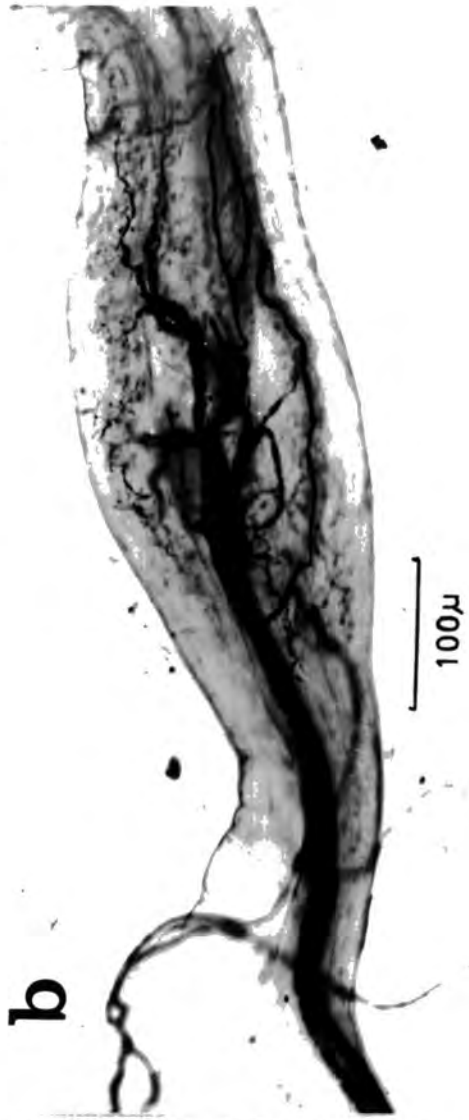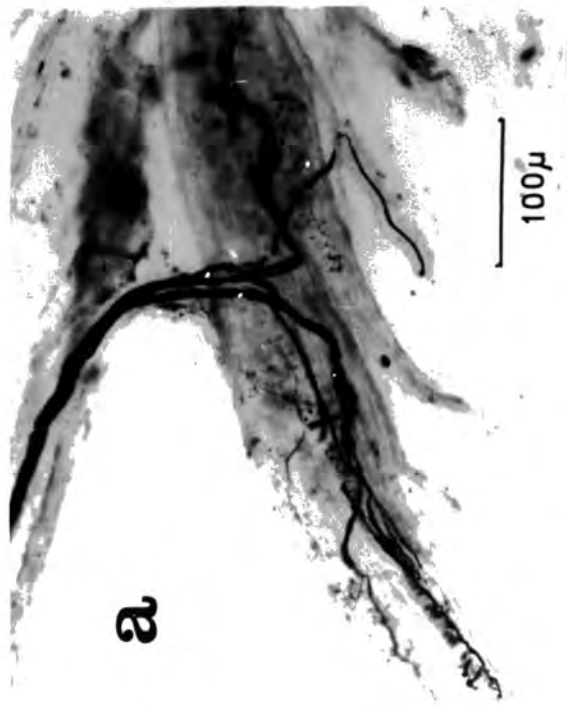
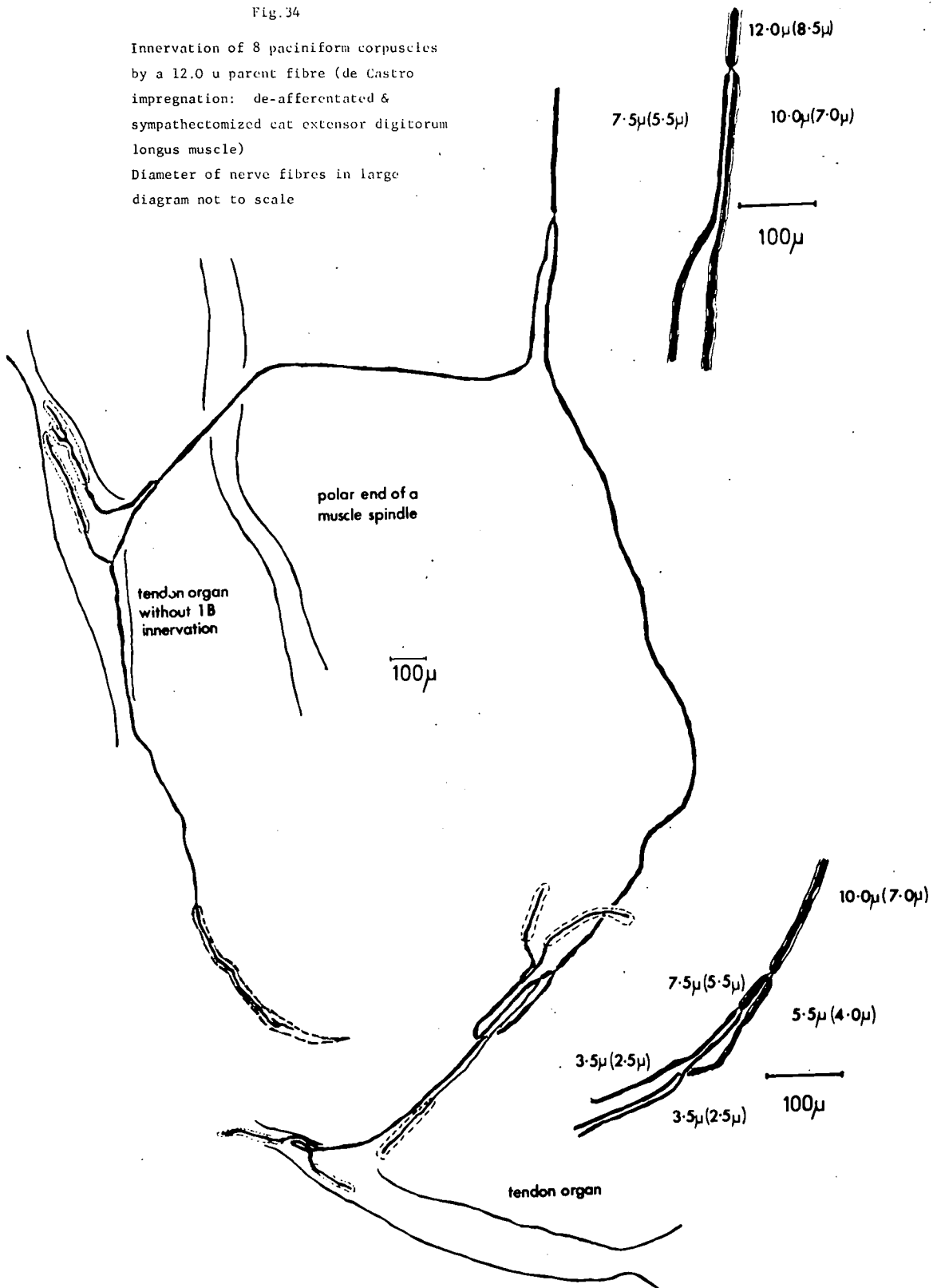


Fig. 34

Innervation of 8 paciniform corpuscles
by a 12.0 μ parent fibre (de Castro
impregnation: de-afferentated &
sympathectomized cat extensor digitorum
longus muscle)
Diameter of nerve fibres in large
diagram not to scale



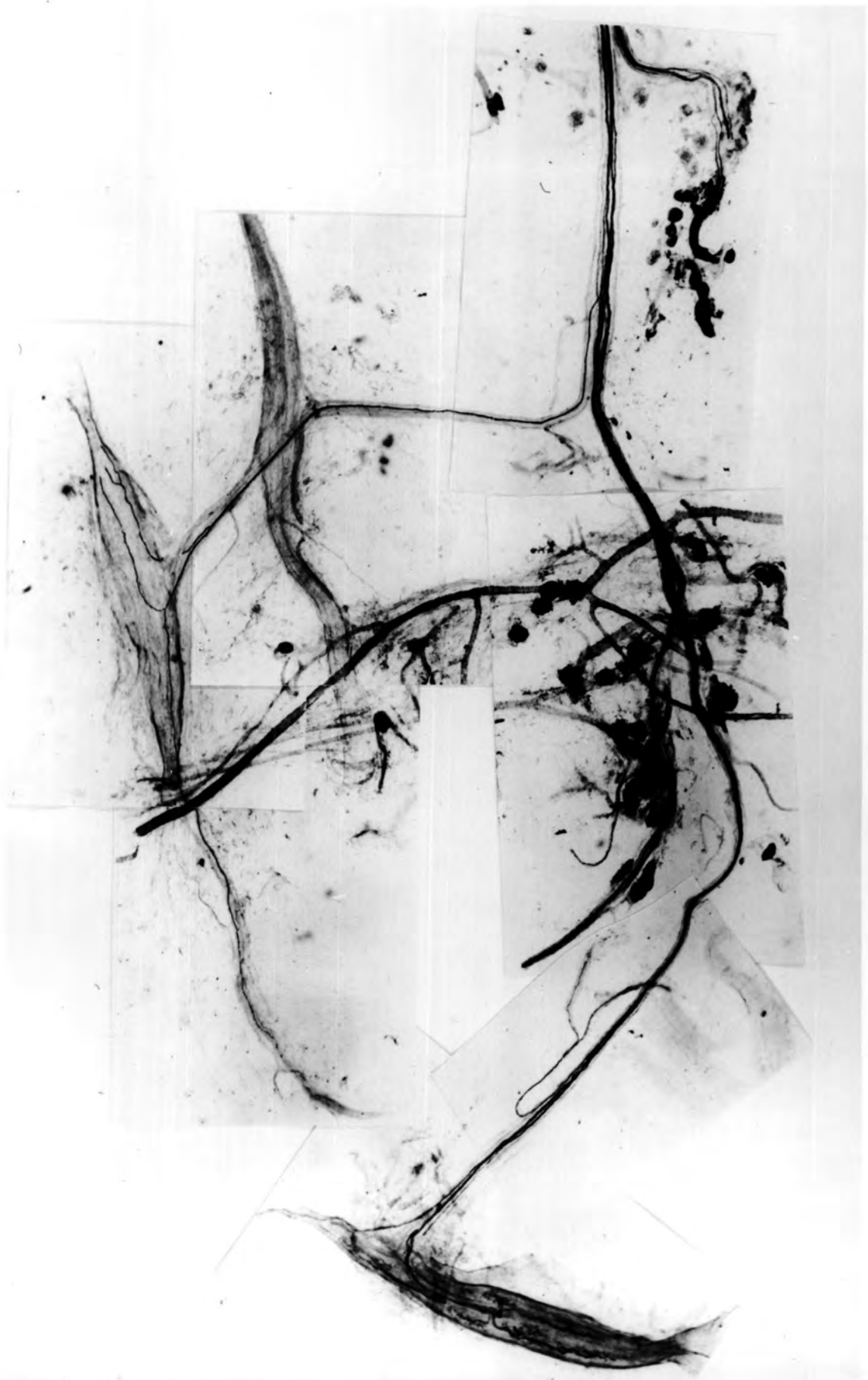


Figure 35

Axon ramifications of free sensory endings

a. n-f.ex. - neurofibrillary expansion

t.ex. - terminal expansion

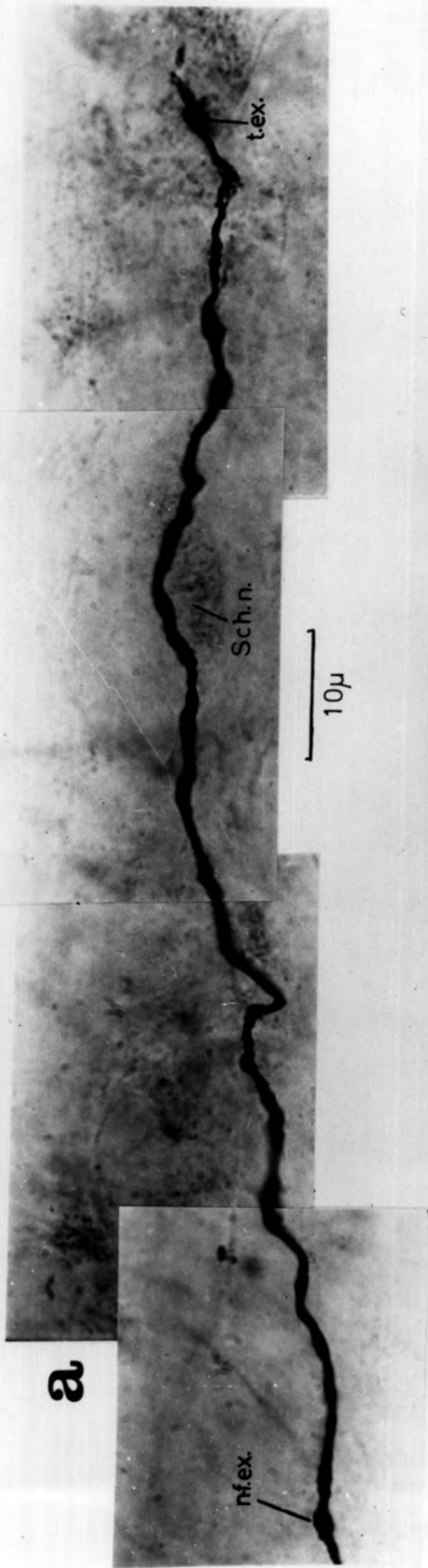
Sch.n. - Schwann-cell nucleus

b. t. - axon terminal ramifications

(de-efferentated and sympathectomized cat hindlimb

muscle; de Castro silver impregnation)

a



b

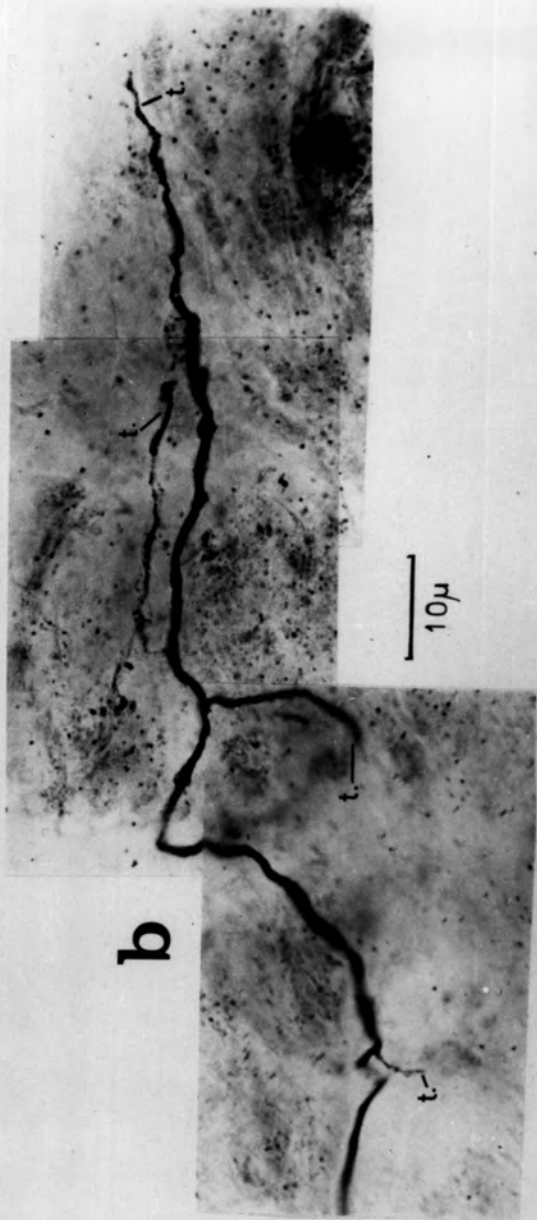


Figure 36

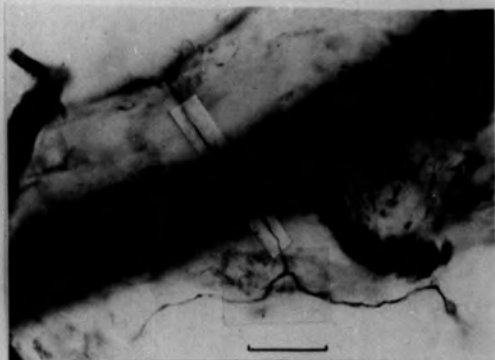
The form of the free ending

- a. Simple ending with two terminal ramifications
- b. Intermediate ending with three terminal ramifications
- c. The same as b. illustrating the terminal node (t.n.)
with subsequent naked axons that are the terminal
ramifications (see Fig.37)

my. - myelin sheath
end. - endoneural tube
- d. Complex ending with six terminal ramifications
(a detailed tracing of this ending is illustrated
in Fig.41)

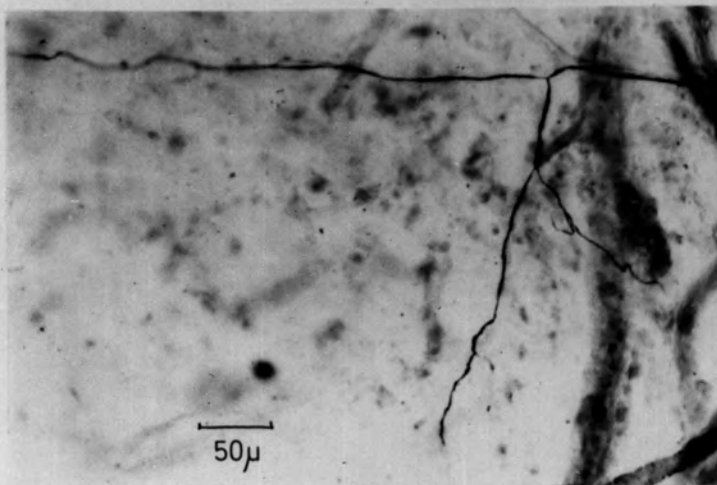
(de-efferentated and sympathectomized cat hindlimb
muscle; de Castro silver impregnation)

a



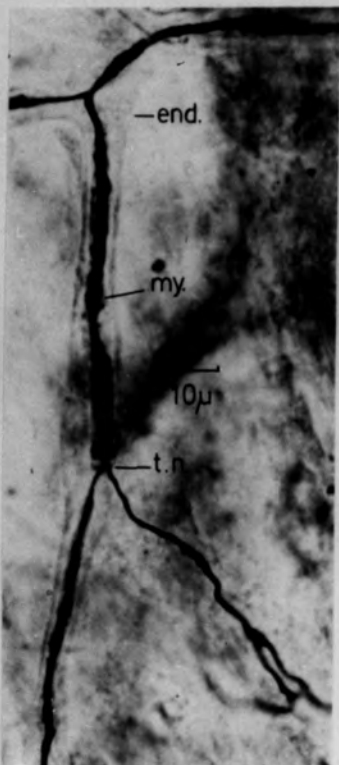
50μ

b



50μ

c



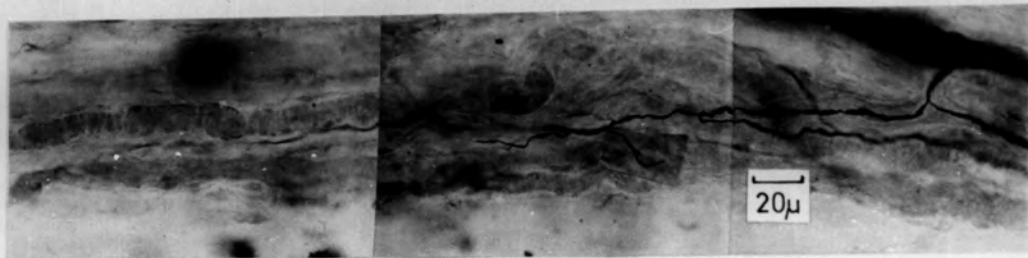
-end.

my.

10μ

-t.n.

d



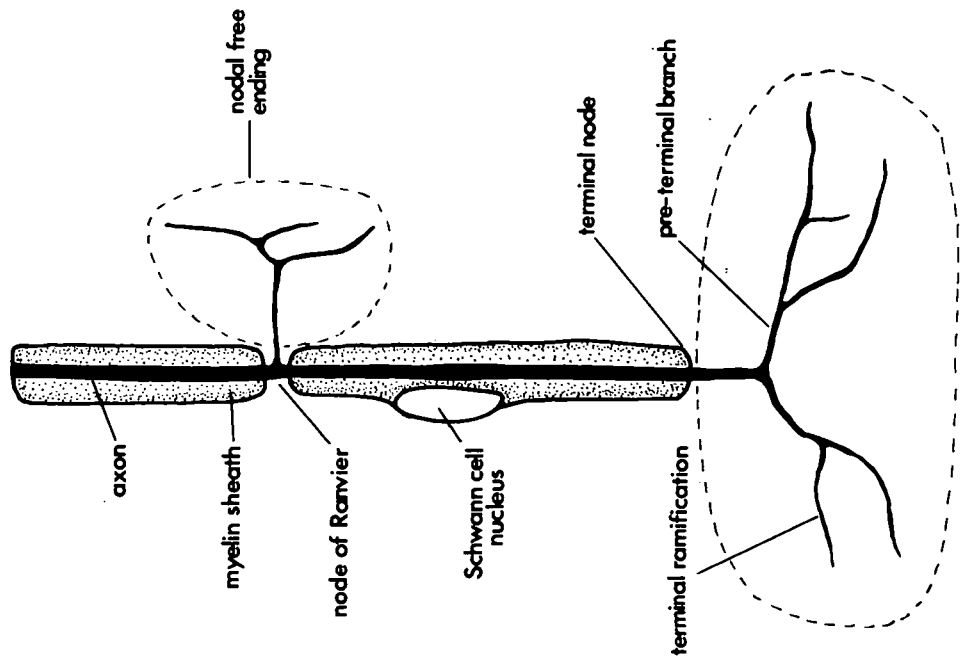
20μ

Figure 37

The classification of free endings

- a. The myelinated-fibre free endings are classified as nodal and terminal
- b. The non-myelinated-axon free endings are equivalent to the terminal type of myelinated-fibre free ending

A



B

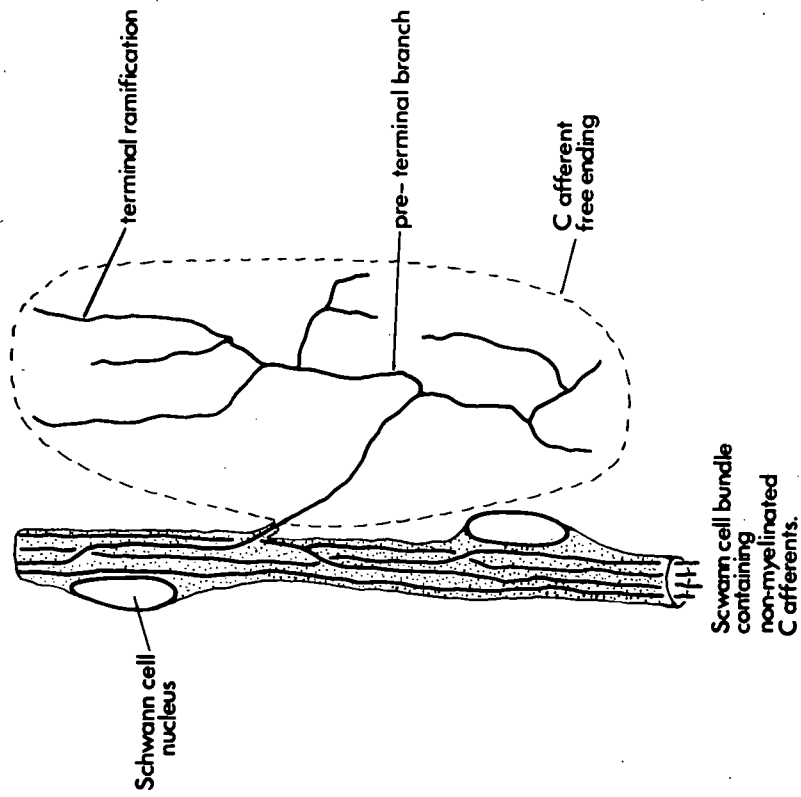
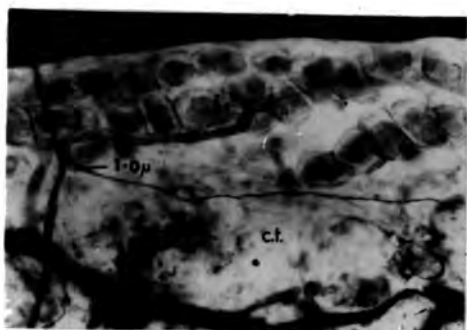


Figure 38

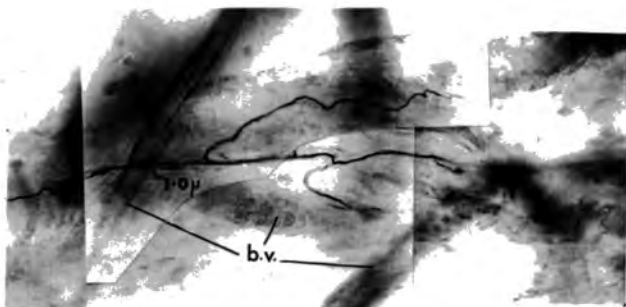
Nodal free endings

- a. Simple type, with terminals in connective tissue (c.t.)
- b. Simple type, with terminals associated with blood-vessel adventitia (b.v.)
- c. Intermediate type: one of the three terminals remains in the small vascular nerve trunk along which it travels in the opposite direction to the myelinated parent fibre
c.t. - connective tissue
b.v.a. - blood-vessel adventitia
- d. Complex type: five terminals are produced from the 3.0 μ parent fibre and are associated with blood-vessel adventitia (b.v.), fat cells (f.c.) connective tissue, and nerve trunk perineurium

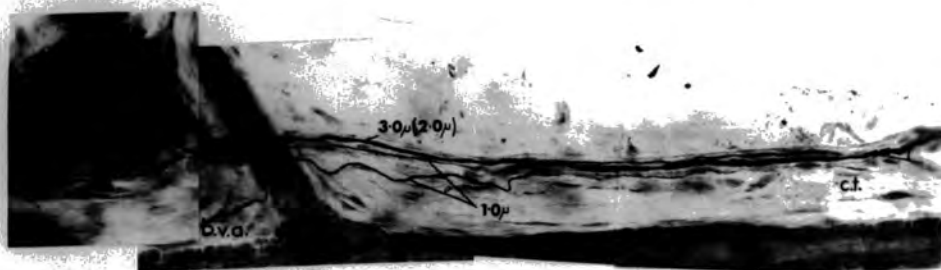
(de-efferentated and sympathectomized
cat hindlimb muscle; de Castro
silver impregnation)



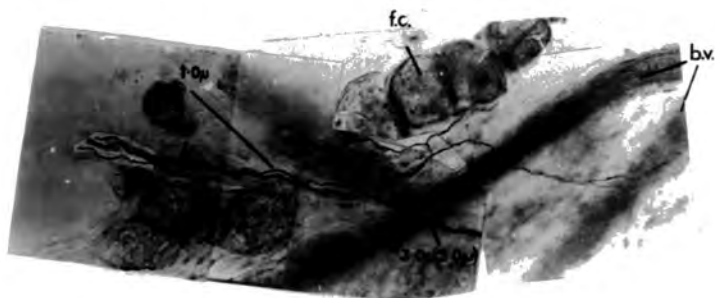
a 50μ



50μ **b**



c 50μ



50μ **d**

Figure 39

Terminal free endings

- a. Complex type
- b. Intermediate type

(de-efferentated and sympathectomized
cat hindlimb muscle; de Castro
silver impregnation)

a

3.5 μ (2.5 μ)

terminal node

arteriole

terminal ramifications
in connective tissue
& blood vessel
adventitia

100 μ

b

3.5 μ (2.5 μ)

3.5 μ (2.5 μ)

3.0 μ (2.0 μ)

1.0 μ

fat cell

terminal node

terminal
ramifications
in connective
tissue

50 μ

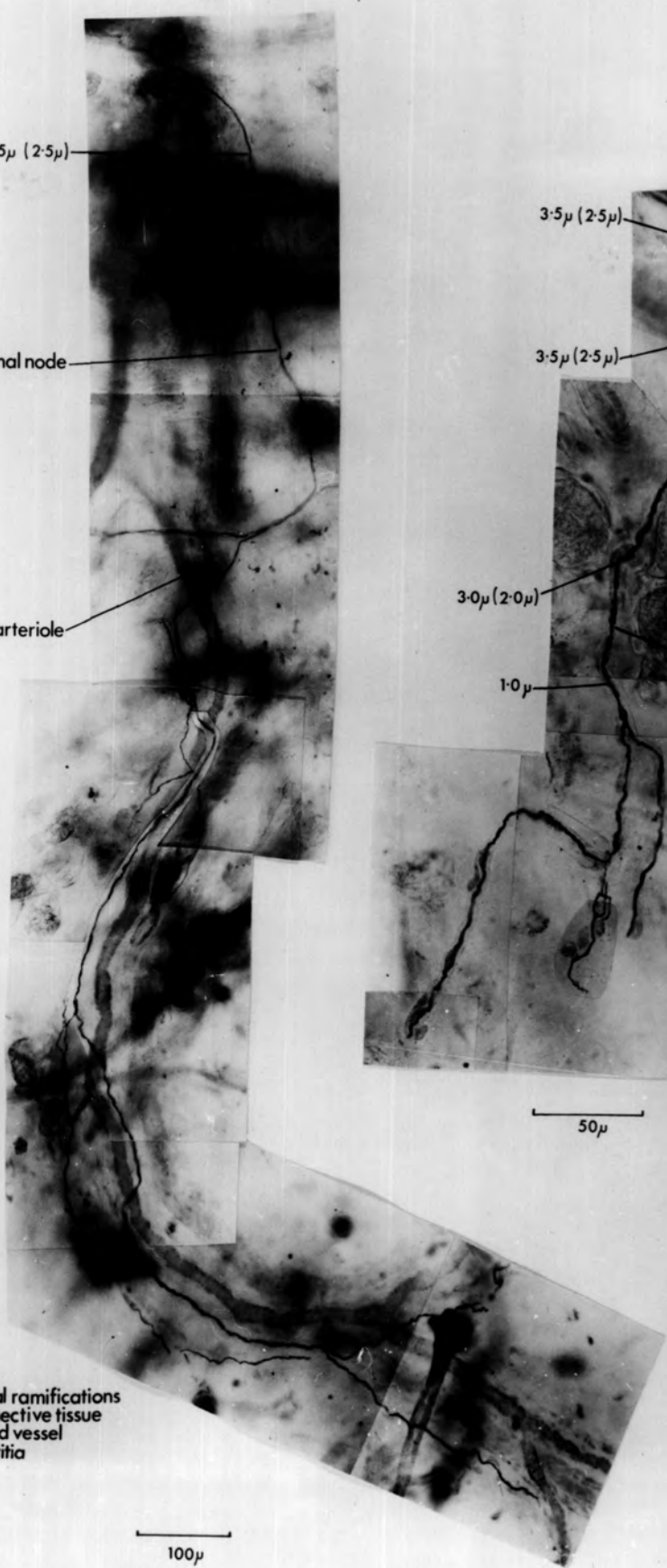


Figure 39 (Cont.)

Terminal free endings

- c. Complex type
- d. Complex type
- e. Simple type

(de-efferentated and sympathectomized
cat hindlimb muscle; de Castro
impregnation)

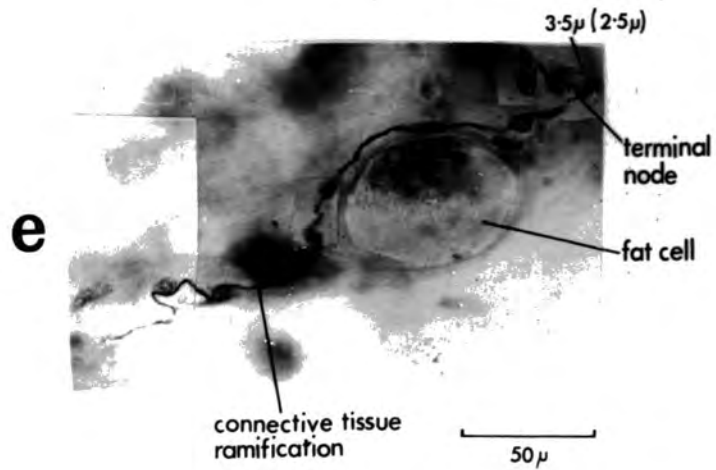
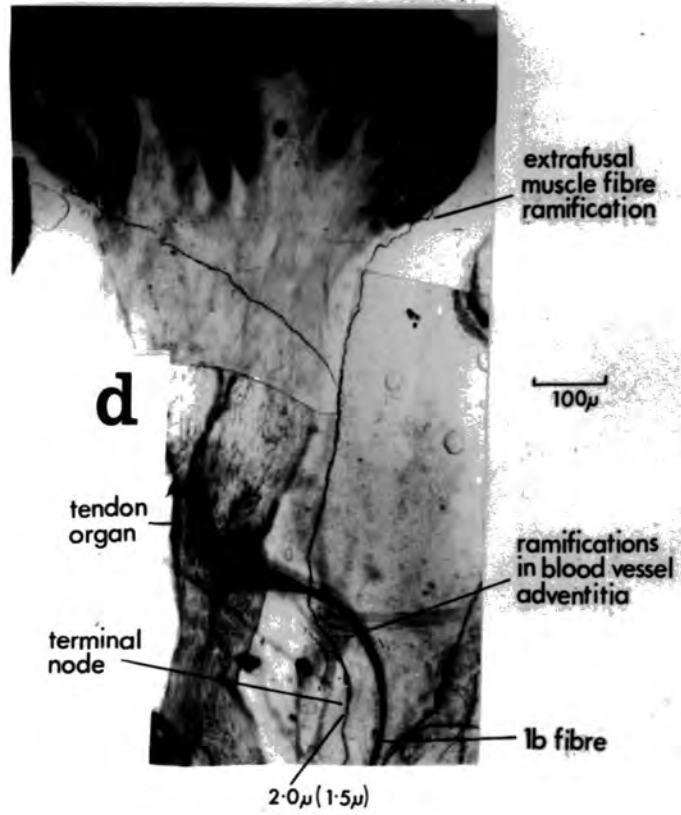
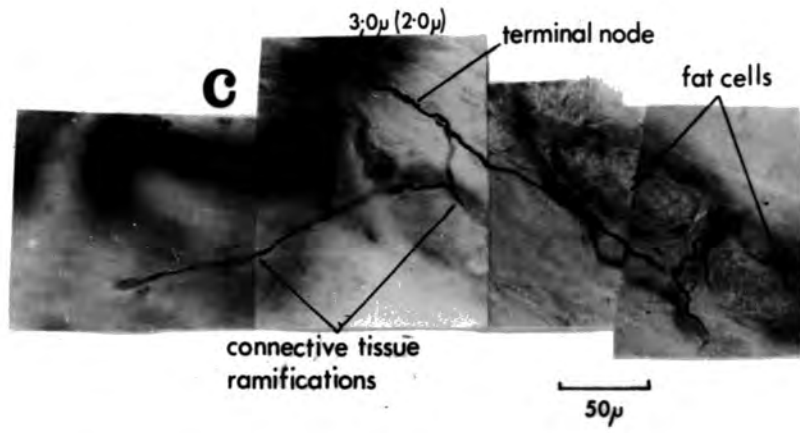


Figure 40

The relationship between nodal endings
of the same myelinated parent fibre

The lower ending is illustrated in Fig. 38d

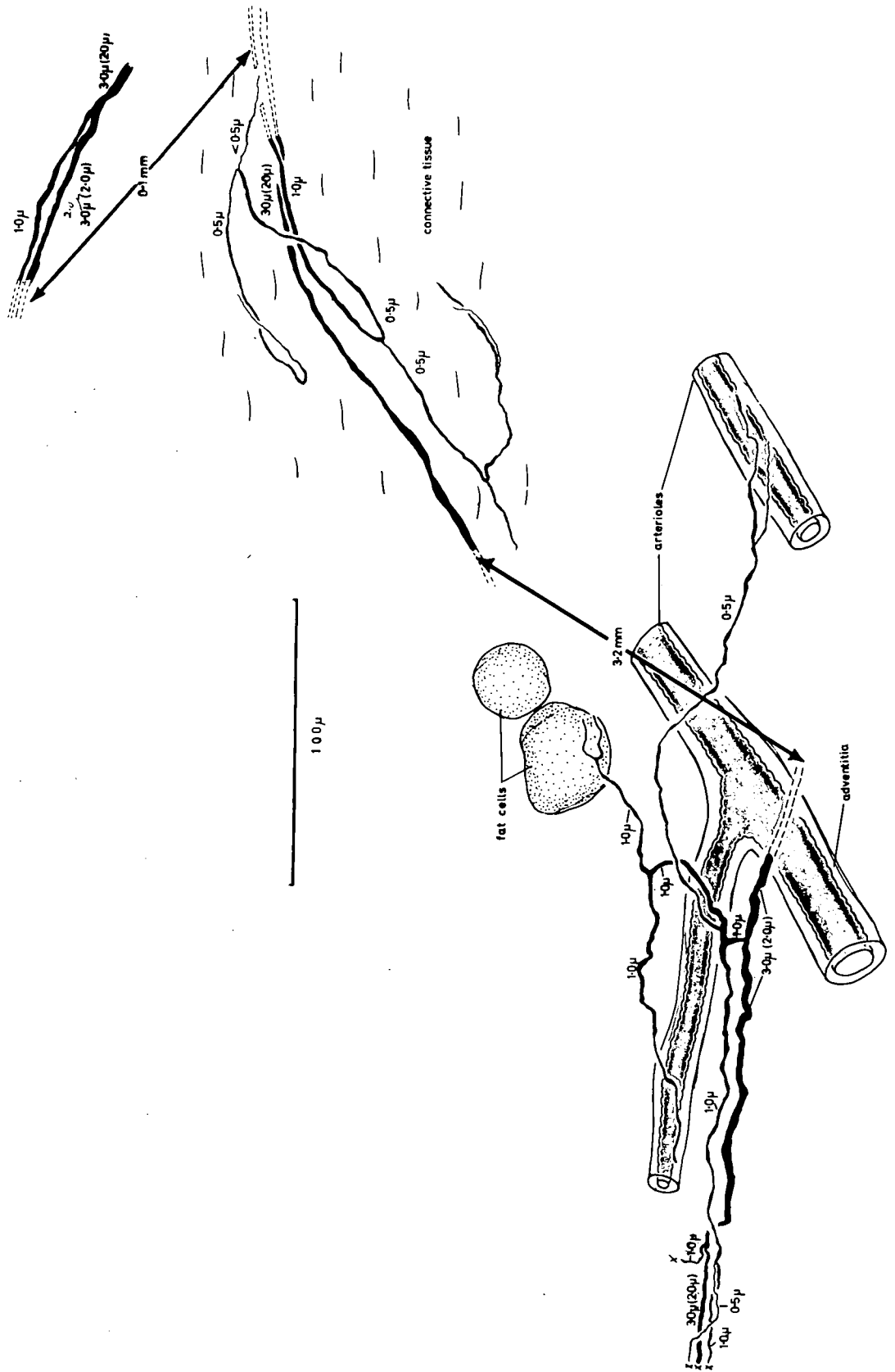


Figure 41

The relationship between a nodal and a
terminal ending of the same myelinated
parent fibre

The upper ending is illustrated in Fig. 36d

The lower ending is illustrated in Fig. 39c

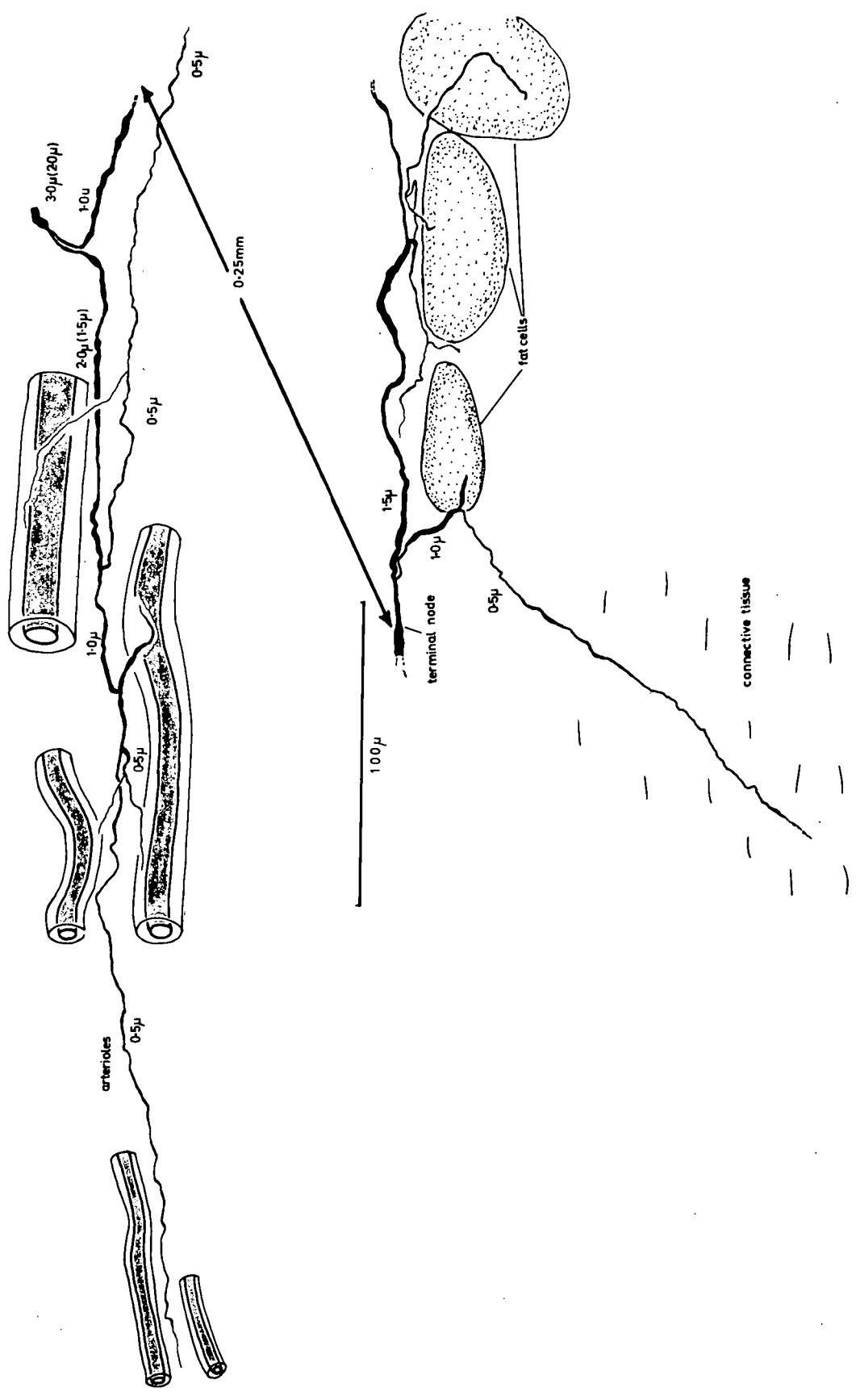



Figure 42

Ramifications of terminal endings from the same
myelinated parent fibre

- b. A ramification in blood-vessel adventitia
- a. Ramifications in connective tissue and
around fat cells

(de-efferentated and sympathectomized
cat hindlimb muscle; de Castro
silver impregnation)



20µ

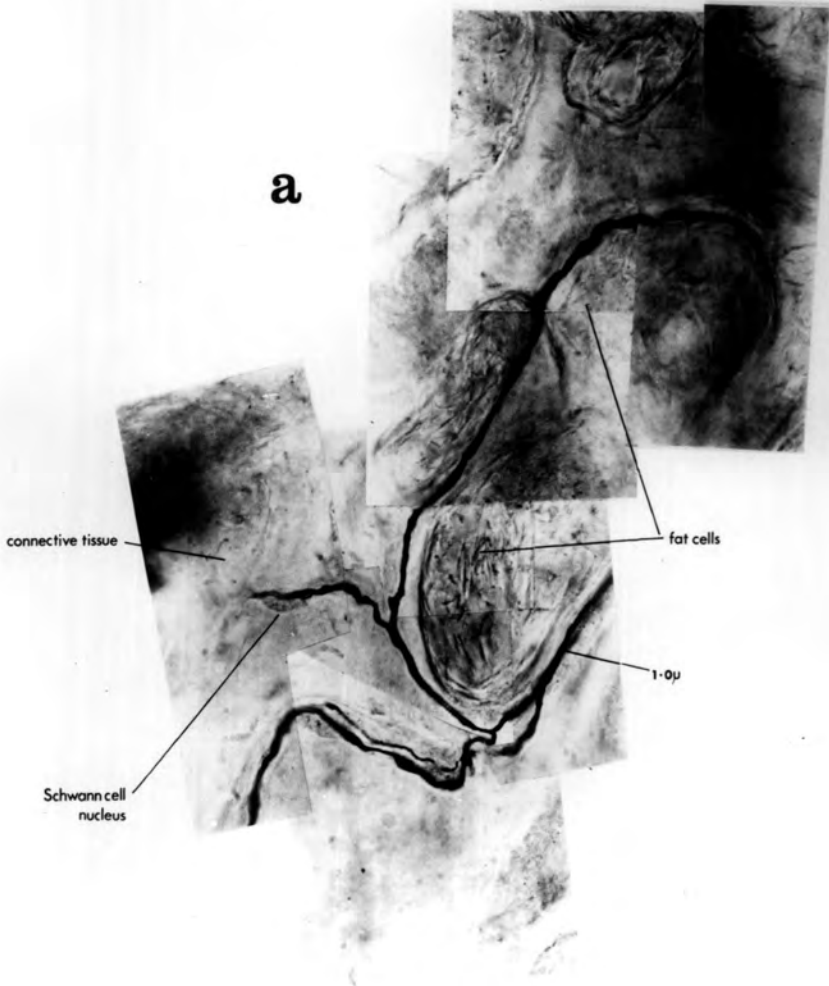


Figure 43

The relationship between the ramifications
illustrated in Figure 42a and b

Both endings with ramifications at a. and b. are derived from the same 5.5 μ (4.0 μ) parent fibre in the small vascular nerve trunk. The position of the terminal nodes is indicated (t.n.). The distance between a. and b. is approximately 0.8mm. The distance between a. and the ramification in blood-vessel adventitia (top right of figure) and also derived from the same parent fibre, is approximately 1.5mm.

(de-efferentated and sympathectomized
cat hindlimb muscle; de Castro
silver impregnation)




Figure 44

Free endings of Group IV sensory axons

- a. Ramifications in connective tissue close to a small intramuscular nerve trunk (I.n.t.)

- b. Ramifications in arteriole adventitia (a.a.)
 - a. - arteriole
 - Sc.b.- Schwann bundle

(de-efferentated and sympathectomized
cat hindlimb muscle; de Castro
silver impregnation)

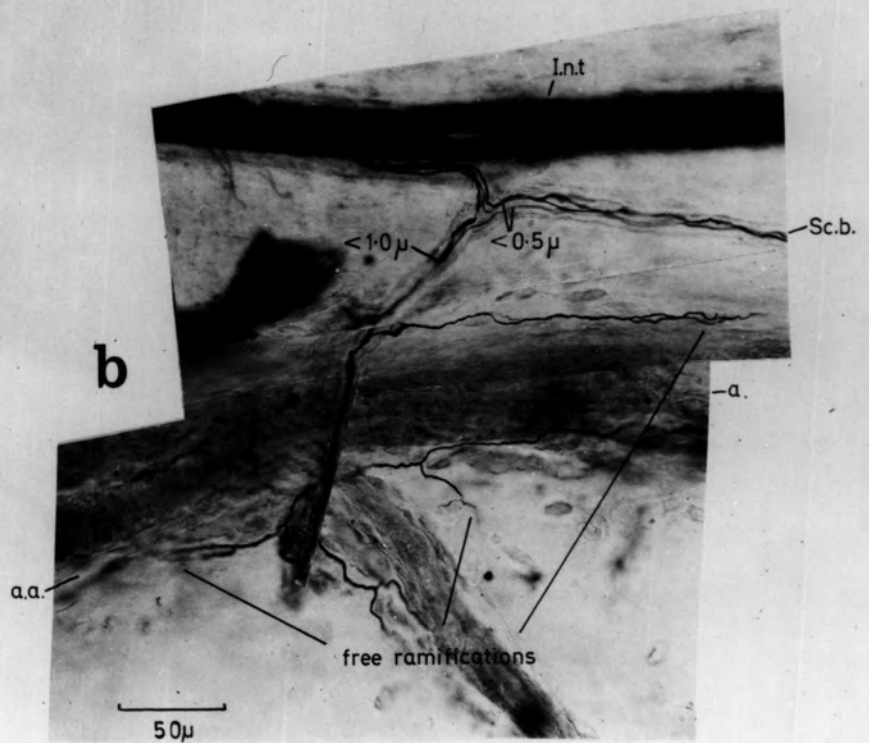
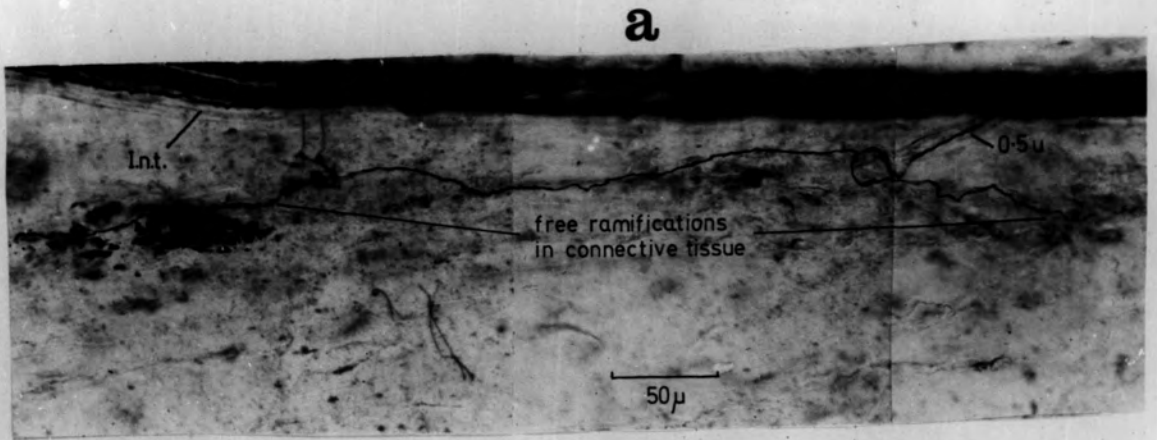


Figure 45

The free ending of a non-myelinated, sensory Group IV axon

The tracing shows the extensive distribution of the terminals that occur in many different planes of focus

The photographs illustrate at high magnification the form of the terminal ramifications in blood-vessel adventitia and the course of the Schwann-cell bundle from which the parent fibre of the ending emerges

(de-efferentated and sympathectomized cat hindlimb muscle;
de Castro silver impregnation)

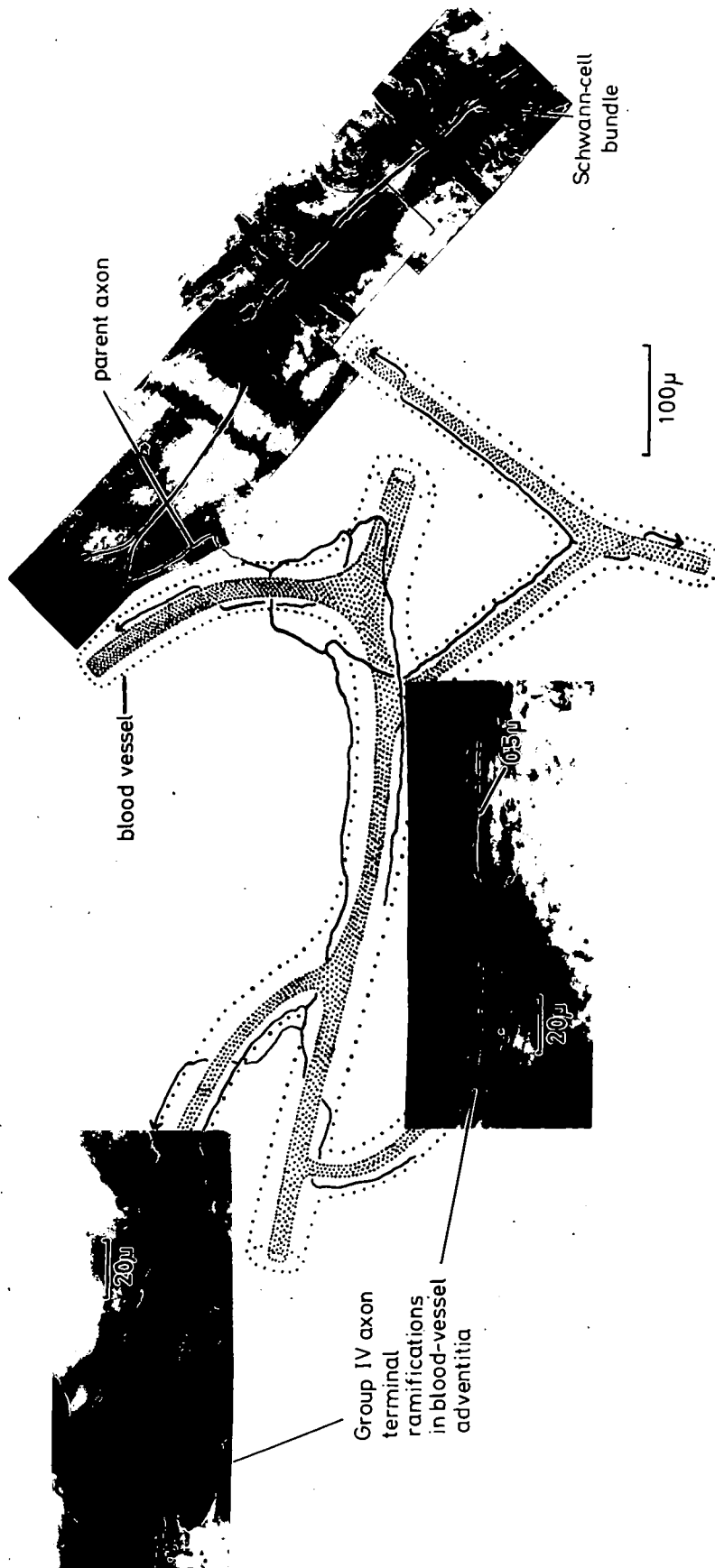


Figure 46

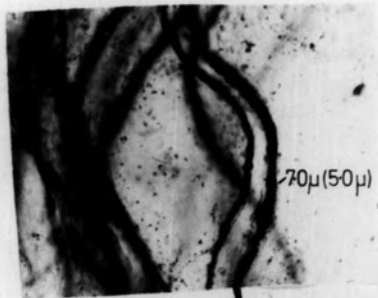The intramuscular course of a Group II sensory fibre
and its free ending terminal ramifications in the
muscle

The terminal ramifications occur in connective
tissue (ct.t.) and among fat cells (f.t.)

The terminals among the fat cells are illustrated
in greater detail in Figure 35b

(de-efferentated and sympathectomized cat
hindlimb muscle; de Castro silver
impregnation)


20 μ



↑ 1.0 mm. nerve entry

5.5 mm

20 μ



0.55 mm



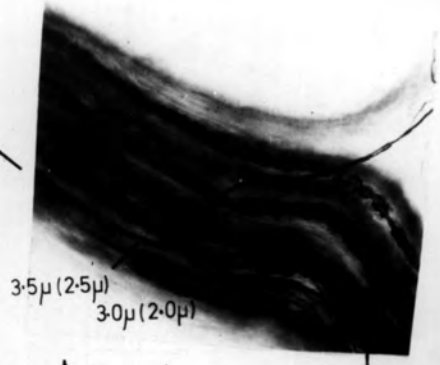
Figure 47

The intramuscular course of a Group III sensory fibre
and its free ending terminal ramifications in the
muscle

The terminal ramifications occur in connective
tissue (ct.t.)

(de-efferentated and sympathectomized
cat hindlimb muscle; de Castro
silver impregnation)

4.0 mm
nerve entry



0.65 mm

100 μ

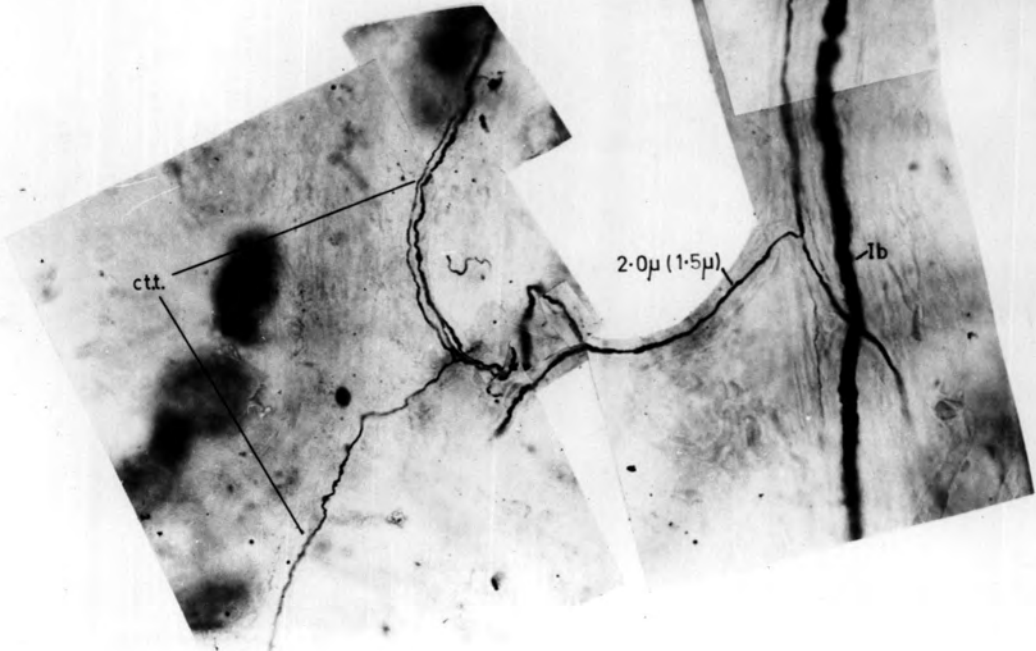
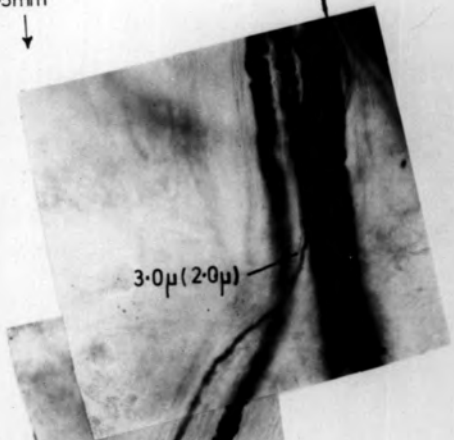


Figure 48

The intramuscular course of a Group IV sensory fibre and pre-terminal branches of the free ending

The terminal ramifications of this ending occur in blood-vessel adventitia and are illustrated in detail in Fig.45

Scw.b. - Schwann-cell bundle in which the free-ending axon courses to nerve entry

(de-efferentated and sympathectomized cat hindlimb muscle; de Castro silver impregnation)

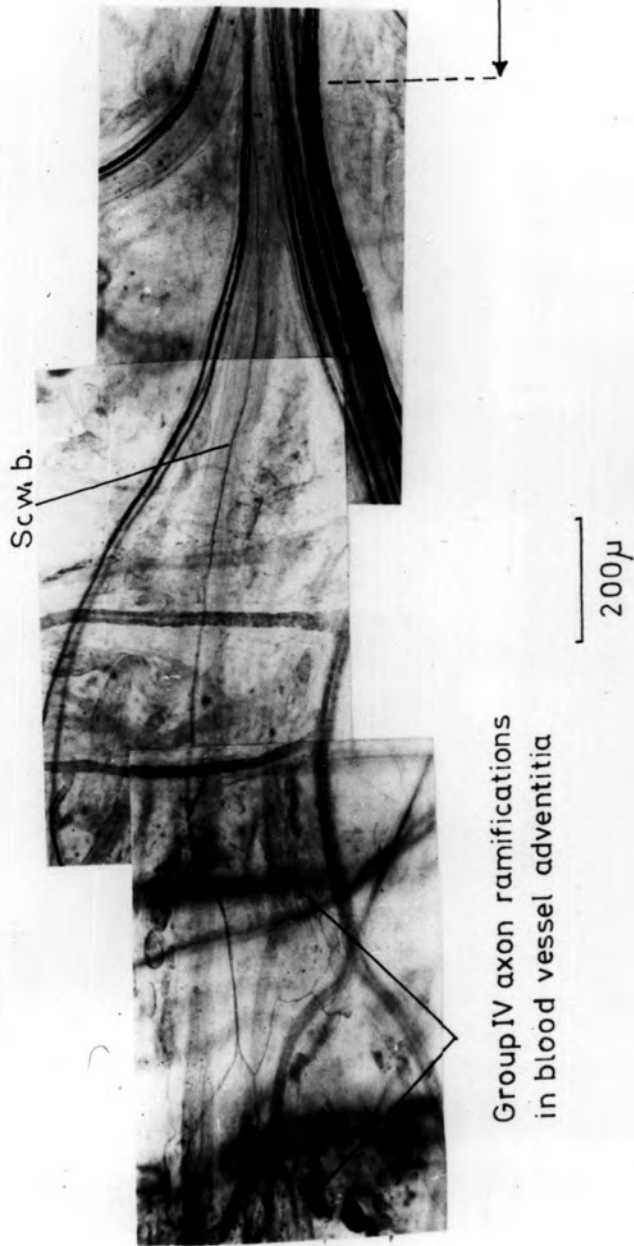


Figure 49

The mode of branching in an intramuscular nerve trunk
of Group I and III free ending nerve fibres

The 100 μ scale line applies only to the individual photographs.

The distance between various points on each photograph is indicated in millimetres (mm)

(C213; de-efferentated and sympathectomized
tibialis anterior muscle; de Castro silver
impregnation)

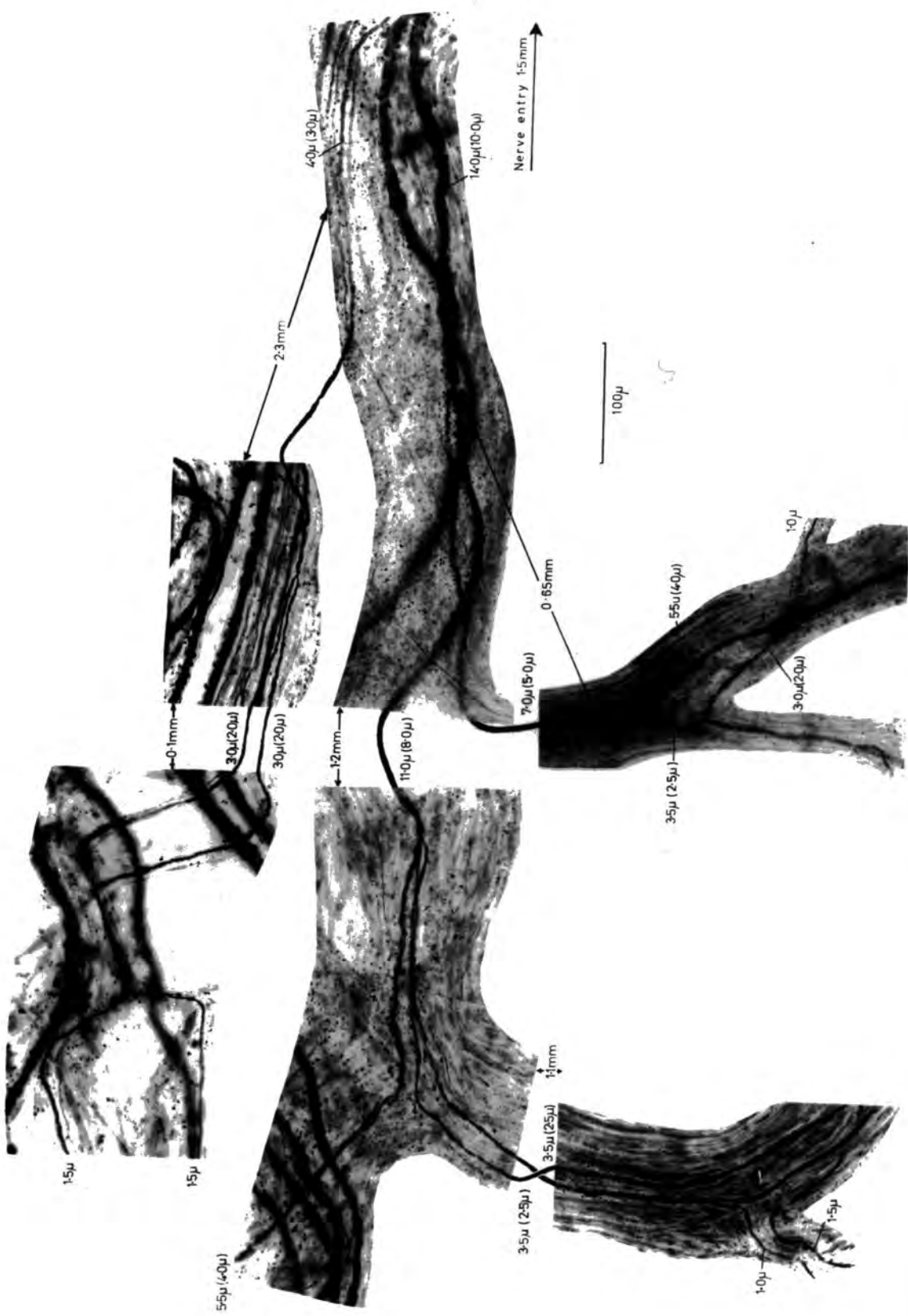


Figure 50

The mode of branching in an intramuscular
nerve trunk of a Group II free-ending nerve fibre

(C213; de-efferentated and sympathectomized tibialis
anterior muscle; de Castro silver impregnation)

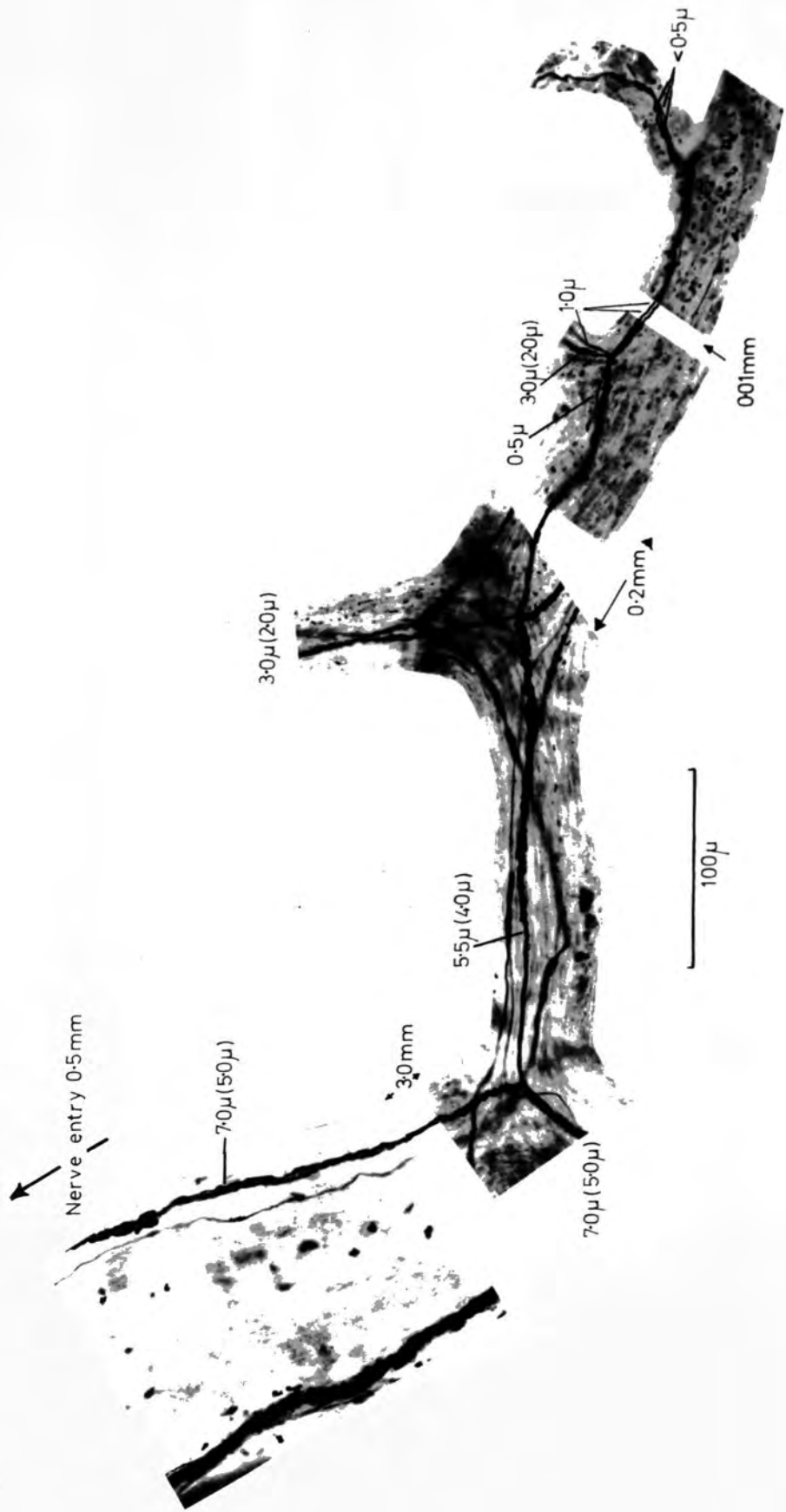


Figure 51

The derivation of small-myelinated fibres and non-myelinated axons of the vascular nerve trunks

- a. A vascular nerve trunk containing small-myelinated fibres (my.) and non-myelinated axons (n.my.)
- b. A small myelinated nerve fibre enters a vascular nerve trunk as a result of larger myelinated parent fibre branching
- c. Direct entry of Group III fibres (my.) from a small intramuscular nerve trunk into a vascular nerve trunk
- d. Derivation of a non-myelinated axon (1.0 μ) in the vascular nerve trunk (v.n.t.) from a myelinated parent fibre (3.0 μ (2.0 μ)) in the intramuscular nerve trunk (i.n.t.)
- e. Non-myelinated (1.0 μ) axon division in an intramuscular nerve trunk (i.n.t.), which produces axons (0.5 μ), that enter a small vascular nerve trunk (v.n.t.)

(de-efferentated and sympathectomized cat hindlimb muscles;

de Castro silver impregnation)

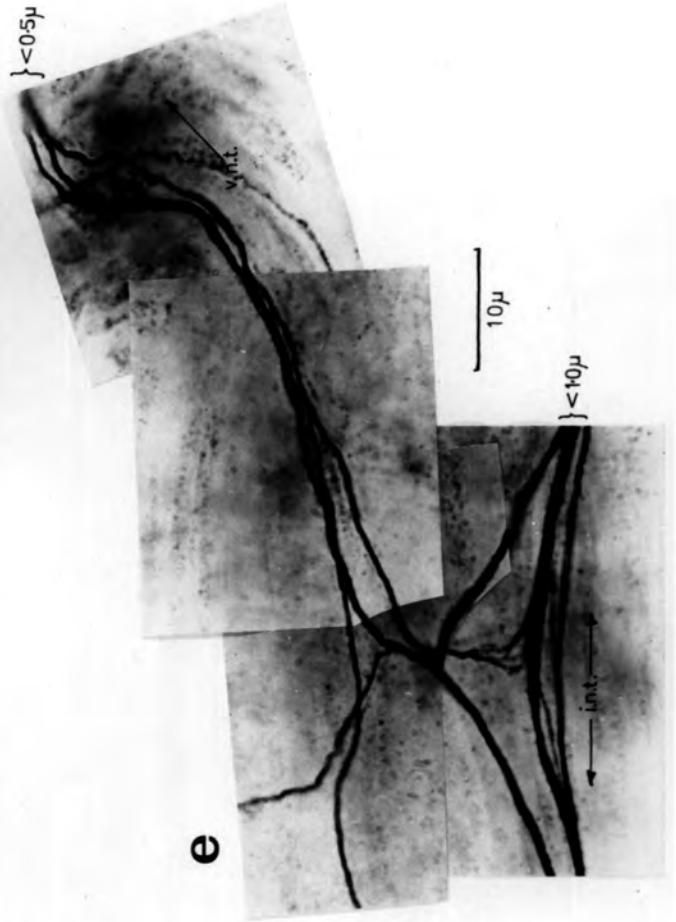
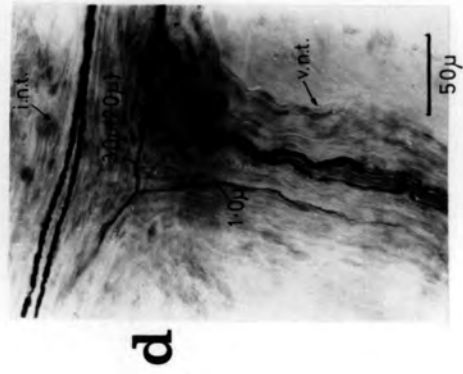
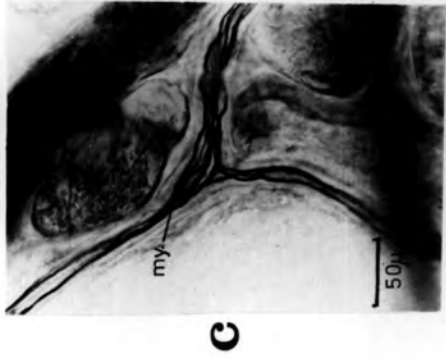

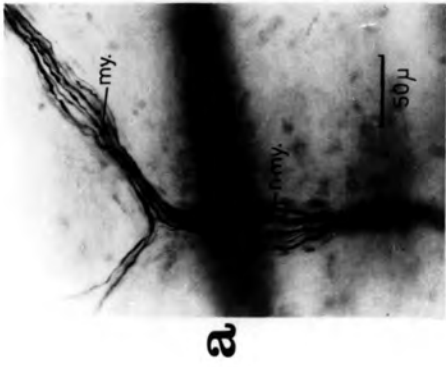


Figure 52

The behaviour of small-myelinated fibres and non-myelinated axons in intramuscular and vascular nerve trunks

- a. A myelinated fibre (3.0 μ (2.0 μ)) produces a non-myelinated axon (1.0 μ) that enters the Schwann-cell bundle of Group IV axons
- b. The myelinated fibre (3.0 μ (2.0 μ)), which is travelling from left to right, produces a non-myelinated axon (1.0 μ) that takes a recurrent path (right to left) in the nerve trunk
- c. The Group IV axon divides twice in this small-vascular nerve trunk and no matter in what direction it is travelling, one of the resultant branches is recurrent in nature

(de-efferentated and sympathectomized cat hindlimb muscle;
de Castro silver impregnation)

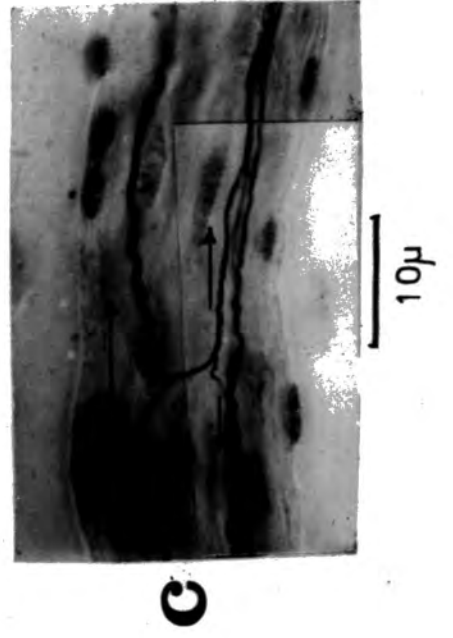
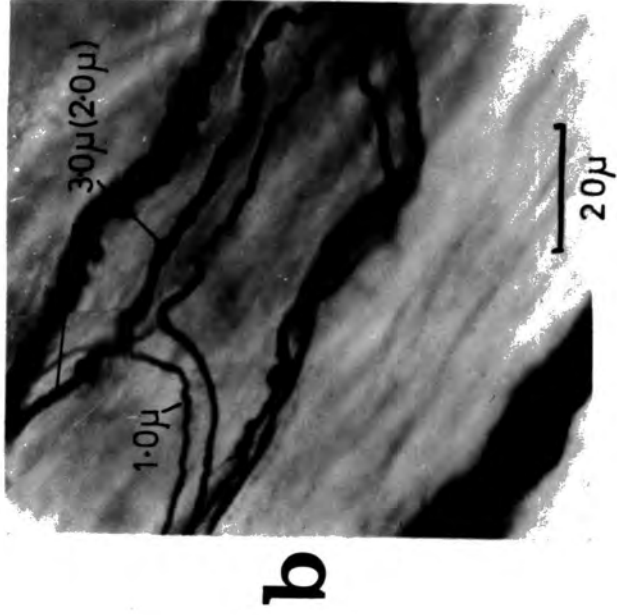
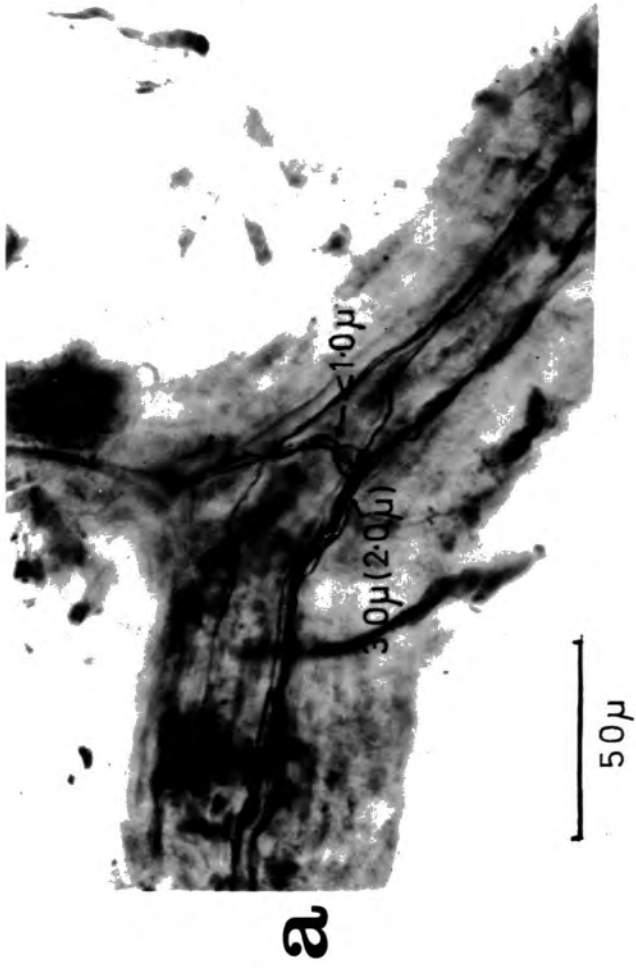


Figure 53

A schematic representation of the sensory innervation
of cat skeletal muscle

- Ia
- Ib
- II - sensory-fibre Group at nerve entry
- III
- IV
- a. - arteriole
- ad. - blood-vessel adventitia
- c.t. - connective tissue (perimysium)
- ep. - epimysium
- Ex.m.f. - extrafusal muscle fibres
- f. - fat deposits
- f.e. - free-ending ramifications
- P. - primary ending
- p.f.c. - paciniform corpuscle
- S₁ - secondary endings
- S₅
- Sp. - muscle spindle
- t.o. - tendon organ
- v. - venule

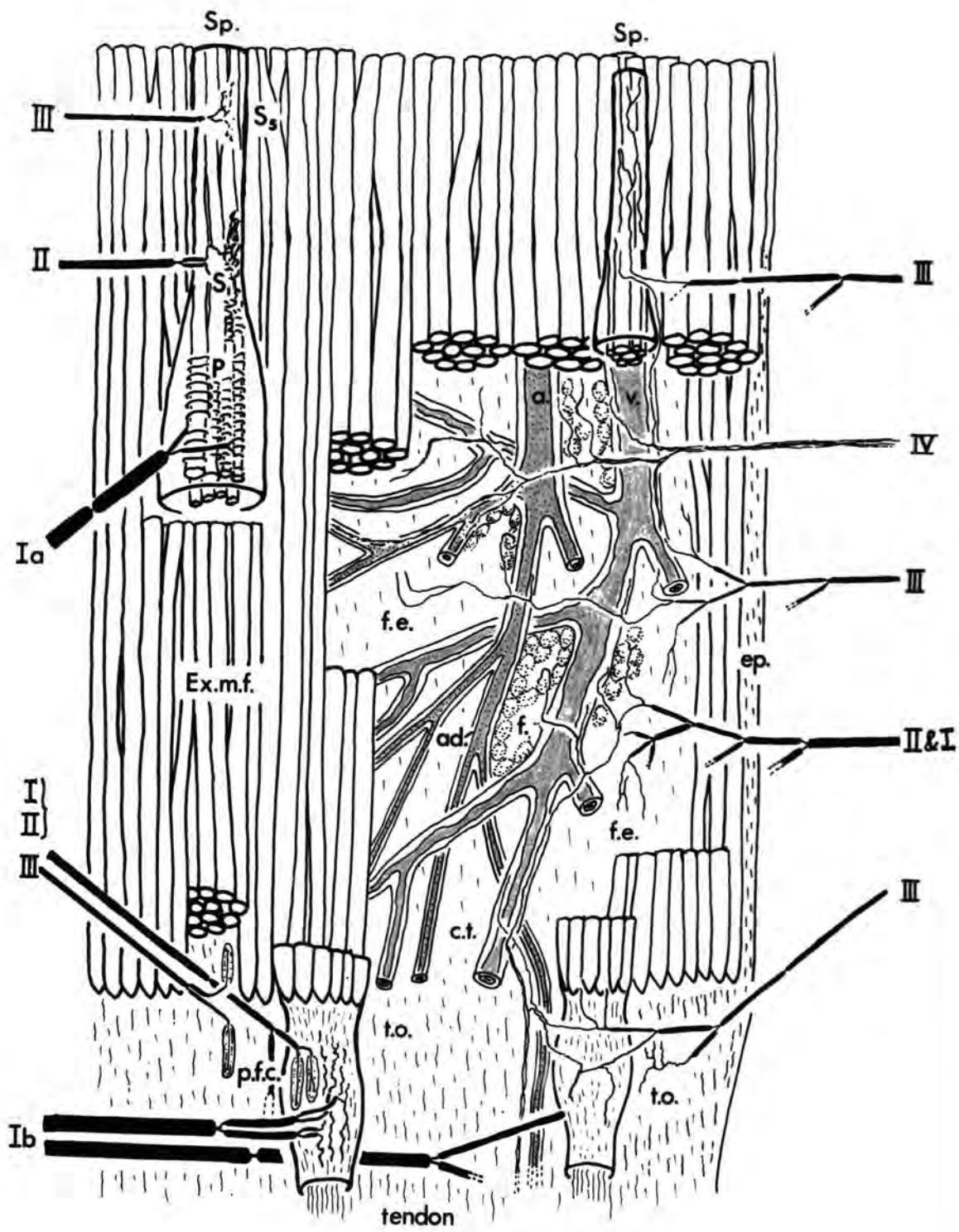


Figure 54

Diagram of the gate control theory of pain mechanisms

A slightly modified version of Melzack & Wall's (1965) original figure.

- T - first central transmission cells
- sg - substantia gelatinosa
- + - excitation
- - inhibition

Figure 55

Cutaneous and muscle sensory input to the pain gate
control system

A modified version of Melzack & Wall's (1965) original figure.

T - first central transmission cells

sg - substantia gelatinosa

+ - excitation

- - inhibition

PAIN GATE CONTROL SYSTEM
(modified from Melzack & Wall)
1965

