

Durham E-Theses

A histochemical and ultrastructural study of vascular innervation in selected human and animal tissues

Janet Elizabeth Kendall

How to cite:

Kendall, Janet Elizabeth (1982) A histochemical and ultrastructural study of vascular innervation in selected human and animal tissues. Masters thesis, Durham University.

Use policy

The full-text may be used and/or reproduced, and given to third parties in any format or medium, without prior permission or charge, for personal research or study, educational, or not-for-profit purposes provided that:

- a full bibliographic reference is made to the original source
- a <https://etheses.durham.ac.uk/id/eprint/7685/> is made to the metadata record in Durham E-Theses
- the full-text is not changed in any way

The full-text must not be sold in any format or medium without the formal permission of the copyright holders.

Please consult the [full Durham E-Theses policy](#) for further details.

A HISTOCHEMICAL AND ULTRASTRUCTURAL
STUDY OF VASCULAR INNERVATION IN
SELECTED HUMAN AND ANIMAL TISSUES.

Janet Elizabeth Kendall

B.Sc. (Dunelm)

KENDALL

Being a thesis presented in candidature
for the degree of Master of Science
of the University of Durham.

The copyright of this thesis rests with the author.
No quotation from it should be published without
his prior written consent and information derived
from it should be acknowledged.

October 1982

St. Mary's College
University of Durham



-5. DEC. 1983

DECLARATION

I hereby declare that the work in this thesis is entirely my own and that no part has been previously submitted for a degree in this or any other university.

STATEMENT OF COPYRIGHT

The copyright of this thesis rests with the author. No quotation from it should be published without her prior written consent and information derived from it should be acknowledged.

Janet E. Kendall

Durham

1982

ACKNOWLEDGEMENTS

I would like to express my gratitude to my supervisor Dr. C.J. Jones for his advice and encouragement throughout the project. I am also grateful to him for performing the animal operations and for his thorough and critical reading of the manuscript.

I wish to thank Prof. D. Barker for providing research facilities in the Department of Zoology and I gratefully acknowledge the help of the technical staff of the department particularly Mr. D. Hutchinson, Mr. P. Sydney and Mr. D. Young for photographic work, and Mr. J. Warner, Mrs. C. Richardson and Miss M.I'Anson for technical advice.

In addition, I thank Dr. K.B. Robinson and Dr. J.D. Simnett for the supply of clinical material and the British Heart Foundation for supporting this work.

Finally, I am sincerely grateful to Mr. Robin Vickers, friends from Emmanuel Church and my mother for their constant support and encouragement. I dedicate this thesis to them.

ABSTRACT

A review of the factors regulating peripheral blood flow is presented and the importance of the autonomic nervous system discussed. The purpose of this project was to extend the animal studies on vascular innervation to human tissues and in this way attempt to determine some of the constraints operating in the control of blood flow in particular vascular beds.

A number of techniques designed to identify autonomic subpopulations were employed. Adrenergic nerves were demonstrated by the formaldehyde-induced fluorescence and glyoxylic acid fluorescence techniques, whilst possible cholinergic nerves were shown by acetylcholinesterase staining. The electron microscope was also used to aid identification of autonomic subpopulations through an examination of vesicle populations in nerve endings.

Extensive ultrastructural studies were undertaken on non-lactating human breast and no periarteriolar axon profiles were observed. Ultra-violet fluorescence microscopy and acetylcholinesterase staining also gave negative results indicating that blood flow through the non-lactating human breast is not controlled by autonomic nerves supplying the vessels. Studies on lactating rat mammary gland revealed a rich periarteriolar adrenergic innervation and the possibility remains that such an innervation may be present in the human gland when lactating. No acetylcholinesterase stained fibres were observed around the vessels but the arteriolar walls themselves stained strongly.

Human axillary lymph nodes were examined in the electron microscope and periarteriolar adrenergic nerves demonstrated.

Application of the histochemical and ultrastructural techniques to vessels in the human skin indicated that adrenergic innervation is both sparse and restricted to vessels in the lower dermis. No acetylcholinesterase-positive fibres were observed around blood vessels but the sweat glands were richly innervated.

For all experiments, the techniques were verified by studies on the rat submandibular gland, a tissue which shows dual innervation by both adrenergic and cholinergic nerves.

In the light of these results and those from other authors, discussions on the possible mechanisms controlling blood flow through the tissues are presented.

GLOSSARY

ACh	-	acetylcholine
AChE	-	acetylcholinesterase
ADP	-	adenosine 5'-triphosphate
AMP	-	adenosine monophosphate
ATP	-	adenosine 5'-triphosphate
BuChE	-	butyrylcholinesterase
cAMP	-	adenosine 3',5'-cyclic monophosphate
cGMP	-	guanosine 3',5'-cyclic monophosphate
ChE	-	cholinesterase
DDSA	-	dodecanyl succinic anhydride
DMP 30	-	2,4,6 tri(dimethylaminomethyl) phenol
FIF	-	formaldehyde-induced fluorescence
GABA	-	gamma aminobutyric acid
GAF	-	glyoxylic acid fluorescence
5-HT	-	5-hydroxytryptamine
H ₂ SO ₄	-	sulphuric acid
Hx-E	-	haematoxylin-eosin
KCl	-	potassium chloride
KH ₂ PO ₄	-	potassium di-hydrogen orthophosphate
L-DOPA	-	L-beta-3,4-dihydroxyphenylalanine
LHRH	-	luteinizing hormone releasing hormone
MNA	-	methyl nadic anhydride
NA	-	noradrenaline
NaOH	-	sodium hydroxide
PTH	-	parathyroid hormone
SHR	-	spontaneously hypertensive rats
VIP	-	vasoactive intestinal polypeptide

CONTENTS

	<u>Page</u>
Acknowledgements	i
Abstract	ii
Glossary	iv
Contents	v
Chapter 1	
<u>THE CONTROL OF BLOOD FLOW - A REVIEW.</u>	1
Introduction.	1
The Autonomic Nervous System.	2
Autonomic Involvement in the Control of Arterial Blood Pressure.	10
Factors Involved in Vascular Control.	19
Passive Mechanical Responses	19
Local Environmental Factors	20
Neural Control of Blood Flow	22
Humoral Control of Blood Flow	41
Summary.	45
Chapter 2	
<u>ASPECTS OF THE HISTOLOGY AND ULTRASTRUCTURE OF NORMAL AND MALIGNANT HUMAN BREAST.</u>	64
Chapter 3	
<u>A STUDY OF THE HISTOLOGICAL FEATURES OF THE RAT SALIVARY GLANDS WITH PARTICULAR REFERENCE TO INNERVATION.</u>	78
1. A Histological Study of Features of the Rat Major Sublingual Gland.	78
2. A Histochemical Study of Catecholamines in the Autonomic Nerves of the Rat Submandibular and Major Sublingual Glands.	81

	<u>Page</u>
3. A Histochemical Study of Acetylcholinesterase- Positive Nerves in the Rat Submandibular and Major Sublingual Glands.	89
4. Discussion on the Control of Blood Flow through Salivary Glands.	95
 Chapter 4 <u>A HISTOLOGICAL STUDY OF ARTERIOLES IN HUMAN BREAST AND LACTATING RAT MAMMARY GLAND WITH SPECIAL REFERENCE TO INNERVATION.</u>	 121
1. The Use of Histochemical Techniques to Search for Periarteriolar Nerves in Human Breast Tissue.	121
2. A Histochemical Study of Nerves in Lactating Rat Mammary Gland.	123
3. Discussion on the Control of Blood Flow through Mammary Tissue.	127
 Chapter 5 <u>AN ULTRASTRUCTURAL STUDY OF PERIARTERIOLAR NERVES IN THE HUMAN AXILLARY LYMPH NODE.</u>	 147
A Note on Lymph Node Structure and Function.	150
 Chapter 6 <u>A HISTOCHEMICAL AND ELECTRON-MICROSCOPICAL STUDY OF PERIARTERIOLAR NERVES IN HUMAN SKIN.</u>	 157
Discussion on the Control of Blood Flow through Skin.	164
 Chapter 7 <u>A COMPARISON OF THE SIZE DISTRIBUTION OF THE ADRENERGICALLY INNERVATED RESISTANCE VESSELS IN VARIOUS ANIMAL AND HUMAN TISSUES.</u>	 188
 Bibliography	 192

Chapter 1.

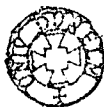
THE CONTROL OF BLOOD FLOW - A REVIEW.

INTRODUCTION

The study of the heart, circulatory system and blood flow in man and higher animals is not hard to justify. Mortality figures for England and Wales in recent years, reveal that over 25% of deaths were due to ischaemic heart disease alone, and if those attributed to cerebrovascular disease (stroke) and conditions related to circulatory malfunction and high blood pressure (hypertension) are included then this rises to over 50% (World Health Statistics Annual, 1979). Diseases of the circulatory system, therefore, account for more deaths than the combined total of all other causes. At the present time, the mortality rate from coronary heart disease for the west of Scotland is the highest in the world. As a result of the extensive studies on the circulation now taking place it is hoped that these figures will be significantly reduced in the coming years.

As well as being the major cause of death, vascular disease also produces serious economic and familial effects. In Great Britain in 1974, for example, over 27 million days were lost from work owing to hypertensive and ischaemic heart disease (Department of Health and Social Security Statistics, 1980). The consequences of this health problem are all too obvious.

In studying vascular disease many different approaches are being employed. Epidemiological studies are being undertaken to identify people and populations at risk, for example, Jews have been shown to be excessively prone to ischaemic heart diseases



(Walker, Segal, Gilat & Horowitz, 1980). The people of North Karelia in Finland have also been found to be at risk and an attempt is being made to reduce the incidence of cardiovascular diseases in the population by reducing the recognised major risk factors of smoking, high blood pressure and high serum cholesterol. Initial results are encouraging (Puska, Tuomilehto, Salonen, Neittaanmaki, Maki, Virtamo, Nissinen, Koskela & Takalo, 1979). Other approaches to tackling the problem come from techniques in transplantation and post-operative care of patients, advances in microvascular surgery and drug therapy together with biochemical and physiological studies on the blood vessels themselves.

In this thesis, the role of the autonomic nervous system in the control of blood flow is being examined as advances in this field should lead to the further development of drugs to relieve angina and hypertension.

THE AUTONOMIC NERVOUS SYSTEM

The autonomic nervous system is involved in processes normally outside the control of the will, including the regulation of heart rate and contractility, the contraction and dilatation of the pupils, bronchi and blood vessels, the movements of the stomach, gut and bladder and the secretion from a number of endocrine and exocrine glands. Autonomic functions, however, should not be considered as totally separate from the control of the will as some people have a remarkable ability to use the will to regulate the heart rate, constrict the pupil of the eye and control intestinal movements.

The autonomic nervous system is divided into two main components; the sympathetic and parasympathetic nervous systems. The original separation of these was based upon differences in anatomy, though they are also distinguished by their distribution, function and chemistry.

Anatomy

The anatomical differentiation of the two components of the autonomic nervous system is based upon their origin and the relative positions of the ganglia. Both systems originate from the central nervous system, the sympathetic nervous system emerging from the thoraco-lumbar region and the parasympathetic from the cranial and sacral regions. Apart from the splanchnic nerve going to the adrenal gland, autonomic nerves are interrupted at ganglia on their way to the target tissue, forming essentially a two nerve system, the pre-ganglionic neuron emerging from the central nervous system and synapsing with the ganglion cell body, and the post-ganglionic neuron extending from the ganglion cell to the target site. In the sympathetic nervous system, the ganglia tend to be close to the vertebral column or approximately midway between the column and the peripheral target site, thus being called vertebral or intermediate ganglia respectively. Parasympathetic ganglia, however, mostly occupy intermediate or peripheral positions. Synapses at the ganglia are not usually simple but demonstrate varying degrees of complexity.

Function

Distinct differences are seen between the functions of the two nervous systems in terms of the animal's welfare and adaptation to its environment. In general, the sympathetic nervous system

is concerned with emergency situations, certain reflexes and the maintenance of sympathetic tone, whereas the parasympathetic nervous system is predominantly concerned with the day-to-day running of the body, particularly digestion.

Adaptive responses, seen in an animal under stress, and mediated by sympathetic fibres, clearly illustrate the vascular functions of the sympathetic nervous system. Serious disturbances such as asphyxia, haemorrhage and pain produce stress, as do confrontation with another animal and exposure to extreme environmental conditions. In preparation for conflict the animal produces a fierce appearance by the bristling of body hairs along the back and tail. The visual capacity of the animal may be increased by dilatation of the pupils and bulging of the eyes. Relaxation of the bronchial smooth muscle dilates the bronchial tubes, thus making breathing easier. Sympathetic firing also inhibits movement of the gut, the sphincters contract and glucose is mobilised from the liver to meet the greater energy demands. Major vascular changes also occur in response to sympathetic discharge. Both heart rate and cardiac contractile force are increased and redistribution of the blood supply occurs, with blood being diverted from the skin and splanchnic areas to the skeletal muscles where more oxygen and nutriment are needed for fight and flight situations. This diversion is brought about by vasoconstriction in the peripheral tissues and vasodilatation in the skeletal muscle. If a severe haemorrhage should occur, then generalised vasoconstriction takes place so the tissues can adapt to the lowered blood volume. The sympathetic nervous system is therefore able to coordinate extensive physiological changes throughout the body. This is due to the branching of the nerves at the vertebral or intermediate ganglia, enabling a more widespread distribution of

the impulse. Close association between sympathetic nerves and secretion of the adrenal gland also enhances the coordination as some of the released hormones augment sympathetic responses.

Not only is the sympathetic nervous system involved in emergency situations but it makes up the efferent pathway for reflex responses involving blood vessels, sweat glands and hair muscles. In the regulation of heat loss by the skin, the peripheral blood vessels dilate and there is increased evaporation of sweat, both being coordinated through a sympathetic mechanism.

Some tissues, for example heart muscle, blood vessels and smooth muscle of the eye are kept in a constant state of contraction or sympathetic tone. If the sympathetic nerves are sectioned, the muscles relax.

Unlike the sympathetic nervous system, many parasympathetic ganglia are situated close to, or even within the tissue itself, thus they tend to exert more localised effects. In the case of blood flow, redistributions are generally confined to particular areas. The parasympathetic nervous system is also involved in the control of the heart, parasympathetic stimulation reducing both rate and contractility. The resultant heart rate when both systems are intact is therefore a combination of the sympathetic excitatory and parasympathetic inhibitory mechanisms. Parasympathetic vasodilator fibres from the cranial region are known to innervate the tongue and salivary glands, and fibres from the sacral region supply the external genitalia. However, parasympathetic vasodilator mechanisms have been observed in the coronary (Feigl, 1969), cerebral (D'Alecy & Rose, 1977) and hepatic (Koo & Liang, 1979a) circulations and the list continues to grow.

Together with its vascular effects the parasympathetic nervous system has a prime function in controlling digestion where it mediates salivary, gastric and intestinal secretions, accelerates the flow of bile, increases muscular activity of the stomach and intestinal walls, and relaxes the sphincters. Reflex lacrimation and bladder activity are also under parasympathetic control.

Chemistry

One of the most obvious differences between the sympathetic and parasympathetic nervous systems is the identity of the neurotransmitter released at the tissue site. In the two nerve system previously described, neurotransmitter is released from the first nerve to act on the second at the ganglion, and released from the second to act on the target site. In the parasympathetic system this neurotransmitter is the same, namely acetylcholine, and therefore both pre- and post-ganglionic nerves are cholinergic. However, in the sympathetic case, although acetylcholine is the pre-ganglionic neurotransmitter, the catecholamine noradrenaline is released at the target site, thus making the post-ganglionic nerve adrenergic. Many other substances have been proposed as neurotransmitters in the autonomic nervous system and these are discussed later.

Receptors

The site of action of the neurotransmitter released from the autonomic nerves consists of specific receptors situated on the target tissue, which may be muscle, gland or nerve, or on the pre-junctional nerve itself mediating a feed-back mechanism whereby the neurotransmitter may regulate its own release.

The sympathetic component of the autonomic nervous system can be subdivided by the concept of alpha and beta adrenoceptors. This was proposed by Ahlquist (1948) based on the relative potencies for the biological effects of agonists. He examined the ability of six sympathomimetic amines to stimulate a number of physiological processes and although many different responses were examined, only two major series of potency were seen indicating the presence of two general types of receptors. Alpha adrenoceptors mediated mainly excitatory functions, namely vasoconstriction, excitation of the uterus and ureters, contraction of the nictitating membrane, dilatation of the pupil, and also the inhibition of the gut. Beta adrenoceptors mediated mainly inhibitory responses, namely vasodilatation, bronchodilatation, and uterine relaxation and also an excitatory response, cardiac stimulation, having both positive chronotropic and inotropic effects. With the later discovery of specific alpha and beta adrenergic antagonists or blockers, the concept of alpha and beta adrenoceptors became more firmly established. Specific alpha blockers include phentolamine, tolazoline and phenoxybenzamine and examples of beta blockers are pronethalol, propranolol and practolol.

Nickerson (1977) suggested that alpha and beta adrenoceptors rather than being two distinct entities, represent two configurations of the same structure, interconvertible by temperature in the amphibian and mammalian heart. At low temperatures, alpha characteristics predominate whereas at higher temperature beta-type responses are seen. He used phenoxybenzamine to block irreversibly the alpha response at low temperatures and after an increase of temperature, no beta response was obtained. Thus he concluded that the alkylated alpha adrenoceptors were not converted into beta adrenoceptors at the higher temperature. Benfey (1979) disputes

this conclusion saying that the concentration of phenoxybenzamine used was too high to have a specific effect and that a non-specific inhibition of the drug was taking place. Benfey used BHC, also an irreversible alpha adrenoceptor blocker on the frog and rat heart, and a beta response was obtained at high temperature, thus contradicting the interconversion hypothesis.

The alpha and beta receptor concept has proved useful in the study of closely related substances, for example noradrenaline, adrenaline and isoprenaline. When these substances are examined for their effect on blood pressure, noradrenaline acts mainly on alpha adrenoceptors, adrenaline equally on alpha and beta adrenoceptors and isoprenaline on beta adrenoceptors alone. Thus in the case of an asthmatic attack where bronchodilatation should be encouraged, noradrenaline would be of little use whereas isoprenaline would have a significant effect. These catecholamines are also important in the subclassification of beta adrenoceptors by Lands, Arnold, McAuliff, Luduena & Brown (1967). Noradrenaline and adrenaline exercise similarities in potency at beta₁ adrenoceptors which are present mostly in cardiac and adipose tissue. In contrast, beta adrenoceptors in smooth muscle appear to have a greater affinity for adrenaline than noradrenaline. These are called beta₂ adrenoceptors, and are also found in the liver and in human white blood cells. The development of beta adrenoceptor blocking drugs gave further support to the subclassification. Drugs like propranolol block both beta₁ and beta₂ adrenoceptors, practolol and metoprolol preferentially block beta₁ adrenoceptors, whereas butoxamine is selective for blocking beta₂ adrenoceptors (see also Ariens, 1981; Daly, 1981).

9

Alpha adrenergic receptors have also been shown to consist of two major subtypes, namely α_1 and α_2 (reviews, Drew, 1981; McGrath, 1981). Presynaptic alpha adrenoceptors have been found to be present in noradrenergic nerve endings (for references see Langer, Briley & Dubocovich, 1980) where they are involved in a negative feed-back mechanism whereby the transmitter, noradrenaline, can modulate its own release. Pharmacological differences were seen to exist between the post-synaptic alpha adrenoceptors mediating target tissue response (review, Furchgott, 1976) and the pre-synaptic alpha adrenoceptors regulating noradrenaline release during nerve stimulation (Drew & Sullivan, 1980). Differences of order of potency of agonists and antagonists were again used to define α_1 and α_2 adrenoceptors. Other adrenergic receptors have been identified which do not fit into the classical alpha and beta classification, for example the gamma adrenoceptors on the rat basilar artery (Hirst, Neild & Silverberg, 1982). The recent development of radioligand binding techniques (see Lefkowitz, 1980) has permitted the direct analysis of interaction of drugs with the adrenergic receptors and thus gives new insight into the biochemistry and physiology of the receptor structures and the various receptor subtypes.

Cholinergic receptors have also been subdivided into two main types, muscarinic and nicotinic. Muscarinic receptors are present in the parasympathetic nervous system only and are situated at the tissue site. Muscarinic receptors are blocked by atropine. Nicotinic receptors are present at the ganglia of both the sympathetic and parasympathetic nervous systems and responses mediated here are blocked by hexamethonium.

Many other specific receptors are present to varying extents in different species and tissues, on both the effector organ and the pre-synaptic nerve. These include receptors for purine compounds, histamine, dopamine, serotonin, peptides, enkephalin and Prostaglandin E and will be considered in more detail later.

AUTONOMIC INVOLVEMENT IN THE CONTROL OF ARTERIAL BLOOD PRESSURE

Arterial blood pressure is strictly regulated to maintain perfusion of tissues at an acceptable level in a wide variety of physiological conditions. Therefore changes in body position, muscular activity and circulating blood volume are possible without significant changes in blood pressure. This control is brought about by two mechanisms, the first consisting of rapidly acting vascular reflexes and the second consisting of slower mechanisms that adjust the volume of fluid in the body and are thus involved in the long term regulation of cardiac output. The more rapidly acting systems will be discussed here.

Measurement of the arterial blood pressure either directly by inserting a catheter into an artery and connecting it to a transducer or indirectly by means of a blood pressure cuff, produces a pressure pulse where the highest pressure, at the peak of the pulse, is the systolic pressure and the lowest pressure is the diastolic pressure. The mean pressure is the average pressure existing in the aorta and major branches during the cardiac cycle. Integration of the pressure pulse provides the true mean pressure but an approximate value can be obtained by applying the following formula :

$$\text{mean pressure} = \text{diastolic pressure} + \frac{1}{3} \text{ pulse pressure}$$

where the pulse pressure is the difference between the diastolic and systolic pressures.

The level of mean arterial pressure is determined by two variables 1) the cardiac output and 2) the peripheral resistance (see Navaratnam, 1975; Little, 1981) as given by Frank's formula (see Pickering, 1974).

Mean Pressure (mmHg)

$$= \frac{\text{Cardiac Output (ml per sec)} \times \text{Peripheral Resistance (dynes cm}^{-5} \text{ sec)}}{1,330}$$

1,330

If one of these factors is altered then a compensatory change occurs in the other. For example, in muscular exercise a fall in peripheral resistance is offset by an increase in cardiac output. Cardiac output can be altered by a change in heart rate, stroke volume, or both. An increase in arterial pressure will result if an increase in either the cardiac output or the peripheral resistance is not compensated for.

From the earlier description of the autonomic nervous system it can be seen that both sympathetic and parasympathetic components will affect cardiac output and peripheral resistance. It must be clearly stated, however, that many other environmental and physiological factors also affect these parameters, some being independent of the autonomic nervous system. Mean arterial pressure is the resultant of these interacting factors. This is seen for example, in the work of Bevan, Honour & Stott (1969) where marked changes in pressure, seen in a healthy volunteer, correlated with particular events, for example, during coitus, waking and falling asleep, and on receipt of a painful stimulus.

The recent advances in the breeding of spontaneously hypertensive rats (SHR) have been very useful for the study of high blood pressure. In the Okamoto strain of SHR overactivity of the sympathetic nervous system is thought to be involved in the hypertension. Sympathetic activity is certainly enhanced in SHR compared to the normotensive Wistar control rats of comparable ages (see Judy, Watanabe, Henry, Besch, Murphy & Hockel, 1976; Henrich & Eder, 1979; Buccafusco & Spector, 1980; Takeda & Buñag, 1980) and ablation of the sympathetic component has produced greater reductions in blood pressure in the hypertensive strain (Folkow, Hallback, Lundgren & Weiss, 1972; Yamori, Yamabe, De Jong, Lovenberg & Sjoerdsma, 1972; Sinaiko, Cooper & Mirkin, 1980). Prolonged administration of propranolol which reduces sympathetic vasomotor tone also prevented the development of spontaneous hypertension in the rats (Takeda & Buñag, 1980). Increased central cholinergic activity has also been thought to be involved in the development of the hypertensive state in young SHR (Buccafusco & Spector, 1980). A problem in working with the SHR has been one of finding a suitable control. The Kyoto Wistar normotensive rat has proved to be adequate for this purpose although it could be argued that differences other than blood pressure in the rats could be due to genetic variability rather than factors involved in the hypertension. This has been partially overcome by Judy et al (1976) who used SHR as its own control and measured blood pressure and sympathetic nerve activity over a range of ages and thus throughout the development of the hypertension. Both parameters correlated well at varying ages. Furthermore, back-crossed SHR which were genetically selected for normal blood pressure have shown nerve activity identical to the Wistar control rats.

Hypertensive patients also demonstrate increased sympathetic activity compared with age, sex and race related normotensive controls, high plasma catecholamine correlating significantly with mean arterial blood pressure (De Champlain, Cousineau & Lapointe, 1978; Fitzgerald, 1979; Bertel, Buhler, Kiowski & Lutold, 1980; Buhler, 1980; Hong Tai Eng, Huber-Smith & McCann, 1980). The increased noradrenaline content, acting on the post-synaptic alpha adrenoceptors mediating vasoconstriction and thus leading to increased blood pressure, could be brought about by a number of factors. In some patients with essential hypertension there may be a defective neuronal uptake of noradrenaline, thus exposing the adrenergic receptors to high local concentration of transmitter (Esler, Leonard, Kelleher, Jackman, Bobik, Skews, Jennings & Korner, 1980) even though the rate of transmitter release is normal (Fitzgerald, 1979). Beta blockers have been extensively used to relieve hypertension and their action is thought to be at pre-synaptic beta adrenoceptors. These receptors are involved in a positive feedback mechanism which is activated by low noradrenaline concentrations in the synaptic cleft and which potentiates the release of noradrenaline, thereby increasing the sympathetic response. Beta blockade of these receptors would decrease the release of noradrenaline at the sympathetic nerve endings (De Champlain et al, 1978).

A further factor in the development of hypertension may be decreased post-synaptic beta adrenoceptor sensitivity or reactivity. Bertel et al (1980) showed that an increase in the patient's blood pressure with age is associated with a reduction in beta adrenoceptor-mediated responses. The reduction in the beta dilator effects would allow the alpha constrictor effects to predominate, thus increasing the peripheral resistance (Buhler, 1980).

When hypertension becomes established, there is an increase in resistance associated with a general narrowing of arterioles in the resting state. These are, however, still capable of being dilated by vasoactive agents and therefore control tissue perfusion despite the raised pressure. Hypertension and atherosclerosis appear to be related. In patients with atherosclerosis or medial sclerosis, the large and medium sized arteries can become rigid, losing elasticity and responsiveness to vasodilators. Although this can enhance the hypertensive condition, it is not the primary cause, as atherosclerosis can be present in patients with normal blood pressure. Hypertension, however, can aggravate the atherosclerotic condition (Siedel, 1981).

In essential hypertension, the cardiac output is usually normal and it is the total peripheral resistance that is elevated (Pickering, 1974; Buhler, 1980). It is important to ascertain the causes of this increase, how to overcome it and how to prevent it. It is necessary to recognise those parts of the vasculature providing the greatest resistance to flow and then to study the neural and humoral mechanisms affecting the calibre of such vessels.

Organisation of the Vasculature

The circulation consists of a system of tubes of differing structure and diameter, usually divided into three components, arterial, capillary and venous. Throughout the entire cardiovascular system, however, the lining of vessels is made up of a continuous single cell endothelial layer. In capillaries, this lining constitutes the entire vessel wall but in the larger vessels it is supported by varying degrees of smooth muscle and fibrous tissue.

The arterial system can be subdivided into large elastic arteries, muscular arteries and arterioles. Blood is pumped from the ventricles under high pressure into the larger arteries. These

have a considerable amount of elastic tissue arranged in many concentric layers interleaved by smooth muscle, and the elasticity of the walls together with the wide lumina help to transform the pulsatile flow from the heart into a more continuous stream. The branches of the elastic arteries are individually narrower but collectively wider than the parent vessel and this is seen through the continued branching down to capillary level with the result that blood flow slows down.

With continued branching there is a gradual transition from elastic arteries to muscular arteries, with less elastic and more muscle being seen in the vessel walls. The actual thickness of the vessel wall also increases in proportion to the lumen with the decreasing vessel size. Muscular arteries regulate blood flow to particular regions by constriction and dilatation.

Arterioles are the smallest arterial vessels, having an external diameter of $100\mu\text{m}$ or less, over half of which consists of a very thick muscular wall and the lumen is very narrow. These vessels are the principal points of resistance in the circulation and any remaining pulsatile flow in the blood stream is completely damped by passing through the arterioles. The muscle contracts to varying degrees and exerts a large influence on the volume and pressure of blood by controlling the outflow of the arterial system.

The smallest arterioles, diameter $10\text{--}20\mu\text{m}$, are called metarterioles and these often provide a channel connecting to a nearby venule. Off each metarteriole and larger arterioles come many branches of capillaries which provide a wider pathway in total than the through-channel. At the branch point of each capillary from the metarteriole is a muscular cuff called the pre-capillary sphincter which regulates the amount of blood entering the capillary network.

Although each capillary is smaller than its parent vessel, the large number of branches off one arteriole means that there is an enormous increase in the total cross-sectional area in the capillary bed. In fact, the total cross-sectional area of systemic capillaries is about 1000 times that of the aorta although each capillary is 10^{-7} of its size. The widening of the circuit slows down the blood stream and this, together with the single cell layer of the capillary wall, enables the exchange of material between the tissue and the blood.

On leaving the capillaries, blood flows through venules to veins and finally back to the heart. The venous vessels increase in size but as on the arterial side, the total cross-sectional area decreases towards the heart. Therefore the blood flow increases through the veins but is never as fast as that in the comparative arterial level because the combined cross-section of the largest veins exceeds that of the aorta. Venules and veins have thinner walls, containing less muscle and elastic than their arterial equivalents, thus enabling them to distend more easily. These capacitance vessels add little resistance in the circulation.

Arteriolar Resistance

The factors involved in the laminar flow of Newtonian fluids through a rigid cylindrical tube can be expressed by Poiseuille's law.

$$Q = \frac{\pi (P_1 - P_0) r^4}{8 \eta l}$$

where

Q = rate of volume flow

$P_1 - P_0$ = pressure difference between the two ends
of the tube

r = radius of the tube

η = viscosity of the fluid

l = length of the channel

This cannot be directly applied to blood flow for a number of reasons. Firstly, blood is not a Newtonian fluid, secondly the flow is not steady but pulsatile and not always streamlined but may be turbulent and thirdly, the blood vessels are not rigid. Nevertheless, although the expression cannot be applied mathematically, it does express principles true for blood flow.

Flow resistance can be treated as analogous to a direct current circuit where

$$\text{resistance (R)} = \frac{\text{voltage gradient}}{\text{current flow}} \quad (\text{Ohm's Law } R = \frac{V}{I})$$

For blood flow

$$R = \frac{\text{pressure gradient}}{\text{volume of flow}} = \frac{P_1 - P_0}{Q} = \frac{8\eta l}{\pi r^4}$$

At a given flow, the largest resistance is operative where the greatest drop in pressure occurs, i.e. at the arteriolar level.

From the above equation it can be seen that the principal factors of resistance to blood flow are the calibre and length of the individual vessels and the viscosity of the blood. Since it is

unlikely that the length of vessels and the blood viscosity will alter in normal circumstances then it must be the alterations in the radius of the arteriole lumen that determines resistance

$$\text{i.e. } R = \frac{k}{r^4}$$

For individual resistances (R_1, R_2, \dots) arranged in series, the total resistance equals the sum of the individual resistances.

$$R_T = R_1 + R_2 + \dots$$

For resistances arranged in parallel then the reciprocals are added together.

$$\frac{1}{R_T} = \frac{1}{R_1} + \frac{1}{R_2} + \dots$$

If a parent artery (radius r) gives off several arterioles of radius $r/2$ then the cross-sectional area of each arteriole would be a quarter of the parent vessel whereas the resistance would be 16 times as great. If more than 4 branches were present then the summated cross-sectional area would be larger than the parent vessel but the resistance would be far greater. This explains how arteriolar resistance can be so great even though the total cross-sectional area is enlarging too.

From this it can be seen that the arteriolar level of the circulation, by virtue of the muscular walls and narrow lumen produces a level of very high resistance to blood flow. The calibre

of the vessels is the most important factor involved in the determination of peripheral pressure therefore it is not surprising that these resistance vessels are generally highly innervated for neural control of the vessel size and are also extremely sensitive to circulating hormones and locally released metabolites.

FACTORS INVOLVED IN VASCULAR CONTROL

The factors influencing arteriolar calibre and therefore tissue blood flow can be divided into two main categories, those that are regulated remotely from the vascular bed and those that are controlled in situ. The former group includes the neural control, which is more important in some organs of the body than in others, and the effect of circulating hormones. Included in the second group is the effect of local changes in the environment as a result of metabolic activity, and also the passive mechanical responses of the resistance vessels to varying degrees of stretch.

Passive Mechanical Responses

Fundamental to these mechanical responses is the fact that the smooth muscle of the resistance vessel walls is usually in a state of partial contraction and thus exhibits a resting tone, maintained mostly by the contraction of the outer smooth muscle layers. The resting tone can be demonstrated by removal of all neuroconstrictor influences. Application of vasodilatory drugs to these preparations increases blood flow further indicating that resistance is still present after nerve ablation (see Little, 1981).

It has been suggested that myogenically active pacemaker cells are present in the arteriolar muscle layers and the rate of discharge of these is related to the pressure within the vessel (Little, 1981). Studies on segments of isolated arterioles and their response to changes in transmural pressure, show that a small reduction in pressure results in elastic recoil of the musculature leading to abrupt obliteration of the lumen. When perfusion pressures increase then the arterioles can be passively distended (Navaratnam, 1975). In arterioles, several pacemakers may act independently, at least some of the fibres being constricted at any one time and producing the muscular resistance. The discharge rate of the pacemaker cells is affected by various factors including vasomotor nerves, circulating vasoactive agents and local feedback systems (Little, 1981).

Organs which require a high blood flow rate during high activity, for example the myocardium and skeletal muscle, have a high resting arteriolar tone. Blood flow can be rapidly increased to these tissues by reducing this resting level of muscular tension. In organs where a constant supply of blood is necessary, for example the kidney, there is no need for rapid vasodilatation and they do not possess a high basal tone.

Local Environmental Factors

The metabolic activity of a tissue greatly affects the calibre of the arterioles. When tissues are active, for example skeletal muscle during exercise, then the blood flow increases and vascular resistance falls. This increase in the volume of blood in the tissue has been thought to be due to the vasodilator activity of end-product metabolites released by the tissue as a result

of increased metabolism. These factors accumulate in the environment of the vessels and produce vasodilatation (Pittman, 1981; Watts & Johnson, 1981).

Many vasoactive substances have been considered to be involved in this dilatation including high carbon dioxide and low oxygen pressures, lactic acid, pH, histamine, bradykinin, polypeptides, prostaglandins and adenine nucleotides. The action of these is shown by the examples in table 1.

The metabolic control of local blood flow produces an autoregulation system within the tissue which maintains a supply of blood necessary for the activity of the tissue. This is especially important for organs such as the brain (Thomas & Bannister, 1980) where blood flow needs to be maintained over varying systemic blood pressures.

Autoregulation acts by the following mechanism. If the blood flow to the tissue is insufficient for the level of metabolic activity taking place, the partial pressure of oxygen in the blood and interstitial fluid falls due to the lack of supply, and the partial pressure of carbon dioxide together with the concentration of other metabolites will rise because they are not being removed. These increased concentrations will produce vasodilatation of the resistance vessels and subsequently an increase in blood flow. The increased flow supplies more oxygen to the tissues and washes out the vasoactive metabolites from the vascular bed, with a consequent vasoconstriction.

Neural Control of Blood Flow

Local metabolites, together with the mechanical responses of vessels, have important effects in regulating the calibre of resistance vessels and controlling blood flow through the tissue. The nervous system, however, is able to produce a rapid and coordinated control of blood flow throughout the body, and to synchronize these adjustments with heart rate and stroke volume.

Studies of the neural control of blood flow fall into two main categories - 1) physiological studies of blood flow through tissues, and 2) anatomical and histochemical studies of nerves likely to influence blood vessels. Isolated blood vessels in organ baths have also been examined to ascertain their responsiveness to autonomic stimuli and vasoactive agents and the subsequent metabolic changes in the vascular muscle. Results of some of these studies are listed in tables 1 and 2. This work, however, is naturally limited to larger vessels because of practical considerations.

1) The Physiological Study of Blood Flow

The responsiveness of vascular beds to neural and chemical stimuli has been investigated for over a century, mostly in larger animals such as dog and cat and on readily accessible organs, for example the salivary glands. Improvements in microsurgical techniques have enabled similar studies to be performed on smaller animals such as the rat (for example Thulin, 1976).

Sympathetic vasoconstrictor fibres innervate resistance vessels throughout the body, though the density of innervation varies from tissue to tissue and between species. All vasoconstrictor fibres are noradrenergic, releasing noradrenaline at the neuroeffector site and acting at alpha adrenoceptors. Vasodilator fibres are not as widespread as constrictor fibres but they are essential in certain tissues for blood flow control. Vasodilator fibres are generally cholinergic but can be either sympathetic or parasympathetic, the former being found around the arterioles in skeletal muscle, and the latter innervating the vessels of the brain, external genitalia, salivary glands, tongue, pancreas and possibly the heart, lung, kidney, bladder and rectum (Burnstock, 1980).

Selective stimulation of these nerves produces changes in blood flow in the tissue and these can be measured accurately. Table 2 gives examples of the responses to sympathetic and parasympathetic stimulation of various tissues and vessels in different species. Parasympathetic stimulation tends to result in vasodilatation whereas sympathetic stimulation can have both constrictor and dilator components. Some results are very easily and adequately explained whilst others have stimulated intense research to produce satisfactory explanations. This has been the case with work on the salivary glands (see Chapter 3 for further details).

Nerve stimulation coupled with infusion of specific agonists and antagonists has shown that a complex interaction of factors is involved in the neural control of blood flow and the picture is far from simple.

An important finding is the presence of atropine-resistant vasodilatation demonstrated initially by Heidenhain (1872) in the submandibular gland of the dog, and subsequently in the cat

(submandibular gland, Darke & Smaje, 1972) and rat (submandibular gland, Thulin, 1976; major sublingual gland, Templeton & Thulin, 1978). although the response is atropine-sensitive in the submandibular gland of the rabbit (Morley, Schachter & Smaje, 1966). Atropine-resistance has also been demonstrated for a number of other nerve-mediated responses, including relaxation of the internal anal sphincter in the cat (Garrett, Howard & Jones, 1974), the excitation of urinary bladder in the toad (Burnstock, O'Shea & Wood, 1963) and guinea-pig (Burnstock, Dumsday & Smythe, 1972), the secretion of tracheal mucin in goose (Phipps, Richardson, Corfield, Gallagher, Jeffery, Kent & Passatore, 1977) and the release of pancreatic bicarbonate-rich juice in pig (Hickson, 1970).

Two major explanations are being considered to account for this phenomenon, either that rogue fibres, running with the main nerve, are being stimulated, or that a second neurotransmitter in addition to acetylcholine, is released from parasympathetic nerve endings.

Sympathetic nerves would be a likely candidate in the search for rogue fibres, especially where the atropine-resistant vasodilatation is similar to that mediated sympathetically via beta adrenoceptors. The atropine-resistant response, however, still remained after anti-adrenergic drug treatment, for example with reserpine (Schachter & Beilenson, 1968), which indicates a non-adrenergic mechanism.

In addition to studies of atropine-resistance, it was also demonstrated in work with guinea-pig taenia coli that transmural stimulation would produce relaxation in the absence of adrenergic fibres (see Burnstock, 1972, 1975a). These unexplained phenomena generated much research and have led to the formulation of two hypotheses proposing novel components of the autonomic nervous system.

1) Burnstock (1972,1975a,1979) has proposed a purinergic nervous system, the principal neurotransmitter being ATP. It has been suggested that purinergic nerves innervate the lung, bladder, trachea, eye, oesophagus, retractor penis, seminal vesicles and the gastrointestinal tract together with blood vessels, the latter having shown a high sensitivity to adenine nucleotides and nucleosides.

2) Polak & Bloom (1978) have proposed a peptidergic system, with a number of peptides acting as possible neurotransmitters. Current evidence suggests that vasoactive intestinal polypeptide (VIP) is the principal transmitter involved. Blood vessels are known to be sensitive to a number of peptides (for examples see Table 1) and VIP-immunoreactive fibres have been observed in close apposition to vascular smooth muscle in several tissues including skeletal muscle, genito-urinary tract, gastrointestinal tract, upper respiratory tract (in cat, Uddman, Alumets, Edvinsson, Håkanson & Sundler, 1981), cerebral artery (in cat, Duckles, 1981) and in salivary glands (in cat, rat and human, Wharton, Polak, Bryant, Van Noorden, Bloom & Pearse, 1979).

Physiological studies have also given insight into the regulation of neurotransmitter release and action at the nerve terminal and effector site. Sympathetic nerves mediate both vasoconstriction and vasodilatation via alpha and beta adrenoceptors respectively. During a stimulus period when high concentrations of neurotransmitter are released then the alpha response dominates. When the stimulus is removed the neurotransmitter concentration falls and beta adrenoceptors are activated mediating beta vasodilatation. This differential sensitivity of the receptors to neurotransmitter concentrations is seen in the control of neurotransmitter release from the nerve (Langer, Enero, Adler-Graschinsky,

Dubocovich & Giorgi, 1976; Martinez & Adler-Graschinsky, 1980; Medgett, McCulloch, Rand & Story, 1980; Rand, Majewski, Medgett, McCulloch & Story, 1980; Westfall, 1980). It is proposed that at the beginning of the stimulation period there are low concentrations of noradrenaline present in the synaptic cleft. This will feed back onto beta adrenoceptors on the nerve ending and enhance the amount of neurotransmitter released. As the noradrenaline concentration at the synapse increases then α_2 adrenoceptors will be activated to produce a negative feedback, which dominates the positive beta-mediated feedback, and thus decreases the amount of noradrenaline released. The sympathetic nervous system is therefore not solely a vasoconstrictor system, but has vasodilator properties, but owing to the dominance of alpha adrenoceptor responses these are often only apparent after alpha blockade (for example, in the human forearm, Brick, Hutchinson & Roddie, 1967).

It has been recently shown that many hormonal and neural substances are involved in the regulation of neurotransmitter release by their action on presynaptic receptors, and they thereby influence the concentration of neurotransmitter at the neuroeffector junction (for discussion see Westfall, 1980). The following substances are reported to decrease adrenergic neurotransmission: alpha adrenoceptor agonists, including noradrenaline; purine compounds, such as ATP and adenosine; prostaglandins of the E series; ACh via muscarinic receptors; dopamine via dopaminergic receptors; histamine; serotonin; and morphine and opioid peptides. Substances facilitating adrenergic neurotransmission include beta-adrenergic agonists, ACh via nicotinic receptors, angiotensin, and maybe prostaglandins of the F series together with thromboxanes. These substances can also regulate vascular tone by acting directly on vascular smooth muscle and/or influencing the activity of other vasoactive substances.

Purine Compounds

Adenosine, ATP, ADP and AMP inhibit the release of noradrenaline from nerve ending in a variety of vascular tissues (Su, 1978; reviews, Weiner, 1980; Westfall, 1980) and thus may be involved in the modulation of adrenergic neurotransmission, though the physiological role is as yet unclear. The purine compounds could be released from the adrenergic nerve itself, postjunctional vascular smooth muscle or from purinergic nerves (Westfall, 1980). Considerable data suggest the adrenergic neuron as the source of ATP and adenosine release. In the case of vascular smooth muscle adenosine may be released by an action of noradrenaline of postjunctional sites, and purinergic nerves running close to adrenergic nerves at neuroeffector sites, could release purine compounds which would act on specific receptors on the adrenergic nerve terminal (for references see Westfall, 1980).

Prostaglandins E₁ and E₂

Prostaglandins of the E series, added exogenously, inhibit neurotransmission in many adrenergically innervated tissues (reviews, Hedqvist, 1977; Westfall, 1980). The effect is species and tissue dependent. Inhibition of prostaglandin synthesis facilitates adrenergic neurotransmission (Weiner, 1980) and increases the vascular response to stimulation (Westfall, 1980). These observations have pointed to the possibility that endogenous prostaglandins of the E series contribute to the regulation of vascular tone by acting on adrenergic neurotransmission at some neuroeffector sites. This is thought to occur principally in those tissue where there is considerable production of prostaglandins (Weiner, 1980). Nerve stimulation releases significant amounts of prostaglandin E₂ in

adrenergically innervated tissues, and the site of this release is thought to be mainly extraneuronal (Hedqvist, 1977). Stimulation, therefore, causes the local release of prostaglandins which then feed back onto the adrenergic nerves inhibiting further transmitter release. The physiological importance of this effect is still to be clarified.

Dopamine

Dopamine can act directly through specific vasodilator receptors on vascular smooth muscle, for example in the canine femoral bed (Bell, Conway, Lang & Padanyi, 1975) and has also been shown to decrease noradrenaline release by an action at specific pre-synaptic receptors (Starke, 1977; Hope, Majewski, McCulloch, Rand & Story, 1980; Weiner, 1980; Westfall, 1980). Dopamine-blocking agents, however, fail to enhance transmitter release during nerve stimulation, except when dopamine levels are high, suggesting that under normal conditions dopamine receptors are not involved in a feedback regulatory mechanism affecting adrenergic neurotransmission (Langer et al, 1976; Weiner, 1980). Raised levels of dopamine can be seen in patients treated with L-dopa or dopamine or in some cases of chronic congestive heart failure (Langer et al, 1976). When there is a high concentration of dopamine present in the adrenergic transmitter stores then dopamine is released on nerve stimulation and acts on presynaptic dopamine receptors to inhibit transmitter release (Weiner, 1980; Fredholm, 1981). It has been suggested that the physiological function of this feedback loop is to conserve transmitter during prolonged stimulation periods (Hope et al, 1980).

Acetylcholine

Acetylcholine inhibits the stimulation-induced release of noradrenaline from adrenergically innervated tissues, and this response is mediated by muscarinic receptors, the inhibitory effect being prevented by atropine (Starke, 1977; Westfall, 1977, 1980; Weiner, 1980). As with dopamine, exposure to the blocking agent did not increase transmitter release, indicating that ACh inhibition does not necessarily imply endogenously mediated feedback regulation (Langer et al, 1976). Yet it is possible that cholinergic nerves have a physiological role in modulating noradrenaline release from blood vessels receiving a dual innervation, ACh released by nerve stimulation inhibiting sympathetic neurotransmission by activating muscarinic receptors on adrenergic nerve endings (Weiner, 1980; Westfall, 1980). Perivascular cholinergic nerves have certainly been seen in close apposition to adrenergic nerves (for example, Iwayama, Furness & Burnstock, 1970; Jones, in press).

Histamine

Recent studies have demonstrated an inhibitory action of histamine on adrenergic neurotransmission, mediated by H₂ histamine receptors (Powell, 1979; Weiner, 1980; Westfall, 1980). H₁ receptor antagonists had no effect on the inhibition (Weiner, 1980). A physiological role in modifying the transmission has not been established, although histamine is present in blood vessel walls, nearby mast cells and has also been demonstrated in sympathetic nerves (for references see Westfall, 1980).

Serotonin

Serotonin (5-Hydroxytryptamine) inhibits the vascular smooth muscle response to nerve stimulation and decreases the concentration of noradrenaline released in some adrenergically-innervated tissues (McGrath, 1977). The effect is not blocked by muscarinic, histamine, alpha adrenoceptor or beta adrenoceptor antagonists or following prostaglandin inhibition. It is unlikely to act at presynaptic serotonergic receptors which appear to be different from the postjunctional ones (see Westfall, 1980).

Angiotensin

Angiotensin enhances the release of noradrenaline from some nerve endings upon stimulation, and thereby increases the vascular responses to the nerve stimulation (Starke, 1977; Westfall, 1977, 1980; Weiner, 1980). This facilitation appears to be due to the action on angiotensin receptors on the nerve terminal, mediating both an increase in transmitter synthesis and increased release of noradrenaline per impulse, rather than a blockade of the reuptake mechanism. It also seems likely to play a physiological role, as angiotensin is formed in the blood vessels in concentrations which have been shown to enhance the release of noradrenaline on nerve stimulation (Westfall, 1977). The increase in vascular response to angiotensin may also be due to its direct action on the smooth muscle cells, making them more sensitive to noradrenaline (Starke, 1977).

Prostaglandin F and Thromboxane A₂ and B₂

Prostaglandins of the F series are formed in blood vessels and have been shown to enhance the tissue response to nerve stimulation, though enhancement of noradrenaline release has not been

demonstrated at physiological concentrations (Hedqvist, 1977; Starke, 1977; Westfall, 1977,1980). Thromboxane A₂ and B₂ may also modulate the vascular response to adrenergic stimuli (Westfall, 1980).

2) The Anatomical and Histochemical Study of Nerves Likely to Influence Blood Flow

The early microscopical work on the innervation of blood vessels was limited by the available techniques of silver and methylene blue staining (Grigor'eva, 1962). These methods demonstrate nerve fibres but cannot distinguish different autonomic nerve populations or clearly reveal the relationship of the individual fibres to the effector sites. With the development of specific histochemical techniques, such as catecholamine fluorescence, to stain for adrenergic nerves (for further details see Chapter 3), and acetylcholinesterase as a possible stain for cholinergic nerves (for further details and its limitations see Chapter 3), together with the greater resolution provided by electron microscopy, a fuller understanding of vessel innervation is being obtained. New techniques enabling more specific identification of nerves are currently being developed, for example the use of immunocytochemistry where antibodies are applied to locate specific proteins within the nerves. All of these ultrastructural and histochemical techniques are complementary and the combined results from these studies should give a clearer picture of innervation than seen by any one technique alone. Control denervations are often used in conjunction with these procedures, either through experiments where the nerves are cut and allowed to die back, or through chemical denervations, for example the use of 6-hydroxydopamine to destroy sympathetic nerves.

Neuroeffector Sites

Using histochemical procedures to stain for noradrenaline it has been demonstrated that functional adrenergic fibres are generally confined to the adventitia-medial junction of blood vessels, although medial penetration by nerves has been reported in a number of large elastic and muscular arteries in animals such as dog, pig, sheep, cow, seal and man, but rarely in the largest vessels of small animals such as mouse, rat, guinea-pig and rabbit (for references see Burnstock, Chamley & Campbell, 1980). At the adventitia-medial junction the nerves branch to form a network of fibres surrounding the vessel. The autonomic neuromuscular junction differs from the synapse formed between voluntary nerves and skeletal muscle in that autonomic fibres do not have a distinct nerve ending synapsing closely with the effector tissue, but instead have a number of bulbous swellings or varicosities at intervals along the nerve terminals. Electron microscopy has shown this arrangement to be the case for all autonomic nerves, as well as elucidating the finer structure of these varicosities. Such studies reveal numerous transmitter-containing vesicles together with many mitochondria. The autonomic nerves are non-myelinated and contained in a Schwann cell investment except at some varicosities where the investment is partially removed. Neurotransmitter is thought to be released, in response to an impulse passing along the nerve, at these sites where the investment is removed and the exposed surface of the axon is close to the target tissue (Burnstock, 1970; Burnstock & Iwayama, 1971).

The effector site for the neurotransmitter is thought to be a muscle bundle rather than a single smooth muscle cell, the individual cells being joined by low-resistance pathways which

enable the electrotonic spread of activity within the bundle. Generally, only some of the cells are directly-innervated and the potential is passed to coupled cells via the low-resistance pathways. The depolarization of the effector bundle cells initiates an all-or-none action potential which propagates throughout the tissue affecting the indirectly-coupled cells. Low resistance pathways have been thought to take the form of nexuses or gap junctions where the plasma membranes of adjacent cells are in close apposition (for further details see Burnstock et al, 1980; Gabella, 1981). There is a wide variation in the density of innervation of smooth muscle, for example all the muscles of the vas deferens are directly-innervated whereas this is true only for a few muscle cells of the uterus, ureter and blood vessels (Burnstock, 1977,1980).

The distance between the varicosities and the smooth muscle also differs greatly, ranging from 15 - 20nm in densely-innervated tissues such as the vas deferens, to 2,000nm in large elastic arteries such as the rabbit pulmonary artery (Bevan & Su, 1974). Arterioles, being fairly heavily innervated, tend to have smaller neuromuscular junctions (80 - 120nm). As the vessels increase in size so do the junctional clefts (Bevan & Su, 1974).

Variations in Innervation Patterns

The density of the adrenergic ground plexus within the effector tissue also varies between tissues, along the same vessel and between species. The pattern of innervation of the smooth muscle greatly affects the response to nerve impulses, the modification of transmission by drugs and circulating factors, and the sensitivity of the muscle to agonists.

Noradrenaline released from sympathetic nerves is largely inactivated after its effect on receptors by re-uptake into the nerve terminals. In tissues where there is dense adrenergic innervation then circulating catecholamines have little effect, as they are rapidly taken up into the nerve plexus. The adrenergic nerve fibres therefore not only mediate nervous control of the smooth muscle, but protect the organ from effects of circulating catecholamines (Burnstock et al, 1980). Sparsely-innervated tissues, on the other hand, are very sensitive to these humoral agents.

Blood vessels are involved in the homeostatic responses elicited by the sympatho-adrenal system. The pattern of innervation of the vessels, whereby the nerves are confined to the adventitia, makes the vessels available for control by both adrenergic nerves and circulating catecholamines. Stimulation of the adrenergic nerves produces a rapid vasomotor response, spread throughout the tissue by the low resistance pathways between the cells. Most of the cells of the media, however, are not innervated and are therefore lacking in catecholamine uptake sites, making these muscle cells more sensitive to circulating catecholamines (Burnstock et al, 1980).

The pattern and density of innervation of different vessels varies according to their physiological role in controlling blood flow to the particular tissue they supply, but some general aspects of blood vessel structure and innervation can be shown (see Burnstock et al, 1980; Figure 1).

Large elastic arteries are not generally well supplied with nerves, though there is variation between species, for example few adrenergic nerves are seen in the rat aorta, moderate innervation is present in the cat, dog, calf, pig and monkey, while the guinea-pig

aorta has a dense nerve supply (Burnstock et al, 1980). Nerve terminals are usually some distance away from the muscle cells (up to 2,000nm) and responses of these vessels to nerve stimulation are slow and weak. These larger vessels are therefore thought to be mainly under humoral control from circulating catecholamines.

Muscular arteries are generally more heavily innervated than elastic arteries and nerve-muscle separation is less, usually 200-500nm in large and medium vessels and as low as 80nm in small vessels (Bevan & Su, 1974). In extracerebral arteries, a rich supply of both adrenergic and cholinergic nerves has been seen in close apposition both to each other and to the smooth muscle (Iwayama et al, 1970) suggesting the possibility of physiological interactions between the two nerve types. This close dual innervation has also been demonstrated by Jones (in press) in rat submandibular gland.

Intimal cushions or thickenings have been seen at the branch points of a number of vessels including coronary, cerebral, renal, thyroid and ciliary arteries (for references see Burnstock et al, 1980). These cushions are often highly innervated.

Arterioles and pre-capillary sphincters show variation in innervation pattern. Large arterioles, being the major resistance vessels in the circulation, are usually richly innervated, the junctional cleft is small, and the vessels respond rapidly to nerve stimulation by changing the diameter of the lumen. The density of innervation of the small arterioles varies considerably from a sparse nerve supply in the cerebral circulation (Dahl, 1973) to a relatively rich supply in the mesenteric circulation (Furness, 1973). Pre-capillary sphincters also range in innervation density from rich in the coronary circulation (Burnstock et al, 1980) to absent in the rat mesentery (Furness, 1973). The latter are probably controlled by circulating hormones.

The capillaries consist of a simple tube of endothelial cells and the absence of smooth muscle in their walls implies the absence of a nerve supply but this is still not clear, as nerve fibres have been observed in close apposition to capillaries, for example in the cat pancreas (Lever, Spriggs & Graham, 1968), rat brain (Itakura, Yamamoto, Tohyama & Shimizu, 1977) and cat submandibular gland (Garrett & Kemplay, 1977). However, these fibres may be merely in transit, running in the same space as the capillaries and therefore may not necessarily be representing a functional innervation.

Venules and veins, although showing considerable variation in their density of innervation, are less well innervated than their equivalent arteries. Muscular veins such as the portal-mesenteric or renal veins tend to be richly supplied with nerves whereas the collecting venules and small veins are sparsely innervated (for references see Burnstock et al, 1980).

Table 3 gives examples of the types of vascular innervation present in various organs of different species, identified by the use of a number of specific histochemical and anatomical procedures.

General Comments on Table 3

Adrenergic fibres have been reported around blood vessels in almost all the tissues listed, though differences are seen between species, for example the intrapulmonary artery and arterioles in the cat (Fisher, 1965; Hebb, 1969), rabbit, sheep, dog (Hebb, 1969; Lee & Rajagopalan, 1981) and pig (Hebb, 1969) are innervated adrenergically whilst in the rat (Hebb, 1969; Fisher, 1965) this is not so. In the case of the carotid artery, adrenergic innervation is found in the guinea-pig, cat and pig but not in the rat (Stanton

& Hinrichsen, 1980).

Cholinergic fibres do not appear to be as widespread in their distribution as their adrenergic counterparts, and again there are species differences, for example the arteries in cattle skin (Jenkinson, Sengupta & Blackburn, 1966) possess a cholinergic innervation whilst those in rabbit skin do not (Hebb & Linzell, 1970).

Within a tissue, different classes of blood vessels may be innervated differently, for example in rat mesentery the arteries, arterioles and veins are supplied with adrenergic nerves whilst the capillaries and venules are not (Furness, 1973).

It is clear therefore that generalisations cannot be made across species or within circulations and so there is no substitute for detailed investigation of individual vascular networks.

Identification of Different Types of Autonomic Nerves

There are two standard histochemical techniques in use for the identification of adrenergic and cholinergic nerves, namely catecholamine fluorescence and acetylcholinesterase staining respectively. Although the former technique has proved reliable, the latter has produced complications in interpretation owing to the finding of positive enzyme staining in adrenergic fibres (for example Barajas & Wang, 1975). More recently it has been shown that purified preparations of acetylcholinesterase can also act on substance P and, in some tissues, a correlation may exist between the distribution of the enzyme and the peptide (Chubb, Hodgson & White, 1980). These problems are discussed further in Chapter 3. Cholinergic somatic motor nerves and central cholinergic nerves have been identified through the histochemical localisation of choline acetyltransferase (Kasa, Mann & Hebb, 1970; Higgins & Barrnett, 1971) but it remains

3

to be demonstrated whether this method is sensitive enough to identify autonomic nerves.

Advances in the search for possible non-adrenergic, non-cholinergic transmitters are being made by the use of immunocytochemical techniques which can be applied both in the light (Polak & Bloom, 1978) and electron (Polak, Buchan, Probert, Tapia, De Mey & Bloom, 1981) microscopes. Antibodies, raised to specific peptides, are applied to fixed tissue slices, and subsequently visualised by the application of a second antibody which carries a marker, for example a fluorescent tag for light microscopy and a gold tag for electron microscopy. Fluorescent compounds are also being used directly, for example quinacrine has been suggested to bind purines, though its specificity has not been clearly established (Olson, Ålund & Norberg, 1976). After sympathectomy, nerve cells and networks, demonstrated by this method, persist in the intestine, bladder and portal vein, preparations considered by physiological experiments to be innervated by purinergic nerves (see Burnstock, 1980).

The identification of the nerve types is not easy in the electron microscope either. The basis of the differentiation is according to the types of vesicles found within the terminal varicosities of the nerves (see Figure 2).

a) Adrenergic Nerves

Nerves containing noradrenaline are characterised by the presence of small granular vesicles (30-60nm) with a dense core (Burnstock & Costa, 1975). These vesicles are usually visualised by the use of special histochemical techniques, for example the chromaffin procedure or pre-treatment with 5-hydroxydopamine (see Jones, 1979a), where the cores of adrenergic vesicles become densely osmiophilic. Different fixation procedures in different

tissues affect the preservation of the granules, therefore care must be taken in the interpretation. Large granular vesicles (60-120nm) are also present which are capable of taking up catecholamines (Burnstock & Costa, 1975) but are fairly resistant to depletion by reserpine. Prior treatment with reserpine does, however, remove the granular cores from the small granular vesicle population and this procedure together with that of chemical sympathectomy by 6-hydroxydopamine, can be used as controls for the staining method (Jones, 1979 a). Some small agranular vesicles are present in adrenergic nerve terminals and these probably represent empty vesicles.

b) Cholinergic Nerves

It is generally accepted that a predominance of small agranular vesicles (35-60nm) identifies a cholinergic axon profile (Burnstock & Iwayama, 1971; Burnstock & Costa, 1975). Large granular vesicles (60-120nm) are also present but these do not take up catecholamines or 5- or 6-hydroxydopamine. Work on cat exocrine glands using the peroxidase-antiperoxidase method and electron microscopy has shown that electron-dense precipitates representing VIP-like immunoreactivity were seen in large granular vesicles in varicosities also containing small agranular vesicles. These varicosities are typically cholinergic (Johansson & Lundberg, 1981). Subcellular fractionation techniques coupled with sucrose density gradients and ultrastructural analysis have shown that VIP is preferentially found in a fraction containing large dense-core vesicles (Lundberg, 1981).

c) Non-adrenergic, non-cholinergic Nerves

Non-adrenergic, non-cholinergic nerves have been observed around arterioles in tissues such as the rat major sublingual gland (Jones, 1980) where atropine-resistant vasodilatation has been shown (Templeton & Thulin, 1978) and fibres containing VIP-like immunoreactivity are seen (Wharton et al, 1979). The major characteristic of the non-adrenergic, non-cholinergic fibres is the predominance of large opaque vesicles (Burnstock, 1975a). These are larger (100-200nm) than the large granular vesicles seen in adrenergic and cholinergic profiles, have a less granular core and a less prominent halo between the core and the vesicle membrane. They are unaffected by treatment with 6-hydroxydopamine or reserpine.

d) Other Nerve Profiles

The above descriptions of axon profiles and the relationship between vesicle types and transmitters is very simplistic and the reality is far more complex. For example, over 16 putative transmitters have been proposed in the autonomic nervous system of the gut, namely ACh, NA, ATP, 5-HT, GABA, dopamine, and the following peptides, enkephalin, VIP, substance P, bombesin, somatostatin, neurotensin, LHRH, cholecystokinin/gastrin, bradykinin, angiotensin and adrenocorticotrophic hormone. It is also likely that more than one transmitter is released from a single nerve upon stimulation (see Burnstock, 1981). More than 9 ultrastructurally distinct nerve profiles have been observed in the gut. These are discussed in detail by Burnstock (1981) who characterises nerve profiles containing a predominance of a) small granular vesicles, b) small agranular vesicles, c) small flattened vesicles, d) large granular vesicles, e) large opaque vesicles,

f) heterogeneous granular vesicles, g) small mitochondria, h) pleomorphic vesicles, together with other nerve profiles probably representing stages of development or degeneration (Figure 3).

Procedures are presently being developed that will produce clear electron-microscopical identification of profile types following specific cytochemical reactions for putative transmitters or enzymes associated with them, and results from these should aid the correlation between transmitter and vesicle type, and thus clarify the identification of chemicals involved in the neural control of blood flow in particular tissues.

Humoral Control of Blood Flow

Although many endocrine substances are able to influence the calibre of vessels it is unlikely that they play a major role in the overall control of the circulation of an organism. The adrenal catecholamines are probably the most important physiologically but even these have far less effect on vessel calibre than the sympathetic innervation. However, due to the presence of adrenergic nerves on only the adventitial side of the vessel wall, the circulating catecholamines are able to act on the inner layers of smooth muscle without immediate inactivation by uptake into the sympathetic nerve fibres. Vessels which are sparsely innervated are certainly more sensitive to the action of circulating hormones.

Upon stimulation, the adrenal medulla of the human adult produces both adrenaline and noradrenaline, though the former predominates, and they have different vasomotor effects. Noradrenaline has a vasoconstrictor action mediated by alpha-adrenoceptors on the vascular smooth muscle. Adrenaline, on the other hand, has a dual effect on vascular resistance by activating both alpha₁ adrenoceptors mediating vasoconstriction and found on all vascular muscle walls, and beta₂ adrenoceptors mediating vasodilatation and present on the membranes of coronary and skeletal muscle blood vessels and the vasculature of the liver. The binding of adrenaline produces alpha-mediated vasoconstriction and beta-mediated dilatation which is the same as that produced by noradrenaline and acetylcholine, respectively.

Stimulation of the adrenal medulla produces a blood level of adrenaline that activates beta₂ adrenoceptors to produce vasodilatation. When adrenaline levels are increased beyond this, alpha adrenoceptors are activated to produce vasoconstriction. Upon sympathetic stimulation, a high concentration of noradrenaline is formed in the junction, activating alpha-adrenoceptors and producing vasoconstriction, the concentration of noradrenaline overshadowing that of circulating adrenaline. However, in vascular beds possessing beta₂ receptors the dilating effect of adrenaline is more pronounced, therefore the overall constriction produced on nerve stimulation is lower than in beds with no beta₂ adrenoceptors. Because of the greater reduction in flow to beds with no beta₂ adrenoceptors, there is a redistribution of flow towards those beds with both alpha- and beta-adrenoceptors, for example skeletal muscle, liver and myocardium (Little, 1981; review, Lundvall, Hillman & Gustafsson, 1981).

Serotonin has been shown both to constrict and dilate vessels (see Table 1 for examples), though its action is usually seen in constriction of small vessels. Under normal circumstances it is present only in blood platelets. Its vasomotor effect probably only comes into play when there is tissue damage, platelets are broken down and the subsequent release of serotonin causes vasoconstriction.

Histamine also can effect both vasoconstriction and vasodilatation (Table 1) and is probably involved in the vasodilatation accompanying inflammation.

Acetylcholine perfusion produces vasodilatation in most vascular beds even where cholinergic innervation is sparse or absent. Its possible mode of action is discussed by Furchgott & Zawadzki (1980), Furchgott (1981) and Furchgott, Zawadzki & Cherry (1981) (also see Chapter 4).

After release of the enzyme renin from the kidney, under circumstances of reduced blood flow, a series of chemical reactions takes place resulting in the release of angiotensin, a very powerful vasoconstrictor (see Table 1). It may have important functions in the control of vascular resistance within the kidney and be involved in acute renal hypertension though it is unlikely to achieve concentrations in the blood sufficient to bring about changes in flow in the whole organism. Its primary function appears to be in the regulation of aldosterone production.

Vasopressin is another vasoactive hormone, secreted by the neurohypophysis, which modifies vascular tone indirectly by affecting vascular smooth muscle reactivity (Lundvall et al, 1981), but under physiological conditions it is unlikely to reach concentrations sufficient to produce direct vasoconstriction in the intact animal (Little, 1981).

Bradykinin is a powerful vasodilator (see Table 1) which is thought to be involved in the regulation of blood flow in sweat and salivary glands (see Chapters 3 and 6).

There are many circulating and locally released substances which are vasoactive. Some of these have direct effect on the vascular smooth muscle and therefore act upon tissues that are not innervated, but where there are appropriate vascular smooth muscle receptors. Other substances exert their effects by modifying blood flow by inhibiting or increasing the action of other humoral vasoactive agents, examples are glucocorticoids and oestrogens. Many substances also influence vessel calibre by regulating the release of neurotransmitter from nerve terminals. Table 1 gives examples of the action of various endocrine and locally produced chemicals and their effect on different vessels and vascular beds. Some vasoactive agents produce only one type of response in all vessels and species listed, for example VIP produces vasodilatation and angiotensin vasoconstriction (Table 1). Many substances, however, have both vasodilator and vasoconstrictor properties and the observed response will depend upon the interaction of a number of factors. These may include differences in receptor density and kinetic properties and in the generation and utilisation of competing factors.

SUMMARY

The development of drugs to alleviate hypertension is of extreme importance. An increased understanding of the role of the autonomic nervous system in the maintenance of blood pressure through the control of peripheral vascular resistance, and the action on vascular smooth muscle of neurotransmitters, hormones and other vasoactive agents present in the body, should aid in this development. Furthermore, this knowledge should result in drugs with a greater specificity of action and reduced side-effects.

Much of this work and the perfecting of techniques has been rightly performed on animals, but if useful results in terms of drug development are to be obtained then it is necessary to apply it to clinical material. Many physiological experiments cannot be performed on man for obvious moral reasons, therefore careful extrapolations have to be made from animal studies. However, where safe non-invasive techniques or procedures using tissue removed during operations or post mortem can be employed then these should be applied to man. This is now being extensively undertaken.

The following experiments show the application of specific histochemical and ultrastructural techniques to identify the nerves likely to influence blood flow in animal tissues and these procedures are then extended to the study of selective human vascular beds.

Table 1 Examples of the Vascular Responses to Vasoactive Agents.

<u>FACTOR</u>	<u>SPECIES</u>	<u>TISSUE/VESSEL</u>	<u>RESPONSE</u>	<u>REFERENCE</u>	
Acetylcholine	Human	Forearm	D	80	
	Human	Brain	D	88	
	Dog	Femoral artery	D	15	
	Dog	Saphenous vein	C	75	
	Dog	Tongue	D	296	
	Dog	Mesentery	D	294	
	Sheep(fetal)	Lungs	D	59,60	
	Cow	Mesenteric vein	C	158	
	Cow	Hepatic vein	C	158	
	Guinea-pig	Uterus	D	13	
	Guinea-pig	Coronary artery	C	196	
	Cat	Heart	D	38	
	Cat	Submandibular gland	D	303	
	Rat	Liver	D	125,198,199	
	Rabbit	Submandibular gland	D	243	
	Rabbit	Ear	D	159	
	Rabbit	Marrow	D	235	
	Adrenaline	Human	Forearm	C	83
		Human	Brain	C	88
		Rat	Portal vein	C	227
Rat		Liver	C	125,128	
Rat		Mammary gland	C	326	
Cat		Mammary gland	C	143	
Cat		Skeletal muscle	D	108	
Dog		Mammary gland	C	143	
Goat		Mammary gland	C	143	
Rabbit		Liver	C	128	
Rabbit		Renal artery	C	280	
Sheep		Coronary artery	D	36	
Mouse		Spleen	C	275,276,277	
Phenylephrine		Human	Brain	C	88
		Human	Brachial artery	C	97

Table 1 (continued)

<u>FACTOR</u>	<u>SPECIES</u>	<u>TISSUE/VESSEL</u>	<u>RESPONSE</u>	<u>REFERENCE</u>
Phenylephrine	Human	Pulmonary artery	C	97
	Rat	Mammary gland	C	326
Noradrenaline	Human	Forearm	C/D	35,65,83
	Human	Cutaneous hand vein	C	
	Human	Finger	C	65
	Human	Brachial artery	C	345
	Human	Brain	C	17
	Dog	Lung	C	88
	Dog	Renal artery,vein	C	184
	Dog	Saphenous vein	C	301
	Dog	Skeletal muscle	C	75
	Dog	Hindpaw skin	C	271
	Dog	Bone	C	271
	Dog	Marrow	C	132
	Dog	Tongue	C	132
	Dog	Mesentery	C	296
	Cat	Intestine	C	294
	Cat	Heart	D	217
	Rabbit	Hindlimb	C	38
	Rabbit	Saphenous vein	C	336
	Rabbit	Hindquarters	C	75
	Rabbit	Marrow	C	126
	Rabbit	Ear	C	235
	Rabbit	Mesentery	C	159,336
	Rabbit	Liver	C	336
	Rabbit	Portal vein	C	128
	Rabbit	Renal artery	C	309
	Rat	Mammary gland	C	280
	Rat	Brain	C	326
	Rat	Liver	C	87
Duck	Leg	C	128	
Cow	Mesenteric vein	C	236	
Cow	Hepatic vein	C	158	
				158

Table 1 (continued)

<u>FACTOR</u>	<u>SPECIES</u>	<u>TISSUE/VESSEL</u>	<u>RESPONSE</u>	<u>REFERENCE</u>	
Noradrenaline	Cow	Cerebral artery	C	298	
	Guinea-pig	Uterus	C	13	
	Sheep	Coronary artery	C/D	36	
Isoprenaline	Mouse	Spleen	C	275,276,277	
	Human	Brain	C	88	
	Dog	Femoral artery	D	15	
	Dog	Mesentery	D	295	
	Sheep(fetal)	Lungs	D	59,60	
	Sheep	Coronary artery	D	36	
	Cow	Mesenteric vein	D	158	
	Cow	Hepatic vein	D	158	
	Cat	Submandibular gland	D	180,303	
	Mouse	Spleen	D	275,276,277	
	Rat	Jugular vein	D	64	
	Rabbit	Saphenous vein	-	75	
	Serotonin	Human	Brain	C	88
		Human	Umbilical vessels	C	152
		Human	Placental vessels	C	152
Dog		Femoral artery	D	15	
Dog		Saphenous vein	C	230	
Dog		Tibial artery	C	230	
Dog		Carotid vessels	C/D	234	
Dog		Cerebral artery	C	85	
Cow		Mesenteric vein	C	158	
Cow		Hepatic vein	C	158	
Cow		Cerebral artery	C	298	
Rat		Jugular vein	C	64	
Cat		Brain	C/D	226	
Rabbit		Portal vein	C	309	
Guinea-pig		Uterus	C	13	
Mouse	Spleen	C	275,276,277		

Table 1 (continued)

<u>FACTOR</u>	<u>SPECIES</u>	<u>TISSUE/VESSEL</u>	<u>RESPONSE</u>	<u>REFERENCE</u>
Dopamine	Dog	Femoral artery	D	15
	Cow	Mesenteric vein	C	158
	Cow	Hepatic vein	C	158
Histamine	Cat	Brain	C	229
	Human	Forearm	D	80
	Human	Hand	D	80
	Human	Brain	C/D	88,292
	Dog	Femoral artery	D	15
	Dog	Skeletal muscle	D	271
	Dog	Skin	D	271
	Dog	Brain	C/D	292
	Dog	Lungs	C	129
	Dog	Mesentery	D	294
	Sheep (fetal)	Lungs	D	59,60
	Cow	Mesenteric artery, vein	C	158
	Cat	Brain	D	201
	Cat	Skeletal muscle	D	108
	Guinea-pig	Uterus	C	13
	Rabbit	Ear	D	159
	Rat	Hindquarters	D	272
Mouse	Spleen	C	275,276,277	
GABA	Human	Cerebral artery	D	85
	Rabbit	Cerebral artery	D	238
	Dog	Cerebral artery	D	85,114,238
	Cat	Brain	D	85,86,238
Adenosine	Cat	Pial artery	D	130
	Cat	Submandibular gland	D	181
	Mouse	Spleen	D	275,276,277
	Baboon	Brain	D	110
cAMP	Cat	Submandibular gland	D	179,180,181
	Baboon	Brain	-	110

Table 1 (continued)

<u>FACTOR</u>	<u>SPECIES</u>	<u>TISSUE/VESSEL</u>	<u>RESPONSE</u>	<u>REFERENCE</u>	
ATP	Human	Forearm	D	81	
	Rabbit	Saphenous vein	D	309	
	Rabbit	Portal vein	D	309	
	Rabbit	Ear artery	D	309	
	Rabbit	Pulmonary artery	D	309	
	Cat	Brain	D	110	
	Cat	Submandibular gland	D	181	
	Baboon	Brain	D	110	
	VIP	Goat	Brain	D	206
		Rabbit	Myometrium	D	259
Cat		Lingual artery	D	323	
Cat		Brachial artery	D	323	
Cat		Renal artery	D	323	
Cat		Mesenteric artery	D	323	
Cat		Femoral artery	D	323	
Substance P		Human	Skin	D	90,220
		Human	Skeletal muscle	D	90,220
		Pig	Mesentery	D	291
	Cat	Skin	D	41	
	Cat	Skeletal muscle	D	41	
	Cat	Small intestine	D	41	
	Guinea-pig	Heart	-	41	
	Rabbit	Heart	-	41	
	Dog	Skin	D	41	
	Dog	Heart	D	41	
	Dog	Skeletal muscle	D	41,222	
	Dog	Small intestine	D	41,263	
Dog	Adipose tissue	D	41		
Dog	Kidney	-	263		
				135	

Table 1 (continued)

<u>FACTOR</u>	<u>SPECIES</u>	<u>TISSUE/VESSEL</u>	<u>RESPONSE</u>	<u>REFERENCE</u>	
Bradykinin	Human	Portal vein	D	7	
	Dog	Femoral artery	D	15	
	Dog	Lung	D	129	
	Dog	Tongue	D	296	
	Dog	Mesentery	D	294	
	Sheep(fetal)	Lung	D	59,60	
	Cat	Submandibular gland	D	303	
	Mouse	Spleen	C	275,276,277	
	Angiotensin	Cat	Intestine	C	217
		Rat	Portal vein	C	227
Rat		Mammary gland	C	326	
Dog		Mesenteric artery	C	58	
Dog		Mesentery	C	37,294	
Dog		Femoral artery	C	58	
Dog		Renal artery	C	58	
Dog		Kidney	C	134,221	
Rabbit		Hindquarters	C	126	
Prostaglandin A ₁ and A ₂		Human	Forearm arterial bed	D	281
	Human	Superficial hand vein	D	281	
PG B ₁	Rabbit	Renal artery	C	280	
	Human	Forearm arterial bed	D	281	
PG D	Human	Superficial hand vein	D	281	
	Dog	Renal artery, vein	C	301	
PG E ₁ and E ₂	Human	Forearm arterial bed	D	21,281	
	Human	Superficial hand vein	D	281	
	Human	Brachial artery	D	17	
	Human	Skin	D	21	
	Human	Brain	D	256	
	Human	Umbilical vessels	C/D	152	
	Human	Placental vessels	C/D	152	
	Goat(perinatal)	Lungs	D	61	
	Rat	Carotid artery	D	260,261	
	Pig	Lung	C	185	

Table 1 (continued)

<u>FACTOR</u>	<u>SPECIES</u>	<u>TISSUE/VESSEL</u>	<u>RESPONSE</u>	<u>REFERENCE</u>	
PG E ₁ and E ₂	Sheep (fetal)	Umbilical vessels	C	285,320	
	Sheep (fetal)	Placental vessels	C	285,320	
	Sheep (fetal)	Skeletal muscle	D	285,320	
	Sheep (fetal)	Skin	D	285,320	
	Sheep (fetal)	Gut	D	285,320	
	Sheep (fetal)	Brain	-	285,320	
	Sheep (fetal)	Kidney	-	285,320	
	Sheep (fetal)	Myocardium	D	285,320	
	Sheep (fetal)	Lungs	D	285,320	
	Sheep (fetal)	Adrenal vessels	D	285,320	
	Lamb	Lung	C	185	
	Rabbit	Hindlimb	C	336	
	Rabbit	Hindquarters	D	126	
	Rabbit	Mesentery	C/D	6,336	
	Rabbit	Ear	D	336	
	Rabbit	Renal artery	C	280	
	Hamster	Cheek pouch	D	182	
	Dog	Renal artery, vein	C	301	
	Dog	Mesentery	D	294	
	Dog	Lung	C	185	
	Cat	Intestine	D	218	
	Cat	Kidney	D	218	
	Cat	Hindquarters	D	218	
	Mouse	Spleen	C	275,276,277	
	PG F ₂ alpha	Human	Forearm arterial bed	D	281
		Human	Superficial hand vein	C	281
		Human	Umbilical vessels	C	152
Human		Placental vessels	C	152	
Human		Brain	C	85	
Cat		Lingual artery	C	323	
Cat		Brachial artery	C	323	
Cat		Renal artery	C	323	

Table 1 (continued)

<u>FACTOR</u>	<u>SPECIES</u>	<u>TISSUE/VESSEL</u>	<u>RESPONSE</u>	<u>REFERENCE</u>	
PG F ₂ alpha	Cat	Mesenteric artery	C	323	
	Cat	Femoral artery	C	323	
	Rabbit	Renal artery	C	280	
	Dog	Submandibular gland	D	313	
	Dog	Tongue	D	296	
	Dog	Mesentery	C	294	
	Mouse	Spleen	C	275,276,277	
	PG I ₂	Human	Saphenous vein	-	212
		Rat	Carotid artery	D	260,261
		Rat	Portal vein	C	212
Rat		Vena cava	C	212	
Dog		Femoral artery, vein	D	106	
Dog		Renal artery, vein	D	301	
Cat		Intestine	D	218	
Cat		Kidney	D	218	
Cat		Hindquarters	D	218	
Rabbit		Hindquarters	D	126	
Glucocorticoid	Sheep(maternal)	Adrenal	D	265	
	Sheep(fetal)	Adrenal	D	265	
	Dog	Kidney	D	134	
	PTH	Hen	Thyroid	C	29
		Hen	Adrenal	D	29
		Hen	Bone	C/D	29
	Nitroglycerin	Rat	Jugular vein	D	64
		Rat	Aorta	D	64
		Dog	Coronary artery	D	288
	Lactic acid	Mouse	Spleen	C	275,276,277
Oxygen	Guinea-pig	Ductus arteriosus	C	101	
Carbon dioxide	Cat	Pial artery	D	130	
	KCl	Rat	Jugular vein	C	64
		Rabbit	Ear	C	187
K ⁺	Rabbit	Aorta	C	187	
	Pig	Coronary artery	C	187	
	Dog	Saphenous vein	C	325	

Table 2 Examples of the Vascular Responses to Nerve Stimulation.

<u>TISSUE/VESSEL</u>	<u>SPECIES</u>	<u>NERVE</u>	<u>RESPONSE</u>	<u>REFERENCE</u>
Lung	Dog	S	C	184
Pulmonary artery	Rabbit	S	C	309, 310
Ear	Rabbit	S	C/D	159
Ear artery	Rabbit	S	C	310
Brain	Human	S	C	88
Brain	Rat	S	C	87
Brain	Cat	S	D	321
Skeletal muscle	Dog	S	C	271
Skeletal muscle	Cat	S	C/D	108
Saphenous vein	Dog	S	C	75, 325
Saphenous vein	Rabbit	S	C	75, 309, 310
Brachial artery	Rabbit	S	C	310
Skin	Dog	S	C	271
Hindquarters	Rabbit	S	C	126
Heart	Cat	S	D	38
Coronary artery	Sheep	S	D	36
Bone	Cat	S	C	132, 335
Bone	Dog	S	C	335
Kidney	Dog	S	C	221
Lobar artery	Rabbit	S	C	309, 310
Spleen	Mouse	S	C	275, 276, 277
Liver	Rat	PS	D	198, 199
Portal vein	Rabbit	S	C	309

Table 2 (continued)

<u>TISSUE/VESSEL</u>	<u>SPECIES</u>	<u>NERVE</u>	<u>RESPONSE</u>	<u>REFERENCE</u>
Tongue	Cat	S	C/D	95
Tongue	Dog	S	C	296
Tongue	Dog	PS	D	296
Submandibular gland	Cat	PS	D	179, 180, 303
Submandibular gland	Cat	S	C/D	179, 180
Submandibular gland	Dog	PS	D	313
Submandibular gland	Rabbit	PS	D	243
Submandibular gland	Rabbit	S	C/D	243
Intestine	Cat	S	C	217
Mesenteric artery	Rabbit	S	C	310
Mesenteric vein	Rabbit	S	C	6
Mesentery	Rat	S	C	147

Table 3 Examples of Perivascular Nerves Demonstrated by Histochemical Techniques.

<u>TISSUE</u>	<u>SPECIES</u>	<u>VESSEL</u>	<u>TECHNIQUES</u>	<u>NERVES</u>	<u>REFERENCE</u>	
Bone Skeletal muscle	Rabbit	Vessels	FIF, EM	Ad	82	
	Cat	A	IH	Pept	323	
	Cat	A, A1	FIF, AChE	Ad, Ch	32	
	Dog	A, A1	FIF, AChE	Ad, Ch	32	
	Human	A, A1	FIF, AChE	Ad, no Ch	32	
	Monkey	A, A1	FIF, AChE	Ad, no Ch	32	
	Dog	Femoral artery	GAF, AChE	Ad, Ch	4	
	Dog	Femoral vein	GAF, AChE	Ad, no Ch	4	
	Rat	Femoral vessels	FIF, EM	Ad	318	
	Rat	Saphenous vessels	FIF, EM	Ad	318	
	Rat	Main tail artery	FIF, EM	Ad	318	
	Skin	Rabbit	A, A1	FIF, AChE	Ad, no Ch	144
		Cattle	A, V	MAO, AChE	Ad, Ch	168
		Human	A1	GAF, AChE, EM	Ad, no Ch	193
		Human	Vessels	AChE	no Ch	162
Human		AVA	AChE	Ch	162	
Sheep		AVA	GAF, EM	Ad	239	
Brain	Human	Vessels	FIF, AChE	Ad, Ch	88	
	Human	A	AChE	Ch	244	
	Human	A, A1	FIF	Ad	254	
	Dog	A, A1	EM	Ad	290	
	Dog	Pial A, A1	AChE	Ch	79	
	Dog	Circle of Willis A	AChE	Ch	34	
	Rat	A1, Cap	GAF, EM	Ad, Ch	164	
	Rat	Pial A, A1	AChE, EM	Ad, Ch	79	
	Rat	Cerebral Artery	FIF, EM	Ad, Ch	165	
	Cat	Pial A, A1	AChE, EM	Ad, Ch	79	
	Cat	Cerebral artery	IH	Pept	79	
	Cattle	Cerebral artery	FIF	Ad	298	
	Guinea-pig	Pial A, A1	AChE	Ch	79	
	Hamster	Pial A, A1	AChE	Ch	79	
	Rabbit	Pial A	AChE, EM	Ch	79	
	Mouse	Pial A, A1	AChE	Ch	79	

Table 3 (continued)

<u>TISSUE</u>	<u>SPECIES</u>	<u>VESSEL</u>	<u>TECHNIQUES</u>	<u>NERVES</u>	<u>REFERENCE</u>
Brain	Domestic fowl	A, A1, Cap	FIF, AChE	Ad, Ch	311
	Turtle	Cerebral artery	FIF, AChE	Ad, Ch	163
	Turtle	A1, Cap	FIF, AChE	Ad, Ch	163
	Carp	Cerebral artery	FIF, AChE	Ad, Ch	330
	Carp	Pial artery	FIF, AChE	Ad, Ch	330
	Carp	A1, Cap	FIF, AChE	Ad, Ch	330
	Bull-frog	Cerebral artery	FIF	Ad	312
	Bull-frog	Extraparenchymal artery	AChE	no Ch	312
	Bull-frog	Parenchymal A1, Cap	FIF, AChE	Ad, Ch	312
Breast	Rabbit	A, A1	FIF, AChE	Ad, no Ch	144
	Rat(lactating)	A1	FIF, AChE	Ad, noCh	192, 193
	Human	A, A1	MB	nerves	237
	Human	A1	FIF, AChE, EM	no nerves	178, 192, 193
Umbilical cord	Human	Umbilical artery	EM	no Ad, no Ch	245
Genito-urinary tract	Cat	A	IH	pept	323
Uterus	Guinea-pig	Main artery	AChE	Ch	13, 14
	Guinea-pig	Main artery	FIF, AChE	Ad, Ch	13
	Guinea-pig	2nd artery	FIF, AChE	Ad, no Ch	13
Prostate	Human	Vessels	FIF	Ad	324
Bladder	Human	Vessels	FIF	Ad	252
	Human	A, A1	FIF	Ad	251
Kidney	Rat	A1	FIF, AChE, EM	Ad	9, 11
	Rat	Glomerular A1	EM	Ad	10
	Cat	Vessels	IH	no pept	323
Pancreas	Cat	Vessels	FIF	Ad	207
	Cat	A, A1, Cap	FIF, EM	Ad	211
	Cat	V	FIF, EM	no nerves	211
	Domestic fowl	Vessels	EM	Ad, Ch	331
Spleen	Mouse	A, A1	FIF, AChE, EM	Ad, no Ch	278, 279
	Mouse	Red pulp V, V1	FIF, AChE	no Ad, no Ch	278
	Cat	Vessels	IH	no pept	323
Liver	Cat	Vessels	IH	no pept	323

Table 3 (continued)

<u>TISSUE</u>	<u>SPECIES</u>	<u>VESSEL</u>	<u>TECHNIQUES</u>	<u>NERVES</u>	<u>REFERENCE</u>	
Nasal respiratory mucosa	Human	AVA	EM	Ad,Ch	62	
	Human	V	EM	no nerves	62	
Dental pulp	Human	Vessels	FIF,AChE	Ad,Ch	200	
Tongue	Human	A,A1	AChE	Ch	92	
	Human	A,A1	EM	Ad,Ch	133	
Submandibular gland	Rat	A1,Cap	EM	Ad,Ch	172,173	
	Rat	V	EM	no nerves	172	
	Rat	Vessels	FIF,GAF	Ad	8,322	
	Rat	A1	FIF,AChE,EM	Ad,Ch	30,250,305	
	Rat	A	AChE	Ch	304	
	Rat	V1	FIF	Ad	257	
	Cat	A,A1	FIF,AChE,EM	Ad,Ch	124,191	
	Cat	Cap	FIF,EM	Ad	124	
	Mouse	Vessels	FIF	Ad	257	
	Cow	A,A1	FIF,AChE,EM	Ad,Ch	3	
	Guinea-pig	A,A1	FIF,AChE,EM	Ad,Ch	3	
	Hamster	A,A1	FIF,AChE,EM	Ad,Ch	3	
	Sublingual gland	Rat	A	AChE	Ch	304
		Rat	A1	AChE	Ch	305
		Rat	A1,V1	FIF	Ad	250
Rat		Vessels	AChE,EM	Ch	31	
Rat		A,A1	IH	pept	339	
Mouse		Vessels	FIF	Ad	257	
Guinea-pig		A,A1	FIF,AChE,EM	Ad,Ch	3	
Hamster		A,A1	FIF,AChE,EM	Ad,Ch	3	
Human		Vessels	FIF,AChE	Ad,Ch	283	
Cat		A,A1	IH	pept	339	
Parotid gland		Rat	Vess	AChE,EM	Ch	31
	Rat	A1,V1	FIF	Ad	250	
	Human	A,A1	FIF,AChE,EM	Ad,Ch	122	
	Mouse	Vessels	FIF	Ad	257	

Table 3 (continued)

<u>TISSUE</u>	<u>SPECIES</u>	<u>VESSEL</u>	<u>TECHNIQUES</u>	<u>NERVES</u>	<u>REFERENCE</u>
Gastro-intestinal tract	Cat	A	IH	pept	323
Small intestine	Cat	Vessels	FIF,EM	Ad	102
Mesentery	Rat	A,V,A1	FIF,AChE	Ad,no Ch	119
	Rat	Cap,V1	FIF,AChE	no Ad,no Ch	119
	Guinea-pig	Mesenteric artery,vein	FIF	Ad	66
	Rat	Superficial epigastric	GAF,AChE	Ad	318
Pericardium,pleura & peritoneum	Dog,cat	A	FIF,AChE	Ad,Ch	194
		A1,V1,V	FIF,AChE	Ad,no Ch	194
		Cap	FIF,AChE	no Ad,no Ch	194
Thyroid	Human	Vessels	FIF	Ad	233
8th nerve & inner ear	Human	A1,Cap	FIF,EM	no Ad	342
Heart	Cat	Coronary artery	IH	no pept	323
	Rat	Coronary A,A1	AChE	Ch	248
Atrial myocardium	Human	Vessels	FIF,GAF,EM	Ad,Ch	202
Upper respiratory tract	Cat	A	IH	pept	323
-	Guinea-pig	Abdominal aorta	GAF	Ad	66
-	Guinea-pig	Carotid artery	GAF	Ad	66
-	Cat	Carotid sinus,artery	FIF	Ad	307
-	Pig	Carotid sinus,artery	FIF	Ad	307
-	Guinea-pig	Carotid sinus,artery	FIF	Ad	307
-	Rat	Carotid sinus,artery	FIF	no Ad	307
Axillary lymph node	Human	A1	EM	Ad	193
Lung	Monkey	Extrapulmonary A	AChE	Ch	104
		Intrapulmonary A,A1	AChE	Ch	104
		Cap	AChE	no Ch	104
	Cat	Extrapulmonary A	FIF,AChE	Ad,Ch	104,142,208
		Intrapulmonary A,A1	FIF,AChE	Ad,Ch	104,142
		Cap	AChE	no Ch	104
		V	FIF	Ad	142
	Guinea-pig	Extrapulmonary A	AChE	Ch	104
		Intrapulmonary A,A1	AChE	Ch	104,142
		Cap	AChE	no Ch	104
	Rat	Extrapulmonary A	FIF,AChE	Ad,Ch	104,142
		Intrapulmonary A,A1	FIF,AChE	no Ad, Ch	104,142

Table 3 (continued)

<u>TISSUE</u>	<u>SPECIES</u>	<u>VESSEL</u>	<u>TECHNIQUES</u>	<u>NERVES</u>	<u>REFERENCE</u>
Lung	Rat	V	FIF	Ad	142
		Cap	AChE	no Ch	104
	Human	Pulmonary artery,vein	MB	nerves	306
		Bronchial artery,vein	MB	nerves	306
	Rabbit	Extrapulmonary A	FIF,AChE	Ad,Ch	142,208
		Intrapulmonary A	FIF,AChE	Ad,Ch	142,208
	Sheep	V	FIF	Ad	142
		Extrapulmonary A	FIF,AChE	Ad,Ch	142,208
		Intrapulmonary A	FIF,AChE	Ad,Ch	142,208
	Dog	V,A1	FIF	Ad	142
		Extrapulmonary A	FIF,AChE,EM	Ad,Ch	142,208
		Intrapulmonary A	FIF,AChE,EM	Ad,Ch	142,208
	Calf	Pulmonary V	AChE,EM	Ad, no Ch	142
		A	FIF,AChE	Ad,Ch	142
	Pig	V	FIF	Ad	142
Extrapulmonary A		FIF,AChE	Ad,Ch	142	
Intrapulmonary A		FIF,AChE	Ad,Ch	142	
A1		AChE	no Ch	142	
		V	FIF	Ad	142

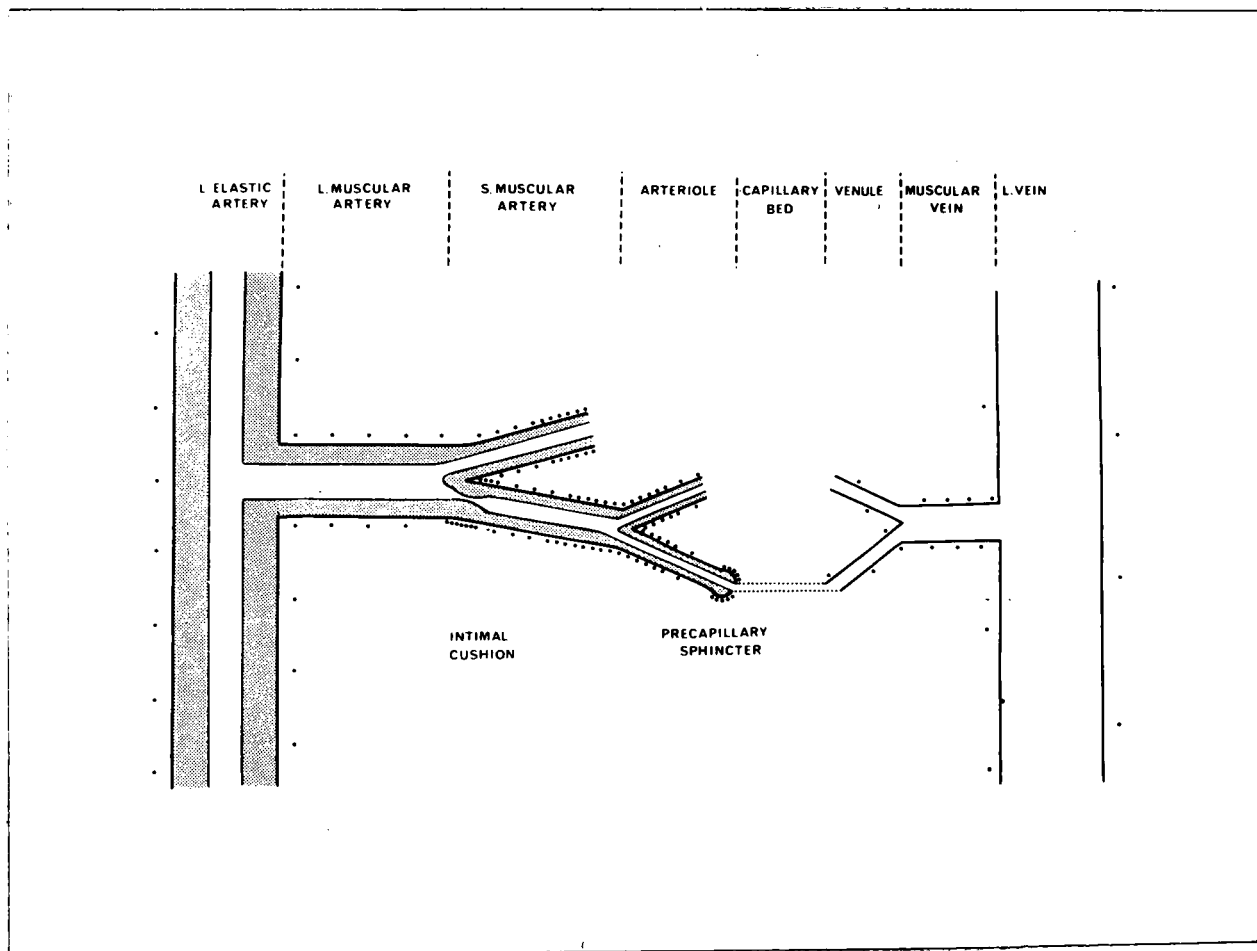


Figure 1 Diagrammatic representation of innervation density in different regions of the vascular system. (reproduced, with permission, from Burnstock, 1975b).

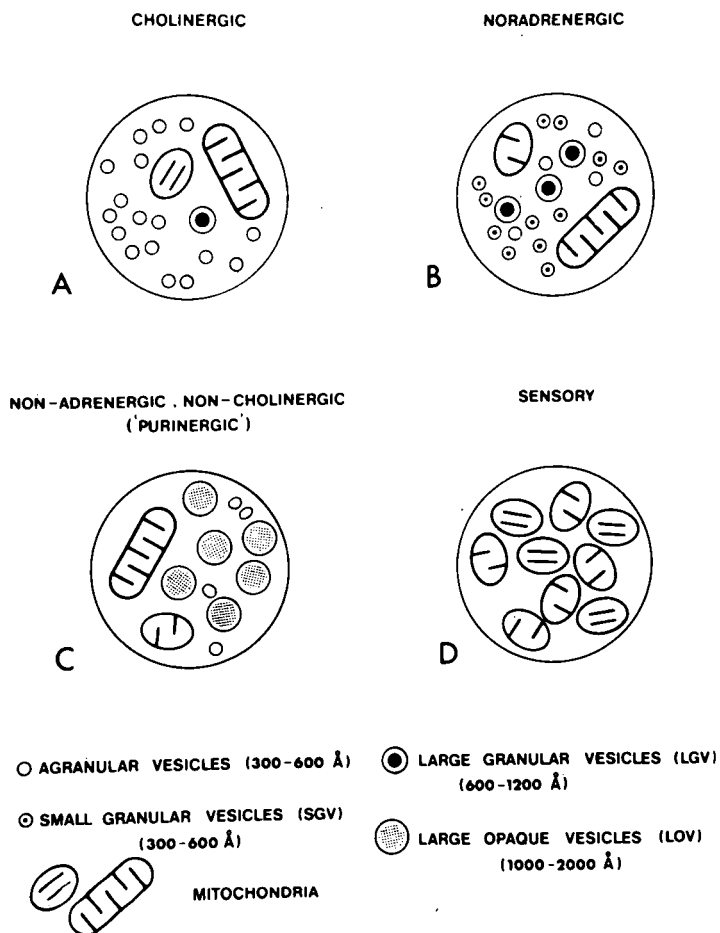


Figure 2 Diagrammatic representations of sections through the terminal varicosities of autonomic nerves (reproduced, with permission, from Burnstock et al, 1980).




Figure 3 Diagrammatic representation of the ultrastructure of the main nerve profiles in the gastrointestinal tract. The name given to each profile is based on the characteristic structure of the predominant vesicle type within that profile. Mitochondria are drawn in every profile. (reproduced with permission, from Burnstock, 1981).

Chapter 2.

ASPECTS OF THE HISTOLOGY AND ULTRASTRUCTURE OF NORMAL AND MALIGNANT HUMAN BREAST

Introduction

Tissues from laboratory animals are readily available for study with expense being a major limiting factor in the research. The age and condition of the animals can be ascertained and the appropriate level chosen for any particular study. When work is extended to human tissues, the availability of fresh material becomes limiting and suitable controls may be difficult to obtain. Human breast tissue was studied initially because of its availability on removal for biopsy examination and after mastectomy operations. In all cases, the most normal-looking tissue was examined though it must be remembered that a number of variables do exist between patients, for example age and medical history, which may influence the results.

Method

Biopsy material for frozen section analysis (Cases 1,2,4,5,6 and 7), and tissue obtained from the periphery of a mastectomy specimen (Case 9), was cut into 1-2mm³ blocks and immersed in fixative solution at 4°C to await collection from the Department of Histopathology at Dryburn Hospital, Durham. On arrival at the University, specimens were cut into smaller pieces under fixative and stored in fresh fixative at 4°C for up to 5 days.

The fixative was decanted and the samples quickly rinsed twice in 100mM sodium cacodylate, pH 7.2/7.3 (hereafter, cacodylate buffer) before being immersed in fresh cacodylate buffer for 2X10 minutes at 0°C with swirling. The buffer was decanted and the samples quickly rinsed twice with osmium tetroxide in cacodylate buffer before post-fixing in the same solution at room temperature for 3 hours. After further rinsing in cacodylate buffer for 2X10 minutes with swirling, the samples were dehydrated in ethanol (70% - 2X15 minutes, 95% - 2X15 minutes, absolute - 2X15 minutes).

After dehydration, the tissue was cleared in absolute alcohol/epoxypropane (1:1 v/v) for 2X30 minutes and then infiltrated with epoxypropane (2X30 minutes). The tissue was immersed in epoxypropane/resin (1:1 v/v) at 45°C for 30 minutes and then in absolute resin at 45°C for 30 minutes before arranging the tissue pieces in fresh resin in foil dishes placed at 45°C for 3 hours, then at 60°C for at least 16 hours.

Fixatives :- Cases 1,2,4,5,6 and 9

2.5% glutaraldehyde in cacodylate buffer

Case 7

Modified Karnovsky Fixative - prepared by mixing together the following two solutions.

<u>Solution 1</u>		<u>Solution 2</u>	
Paraformaldehyde	1g	25% glutaraldehyde	5ml
Distilled water	45ml	0.2M sodium cacodylate (pH 7.2/7.3)	50ml
1N NaOH	2-6 drops	CaCl ₂	50mg

6

Post fixatives :- Cases 1,2,4,5 and 6

2% osmium tetroxide in cacodylate buffer

Cases 7 and 9

1% osmium tetroxide in cacodylate buffer

Resins :- Cases 1,2,4 and 5

Epon - prepared by taking

Epikote 812 47g

DDSA 21g

MNA 32g

DMP 30 1.4ml

(all EM Scope reagents) and stirring the resulting mixture for 10 minutes at room temperature.

Cases 6,7 and 9

Araldite Mixture - prepared by stirring together

Araldite M (CY212) 10ml

DDSA 10ml

Dibutyl phthalate 1ml

DMP 30 0.5ml

(all EM Scope reagents).

Once embedded, blocks were selected, semi-thin (approximately 2 μ m thick) sections cut and then stained with 1% toluidine blue before being examined in the light microscope.

Suitable arterioles were blocked down for further analysis and thin sections cut and stained (uranyl acetate - 10 minutes, lead citrate - 10 minutes) prior to examination in the Philips 400 electron microscope. The structure of the vessel walls and the surrounding adventitia received special attention.

Results

Light Microscopy

Cases 1,2,4,5,6 and 7

All the material examined in this experiment came from patients, age 57,44,58,63,51 and 34 respectively, with invasive ductal carcinoma and so normal tissue features were obscured. Initial impressions were of histological chaos characterised by tissue degeneration, elastosis and the presence of multiple malignant nests. Abundant fibrous tissue was present throughout the material, exhibiting elongate cells with dense-staining nuclei (plate 1). Elastotic fibres were variable in size; thin elastosis tended to be periductal whereas thicker fibres were found in areas of dense fibrous tissue (plate 2). Malignant cells were characterised by the presence of pleomorphic nuclei often containing several nucleoli some of which were quite large. Atypical mitotic figures were occasionally seen. The tumour cells, heterogeneous in size, shape and density were observed either free, in small clusters or, more usually, in malignant nests, some of the latter showing encapsulation by a layer of flattened cells with dark-staining nuclei (plate 2). Encapsulation was independent of nest size. In some instances, an immune response was apparent, with areas of lymphocytic infiltration often close to well-defined blood vessels (plate 3). Plasma cells and mast cells were also abundant in localized regions.

In invasive ductal cancer, much of the ductal structure had been destroyed by the disease and so the normal vascular pattern in relationship to the ducts was obscured. While the larger vessels, those to be examined by electron microscopy, could be readily differentiated and a function proposed, this became progressively more difficult for the smaller vessels whose structure was disparate and whose populations probably included tumour-induced vessels (Jones, 1979b).

Case 9

Case 9 material was obtained from the periphery of a mastectomy specimen removed from a patient, age 52 years, suffering from invasive ductal carcinoma. Very few of the characteristic features of the disease were seen, indicating that the tissue was near normal. The only evidence to suggest neoplastic activity was slight anaplasia of the columnar epithelium of a single duct. Abundant fibrous tissue, showing no sign of disorder or degeneration (plate 4) was present, together with normal lobules (plate 5), ducts and a few well-defined blood vessels. Occasional lymphocytes, plasma cells and mast cells were also observed.

Electron Microscopy

21 arterioles from 7 patients have been examined in the electron microscope and both normal and malignant material has been studied and no differences seen. Characteristic features of the endothelium, smooth muscle and adventitia were observed (Jones & Kendall, 1980).

Endothelial cells, often linked by interdigitations and showing occasional paramembranous densities along the cell junction, were found to possess a rich and varied cytoplasm (plates 6 & 7). In addition to mitochondria, vesicles and free and bound ribosomes, dense nets of microfibrils were observed, the latter possibly contributing to cell structure and affording a means of intracytoplasmic compartmentation. Golgi complexes were also present, suggesting the cells were manufacturing certain proteins for export. Large endothelial cell inclusions were also seen (plate 8). In the endothelial cell nuclei, the nucleoplasm was surrounded by a characteristic dense band immediately within the nuclear membrane.

An unusual cell, probably a macrophage, was observed, seeming to penetrate the endothelial layer (plate 7). This cell had a number of cytoplasmic processes and an increased density compared with the adjacent endothelial cells.

Smooth muscle cells were present in distinct layers in the larger vessels, separated from each other by material appearing to be continuous with the basement membrane. In the smaller vessels, however, the muscle often formed discontinuous layers exposing part of the endothelium to the adventitia. The muscle cells themselves showed a characteristically rich cytoplasm, consisting partly of densely-packed myofibrils lying parallel to the long axis of the cell. Mitochondria and ribosomes were also present, many of the latter bound to the endoplasmic reticulum. Micropinocytotic vesicles were observed in abundance at the plasma membrane, mostly at the abluminal surface (plate 9). These vesicles, or caveolae, were measured from photographs to the nearest 10nm, and were found to have mean dimensions of 46.1nm X 64.6nm, with standard errors of 1.1 and 0.6nm respectively (sample size = 106). The caveolae appear to be smaller than those measuring 70 X 120nm reported by Gabella (1981) in the smooth muscle cells of the gastro-intestinal tract. Some large granular vesicles were also occasionally present in the vascular smooth muscle cytoplasm.

The basement membrane surrounding the muscle layers varied in thickness from vessel to vessel and within the same vessel.

Within the adventitia there was an abundance of fibroblasts, their long thin processes extending around the vessel. Sections through the fibroblast cell bodies revealed the characteristic cytoplasm containing golgi structures, many bound ribosomes and free polysomes, mitochondria and numerous cellular inclusions. Vesicles were seen fusing with the cell membrane. In areas of high fibroblast density around the vessel, there was also abundant collagen and this,

together with the presence of the golgi, ribosomes and mitochondria within the fibroblasts, suggests that the cells are highly active. Scanning the adventitia at high magnifications (90,000X) failed to reveal any periarteriolar axon profiles (see plate 8) in all the vessels examined (Jones & Kendall, 1981).

Discussion

No obvious differences were observed between the vessels studied in the normal tissue from case 9 and the vessels in the carcinoma tissue from the other cases. It can therefore be assumed that the well-defined vessels from the pathological cases are near normal.

The absence of periarteriolar nerve fibres in all 21 vessels studied from 7 patients indicates that blood flow through the breast in the age range 34-63 years, is not controlled by autonomic nerves running along the vessel length. The possibility remains however, that axons supply the vessels at discrete sites such as sphincters, branch points or arteriovenous anastomoses.

It was therefore necessary to undertake a gross examination of the tissue using histochemical techniques to identify specific nerve populations. These techniques were initially performed on the rat submandibular gland, the innervation of which has been previously reported (Jones, 1979a), before being extended to human tissues.




Plate 1 Human Breast Case 7. View of fibrous tissue showing elongate cells (E) with dense-staining nuclei. Toluidine Blue. Magnification 450X

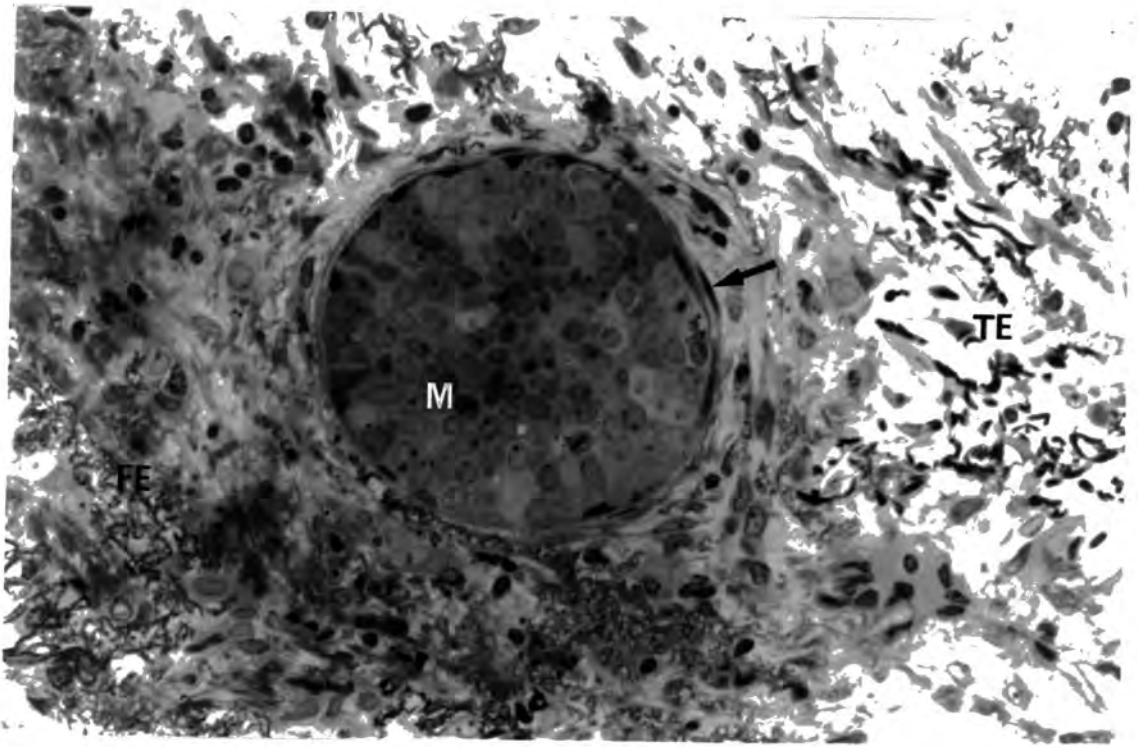


Plate 2 Human Breast Case 7. This shows a small malignant nest (M) encapsulated by a layer of flattened cells (↖). Note the presence of both fine (FE) and thick (TE) elastotic fibres. Toluidine Blue. Magnification 450X

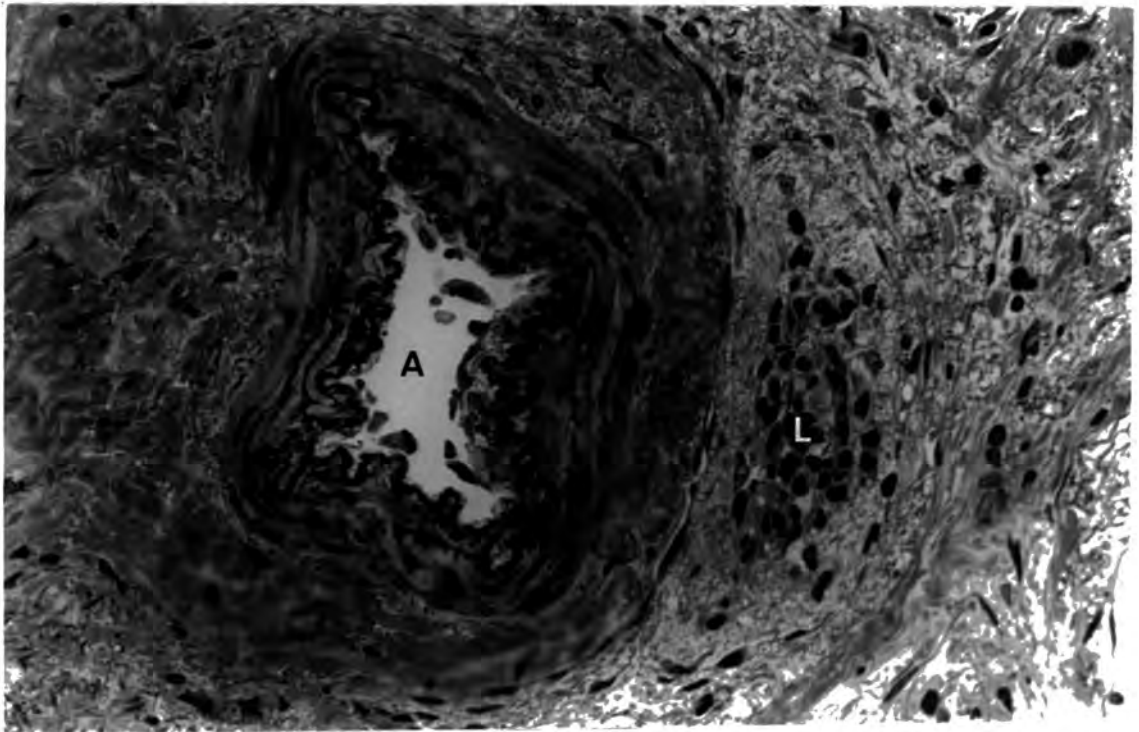


Plate 3 Human Breast Case 7. This plate shows a well-defined arteriole (A) with lymphocytes (L) in the surrounding tissue. Toluidine Blue. Magnification 450X

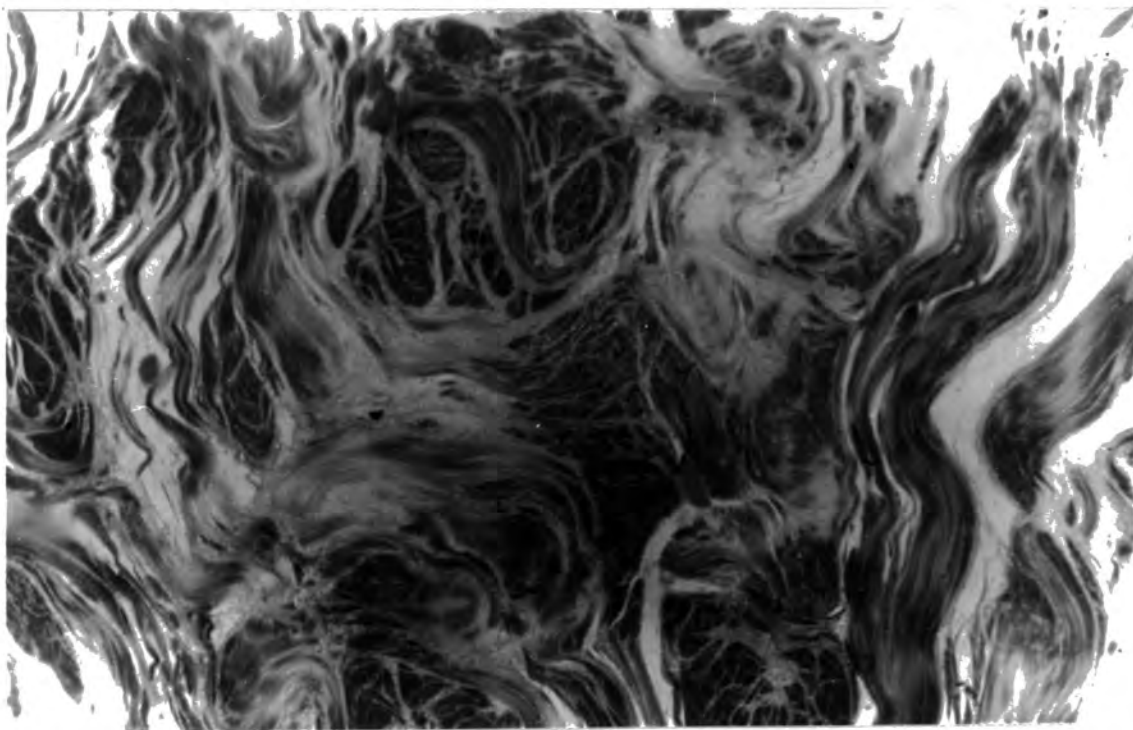


Plate 4 Human Breast Case 9. View of normal fibrous tissue.
Toluidine Blue. Magnification 450X

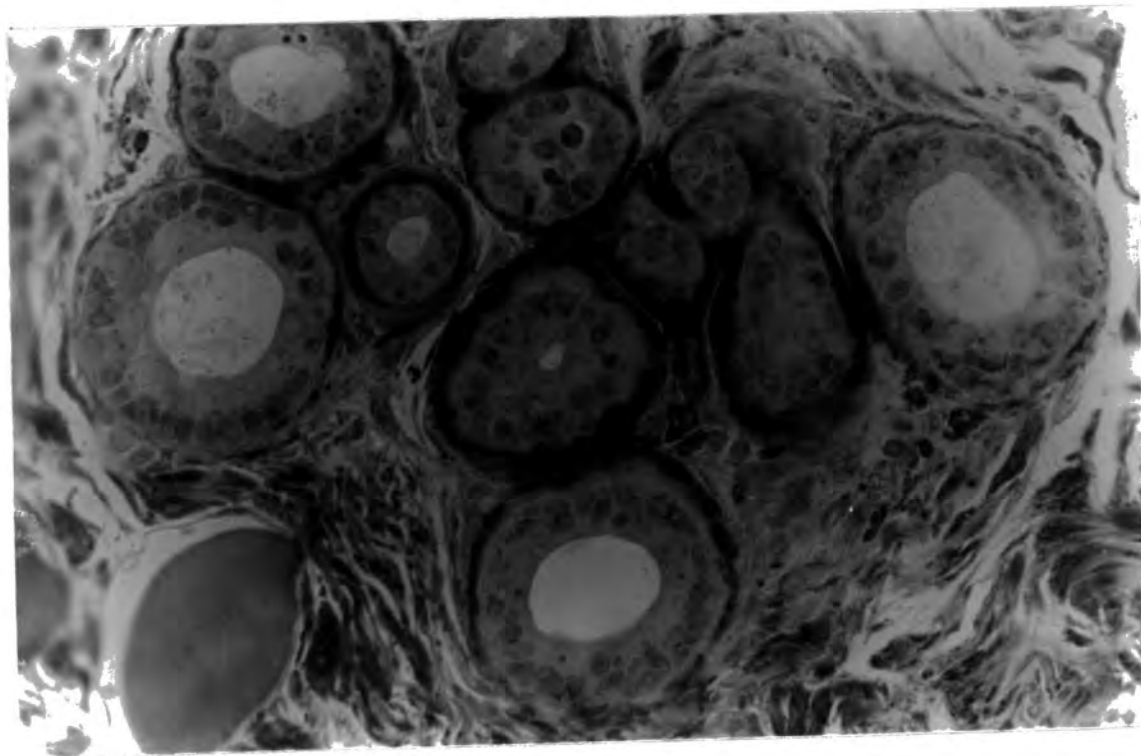


Plate 5 Human Breast Case 9. View of normal lobules and
ducts. Toluidine Blue. Magnification 450X

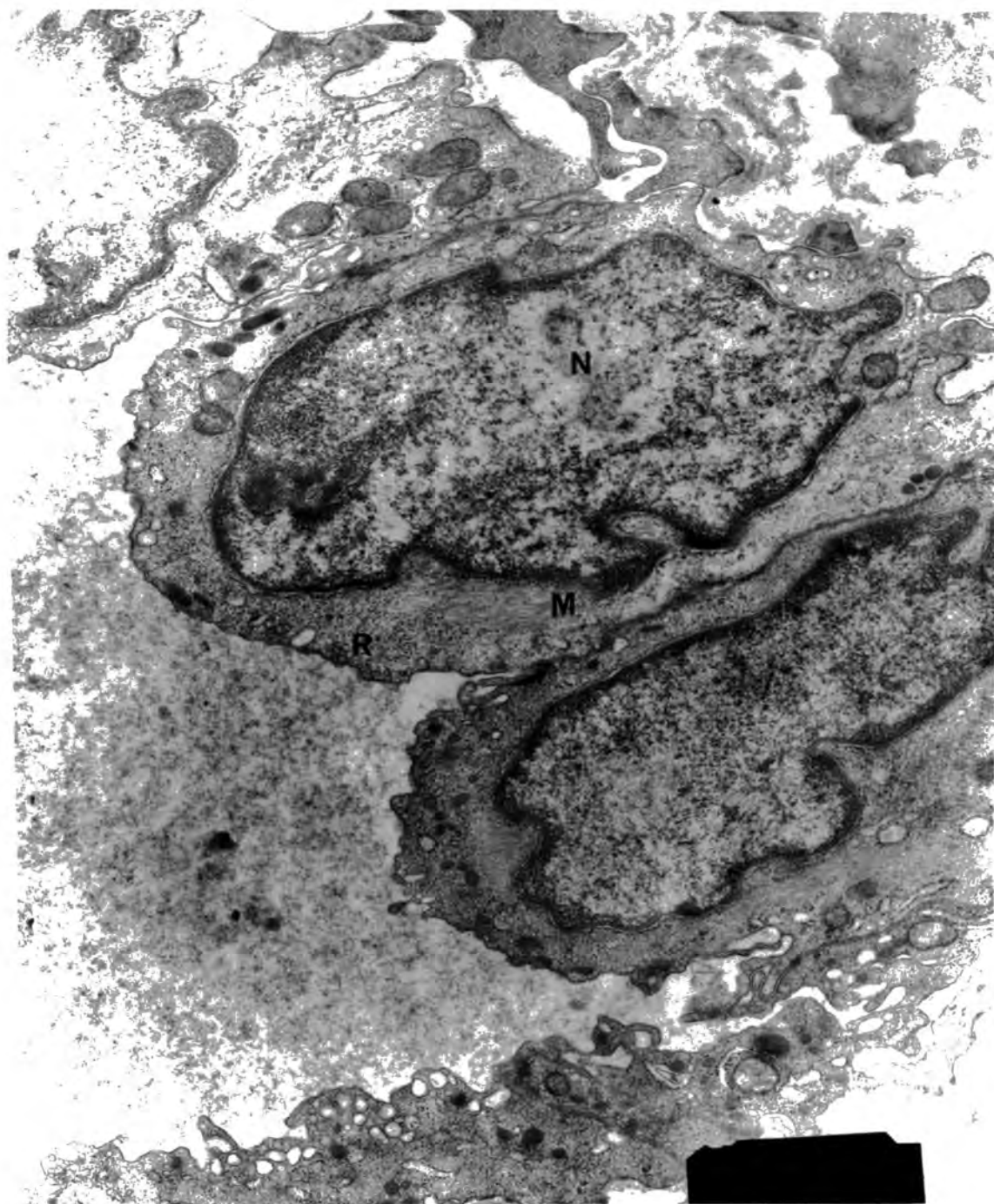


Plate 6 Human Breast Case 1. View of endothelial cells showing typical nuclear staining (N) and the presence of free ribosomes (R) and dense microfibrillar nets (M) in the cytoplasm. EM. Magnification 18,000X

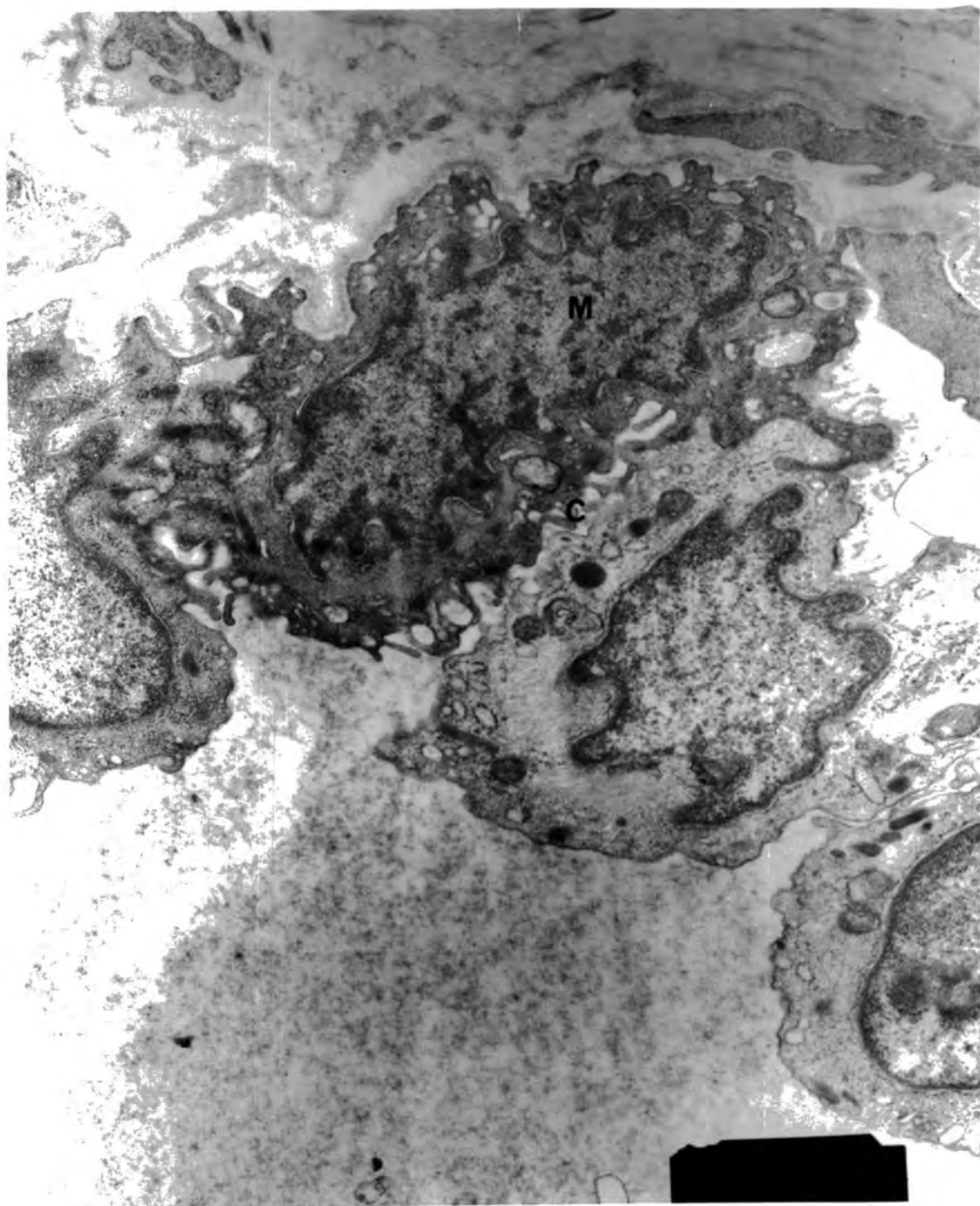


Plate 7 Human Breast Case 1. This shows a possible macrophage (M) seeming to penetrate the endothelial layer. Note the abundance of cytoplasmic processes (C) in the darker cell. EM. Magnification 18,000X

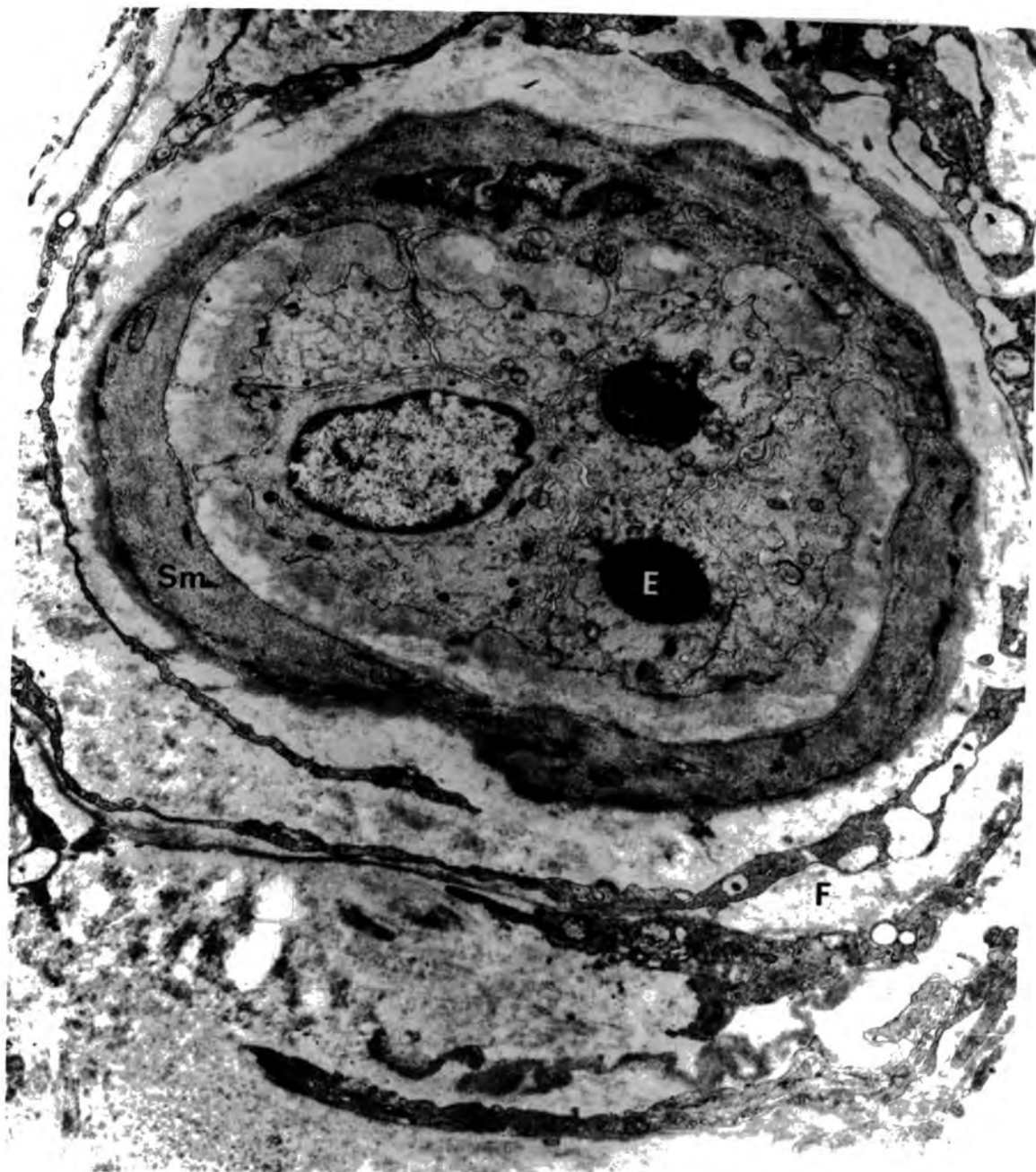

Plate 8 Human Breast Case 5. This plate shows a small arteriole possessing endothelial inclusions (E). Fibroblasts (F) were present outside the smooth muscle layers (Sm). Note the absence of nerves around the blood vessel. EM. Magnification 11,000X

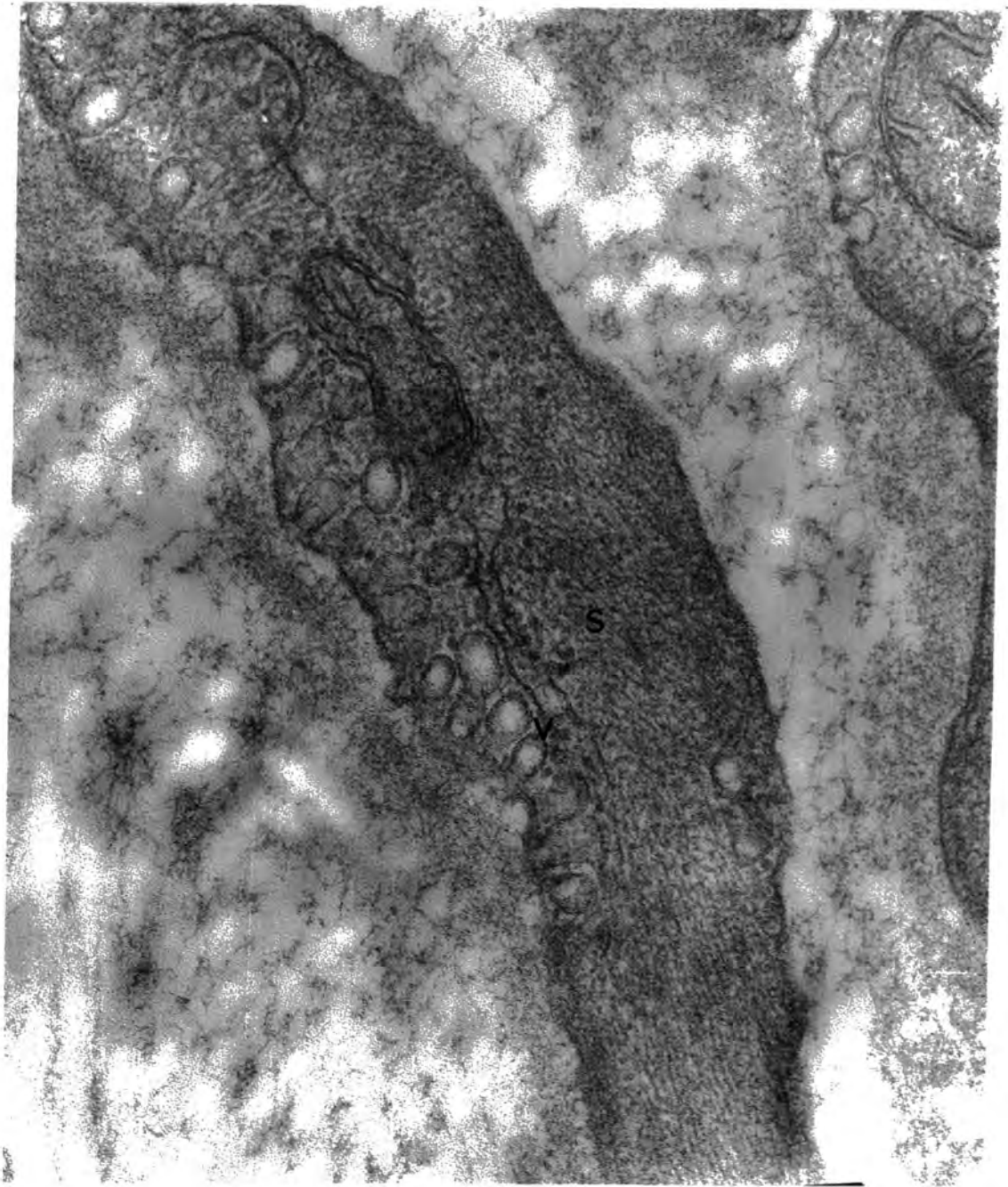


Plate 9 Human Breast Case 1. View of an arteriolar smooth muscle cell (S) showing the generation of micropinocytotic vesicles (V). EM. Magnification 110,000X

Chapter 3

A STUDY OF THE HISTOLOGICAL FEATURES OF THE RAT SALIVARY GLANDS WITH PARTICULAR REFERENCE TO INNERVATION.

1. A Histological Study of Features of the Rat Major Sublingual Gland.

Introduction

The salivary glands, for example in cat, dog and rat, have been shown by histological and physiological techniques to be innervated by both adrenergic and cholinergic autonomic nerves. As such they are useful in verifying histochemical techniques before these are applied to human tissues.

Initially a brief study was performed to identify features of the rat major sublingual gland, especially blood vessels and their innervation.

Method

Major sublingual glands were removed from freshly-killed rats and subjected to the modified chromaffin procedure of Tranzer and Richards (1976) with the clarifications described by Jones (1979a) to facilitate the distinction between autonomic subpopulations in the electron microscope.

The excised glands were immersed in fixative solution (0.1M sodium chromate/potassium dichromate, pH 7.2, containing 1% glutaraldehyde and 0.4% formaldehyde) where they were cut into fine pieces before being transferred to fresh fixative and swirled at 0°C until the total time spent in fixative was 15 minutes.

Following this, the tissue was rinsed twice with storage solution (0.2M sodium chromate/potassium dichromate, pH 6.0) before immersing in this solution for 17-18 hours at 4°C. The following morning, the storage solution was decanted and the specimens post-fixed in 2% osmium tetroxide in 0.1M sodium chromate/potassium dichromate, pH 7.2 for 1 hour at 0°C. The material was then rinsed 3 times in 0.1M sodium chromate/potassium dichromate, pH 7.2 before dehydrating in ethanol (70% - 2X5 minutes, 95% - 10 minutes, absolute - 2X30 minutes) and infiltrating with epoxypropane (2X10 minutes). After this, Epon^{*}/epoxypropane (1:1 v/v) was added and the samples left for 20-21 hours. The next day, the specimens were suspended in Epon mixture for 6 hours before being transferred to fresh Epon mixture in tinfoil dishes and placed in the oven at 60°C for at least 16 hours.

Once embedded, suitable blocks were selected, semi-thin (approximately 2µm thick) sections cut and then stained using 1% toluidine blue. A number of features of the tissue were recorded.

Suitable arterioles were blocked down for further analysis and thin sections cut and stained (uranyl acetate - 10 minutes, lead citrate - 10 minutes) prior to examination in the Philips 400 electron microscope.

Results

Light Microscopy

The blood vessel types were differentiated according to wall structure. Larger vessels were readily identified but capillaries

* For details of preparation see page 66 .

and small venules were more difficult to distinguish. Many of the larger vessels were found in close apposition to ducts (plate 10) whilst capillaries penetrated the inter-acinar spaces. Some mast cells were also observed, especially around arterioles (plate 11). Myoepithelial cell processes encompassed the acini. Attempts were made to distinguish different duct types and both striated ducts (plate 10) and intercalated ducts (plate 12) were observed.

Electron Microscopy

The ultrastructural study of the periarteriolar nerves produced results similar to those of Jones (1979a) for the rat submandibular gland, in that arterioles had a denser innervation than venules. Capillaries had an occasional nerve fibre accompanying them which may have been functional or en route to another site. Basically, two nerve types were revealed, both containing large dense-cored vesicles but one possessing small vesicles with densely stained cores and the other showing small unstained vesicles. These were presumed to represent adrenergic and cholinergic nerves respectively as described by Burnstock (1975 a). All the fibres were unmyelinated and surrounded by a Schwann cell investment. Areas where this investment was partly removed were thought to be neuroeffector sites.

2. A Histochemical Study of Catecholamines in the Autonomic Nerves of the Rat Submandibular and Major Sublingual Glands.

a. Formaldehyde-induced fluorescence technique (FIF)

Introduction

A modification of the formaldehyde-induced fluorescence technique (Falck, 1962; Falck, Hillarp, Thieme & Torp, 1962; Falck & Owman, 1965; Eranko, 1967) was used to identify adrenergic nerves in the rat submandibular gland. It is well established that reserpine depletes biogenic amines (Jonason, 1969) therefore pre-treatment of animals with reserpine distinguishes the fluorescence due to stored catecholamines from the autofluorescence of the tissue.

Method

Groups 1 and 2

Four male rats (group 2) were injected with 0.5mg/kg reserpine in sodium acetate buffer, pH 4.5 daily for 7 days and 3 rats (group 1) were injected with the buffer alone.

The submandibular glands were quickly removed from the animals and immersed for a few minutes in isopentane cooled over liquid nitrogen, before being stored at -70°C .

The tissue was dried over fresh phosphorous pentoxide in a desiccator, the latter being placed in a 70% alcohol bath at -30°C and connected to a vacuum pump. A vacuum of 5×10^{-4} mmHg was maintained during the 5 day freeze-drying process. After this time the freezer was switched off but kept closed, bringing the temperature

to -20°C for 24 hours, and then opened to allow the desiccator to return to room temperature overnight. Finally the desiccator was placed in a 70°C water bath for 1 hour. A high vacuum was maintained throughout these temperature changes.

The formaldehyde gas reaction takes place in two stages. If the formaldehyde humidity is over 70% then strong fluorescence is produced but there is diffusion of the catecholamines. If under 50% humidity is present, there is no diffusion, but the fluorescence is weak (M.Saito, personal communication). Therefore the tissue was treated initially with 50% humidity for 1 hour and then with 70% for 2 hours, both steps taking place in an incubator at 80°C . The 50% and 70% formaldehyde humidities are produced by placing paraformaldehyde over 43% and 34% H_2SO_4 respectively, in strong bottles and leaving them to equilibrate in the dark for 1 week, and in the 80°C oven for at least 1 hour prior to the addition of the tissue.

Following the formaldehyde reaction, the tissue was embedded in paraffin wax under high vacuum for 1.5 hours at 70°C . $20\mu\text{m}$ sections were cut and collected on slides, and the wax removed by xylene. The slides were mounted in fluoromount and examined under the fluorescence microscope. Suitable areas were selected for photography.

Group 3

The submandibular glands of 2 rats were rapidly removed and frozen in isopentane cooled over liquid nitrogen before being stored at -70°C . Tissue was processed as previously described for groups 1 and 2 but with a reduced freeze-drying period of 1 day at -30°C , before switching off the freezer.

Group 4

The submandibular gland was quickly removed from a rat and frozen in isopentane, cooled over liquid nitrogen, the latter also being used for the storage of the tissue. 10 μ m sections were cut on a cryostat at -30°C and then dried at room temperature, 35°C and 45°C for 20 minutes. Slides dried at each temperature were then subjected to the two step formaldehyde vapour reaction for 10, 20 and 60 minutes at 50% relative humidity and 20, 40 and 120 minutes respectively at 70%. Mounting in fluoromount and examination in the fluorescence microscope was as before.

Results

Group 1 (control rats)

A dark green background autofluorescence was observed in the acinar cells, interspersed by bright yellow-green fluorescent fibres (plates 13, 14, 15 and 16). The ducts autofluoresced more strongly than the acini, as did the walls of the blood vessels. Differentiation between the vessel types was on the basis of the wall structure, relative diameter size and luminal contents. Ducts showed columnar epithelial cells and unstained lumina whereas venules and some arterioles had brown staining material in the lumen. Venules also tended to be larger and have thinner walls than the accompanying arterioles. Vessel identification was verified by reference to the previous work on rat salivary glands stained with toluidine blue. Fibres were observed around the arterioles (plate 16) but venules were sparsely innervated. No fluorescent fibres were seen around the ducts (plate 17).

Group 2 (reserpinized rats)

The autofluorescence of the acini, ducts and vessels was similar to that in the controls but no yellow-green fibres were observed around the blood vessels or among the acini (plates 18 and 19).

Group 3 (short freeze-drying period)

Examination in the fluorescence microscope revealed less autofluorescence of the ducts and acini but greater fluorescence of the arteriolar elastic lamina, than in the 6 day freeze-drying procedure. No yellow-green fibres were seen among the acini although they were clearly visible in the adventitia of arterioles. Many mast cells, containing highly fluorescent granules, were present near blood vessels and ducts, this position being as previously described in toluidine blue stained sections of rat salivary gland.

Group 4 (no freeze-drying period)

The autofluorescence increased in intensity with increased formaldehyde vapour treatment. No nerve fibres were observed during the shorter time periods, but with the longer reaction time faint yellow-green fibres could be seen among the acini. The bright autofluorescence, however, made detailed examination impossible.

b. Glyoxylic acid fluorescence technique (GAF)

Introduction

The formaldehyde-induced fluorescence technique, although demonstrating specific catecholamine fluorescence, has several drawbacks which are overcome by the glyoxylic acid fluorescence

technique (Axelsson, Björklund, Falck, Lindvall & Svensson, 1973; Lindvall & Björklund, 1974). Firstly, the FIF technique requires several days freeze-drying of the tissue to produce optimal results; attempts at shorter freeze-drying times have not produced sufficient contrast between specific- and auto-fluorescence. The GAF technique, however, consists of a simple and quick procedure, producing 4-6 times the specific fluorescent yield of FIF and low background fluorescence (Lindvall & Björklund, 1974; Cowen & Burnstock, 1980) thus producing a greater contrast between specific and background fluorescence. This makes the GAF technique more sensitive for areas of low catecholamine concentration such as axons and their terminals (Axelsson et al, 1973; Kyosola et al, 1976; Kirby, McKenzie & Weidman, 1980). GAF is also more stable and less sensitive to humidity than FIF where the outcome of the technique is dependent on the amount of water present (Lindvall & Björklund, 1974). The use of noxious formaldehyde vapour is also avoided with GAF. For these reasons the GAF procedure as modified by König (1979) was used to identify adrenergic nerves in the rat submandibular and major sublingual glands.

Method

The submandibular glands from 3 rats were rapidly removed and frozen in isopentane cooled over liquid nitrogen, before being immersed in liquid nitrogen itself. For longer term storage the tissue was placed in a deep freeze at -70°C .

1% glyoxylic acid solution containing glyoxylic acid monohydrate (Sigma) in 0.236M KH_2PO_4 buffer and 0.2M sucrose (the solution being adjusted to pH 7.4 with a substantial volume of

2M NaOH) was prepared. 20 μ m cryostat sections were collected on slides and immersed in 1% glyoxylic acid solution for 30, 45 or 60 seconds at either room temperature or 0 $^{\circ}$ C. The slides were blotted dry with filter paper and dried for a further 5 minutes with cold air from a hairdryer, then in an oven at 80 $^{\circ}$ C for 5 minutes, before being mounted in fluoromount. They were then placed on a heating plate at 70 $^{\circ}$ C for 3 minutes and examined under ultraviolet light in a Zeiss Ultraphot Photomicroscope. Suitable areas were selected for photography.

The autofluorescence of the acini and ducts was enhanced with increased time in glyoxylic acid. Temperature had no effect within the range studied. With 45 seconds immersion, the autofluorescence was optimal to aid identification of ducts and blood vessels, and to maintain good contrast between the dull green autofluorescence and the yellow-green fluorescence of the nerves. Therefore, glands removed subsequently were processed according to this technique with 45 seconds immersion in glyoxylic acid at room temperature.

In an attempt to differentiate between the specific fluorescence due to catecholamine and the autofluorescence of the tissue, animals were pretreated with reserpine to deplete biogenic amines.

3 male rats weighing approximately 200g each, were injected peritoneally with 5mg/kg reserpine in glacial acetic acid, pH 3.8. 2 control rats were injected with the acid only. 24 hours later, the animals were sacrificed and the capsule containing both the submandibular and the major sublingual glands was removed and rapidly frozen as before. 20 μ m cryostat sections were cut and processed by the glyoxylic acid technique previously described.

Results

The untreated rats and the control rats showed a similar pattern of innervation. Throughout the acinar tissue of both the submandibular and major sublingual glands, strongly yellow-green fluorescent nerve fibres were observed, many showing a beaded appearance. The major sublingual gland had a sparser parenchymal innervation than the submandibular gland and this is demonstrated clearly in plate 20 which shows the junction between the two glands. In addition, a large number of small orange-yellow fluorescent granules were seen in the major sublingual gland. These may be lipofuscin granules (Garrett, 1963) containing waste products of metabolism.

Dense nerve plexuses were seen around the blood vessels, both along their length and at bifurcations (plates 21 and 22). There appeared to be no change in the density of innervation at the branch points. The nerves run both longitudinally and circumferentially around the vessels, appearing as fluorescent points and fibres respectively, when the vessels were examined in transverse section (plate 23). The pale yellow autofluorescent elastic lamina of arterioles is greatly folded in places and is easily distinguished from the brightly yellow-green fluorescent nerves situated in the adventitia. Nerves have not been observed penetrating into the vessel wall. Venules have less innervation than arterioles and no fluorescent fibres have been seen around ducts. Mast cells do not fluoresce with this technique.

Rats pretreated with reserpine showed a complete absence of fluorescent fibres among the acini and around the blood vessels. The autofluorescent elastic lamina, however, remained unchanged (plate 24). These results confirm that the nerves observed using GAF technique contain biogenic amines.

c. Routine histological staining techniques.

To verify the anatomical detail of the tissue examined for adrenergic nerves, the following histological staining procedures were performed on adjacent sections to those used for the GAF procedure.

Haematoxylin - Eosin

20 μ m sections were cut on the cryostat at -30°C . Fixation took place in buffered formalin for 10 minutes at room temperature. The slides were then placed under running tap water for 3 minutes, stained in Mayer's haematoxylin for 3 minutes and rinsed in distilled water, before being placed under running tap water for a further 3 minutes. The slides were dipped into eosin for a few seconds and subsequently rinsed in 95% ethanol for a few seconds, and dehydrated in three changes of butan-1-ol for at least 5 minutes each. The tissue was then cleared in two changes of xylene, for at least 5 minutes each time before mounting in hystomount.

Haematoxylin - Van Gieson

20 μ m sections were cut on the cryostat at -30°C . Fixation took place in buffered formalin for 10 minutes at room temperature. The slides were then placed under running tap water for 3 minutes, washed for 1 minute in distilled water before being stained in Mayer's haematoxylin for 10 minutes. Washing was continued in running tap water for a further 3 minutes and in distilled water for 1 minute. The tissue was then stained in Van Gieson for 3 minutes before rinsing in 95% ethanol for a few seconds and dehydrating in three changes of butan-1-ol for at least 5 minutes each. Two changes of xylene for at least 5 minutes each cleared the tissue prior to mounting in hystomount.

Ducts, blood vessels and acinar tissue were identified as shown by plates 25 and 26.

3. A Histochemical Study of Acetylcholinesterase-Positive Nerves
in the Rat Submandibular and Major Sublingual Glands.

Introduction

Adrenergic nerves are easily identified using the histochemical techniques previously described where the neurotransmitter noradrenaline treated with either formaldehyde vapour or glyoxylic acid, fluoresces under ultra-violet light. Cholinergic nerves, however, cannot be stained directly as at present there is no known stain for acetylcholine (ACh), the cholinergic neurotransmitter. Acetylcholinesterase (AChE), the enzyme involved in the breakdown of ACh, is present in large quantities in cholinergic neurons and is easily stained.

Many authors have simply accepted the staining of AChE as being sufficient to demonstrate cholinergic nerves (for example, Hebb, 1969; Borodulya & Pletchkova, 1973, 1976; Reilly, McCuskey & Meineke, 1976; Tagawa, Ando & Wasano, 1979; Tagawa, Ando, Wasano & Iijima, 1979; Wasano & Iijima, 1979; Kemplay, 1980; Vaalasti & Hervonen, 1980). Other authors have been more cautious. As Lehmann and Fibiger (1979) have noted 'high AChE activity is a necessary but not sufficient characteristic for identifying cholinergic neurons.' AChE activity has been found in a number of seemingly non-cholinergic elements. Barajas and Wang (1975) performed both the FIF and the AChE techniques on rat renal nerves. 6-hydroxydopamine was used to selectively destroy the adrenergic population. Not only did this treatment remove the catecholamine fluorescence, but the AChE-positive fibres were no longer observed, indicating a correlation between the presence of adrenergic fibres and AChE

staining. Ultrastructural studies by Barajas, Wang and De Santis (1976) confirmed this by demonstrating extracellular AChE-positive stain around axons and varicosities. All the axons present contained small dense-cored vesicles, typically adrenergic. No cholinergic axons were observed.

Bogart (1970, 1971) and Jacobowitz and Koelle (1965) however, have demonstrated adrenergic nerves possessing no AChE activity. Many other authors have demonstrated marked differences in nerve plexuses seen in tissues stained consecutively or simultaneously for catecholamines and AChE, thus indicating two separate nerve populations, namely adrenergic and cholinergic, even though they frequently run close to one another (Fisher, 1965; Jacobowitz & Koelle, 1965; Ehinger & Falck, 1966; Garrett, 1967; Kukletová, Zahrádka & Lukáš, 1968; Bolme & Fuxe, 1970; Edvinsson, Owman & Sjöberg, 1976; Iijima, 1977; Amenta, Porcelli & Ferrante, 1979; Rossoni, Machado & Machado, 1979).

Adrenergic nerves, therefore, seem to show differing degrees of AChE activity depending on the species and the tissue studied (Garrett, 1967; Burnstock, 1980). Garrett (1967), Khaisman (1975), Iijima (1977) and Rossoni et al (1979) all comment that adrenergic and sensory nerves tend to have a lower AChE activity than cholinergic nerves and therefore the more strongly stained nerves can be assumed to be cholinergic, but care must be taken over the identification of the lesser stained fibres.

Chubb et al (1980) have recently shown that a purified preparation of AChE hydrolyzes substance P, and a good correlation is demonstrated between the distribution of substance P-like immunoreactivity and AChE staining in the dorsal horn of chick spinal cord. This correlation suggests that AChE may be present

in nerves containing substance P. Positively staining fibres processed by the AChE technique may also have a peptidergic function.

Selective denervations are helpful in the identification of cholinergic nerves in animals, but this is obviously unsuitable treatment for human tissues.

Bearing these problems in mind, a modification of the staining procedure for AChE of El-Badawi & Schenk (1967) was used to demonstrate possible cholinergic nerves.

Method

The technique produces a granular reddish-brown precipitate at the sites of AChE activity, the colour coming from the reduction of ferrocyanide, with the subsequent precipitation of Cu^{++} as cupric ferrocyanide. A brief fixation period in ice cold formalin prevented the loss of AChE activity and an incubation time of 1.5 hours was the optimal time for staining enzyme sites without the occurrence of excess diffusion. The counterstaining was also modified to give optimal results. Ethopropazine was included in the incubation medium as a selective irreversible inhibitor of BuChE, ensuring the specificity of the method for AChE (Naik, 1963; Navaratnam & Palkama, 1965; Jenkinson, Sengupta & Blackburn, 1966; Hebb, 1969; Hebb & Linzell, 1970; Flumerfelt, Lewis & Gwyn, 1973; Silver, 1974).

Submandibular capsules, each containing the submandibular and major sublingual glands, were excised from 4 freshly-killed rats and rapidly frozen by immersion in isopentane cooled over liquid nitrogen before being transferred to liquid nitrogen itself. For long-term storage, the tissue was kept in a deep freeze at -70°C .

20 μ m sections were cut on a cyrostat at -30°C , collected on slides and air dried at room temperature for 3 minutes using a hairdryer. The specimens were fixed in ice cold 4% neutral formalin for 20-25 minutes before being washed thoroughly in two changes of distilled water, 1 minute each time.

Incubation took place at 37°C for 1.5 hours using a solution prepared by adding the following constituents in the order shown.

Acetylthiocholine iodide	25mg
60mM (0.82%) Sodium acetate	31.6ml
100mM (0.6%) Acetic acid	1.0ml
100mM (2.94%) Sodium citrate	2.4ml
30mM (0.75%) Cupric sulphate	5.0ml
1mM (0.035%) Ethopropazine	1.0ml
5mM (0.165%) Potassium ferricyanide	5.0ml
Distilled water	4.0ml

The incubation medium must be used within 30 minutes of being prepared.

After incubation, the sections were rinsed in distilled water before being counterstained in Mayer's haematoxylin for 1 minute. The sections were then washed in distilled water for 1 minute before they were 'blued' under running tap water for 3 minutes. Following this, the tissue was dehydrated in 3 changes of butan-1-ol for at least 5 minutes each, and cleared in 2 changes of xylene, also for at least 5 minutes each.

The sections were then mounted in hystomount and observed in the light microscope. Photographs were taken on the Zeiss Ultraphot and Nikon Optiphot photomicroscopes.

The above method was also applied omitting either the substrate, acetylthiocholine iodide, or the inhibitor, ethopropazine.

To establish the cholinergic nature of the AChE-positive fibres, parasympathectomy of the glands was attempted by the following treatments on anaesthetized rats :- 1) disturbance of the ganglionic complex, 2) clearance of the connective sheath of the duct 2mm north of the point of entry into the gland and 3) a combination of these two treatments. Sham operations were also performed in the first two cases. The submandibular and major sublingual glands were removed 7 and 21 days after the operation and processed as above. These operations were performed by Dr. C.J. Jones with Home Office permission.

Results

The red-brown staining of the nerves by the thiocholine technique was clearly demonstrated. AChE-positive staining of red blood cells was also observed, mainly in venules where red cells were abundant (plate 27) but this did not obscure the staining of the nervous tissue. Densely stained nerve trunks occurred in the connective tissue, often passing near to large arterioles (plate 27) and ducts (plate 31) but not necessarily in close association with them. A rich network of AChE-positive fibres was seen amongst the acinar tissue of the submandibular gland, in marked contrast to the sparse innervation of the major sublingual gland (plate 29). The width of these fibres differed greatly within the same tissue, varying from larger bundles obviously containing a number of axons, to very thin threads where possibly a single axon is running within the Schwann cell. The ducts and venules are sparsely innervated (plates

30 and 31) compared to the dense plexus of fine AChE-positive nerve fibres surrounding the arterioles (plates 27,28,30 and 31).

When acetylcholine iodide was absent from the incubation medium, no positive staining of nerves was observed. On omitting ethopropazine from the incubation medium instead, the density of parenchymal ChE-positive fibres increased, indicating the presence of BuChE activity in the tissue. A marked increase in stained fibres was also observed around the ducts. It is obviously necessary to inhibit the BuChE enzyme to demonstrate AChE activity alone.

Glands from the operated animals showed no difference in the density of innervation from that described either in sham controls or in unoperated animals, indicating that the attempts at parasympathectomy had been unsuccessful or that the nerves needed longer than 21 days to degenerate. The cholinergic nature of the AChE-positive nerves has therefore not been verified.

4. Discussion on the Control of Blood Flow through Salivary Glands.

The results obtained from these techniques employed to identify adrenergic and possible cholinergic nerves in rat salivary glands compare favourably with those of other authors.

A denser parenchymal innervation by yellow-green fluorescent fibres was seen in the rat submandibular gland compared to the major sublingual gland, confirming the previous observations of Norberg and Olson (1965). Comparative studies of the submandibular and sublingual glands in other species, namely mouse (Olson, 1967), guinea-pig (Alm, Bloom & Carlsson, 1973), and human (Rossoni et al, 1979) also demonstrate a similar difference in innervation. This is not the case, however, in the hamster sublingual gland where there is an extensive parenchymal adrenergic network (Alm et al, 1973). The striated ducts of the hamster sublingual gland also show an innervation by fluorescent fibres, in contrast to those of the guinea-pig (Alm et al, 1973), mouse (Olson, 1967) and rat (Norberg & Olson, 1965; Tuch & Matthiesen, 1980) where no fibres have been observed. There is also species variation in the innervation of the ducts of the submandibular gland. Commonly, they are devoid of fibres but some fluorescent nerves have been seen in close apposition to the striated ducts in the cat (Garrett & Kempsey, 1977) and human (Garrett, 1967; Rossoni et al, 1979) submandibular glands. In the present study on rat salivary glands no ductal adrenergic innervation was observed.

The dense adrenergic innervation of the muscular blood vessels is in accordance with previous work on the rat salivary glands using both light microscopy (Norberg & Olson, 1965; Tuch & Matthiesen, 1980) and electron microscopy (Jones, 1979a, 1980).

Formaldehyde-induced fluorescence of mast cells has also been reported both in salivary glands (Norberg & Olson, 1965; Alm et al, 1973) and in other tissues (for example Enerback & Haggendal, 1970; Iijima, 1977; Todd, 1980).

Comparative studies between the submandibular and major sublingual glands, using the AChE technique, have also shown fewer AChE-positive fibres in the parenchyma of the major sublingual gland, but this difference in innervation density is not as marked as with the adrenergic component. These findings are in agreement with the work of Snell and Garrett (1957), Snell (1958) and Bogart (1970, 1971). Also, in the guinea-pig, hamster (Alm et al, 1973) and human (Rossoni et al, 1979) sublingual glands, the parenchymal cholinergic innervation is greater than its adrenergic counterpart. Taking into account that some of the AChE-positive nerves may be adrenergic, the difference in the number of nerves observed by these two techniques, indicates that a more extensive cholinergic than adrenergic population is being stained (Garrett, 1967).

The lack of positive staining obtained when the substrate was omitted from the incubation medium, and the increase in staining on omitting the inhibitor, verifies the specificity of the technique to AChE.

Red blood cells have also been shown to be AChE-positive by other authors (for example, Snell & Garrett, 1957; Garrett, 1967).

In both glands, nerve trunks are seen in the connective tissue and coursing through the parenchyma, commonly adjacent to ducts and blood vessels. Fine fibres have been observed leading from these trunks and forming close associations with the acini, ducts and blood vessels especially the small muscular arterioles around which they form a plexus similar to that of adrenergic nerves.

Electron microscopical studies on the nerves (Bogart, 1970, 1971) demonstrate AChE activity at the axon-Schwann cell interface. Where more than one cholinergic axon is enclosed in a Schwann cell, the whole bundle would stain positively, thus giving rise to the variation in the 'fibre' size from large bundles to single threads. The staining of the axon-Schwann cell interface by the AChE technique accounts for the lack of beaded fibres or varicosities observed, in comparison to the GAF technique where the axon itself is stained.

The difference in innervation patterns of the two glands reflects differing autonomic involvement in secretion, the submandibular being influenced by both the sympathetic and parasympathetic nervous systems, and the sublingual predominantly by the latter. Blood flow in the two glands would appear to be controlled by both adrenergic and cholinergic nerves which supply the muscular blood vessels. This is true, not only for the rat, as shown by this present study and by other authors (Snell, 1958; Norberg & Olson, 1965; Bogart, 1970, 1971; Jones, 1979a, 1980; Tuch & Matthiesen, 1980) but for other species too (for example, mice - Olson, 1967; cow, guinea-pig and hamster - Alm et al, 1973; cat - Garrett & Kemplay, 1977; Human - Garrett, 1976; Rossoni et al, 1979). However, differences can be seen in vascular innervation between the rat submandibular gland and major sublingual gland, the latter having a higher adrenergic to cholinergic axon profile ratio. Non-adrenergic, non-cholinergic axons have also occasionally been seen in the major sublingual gland but have not yet been demonstrated in the submandibular gland (Jones, 1980). These findings suggest major differences in vascular control between the two glands.

Saliva is secreted by the rat (Thulin, 1976), cat and dog (Burgin & Emmelin, 1961) submandibular glands as a result of both

sympathetic and parasympathetic stimulation. Blood flow changes also accompany the salivation. Sympathetic stimulation produces a marked vasoconstriction during the stimulus period followed by an after-dilatation once the stimulation has ended. The vasoconstriction is abolished by alpha adrenoceptor blockade, and the after-dilatation by beta blockade. Parasympathetic stimulation also produces vasodilatation which appears during the stimulus period. This vasodilatation is either wholly or partly atropine-resistant, depending upon species, although the accompanying secretion is blocked (Burgen & Emmelin, 1961). Further investigation of the mediator of this vascular dilatation therefore needed to be undertaken.

Hilton & Lewis (1955a, 1955b, 1956) suggested that the hyperaemia associated with secretion resulted from the release of a stable vasodilator substance, kallikrein, produced by the active gland, and that no special vasodilator nerve fibres were involved in the vascular response. In contrast, Bhoola, Morley, Schachter and Smaje (1965) and Morley, Schachter and Smaje (1966) suggested that kallikrein does not mediate parasympathetic vasodilatation, and the atropine-resistant response of the cat and dog compared to the atropine-sensitive response of the rabbit is a variation in the sensitivity of cholinergic receptors to atropine.

In the case of the sympathetic afterdilatation, beta adrenoceptors are thought to be activated as the response is blocked by propranolol (Morley et al, 1966). Skinner and Webster (1968a) demonstrated that the parasympathetic vasodilatation remaining after atropine treatment was also reduced or abolished by large doses of propranolol, and suggested that beta adrenoceptors were triggered in the parasympathetic response in the same manner as the sympathetic afterdilatation. Schachter and Beilenson (1968) however, showed

that propranolol could act in a non-specific manner by reducing the vasodilatation resulting from close-arterial injection of ACh, and in addition demonstrated that the parasympathetic vasodilatation was unaffected by treatment with reserpine.

Other explanations for the atropine-resistance, and other non-adrenergic, non-cholinergic responses, include the release of ATP from 'purinergic' nerves (Burnstock, 1972, 1975a) and the release of peptides from 'peptidergic' nerves (Bloom & Polak, 1978).

ATP and ADP are certainly potent vasodilators in the submandibular gland. Jones, Mann and Smaje (1980) investigated the role of cyclic nucleotides and a number of other purines in nerve-mediated vasodilatation. Cyclic nucleotide phosphodiesterase inhibitors were seen to potentiate both the sympathetic and parasympathetic vasodilatation, and exogenously added cyclic nucleotides mimicked the response to nerve stimulation, thus indicating that sympathetic and parasympathetic vasodilatation is mediated, at least in part, by pathways involving cyclic nucleotides. The sympathetic after-dilatation is very likely to be mediated by cAMP. cGMP may be involved in the chorda vasodilatation but this has not been satisfactorily established.

Fibres containing VIP immunoreactivity have been found around blood vessels in some salivary glands (Bloom, Bryant, Polak, Van Noorden & Wharton, 1979; Wharton, Polak, Bryant, Van Noorden, Bloom & Pearse, 1979). More recent work by Bloom and Edwards (1980) on cat submandibular gland has shown that on parasympathetic stimulation there is an abrupt rise in the output of VIP from the gland in the presence or absence of atropine. This concentration of VIP when infused intra-arterially produces atropine-resistant vasodilatation similar to that produced by chorda stimulation. The authors suggest that VIP is

released from post-ganglionicparasympathetic neurones and acts as a transmitter to cause atropine-resistant vasodilatation.

The control of the nerve-mediated vascular responses in salivary glands is obviously very complex and probably involved a number of interrelated factors. The present histochemical studies demonstrate the presence of nerves containing high catecholamine and high AChE levels likely to influence the vasculature and therefore to be an important factor in the overall control of blood flow through the glands.

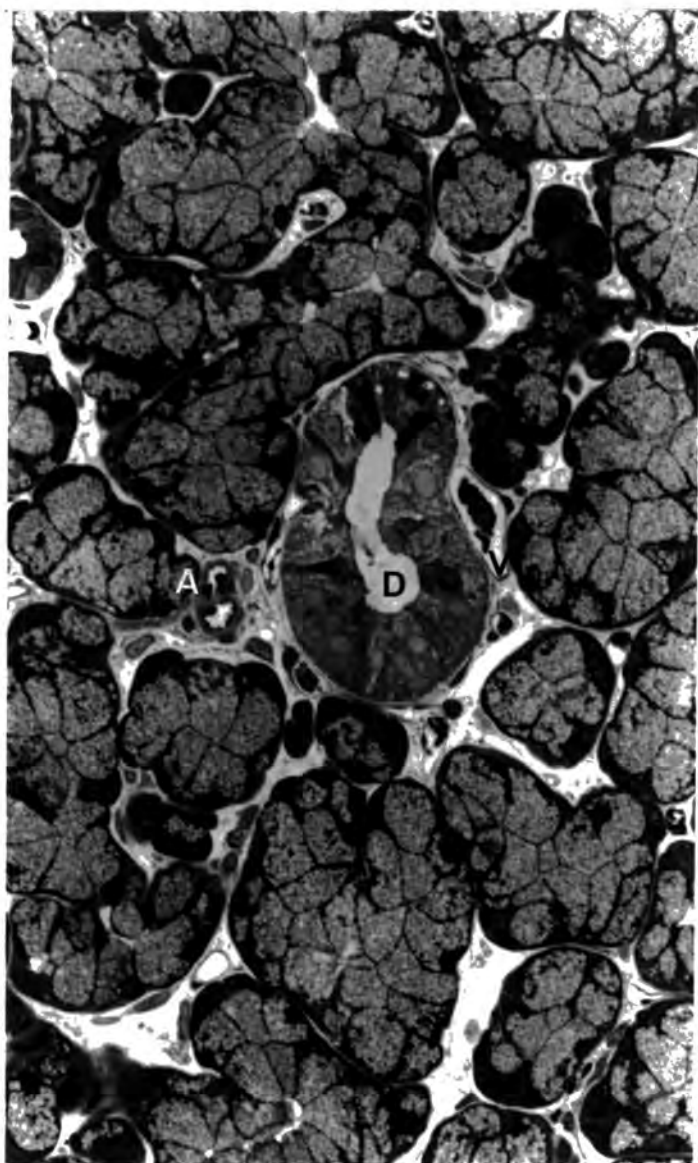
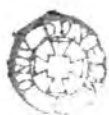

Plate 10 Rat Major Sublingual Gland. This shows a striated duct (D) with surrounding blood vessels, arterioles (A), venules (V), and capillaries, and acini encompassed by myoepithelial cell processes. Toluidine Blue. Magnification 450X



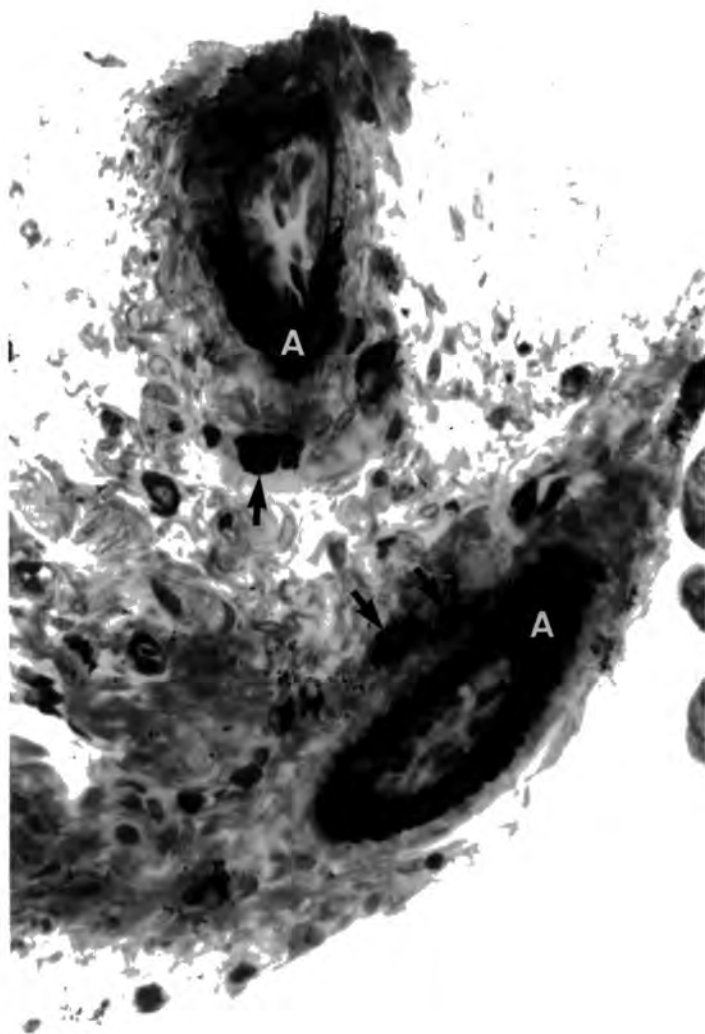


Plate 11 Rat Major Sublingual Gland. This plate shows mast cells (▲) near two arterioles (A). Toluidine Blue. Magnification 450X

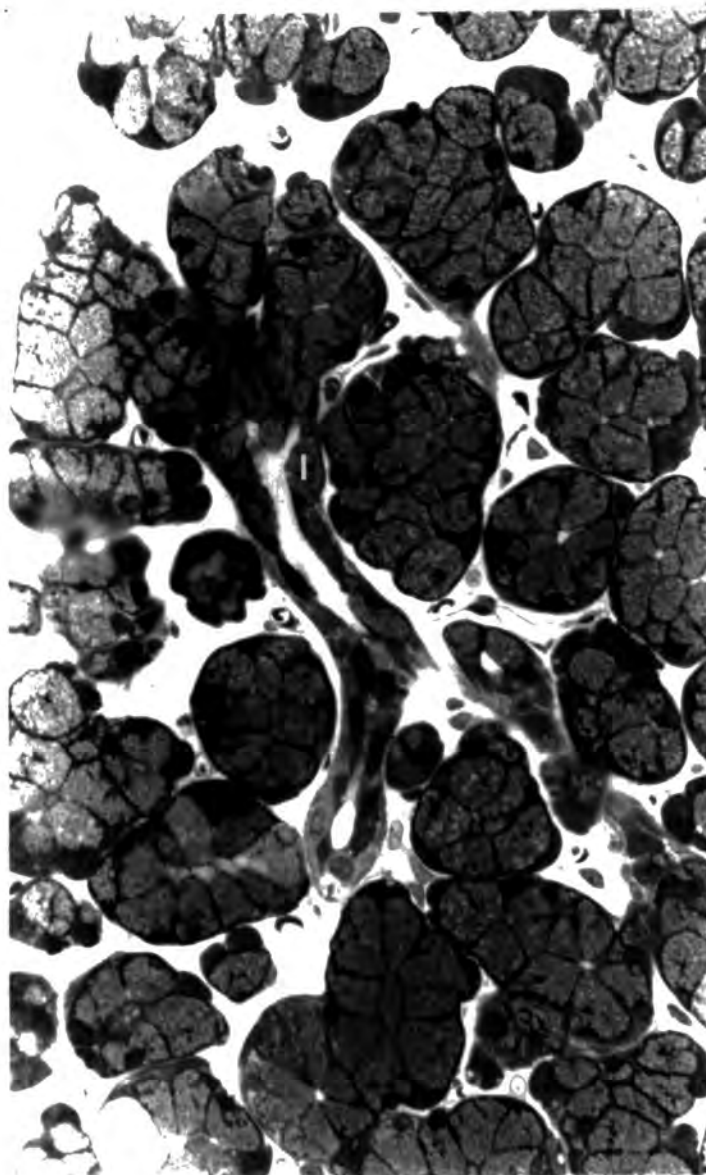


Plate 12 Rat Major Sublingual Gland. Group 1 (control). This shows an intercalated duct (I) emerging from a secretory acinus. Toluidine Blue. Magnification 450X

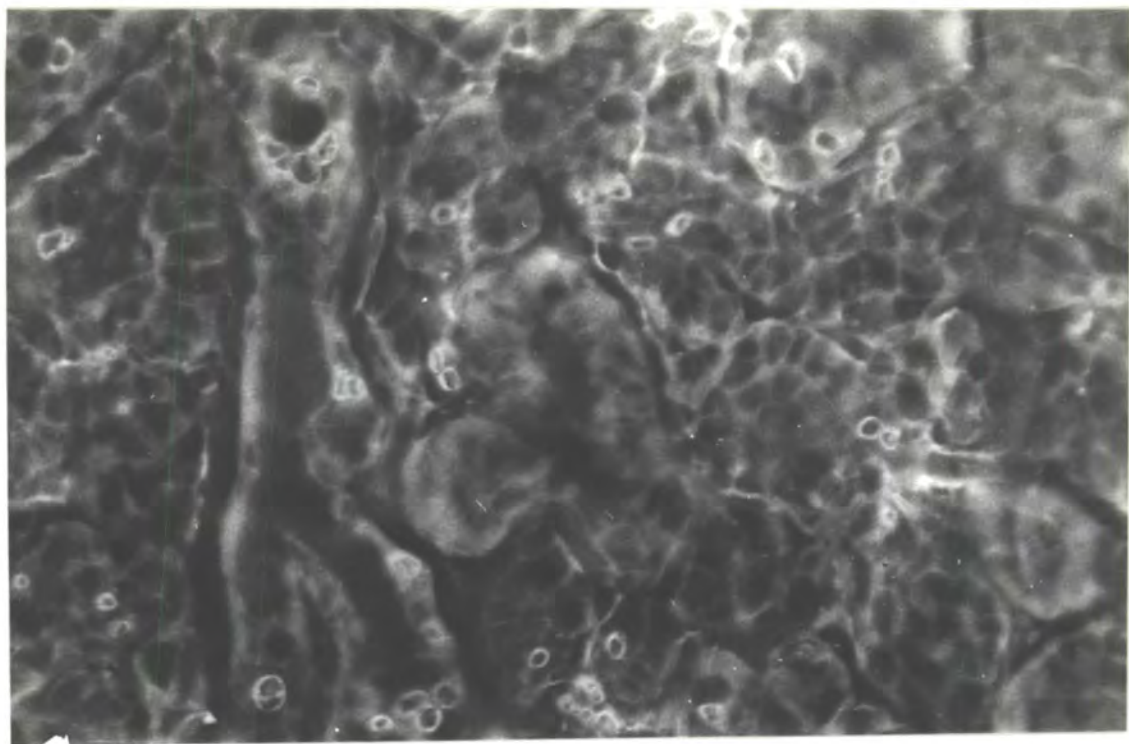


Plate 13 Rat Submandibular Gland. Group 1 (control). View of fluorescent fibres among the acini. FIF. Magnification 450X

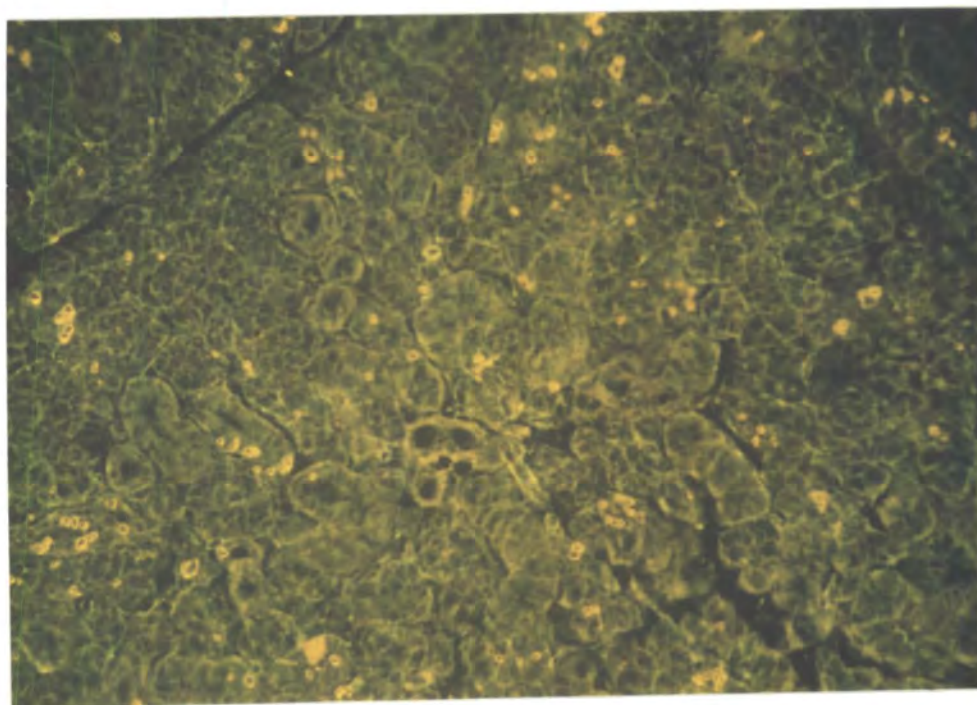


Plate 14 Rat Submandibular Gland. Group 1 (control). View of autofluorescing acini and small ducts. Note the presence of fluorescent fibres among the acini. FIF. Magnification 110X




Plate 15 Rat Submandibular Gland. Group 1 (control). View of duct (D) with two accompanying blood vessels (V), one of which is surrounded by fluorescent nerve fibres (→). FIF. Magnification 110X

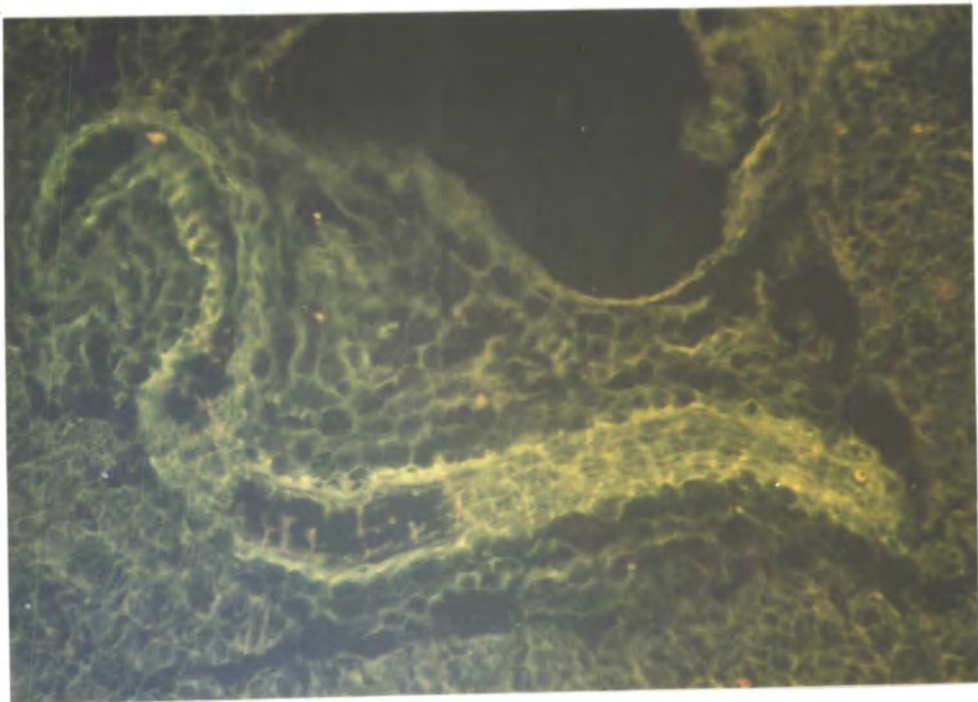


Plate 16 Rat Submandibular Gland. Group 1 (control). This shows an arteriole surrounded by a dense plexus of fluorescent fibres. FIF. Magnification 110X

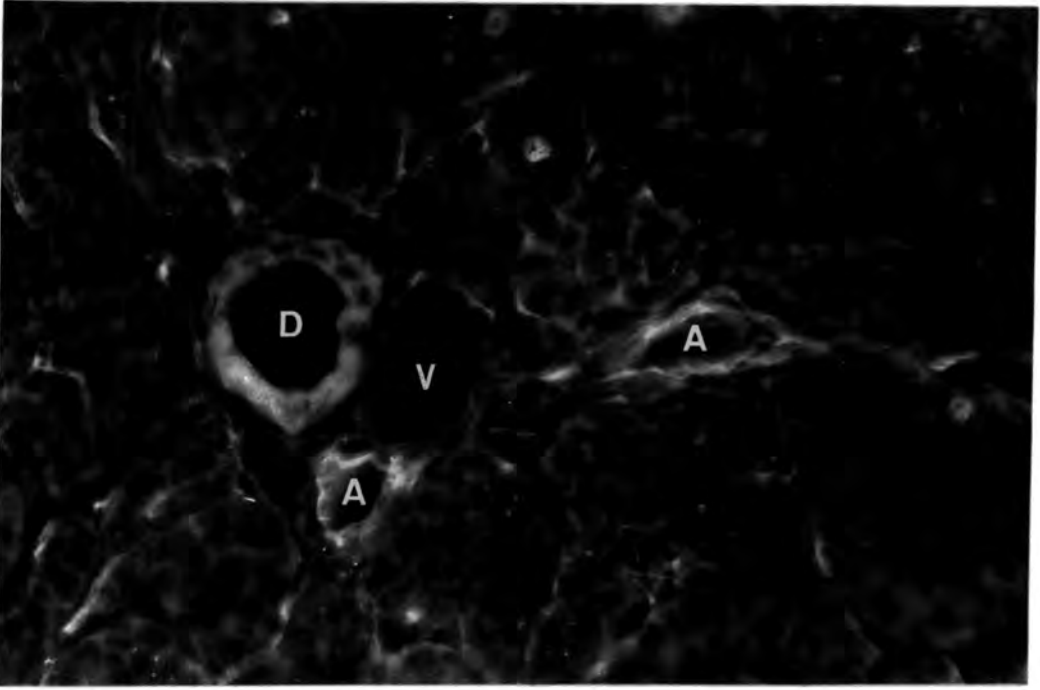


Plate 17 Rat Submandibular Gland. Group 1 (control). View of a duct (D) accompanied by innervated arterioles (A) and a venule (V) almost devoid of fibres. FIF. Magnification 450X

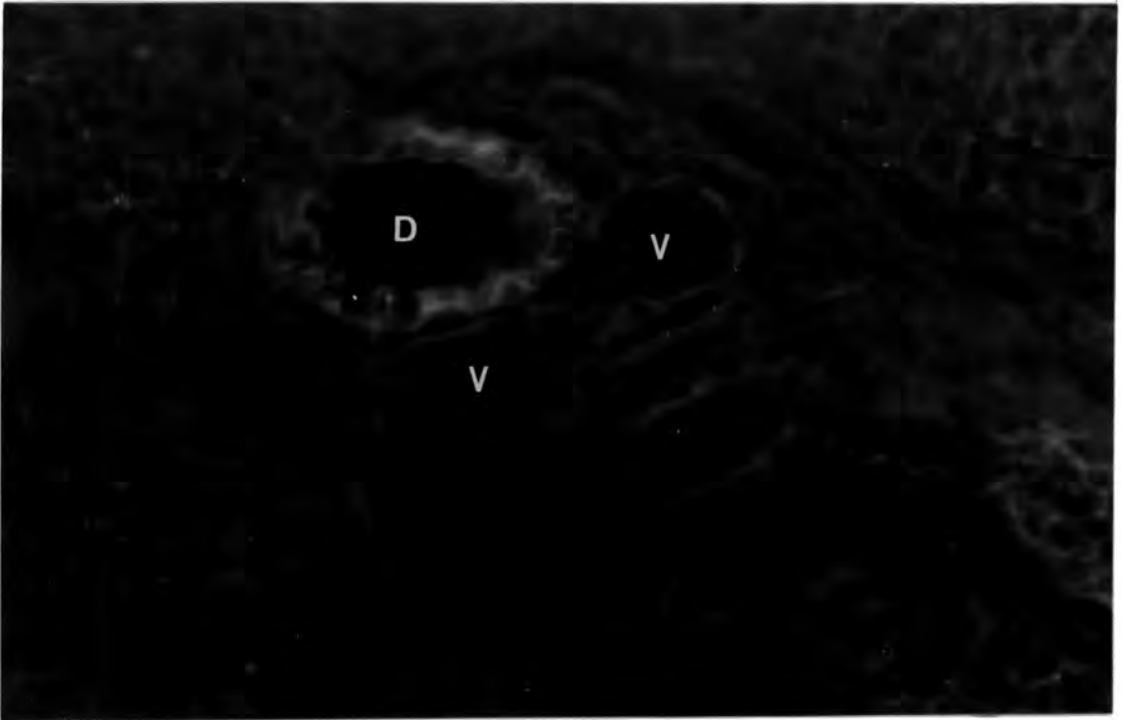


Plate 18 Rat Submandibular Gland. Group 2 (reserpine). This plate shows an autofluorescing duct (D) with accompanying blood vessels (V). Note the absence of fluorescent nerve fibres surrounding the vessels and among the acini. FIF. Magnification 450X

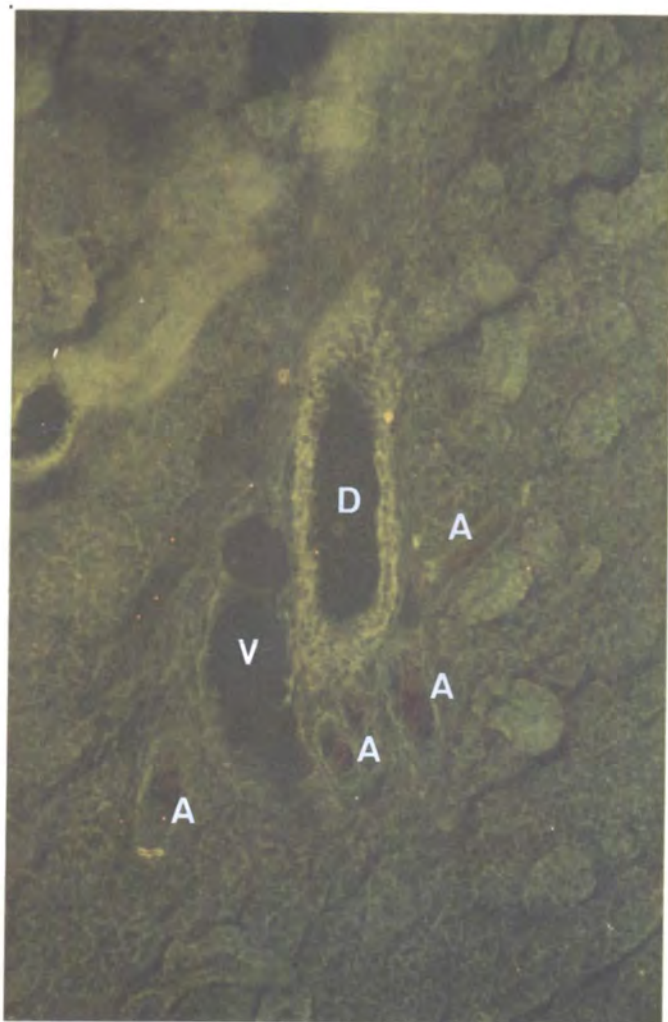


Plate 19 Rat Submandibular Gland. Group 2 (reserpine). This shows a duct (D), with a strong autofluorescence, accompanied by a venule (V) and several small arterioles (A). Note the absence of fluorescent fibres. FIF. Magnification 110X




Plate 20 Rat Salivary Glands (control). The junction between the submandibular gland (A) and the major sublingual gland (B). Note the greater density of beaded nerve fibres (↖) in the submandibular gland, and the possible lipofuscin granules in the major sublingual gland (↗). GAF. Magnification 275X

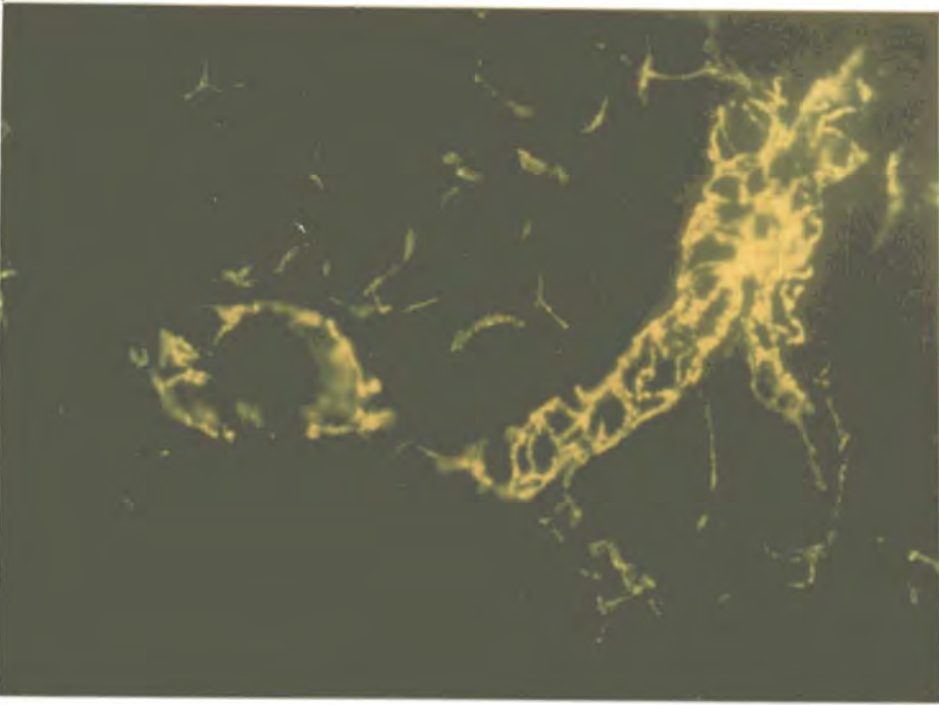


Plate 21 Rat Submandibular Gland (untreated). This plate shows a transverse section and a longitudinal section through blood vessels with a rich adrenergic innervation. GAF Magnification 275X

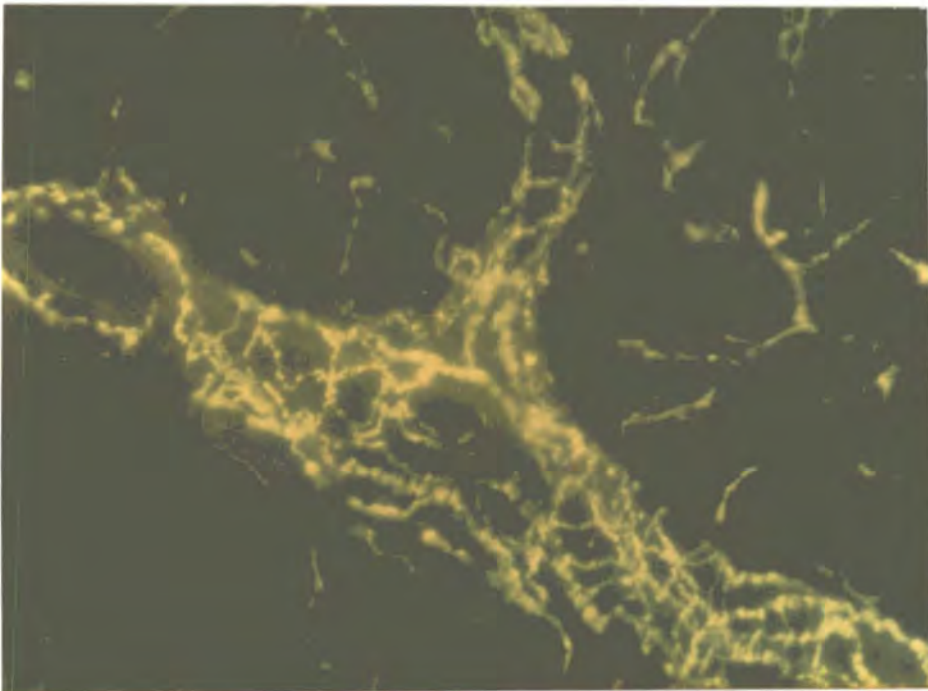


Plate 22 Rat Submandibular Gland (untreated). The bifurcating vessel shown on this plate is surrounded by a dense adrenergic plexus of beaded fluorescent fibres. GAF. Magnification 275X

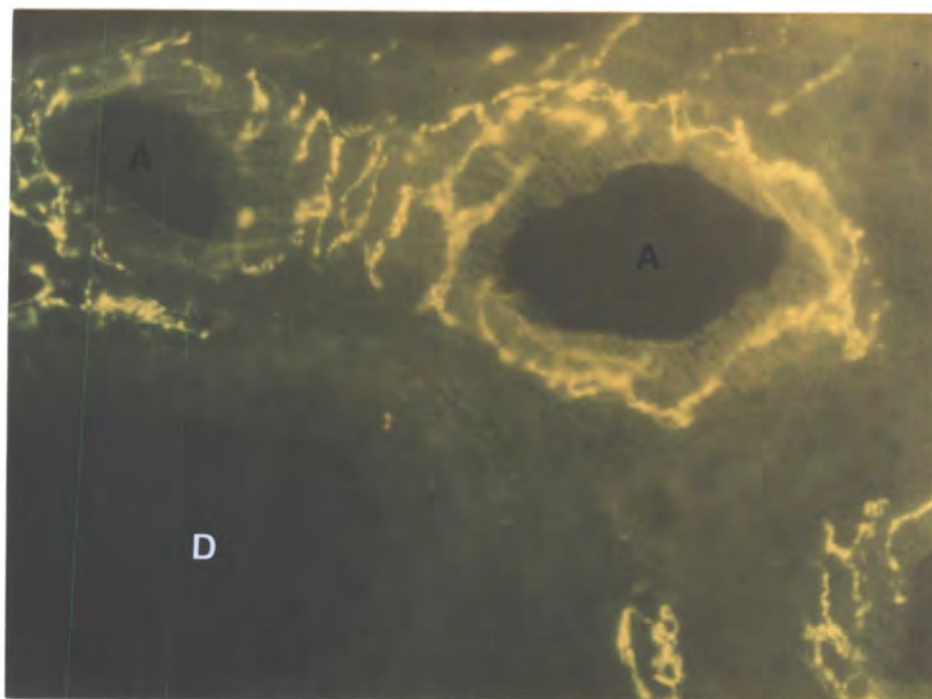


Plate 23 Rat Submandibular Gland (control). Transverse section through a duct (D) and arterioles (A) close to a bifurcation. Note the pronounced adrenergic innervation of the blood vessels. GAF. Magnification 275X

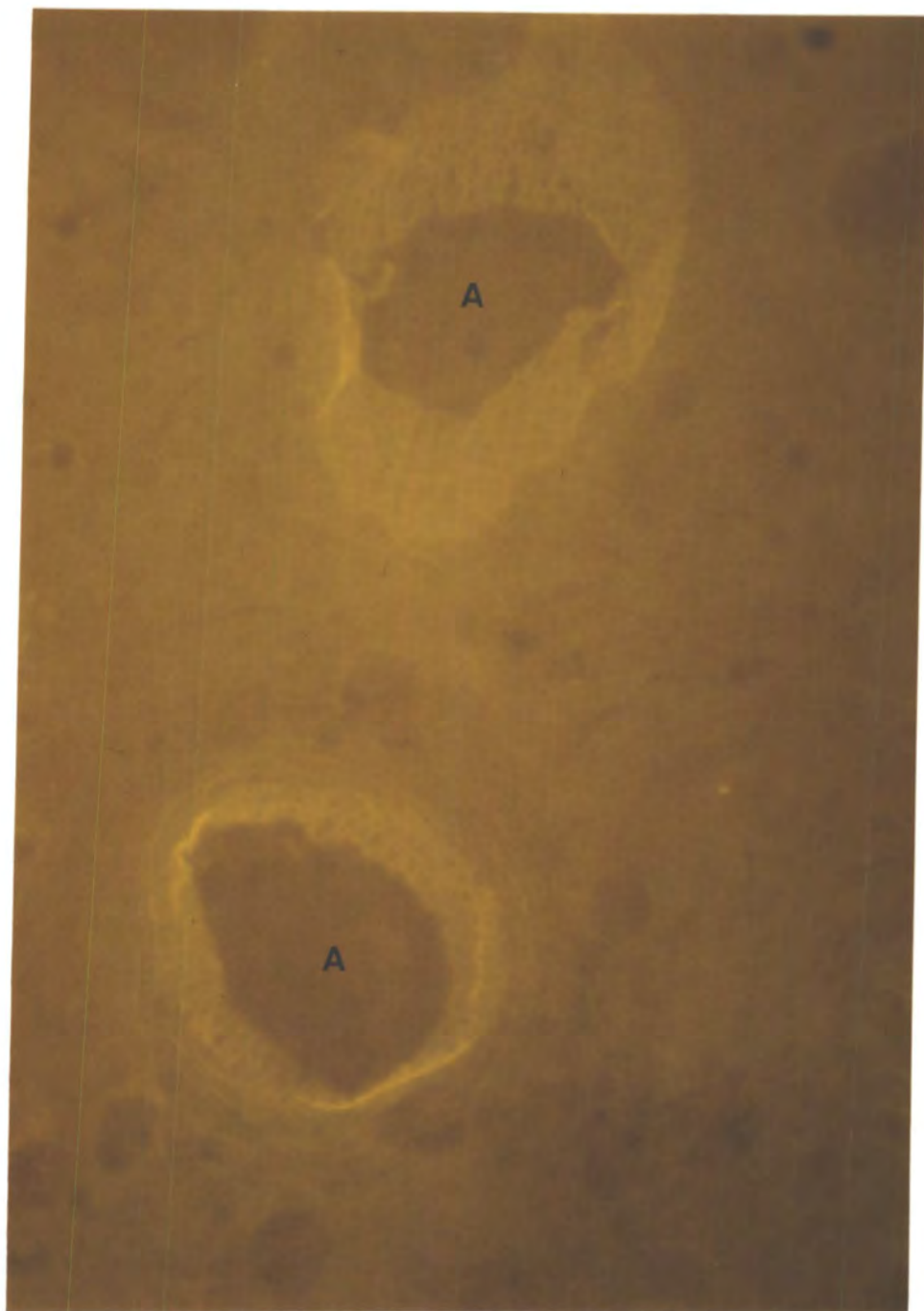


Plate 24 Rat Submandibular Gland (reserpine). View of two arterioles (A) showing the autofluorescent elastic laminae but no adrenergic nerves. GAF. Magnification 550X

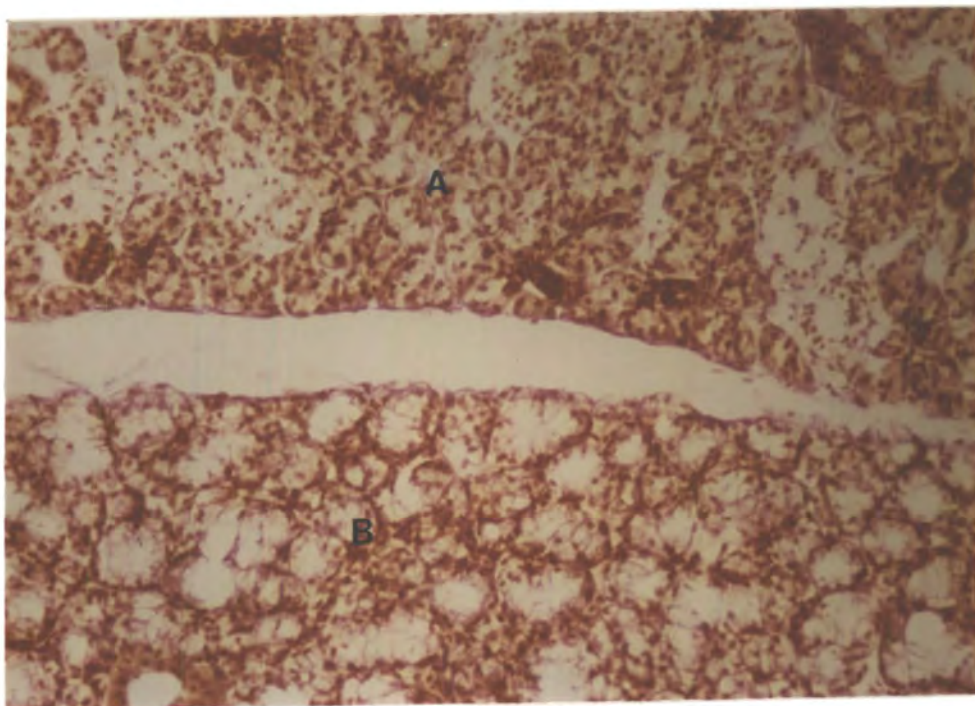


Plate 25 Junction between the rat submandibular (A) and major sublingual (B) glands. Hx-VG. Magnification 140X

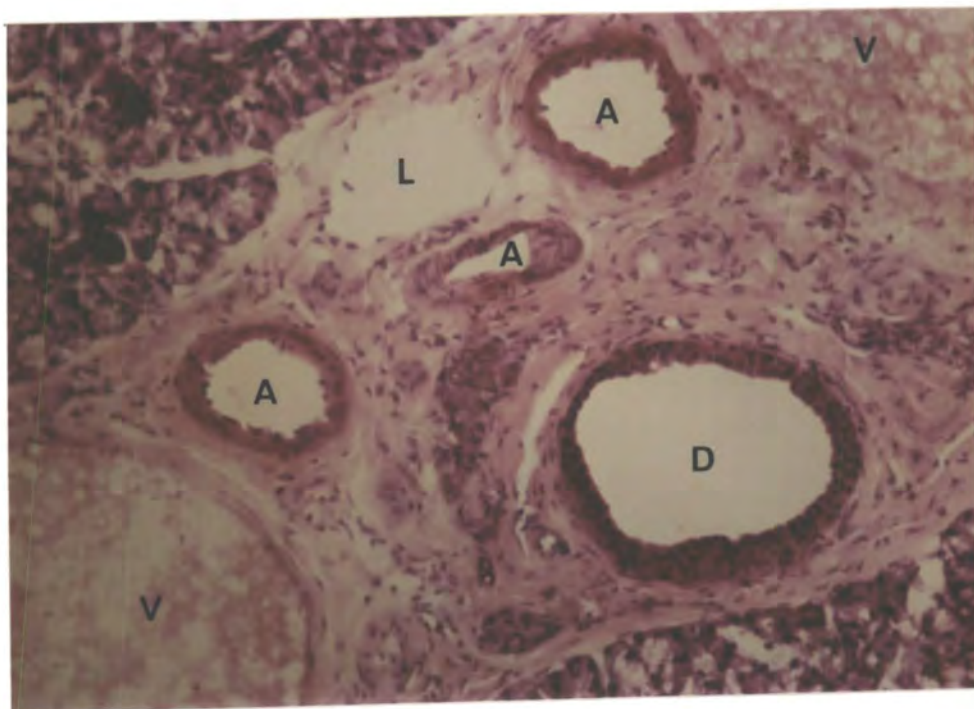

Plate 26 Rat Submandibular Gland. This shows the typical features of ducts (D), venules (V), arterioles (A) and possibly a lymphatic (L) running within a connective tissue sheath. Hx-E. Magnification 140X

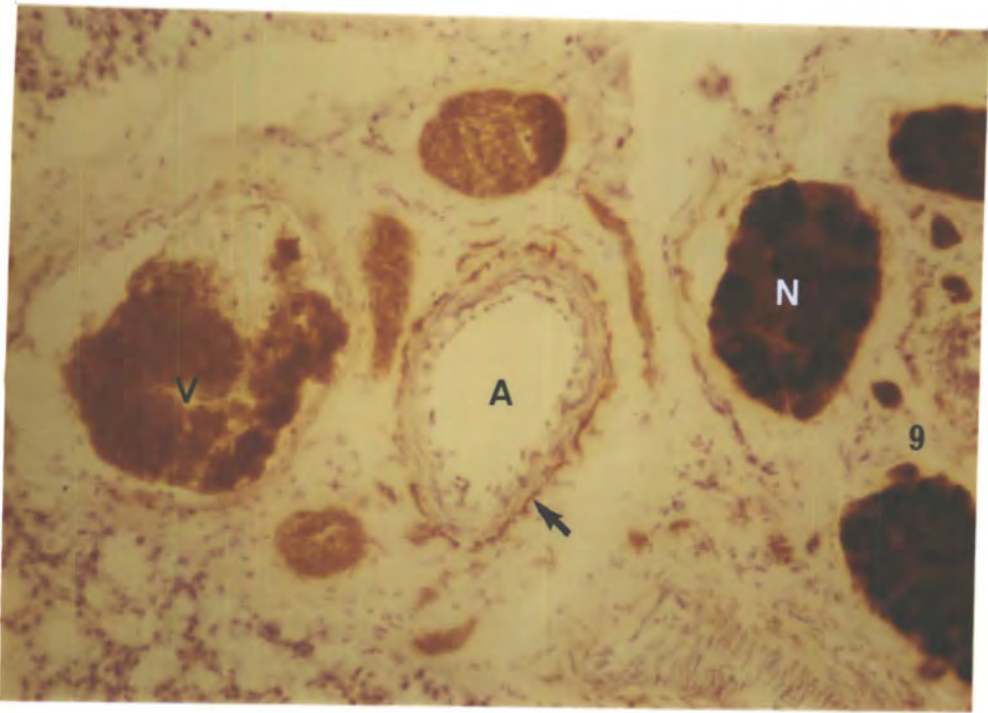


Plate 27 Junction of Rat Submandibular and Major Sublingual Glands. This plate shows an arteriole (A), surrounded by AChE-positive fibres (→), adjacent to a venule (V) and nerve trunks (N). AChE. Magnification 140X

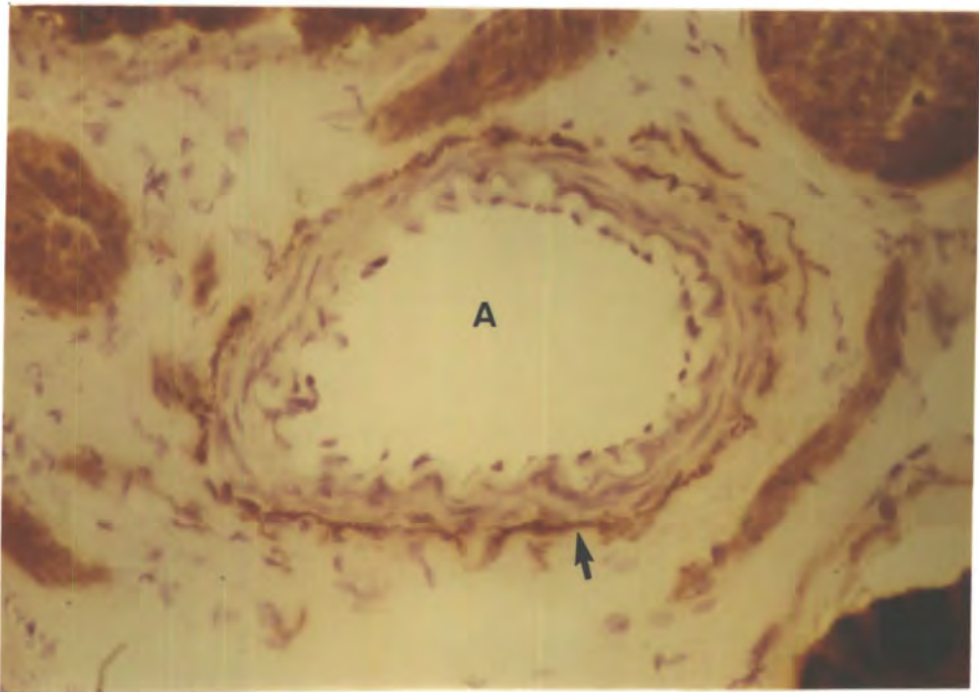


Plate 28 Junction of Rat Submandibular and Major Sublingual Glands. A higher magnification view of the large arteriole (A) on plate 27. Note the AChE-positive fibres (→). AChE. Magnification 275X

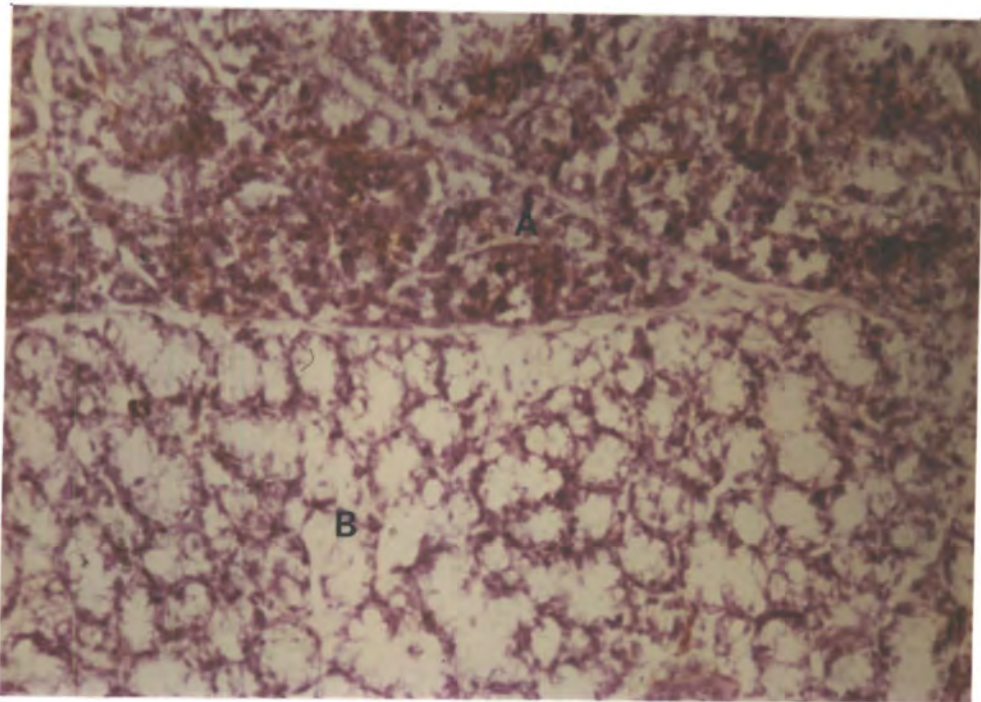


Plate 29 Junction between the rat submandibular (A) and major sublingual (B) glands. Note the greater density of AChE-positive fibres in the submandibular gland. AChE. Magnification 140X

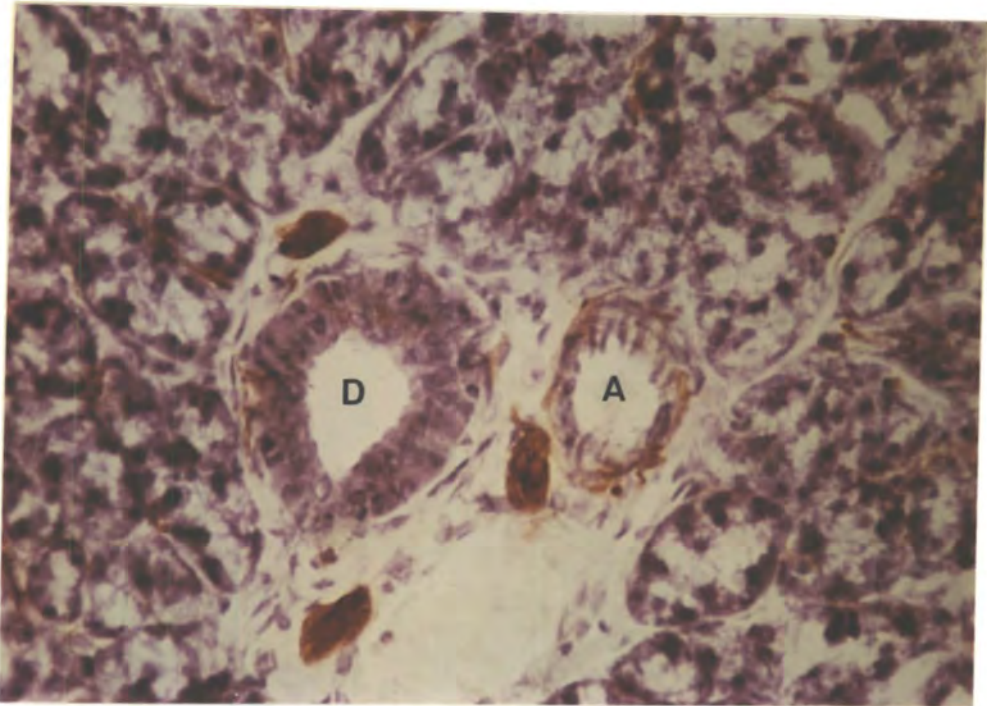


Plate 30 Rat Submandibular Gland. View of AChE-positive fibres surrounding an arteriole (A). Note the sparser innervation of the duct (D). AChE. Magnification 275X

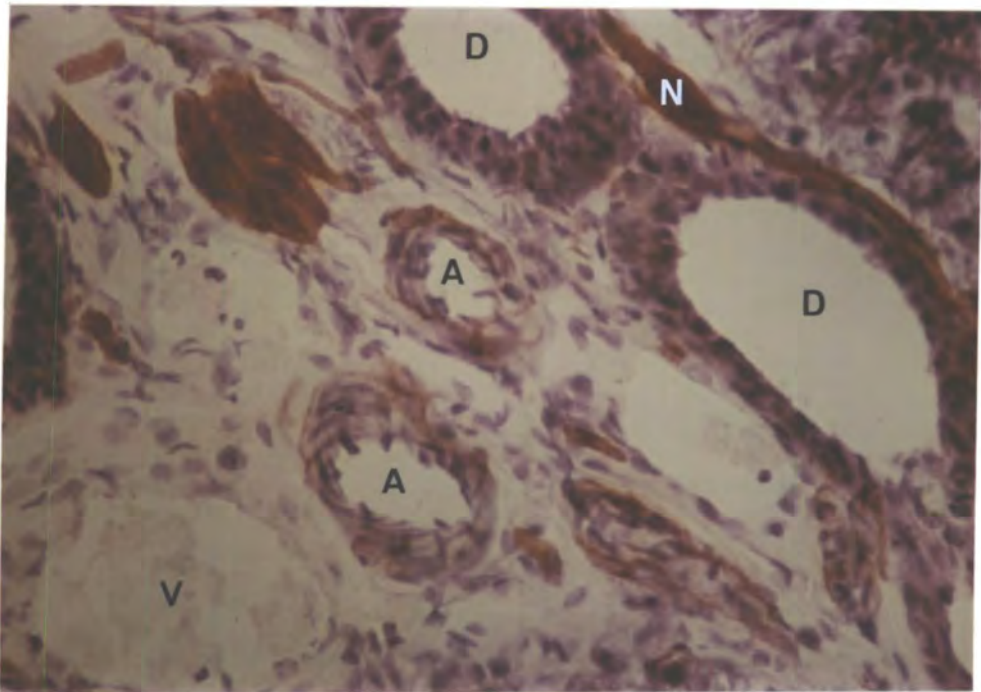


Plate 31 Rat Submandibular Gland. This plate shows AChE-positive fibres surrounding arterioles (A), and a nerve bundle (N) running adjacent to ducts (D). The venule (V) is devoid of fibres. AChE. Magnification 275X

Chapter 4

A HISTOLOGICAL STUDY OF ARTERIOLES IN HUMAN BREAST AND LACTATING RAT MAMMARY GLAND WITH SPECIAL REFERENCE TO INNERVATION.

1. The Use of Histochemical Techniques to Search for Periarteriolar Nerves in Human Breast Tissue.

Introduction

Examination in the electron microscope of 21 arterioles in breast material from 7 patients aged 34-63 years failed to reveal any surrounding autonomic fibres, indicating that flow was not mediated by nerves running along the vessel length (Jones & Kendall, 1981). The possibility remained, however, that autonomic fibres might influence the vessels at discrete sites, for example branch points, and so were not observed in those inevitably restricted regions examined by electron microscopy. Histochemical techniques to identify adrenergic and cholinergic nerves, coupled with light microscopy were therefore applied to the problem.

Methods

Biopsy specimens of breast tissue from cases 10 and 11 were rapidly frozen in liquid nitrogen and stored in a deep freeze below -30°C to await collection from Dryburn Hospital, Durham and the Royal Victoria Infirmary, Newcastle-upon-Tyne, respectively. On arrival at the University, having been transported in liquid nitrogen, the specimens were stored at -70°C until required.

The glyoxylic acid fluorescence procedure modified by König (1979) was used to identify adrenergic nerves. 20µm cryostat serial sections were collected on slides and processed as previously described (see page 85). Examination was under ultra-violet light in a Zeiss Ultraphot Photomicroscope and suitable vessels were selected for photography. In every experiment, the histochemical procedure was verified using an internal control from the rat submandibular salivary gland which possess a rich adrenergic innervation. Previous trials with reserpine to deplete biogenic amines ablated catecholamine fluorescence in this tissue.

To test for the presence of cholinergic fibres, the acetylcholinesterase procedure was employed (modified from El-Badawi & Schenk, 1967). 20µm cryostat sections were cut and processed as before (see page 91). The Nikon Optiphot Photomicroscope was used for examination and photography. An internal control from rat submandibular gland was again included in every experiment to verify the procedure. This tissue has been shown to possess a rich cholinergic innervation, the results being in agreement with those of other authors (for example Bogart, 1971).

Serial sections, adjacent to those examined for either GAF or AChE staining, were stained by the routine haematoxylin - eosin procedure previously described (see page 88).

Results

In both cases 10 and 11, the connective tissue of the breast showed a dull green autofluorescence when observed in the ultra-violet. This was especially prominent in case 11, a 39 year old woman with non-malignant fibroadenomatous hyperplasia. Arterioles

were readily identified by the presence of elastic fibres in the vessel walls, similar to those seen in the rat submandibular gland. No fluorescent adrenergic nerves were observed around arterioles in human breast (plates 32 & 33), the vessels bearing more resemblance to those seen in reserpinized rats (plate 24). Serial sections of 3 arterioles from case 10, covering lengths of 280 μ m, 360 μ m and 400 μ m respectively, failed to reveal any periarteriolar axons. In case 11, serial sections of 5 vessels, covering a total length of 10,280 μ m also gave negative results. Branch points were included in both studies. This work has been reported by Kendall & Jones (1982).

No AChE-positive fibres were observed in the breast tissue examined, which included both ducts and blood vessels (plates 34 & 35). Occasionally some positive staining was seen in red blood cells in the lumina of vessels.

The standard histochemical staining by haematoxylin and eosin confirmed the identification of vessels and ducts as shown in plate 36.

2. A Histochemical Study of Nerves in Lactating Rat Mammary Gland.

Introduction

The previous studies on human breast material have failed to reveal any perivascular nerves. It is possible that the autonomic nervous control of blood flow in the breast only appears when the gland is actively secreting. To investigate this possibility, histochemical techniques were applied to rat mammary gland tissue, removed at various stages of lactation.

Methods

6 female albino Wistar rats were sacrificed on days 1,3,21,23, 31 and 38 after the commencement of lactation. Those used on days 1 and 3 were in early lactation, and days 21 and 23 in late lactation, the litter having been weaned on day 21. The stimulus to lactation was therefore removed at this point and on this basis the rats taken on days 31 and 38 were assumed to be in post-lactation, although the time where lactation actually ceased was difficult to assess.

The subcutaneous mammary tissue was removed and quickly frozen in isopentane cooled over liquid nitrogen before being immersed in liquid nitrogen itself. For longer storage, the tissue was transferred to a deep freeze at -70°C .

20 μm cryostat sections were cut at -30°C and stained according to the glyoxylic acid fluorescence technique. The tissue was immersed in 1% glyoxylic acid solution (see page 85) for 45-60 seconds at room temperature, air dried for at least 5 minutes with cold air from a hairdryer, and placed in an oven at 80°C for 10 minutes. Following this, the sections were mounted in fluoromount before being placed on a hot plate at 70°C for 15 minutes. These time modifications of the technique gave optimal results for this tissue. The tissue was examined under ultra-violet light on the Zeiss Ultraphot Photomicroscope.

Further sections were cut and stained for acetylcholinesterase (see page 91) and routine staining by haematoxylin-eosin and haematoxylin-Van Gieson was also undertaken (see page 88).

Results

The tissue in each of the three stages of lactation has characteristic features illustrated by routine histological staining. Early lactation material demonstrated large lobules ensheathed by narrow connective tissue tracts, each lobule consisting of a number of dilated alveoli. Ducts and blood vessels in the stroma were easily identified by light microscopy. The ducts showed regularly arranged cells in the wall but appeared to be less complex in structure than those observed in the rat salivary gland or human breast. Rat mammary tissue is resorbed after lactation, and the relatively simple form of the ducts may be a reflection of the impermanency of a greater part of the tissue. Most of the arterioles were small, yet showed the characteristic thick muscular wall. Venules were very thin walled vessels.

Late lactation tissue showed smaller and more ordered lobules, the acinar cells being more compact and the alveoli less dilated. Milk production is highest on the 2nd day of lactation then falls off towards late lactation, therefore the smaller lobule size is probably associated with reduced milk storage requirements. Again the smaller vessels were more abundant, only an occasional larger vessel being observed.

By the post-lactation period, very few alveoli were to be seen and the acinar tissue was more dense and surrounded by a network of connective tissue. A greater number of large arterioles was observed, either because the tissue was more compact so more vessels would be seen in a given area, or because the tissue removed was not homogeneous but contained large vessels supplying other tissues. This latter suggestion could be the case, as resorption had already begun before the animals were killed, resulting in the gland having the appearance

of a flattened sheet, therefore being difficult to dissect out than glands taken during lactation itself. This difficulty may have led to other tissues being removed with the gland. It is improbable that vessels supplying the gland would be increasing in size and number whilst resorption was taking place.

The acinar tissue displayed a green autofluorescence when examined under ultra-violet light. The simple ductal structures were not easily seen but the arterioles could be identified by the muscular wall and the convoluted autofluorescent elastic lamina. Throughout the three stages of lactation studied, the same pattern of vessel innervation emerged, with the smaller vessels being highly innervated by a rich network of fluorescent adrenergic fibres (plates 37 & 38). The larger vessels, however, had a sparser innervation (plate 39) and many were completely devoid of fibres (plate 40). The parenchyma also lacked innervation (plates 37 & 38).

Staining by the acetylcholinesterase procedure failed to reveal any positive fibres, either around blood vessels or throughout the gland. Red-brown AChE-positive staining was observed, however, within the walls of some arterioles (plate 41) and also in other structures as yet unidentified (plate 42) but these are unlikely to be neural. When the inhibitor, ethopropazine, was omitted from the incubation medium, the connective tissue also stained positively, demonstrating sites of butyrylcholinesterase activity.

These results have been reported by Kendall and Jones (in press).

3. Discussion on the Control of Blood Flow through Mammary Tissue.

Physiological Changes in Blood Flow.

The prime function of the mammary gland is the production of milk required by the suckling young. All of the milk precursors must be obtained from the circulation, and to maintain an adequate supply of oxygen, glucose, fatty acids, amino acids and water there is a gradual increase in blood flow through the mammary gland during pregnancy and a marked increase at term. A dramatic rise in flow is seen in the cow udder at calving (Linzell, 1974), in the rat at parturition (Hanwell & Linzell, 1973a; Hanwell & Peaker, 1977) and also in the goat (Linzell, 1974) where mammary blood flow, oxygen consumption and glucose uptake all increase markedly 2-0.5 days pre-partum, reaching a maximum at 1-1.5 days post-partum (Davis, Fleet, Goode, Hamon, Maule Walker & Peaker, 1979). In the human, an increase in mammary blood flow, interstitial water and electrolytes is observed by the 4th week of gestation, corresponding to the increasing development of ducts and lobules within the gland. By term, the mammary blood flow is double that of the non-pregnant state and the subcutaneous veins are greatly dilated and prominent (Vorherr, 1978).

Neural Influences on Blood Flow.

The mechanisms involved in the regulation of blood flow appear to be complex. The search for vascular innervation in the human breast has shown an absence of both adrenergic and cholinergic nerves, therefore it seems that blood flow in non-lactating tissue is controlled by circulating

or locally-released factors and not by autonomic nerves. The need for major changes in blood flow through the non-lactating gland is obviously very small, the tissue being in a low metabolic state. The possibility that innervation develops in the human glands during pregnancy to meet the demands for changes in blood flow during lactation, still remains.

In contrast to the situation observed in non-lactating human breast, lactating rat mammary gland arterioles, especially the small resistance vessels, are highly innervated by fluorescent nerves. Unfortunately, non-lactating rat mammary gland cannot be obtained for a control as the gland only forms during pregnancy and is resorbed after lactation. An adrenergic sympathetic innervation of arterioles has also been reported in the mammary glands of the rabbit (Hebb & Linzell, 1970), dog, cat, goat, sheep and cow (see Linzell, 1974), suggesting that autonomic stimuli are important in the control of mammary blood flow in these species. The adrenergic nerve population is likely to influence the vasculature by triggering alpha-mediated vasoconstriction (Vorherr, 1971). No periarteriolar cholinergic nerves have been observed in both rat and human breast and this supports the generally accepted view, reported by Vorherr (1974), that no parasympathetic vasodilator fibres are present in the mammary tissue. He suggests that parasympathetic nerves are not necessary in the gland to mediate vasodilatation and myoepithelial contraction because these functions are performed by the stimulation of vascular beta adrenoceptors and the effects of oxytocin, respectively. Vascular beta adrenoceptors have not, however, been identified.

In accordance with the work of other authors (Hebb & Linzell, 1970; Vorherr, 1974; Weiss & Greep; 1977; Cowie, Forsyth & Hart, 1980) no nerves were observed innervating the myoepithelial cells of the epithelium. This implies that the secretory activities of the

epithelium are probably independent of nervous control and that beta adrenoceptors identified on the myoepithelial cells (Bisset, Clark & Lewis, 1967; Vorherr, 1971, 1974) are triggered by circulating hormones rather than neurotransmitter released at the myoepithelium.

Other Factors Influencing Blood Flow

Changes in blood flow can occur, induced not only by stimulation of autonomic nerves, but also by circulating vasoactive agents. These are likely to be very important in tissues where innervation is sparse or absent, as in human breast.

Catecholamines

Early perfusion experiments by Hebb and Linzell (1951) in the mammary glands of the dog, cat and goat have shown a high sensitivity of the blood vessels to adrenaline, leading to vasoconstriction. This has also been demonstrated in the lactating rat and guinea-pig by Bisset et al (1967) whilst studying the catecholamine inhibition of the milk-ejection response to oxytocin. Emotional stress, fear and pain can lead to impaired nursing or the complete suppression of milk-ejection. Injection of oxytocin corrects this problem whereas the response to the exogenous addition of adrenaline mimics the inhibition. Vorherr (1971) studied the effects of various sympathomimetic agents on the oxytocin-induced response in rats and, with the use of alpha and beta blockers, came to the conclusion that the sites of action of the catecholamines were myoepithelial beta adrenoceptors (mediating myoepithelial relaxation) and vascular alpha adrenoceptors (mediating vasoconstriction). Catecholamine inhibition of oxytocin-induced milk ejection is also seen in women, therefore vascular alpha adrenoceptors appear to be present in

human mammary vessels too (Vorherr, 1978).

Differential activation of inner and outer smooth muscle cells has been reported by Kalsner (1972) who found that noradrenaline perfused through the lumen of the rabbit ear artery produced more contraction than noradrenaline applied to the outside of the vessel, even in the presence of cocaine which reduces the uptake of noradrenaline by nerves. This indicates that the inner muscle layer is more sensitive to constrictor agents than the outer layers. Keatinge and Harman (1980) note that most of a vessel's response to circulating vasoactive agents comes by contraction of the inner muscle layer. The outer muscle is too insensitive to the low concentrations of circulating constrictor agents and can only contract when noradrenaline is released from adrenergic endings when a high local concentration is generated. Vasodilator agents, on the other hand, seem to have an equal effect on both inner and outer muscle layers.

Other Vasoconstrictors

Oxytocin and the diuretic hormone, vasopressin, in large doses both cause vasoconstriction in perfused cow's udders (Petersen, 1942) and in conscious goats (Hardwick & Linzell, 1960; Peaker & Linzell, 1973) but such high levels are unlikely to be present in normal physiological conditions. Serotonin (5-hydroxytryptamine) is another powerful mammary vasoconstrictor (Linzell, 1974). It is released from platelets on contact with foreign materials and causes a contraction of the vessel walls, reducing the blood flow, this effect being enhanced by the aggregation of the platelets themselves within the small vessels. It is not known whether these effects are physiologically significant. Prostaglandins released from the mammary gland may also serve as vasoconstrictors.

Acetylcholine

Dense AChE positive staining has been observed in the arteriolar walls of the rat mammary gland, in contrast to arterioles studied in the human breast where staining was absent, and the rat salivary gland where staining was confined to fibres in the adventitia. This demonstrated that arterioles in different tissues and species are biochemically distinct and this may in turn reflect differing control mechanisms of blood flow through the vessels. The tunica media of the aorta and the pulmonary trunk of rats and rabbits have been shown to contain large amounts of diffusely distributed butyrylcholinesterases (BuChE), contrasting with the coronary arteries from the same animals where no BuChE activity is demonstrated in the wall and AChE is restricted to nerve fibres accompanying the vessel (Navaratnam & Palkama, 1965). A difference in vascular cholinesterase distribution is also seen in the rat brain, where most of the vessels demonstrate BuChE in their walls, some capillaries having both BuChE and AChE. Vessels in structures outside the blood/brain barrier are completely devoid of ChE activity (Flumerfelt, Lewis & Gwyn, 1973). Small pial and parenchymal vessels in other species have demonstrated heavy AChE staining (Hardebo, Edvinsson, Falck, Lindvall, Owman, Rosengren & Svengaard, 1976; Tagawa, Ando & Wasano, 1979; Tagawa, Ando, Wasano & Iijima, 1979; Wasano & Iijima, 1979). Such a high level of AChE activity in the vessel wall suggests it is a site of major ACh breakdown and seeing as ACh has been shown to cause mammary vasodilatation in dogs and cats (Linzell, 1950) it is probable that ACh has a physiological action on these vessels. Circulating ACh is rapidly broken down therefore this vasodilator must be released locally, perhaps from the vessel itself, the wall acting as both a source and a sink.

Vascular smooth muscle responds to ACh by relaxation whereas smooth muscle from other sources responds by contraction. This apparent paradox may be explained by the work of Furchgott and Zawadzki (1980). They showed that application of ACh to isolated preparations of rabbit thoracic aorta and to other blood vessels, produced relaxation only when the endothelium was intact. If the endothelium was damaged either by rubbing or by collagenase treatment, no ACh-induced vasodilatation was observed, but a concentration-dependant contraction of the muscle did occur. The authors therefore suggested that ACh acts on atropine-sensitive muscarinic receptors of the endothelial cells, stimulating release of a substance which causes relaxation of the vascular smooth muscle. This may be one of the principal mechanisms of ACh-induced vasodilatation in vivo. Later work indicated that the substance in question could possibly be a labile hydroperoxide or free radical which activates guanylate cyclase in the smooth muscle (Furchgott, 1981; Furchgott & Zawadzki, 1981).

Histamine

It has been shown in human and rabbit breast that oestrogenic substances can stimulate histamine release (Zeppa, 1969). Oestrogen and oestradiol-17beta increase throughout pregnancy reaching a peak at parturition (Davis et al, 1979; Cowie et al, 1980), and this may be sufficient to induce release of the amine. Histamine causes vasodilatation in the mammary glands of dogs and cats (Linzell, 1950) and could therefore be involved in the increasing mammary blood flow in pregnancy.

Bradykinin

Bradykinin has been shown to cause vasodilatation in goat mammary glands in vivo but vasoconstriction in vitro (Linzell, Fleet, Mepham & Peaker, 1972; Linzell, 1974). This appears to be similar to the results obtained from the work of Furchgott and Zawadzki (1980) on vascular responses to ACh. These authors have also shown that bradykinin requires an intact epithelium to produce the dilatory response.

Prostaglandins

Prostaglandins are derived from fatty acids and so it is not surprising that mammary glands which synthesize high quantities of fatty acids should also produce prostaglandins. The presence of PGF_{2alpha} has been demonstrated and its levels shown to rise markedly at parturition (Davis et al, 1979; Cowie et al, 1980). PGF_{2alpha} is a vasoactive agent capable of producing both vasodilator and vasoconstrictor responses in the same animal (Hillier & Karim, 1968; Shehadeh, Price & Jacobson, 1969; Robinson, Collier, Karim & Somers, 1973; Taira, Narimatsu & Satoh, 1975; Reilly & McCuskey, 1977a, 1977b; Shimizu & Taira, 1978). It may be a possible vasodilator in the mammary gland at parturition.

Other Hormones

During pregnancy and at parturition there is a continuing change in the hormone profile of the circulating mammary blood. Further to those substances previously mentioned, serum progesterone rises during pregnancy but falls rapidly at parturition (Davis et al, 1979; Cowie et al, 1980) as does the human placental lactogen, (Cowie et al, 1980). Adrenal corticoids continue to increase from

late pregnancy through parturition (Cowie et al, 1980). Oxytocin, the hormone concerned with milk ejection, rises rapidly at parturition and on suckling (Vorherr, 1978; Cowie et al, 1980). None of these hormones have demonstrated any vasodilator properties. Oxytocin, however, is known to increase peripheral levels of VIP, released from the gut (Bitar, Said, Weir, Saffouri & Makhlouf, 1980) and this peptide is a known vasodilator (for example, Larsen, Boeck & Ottesen, 1981; Ottesen & Fahrenkrug, 1981).

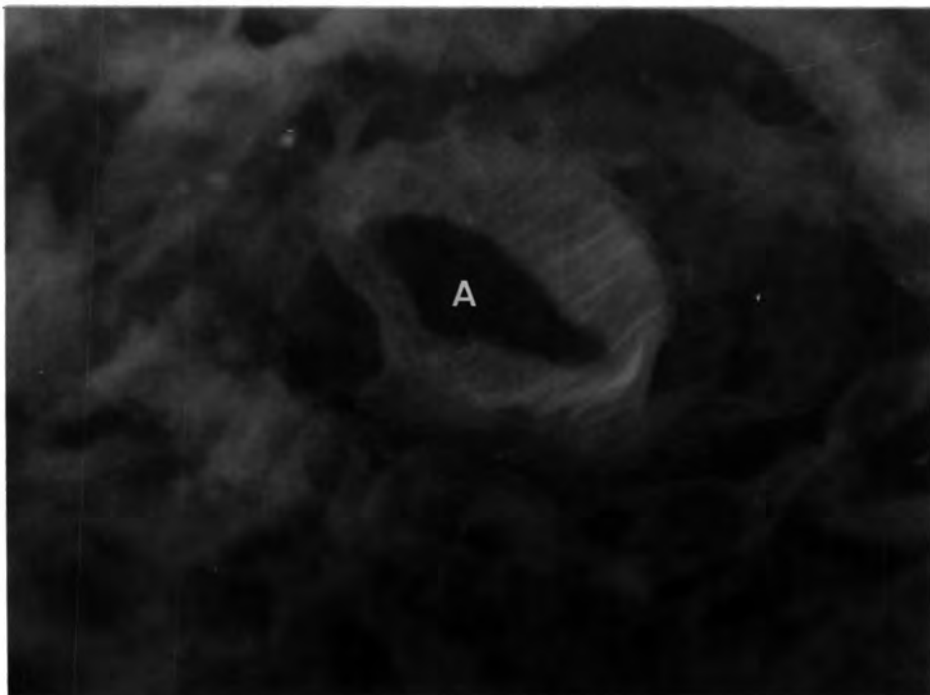
Prolactin

The hormone, prolactin, that stimulates milk secretion, also increases in concentration in the blood throughout pregnancy, reaching a peak just after parturition (Davis et al, 1979; Cowie et al, 1980). During lactation, its level is slightly lower but increases on suckling (Vorherr, 1978). Hanwell and Linzell (1973b) removed the young from lactating rats, resulting in the glands filling with milk and the mammary blood flow falling. The latter was a reflection of both a fall in cardiac output and a fall in the proportion of the cardiac output distributed to the mammary glands. If the young were allowed to continue suckling but the teat ducts were blocked, milk collected in the gland but the blood flow remained unchanged. The flow was the same after suckling in the empty gland and in the full gland where the ducts were sealed. This indicates that the flow of blood through the gland in the short-term is not restricted by the accumulation of milk and that blood flow and milk secretion are dependant on a suckling stimulus.

On suckling, the cardiac output and the prolactin levels both increase. The relationship of the two has been further investigated in virgin rats where administration of prolactin or growth hormone

increased the cardiac output (Hanwell & Linzell, 1972). Hanwell and Linzell (1973a) also measured the cardiac output in lactating rats and showed that between days 1-5 of lactation there were sharp rises in the cardiac output and in blood flow to most organs, including the mammary gland. From days 5-15 the cardiac output remained steady, but blood flow was proportionately increased in the tissues involved in lactation, both directly (mammary gland) and indirectly (liver and gastrointestinal tract), and away from other organs. A further rise in cardiac output and blood flow to most organs occurred between days 15-22. This increase in cardiac output at parturition may be the major factor increasing blood flow to the mammary gland of the rat at the beginning of lactation. This may also hold true for other species.

A clear picture of the mechanisms involved in blood flow control in the mammary gland is not yet available. The rate of mammary blood flow is closely related to the rate of milk secretion. It would seem likely that in normal physiological conditions the active gland produces metabolites which act as local vasodilators. Hanwell & Peaker (1977) suggest that a positive feedback system is in operation whereby an increase in blood flow increases the supply of fluid and substrates to the gland, so more milk is produced and more vasodilator metabolites released to further increase blood flow. The system could be limited by the milk producing capacity of the secretory cells. Vasoconstriction is likely to be brought about by the action of sympathetic neurotransmitter in adrenergically innervated tissues, and by circulating and locally-released factors.



Plates 32 and 33 Human Breast Case 11. These plates show arterioles (A) within fibrous tissue. Note the absence of fluorescent nerve fibres. GAF. Magnification 275X

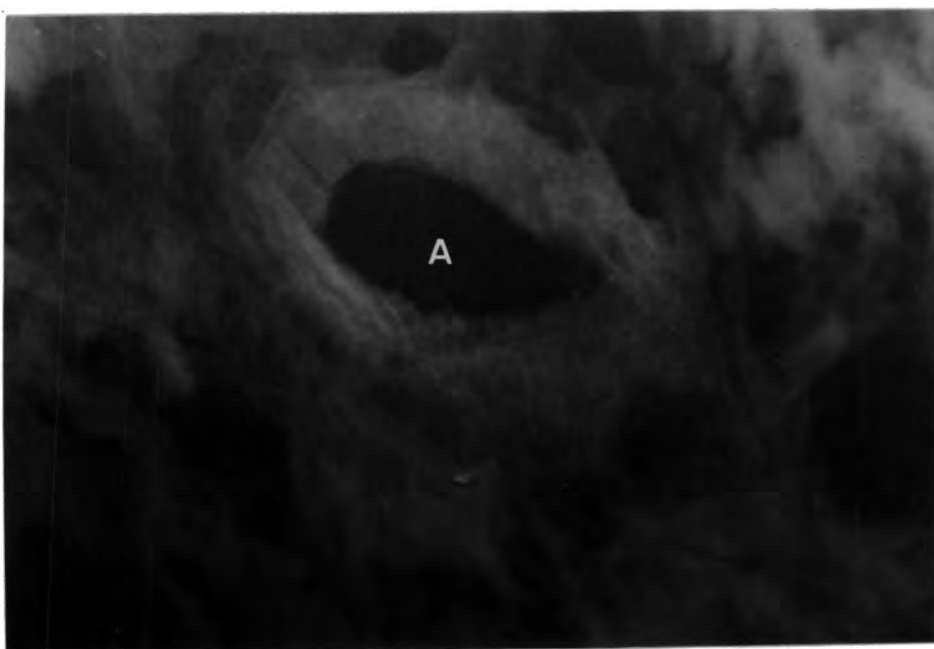




Plate 34 Human Breast Case 11. The ducts (D) and fibrous tissue shown on this plate are not supplied by AChE-positive fibres. AChE. Magnification 140X

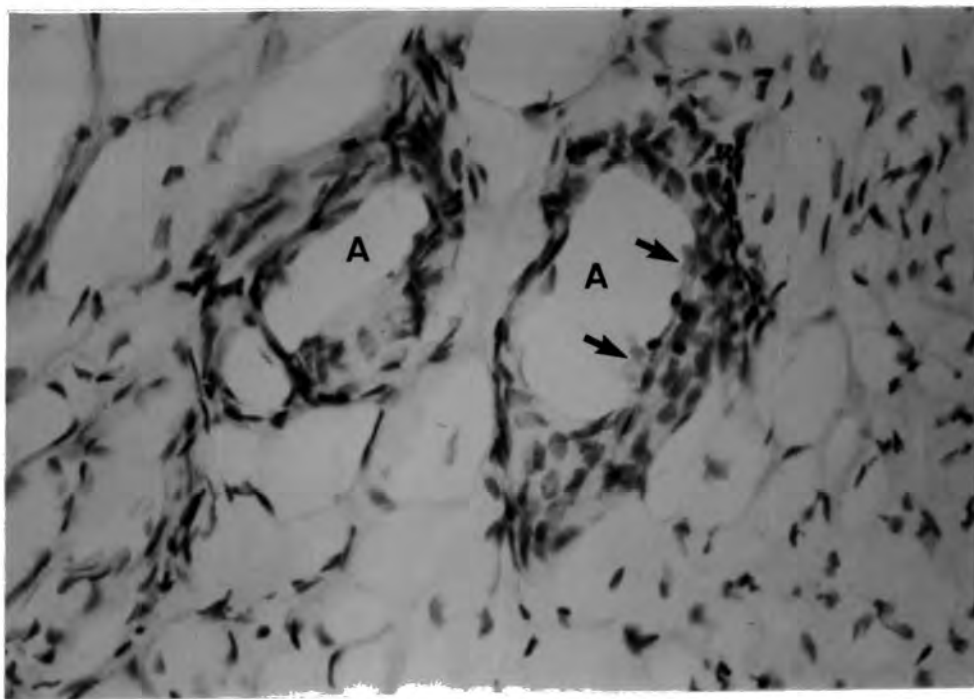


Plate 35 Human Breast Case 11. AChE-positive staining is shown in red blood cells (↑) within the arteriole (A) but no positive fibres are seen in the adventitia. AChE. Magnification 275X

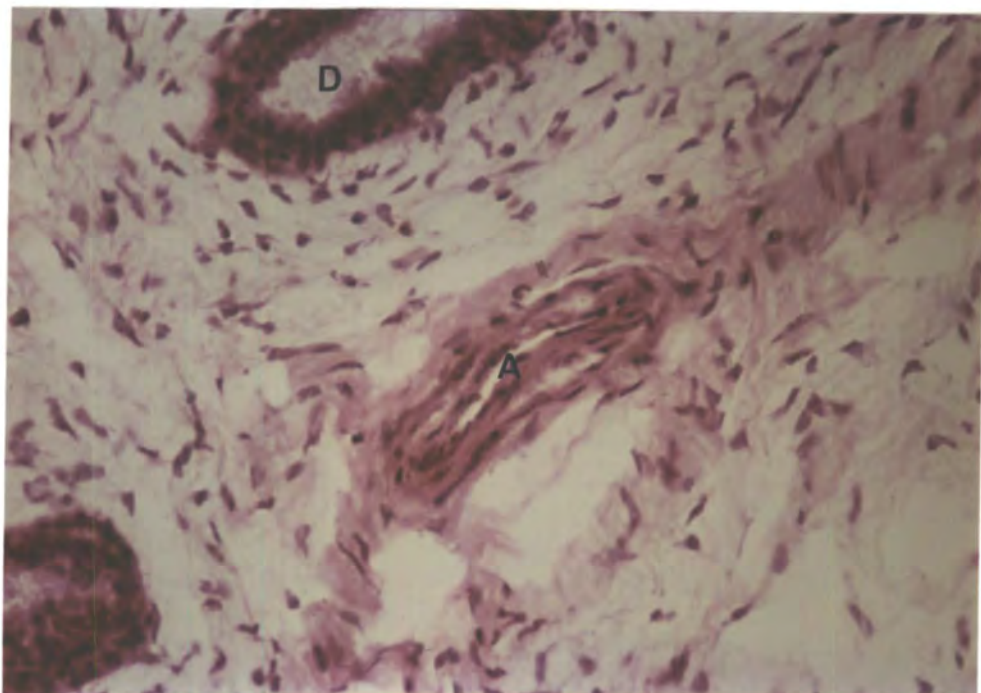


Plate 36 Human Breast Case 11. Characteristic staining of an arteriole (A) and duct (D). Hx-E. Magnification 275X

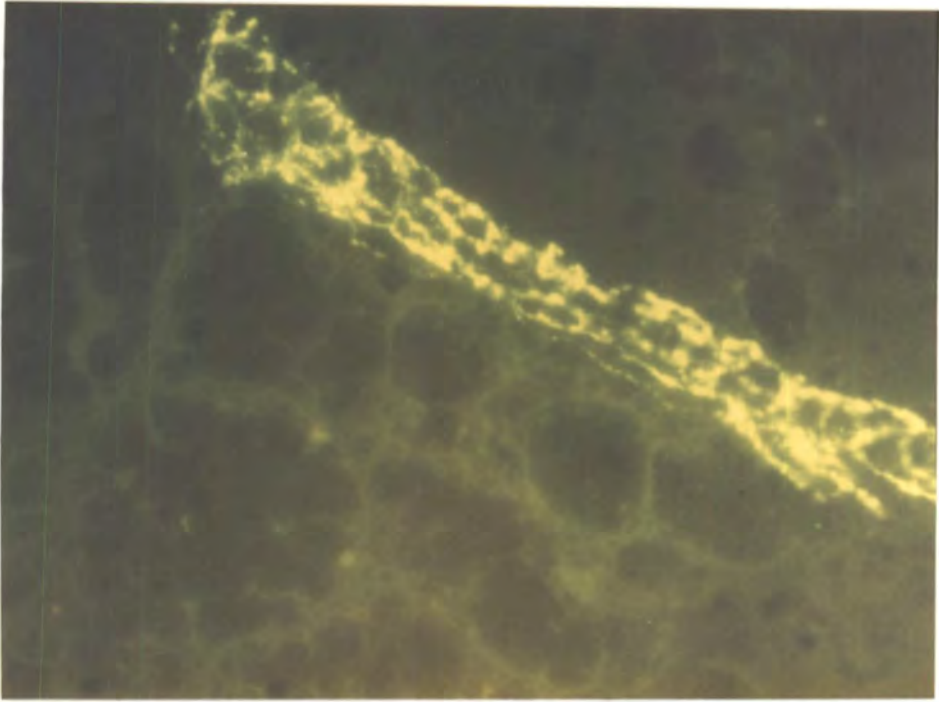


Plate 37 Rat Mammary Gland. This shows a longitudinal section through a blood vessel surrounded by a network of adrenergic fibres. Note the absence of fibres from the parenchyma. GAF. Magnification 275X

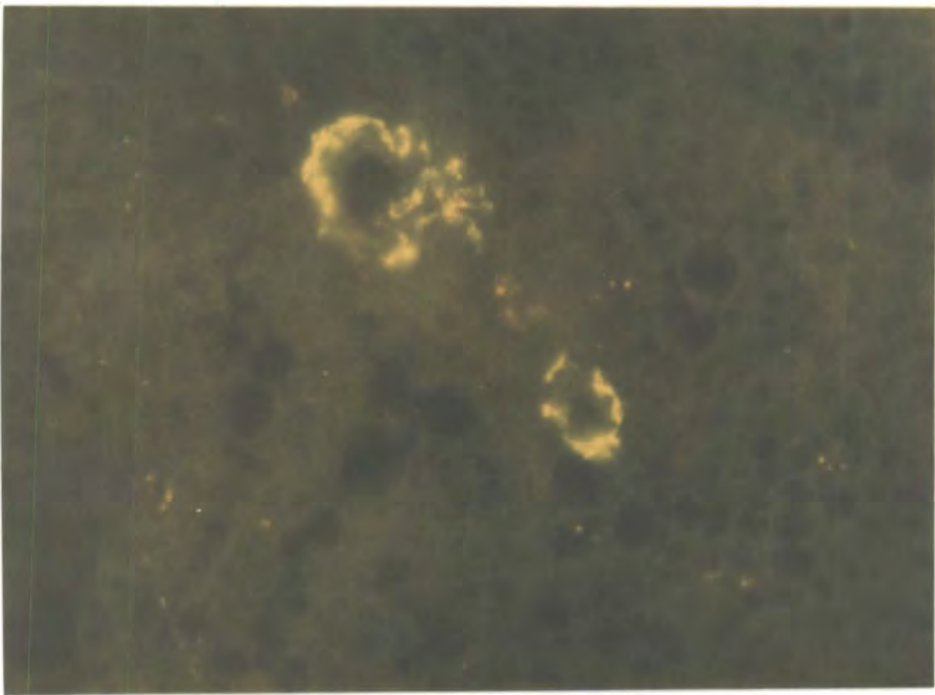


Plate 38 Rat Mammary Gland. Two small adrenergically innervated arterioles are shown on this plate. No fibres are present in the parenchyma. GAF. Magnification 275X

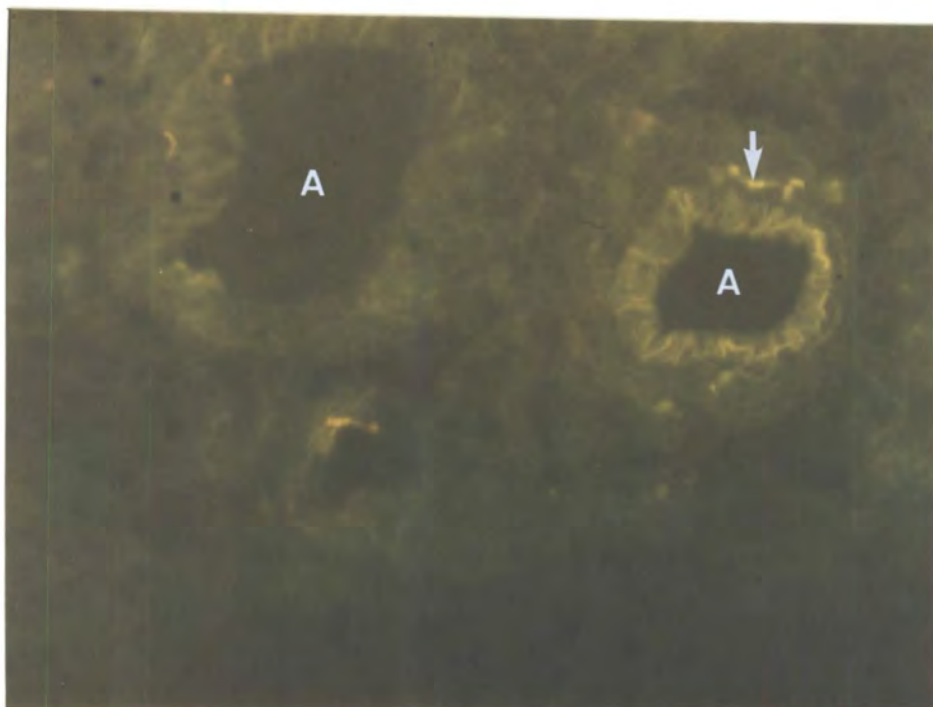


Plate 39 Rat Mammary Gland. The smaller of the two arterioles (A) shown on this plate demonstrates a more pronounced innervation by fluorescent fibres (↓) than the larger. GAF. Magnification 275X

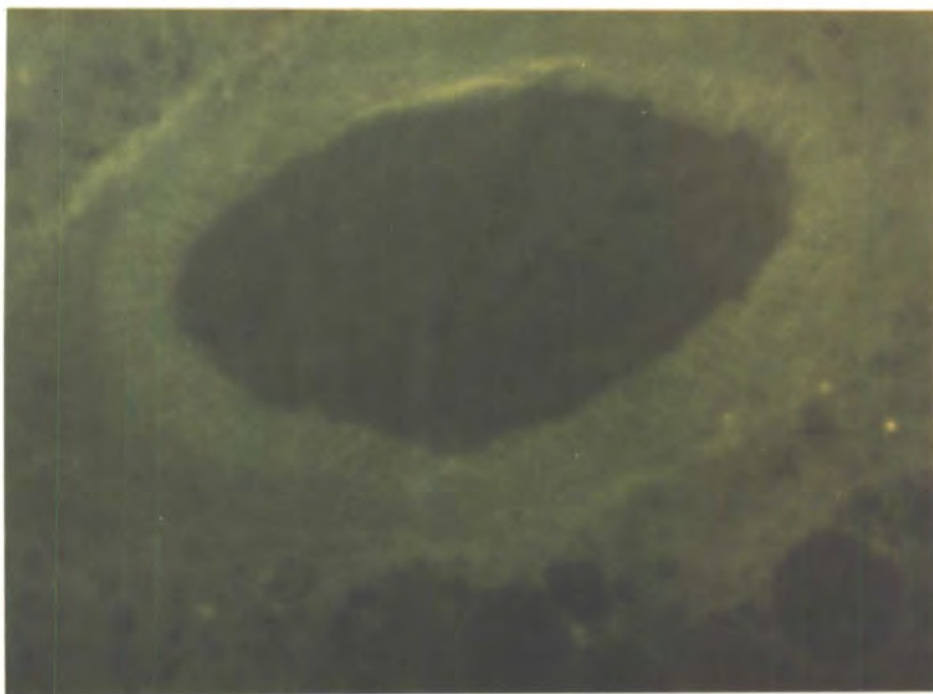


Plate 40 Rat Mammary Gland. No fluorescent nerve fibres are present around this large arteriole. GAF. Magnification 275X

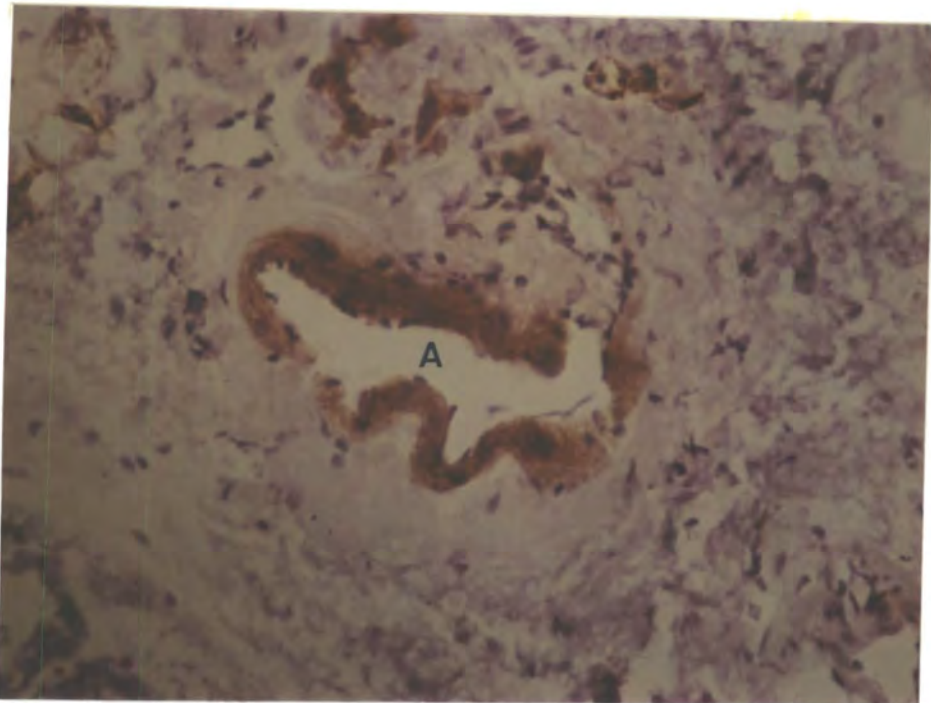


Plate 41 Rat Mammary Gland. This plate shows AChE-positive staining within the wall of an arteriole (A). AChE. Magnification 275X

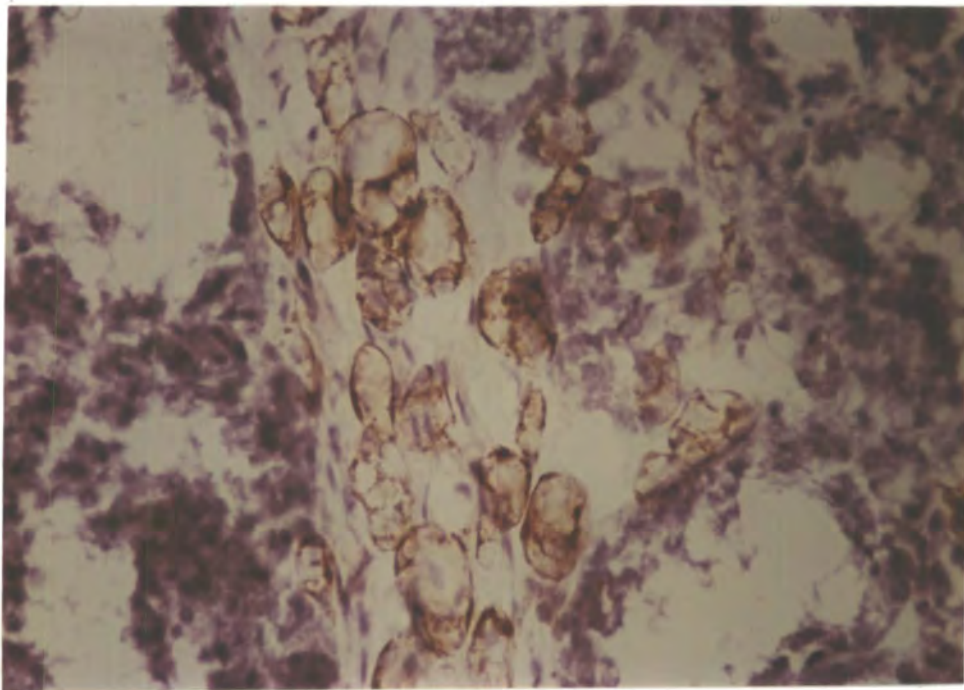


Plate 42 Rat Mammary Gland. View of unidentified AChE-positive structures. AChE. Magnification 275X

Chapter 5

AN ULTRASTRUCTURAL STUDY OF PERIARTERIOLEAR NERVES IN THE HUMAN AXILLARY LYMPH NODE.

Introduction

The lymphatic vessels of the mammary gland empty mainly into the axillary lymph nodes and the parasternal nodes. About 75% of the breast lymph drains into the axillary nodes which act as a filter to trap particulate matter, bacteria and other micro-organisms. Clusters of cancer cells can be spread from an affected site by the lymph vessels and often in cases of breast cancer the axillary lymph nodes become enlarged and infected as a result of filtering out malignant cells from the lymph. These nodes are therefore often removed in mastectomy to enhance the possibility of ridding the body of potential infected areas. The protective action of the lymph nodes is continual, in comparison to the activity of the breast, therefore a study of the innervation of the vasculature was undertaken to ascertain whether any differences in blood flow control might exist between the axillary lymph nodes and the breast tissue in which they are embedded.

Method

In two of the patients from whom breast material was examined, namely cases 9 and 14, axillary lymph nodes were also removed. Case 9 lymph node material was processed according to the schedule described for case 9 breast tissue (see page 64). Case

14 lymph node was similarly processed but included a shorter fixation time of 2 hours and polymerization of the araldite at 45°C for 7 hours and 60°C for 48 hours prior to sectioning.

Semi-thin sections were stained with toluidine blue and the tissue examined in the light microscope. Suitable arterioles were blocked down for further analysis, thin sections cut and stained (uranyl acetate - 10 minutes, lead citrate - 10 minutes), and then examined in the Philips 400 electron microscope.

Results

Sections stained with toluidine blue demonstrated the thick capsule wall of the lymph node, consisting mainly of dense collagen-rich connective tissue, but also possessing some muscle fibres (plate 43). Large fat droplets surrounded the capsule (plate 43). The cortex of the node was packed with white blood cells of typical, though heterogeneous, morphology (plates 43 and 44). Some atypical cells, however, were seen (plate 44) which were different in size and shape from the white cells and also showed nuclear differences. These cells were possibly malignant. Characteristic arterioles were also observed, having an internal elastic lamina and a thick muscular wall (plate 45). Lymphocytes were often seen passing through the walls of these vessels and across the capillary endothelium.

7 arterioles from 2 patients were examined in the electron microscope and typical features of the endothelium, smooth muscle and adventitia were noted, as previously described (Jones & Kendall, 1980).

Scanning the adventitia revealed fibroblasts, collagen and neuronal structures, the latter consisting of a Schwann cell

enclosing a number of axons. The axon profiles bound together in this way were not always similar, for example a myelinated nerve has been observed running in the same Schwann cell as unmyelinated nerves (plate 46). At places, the Schwann cell investment was removed, exposing the nerve to the adventitia and thus forming potential neuroeffector sites. Generally, the exposed areas of the axon were adjacent to the vascular smooth muscle, but possible neuroeffector sites have been seen where the axon surface is exposed to a fibroblast or to a white blood cell close to the arteriole (plate 46). This could indicate an action of the released neurotransmitter on receptors situated on cells other than smooth muscle. The axon profiles seen in effector positions possess both large and small dense-cored vesicles. Measurements to the nearest 10nm of these vesicle populations showed that they are within the size range of those described by Burnstock (1975) for typical adrenergic axon profiles. The large vesicles were found to have mean dimensions of 59.5nm X 82.9 nm with standard errors of 2.1 and 4.7nm respectively (sample size = 21). The small vesicles were also elliptical having dimensions of 33.3 ± 0.6 nm X 44.2 ± 0.7 nm (sample size = 116). Not all the small vesicles were densely stained and in many only residual staining was observed, but the presence of such staining suggests that these axons were adrenergic and that some leaching of the osmiophilic neurotransmitter may have taken place. Leaching is known to occur with long fixation times, therefore in an attempt to combat this loss of transmitter, a shorter fixation time was employed in case 14, but this did not solve the problem. The potassium permanganate fixation technique has been shown to produce excellent maintenance of the amine precipitate on the vesicles (see "Hokfelt, 1967; Ochi, Konishi, Yoshikawa & Sano, 1968; Kyosola, Partanen, Korkala, Merikallio, Penttilä & Siltanen, 1976; Itakura et al, 1977; Kanerva, Hervonen & Grönblad, 1980) and this method should be applied to the present problem to aid nerve identification.

A Note on Lymph Node Structure and Function.

A lymph node consists of three main regions; the capsule, the cortex and the medulla. The capsule wall is formed mostly from dense collagen with a few fibroblasts, elastic fibres and some muscle cells. Trabeculae, continuous with the capsule wall, project into the node itself. A fine reticulum is present throughout the node in the form of a fibrous and cellular meshwork which supports free cells, blood vessels and lymphatic sinuses. Lymphocytes are the most conspicuous cells and at the periphery of the node they are tightly packed together to form the cortex. Within the cortex and reaching to the hilus is the medulla where the cells are grouped together into medullary cords. These regions are not clearly defined structures and there is free movement of cells between them. In the cortex are ovoid follicles which are classed as either primary, consisting of a uniform population of B lymphocytes, or secondary where there is a germinal centre. In the latter, B cell differentiation takes place along with high antibody production. T cells, mainly present in the cortex, are also found in germinal centres in addition to macrophages. Medullary cords are rich in plasma cells, macrophages and lymphocytes (Davies & Davies, 1964; Abramoff & La Via, 1970; Nossal & Ada, 1971; Weiss & Greep, 1977).

The arterioles enter the node at the hilus then pass via the trabeculae to the cortex where they break into a rich capillary plexus. These then group into postcapillary venules, prominent especially within the cortex, and finally into larger venules in the medulla, the vessels then leaving the capsule at their site of entry, the hilus (Davies & Davies, 1964; Weiss & Greep, 1977). Unmyelinated nerves have been reported to enter the node at the hilus and run with

the blood vessels (Weiss & Greep, 1977). The present results confirm that autonomic nerves accompany arterioles in the human axillary lymph nodes and suggests that this innervation is adrenergic (Kendall & Jones, in press) though the possibility remains that other nerve types are also present.

The lymph filtration mechanism together with the trapping of antigen is well developed in the lymph node. In addition, the node is also a site of intense cell division and differentiation stimulated by antigens. The lymph reaches the node by the afferent lymphatic which branches into many lymph vessels distributed throughout the node and opening into the medullary sinuses. Most of the lymph flow passes through these sinuses, though some enters the subcapsular lymph space, passes through the permeable node wall and percolates through the cortex, passing over the tightly packed lymphocytes before reaching the medulla. The lymph leaves the node via an efferent lymphatic (Abramoff & La Via, 1970; Nossal & Ada, 1971).

Retained antigen is usually held by the medullary macrophages and the follicles in the cortex. Upon antigenic stimulation there is a proliferation of plasma cells and large lymphocytes in the medullary cords and an increase in mast cell content of the medullary sinuses (Nossal & Ada, 1971). The increased plasma cell formation is initiated in the follicles from which the plasma cells migrate to the medulla. Increased B cell differentiation and antibody formation also occurs within the follicle (Weiss & Greep, 1977).

The lymph node is therefore a highly active tissue with a continual metabolic demand, which is especially high when the body is fighting disease and much cell division and antibody production is occurring. There is therefore a need for a continual control of

blood with the possibility of mediating sudden changes in flow if necessary when the tissue has a high metabolic demand. This would account for the presence of an autonomic innervation of the vasculature of the node compared to the apparent lack of such an innervation in the human breast which has a low metabolic demand except during lactation.

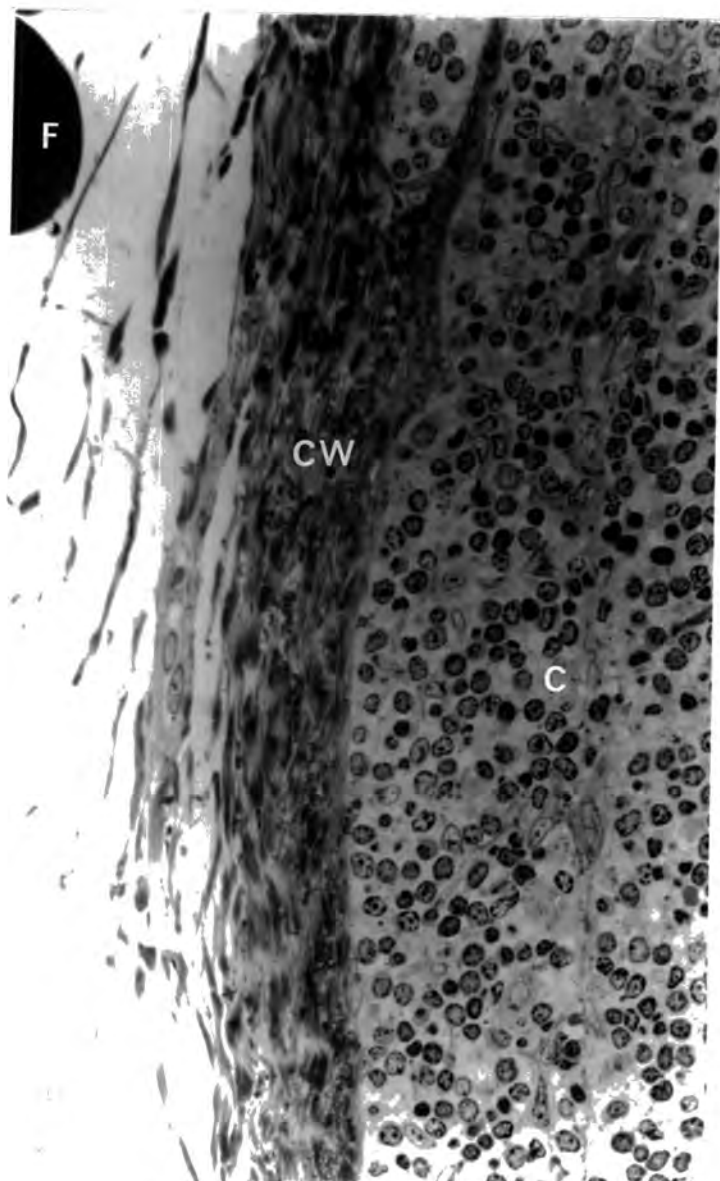


Plate 43 Human Axillary Lymph Node Case 9. This shows the capsule wall (CW) with a fat droplet (F) exterior to the node. Note the heterogeneous population of white blood cells in the cortex (C). Toluidine Blue. Magnification 450X

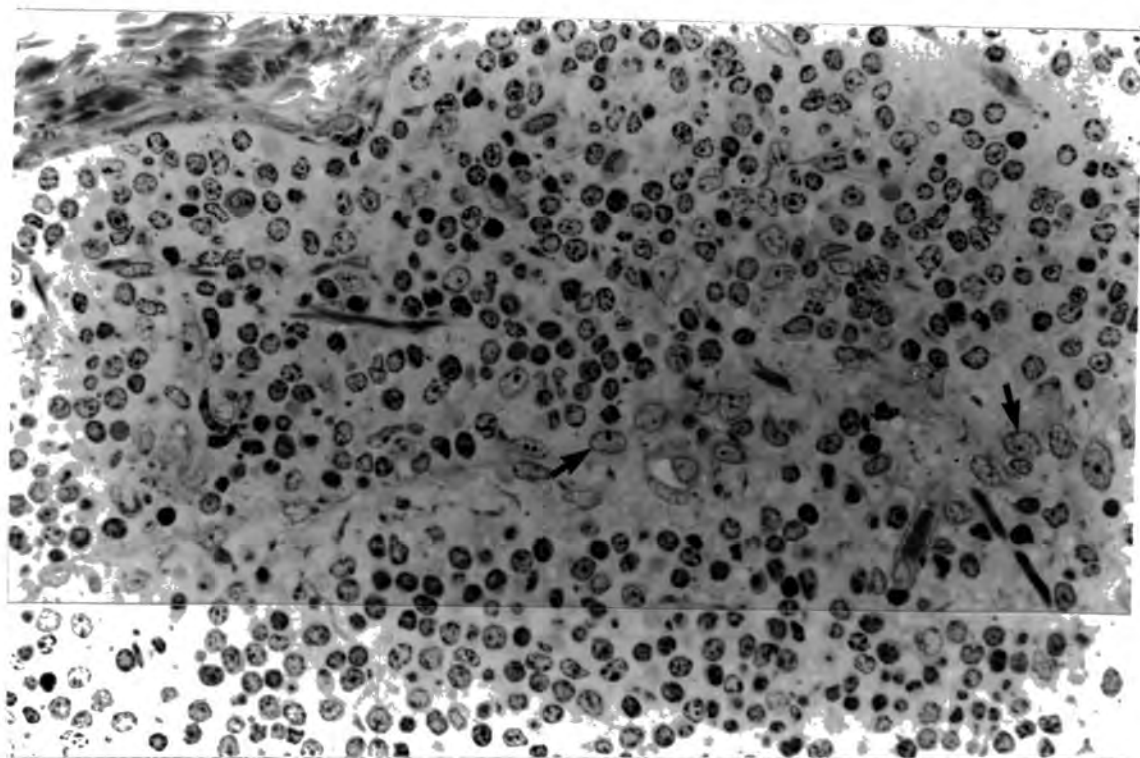


Plate 44 Human Axillary Lymph Node Case 9. View of possible malignant cells (↖) within the stroma of the node. Toluidine Blue. Magnification 450X

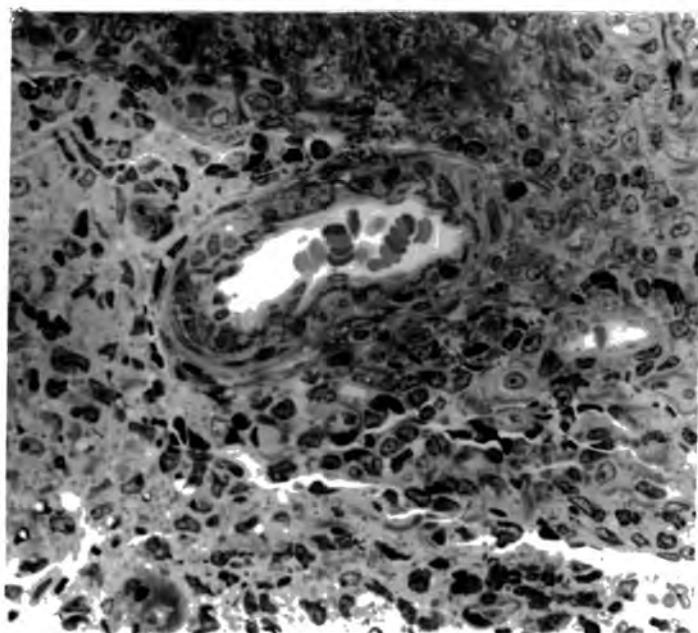


Plate 45 Human Axillary Lymph Node Case 9. A characteristic arteriole within the lymph node stroma. Toluidine Blue. Magnification 450X

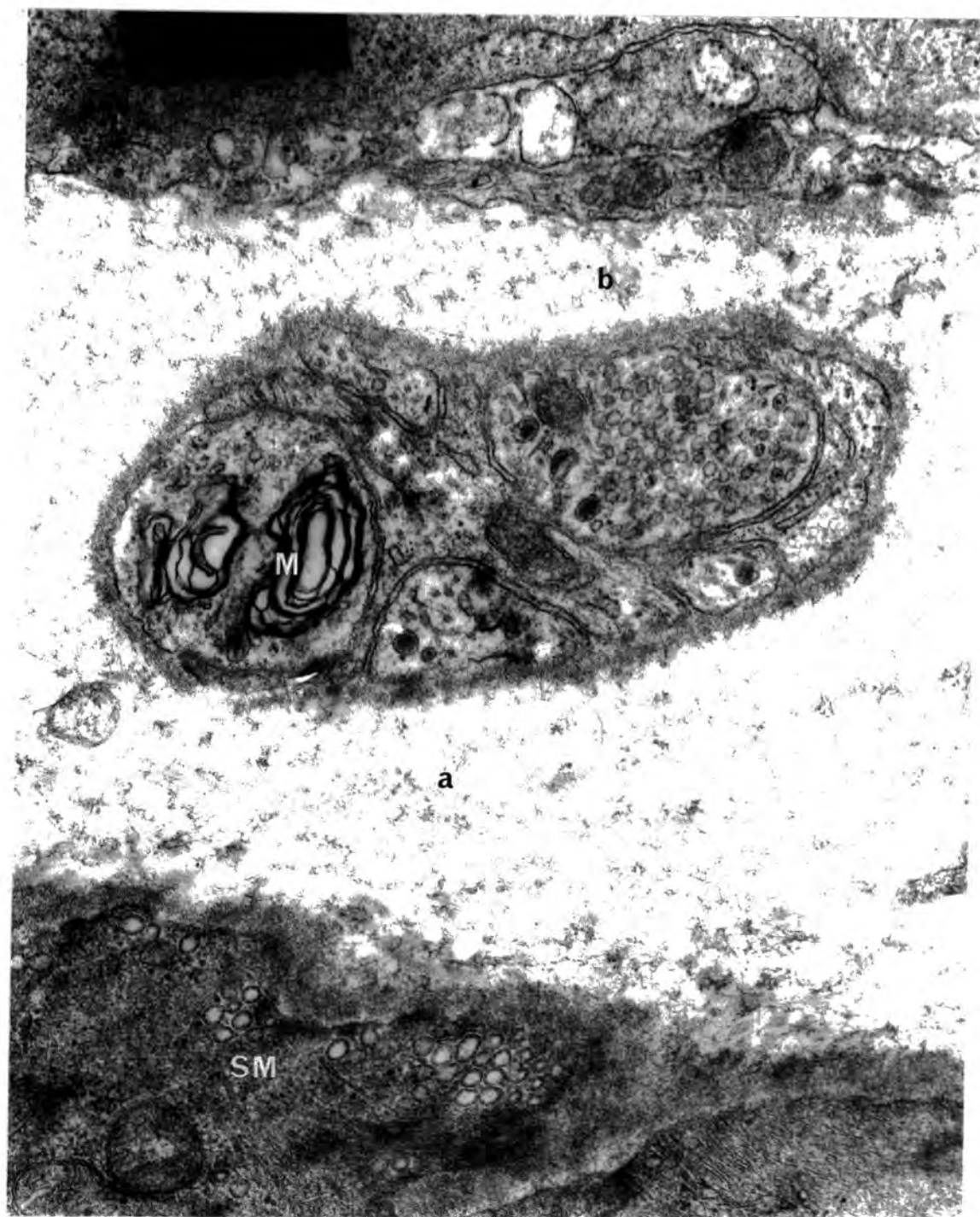

Plate 46 Human Axillary Lymph Node Case 9. View of periarteriolar axon profiles showing large granular vesicles and residual stain in the smaller vesicles. A myelin figure (M) is also enclosed within the Schwann cell investment. This investment is removed to form potential neuroeffector sites with vascular smooth muscle (SM) at a and with a neighbouring cell at b, cleft distances being approximately 800 and 400nm respectively. EM. Magnification 50,000X

other tissues because of the presence of densely innervated arteriovenous anastomoses which are especially abundant in the hands, feet, ears, nose and lips of man, though reports of their distribution in other areas of the skin are conflicting. Usually, blood flows from large arteries to arterioles, through capillaries to venules and thus into veins. Skin, however, possesses this unusual shunting mechanism through anastomoses enabling the blood to pass directly from arteries and arterioles to the equivalent veins and venules. Although the major role of arteriovenous anastomoses is assumed to be in temperature regulation, these shunts have been observed frequently in the stomach and mesentery where they are obviously not involved in the regulation of temperature, but open automatically when there is a sudden closing of the capillary bed due to the action of a local stimulus or circulating vasoconstrictor agent. Burton (1959) suggested that a sudden rise of blood pressure brought about by vasoconstriction in any part of the body would raise the pressure in the lumina of the shunts, resulting in their opening and thus combatting the pressure rise. The anastomoses of the skin could therefore act in a similar way in pressure regulation.

The arterioles of the skin can undergo substantial changes in calibre and this is under the control of both neural and extra-neural factors, though the neural mechanism is dominant. This is especially true in temperature regulation where the response to temperature change is a generalised changes in blood flow throughout the whole organism, indicating the involvement of neural co-ordination. During normal temperatures at rest there is vasoconstrictor tone present in the skin vessels (Navaratnam, 1975; Bini, Hagbarth, Hynninen & Wallin, 1980; Ludbrook, 1980) which is abolished upon denervation when flow increases almost to its maximal value (Navaratnam, 1975).

Bini et al (1980) confirmed the presence of a spontaneous vasoconstrictor activity of the nerves in human hands and feet, which is increased on cooling and decreased on warming. Cooling of the body causes general cutaneous vasoconstriction which initially affects the arteriovenous anastomoses but then spreads to involve other vessels. In this way the skin becomes cold but the core temperature of the body is maintained. This response occurs by an increased vasoconstrictor sympathetic stimulus mediated both reflexly by stimulation of the temperature receptors of the skin and by the cooled blood acting on the hypothalamic temperature regulating centre. The response is also brought about by a direct effect on the cutaneous vessels which is not abolished by sympathectomy (Navaratnam, 1975). Exposure to heat produces cutaneous vasodilatation both locally by direct effect and generally by reflex and other neural mechanisms. Again the arteriovenous anastomoses are brought to maximal dilatation followed by the arterioles. In areas of skin where there are no arteriovenous anastomoses, humoral agents often play a greater role alongside neural mechanisms in the vascular responses.

Skin resistance vessels and, to a lesser extent, venules are widely reported to show an adrenergic vasoconstrictor innervation (Eckstein & Hamilton, 1957; Collier, Nachev & Robinson, 1972; Sinclair, 1973; Navaratnam, 1975; Bini et al, 1980; Demey & Vanhoutte, 1980). Arteriovenous anastomoses show both an intense cholinergic (Hurley & Mescon, 1956) and adrenergic (Molyneux & Hales, 1982) innervation and are therefore able to respond to changes in temperature and pressure. Vasodilator fibres are still the subject of much controversy, but there is evidence of a dilator innervation consisting of axon branches from sensory neurons. These may be the basis of the very complex vasomotor reflexes that exist in the skin, triggered by a wide variety of stimuli

ranging from pain and sudden noise to temperature changes (Sinclair, 1973; Navaratnam, 1975; Johnson & Park, 1979).

The aim of the present study is to elucidate histologically the types of nerves likely to influence the vessels in the human skin and thus mediate the rapid changes in blood flow observed during temperature and pressure regulation.

Methods

Normal overlying skin was removed from mastectomy specimens of Cases 9 and 14, fixed and processed for light and electron microscopy according to the schedules previously described (see Chapter 5). Semi-thin sections of resin-embedded material were stained with toluidine blue and examined in the light microscope. Thin sections of suitable arterioles were then cut and stained before examination in the electron microscope. Further pieces of skin were removed from Case 14, rapidly frozen and stored in liquid nitrogen, prior to sectioning and subsequent treatment with the GAF procedure or staining for AChE. Positive control slides from the rat submandibular gland were included in every experiment. Routine staining by haematoxylin and eosin on cryostat cut sections was also performed.

Results

Toluidine Blue and Haematoxylin-Eosin (Hx-E)

The sections clearly demonstrated typical features (see Montagna & Parakkal, 1974; Ryan, 1973a; Weiss & Greep, 1977). Three main areas of the skin were observed; the epidermis, the dermis and the fatty subcutaneous areolar layer. The epidermis stained very strongly with haematoxylin (plate 52) and the actual form of the epidermal cells

was very clearly seen in the semi-thin toluidine blue stained sections (plate 48). A horny layer protects the skin surface and the underlying polyhedral cells forming the depth of the epidermis. These are tightly packed cells which flatten out into layers towards the skin surface. A single row of basal cells forms the deepest layer of the epidermis.

The dermis stained very strongly with eosin indicating the presence of connective tissue within which are held the skin appendages, glands, blood vessels and lymphatics. Two distinct layers were seen within the dermis itself, the upper papillary layer, and the lower reticular layer. In the papillary layer the collagen fibres were arranged in thin bundles in a loose network orientated roughly parallel to the epidermis. The collagen fibres in the reticular layer however were thicker and had less spaces between them (plates 48 and 49). Elastic fibres were present throughout the dermis and appeared to be coarser in the reticular layer (plate 49).

Most of the cells within the dermis were present in the papillary layer. As expected, fibroblasts were numerous as these are responsible for the formation of collagen, elastic and the ground substance. Macrophages were also abundant, serving an essential role in wound healing and in combatting infections. Numerous mast cells were observed, mostly around blood vessels.

Both eccrine sweat glands and sebaceous glands were demonstrated in the breast skin, the sebaceous glands normally being associated with hair follicles (plate 50).

Blood vessels were characteristically stained by toluidine blue and Hx-E (plates 49 and 51). Large arterioles with a thick muscular wall were mainly observed at the border between the lower dermis and the fatty areolar tissue. Arterioles of the upper dermis

were much smaller but still possessed a prominent muscular coat. Venules also demonstrated a size difference between the upper and lower dermis, though in general they were larger than arterioles in the corresponding layer and appeared to have a larger number of more prominent endothelial cells. A bed of capillaries supplied the papillae though no blood vessels actually entered the epidermis. Arteriovenous anastomoses were not readily identified. The cutaneous appendages and glands were richly supplied with blood vessels. Lymph vessels of varying sizes were also distributed throughout the dermis.

Glyoxylic Acid Fluorescence.

The connective tissue of the dermis displayed an intense autofluorescence which made nerve identification difficult though not impossible. In the papillary layer, elastic fibres were seen to autofluoresce but no nerve fibres were observed, either throughout the tissue or around the small arterioles and capillary loops (plate 53). Sweat glands were easily identified by the brightly yellow-orange fluorescent fat droplets within them. No adrenergic innervation of the glands or their vasculature was observed (plate 54). Innervation was also lacking from the hair follicles and sebaceous glands (plate 55). In these glands, the lipid present in the secretion had either been extracted during processing or did not fluoresce with glyoxylic acid, the latter being more likely. An extensive examination of the larger vessels of the deep cutaneous plexus revealed a very sparse adrenergic innervation (Kendall & Jones, in press). Many arterioles were devoid of fibres but occasionally fluorescent beaded nerves were observed in the walls of the larger arterioles (plates 56 and 57).

Acetylcholinesterase Staining

Many positive red-brown stained fibres were observed around the secretory portions of the sweat glands (plate 58). The rest of the tissue, however, was devoid of fibres. No staining was observed around the sebaceous glands (plate 59) or surrounding blood vessels of the papillary (plate 60) or reticular (plate 61) layers (Kendall & Jones, in press). When the specific inhibitor ethopropazine was omitted from the incubation medium the connective tissue gave a faint positive reaction especially around the hair follicles. The density of fibres around sweat glands increased and occasional fibres were seen close to blood vessels. These structures were thought to be demonstrating BuChE activity.

Electron Microscopy

18 vessels from the 2 patients were examined in the electron microscope. All of these vessels were situated in the reticular dermis or between the reticular dermis and the areolar tissue, and showed the characteristic features of arterioles previously described by Ryan (1973a) and Higgins and Eady (1981) in the skin, and Jones and Kendall (1980) in the human breast. Both large and small arterioles were studied and nerve trunks observed passing close to some of the larger ones. Potential neuroeffector sites were seen in only 5 vessels. Here, the axon profiles possessed large dense-cored vesicles and small vesicles (for dimensions see page 149) some of which contained residual stain (plates 62 and 63). Shorter fixation times did not affect the size of the cores in the small vesicles. The presence of such stain, however, suggests that the axons are adrenergic and leaching of the neurotransmitter has occurred. The presence of other nerve types cannot be ascertained until greater differentiation between granular and agranular vesicles is obtained.

Discussion on the Control of Blood Flow through Skin.

Detailed descriptions of the structure and pattern of the vasculature of the skin have been made by various authors (see Ryan, 1973a; Weiss & Greep, 1977; Montagna & Parakkal, 1974; Higgins & Eady, 1981). The basic form of the vascular tree is as follows. Large vessels enter the skin from the subcutaneous fatty layer and branch in the lower dermis to form a deep anastomosing network called the cutaneous plexus. From this plexus, vessels run vertically and obliquely to the upper dermis where they branch again to form the subpapillary plexus. The arterioles are very much smaller at this stage. Arising from this plexus are the terminal capillaries which form vertical loops supplying the papillae though none enter the epidermis itself. Vessels from the subpapillary plexus also supply the superficial parts of the cutaneous appendages whilst the vessels of the cutaneous plexus supply the fat lobules, sweat glands, sebaceous glands and hair bulbs. Drainage of the skin blood takes place through two venous anastomosing networks situated in the superficial and lower dermis. The dermis also possesses a lymphatic drainage system which is arranged in a double plexus like that of the vasculature and transports lymph to the regional lymph nodes.

The classification of vessels in the present work is based upon this generally accepted structure of the vasculature taking into account the diameter and position of the vessel within the skin. Light microscopic studies have revealed a lack of innervation by both adrenergic and cholinergic nerves of the vessels of the superficial plexus and capillary loops. Vessels supplying the appendages and glands are also lacking in innervation. An occasional ascending arteriole was innervated with adrenergic fibres, as were a

few arterioles of the cutaneous plexus. This was confirmed by the electron microscopic observations. Cholinergic nerves were not observed close to blood vessels but were present in a dense plexus around the sweat glands as previously reported by Montagna (1960, 1962) and Montagna & Parakkal (1974). No innervated arteriovenous anastomoses were seen.

Early microscopic studies of the cutaneous innervation of the human breast were limited by the silver and methylene blue staining techniques. Miller and Kasahara (1959) for example, used methylene blue staining and noted the innervation of small arteries and arterioles in the nipple and areola by non-myelinated fibres but more specific identification of these nerves was not possible. They also noted however that a sympathetic ground plexus of fibres seemed to be absent from the skin of the breast peripheral to the areola, a finding which is confirmed by the present results. This area of skin is said to be essentially similar to other hair-covered skin of the body. The methylene blue technique was also used in conjunction with the cholinesterase and monoamine oxidase techniques to stain for cholinergic and adrenergic nerves respectively in the skin of cattle (Jenkinson, Sengupta & Blackburn, 1966), sheep and goats (Jenkinson & Blackburn, 1967). In all cases, nerves staining for monoamine oxidase were present in a dense network around the cutaneous arterioles of the reticular dermis, with occasional AChE-positive fibres also being seen. After sympathectomy the periarteriolar plexus was lost. Improvement of the AChE staining technique and the introduction of fluorescence histochemistry and electron-microscopy have increased the possibility of identifying such nerves. Arteriovenous anastomoses are often seen to be densely innervated by cholinergic nerves, for example in the human digits (Hurley & Mescon, 1956) and by adrenergic nerves, for example sheep skin (Molyneux & Hales,

1982), but no innervated arteriovenous anastomoses have been observed in the present study on the skin of the human breast nor in earlier work on skin covering rabbit breast (Hebb & Linzell, 1970).

There has been no evidence of a parasympathetic branch of the autonomic nervous system entering the skin, and the cutaneous fibres which supply the sweat glands and smooth muscle of the blood vessels have all been thought to be sympathetic (Herxheimer, 1960). Sympathetic stimulation produces erection of the hairs, secretion of sweat and constriction of the blood vessels. Piloerection is due to the adrenergic innervation of the arrectores pilorum muscle. It has little function in man but is an important factor in temperature regulation in animals. The secretion of sweat, however, is very important in man. It is mediated sympathetically through cholinergic nerves and its importance in blood flow control will be discussed later.

Vasoconstriction of blood vessels in the skin is mainly due to the release of noradrenaline from adrenergic nerves, and its subsequent action on alpha adrenoceptors situated on the vascular smooth muscle (Eckstein & Hamilton, 1957; Collier et al, 1972; Zubanov, Moshkin, Malikov & Korobetskii, 1979). This vasoconstriction is the main influence on blood flow in the hands and feet and any vasodilatation that occurs is passive, due solely to the release of constrictor tone. In the rest of the body a significant active vasodilator component is involved in the regulation of flow (Fox & Edholm, 1963). Circulating catecholamines have a purely constrictor action on cutaneous vessels, indicating that no beta adrenoceptor sites are present to mediate the vasodilatation (Navaratnam, 1975). The mechanism of this dilatation is the basis of much controversy.

Edholm, Fox and MacPherson (1957) showed that at normal temperatures blocking of the cutaneous nerves did not change blood flow in the human forearm. On increasing the temperature, vasodilatation was seen in the control arm but not in the nerve-blocked arm. Also, if the nerves were anaesthetized during the increase of blood flow on heating, then flow fell to that seen at normal temperatures. The authors concluded from these results that vasodilatation seen on heating was not due to release of sympathetic vasoconstrictor tone but was owing to an active nerve-mediated vasodilator mechanism. Studies by Roddie, Shepherd and Whelan (1957) also led to the conclusion that the increase in flow in the skin of the forearm was mediated by vasodilator nerves and that the increase in flow through the hand was due solely to a release of vasoconstrictor tone.

A sympathetic vasodilatory mechanism does not necessarily imply the presence of vasodilator fibres in the skin. The effect could be brought about by release of a vasodilator resulting from sweat gland activity as suggested by Fox and Hilton (1958). These workers demonstrated that sweat contained the enzyme catalysing the formation of bradykinin, a powerful vasodilating polypeptide, and that this vasodilator increased in concentration in the perfusate collected from subcutaneous tissue on heating. They likened the proposed relationship between sweat secretion and blood flow to that between salivary secretion and vasodilatation in the cat submandibular gland as proposed by Hilton and Lewis (1955a, 1955b, 1956). Although studies by Roddie et al (1957) have shown that a greater part of forearm skin vasodilatation was abolished by atropine, indicating a possible involvement of muscarinic receptors, a small atropine-resistant component persisted, even though sweating was completely abolished. A parallel could be drawn between this and the partial

atropine-resistant response observed in the cat submandibular gland (see Bhoola et al, 1965). The fact that a component of vasodilatation persisted when sweating or salivation was blocked suggested that the vasodilatation is independent of factors contained in the secretion. However, although saliva secretion is blocked by atropine, kinin released into the salivary glands was not blocked (Rowell, 1981). The same could be true for sweat glands. So vasodilatation mediated by bradykinin could occur even when no sweat secretion is observed, providing the sweat glands are functional. Increasing evidence, however, suggests that bradykinin does not adequately explain cutaneous vasodilatation (for further details see Rowell, 1981) but a functional connection does exist between sweat gland activity and active cutaneous vasodilatation. A key to this relationship comes from studies on patients with congenital absence of sweat glands, a condition called anhidrotic ectodermal dysplasia, where the vasculature and innervation appears normal. Here, no active vasodilatation occurred in response to heating but a small rise in forearm blood flow was seen which was thought to be due to withdrawal of vasoconstrictor activity. Rowell (1981) states that without sweat glands, active vasodilatation does not occur. The small rise in blood flow seen in patients, however, could be equivalent to the atropine-resistant vasodilatation which persisted even when sweating was blocked.

The vasomotor control of the hand and forearm has been studied extensively due to the convenience of using venous occlusion plethysmography. Differing forms of vasomotor control are demonstrated in these two areas showing that no uniform means of control is exerted throughout the whole body and each area of the body must therefore be examined. The calf, thigh, upper arm, cheeks, forehead, chin, neck and trunk possess a vasodilator mechanism similar to that

of the forearm, whereas the lips and pinnae of the ears have predominantly a vasoconstrictor mechanism like that observed in the hands and feet. These results would be expected if vasodilatation and sweating are connected as very few sweat glands are present in these areas of the lips and ears (Fox & Edholm, 1963). Navaratnam (1975) notes that the vasodilator substances released as a result of sweat secretion promote increases in cutaneous blood flow by the maximal dilatation of arterioles, especially in areas lacking arteriovenous anastomoses. It is interesting to note that in areas where there are few sweat glands and little evidence of a direct vasodilator mechanism arteriovenous anastomoses are abundant. Active reflex vasodilatation is also seen only in animals that sweat and is absent from the cat and dog (Ryan, 1973b). The present histological studies show the presence of cholinergically innervated sweat glands in breast skin where no arteriovenous anastomoses have been observed. Sympathetically mediated secretion from these glands could control vasodilatation in this tissue where there is no shunting mechanism to increase blood flow to the skin.

Bradykinin is not the only substance suggested as a mediator of the atropine-resistant vasodilatation of skin vessels. Prostaglandin E_1 (Bevegård & Öro^L, 1969), A_1 , A_2 , B_1 , E_2 and $F_{2\alpha}$ (Robinson et al, 1973) can produce vasodilatation in the forearm arterial bed. In contrast, only prostaglandins A_1 , A_2 and E_2 induce dilatation of the superficial hand veins whilst prostaglandins B_1 and $F_{2\alpha}$ produce constriction. These results suggest that there are at least two types of receptors in skin vessels mediating responses to prostaglandins (Robinson et al, 1973). Prostaglandins E_1 and E_2 also produce vasodilatation in the skin of sheep limbs (Rudolph & Heymann, 1978; Tripp, Heymann & Rudolph, 1978). Further discussion on prostaglandins and skin vasculature is given by Zimmerman, Dunham & Sugawara (1982). Dopamine is another vasoactive agent which has been

demonstrated as a vasodilator in skin (Bell et al, 1975) as have histamine (Duff, Greenfield, Shepherd & Thompson, 1953; Beck, 1965; Graham & Liroy, 1973; Bell et al, 1975), isoprenaline, serotonin and bradykinin (Bell et al, 1975).

Possible mediators of blood flow control in the salivary gland that have been extensively studied are adenylyl compounds and peptides which may be released from nerves. In view of the similarity between atropine-resistant vasodilatation in the cat submandibular gland and that observed in the skin, it would be interesting to consider the involvement of these substances, and the possibility of a novel component of the autonomic nervous system, in the control of skin blood flow.

In the human forearm and hand, ATP especially when coupled with magnesium, proved to be as powerful a vasodilator as ACh and histamine (Duff et al, 1953; Duff, Patterson & Shepherd, 1954). Burnstock (1977) speculates on the possible involvement of purinergic nerves in the innervation of skin blood vessels and mast cells, where stimulation would affect the release of the vasodilator histamine. He also discusses the possibility of a functional link between ATP, histamine, bradykinin and prostaglandins in cutaneous vasodilatation. (For further information on the possibility of purinergic vasodilator innervation in skin see Burnstock, 1980).

VIP has been demonstrated in nerves surrounding blood vessels in certain salivary glands and these may mediate the atropine-resistant vasodilatation (Wharton et al, 1979). It would be interesting to see if VIP and/or substance P immunoreactive nerves were observed around vessels in human skin. Substance P is known to have a potent vasodilating effect on resistance vessels in the human forearm (Lofstrom, Pernow & Wahren, 1965; Eklund, Jogestrand & Pernow, 1977) and the hindlimb skin of cat and dog (Burcher, Atterhog, Pernow & Rosell, 1977).

Improvement of the fixation procedures used in the present electron-microscopical studies should help in the identification of possible non-adrenergic, non-cholinergic nerves influencing skin vessels. Further development of specific antibody binding techniques to neurotransmitters should also aid in nerve identification and contribute to a greater knowledge of the vasodilating mechanisms in skin vessels.

This work does indicate that periarteriolar adrenergic fibres are present, exerting their probable vasoconstrictor effect on vessels of the deep cutaneous plexus. No perivascular cholinergic fibres have yet been demonstrated but they may be very sparse in number. The possibility remains that 'peptidergic' or 'purinergic' mechanisms mediating vasodilatation may also be present.

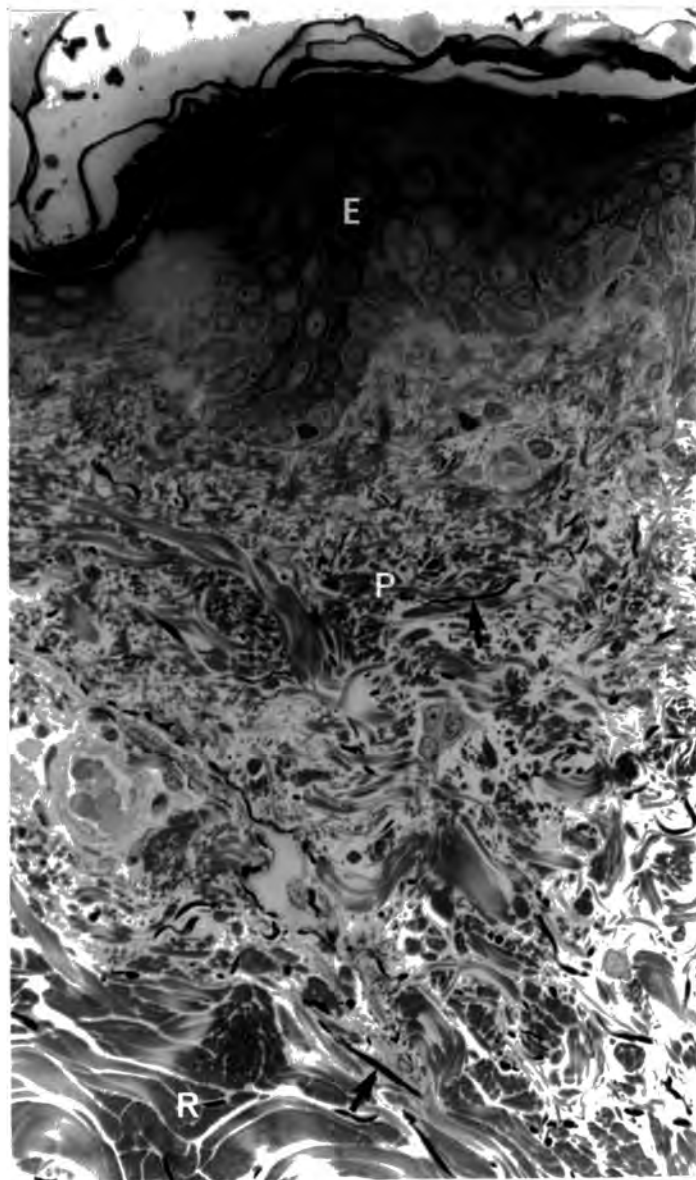


Plate 48 Human Skin Case 9. The skin profile shown on this plate demonstrates the epidermis (E), papillary layer (P) and reticular layer (R). Elastic fibres (↑) are present throughout the dermis. Toluidine Blue. Magnification 450X




Plate 49 Human Skin Case 9. View of the reticular layer of the dermis showing thick collagen bundles (C), coarse elastic fibres (A) and a blood vessel (V). Toluidine Blue. Magnification 450X

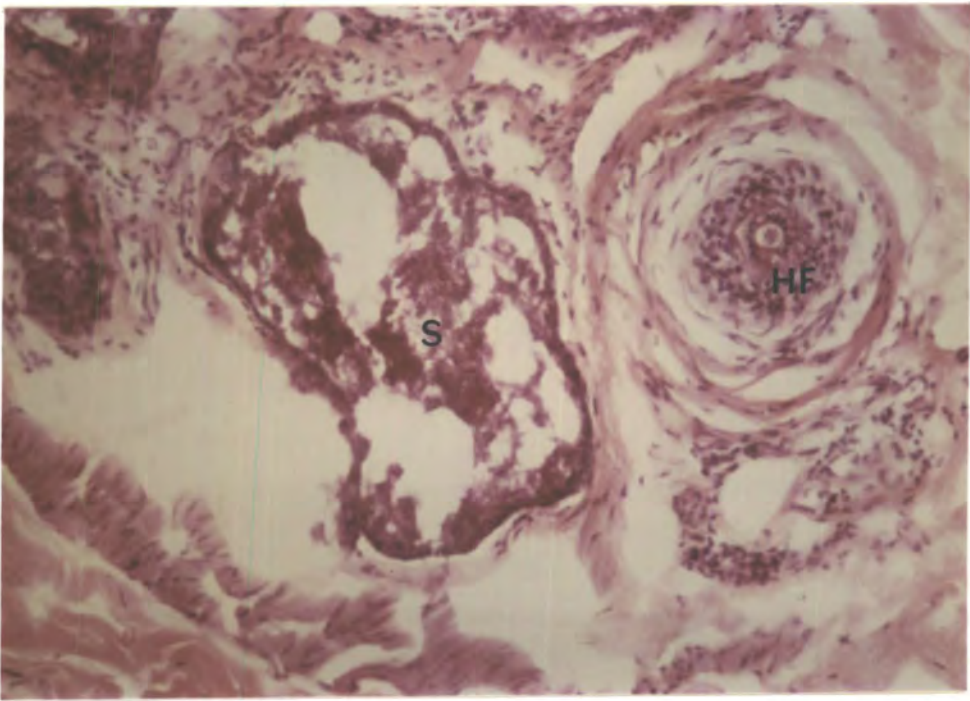


Plate 50 Human Skin Case 14. A characteristically stained hair follicle (HF) and sebaceous gland (S) are shown on this plate. Hx-E. Magnification 140X

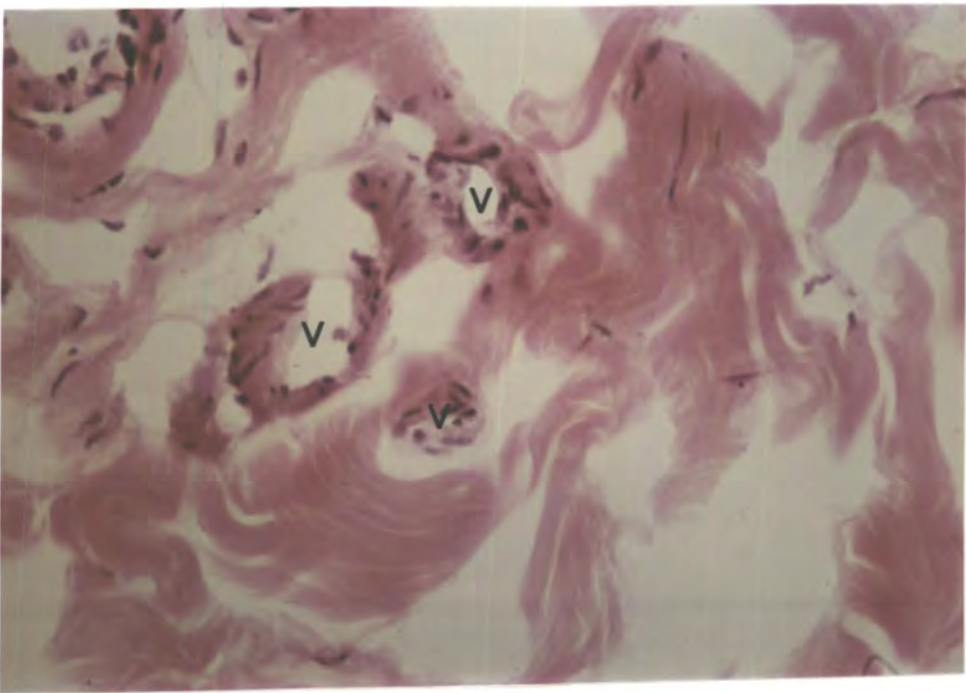

Plate 51 Human Skin Case 14. This plate shows a number of small vessels (v) in the reticular layer of the dermis. Hx-E. Magnification 275X

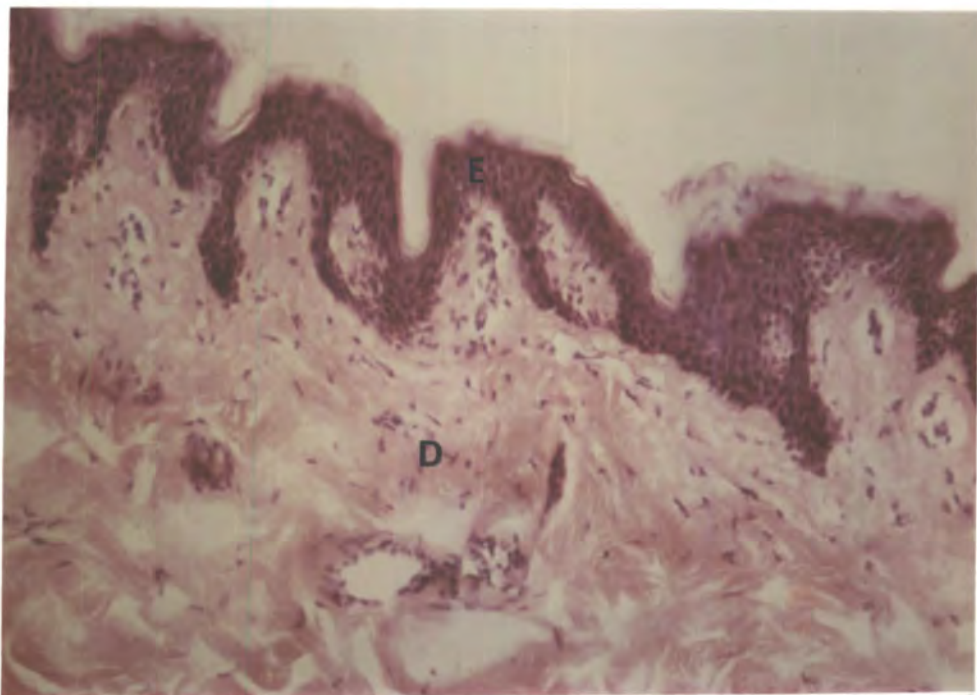


Plate 52 Human Skin Case 14. This shows the cellular epidermis (E), contrasting markedly with the collagen of the dermis (D). Hx-E. Magnification 140X

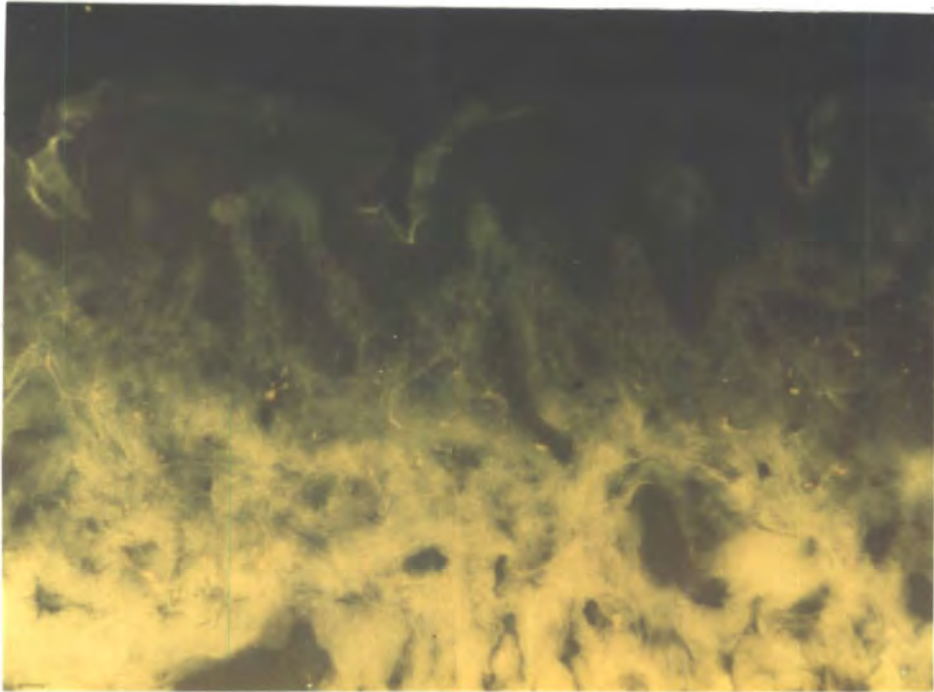


Plate 53 Human Skin Case 14. View of the epidermis and the dermal papillary layer showing the autofluorescent collagen and elastic fibres but no fluorescent nerves. GAF. Magnification 110X

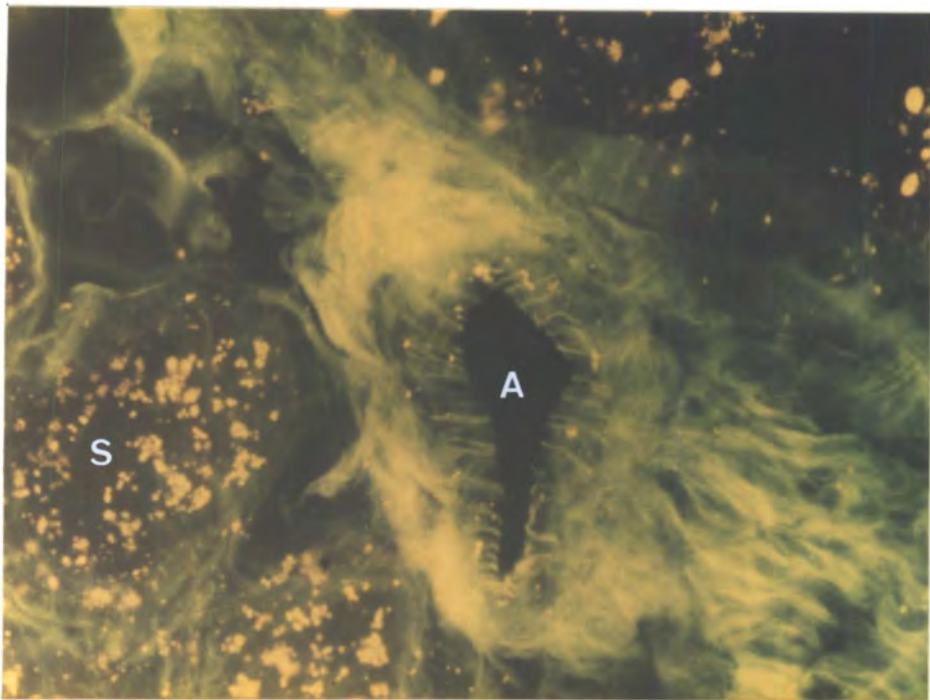


Plate 54 Human Skin Case 14. An arteriole (A) supplying sweat gland (S) is shown on this plate. No nerves are present. GAF. Magnification 275X

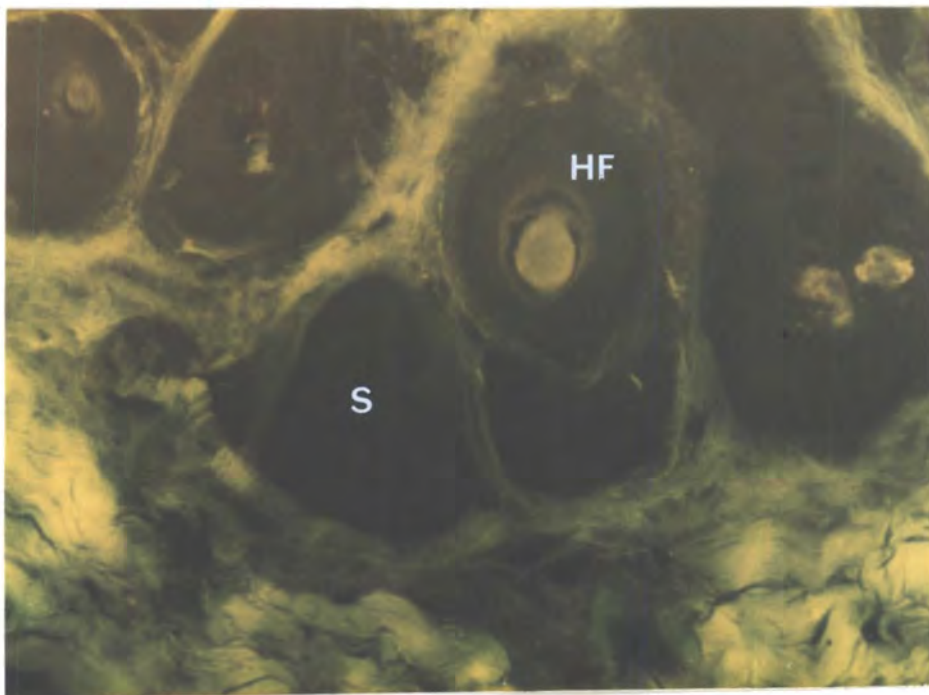
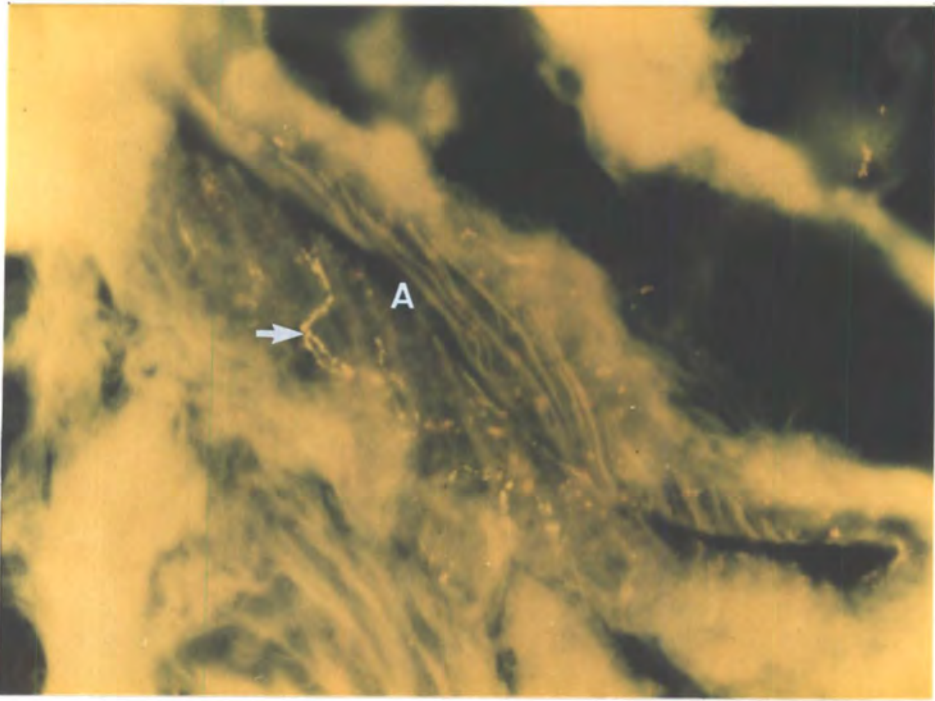
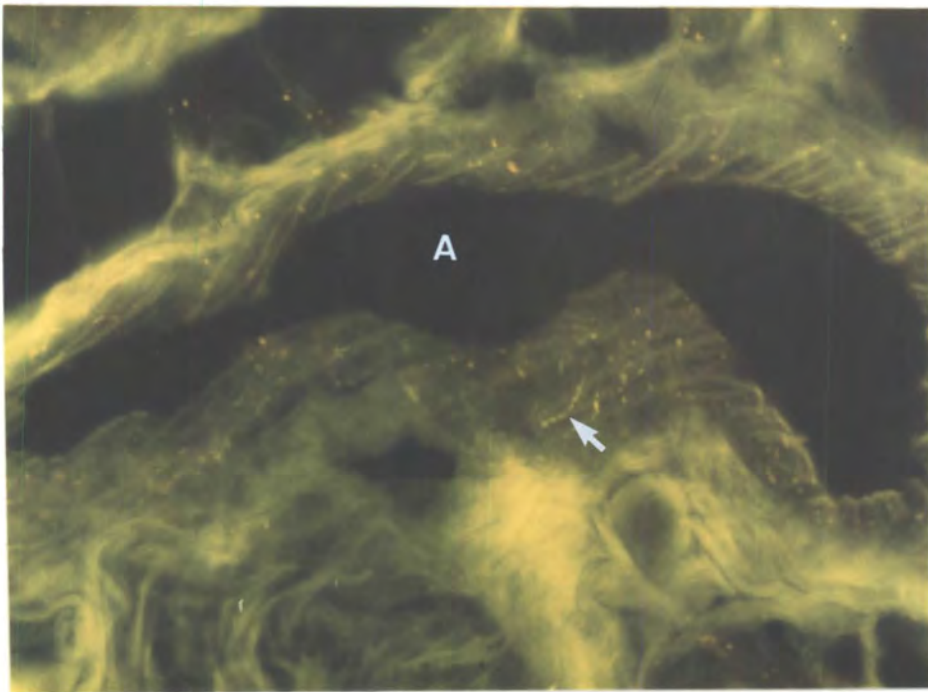


Plate 55 Human Skin Case 14. View of hair follicle (HF) and sebaceous gland (S) both of which lack innervation. GAF. Magnification 110X



Plates 56 and 57 Human Skin Case 14. These plates show arterioles (A) with fluorescent beaded nerve fibres (→) in the walls. GAF. Magnification 275X



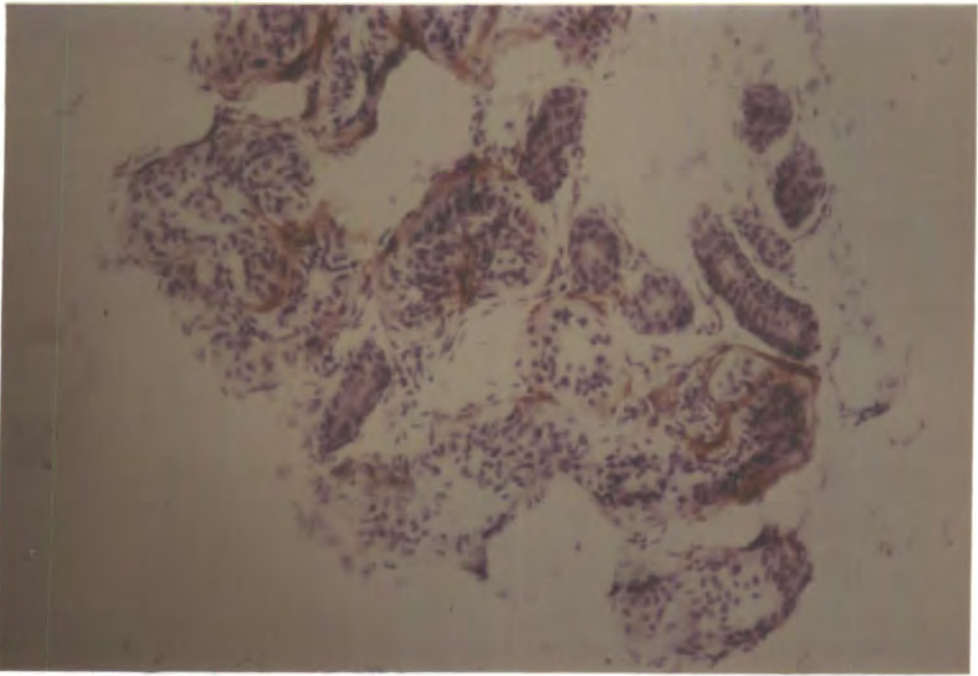


Plate 58 Human Skin Case 14. View of sweat glands innervated by red/brown AChE-positive fibres. AChE. Magnification 140X

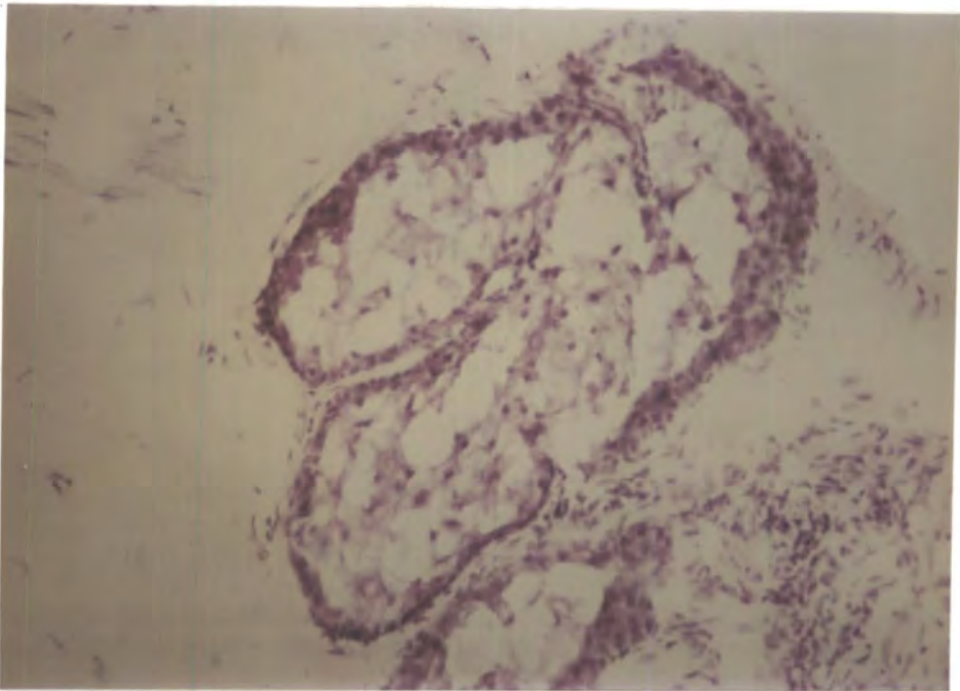


Plate 59 Human Skin Case 14. No AChE-positive nerves innervate the sebaceous glands. AChE. Magnification 140X

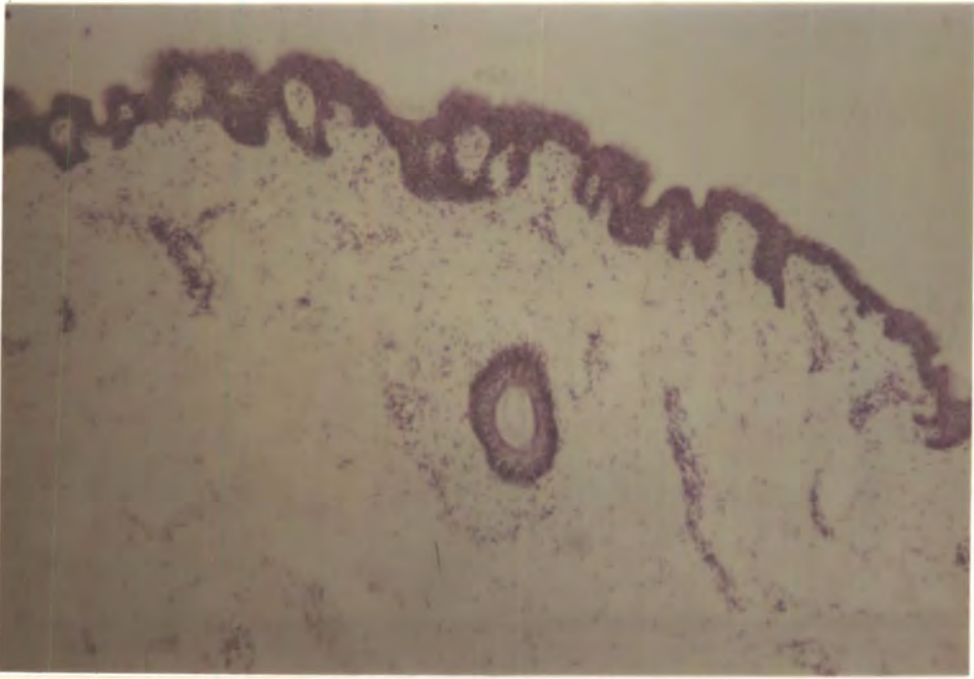

Plate 60 Human Skin Case 14. This shows the absence of AChE-positive fibres in the epidermis and the dermal papillary layer. AChE. Magnification 55X

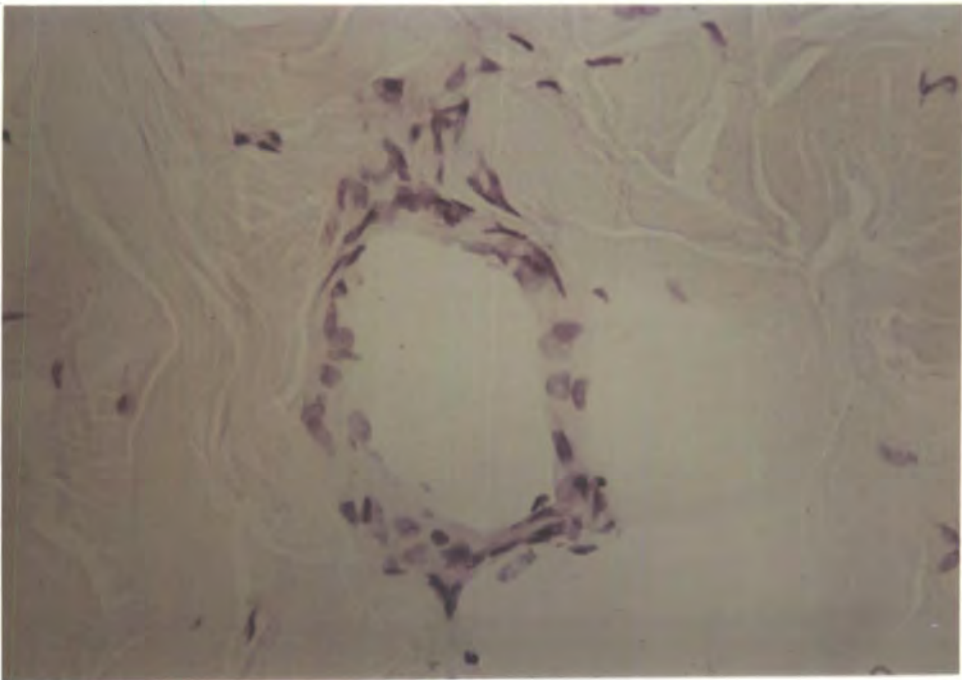


Plate 61 Human Skin Case 14. No AChE-positive fibres are seen around this arteriole in the dermal reticular layer. AChE. Magnification 275X

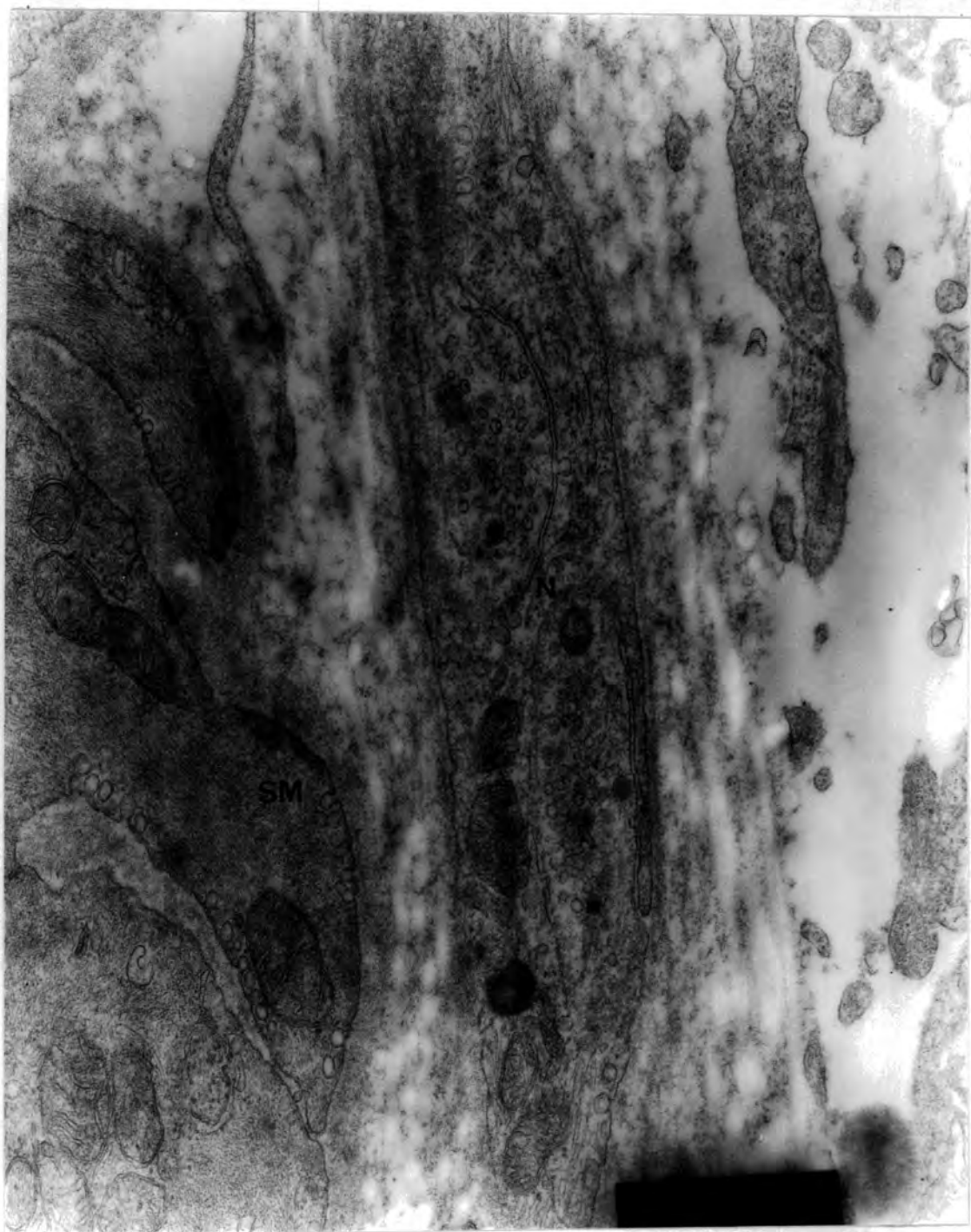


Plate 62 Human Skin Case 14. View of periarteriolar nerve profiles (N) adjacent to smooth muscle (SM). The smallest nerve-muscle separation is approximately 380nm. Note the presence of residual stain in the vesicles of the axons. EM. Magnification 39,000X

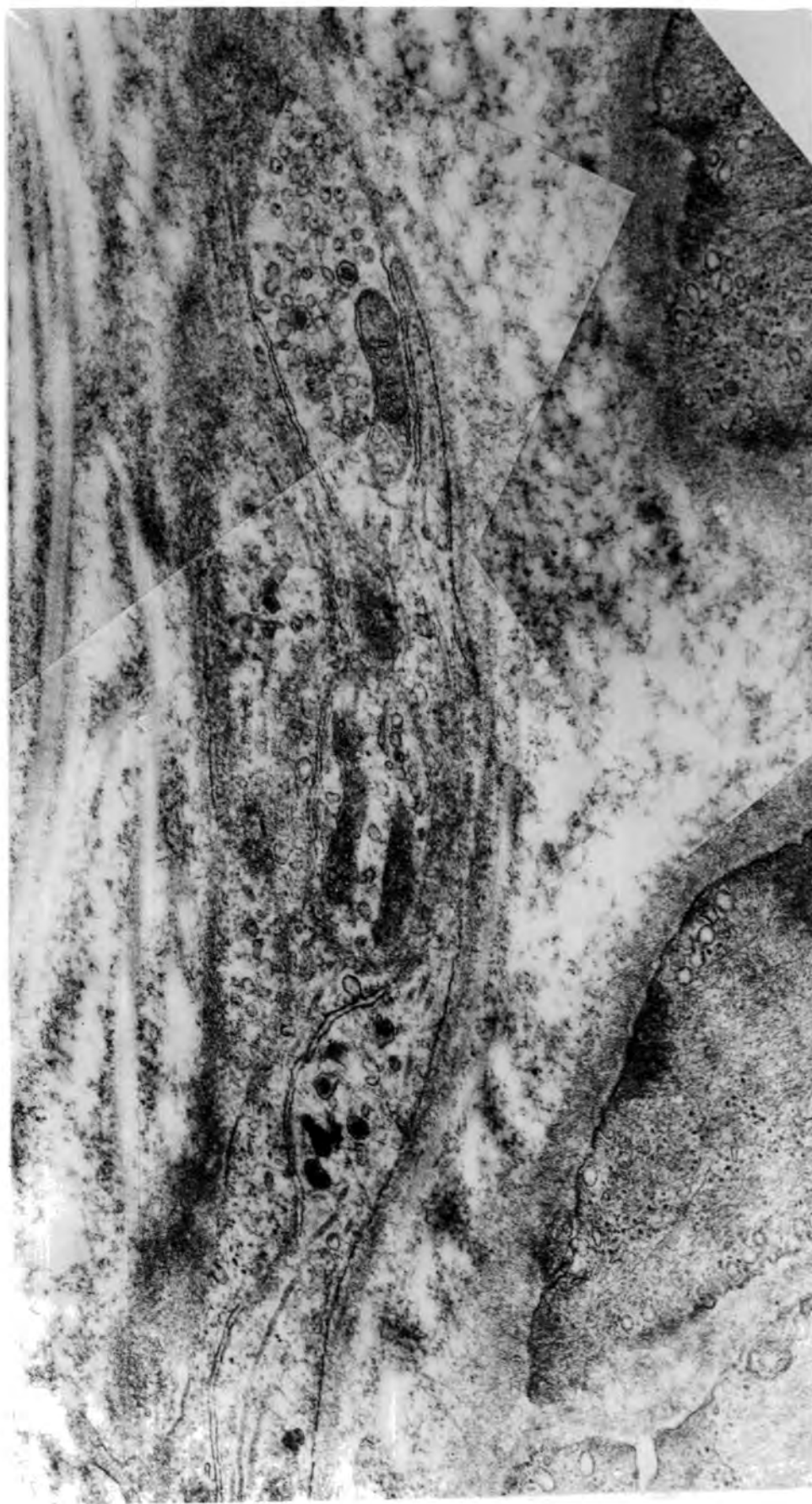

Plate 63 Human Skin Case 14. This montage shows periarteriolar axon profiles containing large granular vesicles and residual stain in the small vesicles. The smallest nerve-muscle separation is approximately 560nm. EM. Magnification 50,000X

Chapter 7

A COMPARISON OF THE SIZE DISTRIBUTION OF THE ADRENERGICALLY INNERVATED RESISTANCE VESSELS IN VARIOUS ANIMAL AND HUMAN TISSUES.

Introduction

A preliminary comparison of the vessels innervated by GAF-positive nerve fibres in rat salivary gland, rat mammary gland, human breast and human skin, indicated a distinct difference in the size of innervated vessels between the tissues. A more detailed study was therefore performed to examine for this.

Method

The material cut and stained by the GAF procedure was examined for arterioles showing fluorescent nerve fibres in the adventitia. These vessels were measured under ultra-violet light using a scale within the eyepiece of the Zeiss Ultraphot Photomicroscope. The external diameters of the vessels were measured, and in cases where the vessels were elliptical, the means of the long and short distances across the vessels were determined.

Results

The results are as shown in table 4 and presented graphically in figure 3. In the rat salivary gland, very small vessels (less than $10\mu\text{m}$) were not innervated or were too small to be identified by this method. 81% of the innervated vessels measured 10-60 μm in diameter

and few larger innervated arterioles were observed.

The rat mammary gland showed a similar profile with 66% of the innervated vessels measuring 10-60 μ m, though a greater number of larger vessels showing innervation were seen in comparison with the salivary glands.

Human skin showed a very different profile. Many of the vessels of all sizes were not innervated and those that did possess fluorescent fibres tended to be 60-90 μ m in diameter or larger. A fairly large number of vessels over 160 μ m were seen to possess adrenergic innervation.

No vessels of any size were seen to be innervated in the human breast.

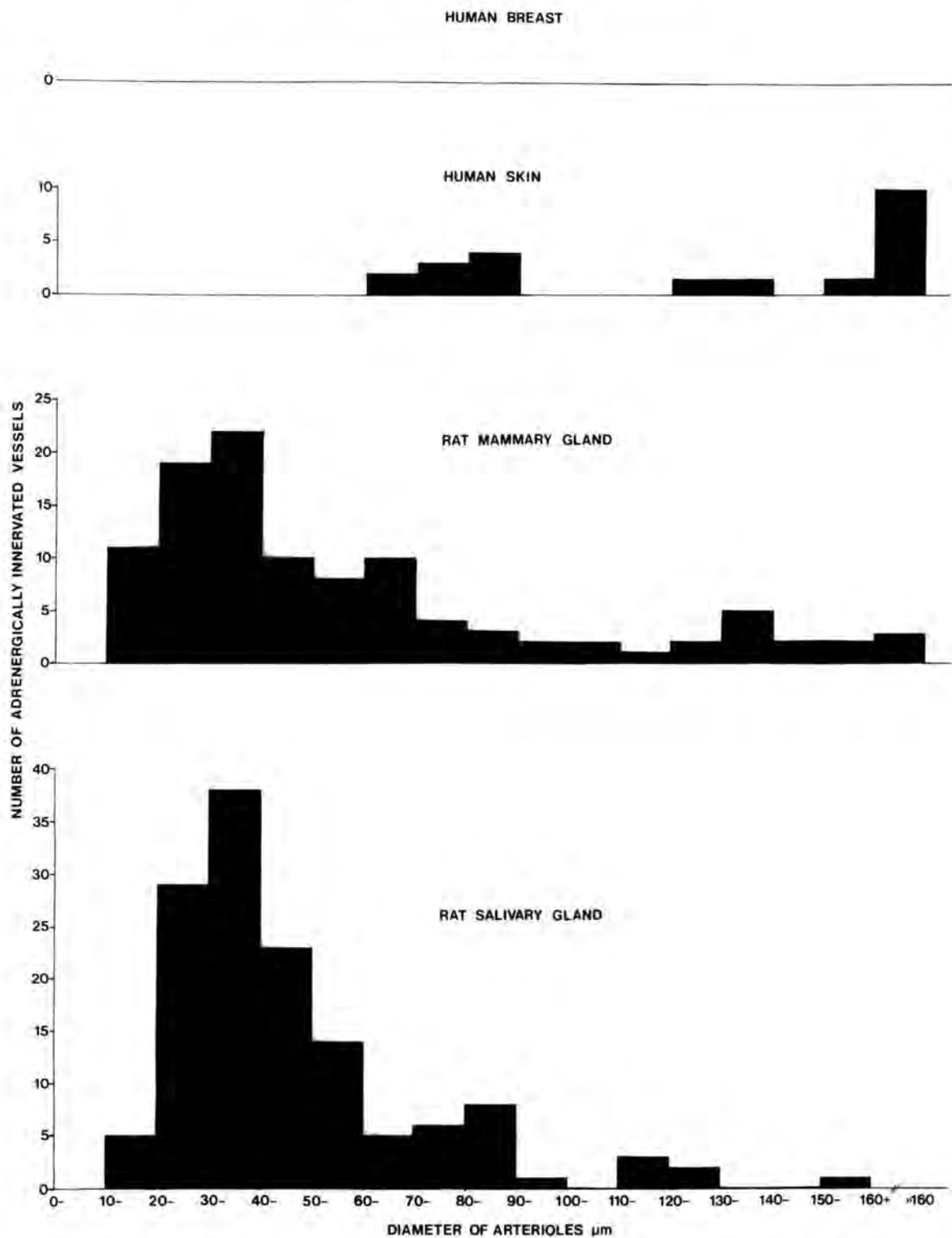
Discussion

These results show that in different vascular beds and in different species, the neural control of blood flow is exerted at differing levels of blood vessel size. It is generally accepted that resistance vessels are very important in controlling flow through the tissue capillary bed but control may be exerted at differing sizes of the resistance vessels. In the rat tissues studied, vessels of the calibre 10-60 μ m diameter appeared to be most important in the control, whereas in the human skin, vessels of this size appeared to lack innervation and adrenergic control took place in larger resistance vessels. The breast tissue showed no neural control of blood flow at all the resistance vessel sizes studied.

Table 4 Size Distribution of Adrenergically Innervated Vessels.

<u>ARTERIOGLAR</u> <u>DIAMETER</u> (μm)	<u>NUMBER OF ADRENERGICALLY</u> <u>INNERVATED VESSELS</u>		
	<u>Rat Salivary</u> <u>Gland</u>	<u>Rat Mammary</u> <u>Gland</u>	<u>Human Skin</u>
0 -	0	0	0
10 -	5	11	0
20 -	29	19	0
30 -	38	22	0
40 -	23	10	0
50 -	14	8	0
60 -	5	10	2
70 -	6	4	3
80 -	8	3	4
90 -	1	2	0
100 -	0	2	0
110 -	3	1	0
120 -	2	2	1
130 -	0	5	1
140 -	0	2	0
150 -	1	2	1
160 +	0	3	10

FIGURE 4. SIZE DISTRIBUTIONS OF ADRENERGICALLY INNERVATED VESSELS



BIBLIOGRAPHY

1. ABRAMOFF, P. & LA VIA, M.F. (1970), Biology of the Immune Response. McGraw Hill Book Company, New York.
2. AHLQUIST, R.P. (1948), A study of the adrenotropic receptors. Am. J. Physiol. 153, 586-600.
3. ALM, P., BLOOM, G.D. & CARLSSON, B. (1973), Adrenergic and cholinergic nerves of bovine, guinea-pig and hamster salivary glands. A light and electron microscopic study. Z. Zellforsch. 138, 407-420.
4. AMENTA, F., PORCELLI, F. & FERRANTE, F. (1979), Histochemical studies on the autonomic innervation of the femoral artery and vein. Anat. Embryol. 157, 231-235.
5. ARIENS, E.J. (1981), The classification of beta-adrenoceptors 2. TIPS 2, 170-172.
6. ARMSTRONG, J.M., THIRSK, G. & SALMON, J.A. (1979), Effects of prostacyclin (PGI_2), 6-oxo-PGF_{1alpha} and PGE₂ on sympathetic nerve function in mesenteric arteries and veins of the rabbit in vitro. Hypertension 1, 309-315.
7. ASPELIN, P., NYLANDER, G. & PETERSON, H. (1976), Bradykinin-induced changes in caliber of portal vein during splanchnic angiography. Invest. Radiol. 11, 10-13.

8. AXELSSON, S., BJÖRKLUND, A., FALCK, B., LINDVALL, O. & SVENSSON, L.-A.^o (1973), Glyoxylic acid condensation: a new fluorescence method for the histochemical demonstration of biogenic monoamines. Acta Physiol. Scand. 87, 57-62.
9. BARAJAS, L. & WANG, P. (1975), Demonstration of acetylcholinesterase in the adrenergic nerves of the renal glomerular arterioles. J. Ultrastruc. Res. 53, 244-253.
10. BARAJAS, L. & WANG, P. (1979), Localization of tritiated norepinephrine in the renal arteriolar nerves. Anat. Rec. 195, 525-534.
11. BARAJAS, L., WANG, P. & DE SANTIS, S. (1976), Light and electron microscopic localization of acetylcholinesterase activity in the rat renal nerves. Am. J. Anat. 147, 219-234.
12. BECK, L. (1965), Histamine as the potential mediator of active reflex dilatation. Fed. Proc. 24, 1298-1310.
13. BELL, C. (1968), Dual vasoconstrictor and vasodilator innervation of the uterine arterial supply in the guinea-pig. Circ. Res. 23, 279-289.
14. BELL, C. (1969), Fine structural localization of acetylcholinesterase at a cholinergic vasodilator nerve - arterial smooth muscle synapse. Circ. Res. 24, 61-70.
15. BELL, C., CONWAY, E.L., LANG, W.J. & PADANYI, R. (1975), Vascular dopamine receptors in the canine hindlimb. Br. J. Pharmac. 55, 167-172.

16. BENFEY, B.G. (1979), Cardiac adrenoceptors at low temperature and the adrenoceptor interconversion hypothesis. Can. J. Physiol. Pharmac. 57, 771-777.
17. BERGSTROM, S., CARLSON, L.A., EKELUND, L.G. & ORO, L. (1965), Cardiovascular and metabolic response to infusions of prostaglandin E_1 and to simultaneous infusions of noradrenaline and prostaglandin E_1 in man. Acta Physiol. Scand. 64, 332-339.
18. BERTEL, O., BUHLER, F.R., KIOWSKI, W. & LUTOLD, B.E. (1980), Decreased beta-adrenoceptor responsiveness as related to age, blood pressure, and plasma catecholamines in patients with essential hypertension. Hypertension 2, 130-138.
19. BEVAN, A.T., HONOUR, A.J. & STOTT, F.H. (1969), Direct arterial pressure recording in unrestricted man. Clin. Sci. 36, 329-344.
20. BEVAN, J.A. & SU, C. (1974), Variation of intra- and perisynaptic adrenergic transmitter concentrations with width of synaptic cleft in vascular tissue. J. Pharmacol. 190, 30-38.
21. BEVEGARD, S. & ORO, L. (1969), Effect of prostaglandin E_1 on forearm blood flow. Scand. J. Clin. Lab. Invest. 23, 347-353.
22. BHOOLA, K.D., MORLEY, J., SCHACHTER, M. & SMAJE, L.H. (1965), Vasodilatation in the submaxillary gland of the cat. J. Physiol. (Lond.) 179, 172-184.

23. BINI, G., HAGBARTH, K.-E., HYNINEN, P. & WALLIN, B.G. (1980), Thermoregulatory and rhythm-generating mechanisms governing the sudomotor and vasoconstrictor outflow in human cutaneous nerves. J. Physiol. (Lond.) 306, 537-552.
24. BISSET, G.W., CLARK, B.J. & LEWIS, G.P. (1967), The mechanism of the inhibitory action of adrenaline on the mammary gland. Br. J. Pharmac. Chemother. 31, 550-559.
25. BITAR, K.N., SAID, S.I., WEIR, G.C., SAFFOURI, B. & MAKHLOUF, G.M. (1980), Neural release of vasoactive intestinal peptide from the gut. Gastroenterology 79, 1288-1294.
26. BLOOM, S.R., BRYANT, M.G., POLAK, J.M., VAN NOORDEN, S. & WHARTON, J. (1979), Vasoactive intestinal peptide (VIP) like immunoreactivity in salivary glands. J. Physiol. (Lond.) 289, 23P.
27. BLOOM, S.R. & EDWARDS, A.V. (1980), Vasoactive intestinal polypeptide in relation to atropine resistant vasodilatation in the submaxillary gland of the cat. J. Physiol. (Lond.) 300, 41-53.
28. BLOOM, S.R. & POLAK, J.M. (1978), Peptidergic versus purinergic. Lancet i, 93.
29. BOELKINS, J.N., MAZURKIEWICZ, M., MAZUR, P.E. & MUELLER, W.J. (1976), Changes in blood flow to bones during hypocalcaemic and hypercalcaemic phases of the response to parathyroid hormone. Endocrinology 98, 403-412.

30. BOGART, B.I. (1970), Fine structural localization of cholinesterase activity in the rat submandibular gland. J. Histochem. Cytochem. 18, 730-739.
31. BOGART, B.I. (1971), The fine structural localization of acetylcholinesterase activity in the rat parotid and sublingual glands. Am. J. Anat. 132, 259-266.
32. BOLME, P. & FUXE, K. (1970), Adrenergic and cholinergic nerve terminals in skeletal muscle vessels. Acta Physiol. Scand. 78, 52-59.
33. BORODULYA, A.V. & PLETCHKOVA, E.K. (1973), Distribution of cholinergic and adrenergic nerves in the internal carotid artery. A histochemical study. Acta Anat. 86, 410-425.
34. BORODULYA, A.V. & PLETCHKOVA, E.K. (1976), Cholinergic innervation of vessels of the base of the brain. Acta Anat. 96, 135-147.
35. BRICK, I., HUTCHINSON, K.J. & RODDIE, I.C. (1967), The vasodilator properties of noradrenaline in the human forearm. Br. J. Pharmac. Chemother. 30, 561-567.
36. BRINE, F., CORNISH, E.J. & MILLER, R.C. (1979), Effects of uptake inhibitors on responses of sheep coronary arteries to catecholamines and sympathetic nerve stimulation. Br. J. Pharmacol. 67, 553-561.

37. BRITTON, S.L., SEXTON, J.M., FIKSEN-OLSEN, M.J., WERNESS, P.G. & ROMERO, J.C. (1980), A comparison of angiotensin II and angiotensin III as vasoconstrictors in the mesenteric circulation of dogs. Circ. Res. 46, 146-151.
38. BROWN, A.M. (1968), Motor innervation of the coronary arteries of the cat. J. Physiol. (Lond.) 198, 311-328.
39. BUCCAFUSCO, J.J. & SPECTOR, S. (1980), Role of central cholinergic neurons in experimental hypertension. J. Cardiovasc. Pharmacol. 2, 347-355.
40. BUHLER, F.R. (1980), Elevated plasma adrenaline, age-related decrease in beta-adrenoceptor-mediated cardiovascular functions and increase in alpha-receptor-mediated vasoconstriction in essential hypertension. In: Central Adrenaline Neurons. Basic Aspects and their Role in Cardiovascular Functions, edited by K. Fuxe, M. Goldstein, B. Hokfelt and T. Hokfelt, pp. 305-316. Pergamon Press, Oxford.
41. BURCHER, E., ATTERHÖG, J.H., PERNOW, B. & ROSELL, S. (1977), Cardiovascular effects of substance P: effects on the heart and regional blood flow in the dog. In: Substance P, edited by U.S. Von Euler and B. Pernow, pp. 261-268. Raven Press, New York.
42. BURGÉN, A.S.V. & EMMELIN, N.G. (1961), Physiology of the Salivary Glands. Physiological Society Monograph. Arnold, London.

43. BURNSTOCK, G. (1970), Structure of smooth muscle and its innervation. In: Smooth Muscle, edited by E. Bulbring, A. Brading, A. Jones and T. Tomita, pp. 1-69. Edward Arnold, London.
44. BURNSTOCK, G. (1972), Purinergic nerves. Pharmacol. Rev. 24, 509-581.
45. BURNSTOCK, G. (1975a), Purinergic transmission. In: Handbook of Psycho-Pharmacology, Vol. 5, edited by L.L. Iversen, S.D. Iversen and S.H. Snyder, pp. 131-194. Plenum, New York.
46. BURNSTOCK, G. (1975b), Innervation of vascular smooth muscle: histochemistry and electron microscopy. Clin. Exp. Pharmacol. Physiol. Suppl. 2, 7-20.
47. BURNSTOCK, G. (1977), Autonomic neuroeffector junctions - reflex vasodilatation of the skin. J. Invest. Dermatol. 69, 47-57.
48. BURNSTOCK, G. (1979), Past and current evidence for the purinergic nerve hypothesis. In: Physiological and Regulatory Functions of Adenosine and Adenine Nucleotides, edited by H.P. Baer and G.I. Drummond, pp. 3-32. Raven Press, New York.
49. BURNSTOCK, G. (1980), Cholinergic and purinergic regulation of blood vessels. In: Handbook of Physiology, Section 2 The Cardiovascular System, edited by D.F. Bohr, A.P. Somlyo, H.V. Sparks and S.R. Geiger. American Physiological Society, Bethesda, Maryland.

50. BURNSTOCK, G. (1981), Ultrastructural identification of neurotransmitters. Scand. J. Gastroent. 16, 1-9.
51. BURNSTOCK, G., CHAMLEY, J.H. & CAMPBELL, G.R. (1980), The innervation of arteries. In: Structure and Function of the Circulation, Vol. 1, edited by C.J. Schwartz, N.T. Werthessen and S. Wolf, pp. 729-767. Plenum Press, New York.
52. BURNSTOCK, G. & COSTA, M. (1975), Adrenergic Neurons and their Organisation, Function and Development in the Peripheral Nervous System. Chapman and Hall, London.
53. BURNSTOCK, G., DUMSDAY, B.H. & SMYTHE, A. (1972), Atropine resistant excitation of the urinary bladder: the possibility of transmission via nerves releasing a purine nucleotide. Brit. J. Pharmacol. 44, 451-461.
54. BURNSTOCK, G. & IWAYAMA, T. (1971), Fine-structural identification of autonomic nerves and their relation to smooth muscle. Prog. Brain Res. 34, 389-404.
55. BURNSTOCK, G., O'SHEA, J. & WOOD, M. (1963), Comparative physiology of the vertebrate autonomic nervous system. I. Innervation of the urinary bladder of the toad (Bufo marinus). J. Exp. Biol. 40, 403-419.

56. BURTON, A.C. (1959), Physiology of cutaneous circulation, thermoregulatory functions. In: The Human Integument, edited by S. Rothman, Publ. No. 54, pp. 77-88. Amer. Assoc. Advance. Sci., Washington D.C.
57. BURTON, A.C. (1961), Special features of the circulation of the skin. In: Advances in Biology of Skin. Blood Vessels and Circulation, Vol. 2, edited by W. Montagna and R.A. Ellis, pp. 117-122. Pergamon Press, Oxford.
58. CALDICOTT, W.J.H., TAUB, K.J. & HOLLENBERG, N.K. (1977), Identical mesenteric, femoral and renal vascular responses to angiotensins II and III in the dog. Life Sci. 20, 517-522.
59. CAMPBELL, A.G.M., DAWES, G.S., FISHMEN, A.P., HYMAN, A.L. & PERKS, A.M. (1968), The release of bradykinin-like pulmonary vasodilator substance in foetal and newborn lambs. J. Physiol. (Lond.) 195, 83-96.
60. CASSIN, S., DAWES, G.S. & ROSS, B.B. (1964), Pulmonary blood flow and vascular resistance in immature foetal lambs. J. Physiol. (Lond.) 171, 80-89.
61. CASSIN, S., TYLER, T. & LEFFLER, C. (1978), Pulmonary vascular responses to prostaglandins and prostaglandin synthetase inhibitors in perinatal goats. In: Advances in Prostaglandin and Thromboxane Research, Vol. 4, edited by F. Cocceani and P.M. Olley, pp. 249-256. Raven Press, New York.

62. CAUNA, N. (1970), The fine structure of the arteriovenous anastomosis and its nerve supply in the human nasal respiratory mucosa. Anat. Rec. 168, 9-22.
63. CHUBB, I.W., HODGSON, A.J. & WHITE, G.H. (1980), Acetylcholinesterase hydrolyzes substance P. Neuroscience 5, 2065-2072.
64. COHEN, M.L. & WILEY, K.S. (1979), Vascular responsiveness to norepinephrine, serotonin and potassium chloride in veins from spontaneously hypertensive and age-matched Wistar Kyoto rats. Clin. Exp. Hypertension 1, 761-778.
65. COLLIER, J.G., NACHEV, C.H. & ROBINSON, B.F. (1972), Comparison of blockade at alpha-adrenoceptors by thymoxamine and phentolamine in peripheral arteries and veins of man. Br. J. Pharmacol. 44, 294-300.
66. COWEN, T. & BURNSTOCK, G. (1980), Quantitative analysis of the density and pattern of adrenergic innervation of blood vessels. Histochemistry 66, 19-34.
67. COWIE, A.T., FORSYTH, I.A. & HART, I.C. (1980), Hormonal Control of Lactation. Springer-Verlag, Berlin.
68. DAHL, E. (1973), The innervation of the cerebral arteries. J. Anat. 115, 53-63.
69. D'ALECY, L.G. & ROSE, C.J. (1977), Parasympathetic cholinergic control of cerebral blood flow in dogs. Circ. Res. 41, 324-331.

70. DALY, M.J. (1981), The classification of beta-adrenoceptors 1. TIPS 2, 168-169.
71. DARKE, A.C. & SMAJE, L.H. (1972), Dependence of functional vasodilatation in the cat submaxillary gland upon stimulation frequency. J. Physiol. (Lond.) 226, 191-203.
72. DAVIES, D.V. & DAVIES, F. (1964), Gray's Anatomy. Longmans, London.
73. DAVIS, A.J., FLEET, I.R., GOODE, J.A., HAMON, M.H., MAULE WALKER, F.M. & PEAKER, M. (1979), Changes in mammary function at the onset of lactation in the goat; correlation with hormonal changes. J. Physiol. 288, 33-44.
74. DE CHAMPLAIN, J., COUSINEAU, D. & LAPOINTE, L. (1978), The role of the sympathetic system in the maintenance of human hypertension. Clin. Invest. Med. 1, 123-128.
75. DEMEY, J.G. & VANHOUTTE, P.M. (1980), Comparison of the responsiveness of cutaneous veins of dog and rabbit to adrenergic and cholinergic stimulation. Blood Vessels 17, 27-43.
76. DEPARTMENT OF HEALTH AND SOCIAL SECURITY STATISTICS (1980), Health and Personal Social Services Statistics for England (with summary tables for Great Britain) 1978, pp. 191-193. HMSO, London.
77. DREW, G.M. (1981), Pre- and post-junctional alpha-adrenergic receptors in the blood vessel wall. In: Vasodilatation, edited by P.M. Vanhoutte and I. Leusen, pp. 85-96. Raven Press, New York.

78. DREW, G.M. & SULLIVAN, A.T. (1980), Effects of alpha-adrenoceptor agonists and antagonists on adrenergic neurotransmitter overflow from dog isolated saphenous veins. Br. J. Pharmacol. 68, 139-140.
79. DUCKLES, S.P. (1981), Vasodilator innervation of cerebral blood vessels. In: Vasodilatation, edited by P.M. Vanhoutte and I. Leusen, pp. 27-38. Raven Press, New York.
80. DUFF, F., GREENFIELD, A.D.M., SHEPHERD, J.T. & THOMPSON, I.D. (1953), A quantitative study of the response to acetylcholine and histamine of the blood vessels of the human hand and forearm. J. Physiol. (Lond.) 120, 160-170.
81. DUFF, F., PATTERSON, G.C. & SHEPHERD, J.T. (1954), A quantitative study of the response to adenosine triphosphate of the blood vessels of the human hand and forearm. J. Physiol. (Lond.) 125, 581-589.
82. DUNCAN, C.P. & SHIM, S.S. (1977), The autonomic nerve supply of bone. An experimental study of the intraosseous adrenergic nervi vasorum in the rabbit. J. Bone J. Surg. 59B, 323-330.
83. ECKSTEIN, J.W. & HAMILTON, W.K. (1957), The pressure-volume responses of human forearm veins during epinephrine and norepinephrine infusions. J. Clin. Invest. 36, 1663-1671.
84. EDHOLM, O.G., FOX, R.A. & MACPHERSON, R.K. (1957), Vasomotor control of the cutaneous blood vessels in the human forearm. J. Physiol. (Lond.) 139, 455-465.

85. EDVINSSON, L. & KRAUSE, D.N. (1979), Pharmacological characterization of GABA receptors mediating vasodilatation of cerebral arteries in vitro. Brain Res. 173, 89-97.
86. EDVINSSON, L., KRAUSE, D.N., LARSSON, B. & SKÄRBY, T. (1980), GABA dilates cerebral arteries in vitro and increases regional cerebral blood flow in vivo. Brain Res. Bull. 5, 335-339.
87. EDVINSSON, L. & ÖWMAN, C. (1980), Noradrenaline and the cerebral circulation. In: Cerebral Circulation and Neurotransmitters, edited by A. Bes and G. Géraud, pp. 149-156. Excerpta Medica, Amsterdam.
88. EDVINSSON, L., ÖWMAN, C. & SJOBERG, N.-O. (1976), Autonomic nerves, mast cells, and amine receptors in human brain vessels. A histochemical and pharmacological study. Brain Res. 115, 377-393.
89. EHINGER, B. & FALCK, B. (1966), Concomitant adrenergic and parasympathetic fibres in the rat iris. Acta Physiol. Scand. 67, 201-207.
90. EKLUND, B., JOGESTRAND, T. & PERNOW, B. (1977), Effect of substance P on resistance and capacitance vessels in the human forearm. In: Substance P, edited by U.S. Von Euler and B. Pernow, pp. 275-285. Raven Press, New York.
91. EL-BADAWI, A. & SCHENK, E.A. (1967), Histochemical methods for separate, consecutive and simultaneous demonstration of acetylcholinesterase and norepinephrine in cryostat sections. J. Histochem. Cytochem. 15, 580-588.

92. EL-RAKHAWY, M.T. & BOURNE, G.H. (1960), Cholinesterases in the human tongue. Bibl. Anat. 2, 243-255.
93. ENERBÄCK, L. & HÄGGENDAL, J. (1970), Uptake and storage of catecholamines in mucosal mast cells of the rat. J. Histochem. Cytochem. 18, 803-811.
94. ERÄNKÖ, O. (1967), The practical histochemical demonstration of catecholamines by formaldehyde-induced fluorescence. J. Royal Microscop. Soc. 87, 259-276.
95. ERICI, I., FOLKOW, B. & UVNÄS, B. (1952), Sympathetic vasodilator nerves to the tongue of the cat. Acta Physiol. Scand. 25, 1-14.
96. ESLER, M., LEONARD, P., KELLEHER, D., JACKMAN, G., BOBIK, A., SKEWS, H., JENNINGS, G. & KORNER, P. (1980), Assessment of neuronal uptake of noradrenaline in humans: defective uptake in some patients with essential hypertension. Clin. Exp. Pharmac. Physiol. 7, 535-539.
97. FAGARD, R., AMERY, A., REYBROUCK, T., LIJNEN, P. & BILLIET, L. (1979), Response of the systemic and pulmonary circulation to alpha- and beta-receptor blockade (labetalol) at rest and during exercise in hypertensive patients. Circulation 60, 1214-1219.
98. FALCK, B. (1962), Observations on the possibilities of the cellular localization of monoamines by a fluorescence method. Acta Physiol. Scand. 56, Suppl. 197.

99. FALCK, B., HILLARP, N.-A., THIEME, G. & TORP, A. (1962), Fluorescence of catecholamines and related compounds condensed with formaldehyde. J. Histochem. Cytochem. 10, 348-354.
100. FALCK, B. & OWMAN, C. (1965), A detailed methodological description of the fluorescence method for the cellular demonstration of biogenic monoamines. Acta Univ. Lund. Sect. II, 7, 5-23.
101. FAY, F.S (1971), Guinea-pig ductus arteriosus. Cellular and metabolic basis for oxygen sensitivity. Am. J. Physiol. 221, 470-479.
102. FEHER, E. & VAJDA, J. (1976), Selective sympathetic denervation induced by 6-hydroxydopamine in the small intestine. Acta Morphol. Acad. Sci. Hung. 24, 121-128.
103. FEIGL, E.O. (1969), Parasympathetic control of coronary blood flow in dogs. Circ. Res. 25, 509-519.
104. FISHER, A.W.F. (1965), The intrinsic innervation of the pulmonary vessels. Acta Anat. 60, 481-496.
105. FITZGERALD, G.A. (1979), Neurogenic aspects of essential hypertension in man. Ir. J. Med. Sci. 148, 280-289.
106. FITZPATRICK, T.M., ALTER, I., COREY, E.J., RAMWELL, P.W., ROSE, J.C. & KOT, P.A. (1978), Cardiovascular responses to PGI₂ in the dog. Circ. Res. 42, 192-194.

107. FLUMERFELT, B.A., LEWIS, P.R. & GWYN, D.G. (1973), Cholinesterase activity of capillaries in the rat brain. A light and electron microscopic study. Histochem. J. 5, 67-77.
108. FOLKOW, B., HAEGER, K. & UVNÄS, B. (1948), Cholinergic vasodilator nerves in the sympathetic outflow to the muscles of the hind limbs of the cat. Acta Physiol. Scand. 15, 401-411.
109. FOLKOW, B., HALLBACK, M., LUNDGREN, Y. & WEISS, L. (1972), The effects of 'immunosympathectomy' on blood pressure and vascular 'reactivity' in normal and spontaneously hypertensive rats. Acta Physiol. Scand. 84, 512-523.
110. FORRESTER, T., HARPER, A.M., MACKENZIE, E.T. & THOMSON, E.M. (1979), Effect of ATP and some derivatives on cerebral blood flow and metabolism. J. Physiol. (Lond.) 296, 343-355.
111. FOX, R.H. & EDHOLM, O.G. (1963), Nervous control of the cutaneous circulation. Brit. Med. Bull. 19, 110-114.
112. FOX, R.M. & HILTON, S.M. (1958), Bradykinin formation in human skin as a factor in heat vasodilatation. J. Physiol. (Lond.) 142, 219-232.
113. FREDHOLM, B.B. (1981), Sources and actions of dopamine. In: Vasodilatation, edited by P.M. Vanhoutte and I. Leusen, pp. 117-130. Raven Press, New York.
114. FUJIWARA, M., MURAMATSU, I. & SHIBATA, S. (1975), Gamma-aminobutyric acid receptor on vascular smooth muscle of dog cerebral arteries. Brit. J. Pharmacol. 55, 561-562.

115. FURCHGOTT, R.F. (1976), Postsynaptic adrenergic receptor mechanisms in vascular smooth muscle. In: Vascular Neuroeffector Mechanisms, pp, 131-142. Karger, Basel.
116. FURCHGOTT, R.F. (1981), The requirement for endothelial cells in the relaxation of arteries by acetylcholine and some other vasodilators. TIPS 2, 173-176.
117. FURCHGOTT, R.F. & ZAWADZKI, J.V. (1980), The obligatory role of endothelial cells in the relaxation of arterial smooth muscle by acetylcholine. Nature 288, 373-376.
118. FURCHGOTT, R.F., ZAWADZKI, J.V. & CHERRY, P.D. (1981), Role of endothelium in the vasodilator response to acetylcholine. In: Vasodilatation, edited by P.M. Vanhoutte and I. Leusen, pp. 49-66. Raven Press, New York.
119. FURNESS, J.B. (1973), Arrangement of blood vessels and their relation with adrenergic nerves in the rat mesentary. J. Anat. 115, 347-364.
120. GABELLA, G. (1981), Structure of muscles and nerves in the gastrointestinal tract. In: Physiology of the Gastrointestinal Tract, edited by L.R. Johnson, pp. 197-239. Raven Press, New York.
121. GARRETT, J.R. (1963), The ultrastructure of intracellular fat in the parenchyma of human submandibular salivary glands. Arch. Oral Biol. 8, 729-734.

122. GARRETT, J.R. (1967), The innervation of normal human submandibular and parotid salivary glands. Arch. Oral Biol. 12, 1417-1436.
123. GARRETT, J.R., HOWARD, E.R. & JONES, W. (1974), The internal anal sphincter in the cat: a study of nervous mechanisms affecting tone and reflex activity. J. Physiol. (Lond.) 243, 153-166.
124. GARRETT, J.R. & KEMPLAY, S.K. (1977), The adrenergic innervation of the submandibular gland of the cat and the effects of various surgical denervations on these nerves. A histochemical and ultrastructural study including the use of 5-hydroxydopamine. J. Anat. 124, 99-115.
125. GINSBURG, M. & GRAYSON, J. (1954), Factors controlling liver blood flow in the rat. J. Physiol. (Lond.) 123, 574-602.
126. GOTTLIEB, A.L., LIPPON, H.L., PAREY, S.E., PAUSTIAN, P.W. & KADOWITZ, P.J. (1980), Blockade of vasoconstrictor responses by prostacyclin (PGI₂), PGE₂ and PGE₁ in the rabbit hindquarters vascular bed. Prostaglandins and Medicine 4, 1-11.
127. GRAHAM, B.H. & LIOY, F. (1973), Histaminergic vasodilatation in the hindlimb of the dog. Pflugers Arch. 342, 307-318.
128. GRAYSON, J. & JOHNSON, D.H. (1953), The effect of adrenaline and noradrenaline on the liver blood flow. J. Physiol. (Lond.) 120, 73-94.
129. GREGA, G.J., DAUGHERTY, R.M., SCOTT, J.B., RADAWSKI, D.P. & HADDY, F.J. (1971), Effect of pressure, flow and vasoactive agents on vascular resistance and capillary filtration in canine fetal, newborn and adult lung. Microvasc. Res. 3, 297-307.

130. GREGORY, P.C., BOISVERT, D.P.J. & HARPER, A.M. (1980), Adenosine response on pial arteries, influence of CO₂ and blood pressure. Pflugers Arch. 386, 187-192.
131. GRIGOR'EVA, T.A. (1962), The Innervation of Blood Vessels. Pergamon Press, Oxford.
132. GROSS, P.M., HEISTAND, D.D. & MARCUS, M.L. (1979), Neurohumoral regulation of blood flow to bones and marrow. Am. J. Physiol. 237, H440-H448.
133. GROVER-JOHNSON, N. & PEARSON, J. (1976), Deficient vascular innervation in familial dysautonomia, an explanation for vasomotor instability. Neuropath. and App. Neurobiol. 2, 217-224.
134. HALL, J.E., MORSE, C.L., SMITH, M.J., YOUNG, D.B. & GUYTON, A.C. (1980), Control of arterial pressure and renal function during glucocorticoid excess in dogs. Hypertension 2, 139-148.
135. HALLBERG, D. & PERNOW, B. (1975), Effect of substance P on various vascular beds in the dog. Acta Physiol. Scand. 93, 277-285.
136. HANWELL, A. & LINZELL, J.L. (1972), Elevation of the cardiac output in the rat by prolactin and growth hormone. J. Endocr. 53, Ivii-Iviii.
137. HANWELL, A. & LINZELL, J.L. (1973a), The time course of cardiovascular changes in lactation of the rat. J. Physiol. (Lond.) 233, 93-109.

138. HANWELL, A. & LINZELL, J.L. (1973b), The effects of engorgement with milk and of suckling on mammary blood flow in the rat. J. Physiol. (Lond.), 233, 111-125.
139. HANWELL, A. & PEAKER, M. (1977), Physiological effects of lactation on the mother. Symp. Zool. Soc. Lond. 41, 297-312.
140. HARDEBO, J.E., EDVINSSON, L., FALCK, B., LINDVALL, M., OWMAN, C., ROSENGREN, E. & SVENGAARD, N.-Aa. (1976), Experimental models for histochemical and chemical studies of the enzymatic blood-brain barrier for amine precursors. In: The Cerebral Vessel Wall, edited by J. Cervós-Navano, E. Betz, F. Matakas and R. Wullenweber, pp. 233-244. Raven Press, New York.
141. HARDWICK, D.C. & LINZELL, J.L. (1960), Some factors affecting milk secretion by the isolated perfused mammary gland. J. Physiol. (Lond.) 154, 547-571.
142. HEBB, C. (1969), Motor innervation of the pulmonary blood vessels of mammals. In: The Pulmonary Circulation and Interstitial Space, edited by A.P. Fishman and H.H. Hecht, pp. 195-222. University of Chicago Press, Chicago.
143. HEBB, C.O. & LINZELL, J.L. (1951), Some conditions affecting the blood flow through the perfused mammary gland with special reference to the action of adrenaline. Q. J. Exp. Physiol. 36, 159-175.

144. HEBB, C. & LINZELL, J.L. (1970), Innervation of the mammary gland. A histochemical study in the rabbit. Histochem. J. 2, 491-505.
145. HEDQVIST, P. (1977), Basic mechanisms of prostaglandin action on autonomic neuro-transmission. Ann. Rev. Pharmacol. Toxicol. 17, 259-279.
146. HEIDENHAIN, R. (1872), Ueber die wirkung einiger gifte auf die nerven der glandula submaxillaris. Pflugers Arch. ges. Physiol. 5, 309-318.
147. HENRICH, H. & EDER, M. (1979), Sympathetic-adrenergic regulation of the microvasculature in spontaneously hypertensive rats. Bibl. Anat. 18, 187-189.
148. HERXHEIMER, A. (1960), The autonomic innervation of the skin. In: Advances in Biology of Skin I. Cutaneous Innervation, edited by W. Montagna, pp. 63-73. Pergamon Press, New York.
149. HICKSON, J.C.D. (1970), The secretion of pancreatic juice in response to stimulation of the vagus nerves in the pig. J. Physiol. (Lond.) 206, 275-297.
150. HIGGINS, J.A. & BARNETT, R.J. (1971), Fine structural localization of acyltransferases. J. Cell. Biol. 50, 102-120.
151. HIGGINS, J.C. & EADY, R.A.J. (1981), Human dermal microvasculature: I Its segmental differentiation. Light and electron microscopic study. Brit. J. Dermatol. 104, 117-129.

152. HILLIER, K. & KARIM, S.M.M. (1968), Effects of prostaglandin E_1 , E_2 , $F_{1\alpha}$, $F_{2\alpha}$ on isolated human umbilical and placental blood vessels. J. Obstet. Gynaec. Brit. Cwlth. 75, 667-673.
153. HILTON, S.M. & LEWIS, G.P. (1955a), The cause of the vasodilatation accompanying activity in the submandibular salivary gland. J. Physiol. (Lond.) 128, 235-248.
154. HILTON, S.M. & LEWIS, G.P. (1955b), The mechanism of the functional hyperaemia in the submandibular salivary gland. J. Physiol. (Lond.) 129, 253-271.
155. HILTON, S.M. & LEWIS, G.P. (1956), The relationship between glandular activity, bradykinin formation and functional vasodilatation in the submandibular salivary gland. J. Physiol. (Lond.) 134, 471-483.
156. HIRST, G.D.S., NEILD, T.O. & SILVERBERG, G.D. (1982), Noradrenaline receptors on the rat basilar artery. J. Physiol. (Lond.) 328, 351-360.
157. HOKFELT, T. (1967), On the ultrastructural localization of noradrenaline in the central nervous system of the rat. Z. Zellforsch 79, 110-117.
158. HOLROYDE, M.C. & EYRE, P. (1975), Reactivity of isolated bovine mesenteric and hepatic veins to vasoactive agents and specific antigen. Eur. J. Pharmacol. 30, 36-42.
159. HOLTON, P. & RAND, M.J. (1962), Sympathetic vasodilatation in the rabbit ear. Brit. J. Pharmacol. 19, 513-526.

160. HONG TAI ENG, F.W., HUBER-SMITH, M. & McCANN, D.S. (1980), The role of sympathetic activity in normal renin essential hypertension. Hypertension 2, 14-19.
161. HOPE, W., MAJEWSKI, H., McCULLOCH, M.W., RAND, M.J. & STORY, D.F. (1980), Evidence for a modulatory role of dopamine in sympathetic transmission. Circ. Res. 46, Suppl. 1, 77-79.
162. HURLEY, H.A. & MESCON, H. (1956), Cholinergic innervation of the digital arteriovenous anastomoses of human skin. A histochemical localization of cholinesterase. J. Appl. Physiol. 9, 82-84.
163. IIJIMA, T. (1977), A histochemical study of the innervation of cerebral blood vessels in the turtle. J. Comp. Neurol. 176, 307-313.
164. ITAKURA, T., YAMAMOTO, K., TOHYAMA, M. & SHIMIZU, N. (1977), Central dual innervation of arterioles and capillaries in the brain. Stroke 8, 360-365.
165. IWAYAMA, T., FURNESS, J.B. & BURNSTOCK, G. (1970), Dual adrenergic and cholinergic innervation of the cerebral arteries of the rat. An ultrastructural study. Circ. Res. 26, 635-646.
166. JACOBOWITZ, D. & KOELLE, G.B. (1965), Histochemical correlations of acetylcholinesterase and catecholamines in postganglionic autonomic nerves of the cat, rabbit and guinea-pig. J. Pharmacol. Exp. Ther. 148, 225-237.
167. JENKINSON, D.M. & BLACKBURN, P.S. (1967), The distribution of nerves, monoamine oxidase and cholinesterase in the skin of the sheep and goat. J. Anat. Lond. 101, 333-341.

168. JENKINSON, D.M., SENGUPTA, B.P. & BLACKBURN, P.S. (1966), The distribution of nerves, monoamine oxidase and cholinesterase in the skin of cattle. J. Anat. 100, 593-613.
169. JOHANSSON, O. & LUNDBERG, J.M. (1981), Ultrastructural localization of VIP-like immunoreactivity in large dense-core vesicles of 'cholinergic-type' nerve terminals in cat exocrine glands. Neuroscience 6, 847-862.
170. JOHNSON, J.M. & PARK, M.K. (1979), Reflex control of skin blood flow by skin temperature: role of core temperature. J. Appl. Physiol. 47, 1188-1193.
171. JONASON, J. (1969), Effects of reserpine on the noradrenaline content of atrophied rat salivary glands. Acta Physiol. Scand. 75, 73-77.
172. JONES, C.J. (1978), Vascular innervation in the rat submandibular gland. J. Physiol. (Lond.) 289, 25-26P.
173. JONES, C.J. (1979a), Perivascular nerves in the rat submandibular salivary gland. Neurosci. Lett. 13, 19-23.
174. JONES, C.J. (1979b), An investigation of vascular structure and organisation in invasive ductal carcinoma of the breast. Report of a pilot study submitted to the North of England Cancer Research Campaign.

175. JONES, C.J. (1980), Differences in periarteriolar innervation between the rat submandibular and major sublingual glands. J. Physiol. (Lond.) 301, 61P-62P.
176. JONES, C.J. (in press), Autonomic nerves and the control of blood flow. In: Blood Flow: Theory and Practice, edited by D.E.M Taylor, pp. 267-286. Academic Press, London.
177. JONES, C.J. & KENDALL, J.E. (1980), An ultrastructural study of arterioles in human breast biopsy specimens. Microvasc. Res. 20, 253.
178. JONES, C.J. & KENDALL, J.E. (1981), An ultrastructural study of human arterioles with particular reference to their innervation. Microvasc. Res. 22, 235.
179. JONES, C.J. & MANN, G.E. (1975), Involvement of cAMP in nerve-mediated vasodilatation in cat submandibular gland. J. Physiol. (Lond.) 256, 92-93P.
180. JONES, C.J. & MANN, G.E. (1977), A possible role for adenosine 3':5'-cyclic monophosphate in nerve mediated vasodilatation. Biochem. Soc. Tran. 5, 428-429.
181. JONES, C.J., MANN, G.E. & SMAJE, L.H. (1980), The role of cyclic nucleotides and related compounds in nerve-mediated vasodilatation in the cat submandibular gland. Br. J. Pharmac. 68, 485-497.
182. JOYNER, W.L., SVENSJO, E. & ARFORS, K.E. (1979), Simultaneous measurements of macromolecule leakage and arteriolar blood flow as altered by PGE₁ and beta₂-receptor stimulant in the hamster cheek pouch. Microvasc. Res. 18, 301-310.

183. JUDY, W.V., WATANABE, A.M., HENRY, D.P., BESCH, H.R., MURPHY, W.R. & HOCKEL, G.M. (1976), Sympathetic nerve activity. Role in regulation of blood pressure in the spontaneously hypertensive rat. Circ. Res. 38, Suppl. II, 21-29.
184. KADOWITZ, P.J. & HYMAN, A.L. (1973), Effect of sympathetic nerve stimulation on pulmonary vascular resistance in the dog. Circ. Res. 32, 221-227.
185. KADOWITZ, P.J., JOINER, P.D. & HYMAN, A.L. (1975), Effect of prostaglandin E₂ on pulmonary vascular resistance in intact dog, swine and lamb. Eur. J. Pharmacol. 31, 72-80.
186. KALSNER, S. (1972), Differential activation of the inner and outer muscle cell layers of the rabbit ear artery. Eur. J. Pharmacol. 20, 122-124.
187. KAMM, K.E. & CASTEELS, R. (1979), Activation of contraction of arterial smooth muscle in the presence of nitrate and other anions. " Pflügers Arch. 381, 63-69.
188. KANERVA, L., HERVONEN, A. & GRÖNBLAD, M. (1980), Observations on the ultrastructural localization of monoamines with permanganate fixation. In: Histochemistry and Cell Biology of Autonomic Neurons, SIF cells and Paraneurons, edited by O. Eränkö, S. Soinila and H. Paivarinta, pp. 279-285. Raven Press, New York.

189. KASA, P., MANN, S.P. & HEBB, C. (1970), Localization of choline acetyltransferase. Nature 226, 812-816.
190. KEATINGE, W.R. & HARMAN, M.C. (1980), Local Mechanisms Controlling Blood Vessels. Monographs of the Physiological Society. No. 37. Academic Press, London.
191. KEMPLAY, S. (1980), Inhibition of parasympathetic axonal sprouting in the cat submandibular gland by sympathetic axons. Cell. Tiss. Res. 207, 155-163.
192. KENDALL, J.E. & JONES, C.J. (1982), The use of histochemical techniques to search for periarteriolar nerves in human breast tissue. Microvasc. Res. 23, 394-395.
193. KENDALL, J.E. & JONES, C.J. (in press), The search for periarteriolar nerves in human breast, axillary lymph node and overlying skin. Microvasc. Res.
194. KHAISMAN, E.B. (1975), A histochemical study of vegetative innervation of blood vessels of serosa. Arch. Anat. Mor. Morphol. Exp. 64, 337-358.
195. KIRBY, M.L., MCKENZIE, J.W. & WEIDMAN, T.A. (1980), Developing innervation of the chick heart: a histofluorescence and light microscopic study of sympathetic innervation. Anat. Rec. 196, 333-340.

196. KITAMURA, K. & KURIYAMA, H. (1979), Effects of acetylcholine on the smooth muscle cell of isolated main coronary artery of the guinea-pig. J. Physiol. (Lond.) 293, 119-133.
197. KONIG, R. (1979), Consecutive demonstration of catecholamines and dopamine-beta-hydroxylase within the same specimen. Histochemistry 61, 301-305.
198. KOO, A. & LIANG, I.Y.S. (1979a), Parasympathetic cholinergic vasodilator mechanism in the terminal liver microcirculation in rats. Q. Jl. Exp. Physiol. 64, 149-159.
199. KOO, A. & LIANG, I.Y.S. (1979b), Vagus-mediated vasodilator tone in the rat terminal liver microcirculation. Microvasc. Res. 18, 413-420.
200. KUKLETOVÁ, M., ZAHŘÁDKA, J. & LUKÁŠ, Z. (1968), Monoaminergic and cholinergic nerve fibres in the human dental pulp. Histochemie 16, 154-158.
201. KUSCHINSKY, W. & WAHL, M. (1980), Histamine and cerebral circulation. In: Cerebral Circulation and Neurotransmitters, edited by A. Bes and G. Géraud, pp. 211-216. Excerpta Medica, Amsterdam.
202. KYÖSOLA, K., PARTANEN, S., KORKALA, O., MERIKALLIO, E., PENTTILÄ, O. and SILTANEN, P. (1976), Fluorescence histochemical and electron-microscopical observations on the innervation of the atrial myocardium of the adult human heart. Virchows Arch. A Path. Anat. and Histol. 371, 101-119.

203. LANDS, A.M., ARNOLD, A., McAULIFF, J.P., LUDUENA, F.P. & BROWN, T.G. (1967), Differentiation of receptor systems activated by sympathomimetic amines. Nature 214, 597-598.
204. LANGER, S.Z., BRILEY, M. & DUBOCOVICH, M.L. (1980), Adrenergic receptor mechanisms in the central nervous system in relation to catecholamine neurons. In: Central Adrenaline Neurons. Basic Aspects and their Role in Cardiovascular Functions, edited by K. Fuxe, M. Goldstein, B. Hokfelt and T. Hokfelt, pp. 199-209. Pergamon Press, Oxford.
205. LANGER, S.Z., ENERO, M.A., ADLER-GRASCHINSKY, E., DUBOCOVICH, M.L. and GIORGI, O. (1976), Regulation of transmitter release. In: Vascular Neuroeffector Mechanisms, pp. 112-122. Karger, Basel.
206. LARSEN J.-J., BOECK, V. & OTTESEN, B. (1981), Effect of vasoactive intestinal polypeptide on cerebral blood flow in the goat. Acta Physiol. Scand. 111, 471-474.
207. LARSSON, L.-I. & REHFELD, J.F. (1979), Peptidergic and adrenergic innervation of pancreatic ganglia. Scand.J. Gastroent. 14, 433-437.
208. LEE, G.de J. & RAJAGOPALAN, B. (1981), Pulmonary blood flow. In: Structure and Function of the Circulation. Vol. 2, edited by C.J. Schwartz, N.T. Werthessen & S.Wolf, pp. 363-403. Plenum Press, New York.

209. LEFKOWITZ, R.J. (1980), Radioligand binding studies of adrenergic receptors. In: Central Adrenaline Neurons. Basic Aspects and their Role in Cardiovascular Functions, edited by K. Fuxe, M. Goldstein, B. Hokfelt and T. Hokfelt, pp. 291-301. Pergamon Press, Oxford.
210. LEHMANN, J. & FIBIGER, H.C. (1979), Acetylcholinesterase and the cholinergic neuron. Life Sci. 25, 1939-1947.
211. LEVER, J.D., SPRIGGS, T.L.B. & GRAHAM, J.D.P. (1968), A formol-fluorescence, fine-structural and autoradiographic study of the adrenergic innervation of the vascular tree in the intact and sympathectomised pancreas of the cat. J. Anat. 103, 15-34.
212. LEVY, J.V. (1978), Contractile responses to prostacyclin (PGI₂) of isolated human saphenous and rat venous tissue. Prostaglandins 16, 93-97.
213. LINDVALL, O. & BJÖRKLUND, A. (1974), The glyoxylic acid fluorescence histochemical method: a detailed account of the methodology for the visualization of central catecholamine neurons. Histochemistry 39, 97-127.
214. LINZELL, J.L. (1950), Vasomotor nerve fibres to the mammary glands of the cat and dog. Q. J. Exp. Physiol. 35, 295-319.
215. LINZELL, J.L. (1974), Mammary blood flow and methods of identifying and measuring precursors of milk. In: Lactation - A Comprehensive Treatise, Vol. 1, edited by B.L. Larson and V.R. Smith, pp. 143-225. Academic Press, London.

216. LINZELL, J.L., FLEET, I.R., MEFHAM, T.B. AND PEAKER, M. (1972),
Perfusion of the isolated mammary gland of the goat. Q. J. Exp. Physiol. 57, 139-161.
217. LIPPTON, H.L., CHAPNICK, B.M., HYMAN, A.L. & KADOWITZ, P.J. (1980),
Influence of prostacyclin on sympathetic neurotransmission in the
feline intestinal vascular bed. In: Advances in Prostaglandin and
Thromboxane Research, Vol. 8, edited by B. Samuelsson, P.W. Ramwell
and R. Paoletti. Raven Press, New York.
218. LIPPTON, H.L., PAUSTIAN, P.W., MELLION, B.T., NELSON, P.K., FEIGEN,
L.P., CHAPNICK, B.M., HYMAN, A.L. & KADOWITZ, P.J. (1979),
Cardiovascular actions of prostacyclin (PGI₂) in the cat. Arch. Int.
Pharm. Ther. 241, 121-130.
219. LITTLE, R.C. (1981), Physiology of the Heart and Circulation. Year
Book Medical Publishers, Chicago.
220. LÖFSTROM, B., PERNOW, B. & WAHREN, J. (1965), Vasodilating action
of substance P in the human forearm. Acta Physiol. Scand. 63, 311-324.
221. LOKHANDWALA, M.F. & JANDHYALA, B.S. (1979), Sympathetic nerve
function and renal hemodynamics during hemorrhage: role of pre- and
postsynaptic interactions between angiotensin II and prostaglandins.
J. Pharmacol. Exp. Ther. 211, 539-545.
222. LOSAY, J., MROZ, E.A., TREGGAR, G.W., LEEMAN, S.E. & GAMBLE, W.J.
(1977), Action of substance P on the coronary blood flow in the
isolated dog heart. In: Substance P, edited by U.S. Von Euler and
B. Pernow, pp. 275-285. Raven Press, New York.

223. LUDBROOK, J. (1980), Regulation of arterial blood flow, pressure and resistance in the systemic circulation. In: Structure and Function of Circulation, Vol. 1, edited by C.J. Schwartz, N.T. Werthessen and S. Wolf, pp. 587-630. Plenum Press, New York.
224. LUNDBERG, J.M. (1981), Evidence for coexistence of vasoactive intestinal polypeptide (VIP) and acetylcholine in neurons of cat exocrine glands. Morphological, Biochemical and Functional Studies. Acta Physiol. Scand. Suppl. 496.
225. LUNDVALL, J., HILLMAN, J. & GUSTAFSSON, D. (1981), Beta-adrenergic regulation of the capillary exchange and resistance functions. In: Vasodilatation, edited by P.M. Vanhoutte and I. Leusen, pp. 107-116. Raven Press, New York.
226. MACKENZIE, E.T. & EDVINSSON, L. (1980), Effects of serotonin on cerebral circulation and metabolism as related to cerebrovascular disease. In: Cerebral Circulation and Neurotransmitters, edited by A. Bes and G. Géraud, pp. 163-171. Excerpta Medica, Amsterdam.
227. MANTEL, R., TAQUINI, A.C. & SAVINDO, E.A. (1975), Effects of adrenaline, angiotensin and calcium on spontaneously active and potassium-depolarized rat portal veins. Arch. Int. Physiol. Biochim. 83, 211-219.
228. MARTINEZ, A.E. & ADLER-GRASCHINSKY, E. (1980), Modulatory role of alpha adrenoceptors on the release of (³H) norepinephrine elicited by preganglionic stimulation of the cat superior cervical ganglion. J. Pharmacol. Exp. Ther. 212. 533-535.

229. McCULLOCH, J. (1980), Dopamine and cerebral tissue perfusion. In: Cerebral Circulation and Neurotransmitters, edited by A. Bes and G. Géraud, pp. 157-162. Excerpta Medica, Amsterdam.
230. McGRATH, M.A. (1977), 5-Hydroxytryptamine and neurotransmitter release in canine blood vessels: inhibition by low and augmentation by high concentrations. Circ. Res. 41, 428-435.
231. McGRATH, J.C. (1981), Vascular adrenergic receptors. In: Vasodilatation, edited by P.M. Vanhoutte and I. Leusen, pp. 97-106. Raven Press, New York.
232. MEDGETT, I.C., McCULLOCH, M.W., RAND, M.J. & STORY, D.F. (1980), Facilitation of sympathetic transmission by prejunctional beta-adrenoceptors in cardiac and vascular tissues. Clin. Exp. Pharmacol. Physiol. 7, 573-577.
233. MELANDER, A., LJUNGGREN, J.-G., NORBERG, K. -A., PERSSON, B., ROSENGREN, E., SUNDLER, F., TIBBLIN, S. & WESTGREN, U. (1978), Sympathetic innervation and noradrenaline content of normal human thyroid tissue from fetal, young and elderly subjects. J. Endocrinol. Invest. 2, 175-177.
234. MENA, M.A. & VIDRIO, M. (1979), Reversal of serotonin vasodilatation in the dog external carotid bed by sympathetic denervation. J. Cardiovasc. Pharmacol. 1, 149-154.

235. MICHELSON, K. (1968), Hemodynamics of the bone marrow circulation. Acta Physiol. Scand. 73, 264-280.
236. MILLARD, R.W. & REITE, O.B. (1975), Peripheral vascular response to norepinephrine at temperatures from 2-40°C. J. Appl. Physiol. 38, 26-30.
237. MILLER, M.R. & KASAHARA, M. (1959), The cutaneous innervation of the human female breast. Anat. Rec. 135, 153-157.
238. MIRZOYAN, S.A. & AKORYAN, V.P. (1967), The effect produced by gamma-amino butyric acid on the cerebral circulation and oxygen tension in the brain. Farmakol. i Toksikol.(USSR) 5, 572-574.
239. MOLYNEUX, G.S. & HALES, J.R.S. (1982), The use of ultrastructural and histochemical techniques to correlate sympathetic activity with blood flow through cutaneous arteriovenous anastomoses in conscious sheep. Int. J. Microcirc. Clin. Exp. 1, 41-53.
240. MONTAGNA, W. (1960), Advances in Biology of Skin Vol. 1 Cutaneous Innervation. Pergamon Press, New York.
241. MONTAGNA, W. (1962), The Structure and Function of Skin. Academic Press, New York.
242. MONTAGNA, W. & PARAKKAL, P.F. (1974), The Structure and Function of Skin. Academic Press, London.
243. MORLEY, J., SCHACHTER, M. & SMAJE, L.H. (1966), Vasodilatation in the submaxillary gland of the rabbit. J. Physiol. (Lond.) 187, 595-602.

244. MOTAVKIN, P.A. & OSIPOVA, L.P. (1973), Cholinergic innervation of the human brain arteries. Z. Mikrosk. Anat. Forsch. Leipzig 87, 365-378.
245. NADKARNI, B.B. (1970), Innervation of the human umbilical artery. An EM study. Am. J. Obstet. Gynaecol. 107, 303-312.
246. NAIK, N.T. (1963), Technical variations in Koelle's histochemical method for demonstrating cholinesterase activity. Q. Jl. Micros. Sci. 104, 89-100.
247. NAVARATNAM, V. (1975), The Human Heart and Circulation. Academic Press, London.
248. NAVARATNAM, V. & PALKAMA, A. (1965), Cholinesterases in the walls of the great arterial trunks and coronary arteries. Acta Anat. 60, 445-448.
249. NICKERSON, M. (1977), Adrenoceptors of the cardiovascular system. In: Proceedings of the International Union of Physiological Sciences, Vol. X11, pp. 78-79.
250. NORBERG, K.-A. & OLSON, L. (1965), Adrenergic innervation of the salivary glands in the rat. Z. Zellforsch. 68, 183-189.
251. NORDLING, J. & CHRISTENSEN, B. (1978), Human sympathetic bladder innervation - a morphological investigation. Urol. Int. 33, 359-365.

252. NORDLING, J., CHRISTENSEN, B. & GOSLING, J.A. (1980), Noradrenergic innervation of the human bladder in neurogenic dysfunction. Urol. Int. 35, 188-193.
253. NOSSAL, G.J.V. & ADA, G.L. (1971), Antigens, Lymphoid Cells and the Immune Response. Academic Press, London.
254. NYSTRÖM, B. & OLSON, L. (1973), Adrenergic innervation of human cerebral arteries. Acta Neurochir. (Wein) 29, 260-261.
255. OCHI, J., KONISHI, M., YOSHIKAWA, H. & SANDO, Y. (1968), Fluorescence and electron microscopic evidence for the dual innervation of the iris sphincter muscle of the rabbit. Z. Zellforsch. 91, 90-95.
256. OLESEN, J. (1980), Prostaglandins in cerebral circulation and metabolism. In: Cerebral Circulation and Neurotransmitters, edited by A. Bes and G. Géraud, pp. 233-239. Excerpta Medica, Amsterdam.
257. OLSON, L. (1967), Outgrowth of sympathetic adrenergic neurons in mice treated with a nerve-growth factor (NGF). Z. Zellforsch. 81, 155-173.
258. OLSON, L., ALUND, M. & NORBERG, K. (1976), Fluorescence-microscopical demonstration of a population of gastrointestinal nerve fibres with a selective affinity for quinacrine. Cell Tiss. Res. 171, 407-423.

259. OTTESEN, B. & FAHRENKRUG, J. (1981), Effect of vasoactive intestinal polypeptide (VIP) upon myometrial blood flow in non-pregnant rabbit. Acta Physiol. Scand. 112, 195-201.
260. PACE-ASCIAK, C.R., CARRARA, M.C. & NICOLACU, K.C. (1978), Prostaglandin I₂ has more potent hypotensive properties than prostaglandin E₂ in the normal and spontaneously hypertensive rat. Prostaglandins 15, 999-1003.
261. PACE-ASCIAK, C.R., CARRARA, M.C., RANGARAJ, G. & NICOLAOU, K.C. (1978), Enhanced formation of PGI₂, a potent hypotensive substance, by aortic rings and homogenates of the spontaneously hypertensive rats. Prostaglandins 15, 1005-1012.
262. PEAKER, M. & LINZELL, J.L. (1973), Vasopressin and milk secretion: lack of effect of low doses. J. Endocr. 57, 87-95.
263. PERNOW, B. & ROSELL, S. (1975), Effect of substance P on blood flow in canine adipose tissue and skeletal muscle. Acta Physiol. Scand. 93, 139-141.
264. PETERSEN, W.E. (1942), Effect of certain hormones and drugs on the perfused mammary gland. Proc. Soc. Exp. Biol. Med. 50, 298-300.
265. PHERNETTON, T.M. & RANKIN, J.H.G. (1979), Effect of PGI₂ on ovine maternal and fetal adrenal blood flows. Proc. Soc. Exp. Biol. Med. 162, 324-327.

266. PHIPPS, R.J., RICHARDSON, P.S., CORFIELD, A., GALLAGHER, J.T., JEFFERY, P.K., KENT, P.W. & PASSATORE, M. (1977), A physiological, biochemical and histological study of goose tracheal mucin and its secretion. Phil. Trans. Roy. Soc. Lond. B. 279, 513-540.
267. PICKERING, G. (1974), Hypertension. Causes, Consequences and Management. Churchill Livingstone, Edinburgh.
268. PITTMAN, R.N. (1981), Influence of oxygen lack on vascular smooth muscle contraction. In: Vasodilatation, edited by P.M. Vanhoutte and I. Leusen, pp. 181-191. Raven Press, New York.
269. POLAK, J.M. & BLOOM, S.R. (1978), Peptidergic innervation of the gastrointestinal tract. In: Advances in Experimental Medicine and Biology, Vol. 106, Gastrointestinal Hormones and Pathology of the Digestive System, edited by M. Grossman, V. Speranza, N. Basso and E. Lezoche, pp. 27-49. Plenum Press, New York.
270. POLAK, J.M., BUCHAN, A.M.J., PROBERT, L., TAPIA, F., DE MEY, J. & BLOOM, S.R. (1981), Regulatory peptides in endocrine cells and autonomic nerves. Electron immunocytochemistry. Scand. J. Gastroent. 16 (Suppl. 70), 11-23.
271. POWELL, J.R. (1979), Effects of histamine on vascular sympathetic neuroeffector transmission. J. Pharmacol. Exp. Ther. 208, 360-365.
272. POWELL, J.R. & SHAMEL, L.B. (1979), Characterization of vascular histamine receptors in the rat. Br. J. Pharmacol. 66, 517-520.

273. PUSKA, P., TUOMILEHTO, J., SALONEN, J., NEITTAANHAKI, L., MAKI, J., VIRTAMO, J., NISSINEN, A., KOSKELA, K. & TAKALO, T. (1979), Changes in coronary risk factors during comprehensive five-year community programme to control cardiovascular diseases (North Karelia Project). Brit. Med. J. 2, 1173-1178.
274. RAND, M.J., MAJEWSKI, H., MEDGETT, I.C., McCULLOCH, M.W. & STORY, D.F. (1980), Prejunctional receptors modulating autonomic neuroeffector transmission. Circ. Res. 46, 70-76.
275. REILLY, F.D. & McCUSKEY, R.S. (1976), Neural influences in the humoral regulation of the splenic microvasculature. Microcirculation 1, 356-357.
276. REILLY, F.D. & McCUSKEY, R.S. (1977a), Studies of the hemopoietic micro-environment. VI. Regulatory mechanisms in the splenic microvascular system of mice. Microvasc. Res. 13, 79-90.
277. REILLY, F.D. & McCUSKEY, R.S. (1977b), Studies of the hemopoietic micro-environment. VII. Neural mechanisms in splenic microvascular regulation in mice. Microvasc. Res. 14, 293-302.
278. REILLY, F.D., McCUSKEY, R.S. & MEINEKE, H.A. (1976), Studies of the hemopoietic micro-environment. VIII. Adrenergic and cholinergic innervation of the murine spleen. Anat. Rec. 185, 109-118.
279. REILLY, F.D., McCUSKEY, P.A., MILLER, M.L., McCUSKEY, R.S. & MEINEKE, H.A. (1979), Innervation of the periarteriolar lymphatic sheath of the spleen. Tissue and Cell 11, 121-126.

280. RIOUX, F., GAGNON, G. & REGOLI, D. (1978), Stimulating actions of various prostaglandins and noradrenaline in strips of rabbit renal artery. Can. J. Physiol. Pharmacol. 56, 321-323.
281. ROBINSON, B.F., COLLIER, J.G., KARIM, S.M.M. & SOMERS, K. (1973), Effect of prostaglandins A_1 , A_2 , B_1 , E_2 and $F_{2\alpha}$ on forearm arterial bed and superficial hand veins in man. Clin. Sci. 44, 367-376.
282. RODDIE, I.C., SHEPHERD, J.T. & WHELAN, R.F. (1957), The contribution of constrictor and dilator nerves to the skin during body heating. J. Physiol. (Lond.) 136, 489-497.
283. ROSSONI, R.B., MACHADO, A.B. & MACHADO, C.R.S. (1979), A histochemical study of catecholamines and cholinesterases in the autonomic nerves of the human minor salivary glands. Histochem. J. 11, 661-668.
284. ROWELL, L.B. (1981), Active neurogenic vasodilatation in man. In: Vasodilatation, edited by P.M. Vanhoutte and I. Leusen, pp. 1-18. Raven Press, New York.
285. RUDOLPH, A.M. & HEYMANN, M.A. (1978), Hemodynamic changes induced by blockers of prostaglandin synthesis in the fetal lamb in utero. In: Advances in Prostaglandin and Thromboxane Research, Vol. 4, edited by F. Coceani and P.M. Olley, pp. 231-237. Raven Press, New York.

286. RYAN, T.J. (1973a), Structure, pattern and shape of the blood vessels of the skin. In: The Physiology and Pathophysiology of the Skin, Vol. 2, The Nerves and Blood Vessels, edited by A. Jarrett, pp. 577-651. Academic Press, London.
287. RYAN, T.J. (1973b), Permeability and responses of blood vessels in skin. In: The Physiology and Pathophysiology of the Skin, Vol. 2, The Nerves and Blood Vessels, edited by A. Jarrett, pp. 681-718. Academic Press, London.
288. SANTAMORE, W.P. & WALINSKY, P. (1980), Altered coronary flow responses to vasoactive drugs in the presence of coronary arterial stenosis in the dog. Am. J. Cardiol. 45, 276-285.
289. SCHACHTER, M. & BEILENSON, S. (1968), Mediator of vasodilatation in the submaxillary gland. Fed. Proc. 27, 73-75.
290. SATO, T., SATO, S. & SUZUKI, J. (1980), Correlation with superior sympathetic ganglion and sympathetic nerve innervation of intracranial artery - electron microscopical studies. Brain Res. 188, 33-41.
291. SCHRAUWEN, E. & HOUVENHAGHEL, A. (1980), Substance P: A powerful intestinal vasodilator in the pig. Pflugers Arch. 386, 281-284.
292. SCHWARTZ, J. (1980), Histamine and cerebral circulation. In: Cerebral Circulation and Neurotransmitters, edited by A. Bes and G. Géraud, pp. 217-223. Excerpta Medica, Amsterdam.

293. SEIDEL, C.L. (1981), The arterial wall in hypertension. In: Vasodilatation, edited by P.M. Vanhoutte and I. Leusen, pp 417-427. Raven Press, New York.
294. SHEHADEH, Z., PRICE, W.E. & JACOBSON, E.D. (1969), Effects of vasoactive agents on intestinal blood flow and motility in the dog. Am. J. Physiol. 216, 386-392.
295. SHEPHERD, A.P., MAO, C.C., JACOBSON, E.D. & SHANBOUR, L.L. (1973), The role of cyclic AMP in mesenteric vasodilatation. Microvasc. Res. 6, 332-341.
296. SHIMIZU, T. & TAIRA, N. (1978), Vasodilatation by prostaglandin $F_{2\alpha}$ in the canine tongue through a sympathetic mechanism. Brit. J. Pharmacol. 63, 567-574.
297. SILVER, A. (1974), The Biology of Cholinesterases. Frontiers of Biology Vol. 36, edited by A. Neuberger and E.L. Tatum. North Holland Publishing Company, Amsterdam.
298. SIMEONE, F.A., VINALL, P.E., ALDERMAN, J.L. & IRVIN, J.D. (1979), Role of adrenergic nerves in blood-induced cerebral vasospasm. Stroke 10, 375-380.
299. SINAIKO, A.R., COOPER, M.J. & MIRKIN, B.L. (1980), Effect of neonatal sympathectomy with 6-hydroxydopamine on reactivity of the renin-angiotensin system in spontaneously hypertensive rats. Clin. Sci. 59, 123-129.

300. SINCLAIR, D. (1973), Motor nerves and reflexes. In: The Physiology and Pathophysiology of the Skin, Vol. 2, The Nerves and Blood Vessels, edited by A. Jarrett, pp. 475-508. Academic Press, London.
301. SINTETOS, A.L., BOLGER, P.M. & RAMWELL, P.W. (1979), Effects of prostacyclin on isolated canine renal artery and vein. In: Prostacyclin edited by J.R. Vane and S. Bergstrom. Raven Press, New York.
302. SKINNER, N.S. & WEBSTER, M.E. (1968a), Submaxillary gland blood flow: the role of kinins and beta-adrenergic receptors. Fed. Proc. 27, 76-79.
303. SKINNER, N.S. & WEBSTER, M.E. (1968b), Kinins, beta-adrenergic receptors and functional vasodilatation in the submaxillary gland of the cat. J. Physiol. (Lond.) 195, 505-519.
304. SNELL, R.S. (1958), The histochemical appearances of cholinesterase in the parasympathetic nerves supplying the submandibular and sublingual salivary glands of the rat. J. Anat. 92, 534-543.
305. SNELL, R.S. & GARRETT, J.R. (1957), The distribution of cholinesterase in the submaxillary and sublingual salivary glands of the rat. J. Histochem. Cytochem. 5, 236-245.
306. SPENCER, H. & LEOF, D. (1964), The innervation of the human lung. J. Anat. 98, 599-609.

307. STANTON, P.D. & HINRICHSSEN, C.F.L. (1980), Monoaminergic innervation of the carotid sinus in mammals: a histochemical study. Acta Anat. 108, 34-44.
308. STARKE, K. (1977), Regulation of noradrenaline release by presynaptic receptor systems. Rev. Physiol. Biochem. Pharmacol. 77, 1-124.
309. SU, C. (1978), Purinergic inhibition of adrenergic transmission in rabbit blood vessels. J. Pharmacol. Exp. Ther. 204, 351-361.
310. SU, C. (1980), Potentiative effects of alpha agonistic sympathomimetic amines on vasoconstriction by adrenergic nerve stimulation. J. Pharmacol. Exp. Ther. 215, 377-381.
311. TAGAWA, T., ANDO, K. & WASANO, T. (1979), A histochemical study of the innervation of the cerebral blood vessels in the domestic fowl. Cell Tissus Res. 198, 43-51.
312. TAGAWA, T., ANDO, K., WASANO, T. & IJIMA, T. (1979), A histochemical study on the innervation of cerebral blood vessels in the bullfrog. J. Comp. Neurol. 183, 25-32.
313. TAIRA, N., NARIMATSU, A. & SATOH, S. (1975), Differential block by l-hyoscyanine of the salivary and vascular responses of the dog mandibular gland to prostaglandin F_{2alpha}. Life Sci. 17, 1869-1876.

314. TAKEDA, K. & BUÑAG, R.D. (1980), Chronic propranolol treatment inhibits sympathetic nerve activity and keeps blood pressure from rising in spontaneously hypertensive rats. Hypertension 1, 228-235.
315. TEMPLETON, D. & THULIN, A. (1978), Secretory, motor and vascular effects in the sublingual gland of the rat caused by autonomic nerve stimulation. Q. Jl. Exp. Physiol. 63, 59-66.
316. THOMAS, D.J. & BANNISTER, R. (1980), Preservation of autoregulation of cerebral blood flow in autonomic failure. J. Neurol. Sci. 44, 205-212.
317. THULIN, A. (1976), Blood flow changes in the submaxillary gland of the rat on parasympathetic and sympathetic nerve stimulation. Acta Physiol. Scand. 97, 104-109.
318. TODD, M.E. (1980), Development of adrenergic innervation in rat peripheral vessels: a fluorescence microscopic study. J. Anat. 131, 121-133.
319. TRANZER, J.P. & RICHARDS, J.G. (1976), Ultrastructural cytochemistry of biogenic amines in nervous tissue: methodological improvements. J. Histochem. Cytochem. 24, 1178-1193.
320. TRIPP, M.E., HEYMANN, M.A. & RUDOLPH, A.M. (1978), Hemodynamic effects of PGE₁ on lambs in utero. In: Advances in Prostaglandin and Thromboxane Research, Vol. 4, edited by F. Coceani and P.M. Olley, pp. 221-229. Raven Press, New York.

321. TSUBOKAWA, T., KATAYAMA, Y., KONDO, T., UENO, Y., HAYASHI, N. & MORIYASU, N. (1980), Changes in local cerebral blood flow and neuronal activity during sensory stimulation in normal and sympathectomized cats. Brain Res. 190, 51-64.
322. TUCH, K. & MATTHIESEN, Th. (1980), A fluorescent histochemical investigation of the rat submandibular gland after ligation of the excretory duct and isoproterenol treatment. Exp. Path. 18, 360-365.
323. UDDMAN, R., ALUMETS, J., EDVINSSON, L., HAKANSON, R. & SUNDLER, F. (1981), VIP nerve fibres around peripheral blood vessels. Acta Physiol. Scand. 112, 65-70.
324. VAALASTI, A. & HERVONEN, A. (1980), Autonomic innervation of the human prostate. Invest. Urol. 17, 293-297.
325. VANHOUTTE, P.M. & VERBEUREN, T.J. (1976), Inhibition by acetylcholine of the norepinephrine release evoked by potassium in canine saphenous veins. Circ. Res. 39, 263-269.
326. VORHERR, H. (1971), Catecholamine antagonism to oxytocin-induced milk-ejection. Acta Endocrinol. Suppl. 154.
327. VORHERR, H. (1974), The Breast. Morphology, Physiology and Lactation. Academic Press, London.

328. VORHERR, H. (1978), Human lactation and breast feeding. In: Lactation - A Comprehensive Treatise, Vol. IV, edited by B.L.Larson, pp. 181-280. Academic Press, London.
329. WALKER, A.R.P., SEGAL, I., GILAT, T. & HOROWITZ, C. (1980), Excessive proneness of Jews to ischaemic heart and bowel diseases. Am. Heart J. 99, 130.
330. WASANO, T. & IIJIMA, T. (1979), A histochemical study on the innervation of the cerebral blood vessels in the carp. Experientia 35, 1235-1236.
331. WATANABE, T. & YASUDA, M. (1977), Electron microscopic study on the innervation of the pancreas of the domestic fowl. Cell Tissue Res. 180, 453-465.
332. WATTS, R.P. & JOHNSON, P.C. (1981), Metabolism and vasodilatation. In: Vasodilatation, edited by P.M. Vanhoutte and I. Leusen, pp. 175-179. Raven Press, New York.
333. WEINER, N. (1980), The role of cyclic nucleotides in the regulation of neurotransmitter release from adrenergic neurons by neuromodulators. In: Essays in Neurochemistry and Neuropharmacology, Vol. 4, edited by M.B.H. Youdim, W. Lovenberg, D.F. Sharman and J.R. Lagnado, pp. 69-124. John Wiley & Sons Ltd., New York.
334. WEISS, L. & GREEP, R.O. (1977), Histology. McGraw, New York.

335. WEISS, R.A. & ROOT, W.S. (1959), Innervation of the vessels of the marrow cavity of certain bones. Am. J. Physiol. 197, 1255-1257.
336. WENNMALM, A. (1977), Differentiation of vasoconstrictor sensitivity caused by PGE₁ in peripheral vascular beds of the rabbit. Acta Physiol. Scand. 100, 115-121.
337. WESTFALL, T.C. (1977), Local regulation of adrenergic neurotransmission. Phys. Rev. 57, 659-728.
338. WESTFALL, T.C. (1980), Neuroeffector mechanisms. Ann. Rev. Physiol. 42, 383-397.
339. WHARTON, J., POLAK, J.M., BRYANT, M.G., VAN NOORDEN, S., BLOOM, S.R. & PEARSE, A.G.E. (1979), Vasoactive intestinal polypeptide (VIP)-like immunoreactivity in salivary glands. Life Sci. 25, 273-280.
340. WORLD HEALTH STATISTICS ANNUAL (1979), Vital Statistics and Causes of Death. World Health Organisation, Geneva.
341. YAMORI, Y., YAMABE, H., DE JONG, W., LOVENBERG, W. & SJOERDSMA, A. (1972). Effect of tissue norepinephrine depletion by 6-hydroxydopamine on blood pressure in spontaneously hypertensive rats. Eur. J. Pharmacol. 17, 135-140.
342. YLIKOSKI, J., PARTANEN, S. & PALVA, T. (1979), Adrenergic innervation of blood vessels. A fluorescence microscopic study of the eighth nerve and inner ear structures in man. Arch. Otolaryngol. 105, 726-729.

343. ZEPPA, R. (1969), Vascular response of the breast to estrogen. J. Clin. Endocrin. 29, 695-700.
344. ZIMMERMAN, B.G., DUNHAM, E.W. & SUGAWARA, K. (1982), Prostaglandins and the cutaneous vasculature. In: Prostaglandins, edited by S. Greenberg, P.J. Kadowitz and T.F. Burks, pp. 91-105. Marcel Dekker, New York.
345. ZUBANOV, V.P., MOSHKIN, M.P., MALIKOV, N.V. & KOROBETSKII, A.A. (1979), Estimating vascular reactivity by iontophoretic injection of vasoactive agents. Hum. Physiol. 5, 252-254.

