

Durham E-Theses

The role of steroid hormones in the differentiation of the gonads of the clawed toad, Xenopus laevis Daudin

Gabriel Gabriel

How to cite:

Gabriel, Gabriel (1981) The role of steroid hormones in the differentiation of the gonads of the clawed toad, *Xenopus laevis* Daudin. Doctoral thesis, Durham University.

Use policy

The full-text may be used and/or reproduced, and given to third parties in any format or medium, without prior permission or charge, for personal research or study, educational, or not-for-profit purposes provided that:

- a full bibliographic reference is made to the original source
- a <https://etheses.durham.ac.uk/id/eprint/7645/> is made to the metadata record in Durham E-Theses
- the full-text is not changed in any way

The full-text must not be sold in any format or medium without the formal permission of the copyright holders.

Please consult the [full Durham E-Theses policy](#) for further details.

The role of steroid hormones in the differentiation of the
gonads of the clawed toad, *Xenopus laevis* Daudin.

by

Gabriel Gabriel
B.Sc., M.Sc. London

The copyright of this thesis rests with the author.
No quotation from it should be published without
his prior written consent and information derived
from it should be acknowledged.

..... being a thesis presented in candidature
for the degree of Doctor of Philosophy
in the University of Durham,

1981

VOLUME 2



TABLE OF CONTENTS

	<u>page no.</u>
Abbreviations	1
Hind limb development in larva PLATE I-II	2-3
Gonadal and Interrenal development of larva PLATE III-XIV	4-15
Gonadal ultrastructure PLATE XV-XVIII	16-19
Treatment for 26 days (st.50 till 56) with 25, 100 and 500µg/l 17β-oestradiol respectively PLATE XIX-XX	20-21
Treatment with 2mg/l oestradiol (st.51 till 57) PLATE XXI-XXV	22-26
Effect of the high dose oestradiol treatment on the larval body (teratogenic effects) PLATE XXVI-XXVIII	27-29
Treatment for 26 days (st.51 till 57) with 25, 100, 500µg/l and 2mg/l of β-oestradiol-3- benzoate respectively. PLATE XXIX-XXXV	30-36
Treatment for 26 days (st.51-57) with 25, 100 and 500µg/l hexestrol respectively PLATE XXXVI-XL	37-41
Treatment for 26 days (st.50-56) with 25, 100 and 500µg/l progesterone respectively PLATE XLI-XLIII	42-44
Treatment for 26 days (st.51-57) with 25, 100, 500µg/l and 2mg/l testosterone acetate respectively PLATE XLIV-XLIX	45-50
Treatment for 26 days (st.51-57) with 25, 100, 500µg/l and 2mg/l 5α-dihydrotestosterone respectively PLATE L-LVII	51-58
Treatment for 26 days (st.51-57) with 25, 100, 500µg/l and 2mg/l cortisone respectively PLATE LVIII-LXII	59-63
Tissue culture of gonads:-	
Gonads maintained <u>in vitro</u> for 12 days with no hormone added PLATE LXIII-LXV	64-66
Gonads maintained <u>in vitro</u> for 12 days and treated with oestradiol PLATE LXVI	67

Toad ovary, 12 months old, treated <u>in vitro</u> with oestradiol for 15 days PLATE LXVIII	69
Testis of 12 month old toad <u>in vivo</u> PLATE LXIX	70
Testis of 12 month old toad <u>in vitro</u> for 15 days and treated with oestradiol PLATE LXX	71
Treatment with antibiotic with and without oestradiol:-	
Alcohol treated and oestradiol treated controls PLATE LXXI-LXXII	72-73
Treatment with antibiotic PLATE LXXIII	74
Simultaneous administration of oestradiol and antibiotic PLATE LXXIV	75
Demonstration of Δ^5 - 3β HSDH activity PLATE LXXV-LXXVIII	76-80
Demonstration of Δ^5 - 3β -HSDH activity in a late stage of tadpole of <u>Rana catesbeiana</u> PLATE LXXIX	81
Effect on Δ^5 - 3β -HSDH activity of 26 day treatment with 2mg/l oestradiol PLATE LXXX	82
Demonstration of Δ^5 - 3β -HSDH activity in the gonads and interrenals of 2 year old toads PLATE LXXXI-LXXXII	83-84
Demonstration of G-6-PO ₄ DH activity PLATE LXXXIII	85
Effect of 26 day treatment with 2mg/l oestradiol on G-6-PO ₄ DH activity PLATE LXXXIV	86
Demonstration of enzyme activity in the duodenum of tadpole PLATE LXXXV	87
Demonstration of enzyme activity in 2 year old adult toad. PLATE LXXXVI	88
Demonstration of lipid material with Sudan Black B PLATE LXXXVII-LXXXIX	89-91

	<u>page no.</u>
St.56 larvae raised in 400ml of water with 15 μ Ci of 6,7- ³ H -oestradiol. PLATE XC	92
Injection of 5 μ Ci/10 μ l/st.56 larva 6,7- ³ H -oestradiol PLATE XCI	93
Ag grains in the liver after injection of 5 μ Ci/10 μ l/larva 6,7- ³ H -oestradiol PLATE XCII	94
Distribution of injected 6,7- ³ H -oestradiol (5 μ Ci/10 μ l/st.57 larva) following 26 days pretreatment with cold oestradiol PLATE XCIII	95
Distribution of injected 5,6- ³ H -uridine (5 μ Ci/10 μ l/st.56 larva) following 26 days pretreatment with cold oestradiol. PLATE XCIV-XCVII	96-99
Injected 6,7- ³ H -oestradiol (5 μ Ci/10 μ l/juvenile) in 7 month old <u>Xenopus</u> PLATE XCVIII-XCIX	100-101
Injected 1,2,6,7- ³ H -progesterone in larvae (5 μ Ci/10 μ l/st.56 larva) PLATE C	102
Injected 1,2,6,7- ³ H -progesterone in 7 month old juvenile (5 μ Ci/10 μ l/juvenile) PLATE CI-CII	103-104

ABBREVIATIONS USED ON FIGURES

AT, adult testis; ^{C/A, cavity,} C, cortex; _h CR, chromosomes; CSC, chromosomal synaptonemal complexes; CY, cytoplasm; CV, caval vein;

DA, dorsal aorta; DAT, degenerating adult testis; DI, diplotene stage oocyte; ^{F.B, fat body,} EO, early oocytes; EP, epithelium; _h FC, follicle cell; ^{FM, ovarian membrane, ND, hepatic duct} FD, formazan deposits; _h HL, hind limb; HLB, hind limb bud; ^{HV, hepatic vein,} _h IG, indifferent gonad; IOV, inhibited ovary; IR, interrenal gland;

IT, interstitial tissue; IW, intestinal wall; K, kidney; KT, kidney tubule; ^{LV, lipid vacuole,} LE, leptotene stage oocyte; LU, lumen; _h M, medulla; ^{MB, mesonephros,} _h MC, medullary cells; ^{holostema,} MT, mitochondria; MU, mucosa; N, nucleus; NM, nuclear membrane; NO, nucleolus; NOB, nucleolar body;

OC, ovarian cavity; OG, oogonium; OV, ovary; PA, pachytene stage oocyte; PC, pigment cells; PG, primordial germ cell; PSP, primary spermatocyte; ^{SD, sudanophilic droplets,} RV, renal blood vessel; _h SG, spermatogonium; SPD, spermatids; SSP, secondary spermatocyte; ST, primordium of seminiferous tubules; SZ, spermatozoa; T, testis; TA, tail;

TJ, WD, Wolffian duct; ZY, zygotene stage oocyte.

Hind limb development in larva

PLATE I

Fig. 1. Right hind limb bud of a st.48
tadpole. x 130.

Fig. 2. Hind limb buds of a st.50
tadpole. x 110.

Fig. 3. Right hind limb bud of a st.51
tadpole. x 110.

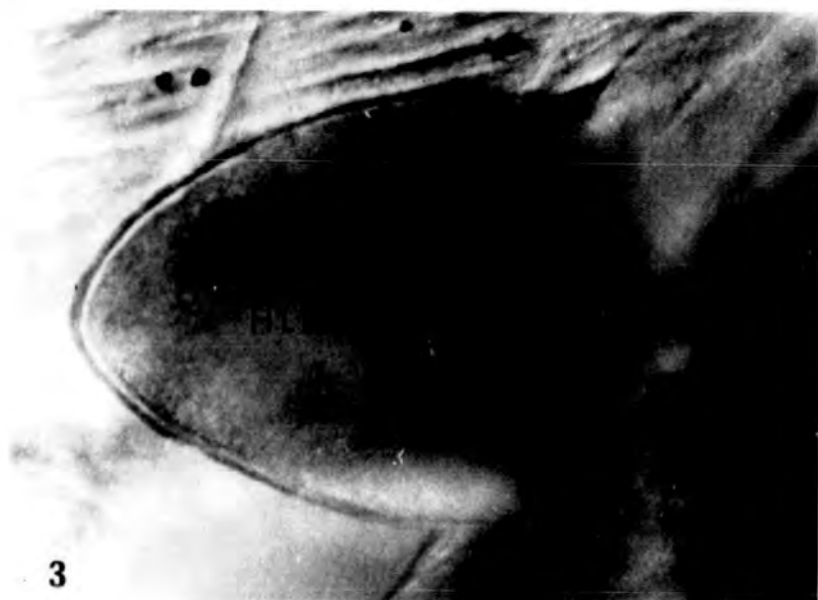
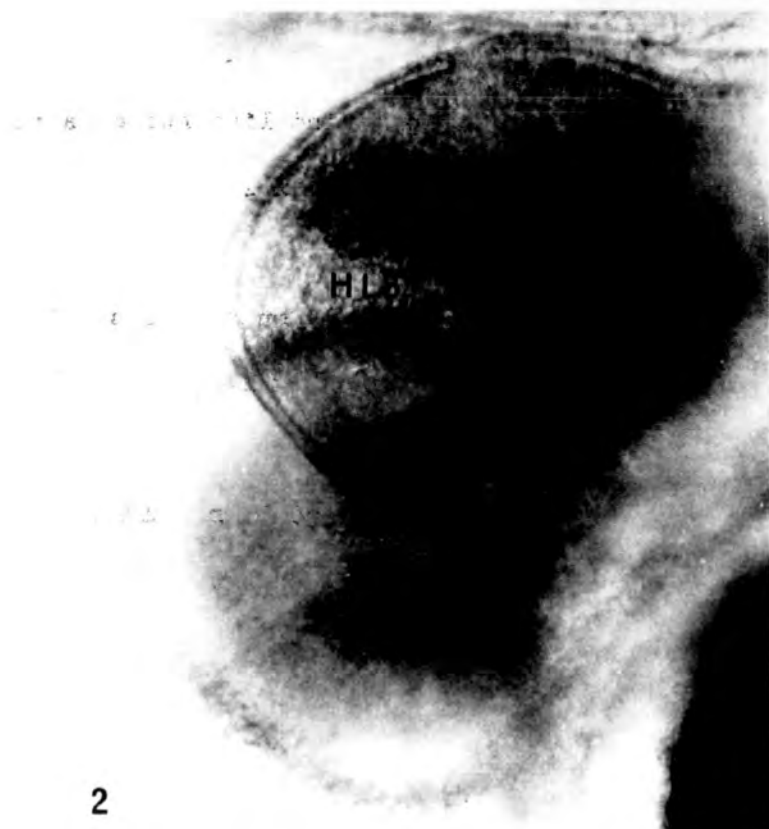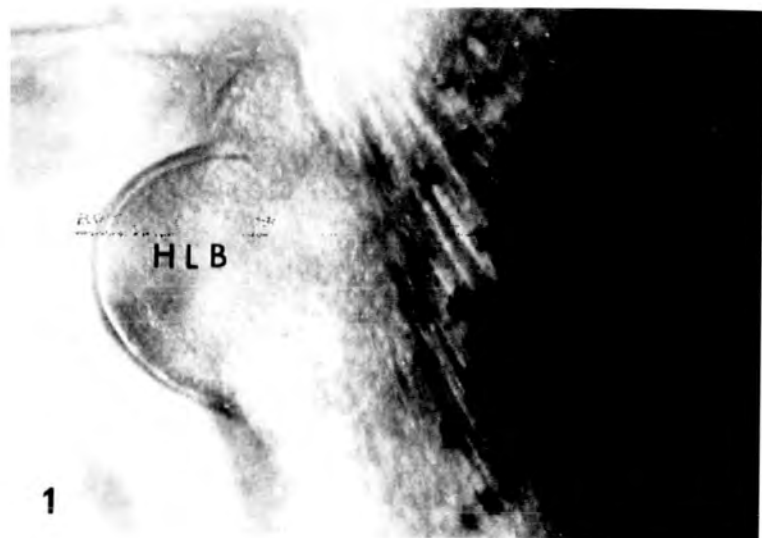
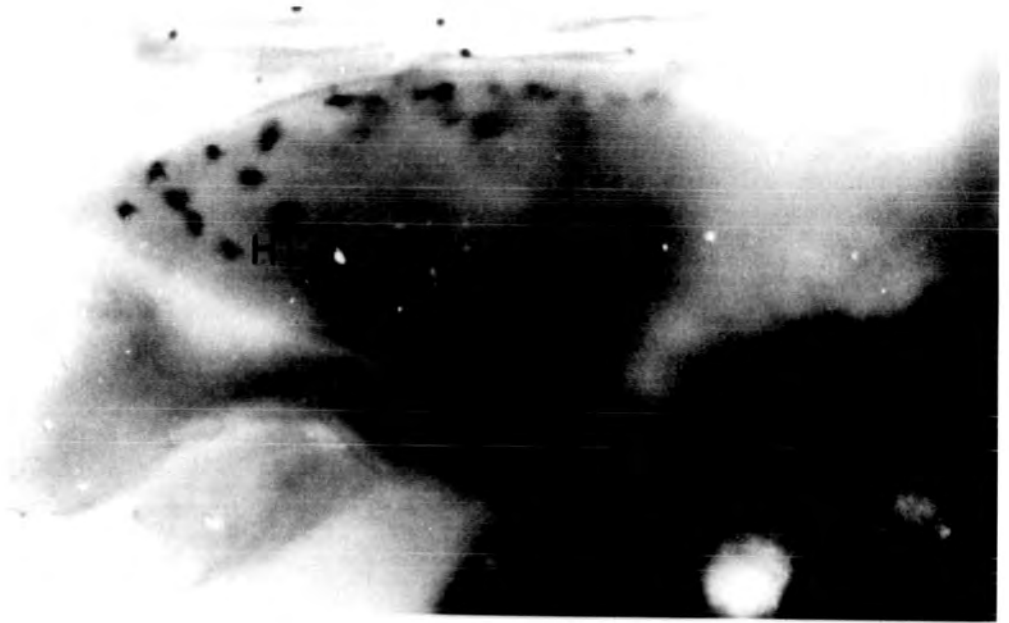


PLATE II

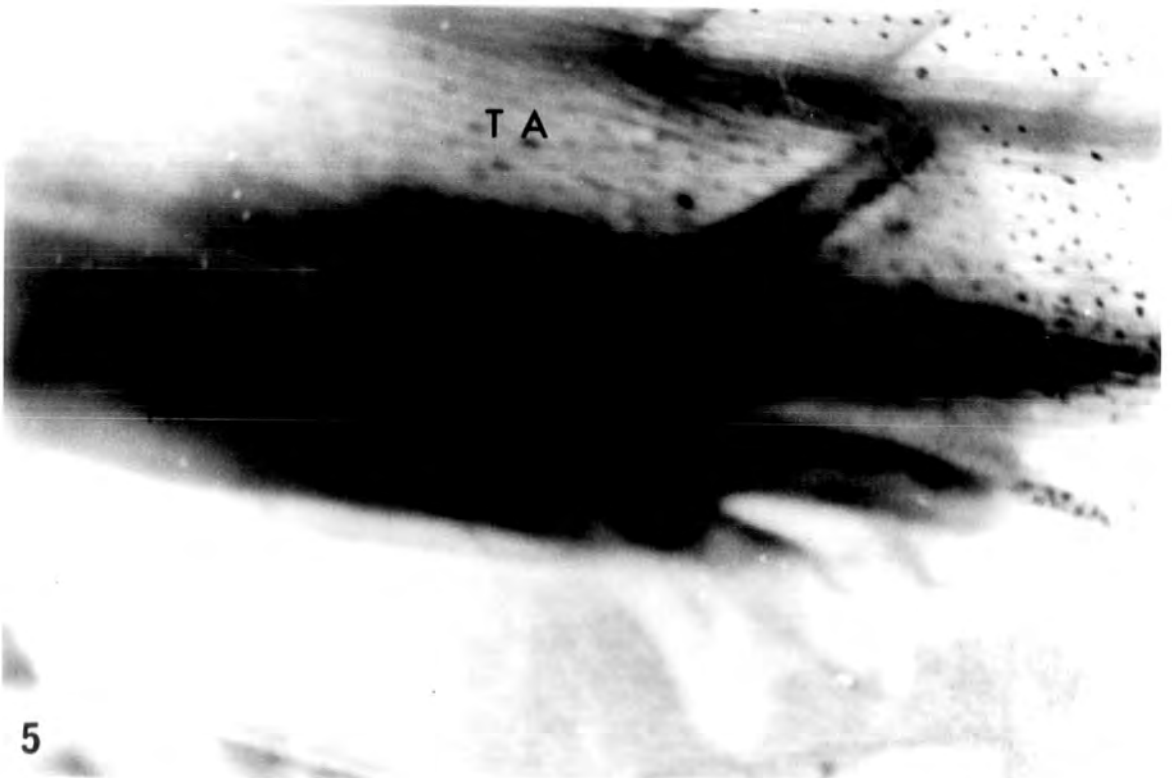
Fig. 4. Right hind limb bud of a st.52 tadpole. x 125.

Fig. 5. Left hind limb of a st.57 tadpole showing complete five toe arrangement. x 75.

4



5



Gonadal and Interrenal development of larva

PLATE III

Fig. 6. Indifferent gonads of st.47 tadpole showing primordial germ cells and associated follicle cells. Interrenal anlage present on top of the caval vein. x 640.

Fig. 7. Indifferent gonads of st.48 tadpole. x 640.

Figs. 8-9. Indifferent gonads of st.49 tadpole, showing primordial germ cells at the periphery and medullary cells at the hilum of the gonads.
8 x 400; 9 x 640.

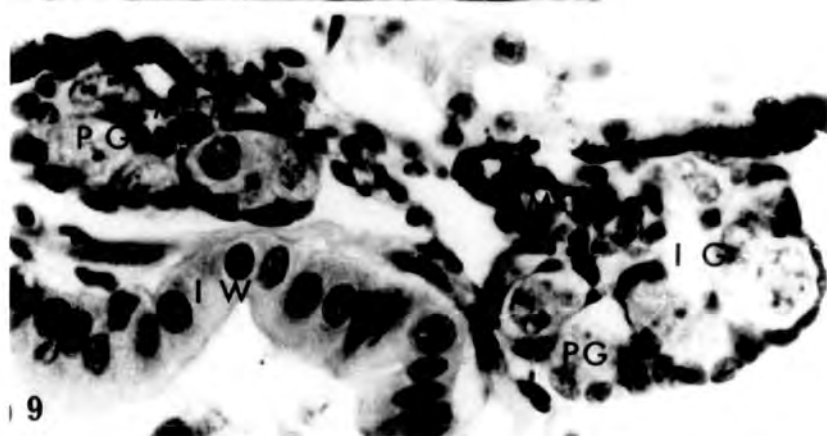
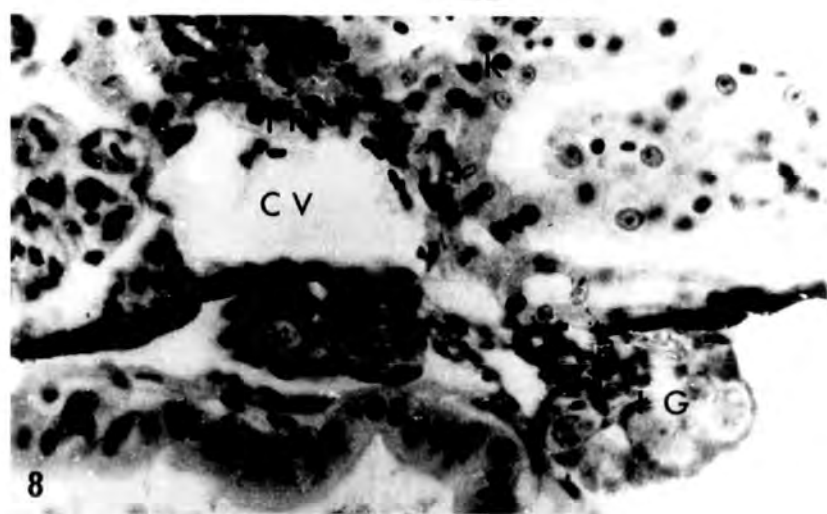
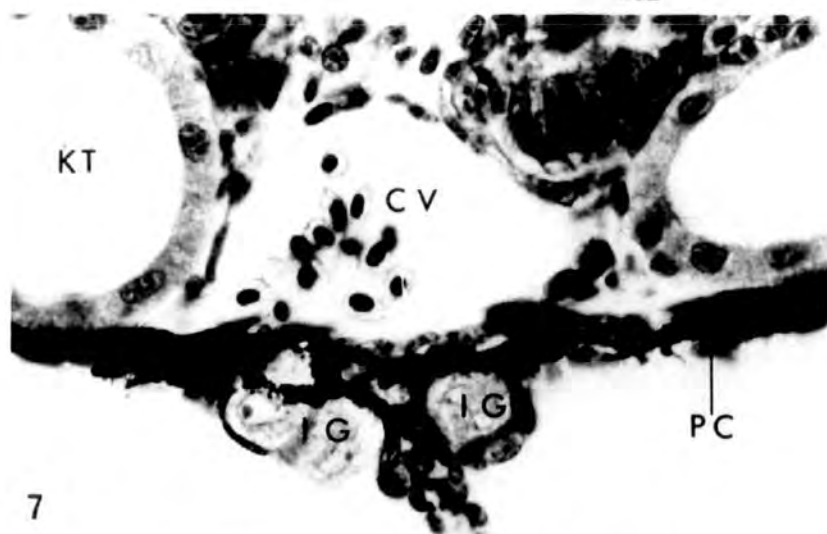
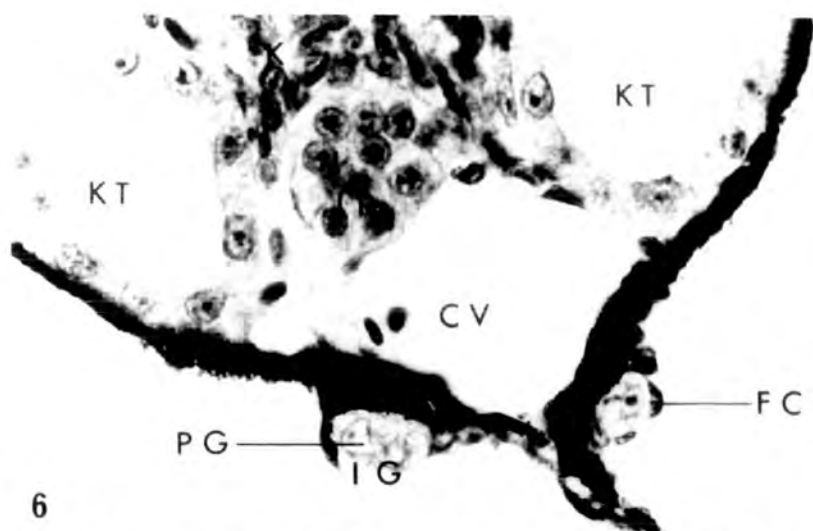


PLATE IV

- Fig. 10. Indifferent gonads of st.50 tadpole showing distinct cortex and medulla.
x 760.
- Fig. 11. Sexually indifferent gonads of st.51 with medulla-cortex constitution.
x 760.
- Fig. 12. 1μ araldite section of st.52 gonads indicating cortical and medullary regions, the primordial germ cells being present in the latter. All cells show a clearer outline in this section, than in wax-impregnated material. x 760.

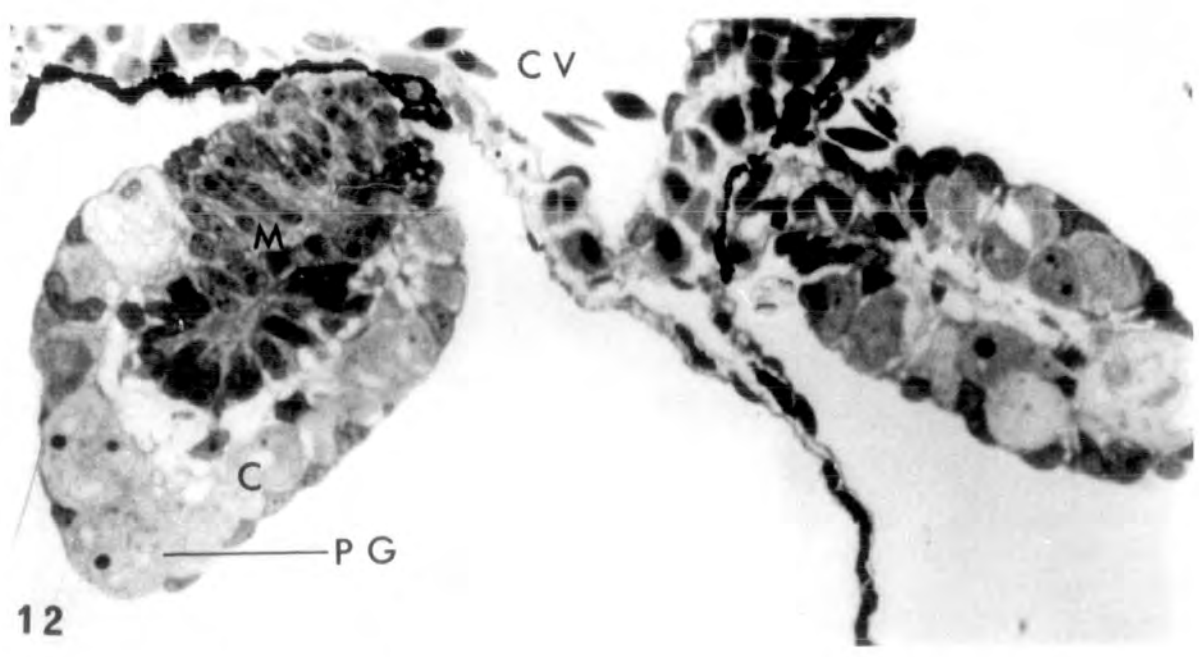
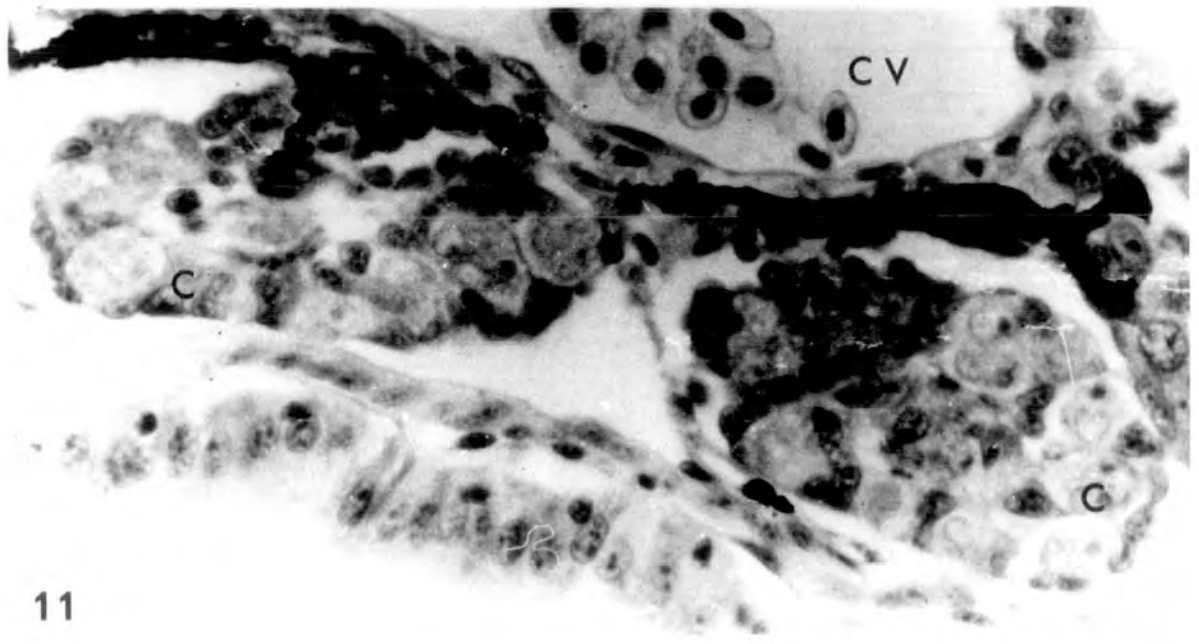
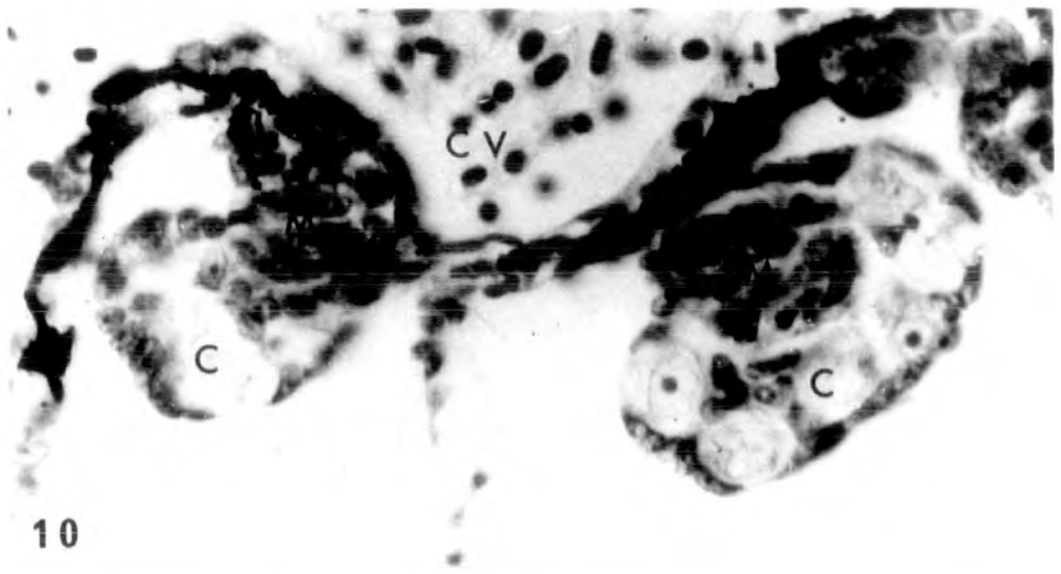


PLATE V

Figs. 13-16. Early ovaries of st.53 female tadpole. The cortical region is prominent and contains oogonia; the medullary region small or absent.

13-15 x 400

16 x 640

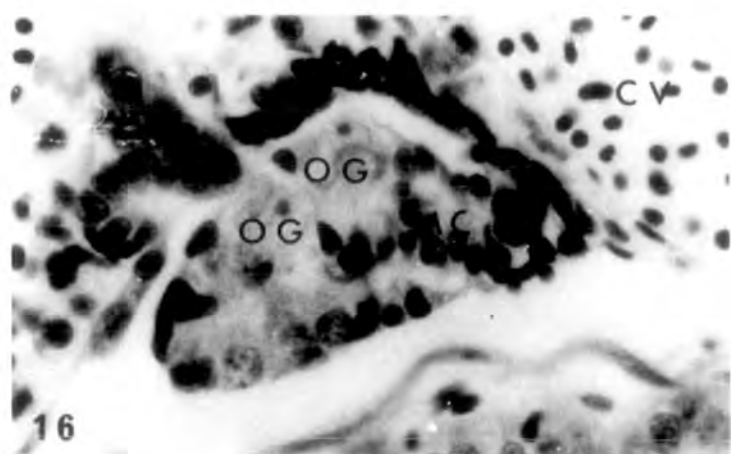
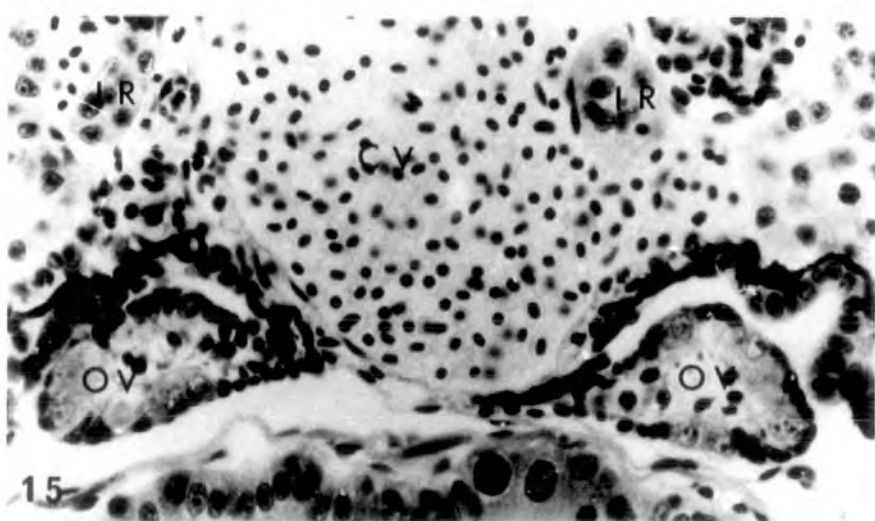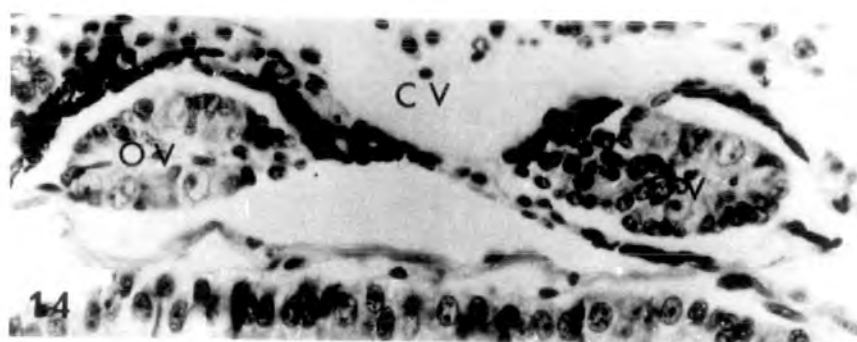
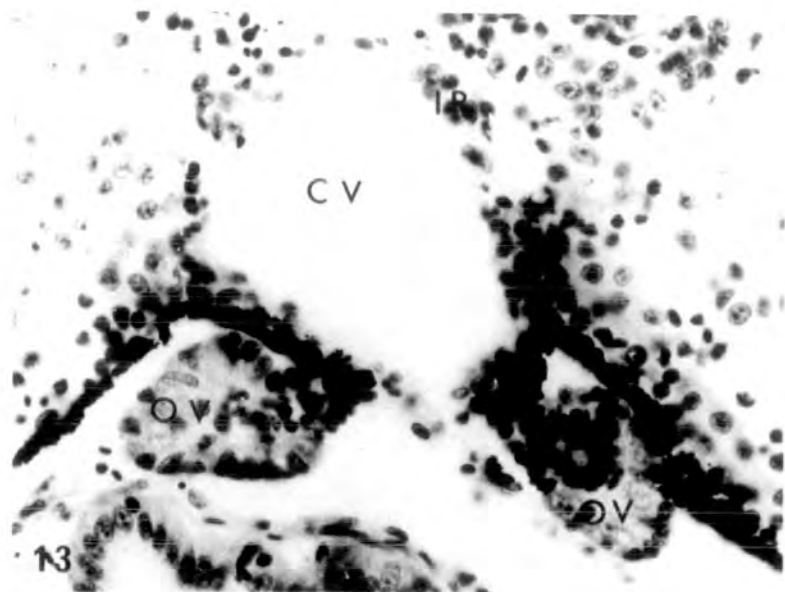


PLATE VI

Figs. 17-18. Early testes from st.53 male tadpoles.

Medulla is more distinct than at earlier stages and the cortex is being invaded by medullary cells. Part of the interrenal gland can be seen in Fig.17 on the side of the caval vein.

17 x 400

18 x 640

Figs. 19-20. Compact testicular structures from st.54

tadpoles. Nests of spermatogonia can be seen throughout the testicular soma. Interrenal islets are present in 19, on either side of the caval vein.

19 x 400

20 x 640

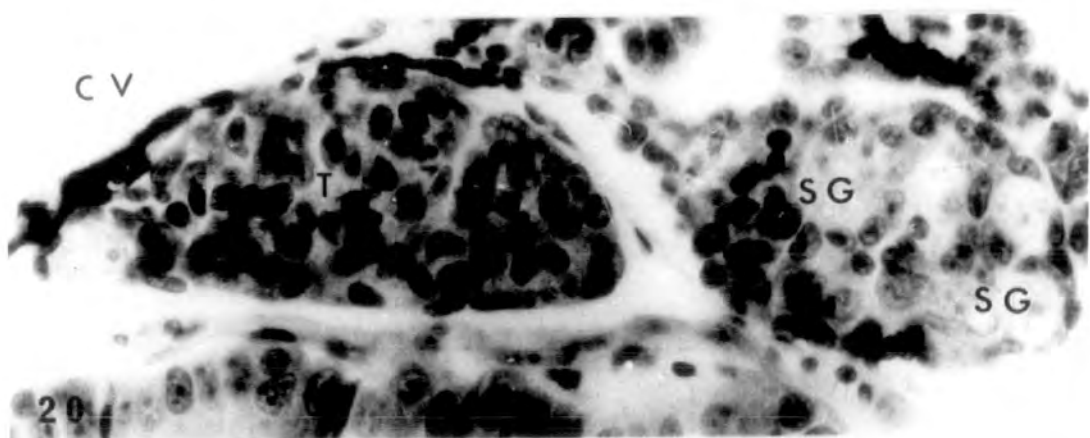
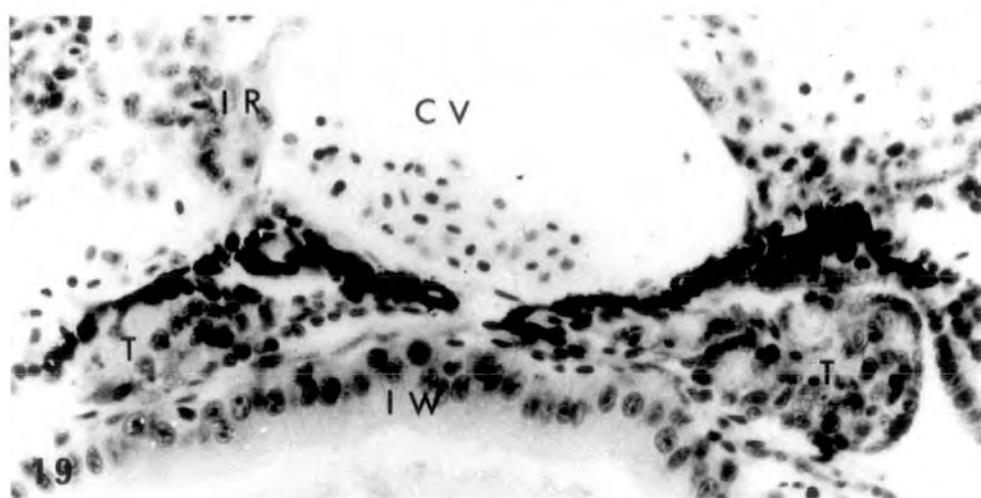
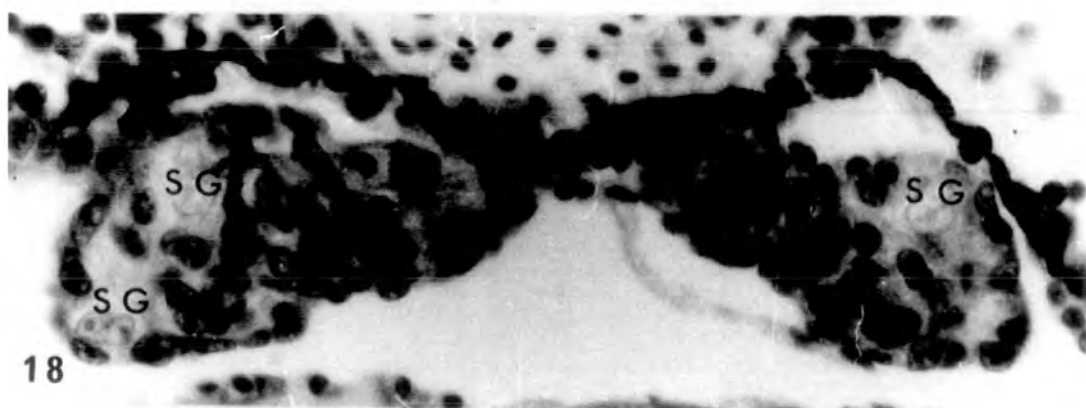
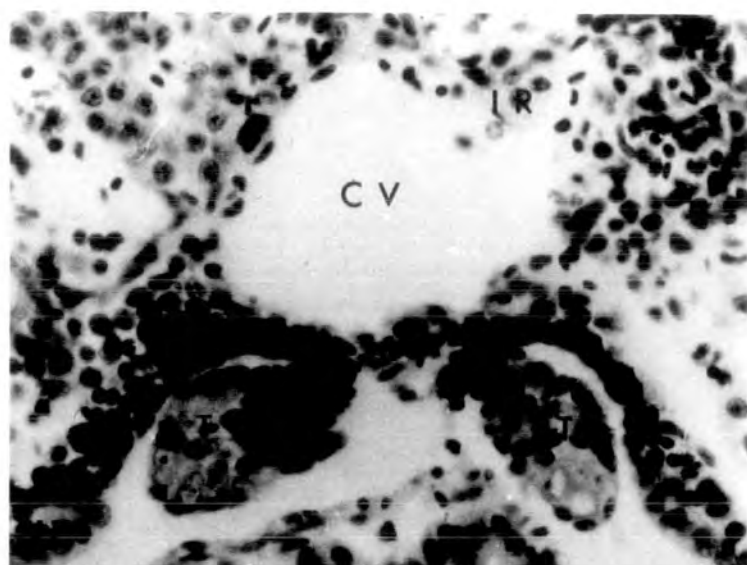


PLATE VII

Fig. 21. St.54 ovaries showing thick cortical region and very small medulla. Nests of early oocytes are present in the cortex and a small ovarian cavity can be seen in the right ovary. x 640.

Figs. 22-23. Section from the same tadpole showing st.55 ovaries. Ovarian cavities evident, and nests of oogonia, early oocytes and leptotene oocytes are present in the ovarian cortex. In Fig. 23 a large interrenal islet can be seen on the side of the caval vein. x 640.

(Arrowheads indicate the nests of early oocytes in the cortex).

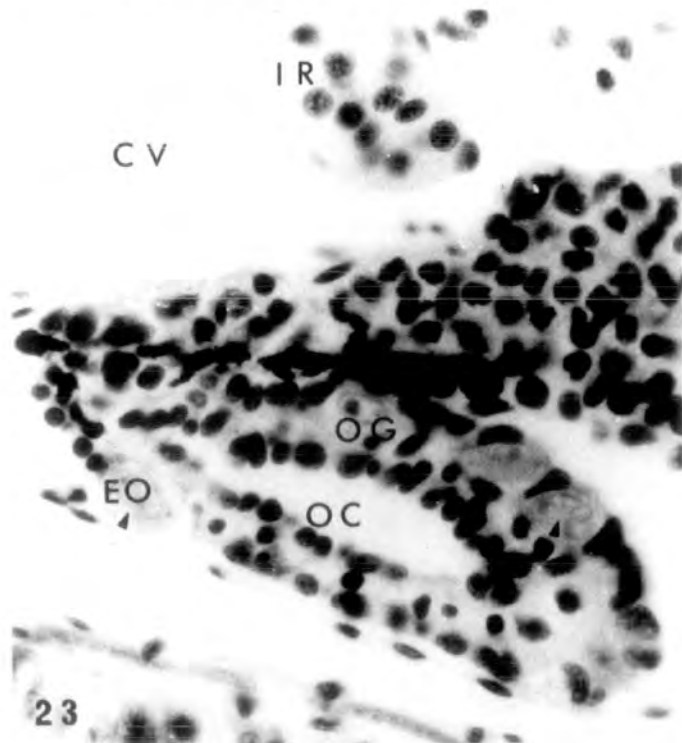
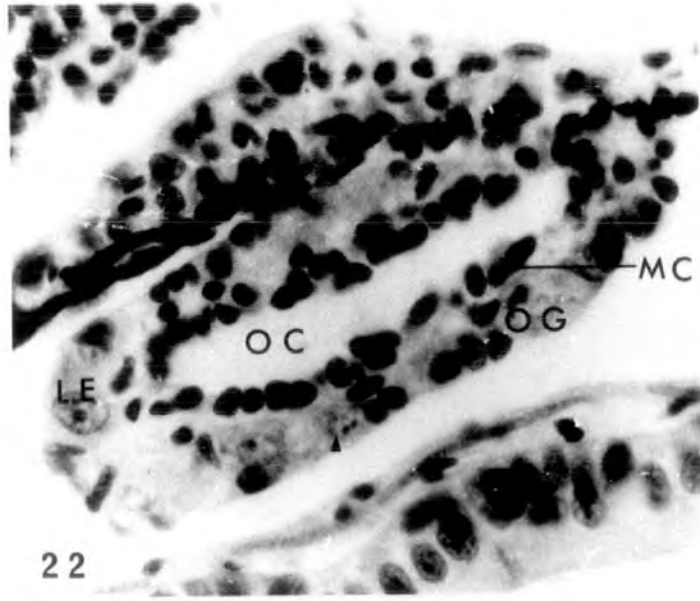
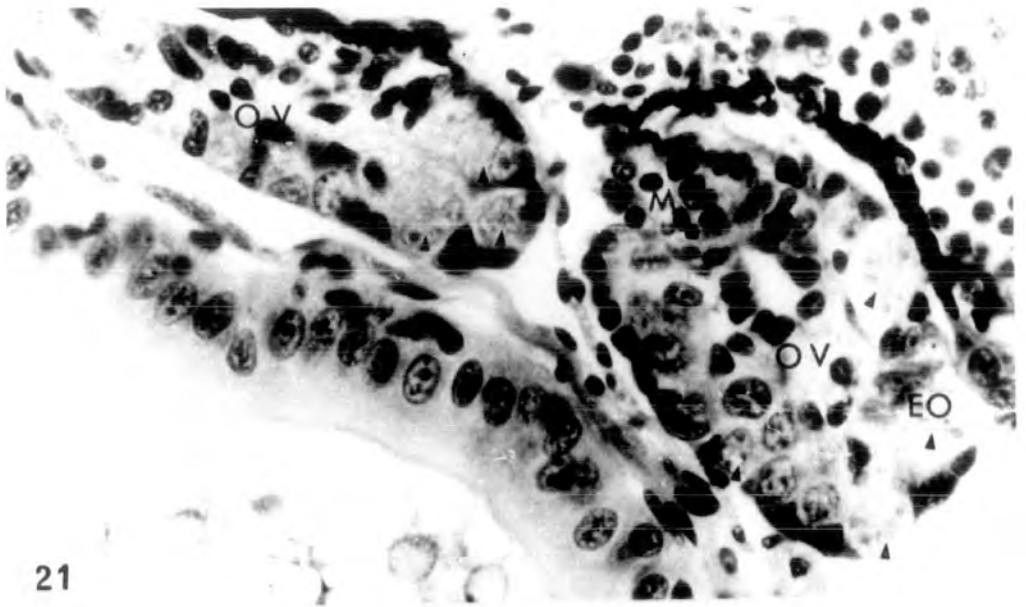


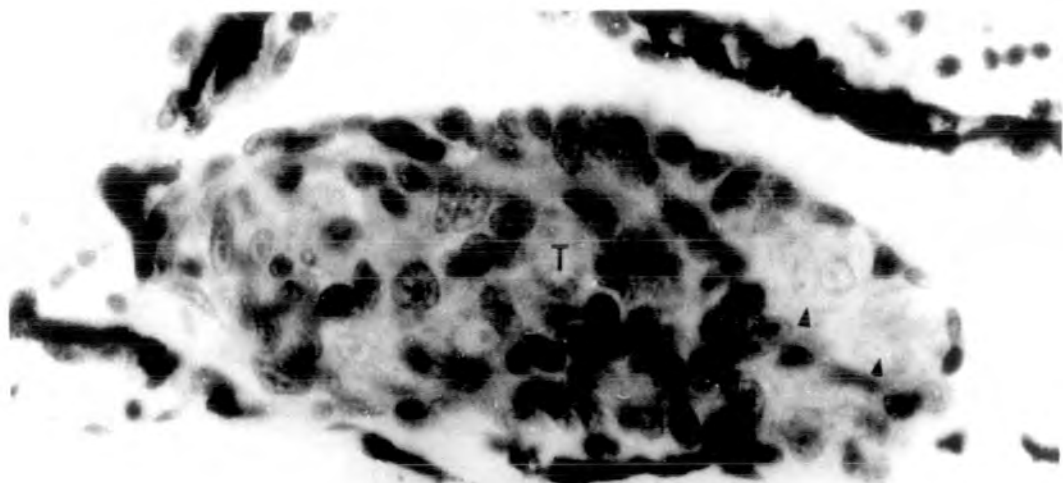
PLATE VIII

Fig. 24. Compact testicular structure of st.55 tadpole. x 760.

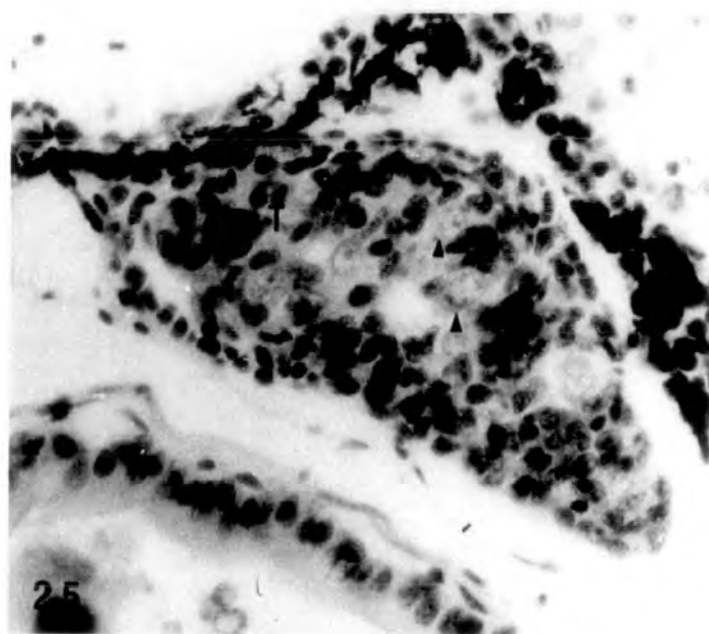
Fig. 25. Testis from st.56 tadpole. x 475.

Fig. 26. Testis from st.57 tadpole. The small circular cavities in the testicula soma could be the primordia of seminiferous tubules. x 475.

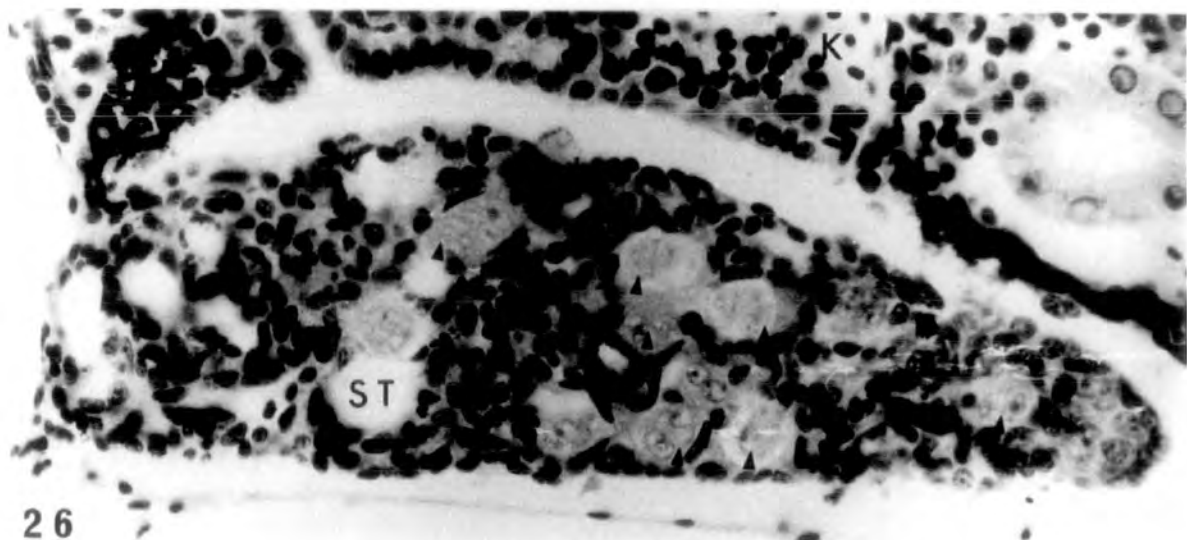
(Arrowheads indicate nests of dividing spermatogonia in the testicular soma).



24



25

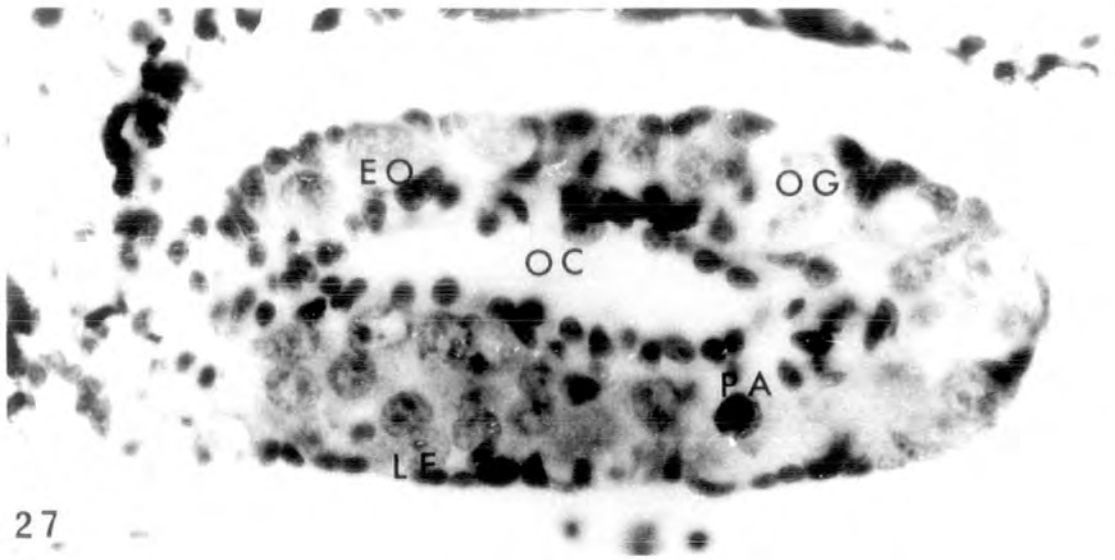


26

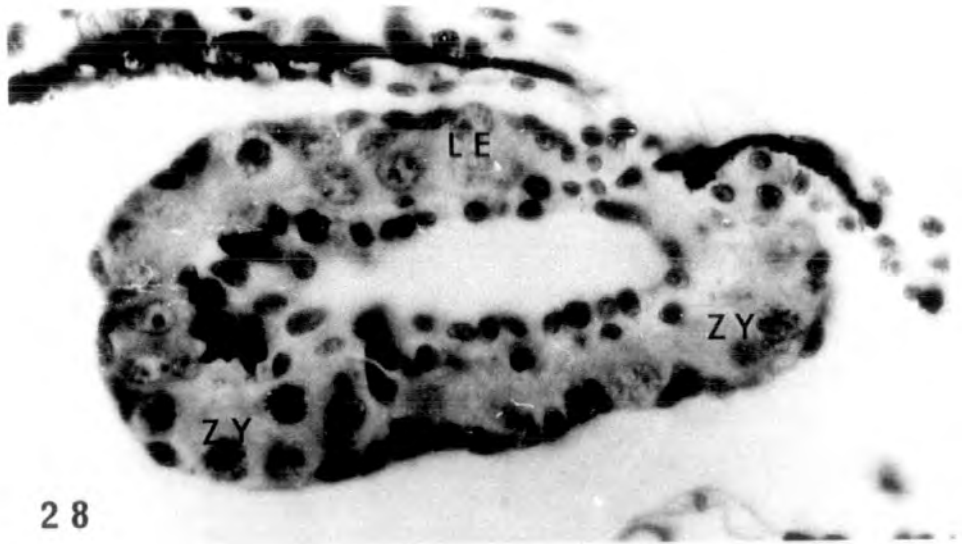
PLATE IX

Figs. 27-28. Left and right ovaries from the same section of st.56 tadpole. Oocytes of various developmental stages up to pachytene can be seen in the thick ovarian cortex. The ovarian cavities are lined by a layer of medullary cells. x 700.

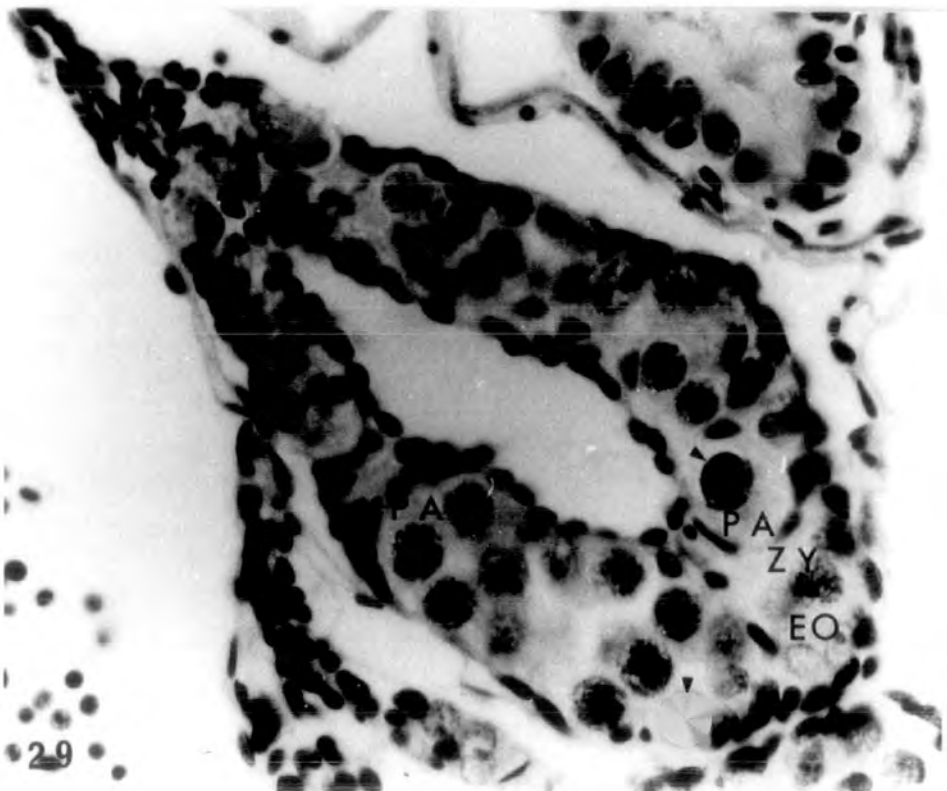
Fig. 29. A st.57 ovary containing many pachytene oocytes in the cortical region. The mitochondrial cap can be seen at the periphery of some of these oocytes (arrowheads). x 700.



27



28



29

PLATE X

Fig. 30. St.58 testis containing many nests of spermatogonia surrounded by masses of somatic cells. Primordia of seminiferous tubules can be seen in the testicular soma. A club-shape interrenal islet has descended to the lower side of the caval vein. x 400.

Fig. 31. St.58 ovaries showing clear ovarian cavities. Various developmental stages of oocytes up to pachytene can be seen in the cortical region. x 400.

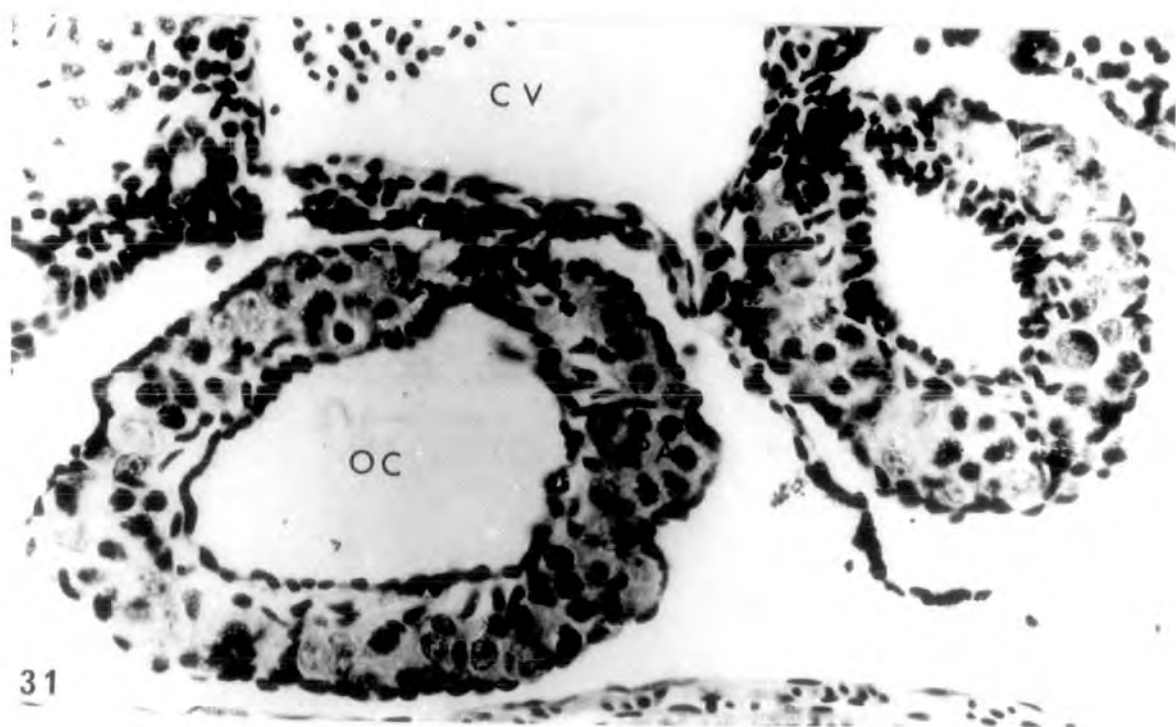
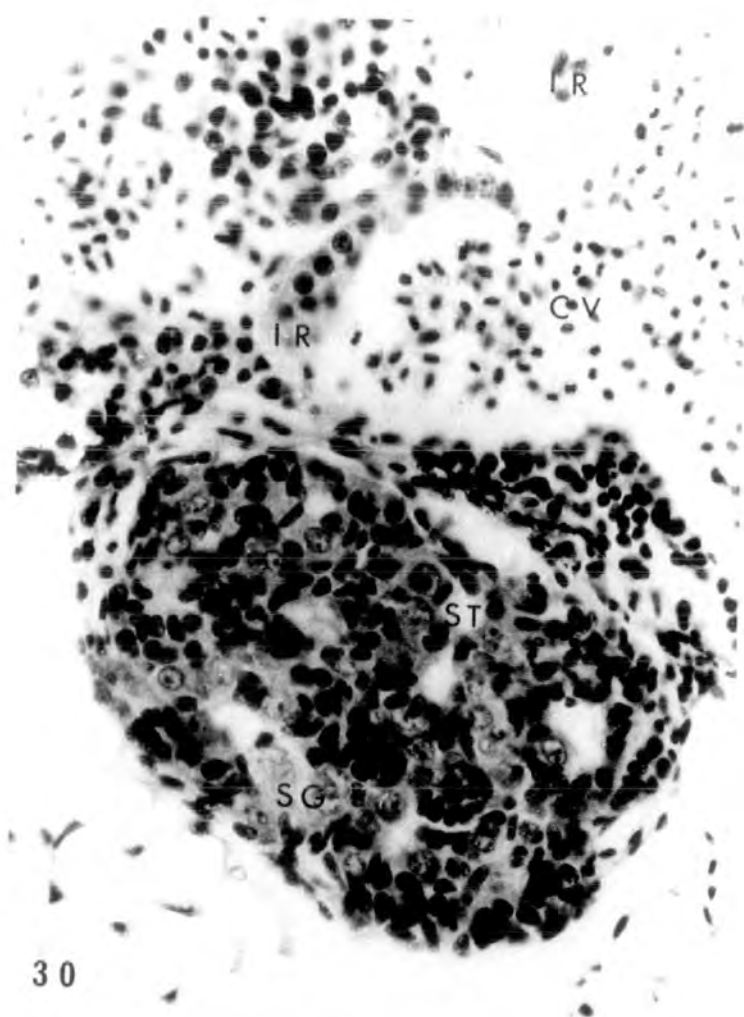


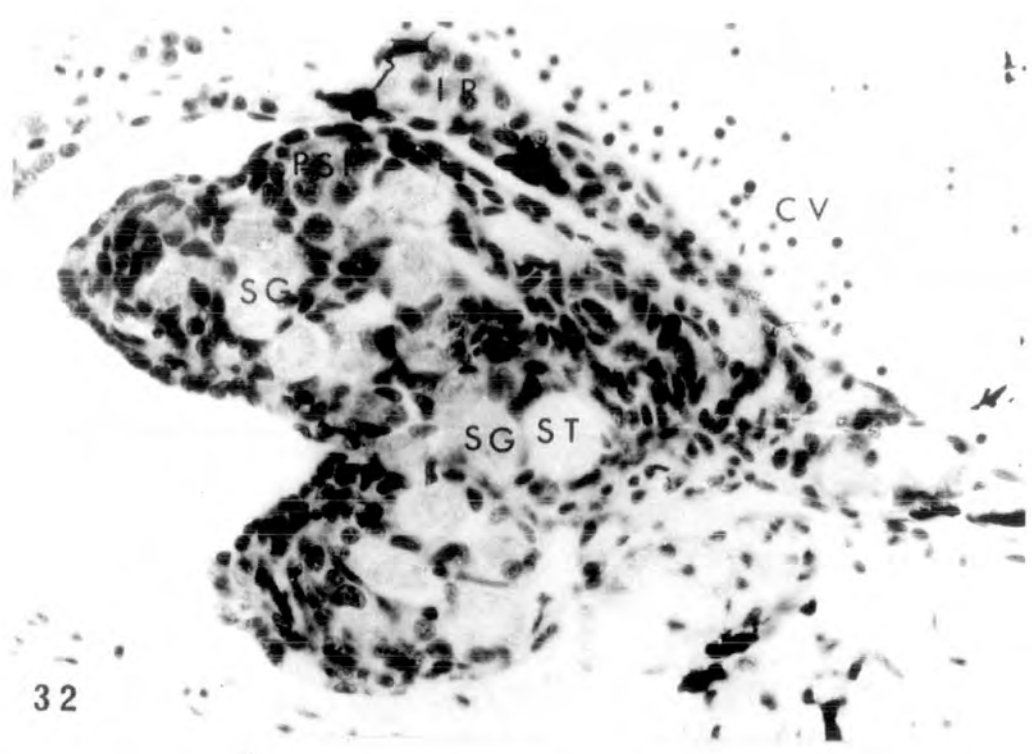PLATE XI

Fig. 32. The left testis from a st.62 tadpole.

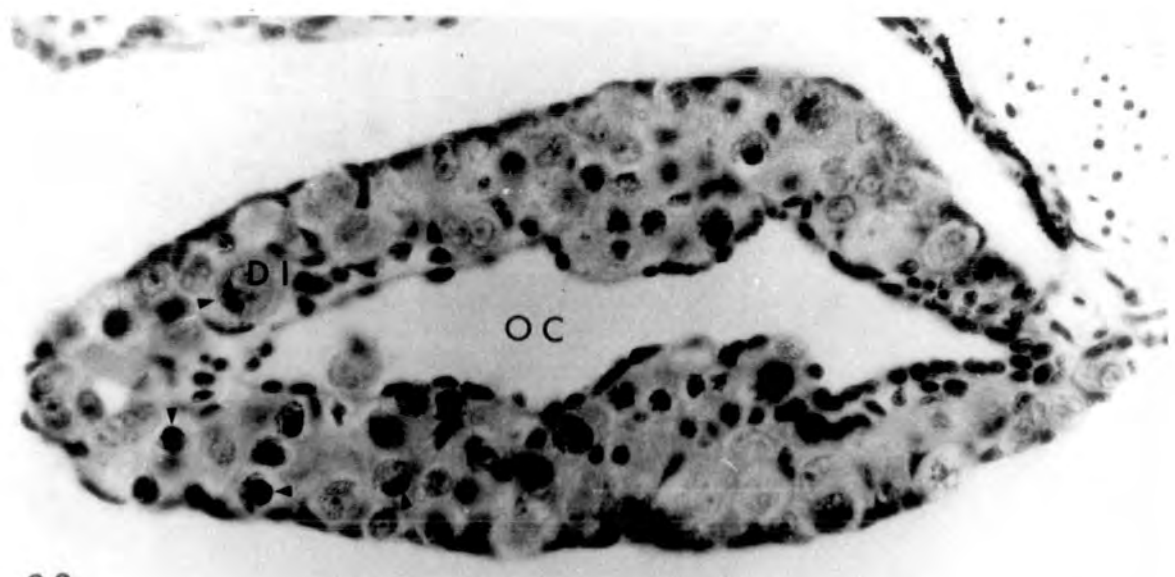
Many nests of spermatogonia and some primary spermatocytes can be seen in the testicular soma. An interrenal islet can be seen on the lateral side of the caval vein. x 400.

Figs.33-34. Two sections from the left ovary

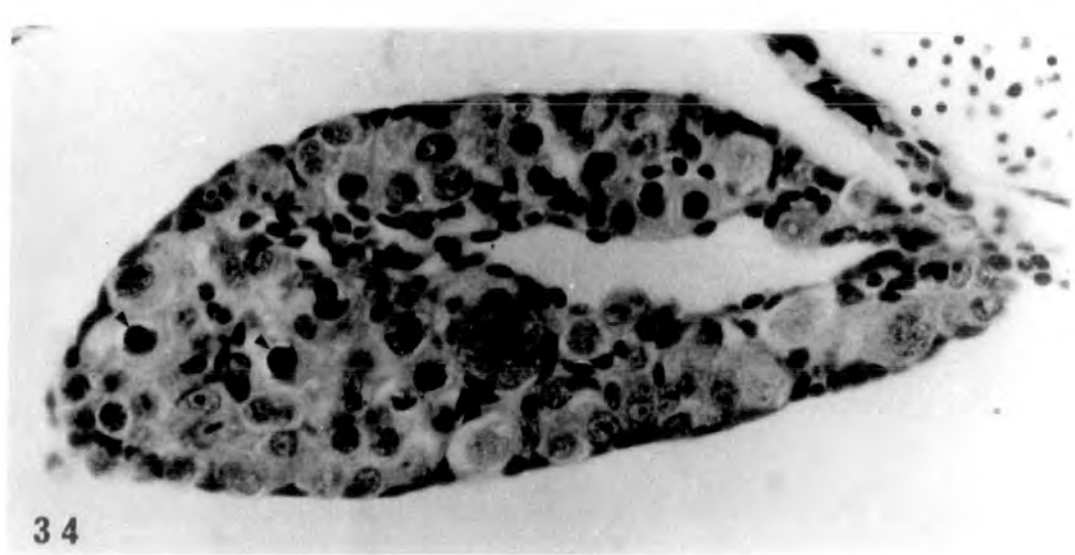from a st.62 tadpole, the first more anterior than the second. Oocytes of various stages up to early diplotene can be seen in the ovarian cortex. Mitochondrial caps evident (arrowheads) in pachytene oocytes. x 400.



32



33



34

PLATE XII

Fig. 35. St.63 testis. Spermatogonia, spermatocytes and seminiferous tubules can be seen in the testicular soma. x 400.

Fig. 36. St.63 ovary. Many diplotenic oocytes are present in the ovarian cortex. x 400.

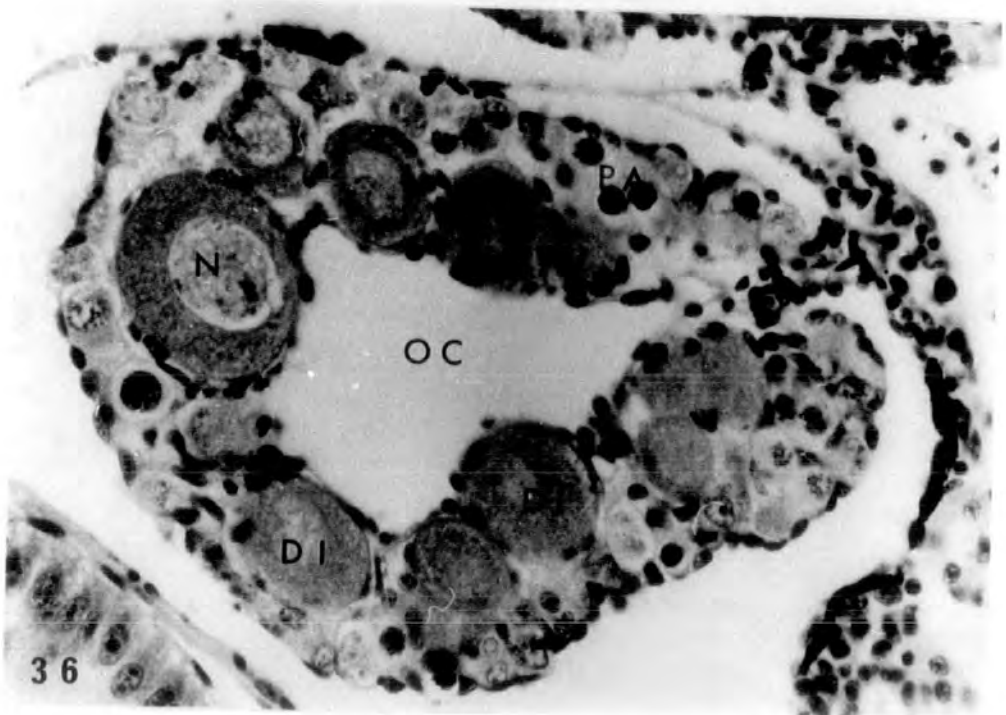
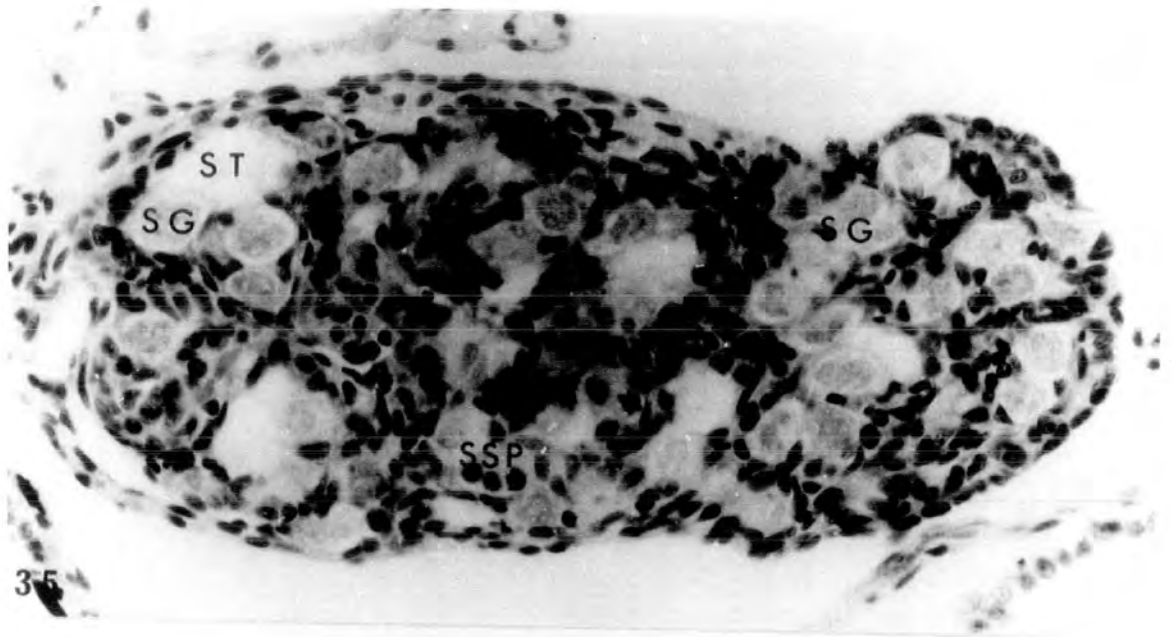
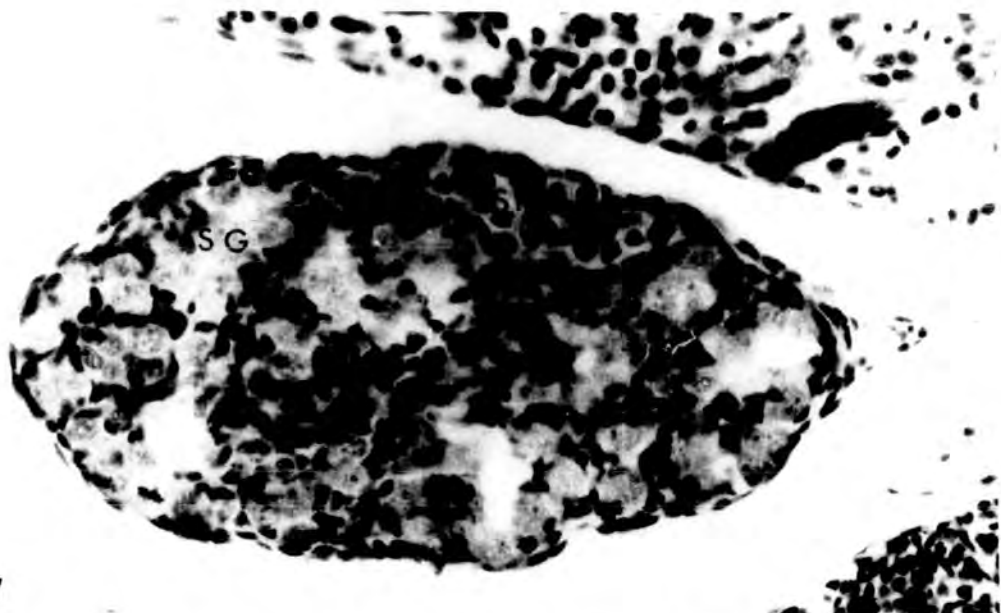


PLATE XIII

Fig.37. St.66 testis. Spermatogonia and secondary spermatocytes are present. x 400.

Figs.38-39. St.66 ovaries showing large diplotenic oocytes in the cortex. Numerous nucleoli (arrowheads) are present in the diplotenic nuclei. In 38 an interrenal islet can be seen on the lateral side of the caval vein. x 400.



37

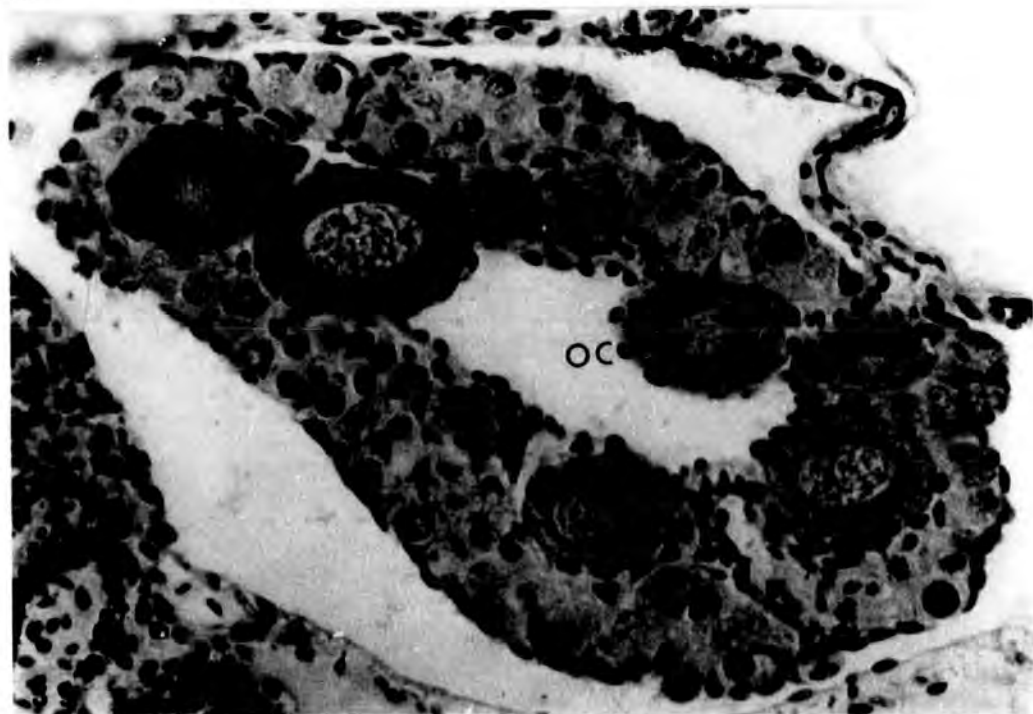
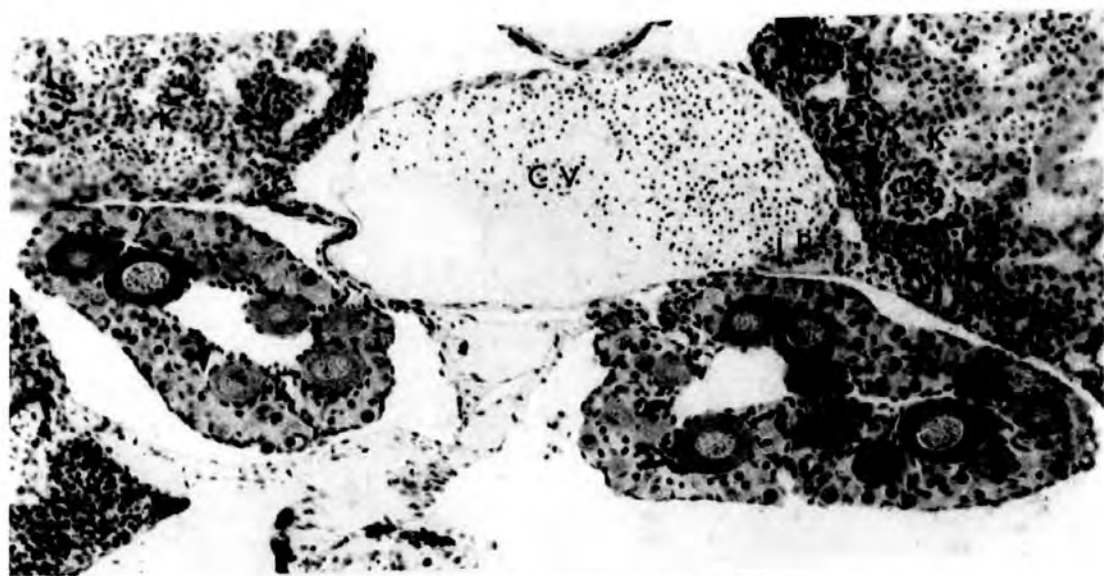
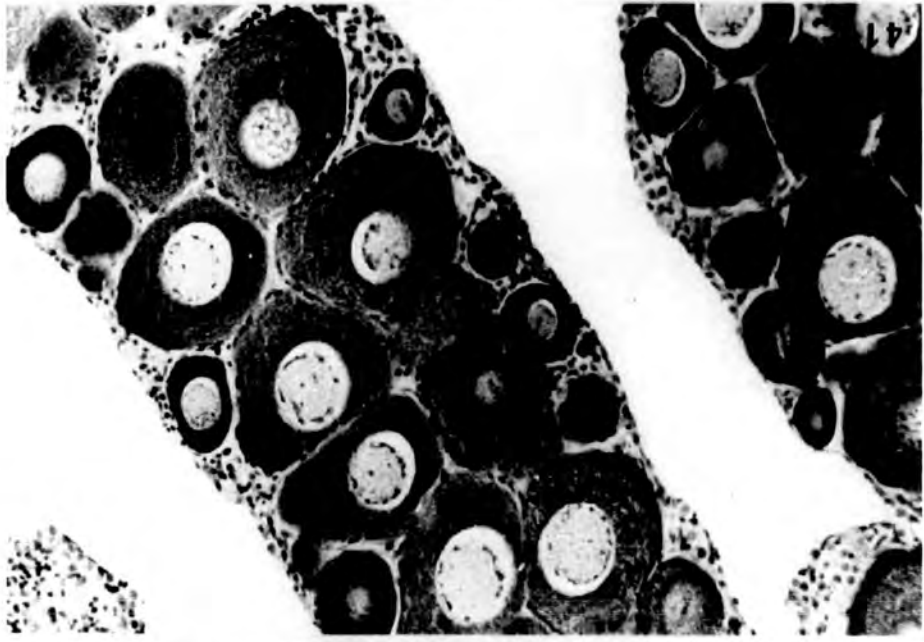
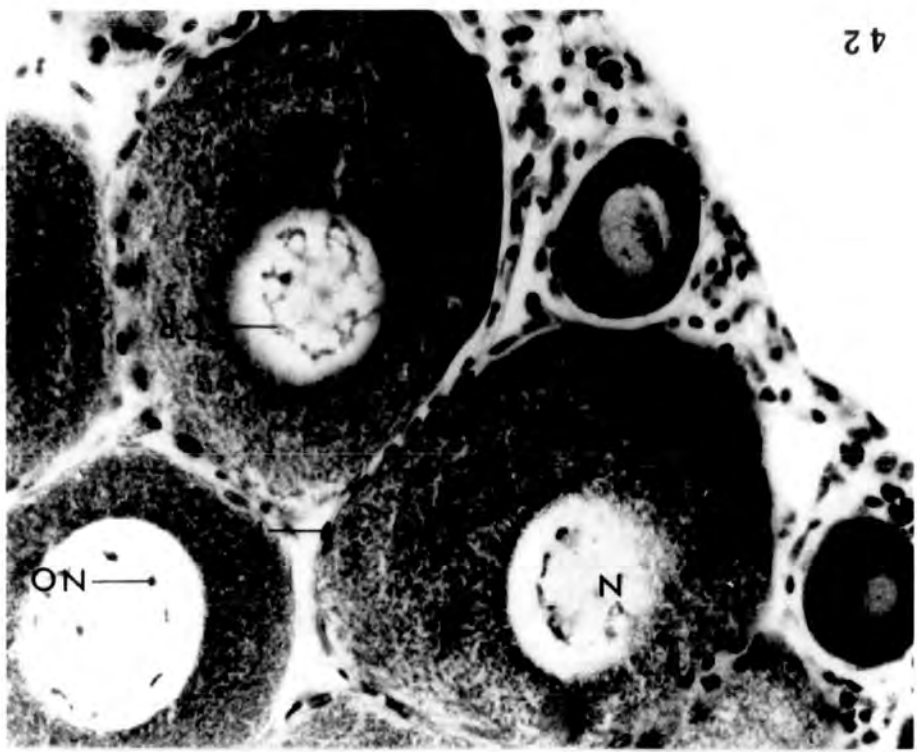


PLATE XIV

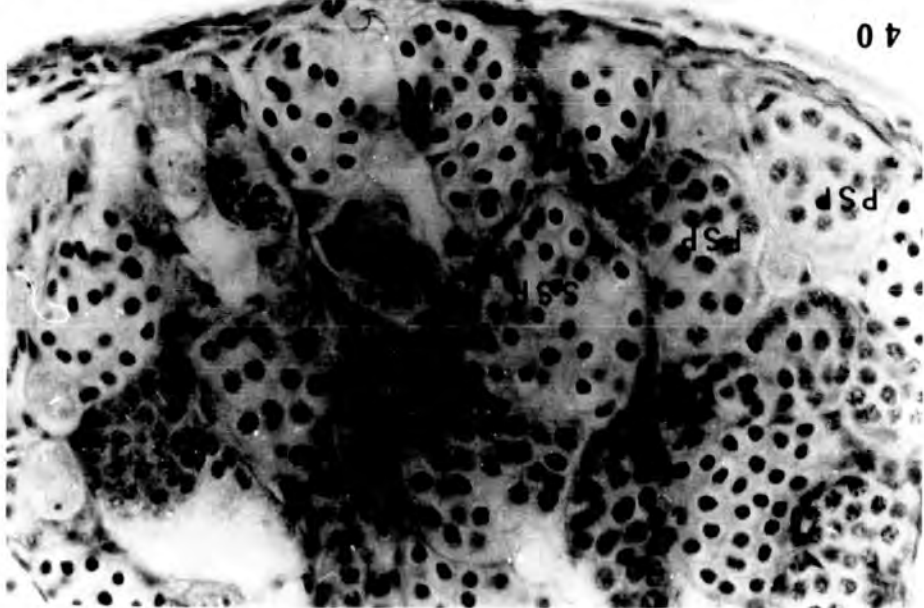
Fig. 40. Testis of a 4 month juvenile Xenopus, showing seminiferous tubules containing germinal cysts at various stages of development. Primary and secondary spermatocytes, spermatids and spermatozoa are present. In any one cyst the germ cells present are at the same developmental stage.
x 400.

Figs. 41-42. Ovary of a 4 month old female showing oocytes well into diplotene. In 42 chromosomes can be seen in the characteristically large nucleus. Follicle cells are present around the oocytes.
41 x 160
42 x 400

42



40



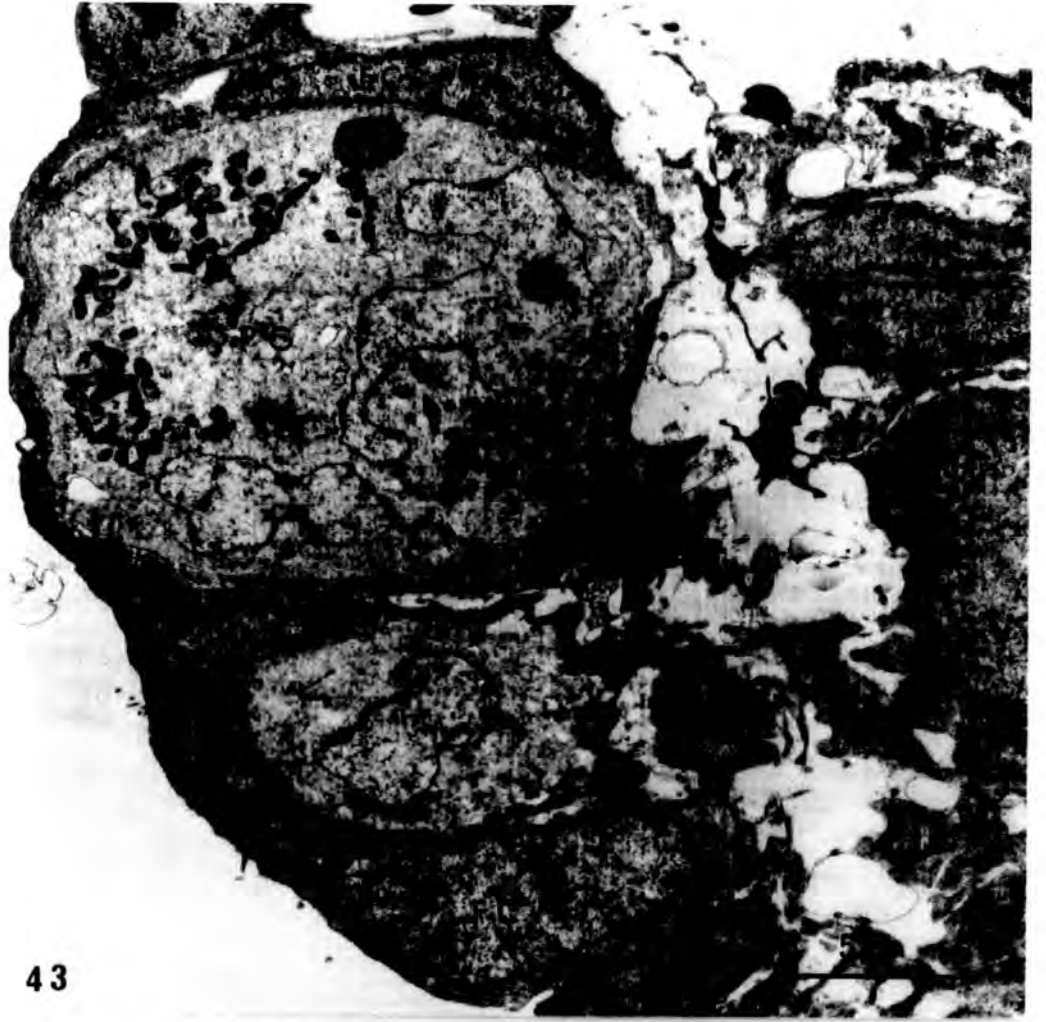Gonadal ultrastructure

PLATE XV

Figs. 43-44. Part of a st.49 indifferent gonad, showing primordial germ cells (pg) and follicle cells. The primary germ cell possesses a characteristically large multilobed nucleus containing a round nucleolus. In the cytoplasm, to either side of the nucleus, aggregation of mitochondria is evident. Present near the nucleus is a nucleolar body adjacent to the primary germ cell there is a follicula cell. Its very large nucleus is densely stained, with condensations of chromatin in the nucleoplasm and the nuclear membrane.

43 x 5,000

44 x 8,000



43

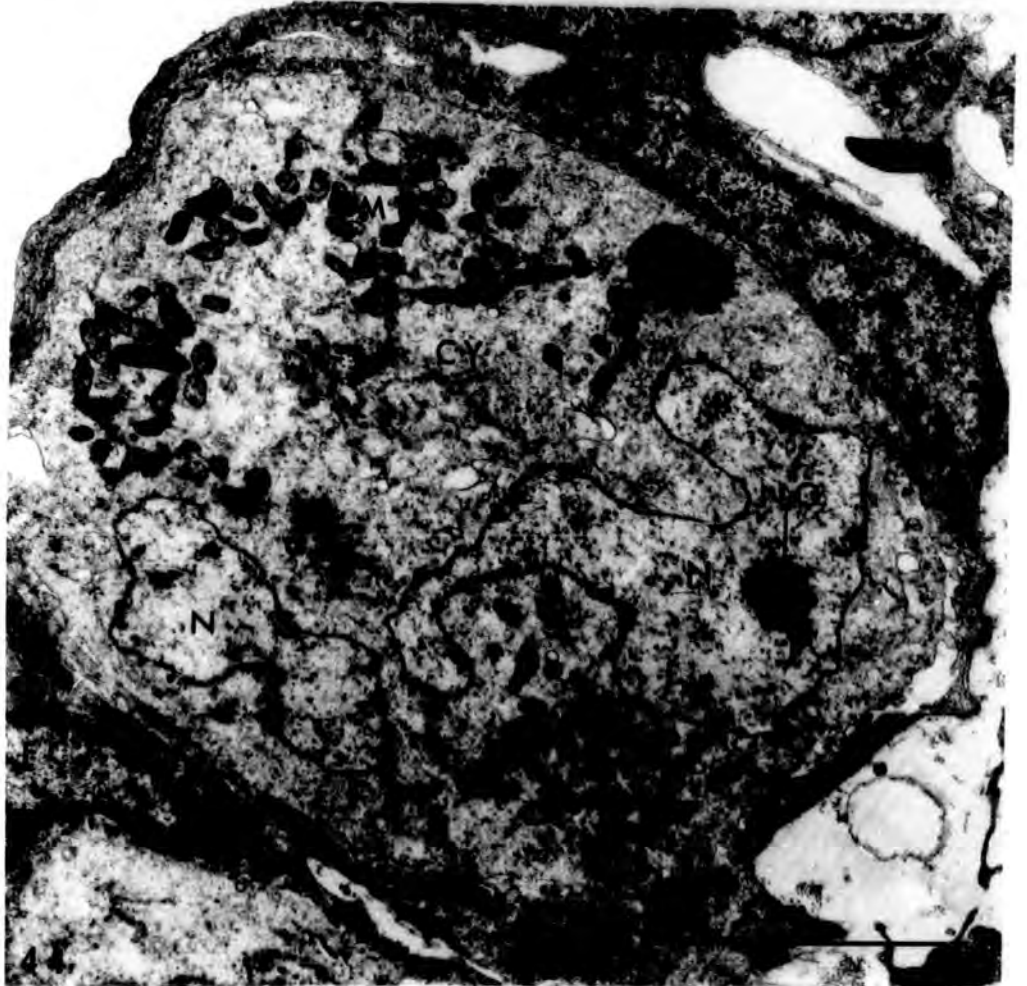


PLATE XVI

Fig. 45. Another primordial germ cell in the same st.49 gonad as before. x 8,000.

Fig. 46. An oogonium from a st.56 ovary, showing a multilobed nucleus with three compact nucleoli. The nucleus is enclosed by a double layer nuclear membrane and some of the electron dense granular material in the nucleus is associated with the nuclear membrane (arrowheads). There is a mitochondrial aggregate on one side of the nucleus. Note the similarity of this cell to the primordial germ cell. x 12,600.

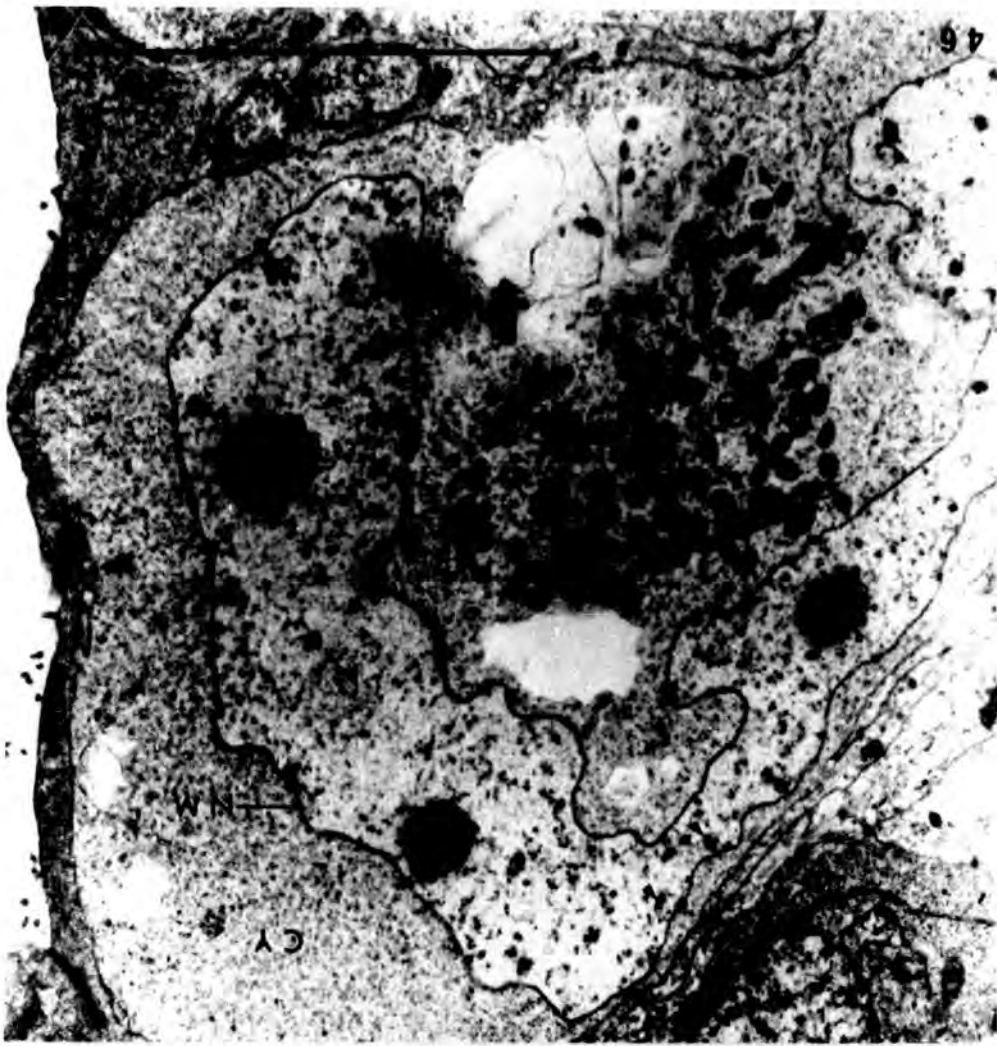


PLATE XVII

Fig. 47. An early leptotene oocyte in a st.56 ovary. Note the large round nucleus two nucleoli and the chromatin which is denser than in the oogonium.
x 8,000.

Fig. 48. Another leptotene oocyte from the same st.56 ovary, showing one nucleolus in the large nucleus. x 8,000.

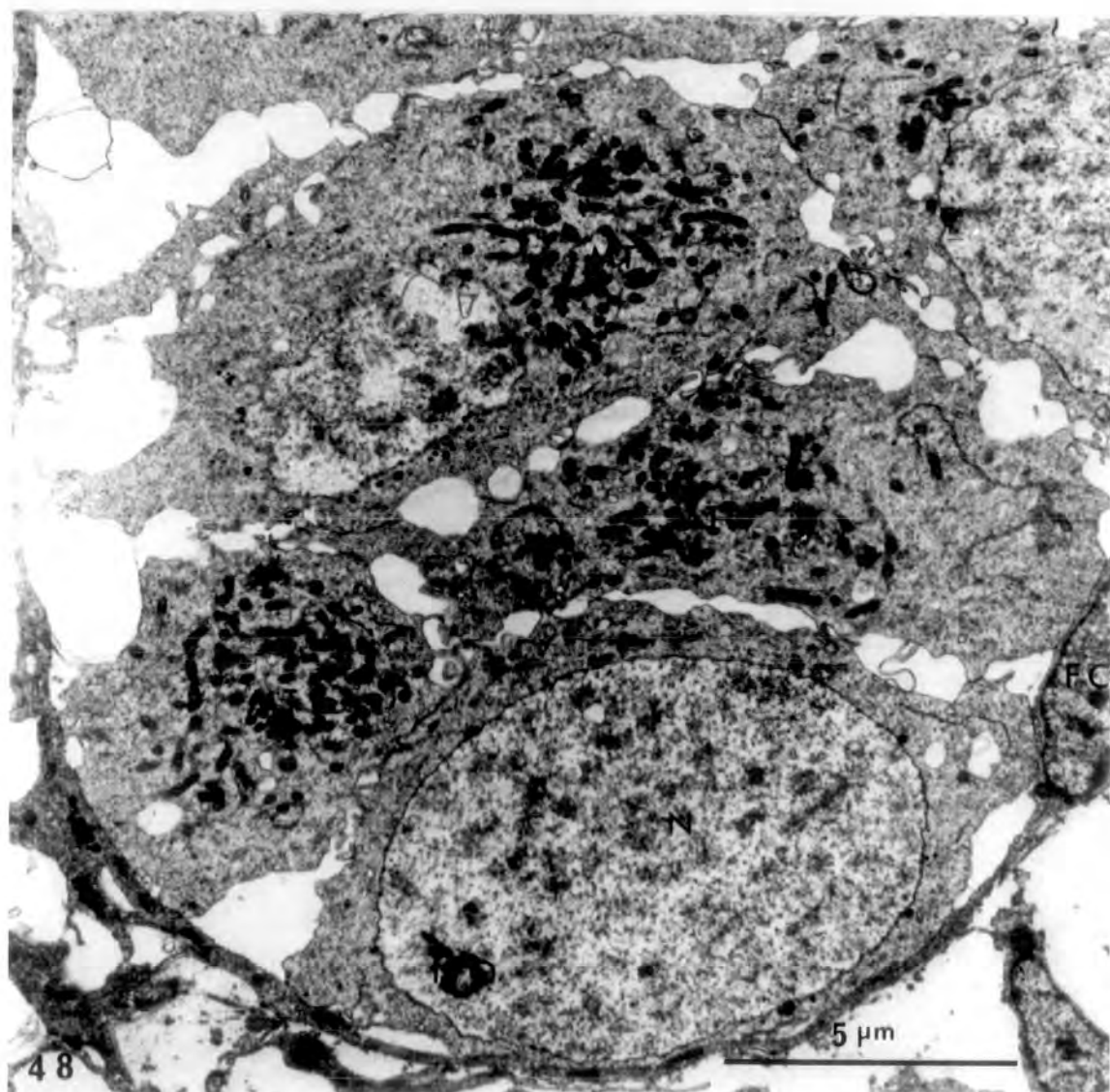
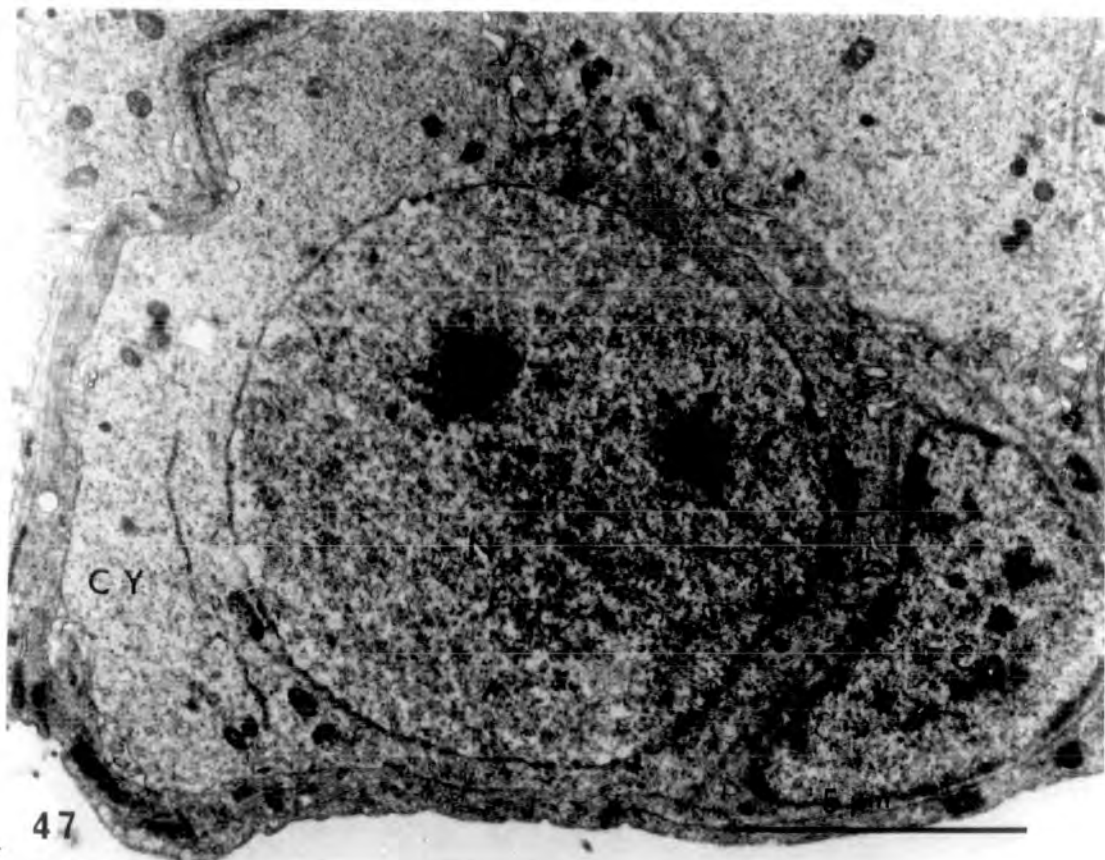
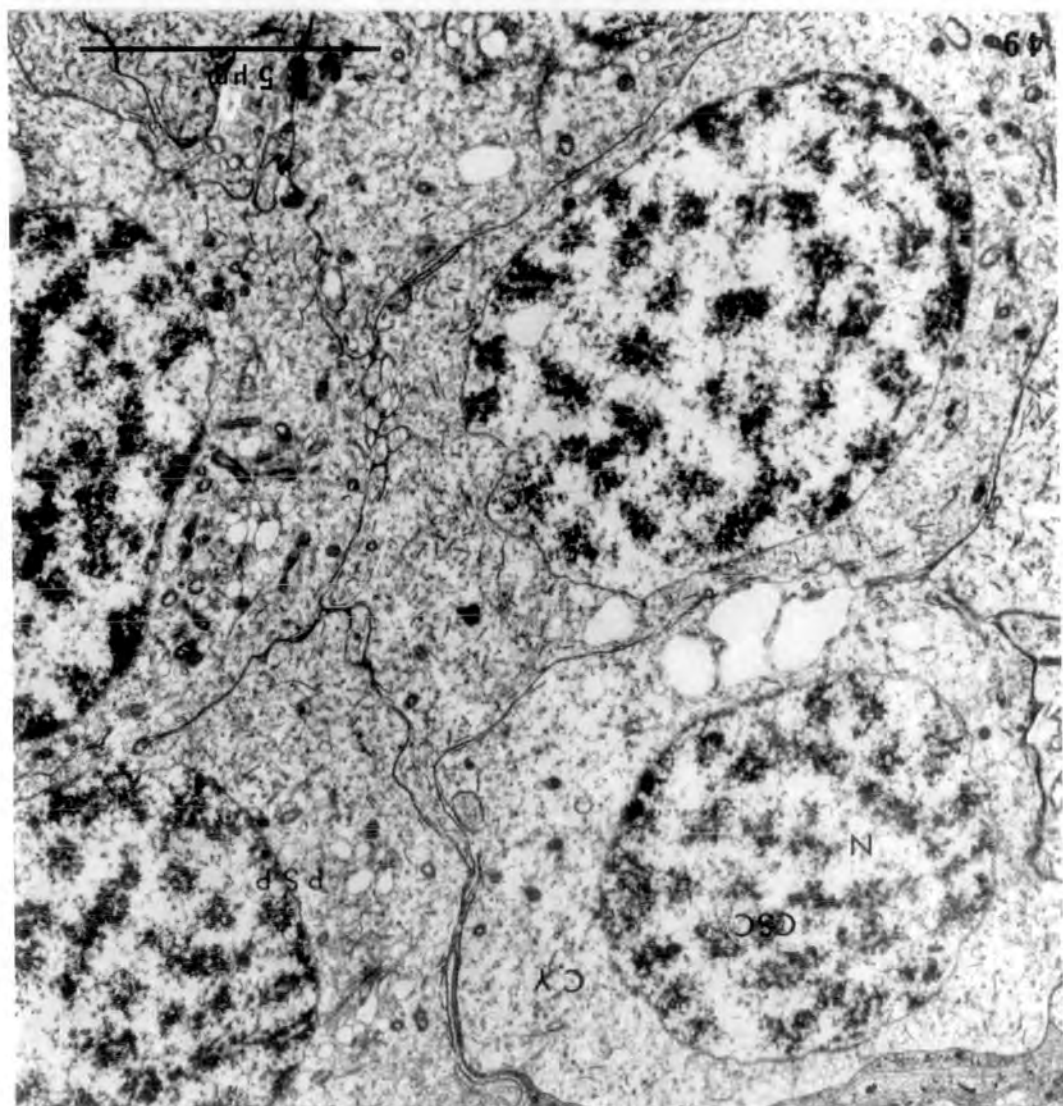
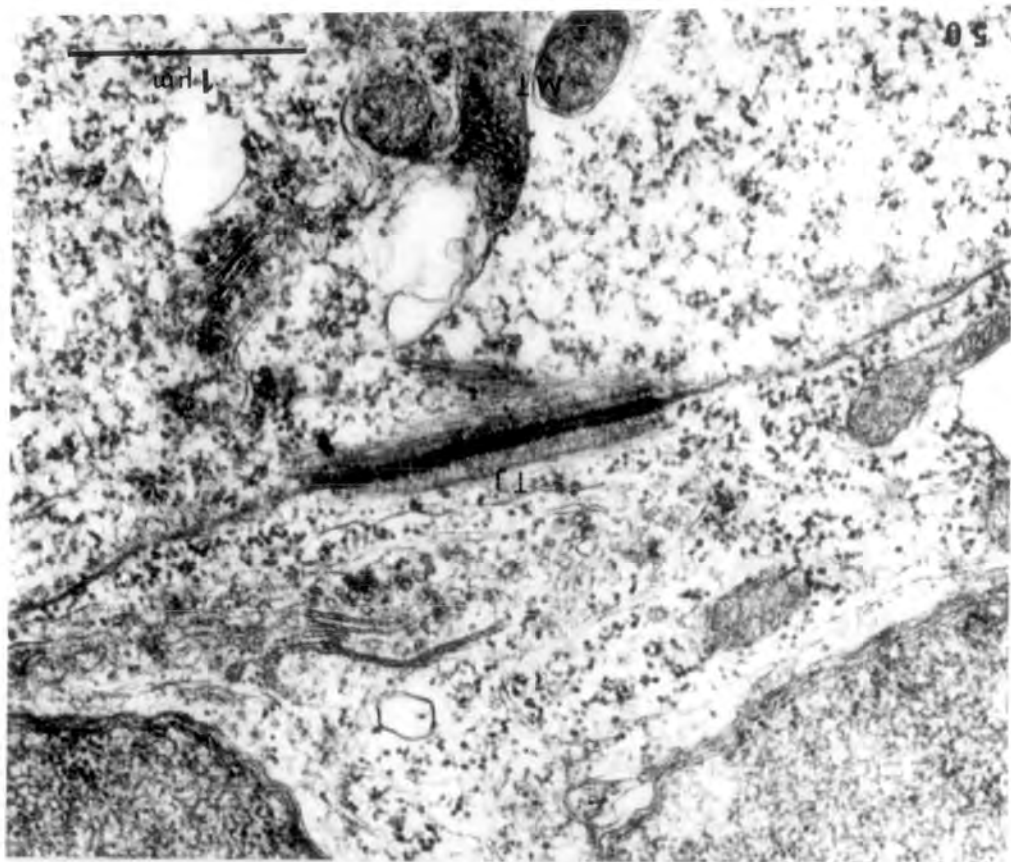


PLATE XVIII

Fig. 49. A nest of primary spermatocytes in synaptene, in the testis of a 4-month old juvenile toad. The cells possess a round nucleus in which interconnected chromosomal synaptonemal complexes are scattered. x 8,000.

Fig. 50. A tight junction between spermatocytes in the same juvenile testis. x 32,000.



Treatment for 26 days (st.50 till 56) with 25, 100
and 500µg/l 17β-oestradiol respectively

PLATE XIX

- Fig. 51. Control, alcohol-treated, st.56 ovaries (♀ N), showing ovarian cavity and some pachytene oocytes in the cortex. x 400.
- Fig. 52. Control, alcohol-treated, st.56 testis (♂ N) showing nests of spermatogonia in the testicular soma surrounded by many somatic cells. x 400.
- Fig. 53. Treatment with 25µg/l. St.56 ovary (♀ N) resembling that of controls. x 400.
- Fig. 54. Treatment with 25µg/l. Gonadal section of a st.56 individual with sex reversed testes having the appearance of inhibited ovaries (♀ +). The one on the left has no trace of an ovarian cavity and instead some medullary cells are present. The right gonad shows the beginning of an ovarian cavity. This tadpole could be a genetic male with inverted testes (see page 41 Vol.1). x 400.

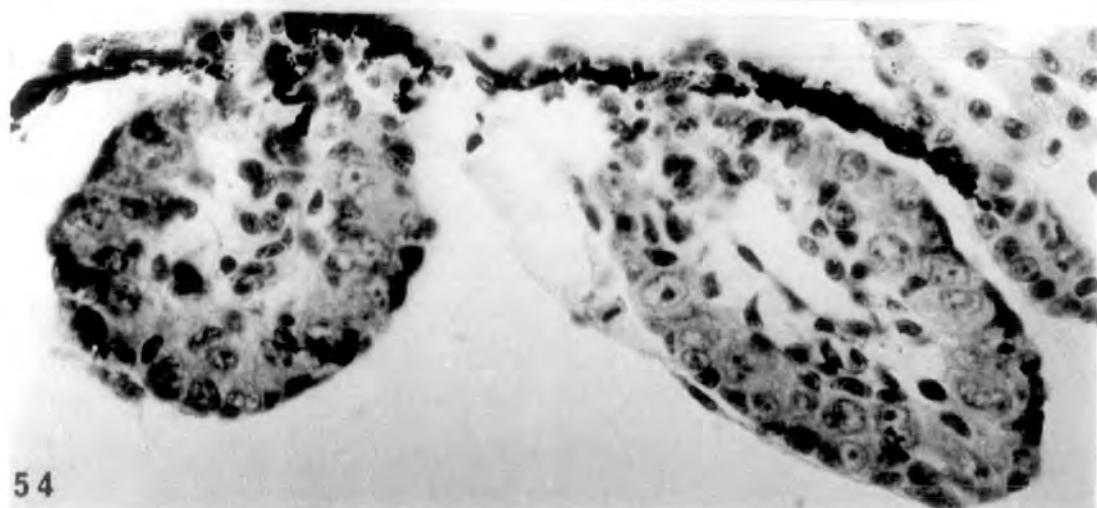
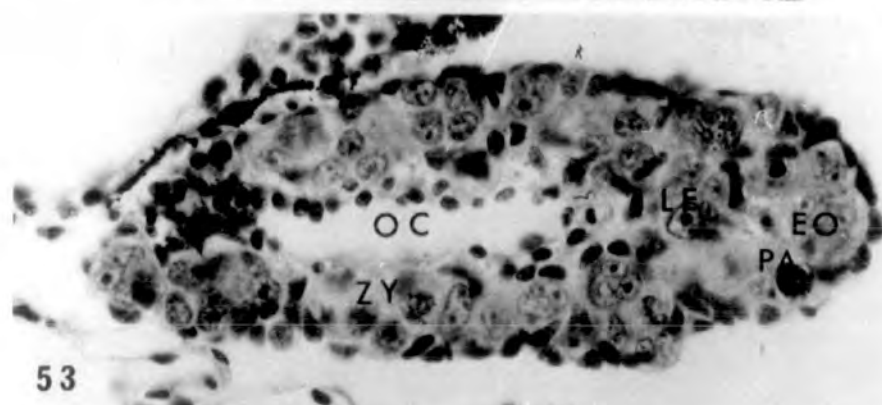
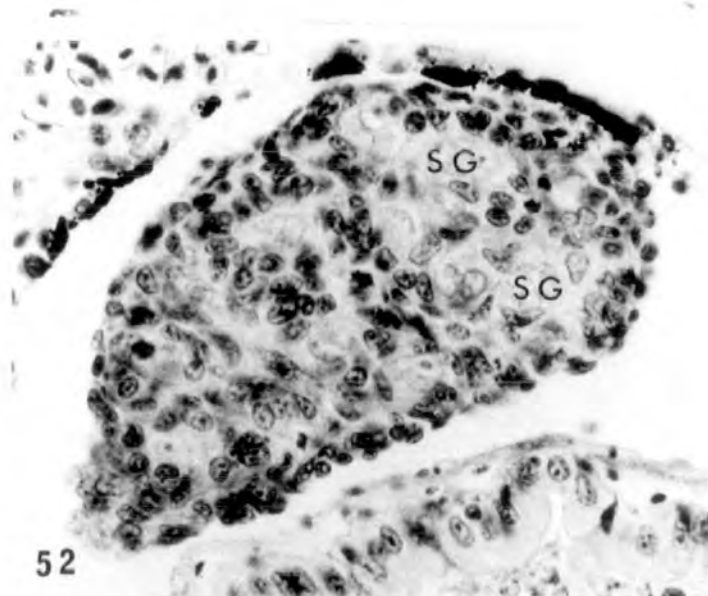
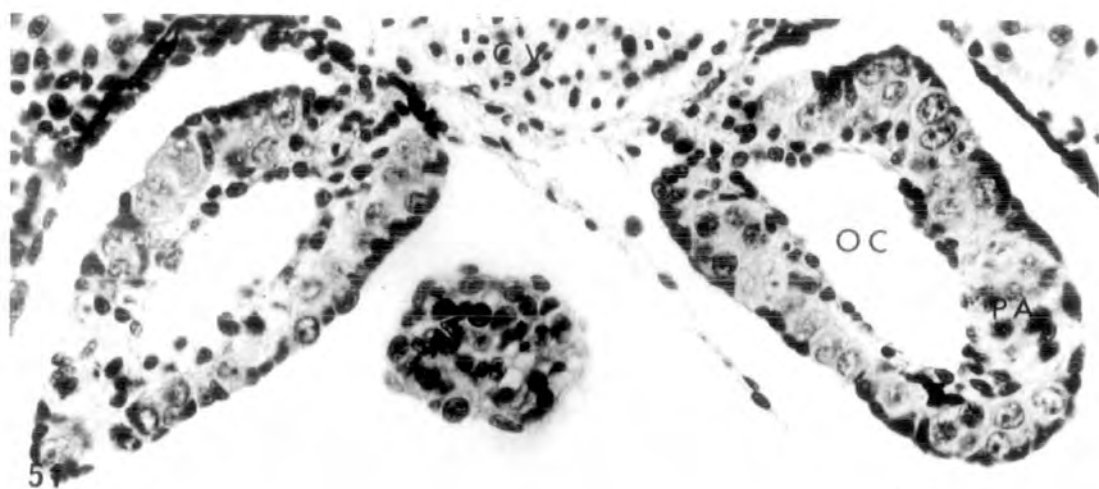
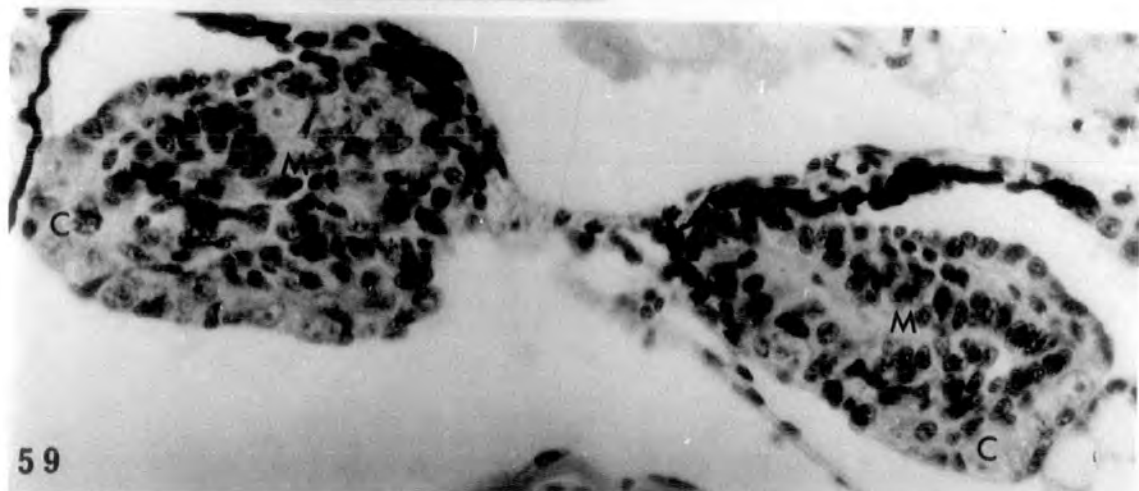
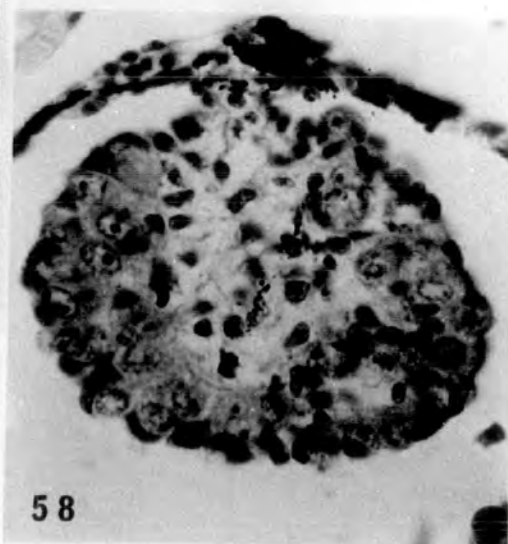
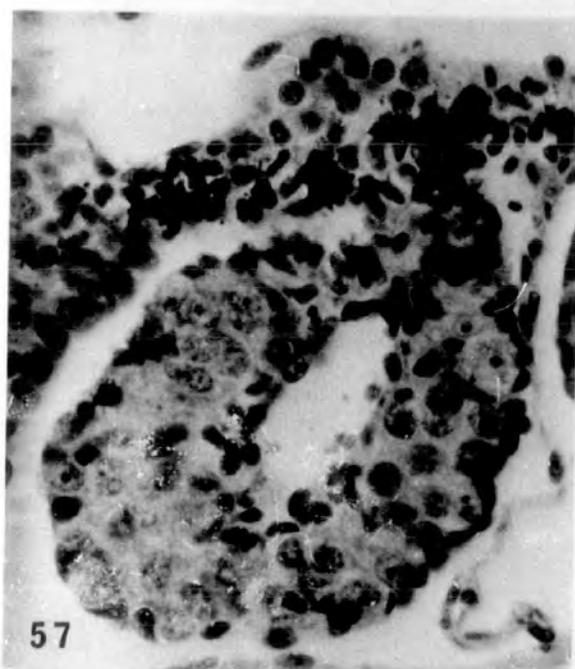
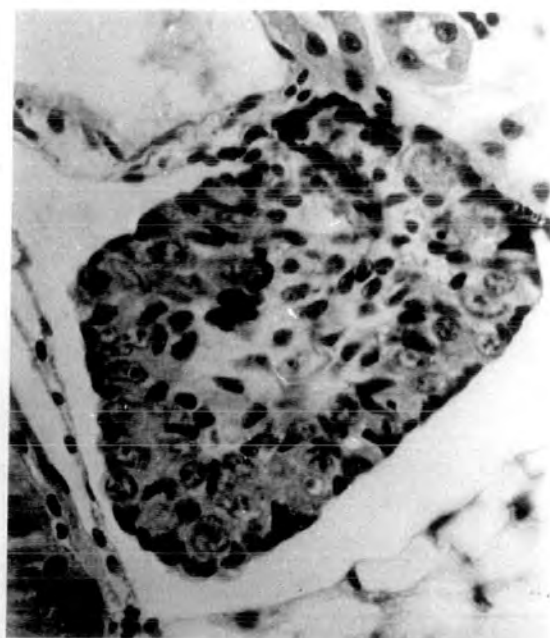
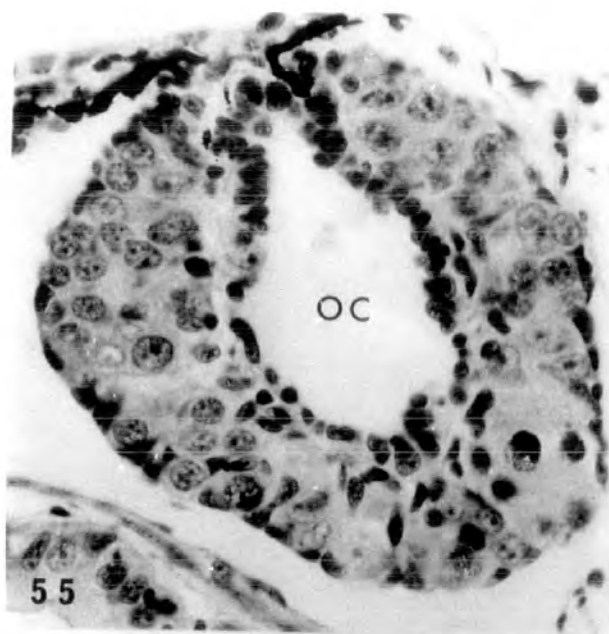


PLATE XX

- Fig. 55. Treatment with 100 μ g/l. Normal st.56 ovary (♀ N) showing large ovarian cavity and pachytene oocytes in the thick cortex. x.400.
- Fig. 56. Treatment with 100 μ g/l. Inhibited ovary or inverted testis (♀ †) from a st.56 individual, showing no obvious ovarian cavity or any pachytene stage oocytes in the cortex. x 400.
- Fig. 57. Treatment with 500 μ g/l. Normal st.56 ovary (♀ N). x 400.
- Fig. 58. Treatment with 500 μ g/l. Inhibited ovary or an inverted testes (♀ †) from a st.56 individual probably a genetic male. x 400.
- Fig. 59. Treatment with 500 μ g/l. Anterior region of intersexual gonads (♀ ♂) at st.56 possessing distinct cortex and medulla. There is a trend towards maleness since the medullary tissue occupies most of the gonadal area. x 400.



Treatment with 2mg/l oestradiol
(st.51-57)

PLATE XXI

Fig. 60. Control, alcohol-treated, st.57 ovary (♀ N)
showing many pachytene oocytes in the thick
cortex. x 400.

Fig. 61. Control, alcohol-treated, st.57 testis (♂ N).
x 400.

Figs. 62-63. The 2mg/l oestradiol treatment caused
varying degrees of intersexuality and even
masculinization (♀[♂]). The left gonad
(62) is intersexual showing distinct cortex
and medulla whilst the right one (63) is
highly testicular. Note also the tremendous
interrenal hyperplasia.

62 x 160

63 x 400

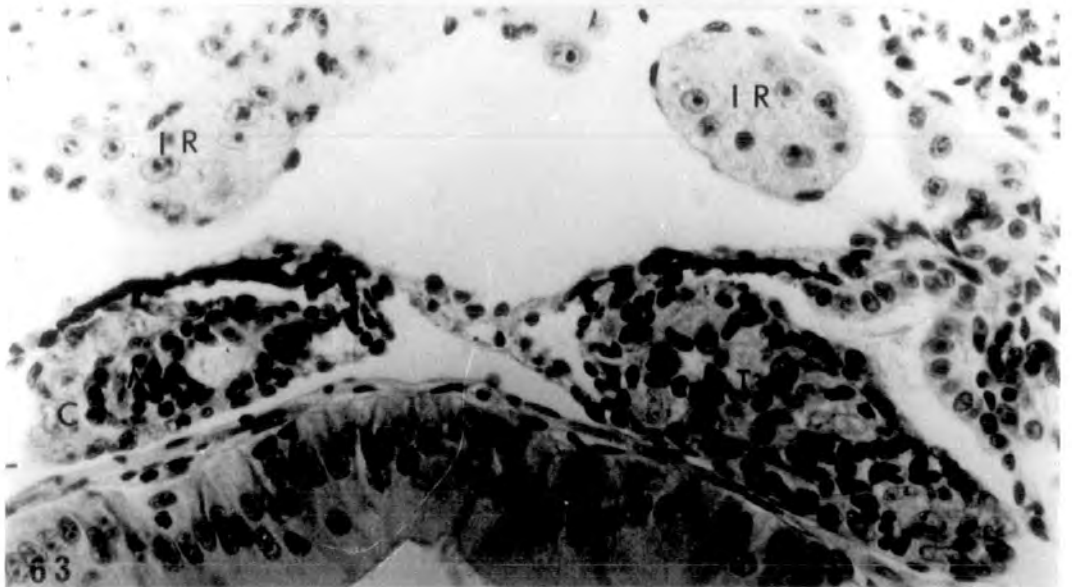
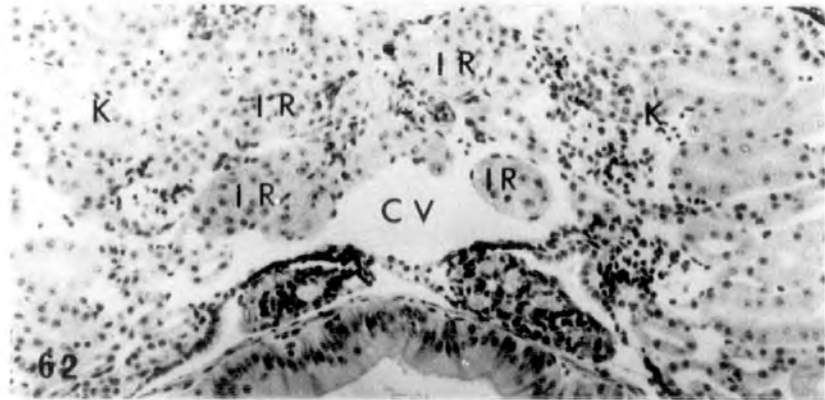
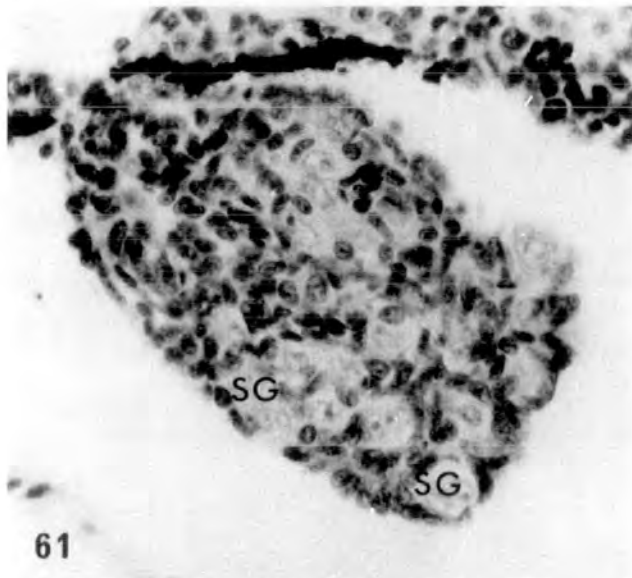
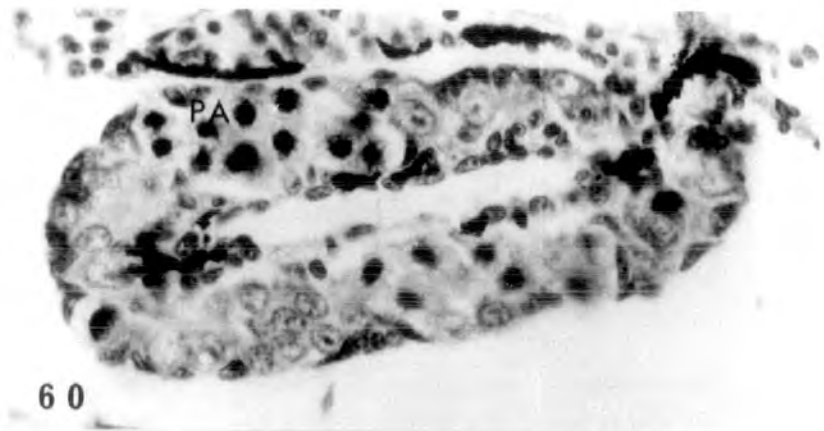


PLATE XXII

Figs. 64-66. Testicular sections from anterior to posterior end. Frontal gonadal region (64) showing testes with large cavities. The cavity at the hilum of each testis could be precocious Wolffian duct development due to the high dose of steroid. The rest of the gonads (65-66) resemble normal testes (♂ Abn). x 400.

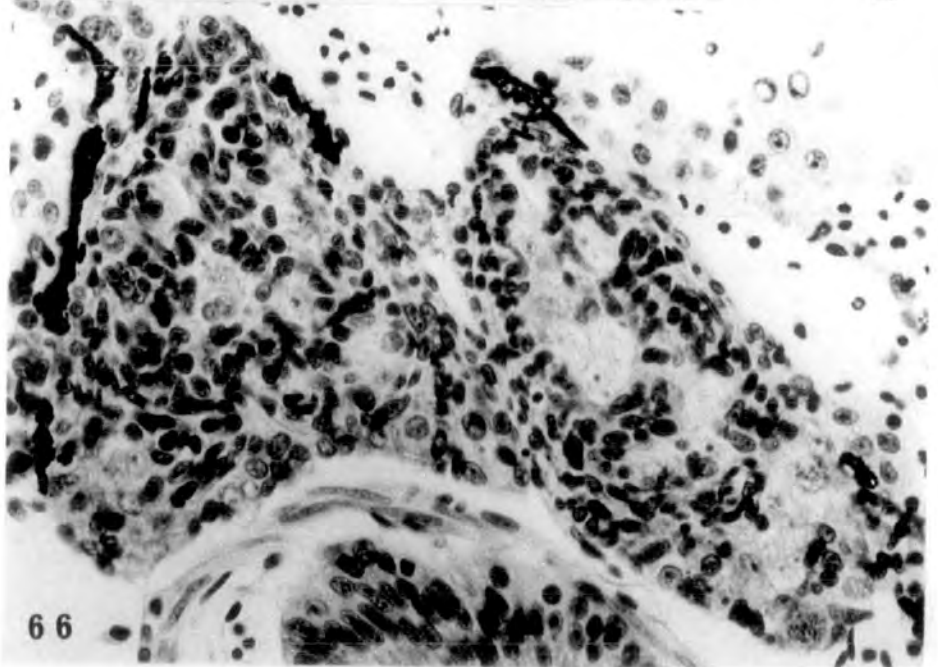
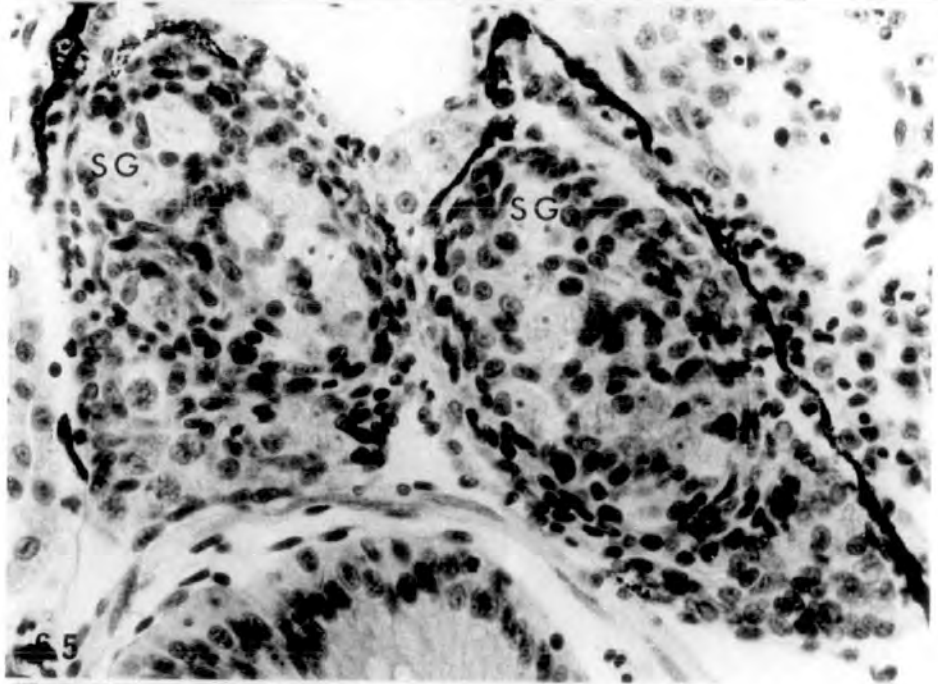
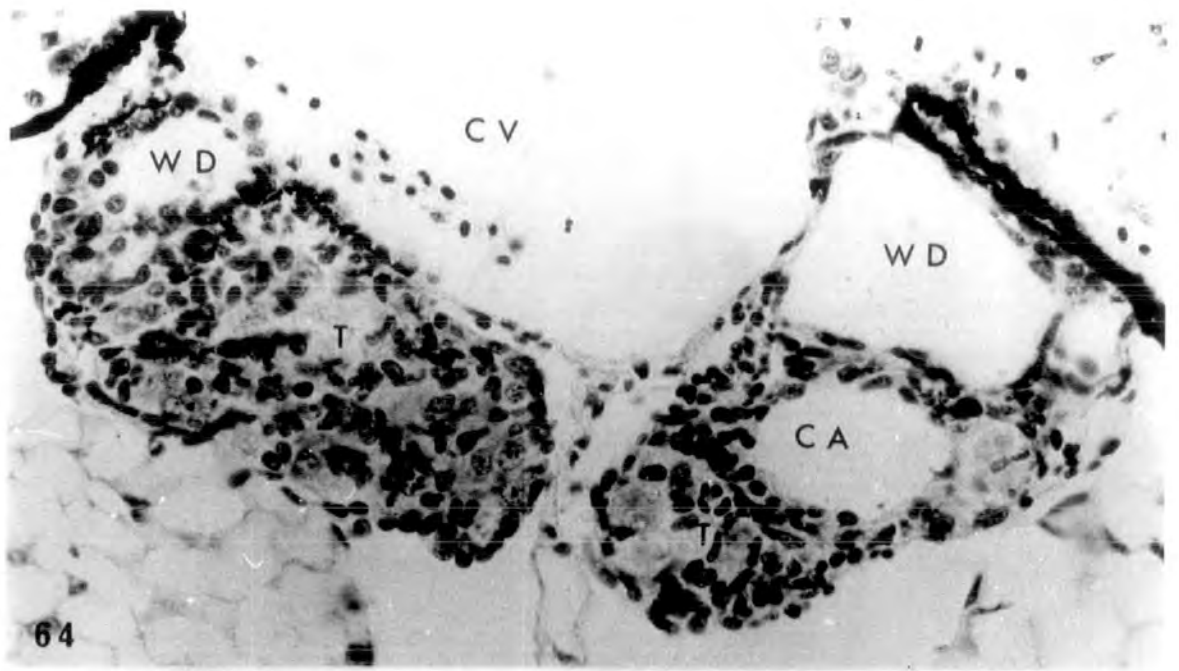


PLATE XXIII

Figs. 67-70. Sections of the same tadpole from anterior to posterior end. The anterior gonadal region (67-69) consists of testes (or inverted ovaries) with precocious Wolffian duct development at the hilum. The duct is lined by cubical epithelium. The posterior part of the gonadal region (70) is intersexual. Zygotene and pachytene oocytes are present but there is no ovarian cavity. (♂-♂). x 400.

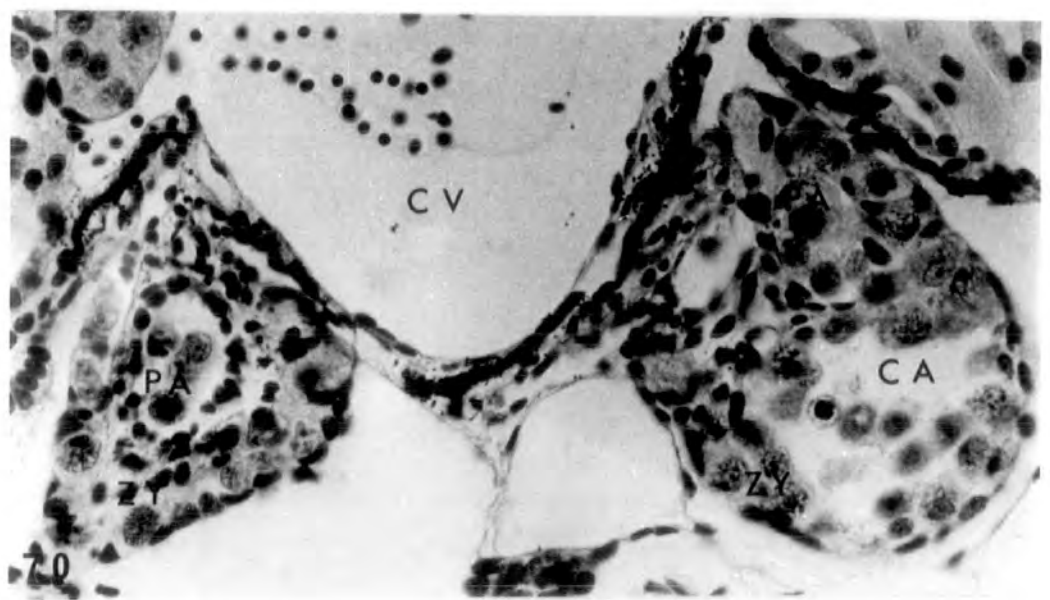
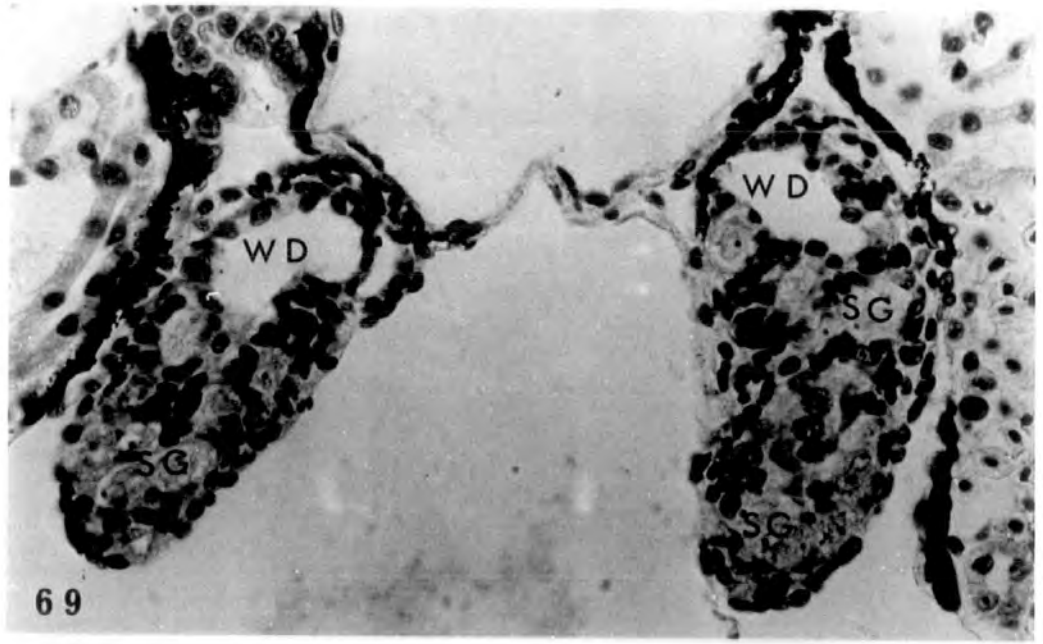
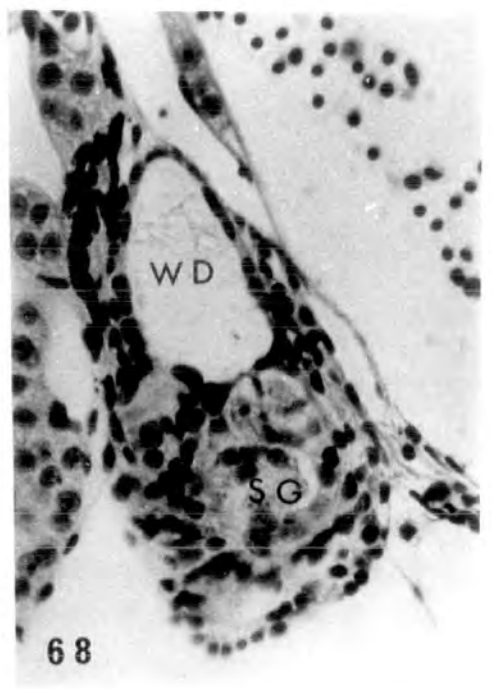
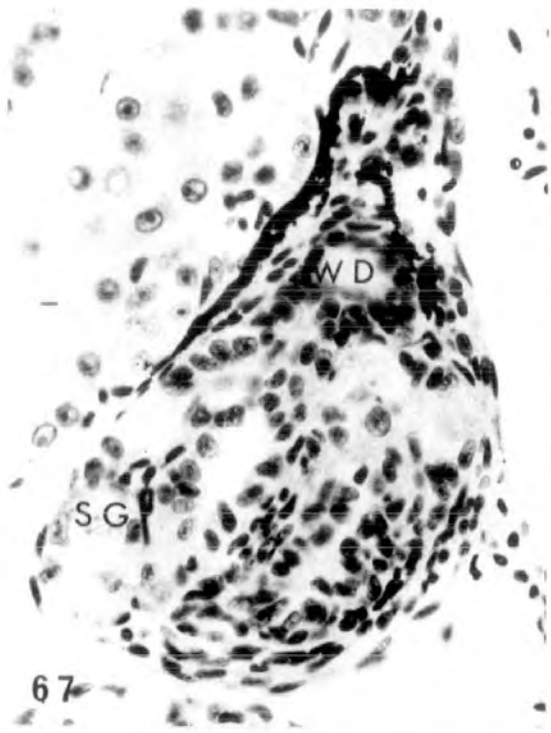


PLATE XXIV

Figs. 71-73. Sections from the same tadpole showing a highly masculinized anterior gonadal region (left and right gonads in 71 & 72 respectively) and a caudal intersexual region (♀♂). Note interrenal hyperplasia. x 400.

Figs. 74-75. Anterior and posterior gonadal regions showing small ovaries with thin cortex almost completely devoid of germ cells. Absence of germ cells could indicate sterility (♀ S). x 400.

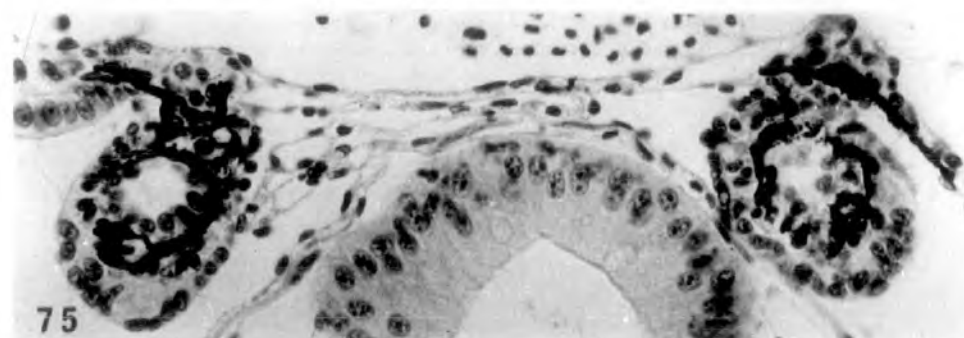
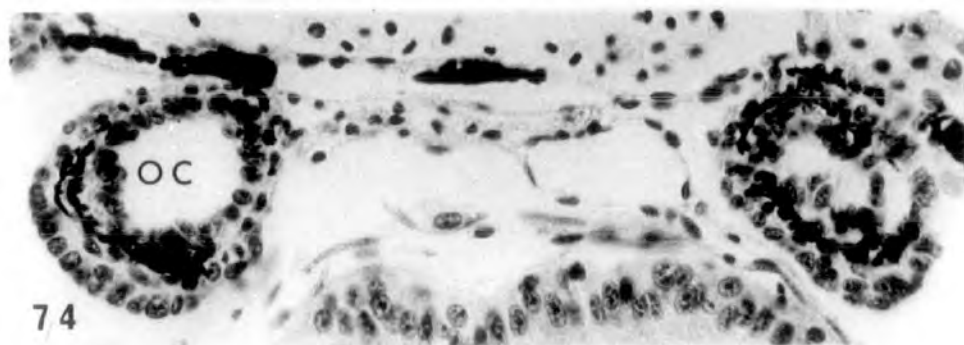
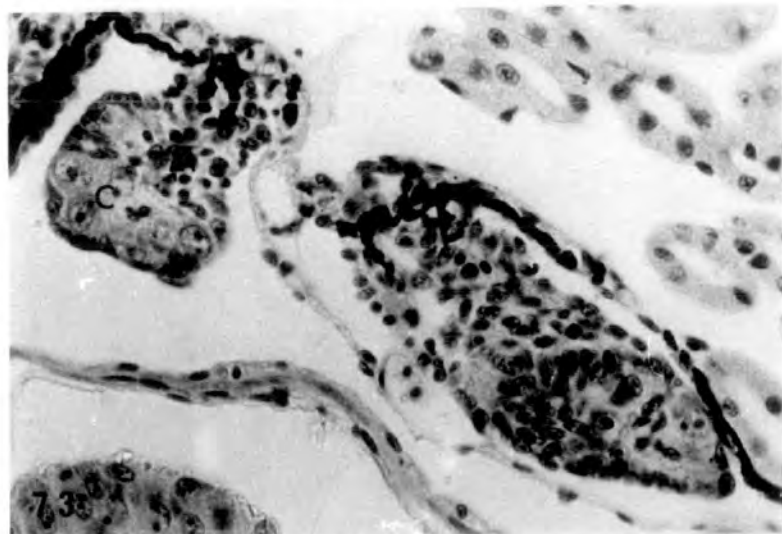
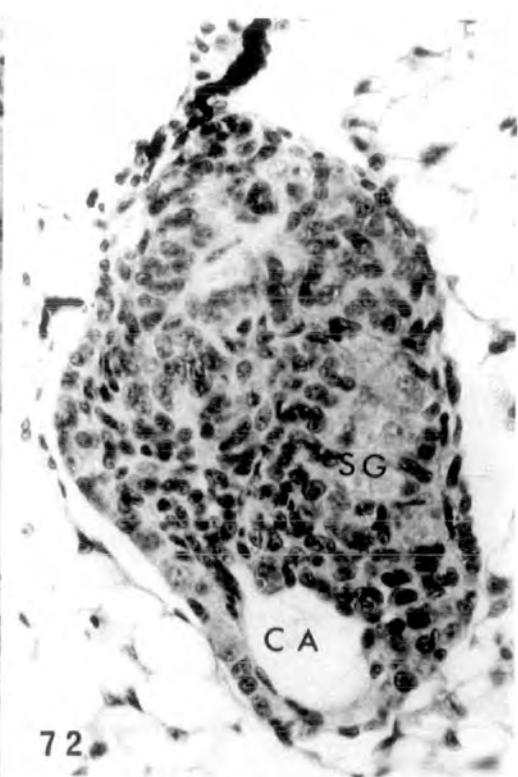
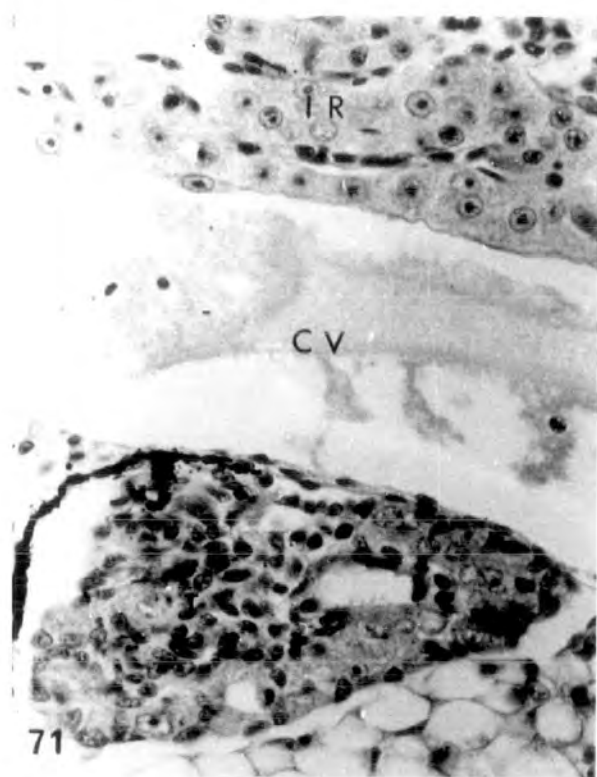
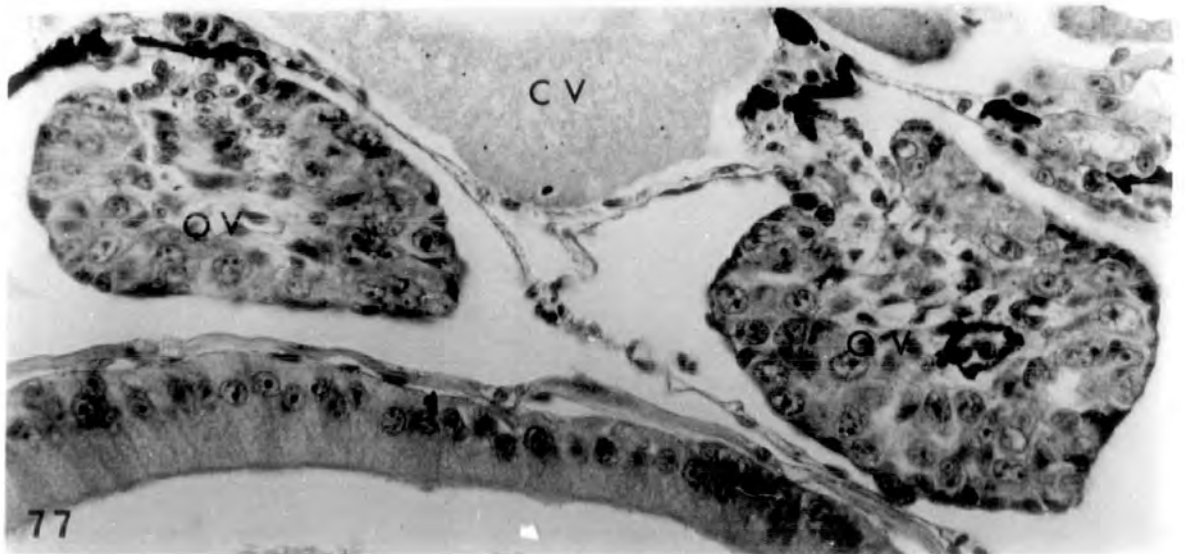
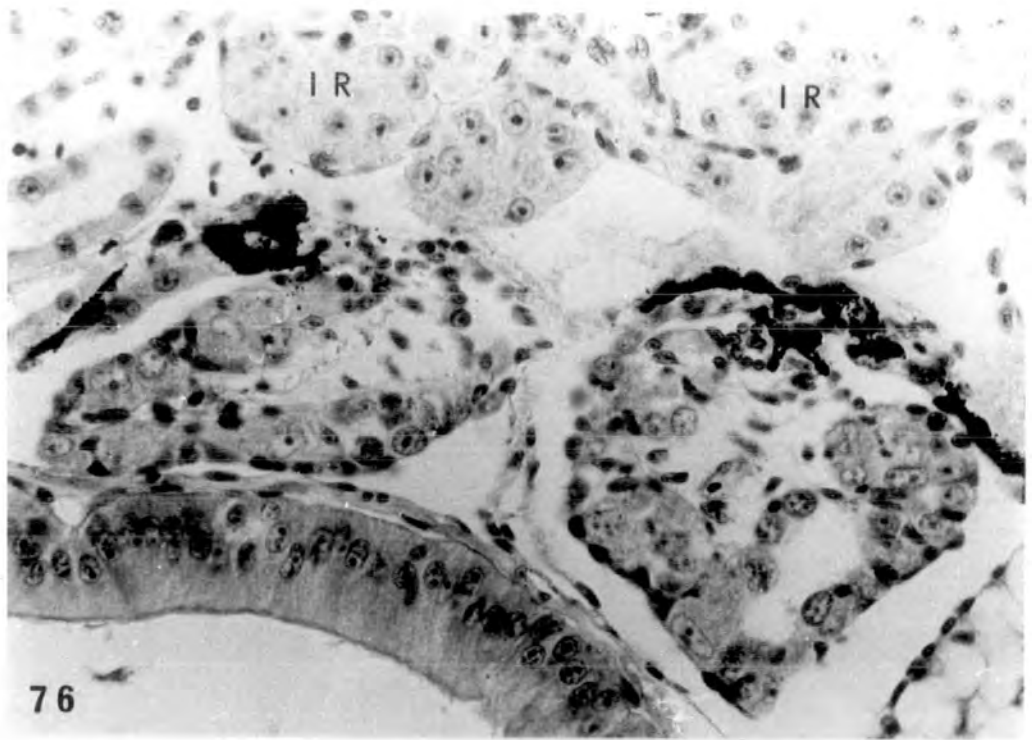


PLATE XXV

Fig. 76. Inhibited ovaries due to high dose steroid treatment (♀ †). There is no clear ovarian cavity and no pachytene oocytes in the cortex. Some cortical excavation has taken place. Interrenal hyperplasia evident. x 400.

Fig. 77. Inhibited ovaries (♀ †) from another larva. x 400.



Effect of the high dose oestradiol-treatment on the
larval body (teratogenic effects)

PLATE XXVI

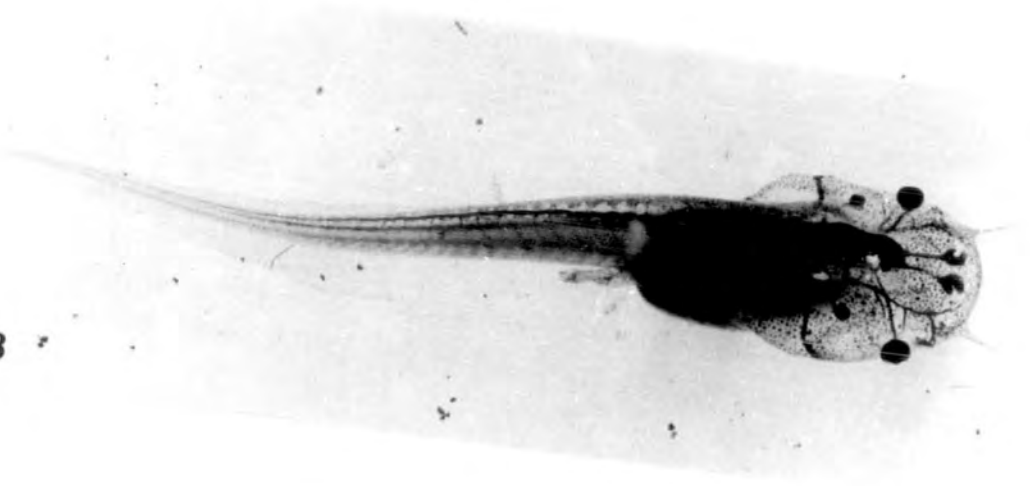Fig. 78. A st.56 normal, alcohol treated, larva.

x 2.5.

Fig. 79. Treatment with 2mg/l oestradiol for 26 days
(st.50-56) caused branching of the tentacles.

x 2.5.

78



79

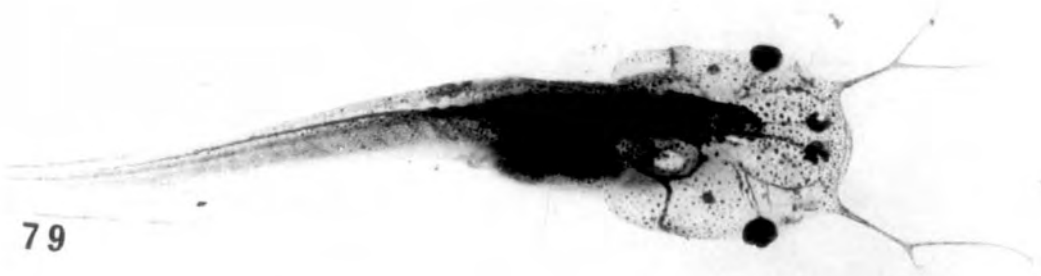
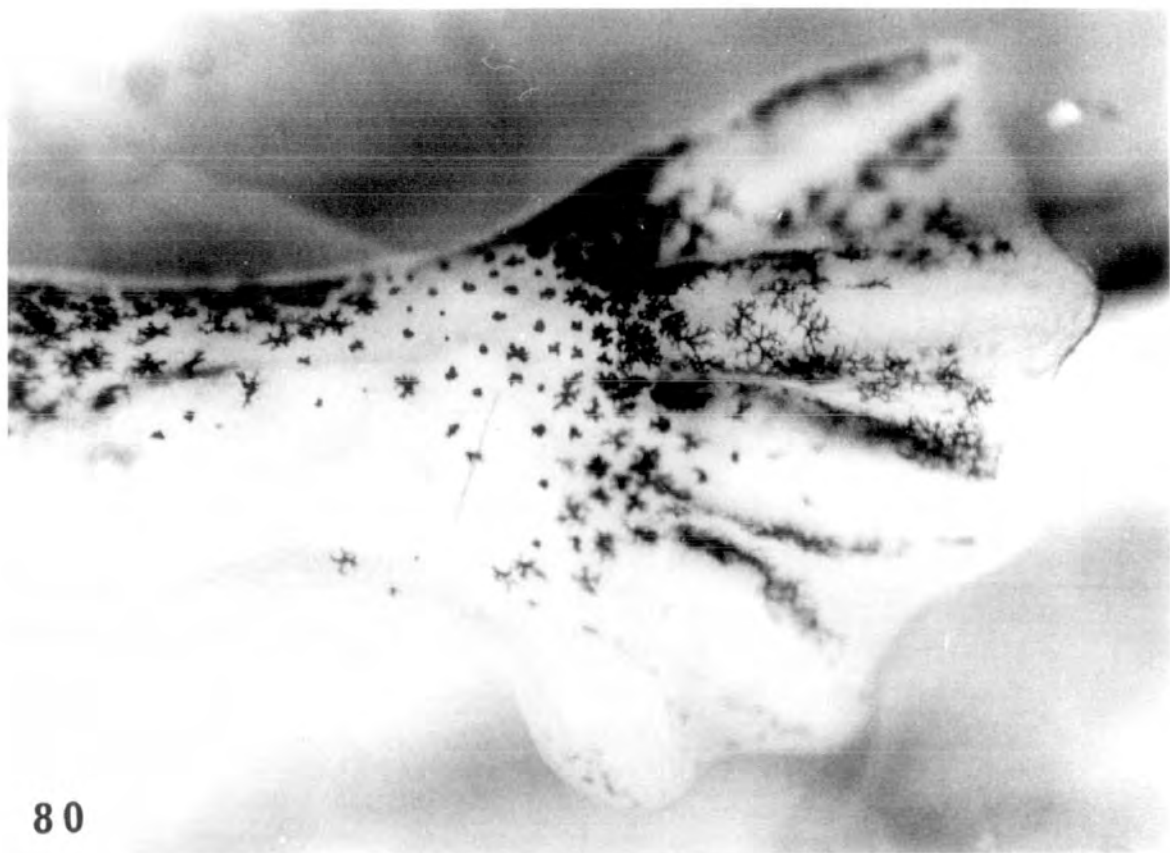
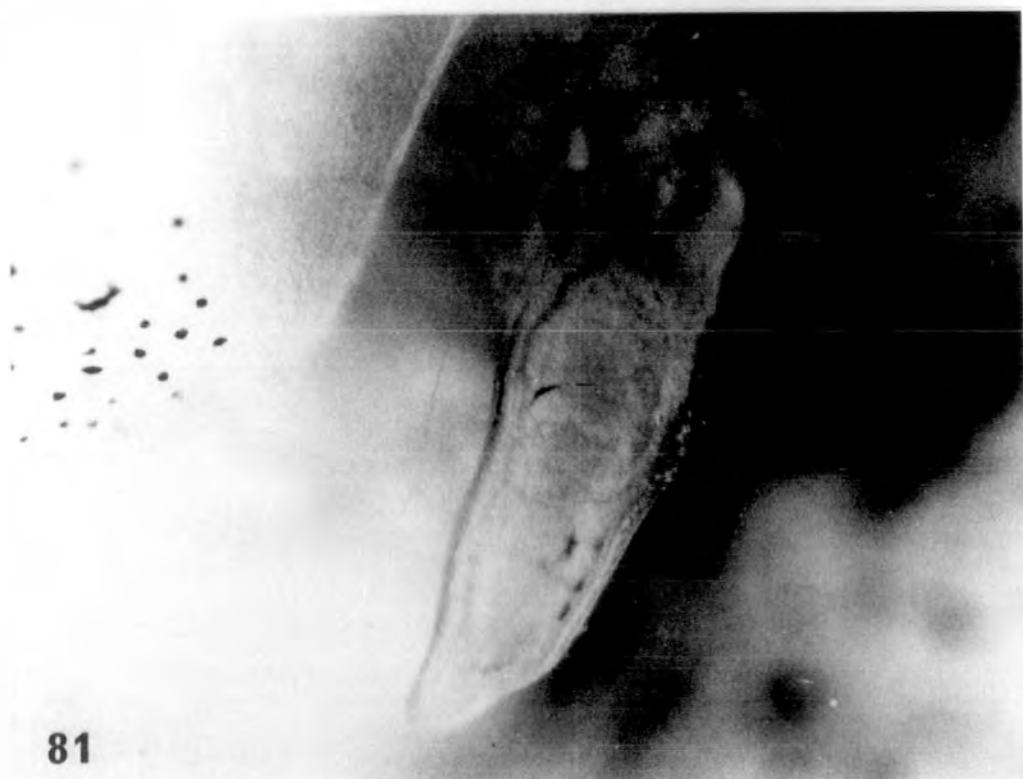PLATE XXVII

Fig. 80. Left hind limb of st.56 control, alcohol treated larva. x 225.

Fig. 81. Larva treated with 2mg/l oestradiol for 26 days (st.50-56) developed a foot-stump devoid of any toes. x 225.



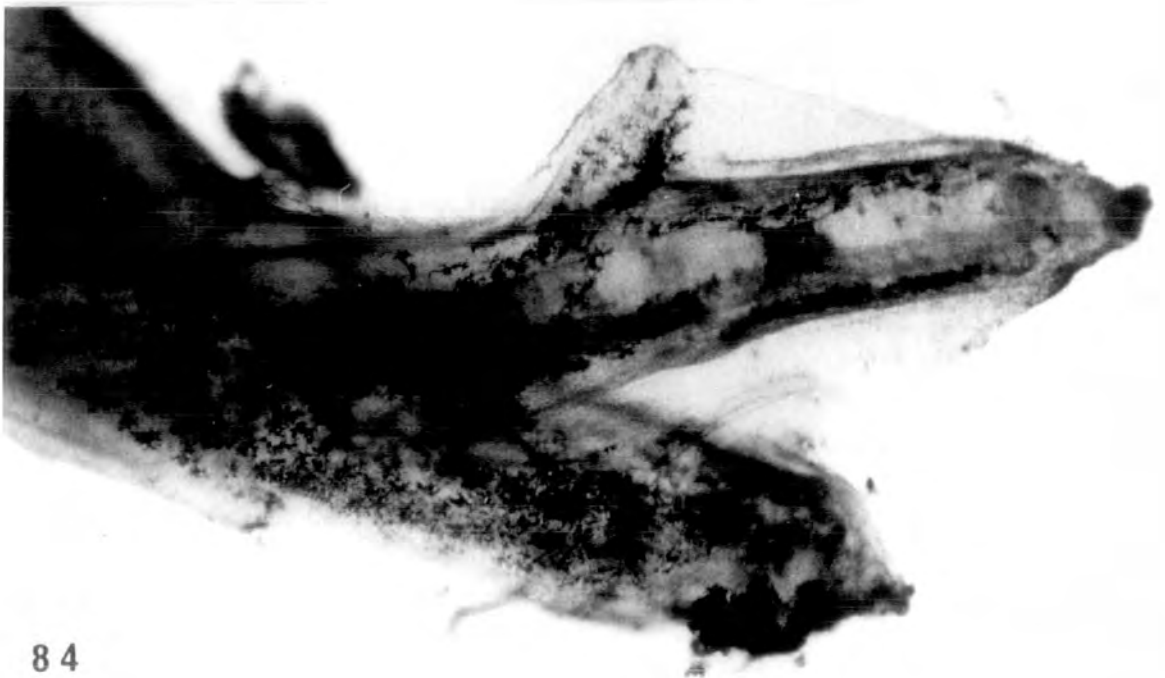
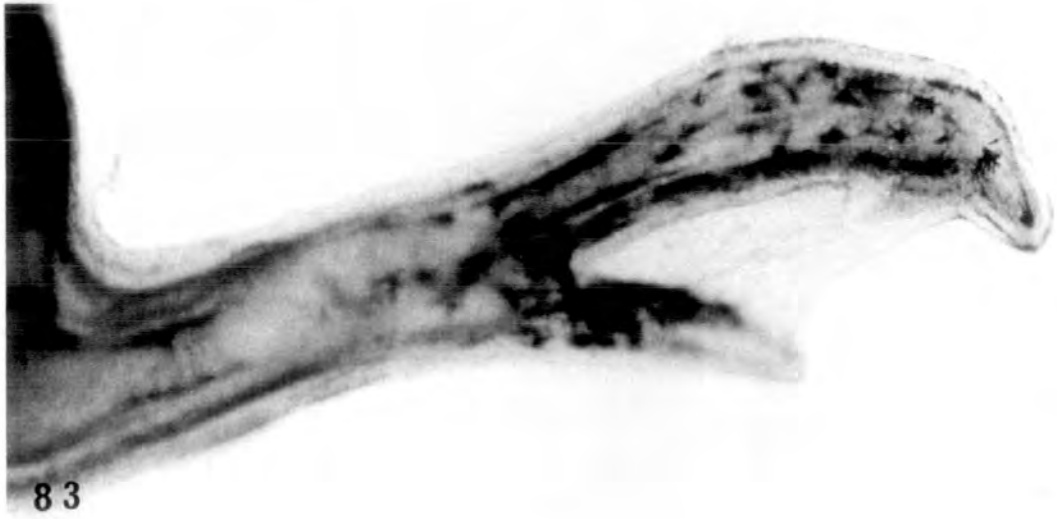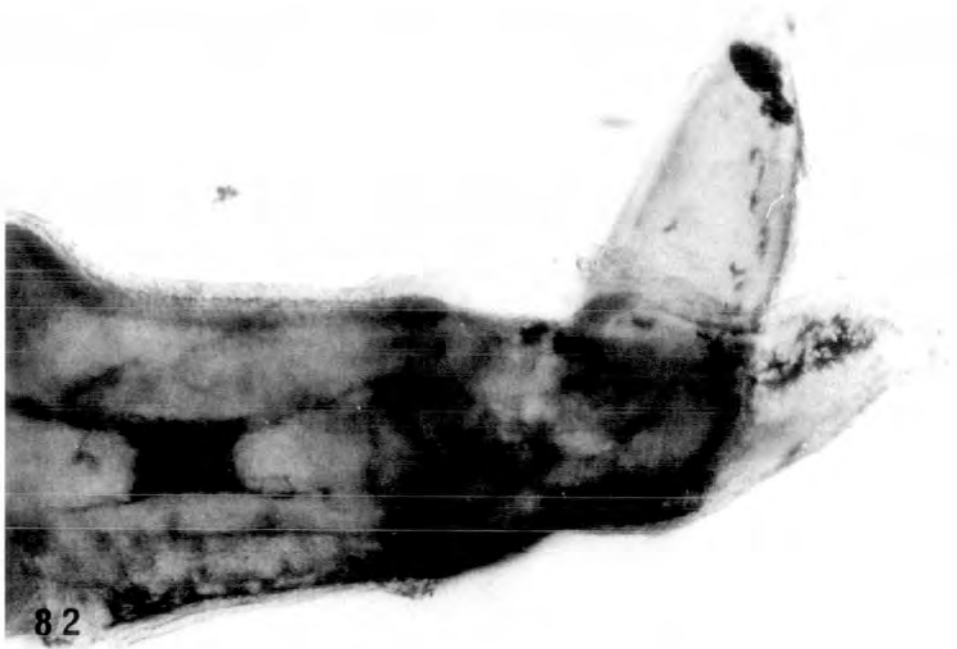
80



81

PLATE XXVIII

Figs. 82-84. Right hind limb from three different tadpoles treated with 2mg/l oestradiol for 26 days (st.50 to 56). The first has two toes and the second and third three toes. x 210.

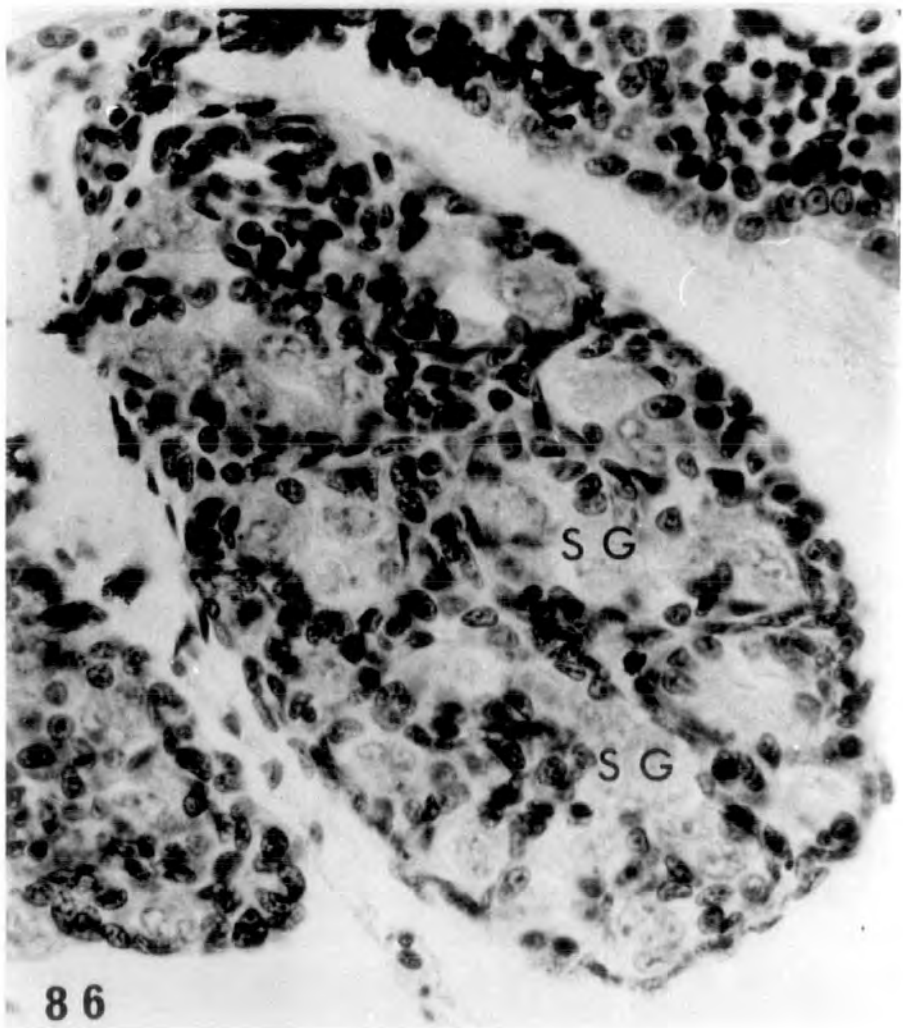
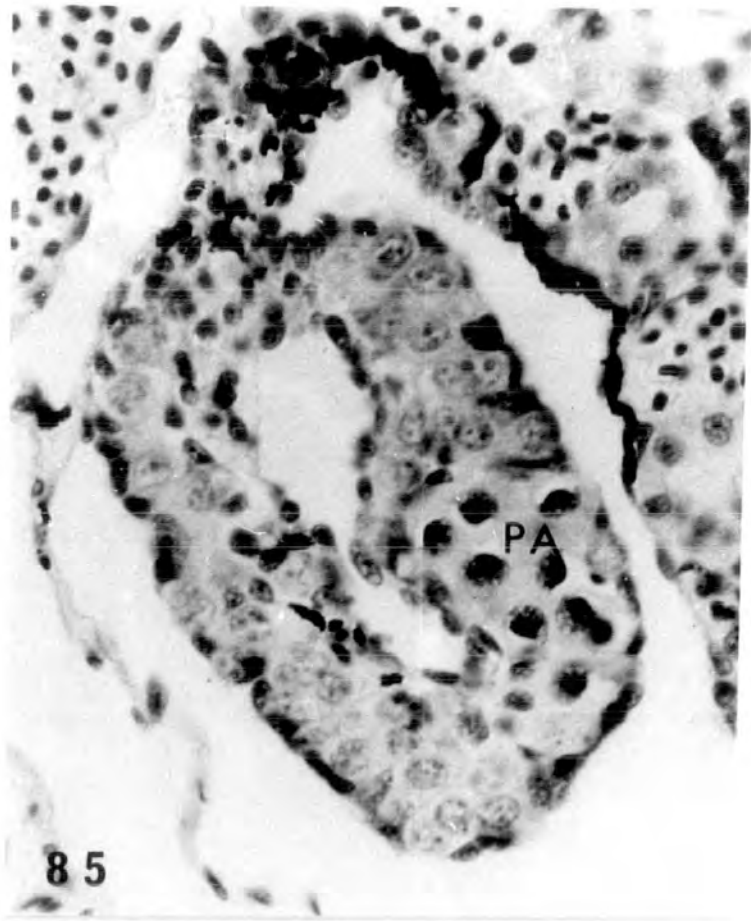


Treatment for 26 days (st.51 till st.57) with 25,
100, 500 μ g/l and 2mg/l of β -oestradiol-3-benzoate
respectively

PLATE XXIX

Fig. 85. St.57 control, alcohol treated. Right ovary shows obvious ovarian cavity and pachytene oocytes in the cortex (♀ N).
x 575.

Fig. 86. St. 57 control, alcohol-treated, right testis showing many nests of spermatogonia in the testicular soma (♂ N). x 575.



Treatment with 25µg/l

PLATE XXX

Figs. 87-88. Left gonad highly testicular and
right gonad an inhibited ovary (♂[†]).
x 500.

Fig. 89. Normal right ovary showing ovarian
cavity and pachytene oocytes in the
thick cortex (♀ N). x 500.

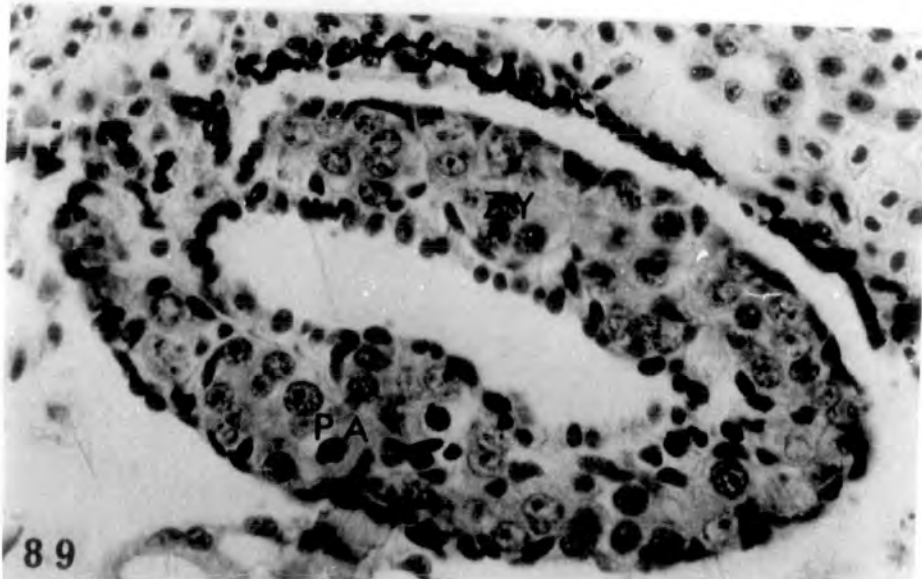
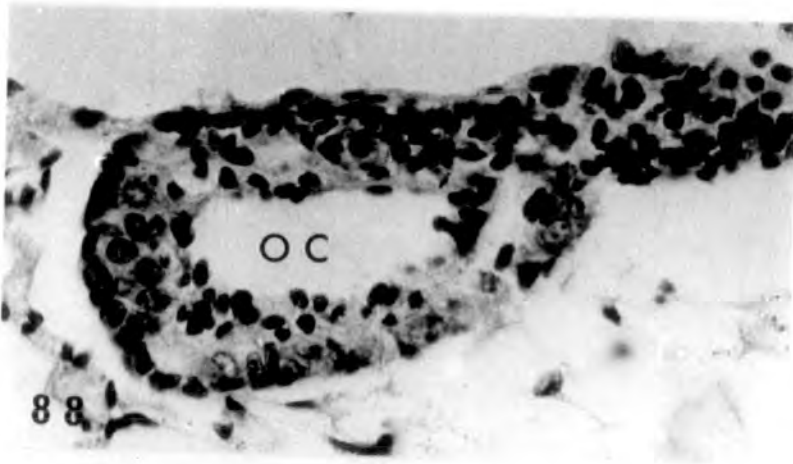
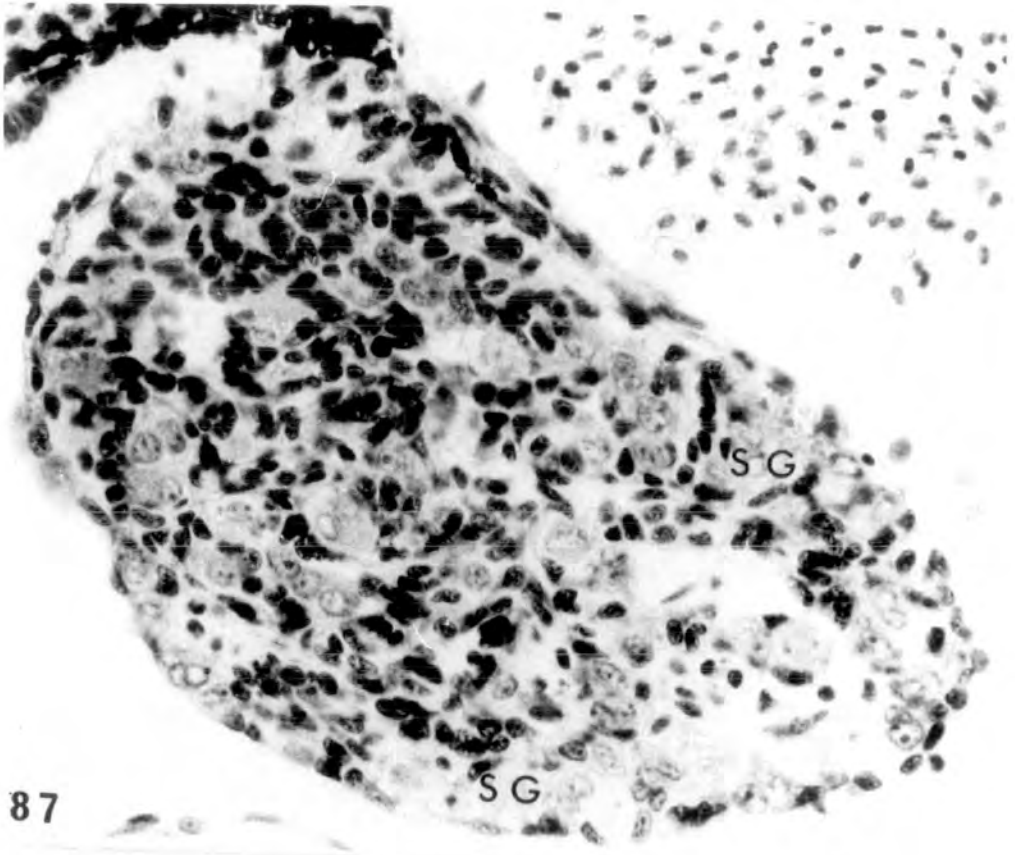
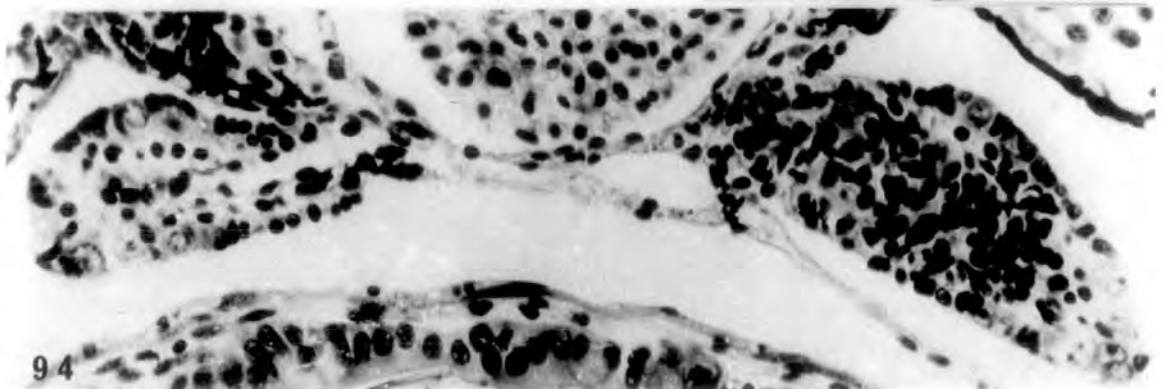
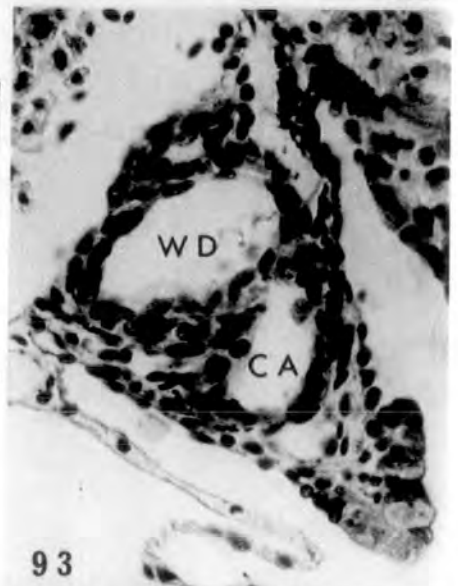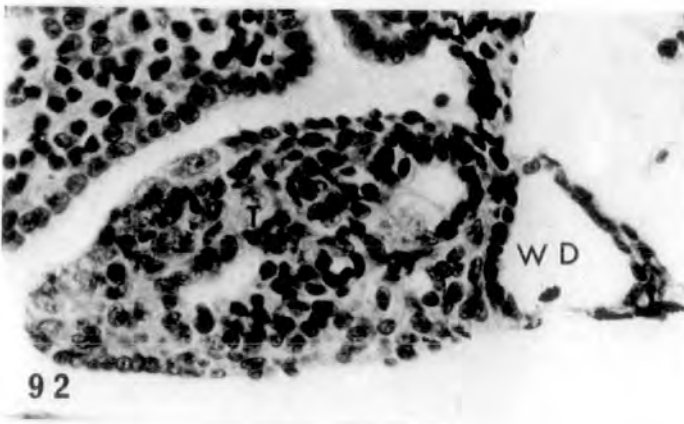
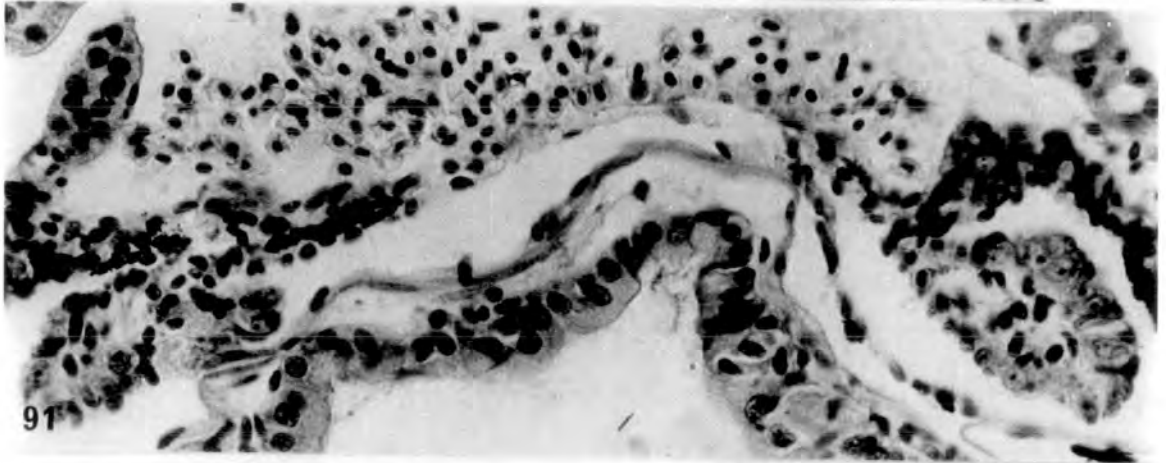
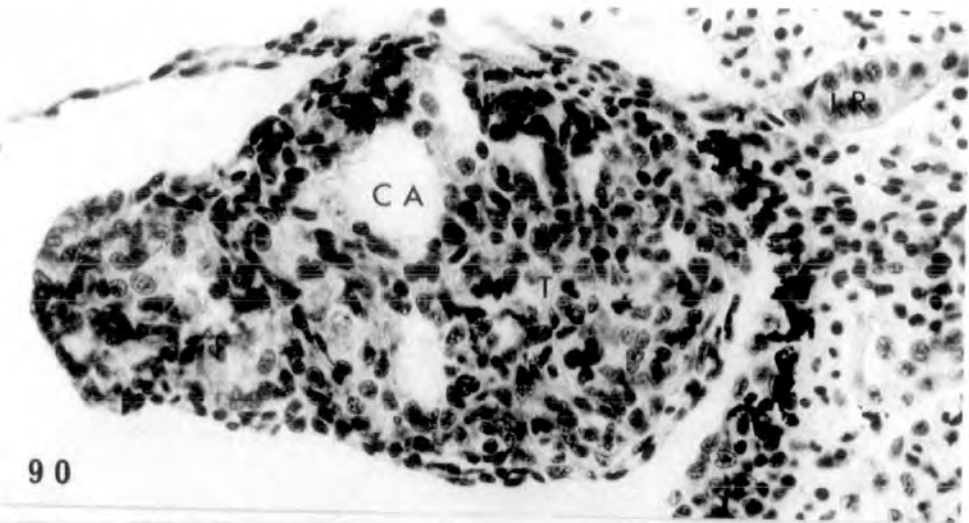


PLATE XXXI

Figs. 90-91. Anterior gonadal region (90) large and testicular showing some excavation in the soma, and posterior region (91) intersexual (♂-♀). x 400.

Figs. 92-94. Anterior gonadal region (92-93) showing testes with large cavities. The cavity at the hilum which is lined by a single layer epithelium, could be precocious development of the Wolffian duct. The posterior region (94) is intersexual (♂-♀). x 400.

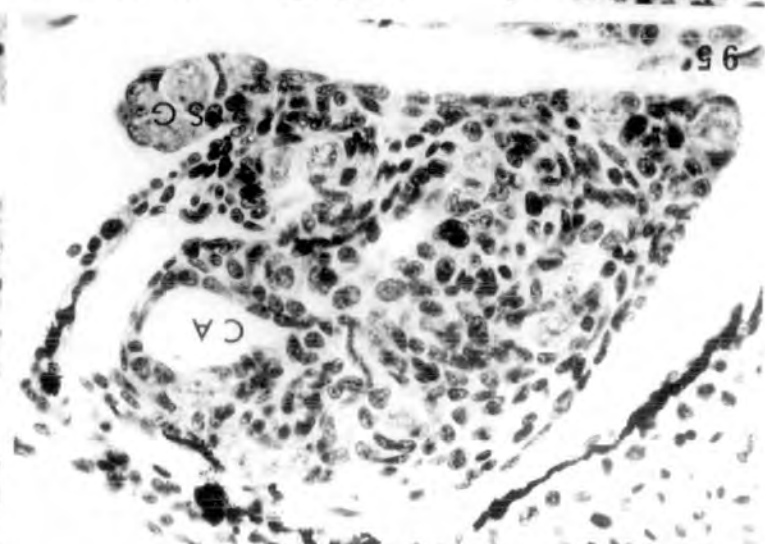
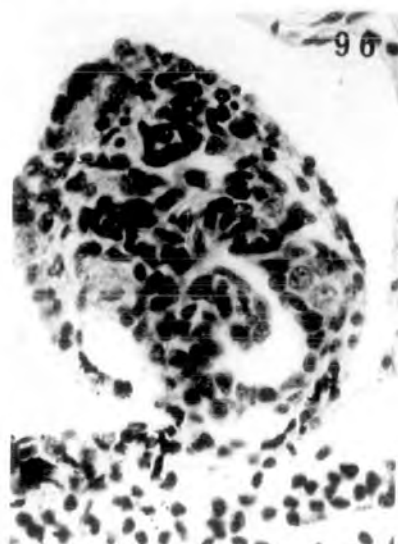
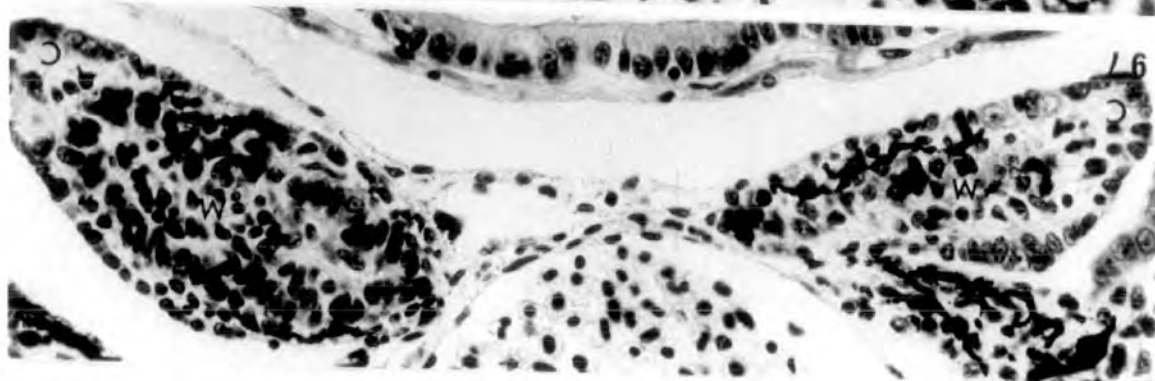
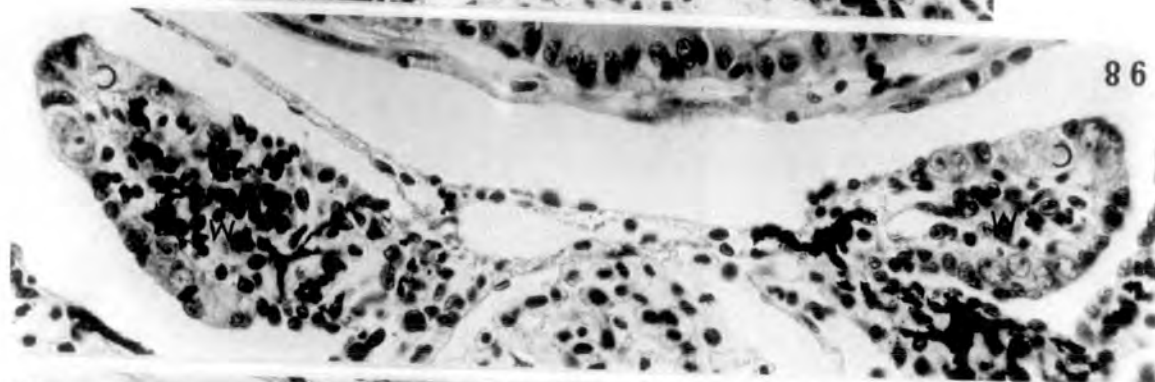
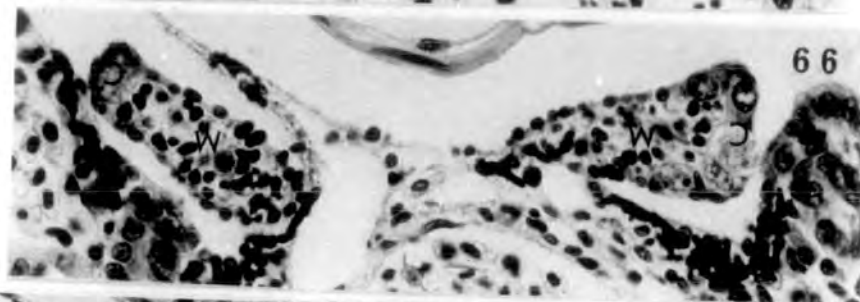
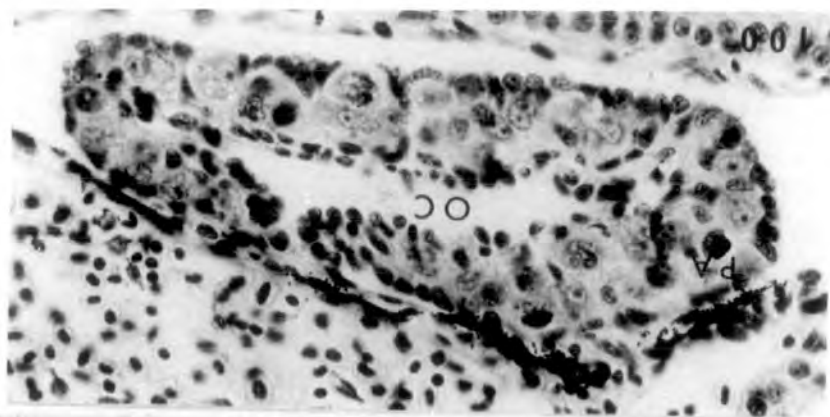


Treatment with 100µg/l

PLATE XXXII

Figs. 95-99. Testicular structures with some cavities in the soma at the anterior end (95-96) and at the posterior end (97-99) intersexual gonads with distinct cortex and medulla (♂-♂).
x 400.

Fig. 100. Normal ovary showing ovarian cavity and pachytene oocytes in the cortex (♀ N). x 400.

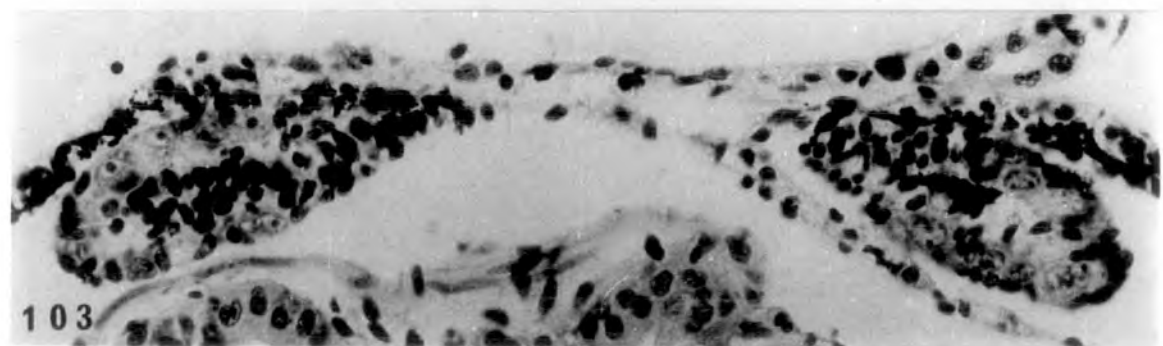
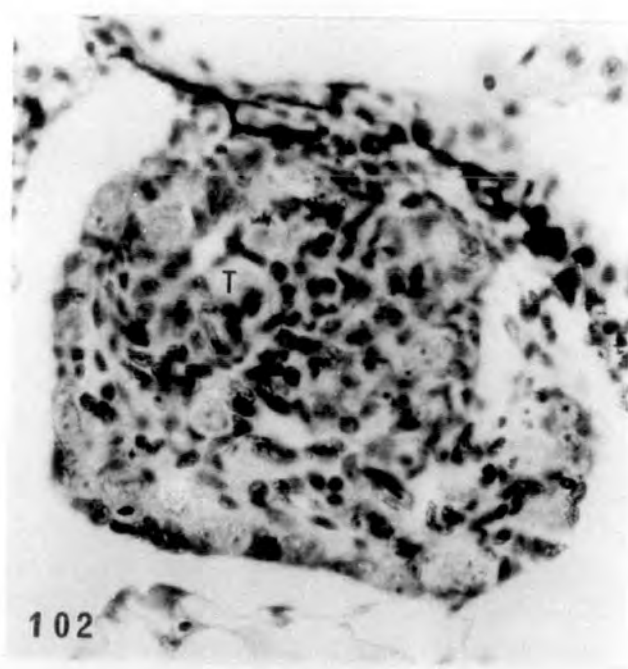
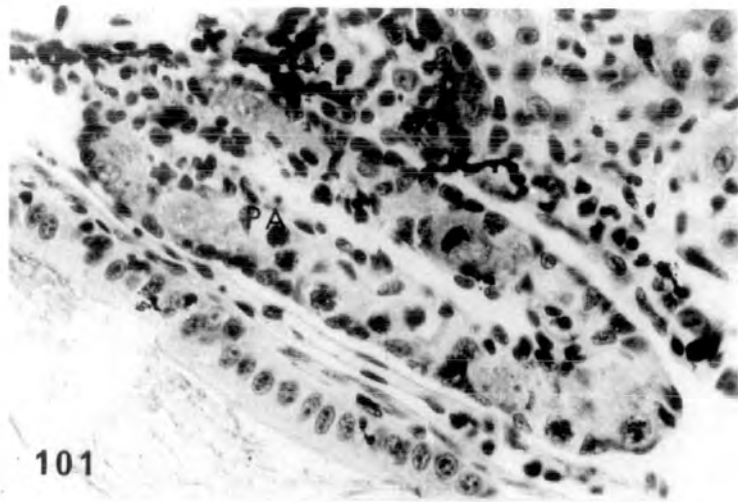


Treatment with 500µg/l

PLATE XXXIII

Fig. 101. Normal ovary (♀ N). x 400.

Figs. 102-103. Gonads highly testicular
(102) at the anterior gonadal
end and intersexual (103) at the
posterior end (♀[♂]-♂[♂]). x 400.

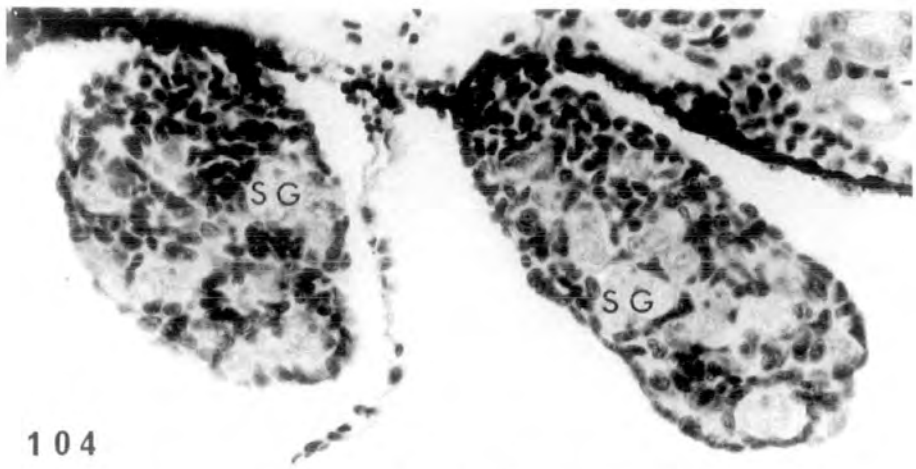


Treatment with 2mg/l

PLATE XXXIV

Figs. 104-106. This individual possesses masculine gonads, with normal testicular structure at the anterior end (104) and inhibited testes at the posterior end (105-106) ($\vec{\sigma}$ - σ). x 400.

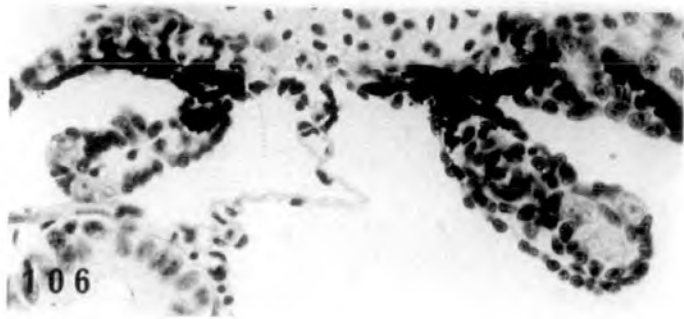
Figs. 107-108. Anteriorly (107) normal testicular structures and posteriorly (108) inhibited testes ($\vec{\sigma}$ - σ). x 400.



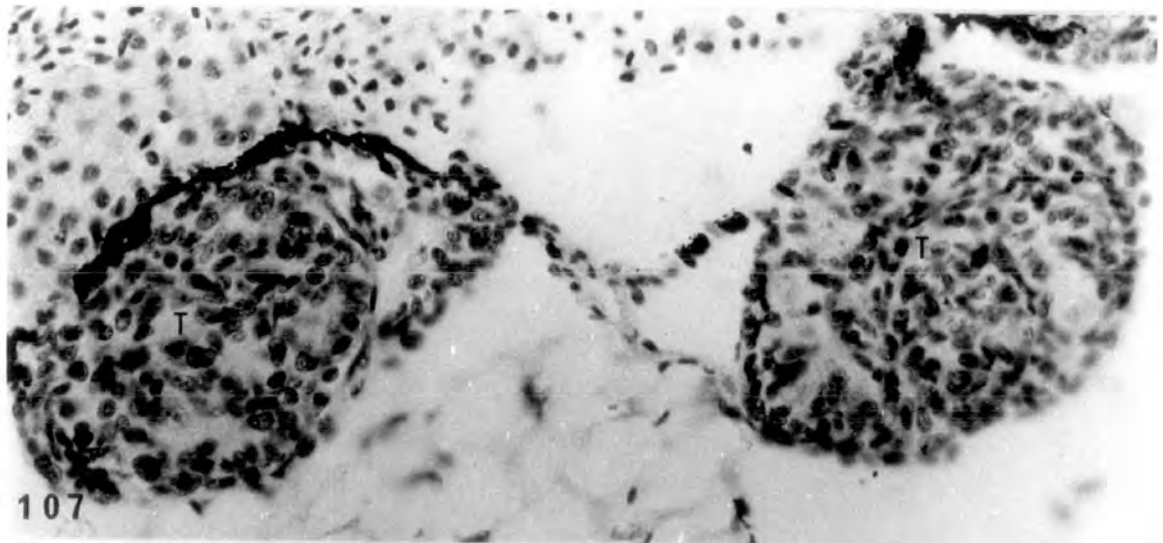
104



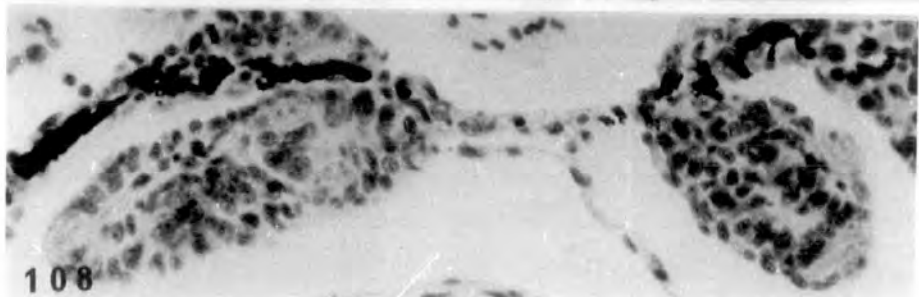
105



106



107



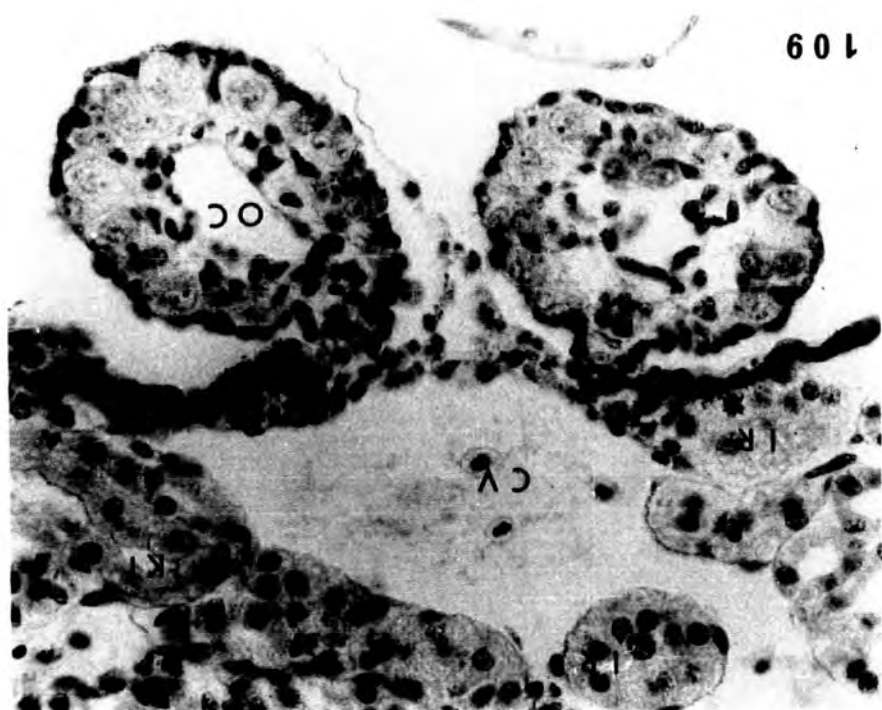
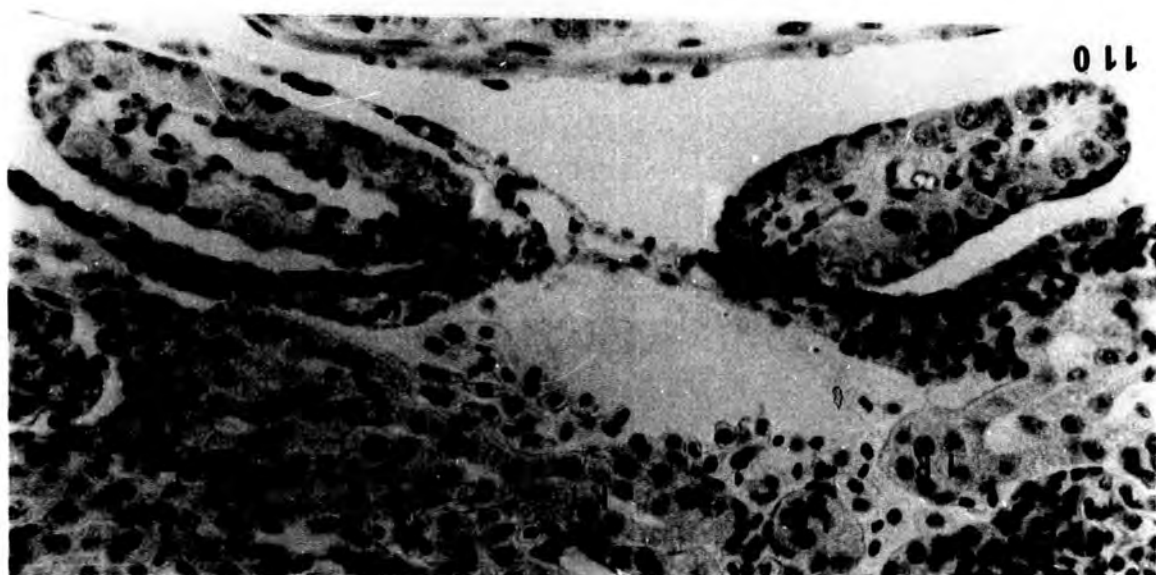
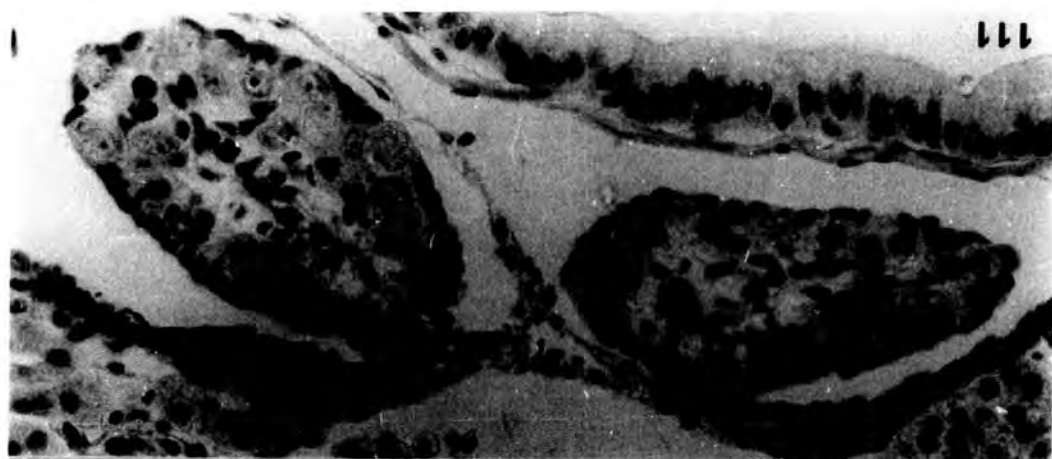
108

PLATE XXXV

Fig. 109. Inhibited ovaries (♀+). The left ovary lacks an obvious ovarian cavity. Both ovaries lack pachytene oocytes in the cortex. Increased diameter of the kidney tubules and some interrenal hyperplasia are evident. x 400.

Fig. 110. Further example of inhibited ovaries (♀+). The left ovary is devoid of ovarian cavity. No pachytene oocytes present. x 400.

Fig. 111. A third example with inhibited ovaries (♀+). Both ovaries lack ovarian cavity. Again no pachytene oocytes present. x 400.



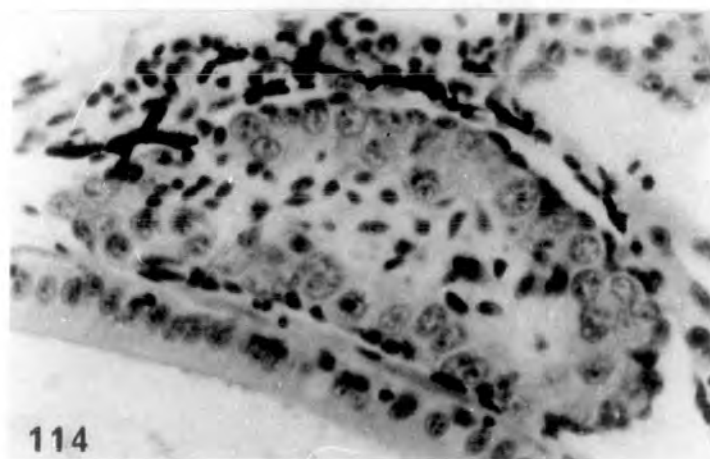
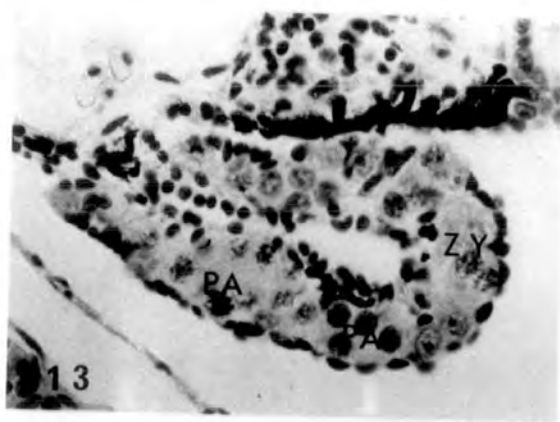
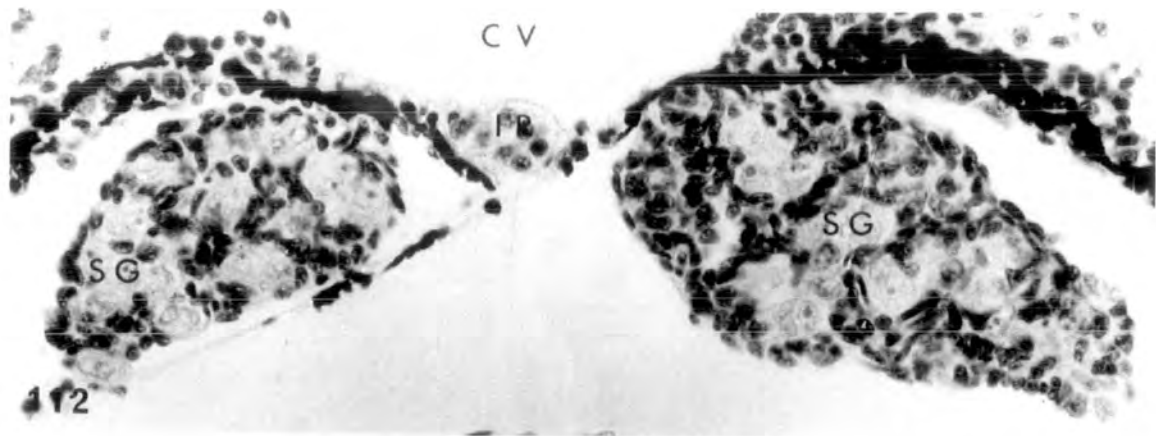
Treatment for 26 days (st.51-57) with 25, 100 and
500µg/l hexestrol respectively.

PLATE XXXVI

Fig. 112. Control, alcohol treated testes (♂ N).
x 400.

Fig. 113. Control, alcohol treated ovary (♀ N).
x 400.

Fig. 114. Treatment with 25µg/l. Inhibited ovary
with no obvious ovarian cavity, instead
some medullary cells are present. There
are no pachytene oocytes in the cortex.
x 400.

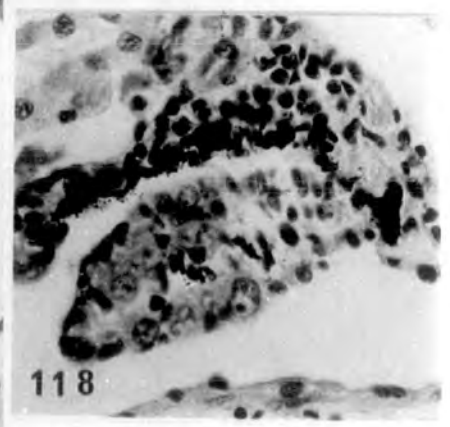
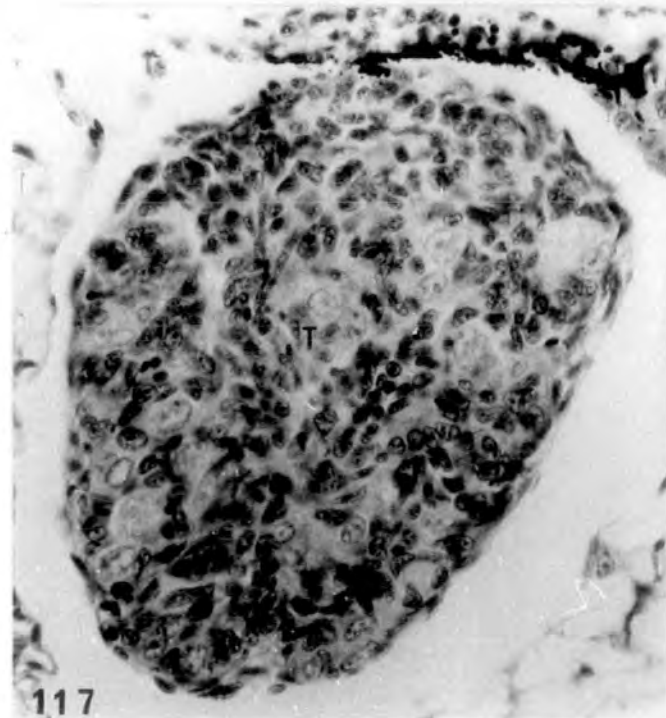
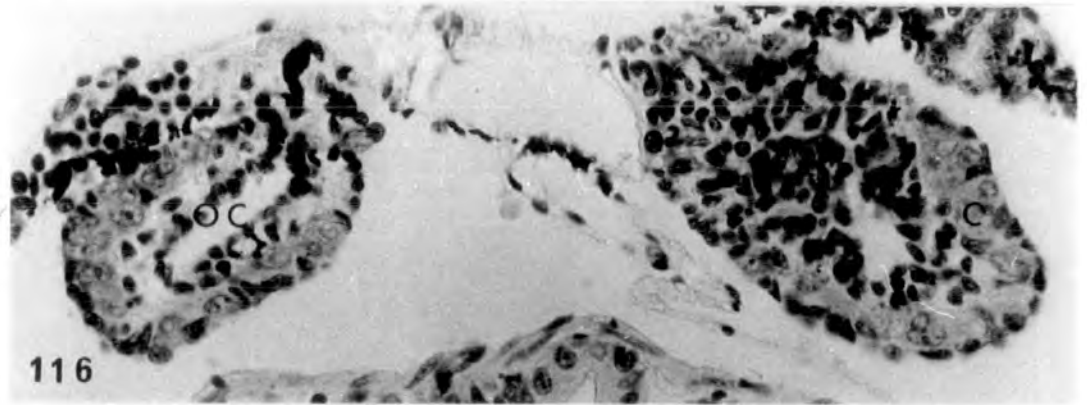
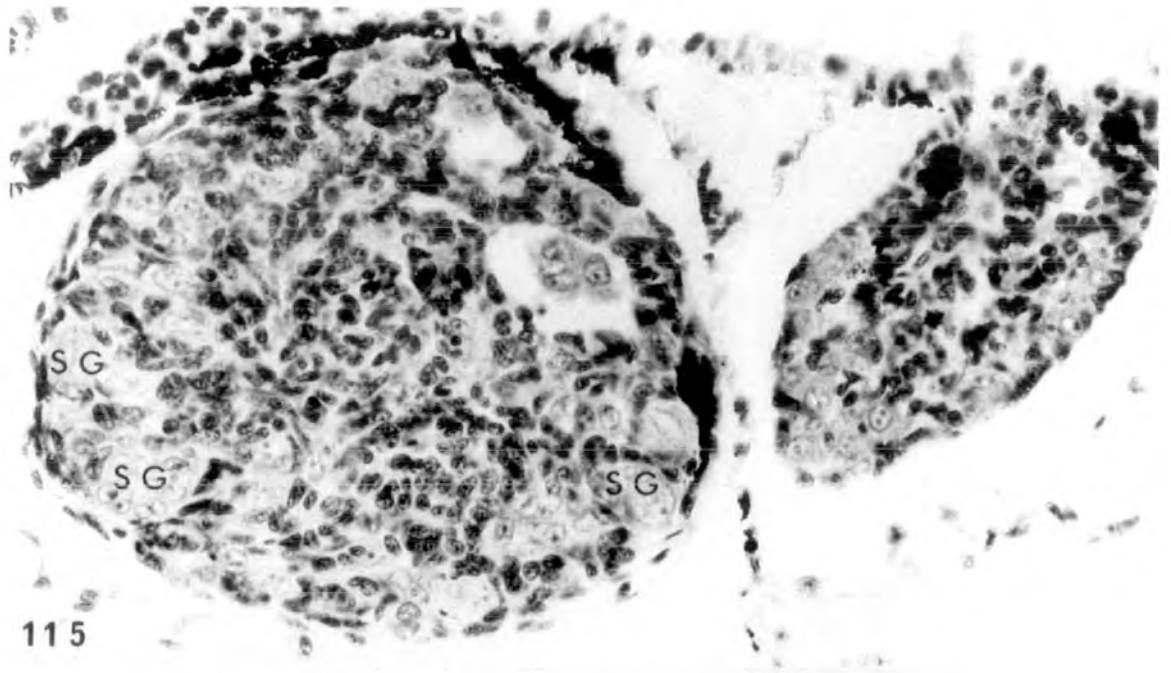


Treatment with 25µg/l

PLATE XXXVII

Figs. 115-116. Frontal gonadal region highly masculinized and the posterior intersexualised (♂-♂). x 400.

Figs. 117-118. Anterior gonadal region of a large testis and end posterior of a small intersexual gonad. (♂-♂). x 400.

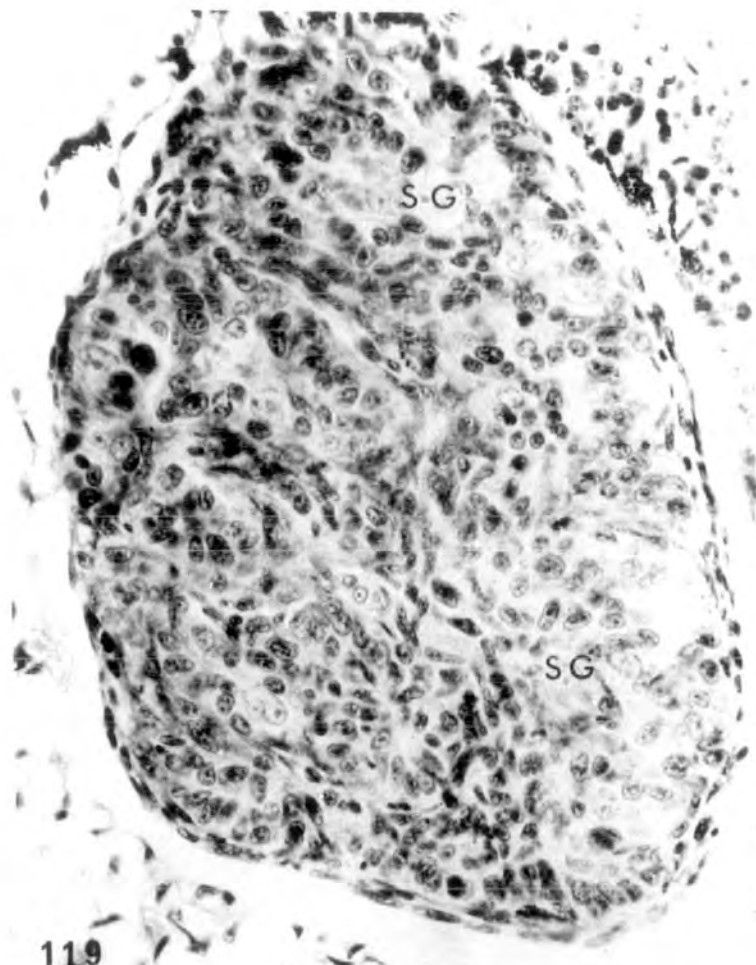

Treatment with 100µg/l

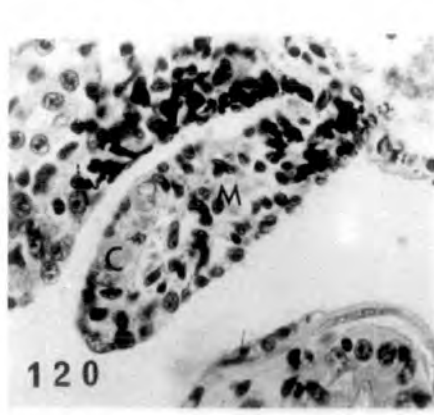
PLATE XXXVIII

Figs. 119-121. Large testicular structure anteriorly (119) and small intersexual gonads (120-121) at the posterior end (♂-♀). x 400.

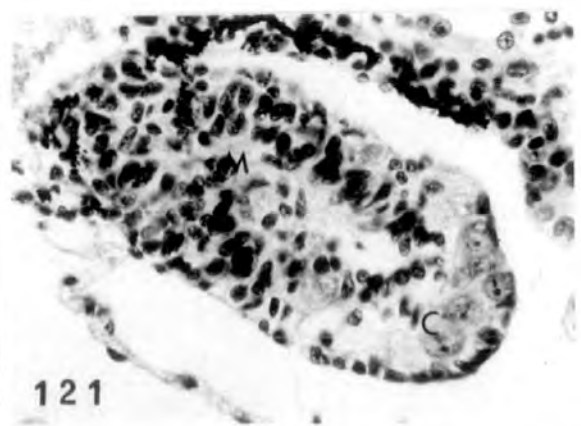
Fig. 122. Inhibited ovaries (♀ †) showing ovarian cavity but no pachytene oocytes in the cortical area. x 400.



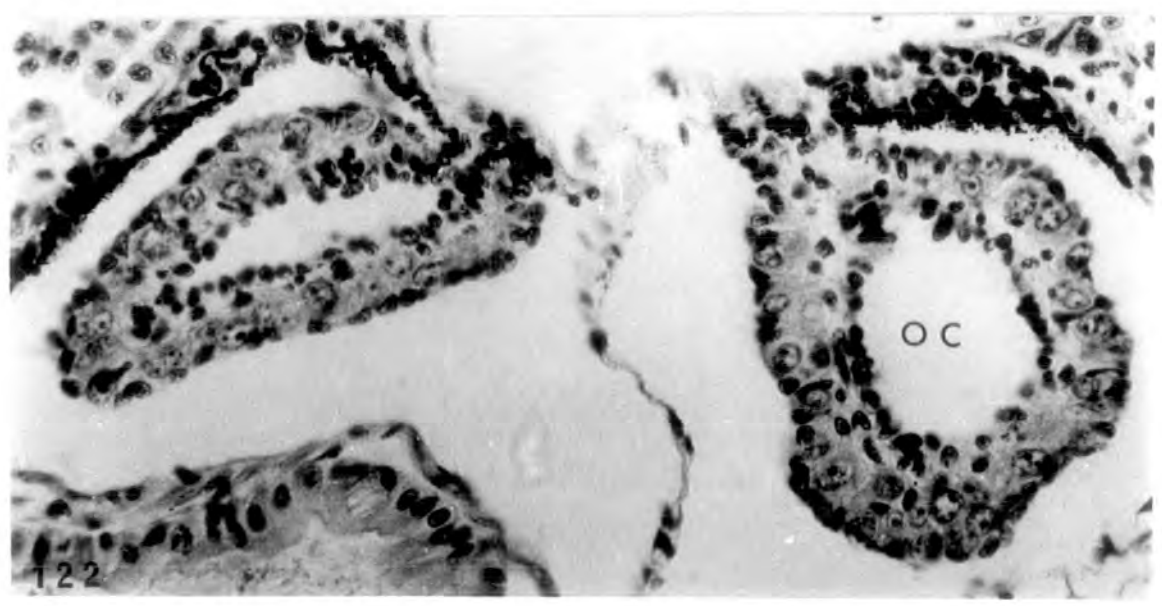
119



120



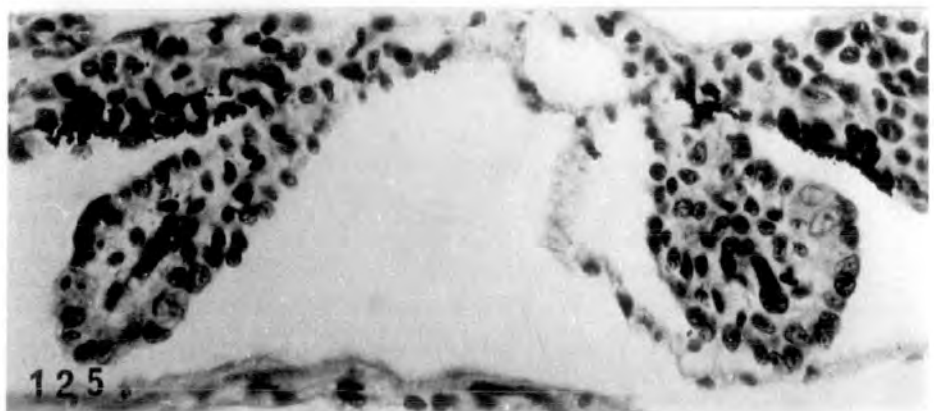
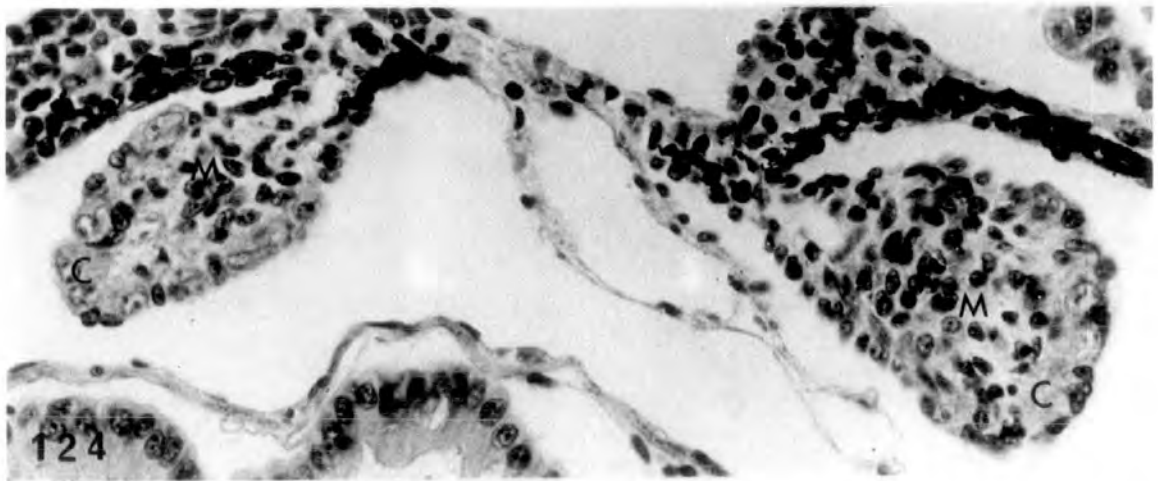
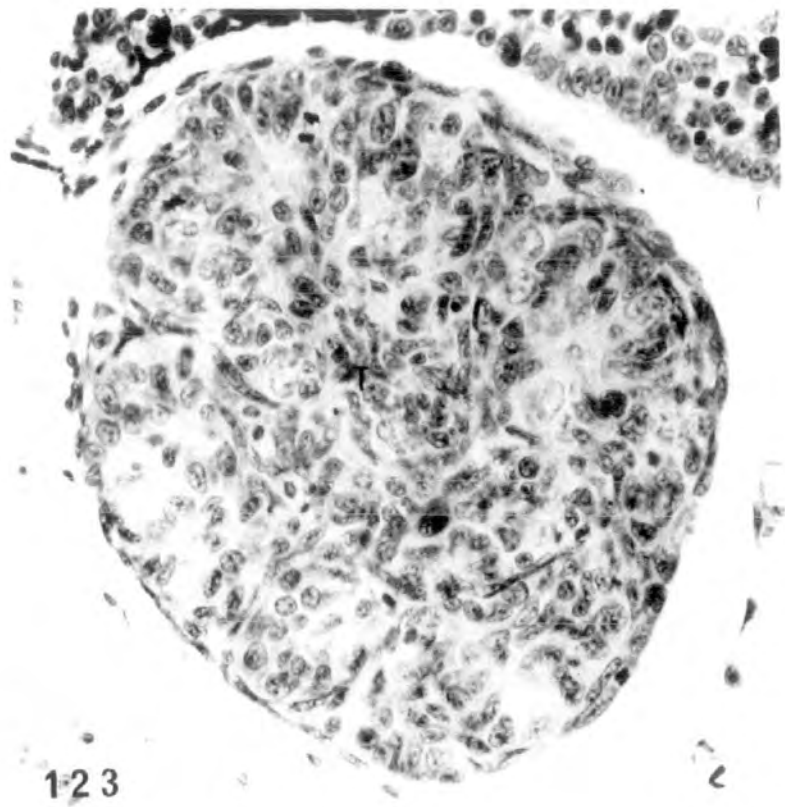121



122

PLATE XXXIX

Figs. 123-125. Three sections from the same tadpole. At the anterior region (123) a large testicular structure (right testis) at the posterior region (124-125) intersexual gonads are evident showing distinct cortex and medulla (♂-♀). x 450.



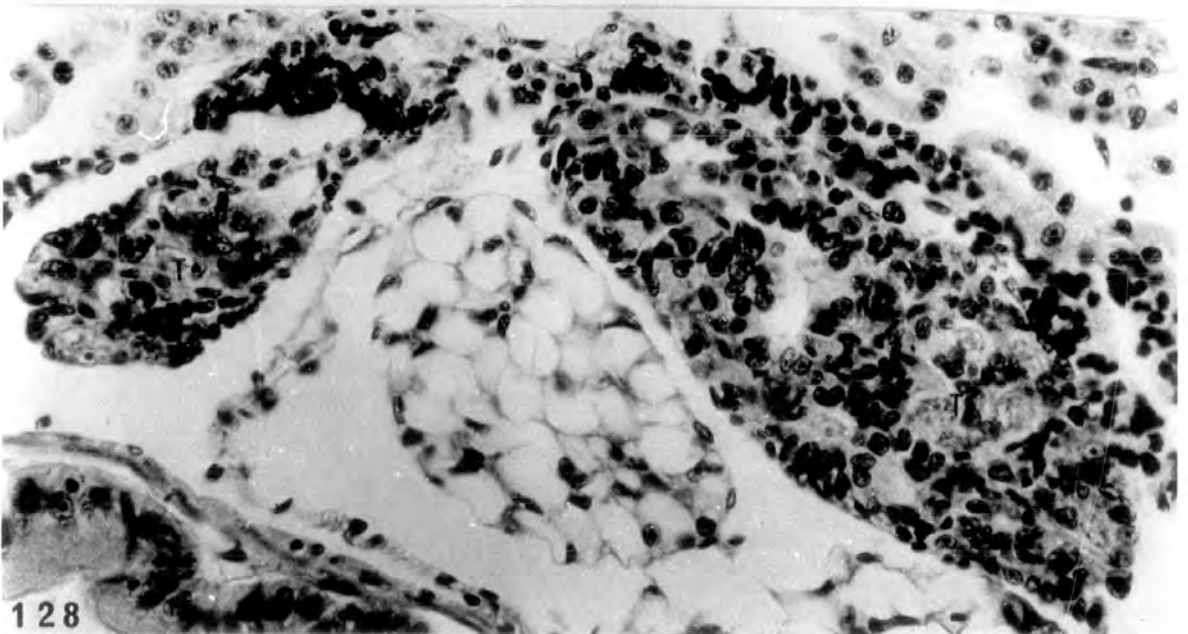
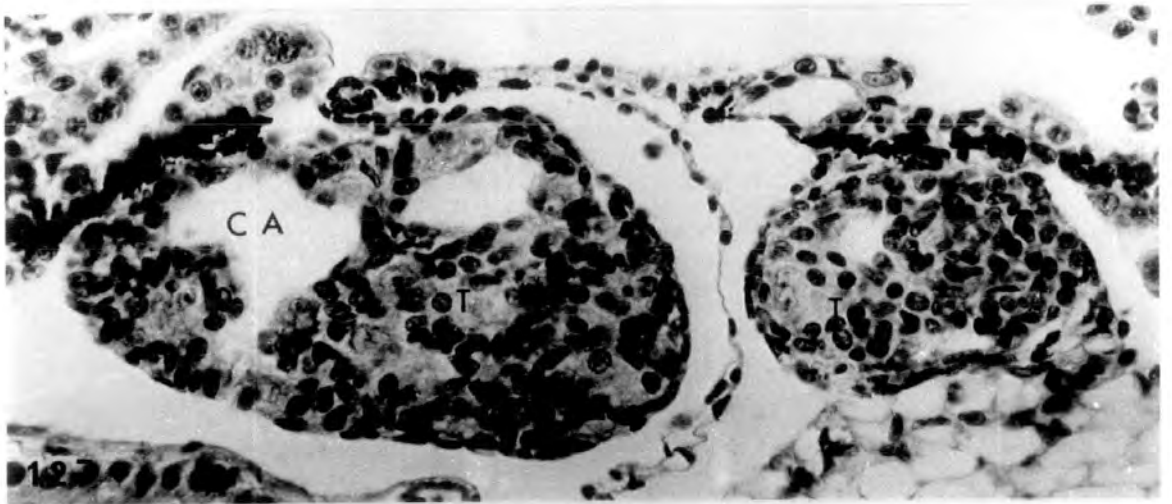
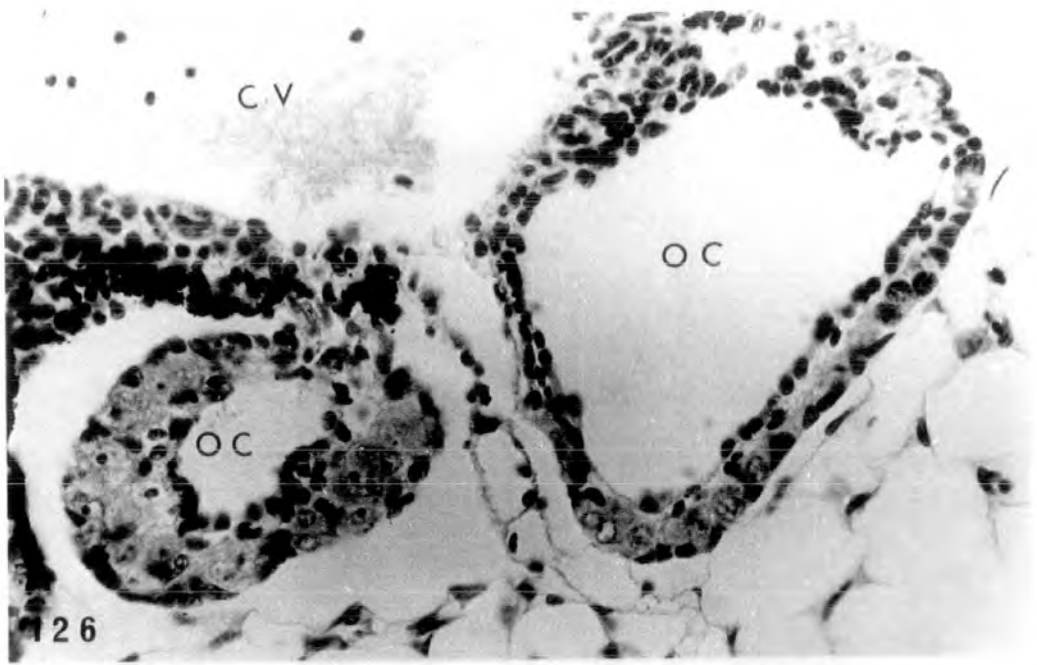
Treatment with 500 μ g/l

PLATE XL

Fig. 126. Inhibited ovaries (♀) with large ovarian cavities and thin cortex, especially round right ovary which contains no pachytene oocytes. x 400.

Fig. 127. Normal testes with some cavities (♂ Cav.) x 400.

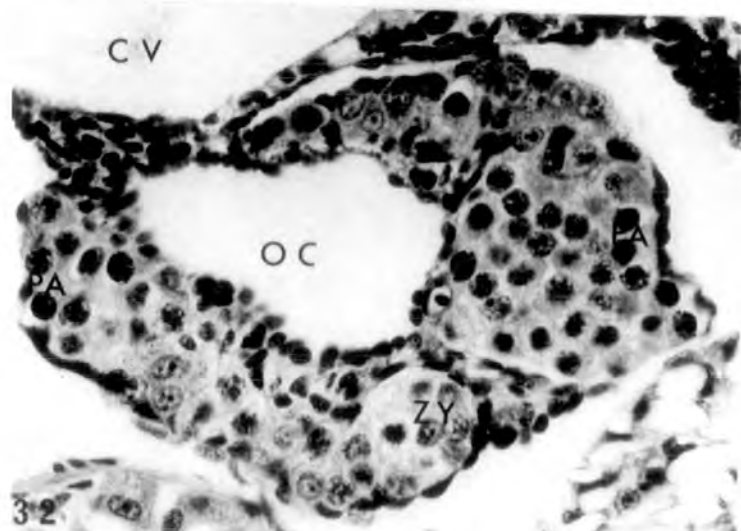
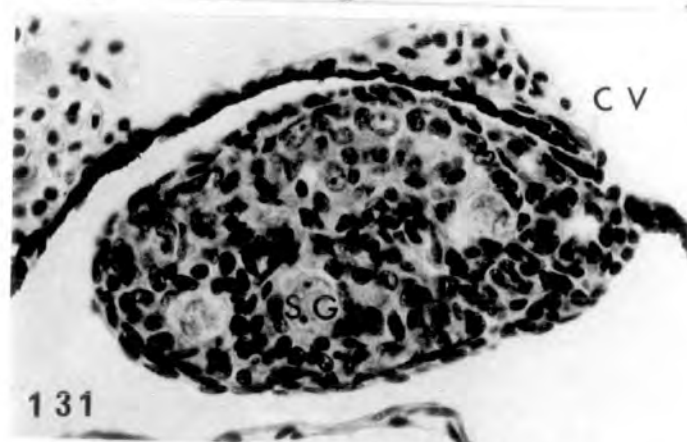
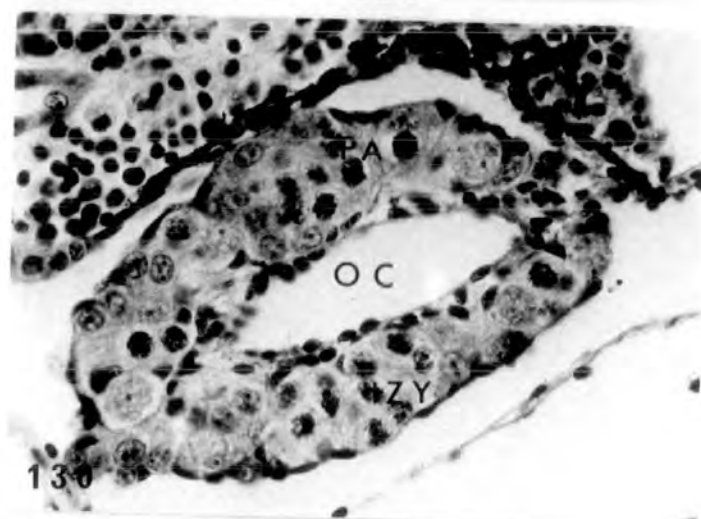
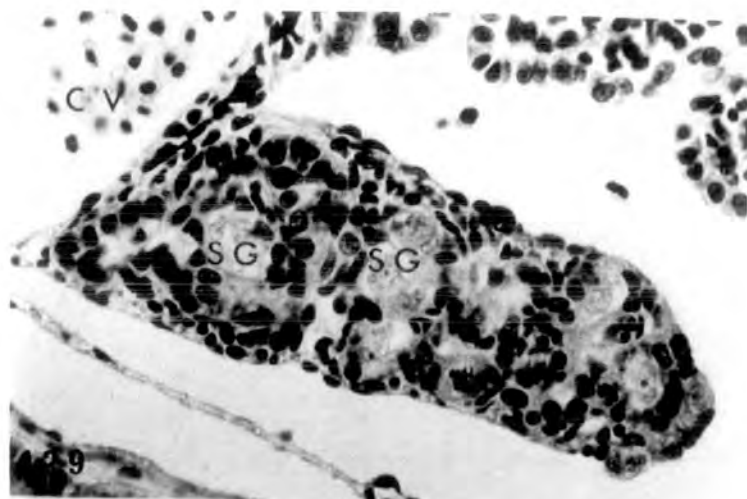
Fig. 128. Normal testes of another tadpole showing cavities (♂ Cav.) x 400.



Treatment for 26 days (st.50-56) with 25, 100 and 500µg/l
progesterone respectively

PLATE XLI

- Fig. 129. Control, alcohol treated testis showing nests of spermatogonia in the testicular soma (♂ N). x 400.
- Fig. 130. Control, alcohol treated ovary, showing obvious cavity and a thick cortex containing various developmental stages oocytes up to pachytene (♀ N). x 400.
- Fig. 131. Treatment with 25µg/l. Normal testis as in control (♂ N). x 400.
- Fig. 132. Treatment with 25µg/l. Ovary resembling control (♀ N). x 400.



Treatment with 100µg/l

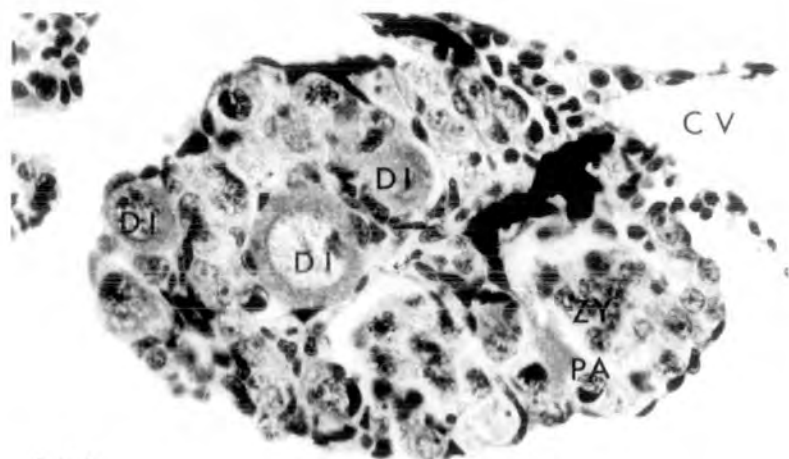
PLATE XLII

Fig. 133. Ovary stimulated by progesterone treatment. Diplotene stage oocytes are found in the thickened cortex. Ovarian cavity absent and instead some medullary cells are present (♀ ↑).
x 400.

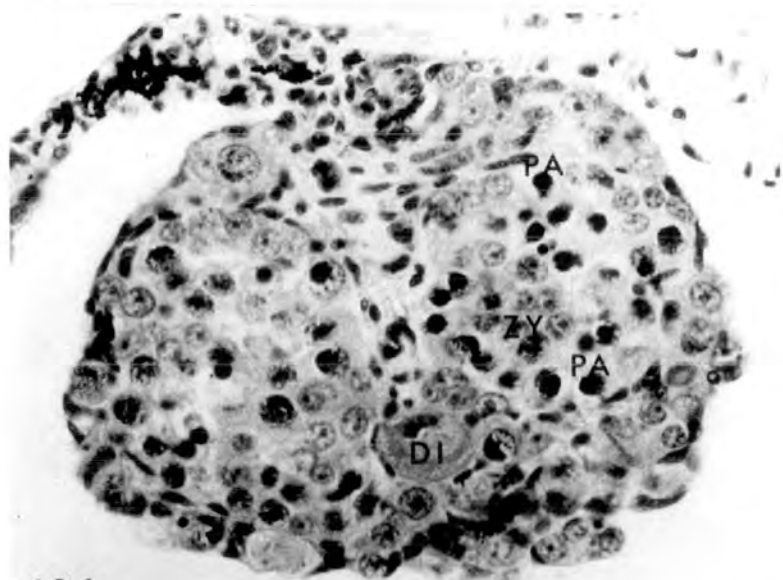
Fig. 134. Stimulated ovary from another tadpole
(♀ ↑). x 400.

Figs.135-136. Small, inhibited ovaries showing thin cortex with no pachytene oocytes in it
(♀ ↓). x 400.

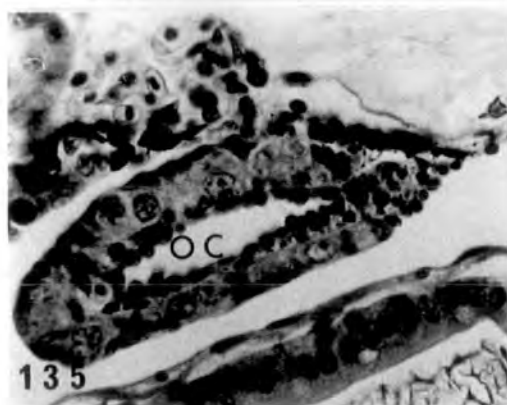
Fig. 137. Normal testis resembling control (♂ N).
x 400.



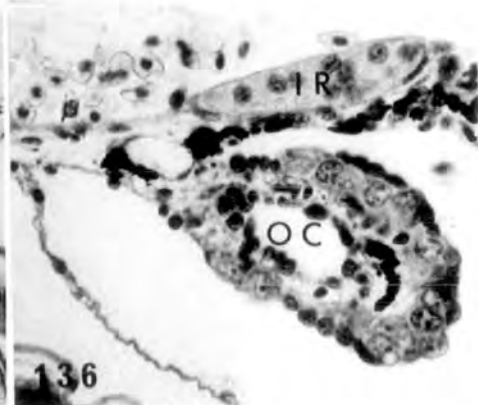
133



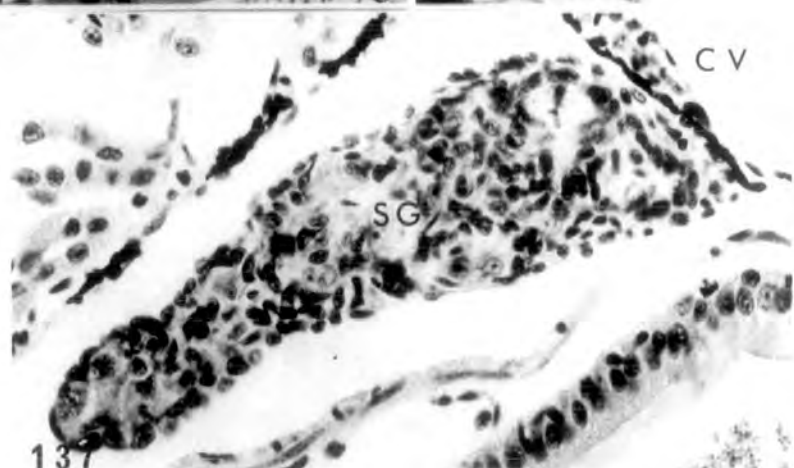
134



135



136



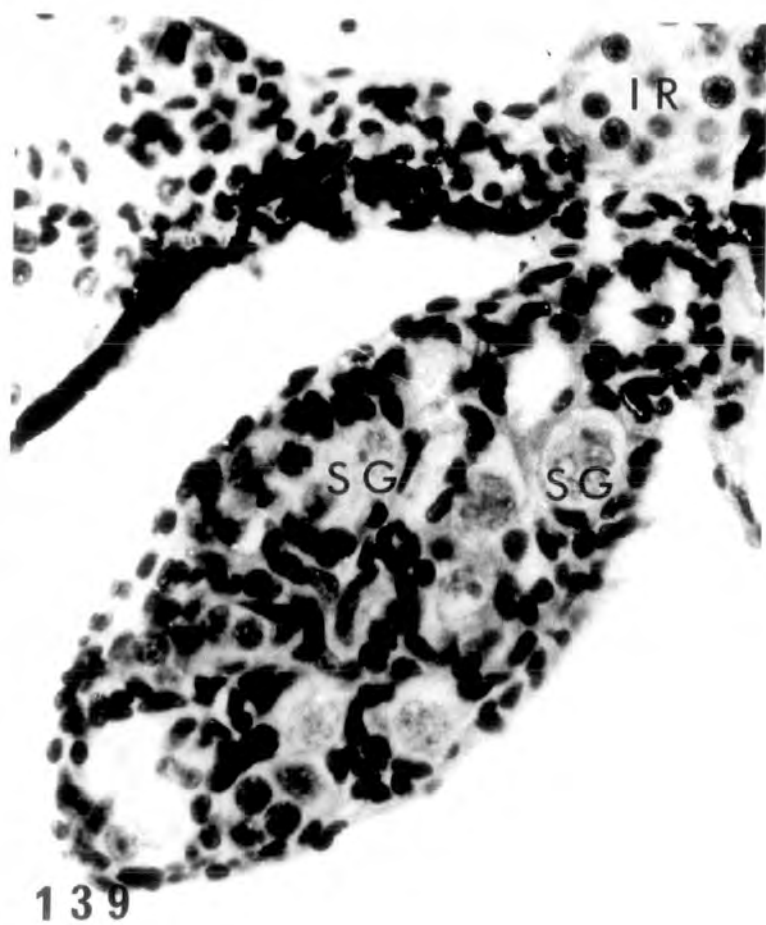
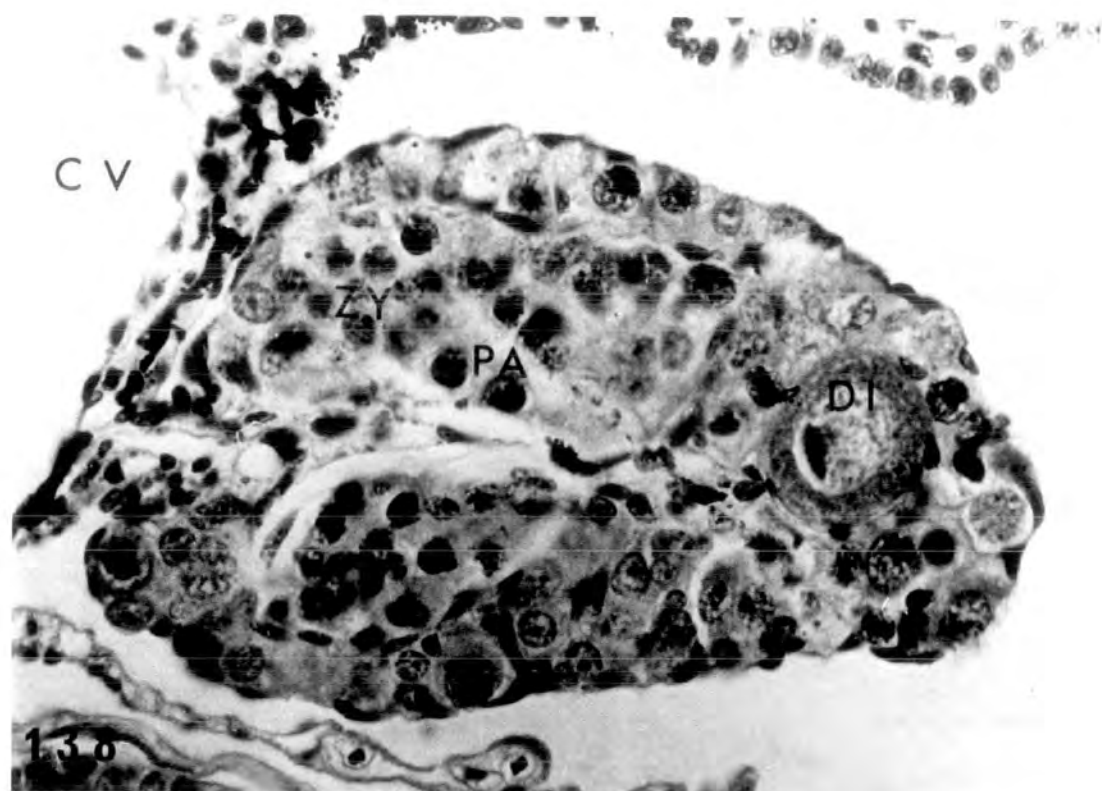
137

Treatment with 500µg/l

PLATE XLIII

Fig. 138. Stimulated ovary showing diplotenic
oocytes (♀ †). x 600.

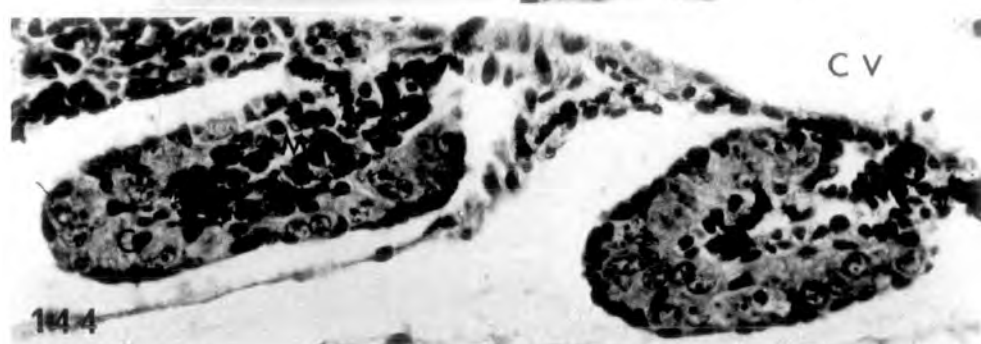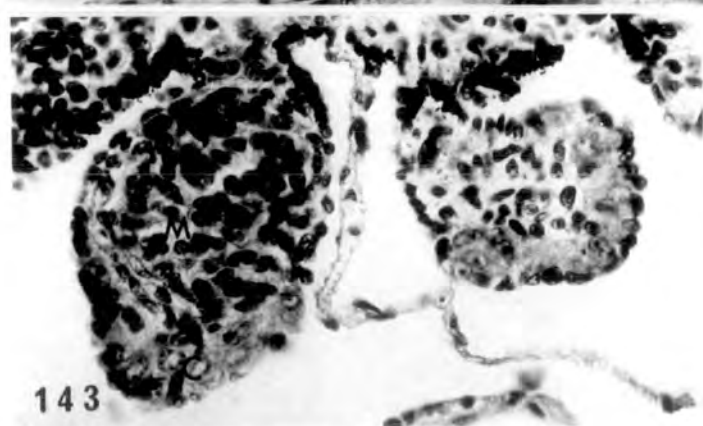
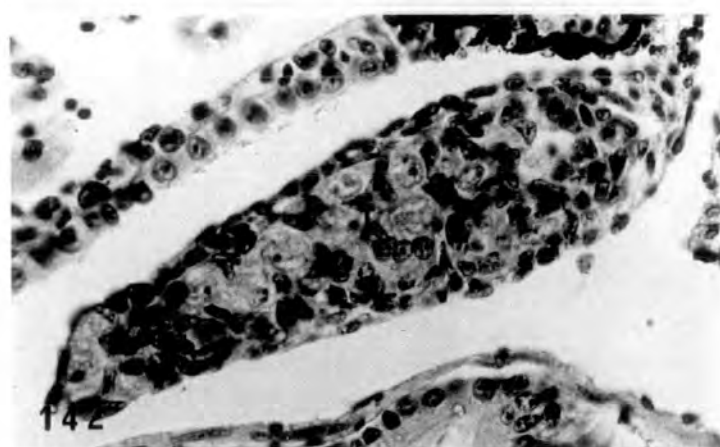
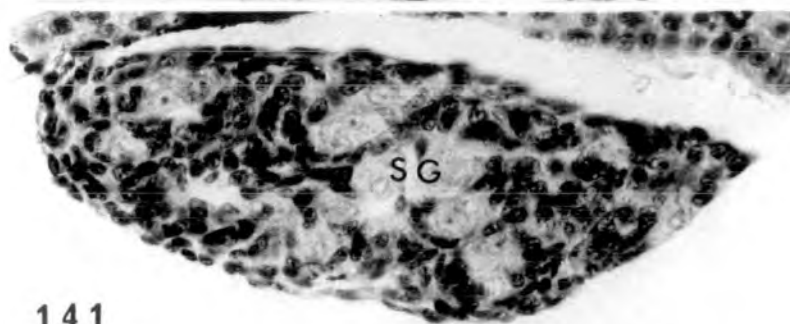
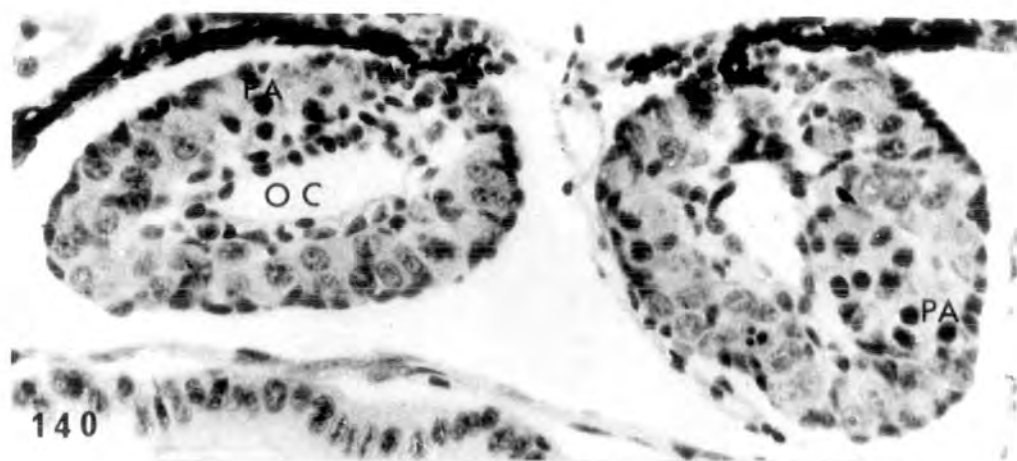
Fig. 139. Normal testis resembling control
(♂ N). x 600.



Treatment for 26 days (st.51-57) with 25, 100, 500 μ g/l
and 2mg/l testosterone acetate respectively

PLATE XLIV

- Fig. 140. Control, alcohol treated ovaries showing obvious cavity and pachytene oocytes in the cortex (♀ N). x 400.
- Fig. 141. Control, alcohol treated testis with many spermatogonial nests in the testicular soma (♂ N). x 400.
- Fig. 142. Treatment with 25 μ g/l. Testis resembling control (♂ N). x 400.
- Fig. 143. Treatment with 25 μ g/l. Intersexual gonads (♀♂). In the left gonad the medullary region occupies most of the gonadal area. The right gonad is an inhibited ovary. x 400.
- Fig. 144. Treatment with 25 μ g/l. Inhibited ovaries with no obvious cavity and medullary cells are present (♀ +). x 400.



Treatment with 100µg/l

PLATE XLV

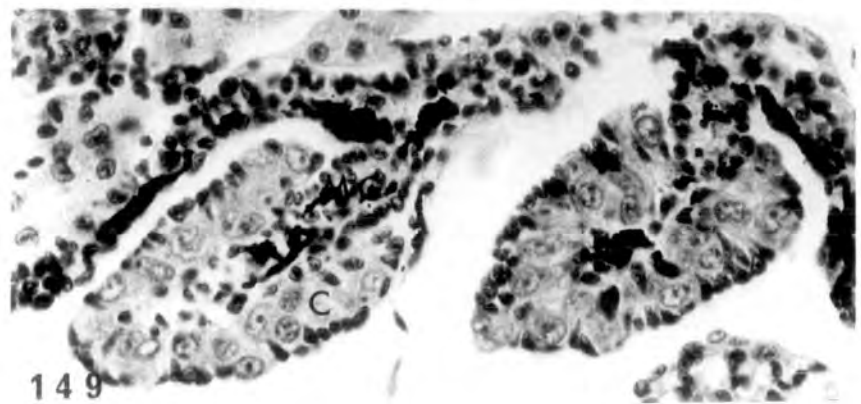
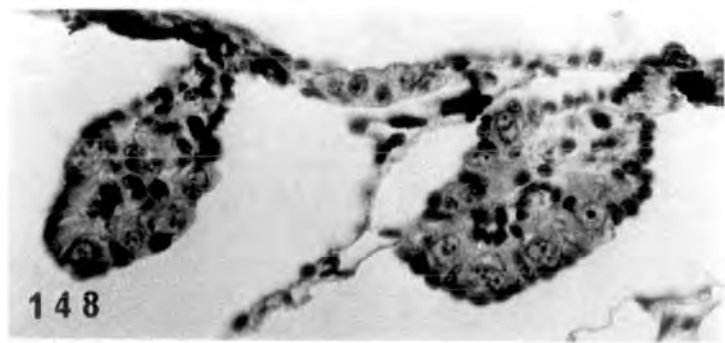
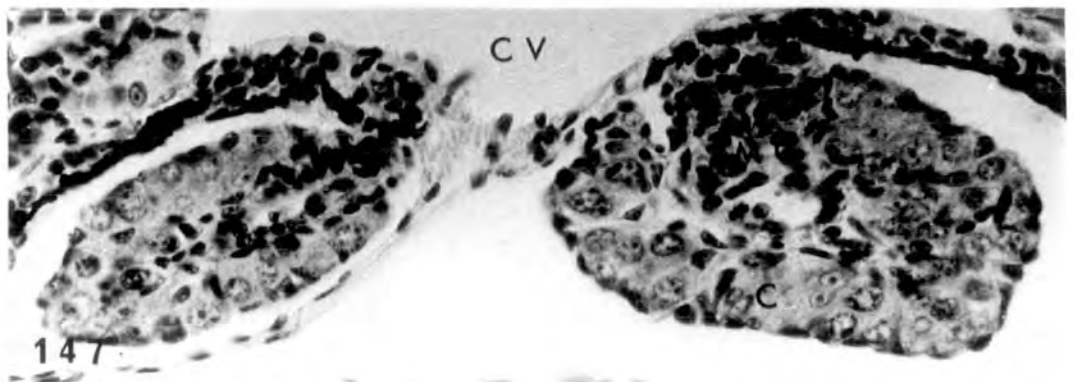
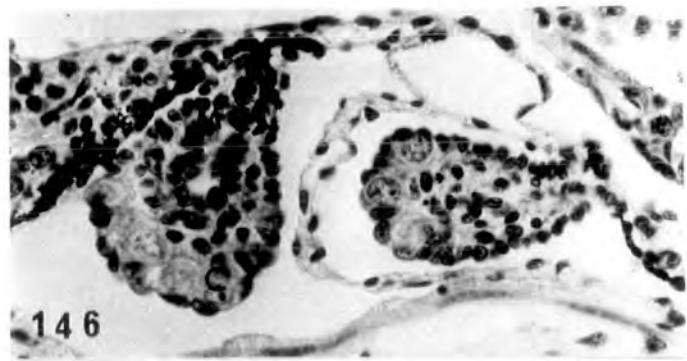
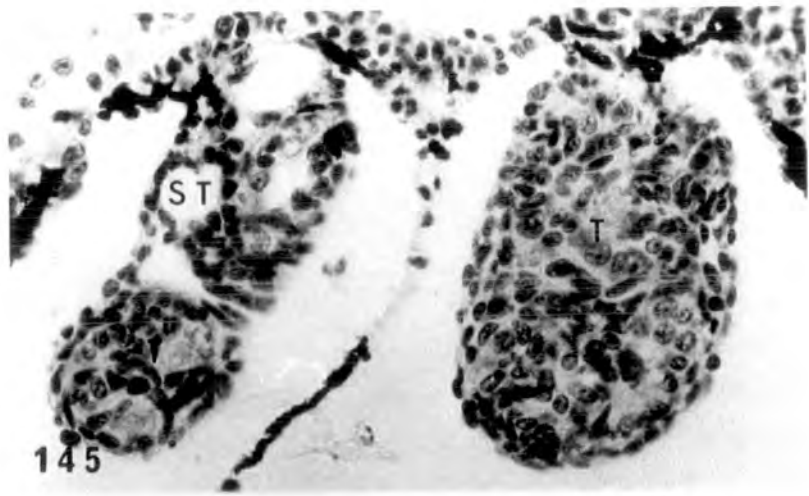
Fig. 145. Testes resembling controls (♂ N).

The small cavities present in the testicular soma could be primordia of seminiferous tubules. x 400.

Figs. 146-149. Inhibited ovaries from four

tadpoles, showing no obvious ovarian cavity but instead medullary cells are present. There are no pachytene oocytes in the cortical region

(♀ +). x 400.

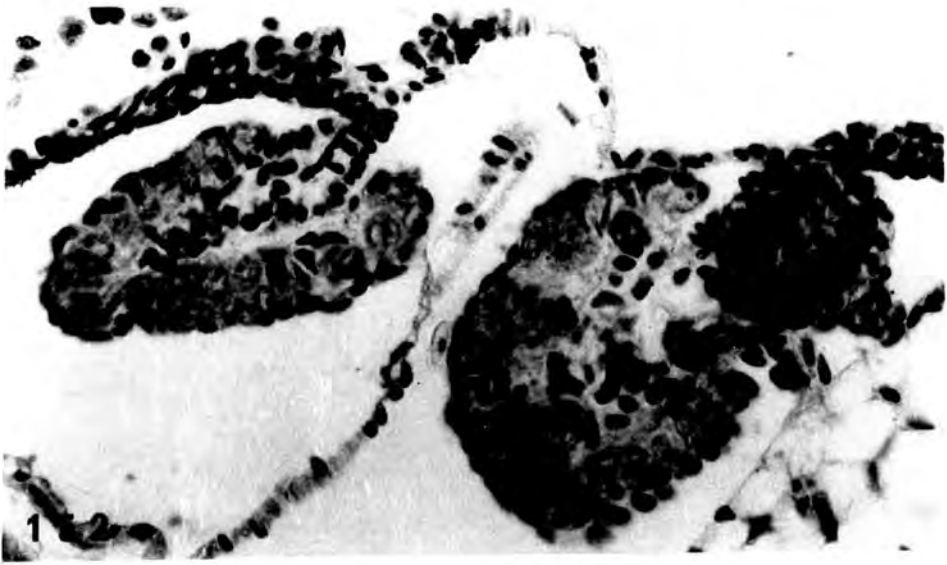
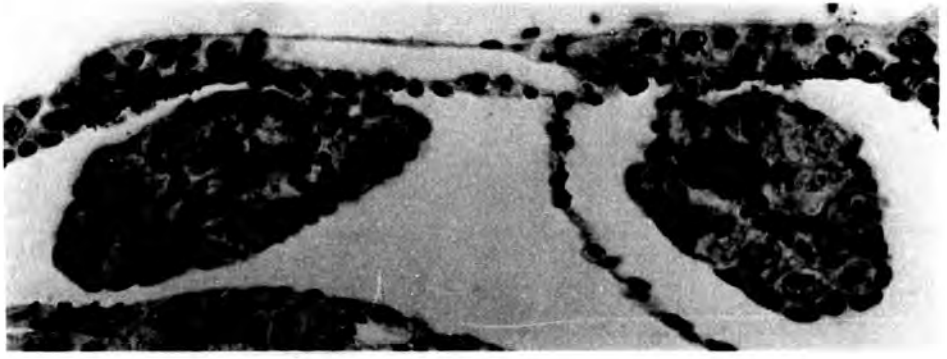
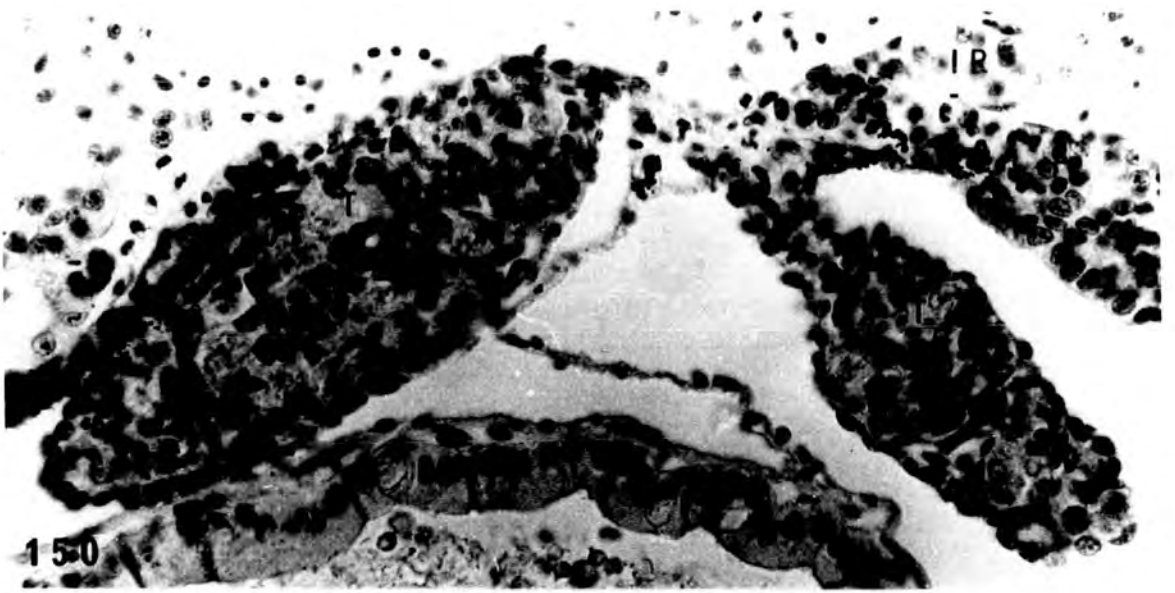


Treatment with 500µg/l

PLATE XLVI

Fig. 150. Testes resembling control (♂ N).
x 425.

Figs. 151-152. Inhibited ovaries from two
larvae, lacking both ovarian
cavity and pachytene oocytes
(♀ +). x 425.



Treatment with 2mg/l

PLATE XLVII

Figs. 153-154. Sections through the anterior part of the gonad, showing testes resembling control testes although smaller than normal. Precocious Wolffian duct development at the hilum of the right testis. Tremendous interrenal hyperplasia around the caval vein (♂ Abn.).
x 500.

Fig. 155. Anterior gonadal region from another larva showing testis with precocious Wolffian duct development (♂ Abn.).
x 500.

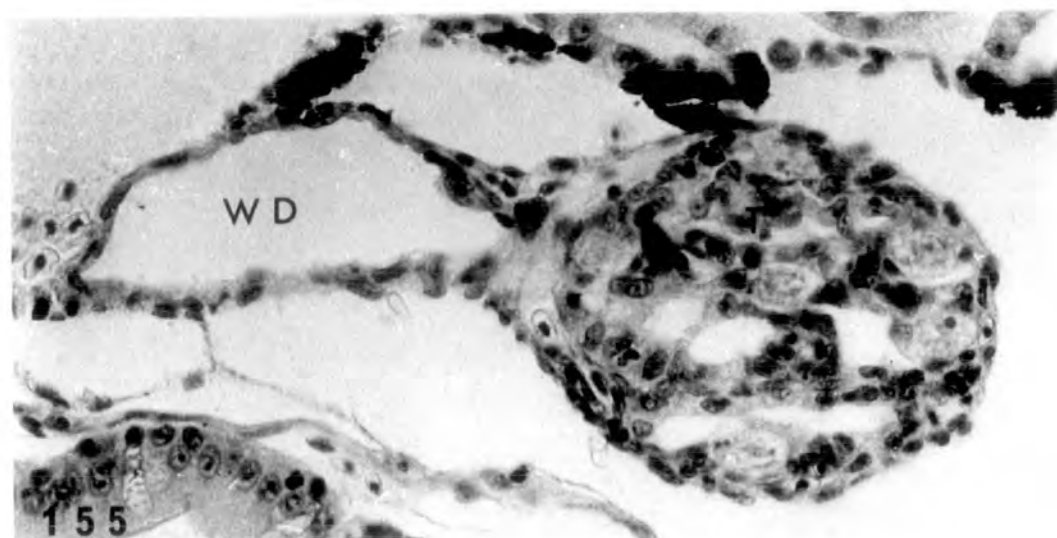
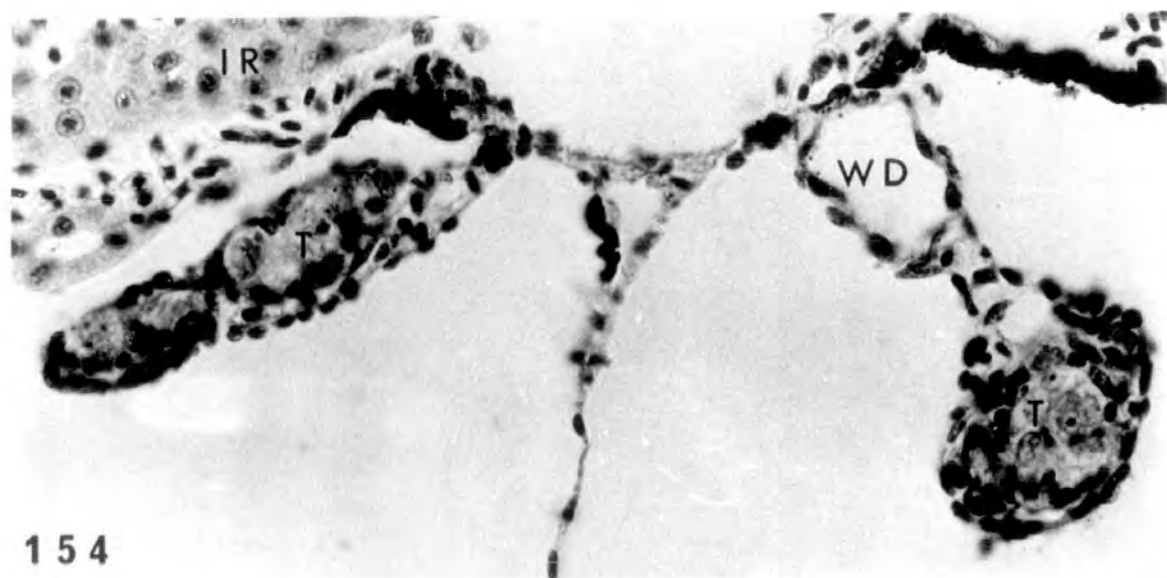
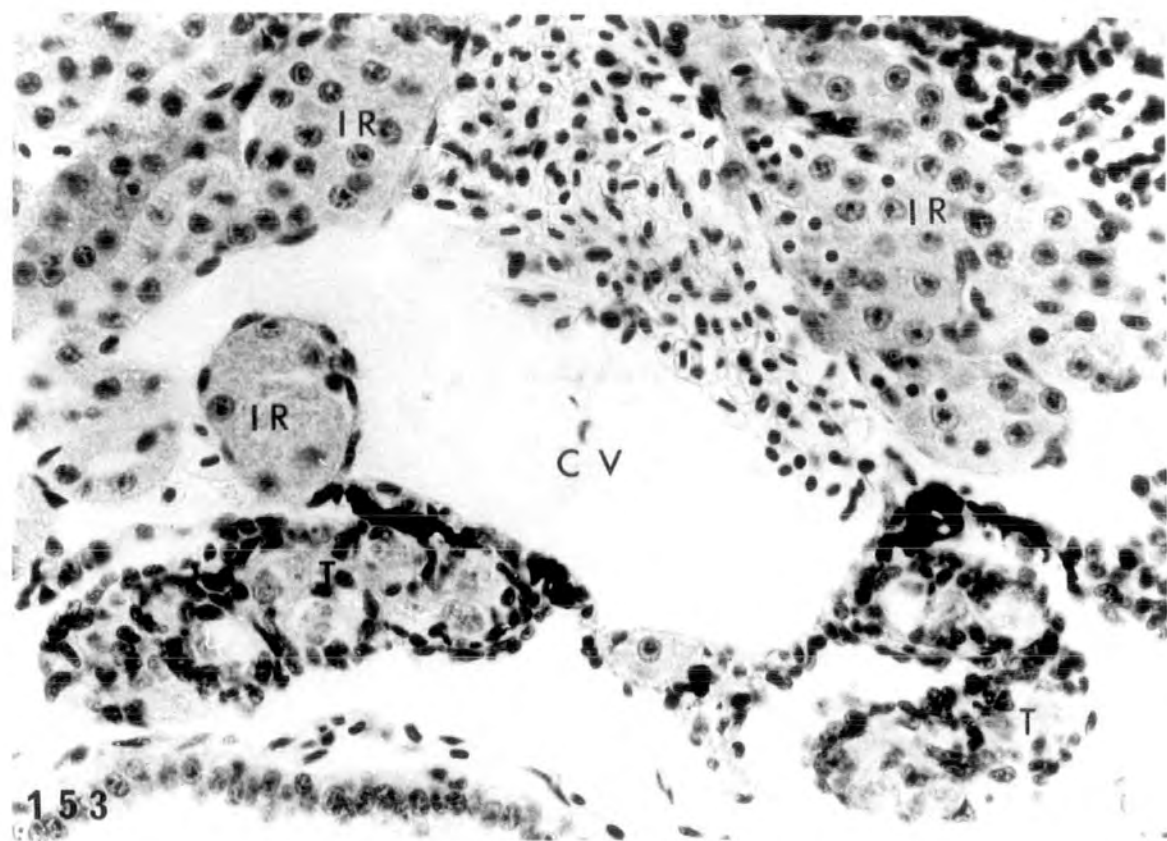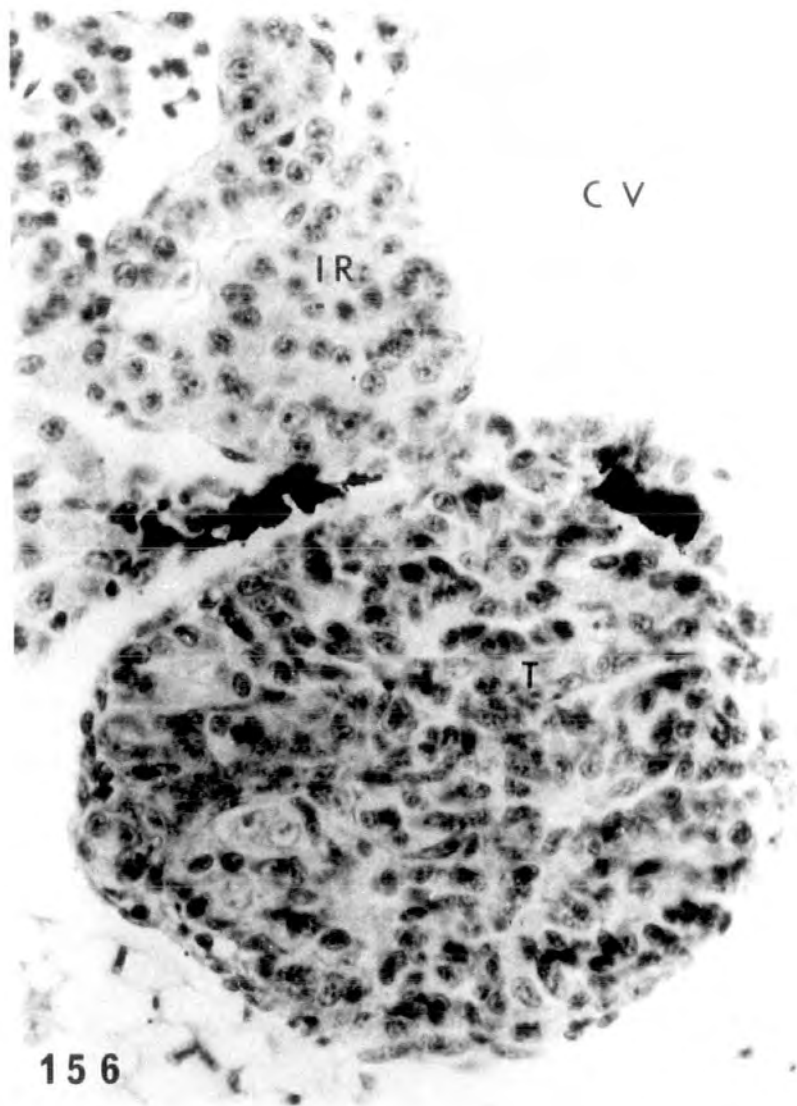
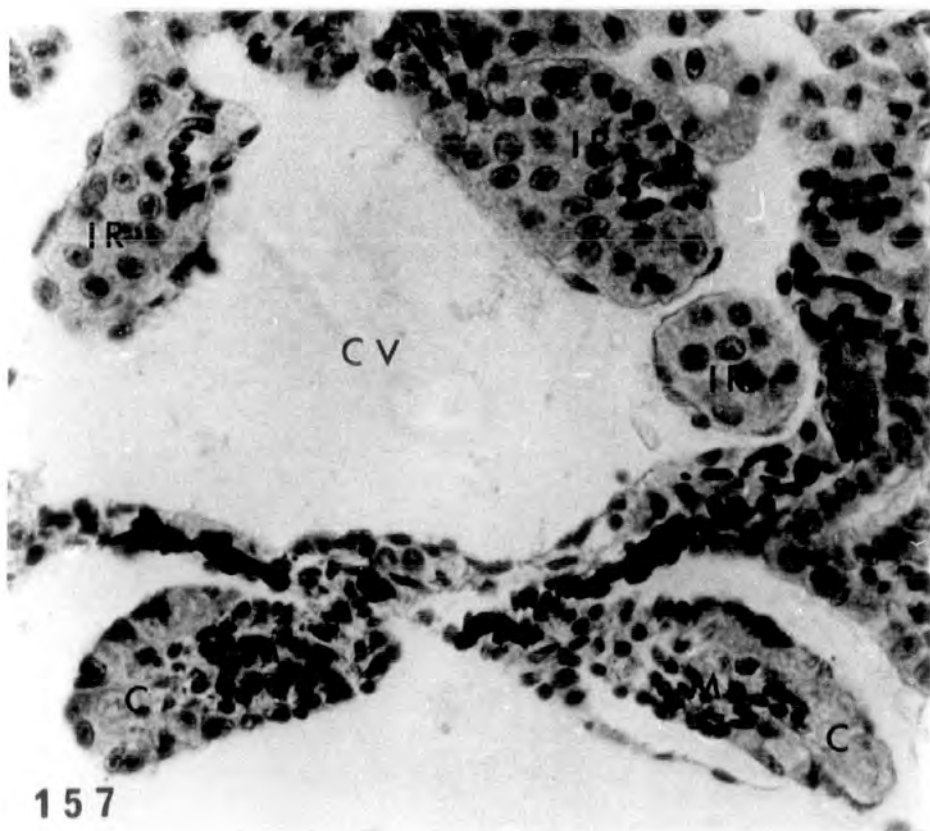


PLATE XLVIII

Figs. 156-157. Anterior gonadal region (156) showing a highly testicular structure whereas the posterior (157) showing small intersexual gonads possessing distinct cortex and medulla (♂-♀). Interrenal hyperplasia evident. x 490.



156



157

PLATE XLIX

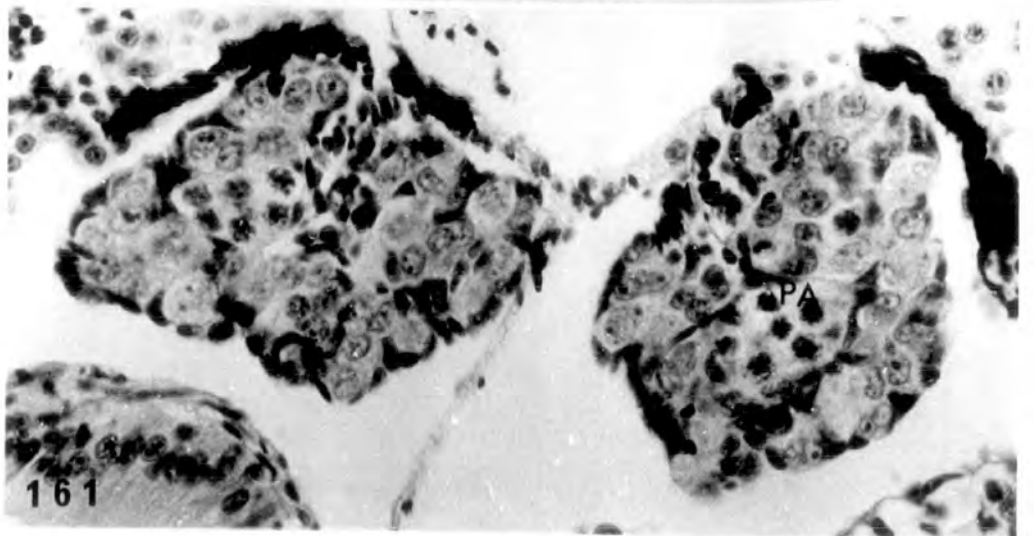
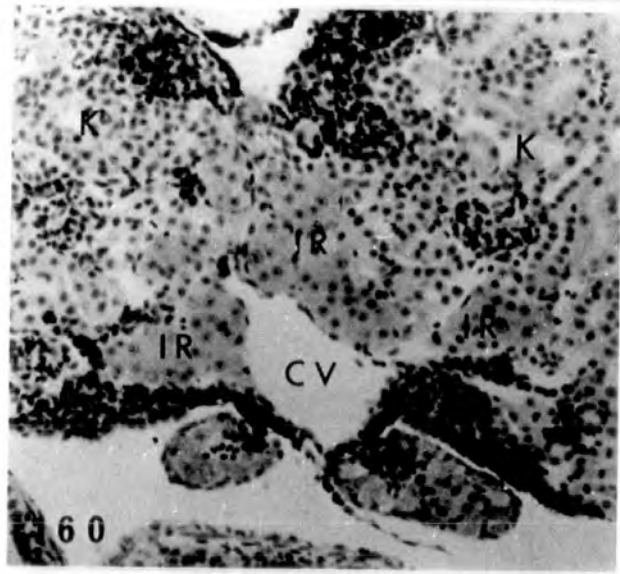
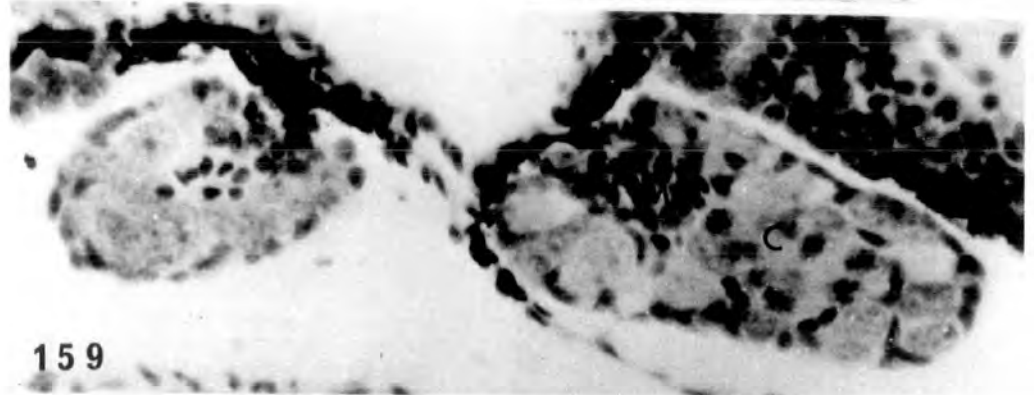
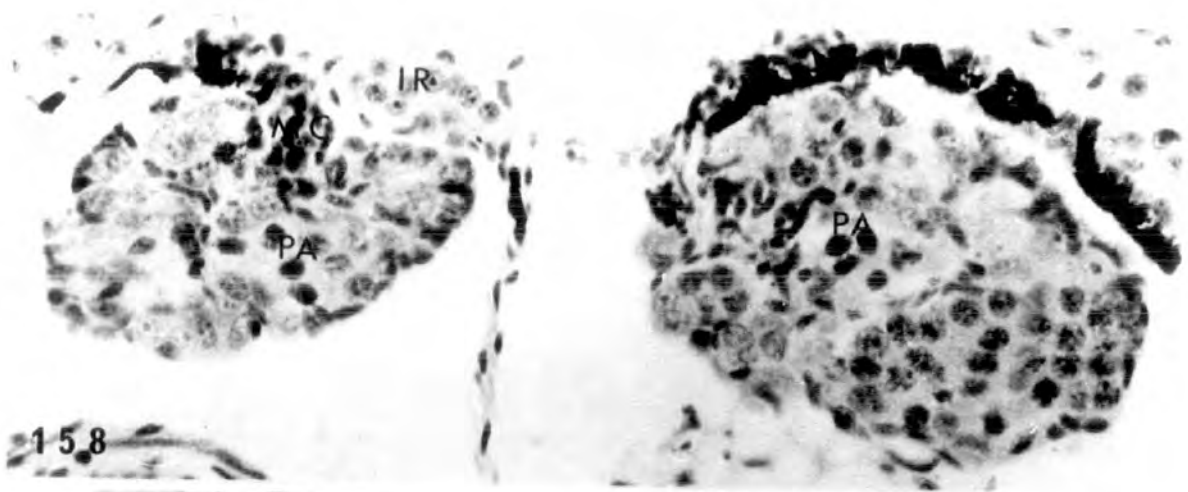
Figs. 158-160. Anterior region (158) showing highly feminized gonads with thick cortex containing pachytene oocytes but no ovarian cavity. The posterior region (159) shows intersexual gonads (♂[→]♀). Interrenal hyperplasia can be seen in the last photograph.

158 x 400

159 x 400

160 x 160

Fig. 161. Anterior gonadal part from another larva also showing high feminized structures (♂[→]♀). x 400.



Treatment for 26 days (st.51-57) with 25, 100, 500µg/l
and 2mg/l 5α-dihydrotestosterone respectively.

PLATE L

Fig. 162. Control, alcohol treated ovary at st.57
(♀ N). x 400.

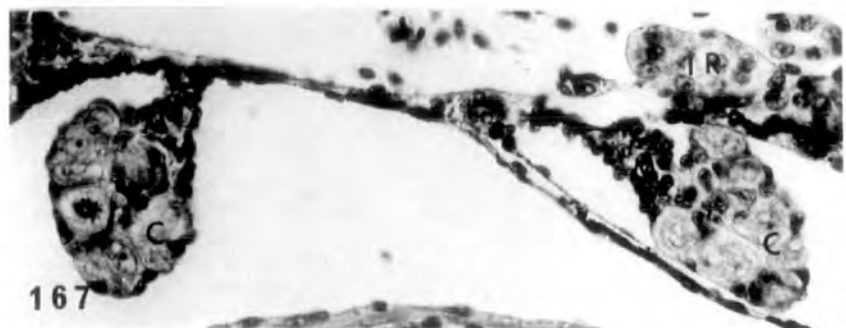
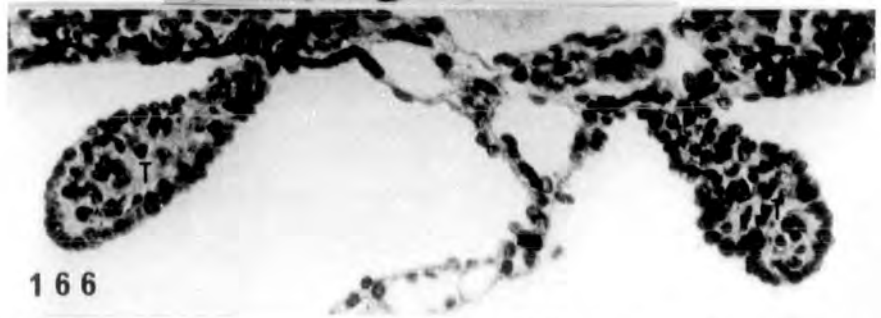
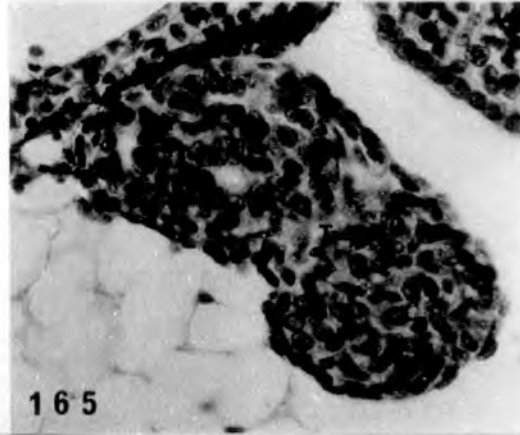
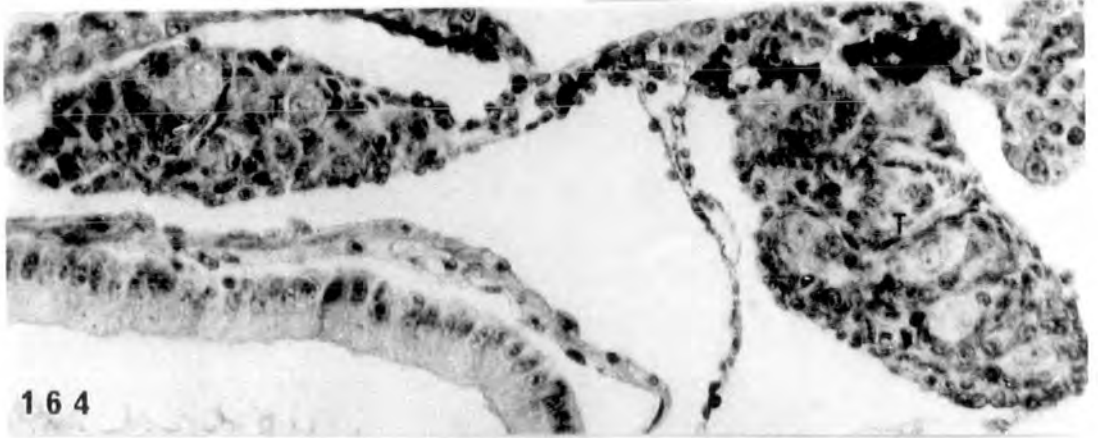
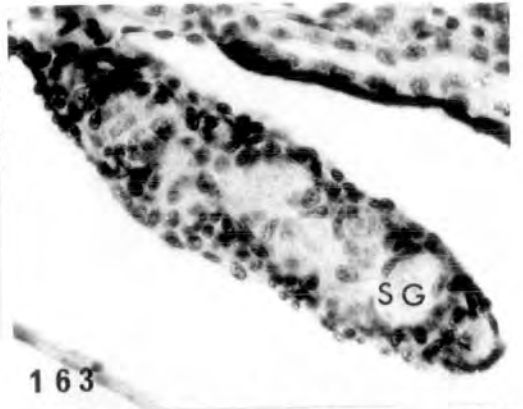
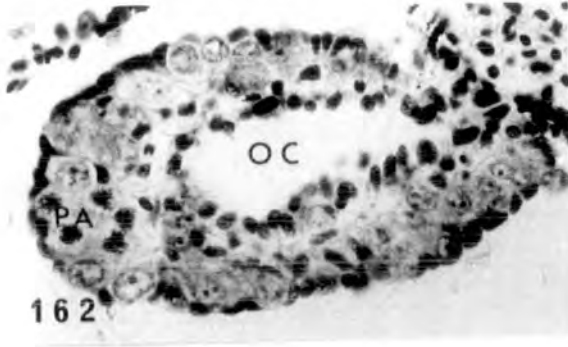
Fig. 163. Control, alcohol treated testis at st.57
(♂ N). x 400.

Fig. 164. Treatment with 25µg/l. Testes resembling
control (♂ N). x 400.

Fig. 165. Treatment with 25µg/l. Testicular structure
containing masses of somatic cells but no
germ cells (♂ Sub †). x 400.

Fig. 166. Treatment with 25µg/l. Testicular structures
smaller than control or O Sub †, and possessing
no germ cells (♂ Sub †). x 400.

Fig. 167. Treatment with 25µg/l. Intersexual gonads
possessing distinct medulla and cortex,
all the germ cells being in the latter
region (♀). x 400.



Treatment with 100µg/l

PLATE LI

Fig. 168. Testis resembling control (♂^N).
x 450.

Fig. 169-171. Right (170) and left (169)
testes containing some spermatogonia
and numerous somatic cells. The
cavity at the hilum of each testis
could be precocious development of
Wolffian duct. The cubical epithelium
lining this duct is seen in 171. (♂^{Abn.}).

169 x 450

170 x 450

171 x 720

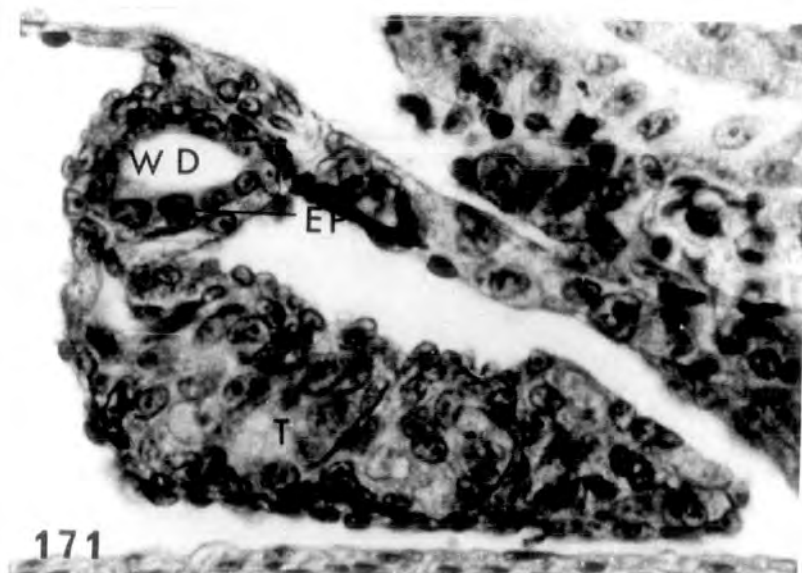
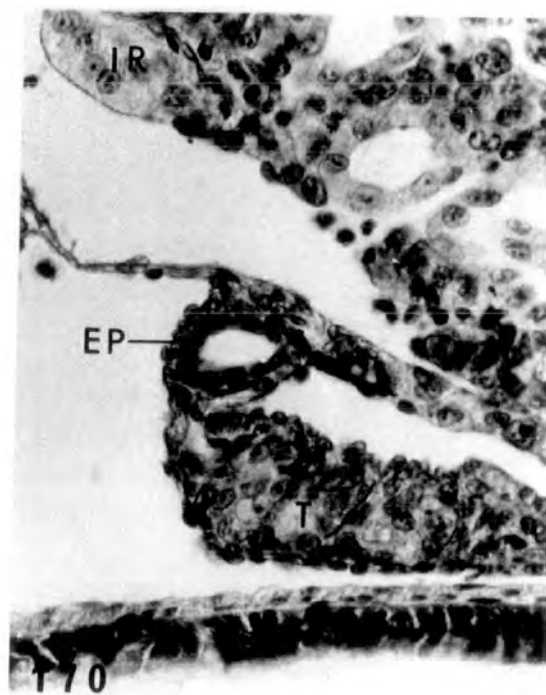
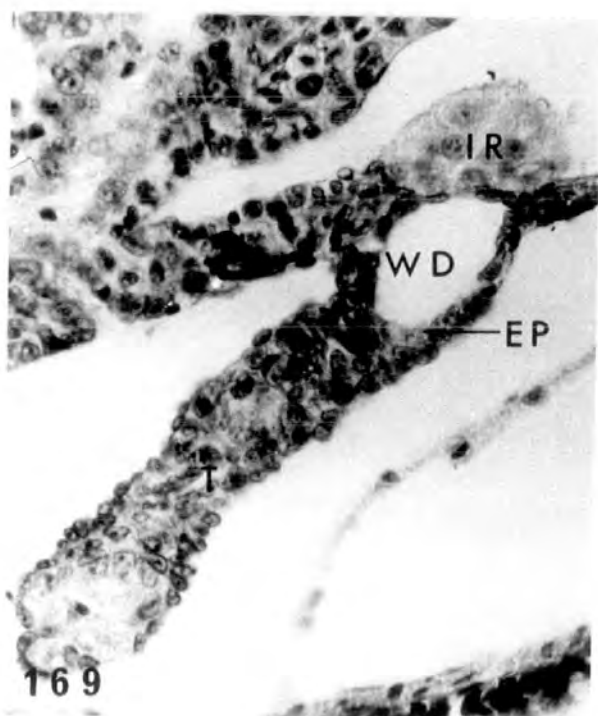
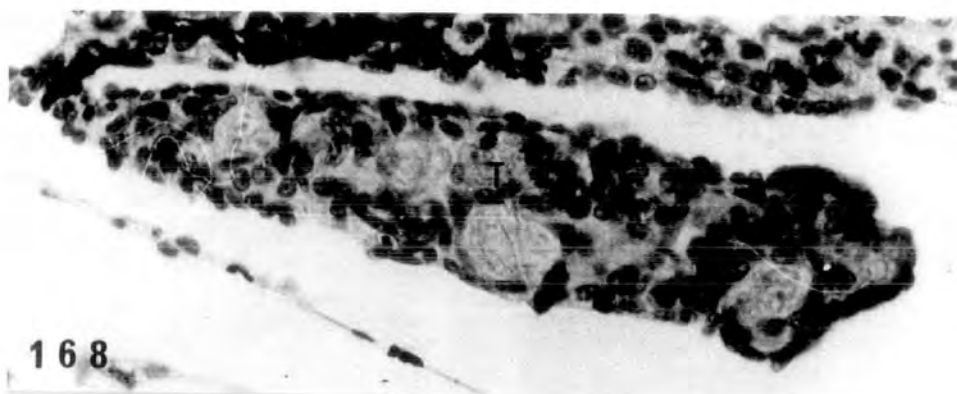
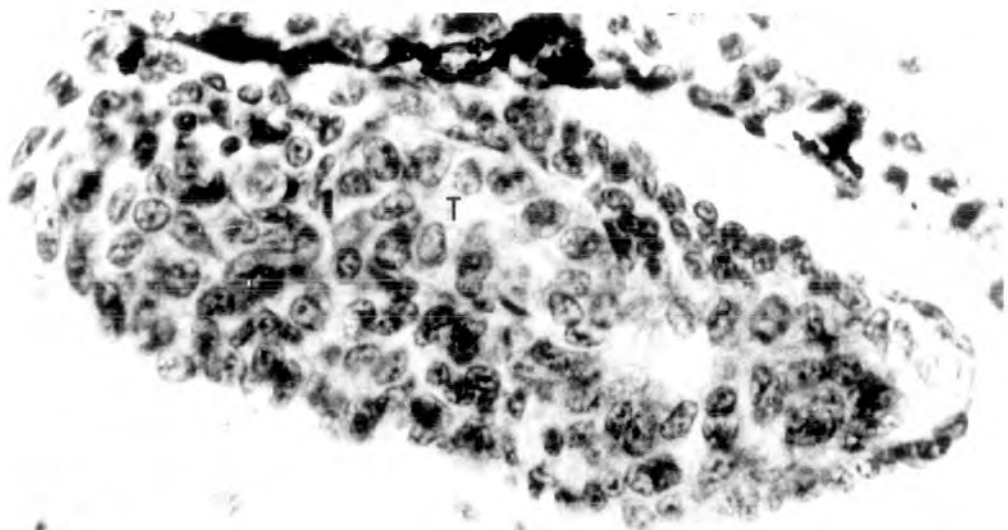


PLATE LII

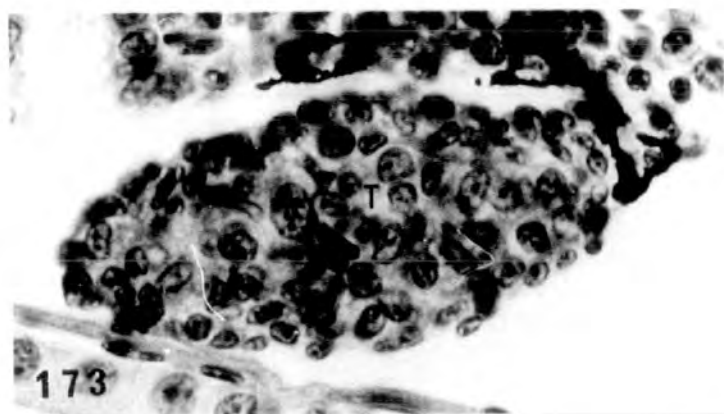
Fig. 172. Testis containing somatic cells and very few spermatogonia (♂[→]Sub †).
x 640.

Fig. 173. Small testis packed with somatic cells but no spermatogonia present (♂[→]Sub †). x 640.

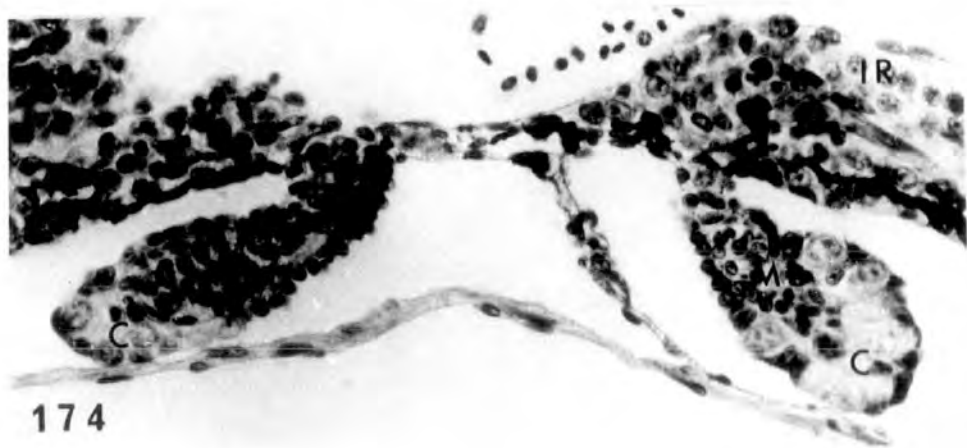
Figs. 174-175. Intersexual gonads from two larvae showing distinct medulla and cortex with the gonia present in the latter. Interrenal hyperplasia evident (♀[→]). x 400.



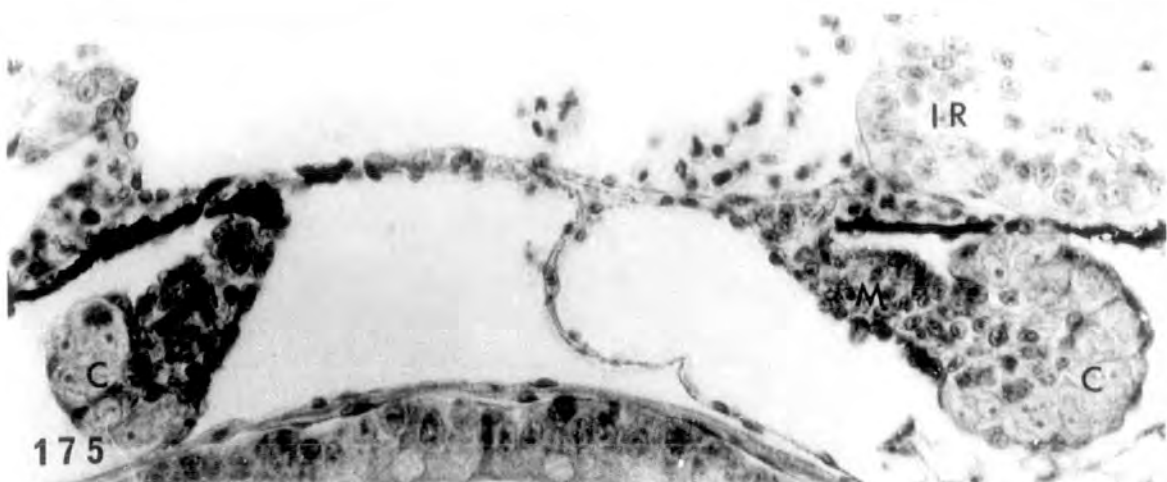
172



173



174



175

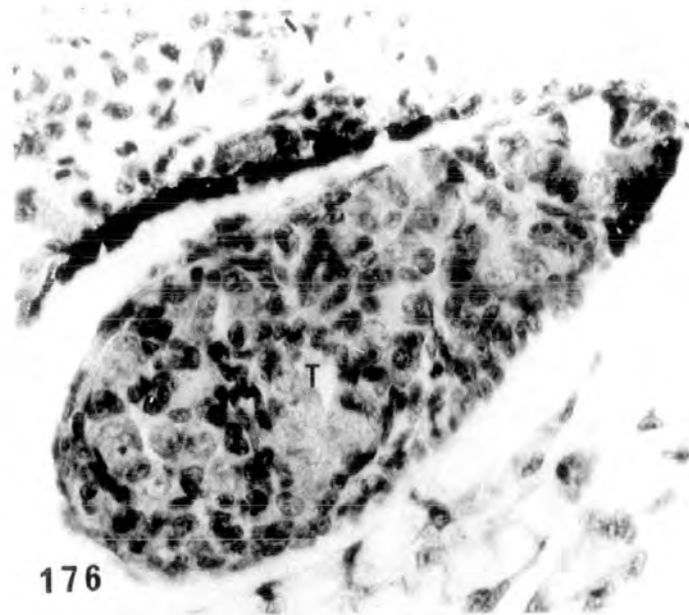
Treatment with 500µg/l

PLATE LIII

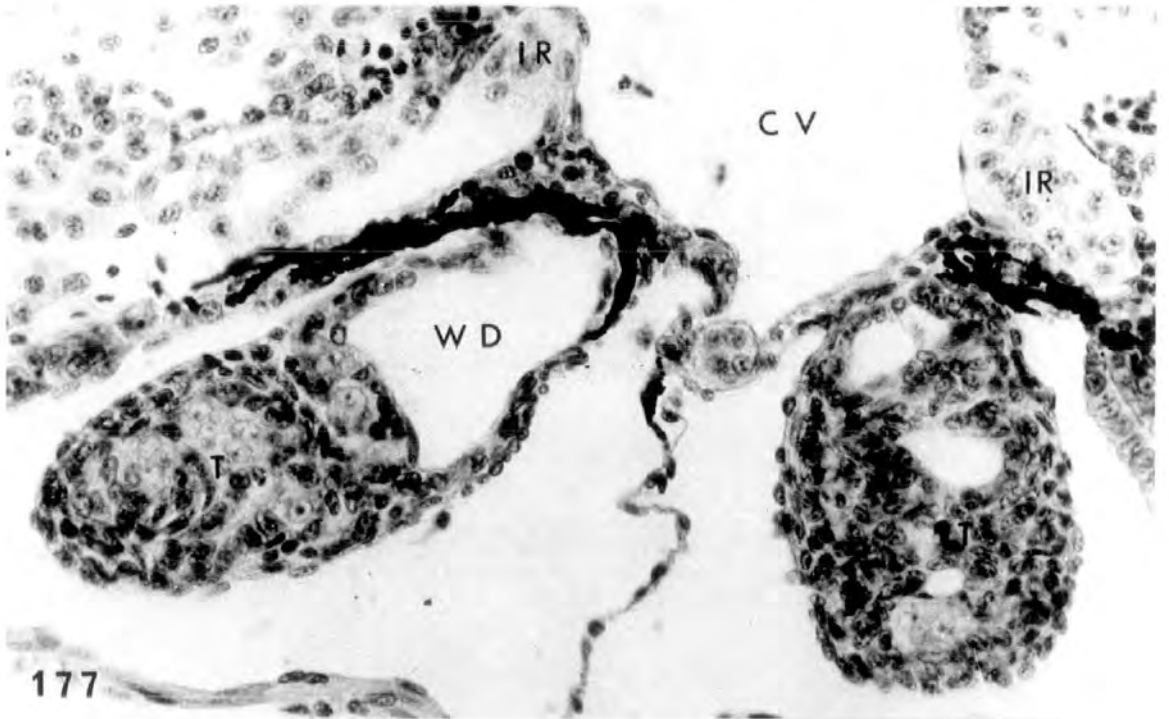
Fig. 176. Testis resembling control (♂ N).
x 400.

Fig. 177. Testes possessing spermatogonia and somatic cells. The cavity in the left testis is probably precocious development of Wolffian duct. Note enlarged interrenal islet on the right of the caval vein (♂ Abn.). x 400.

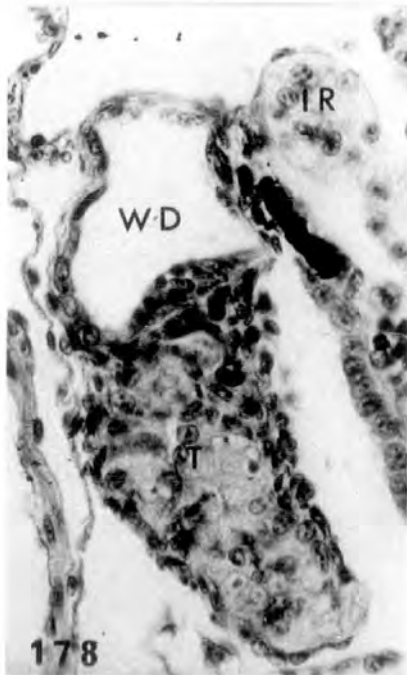
Figs. 178-179. Testes from other tadpoles showing the precocious Wolffian duct development. The cavity is lined by cubical epithelium (♂ Abn.). x 400.



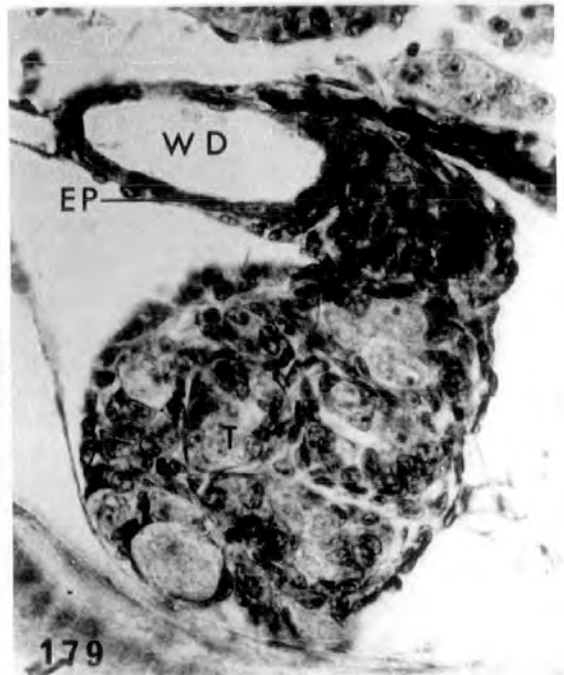176



177



178



179

PLATE LIV

Fig. 180. The prominent cavity at the hilum of the right testis could be precocious development of Wolffian duct. Similar cavity in the left testis (♂ Abn.). Note hypertrophied interrenal. x 400.

Fig. 181. Another larva possessing testes with precocious Wolffian duct development (♂ Abn.). x 400.

Fig. 182. Testis lacking germ cells (♂ Sub †). x 400.

Fig. 183. Reduced testes packed with somatic cells but lacking spermatogonia (♂ Sub †). Hypertrophied interrenal evident. x 400.

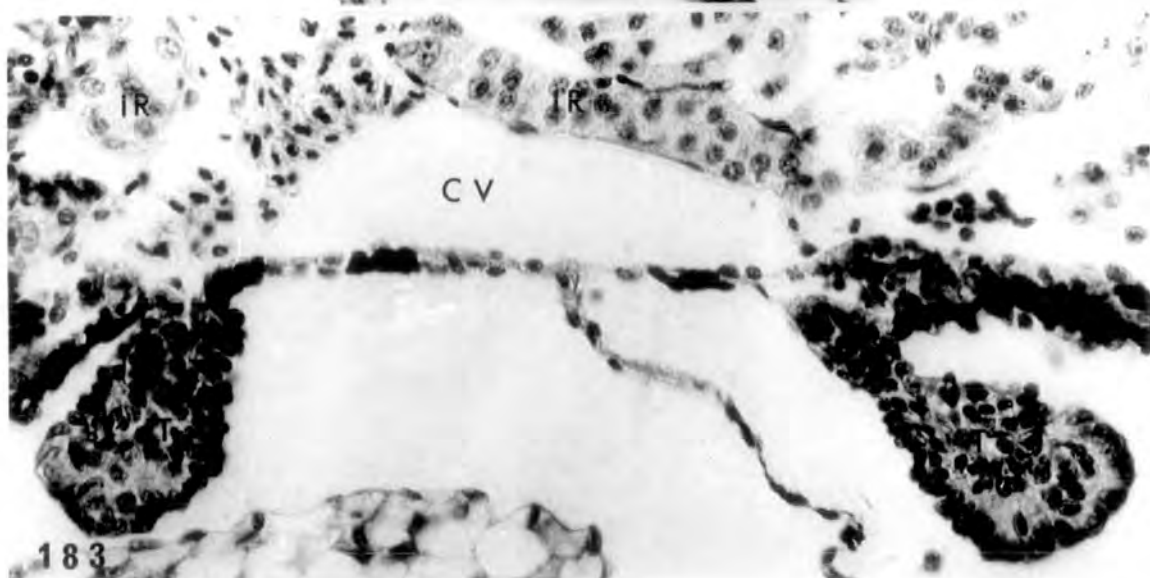
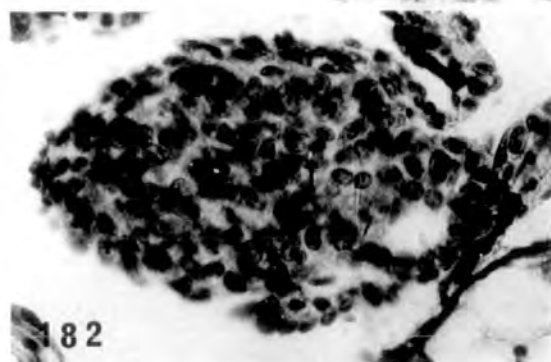
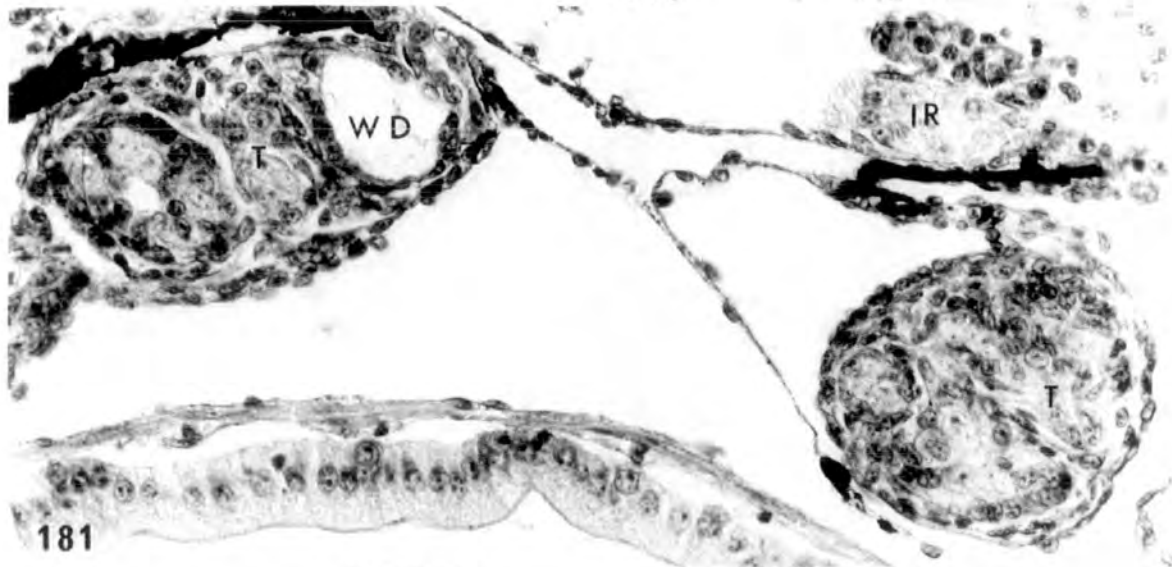
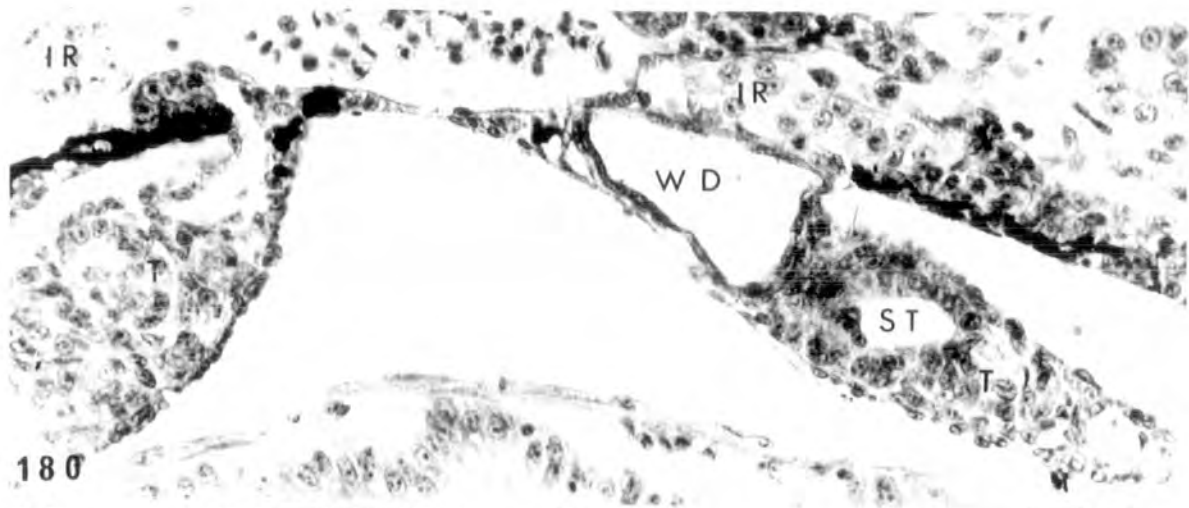
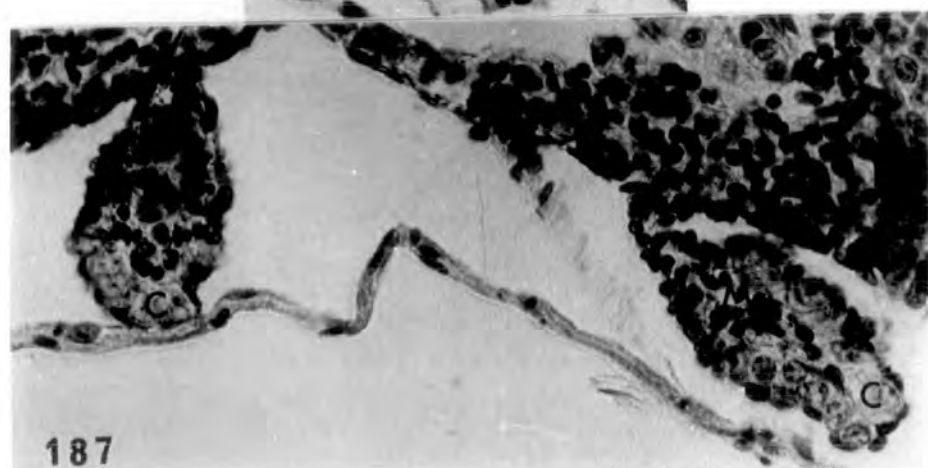
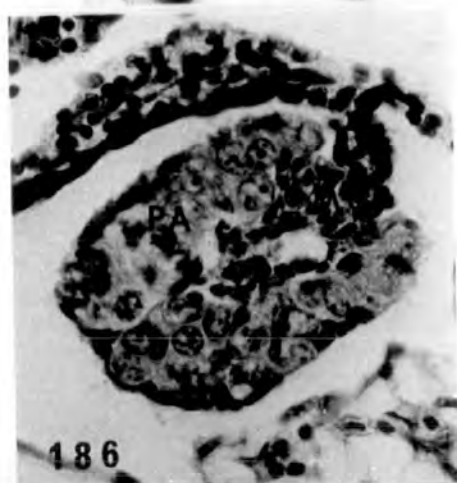
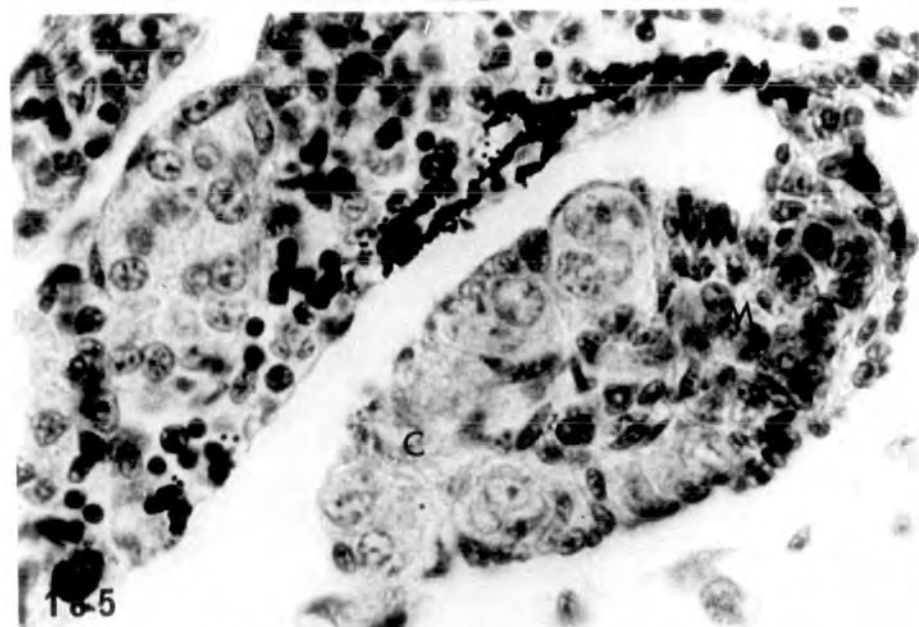
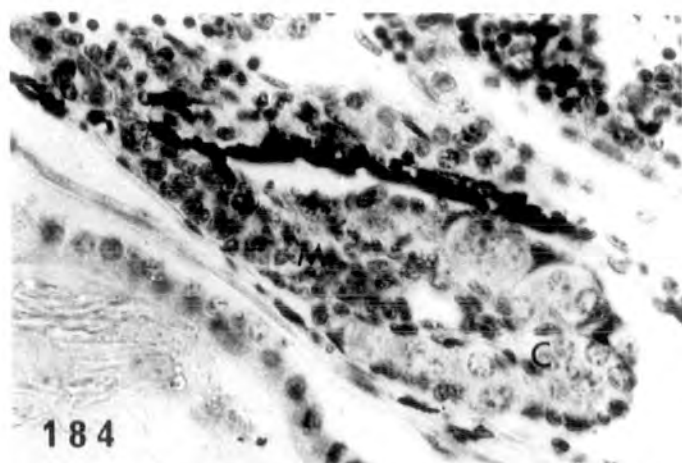
PLATE LV

Figs. 184-185. Intersexual gonads from two larvae showing distinct cortex and medulla. In the first gonads (184) a small ovarian cavity is evident (♂[→]).

184 x 400

185 x 640

Figs. 186-187. The anterior part (186) of the gonad is partially feminized, showing thick cortical region containing some pachytene oocytes. There is a small ovarian cavity and some medullary cells around it. The posterior part (187) is intersexual showing distinct cortex and medulla (♂[→]♀).
x 400.



Treatment with 2mg/l

PLATE LVI

Figs. 188-189. Interrenal hyperplasia evident.

Precocious Wolffian duct development
at the hilum of the left testis.

At the higher magnification the cubical
epithelium can be seen lining the
Wolffian duct (♂ Abn.).

188 x 160

189 x 400

Fig. 190. Apart from the Wolffian duct in the
right testis, further cavitation of the
testicular soma has taken place. Hyper-
trophied interrenal on the left of the
caval vein (♂ Abn.). x 400.

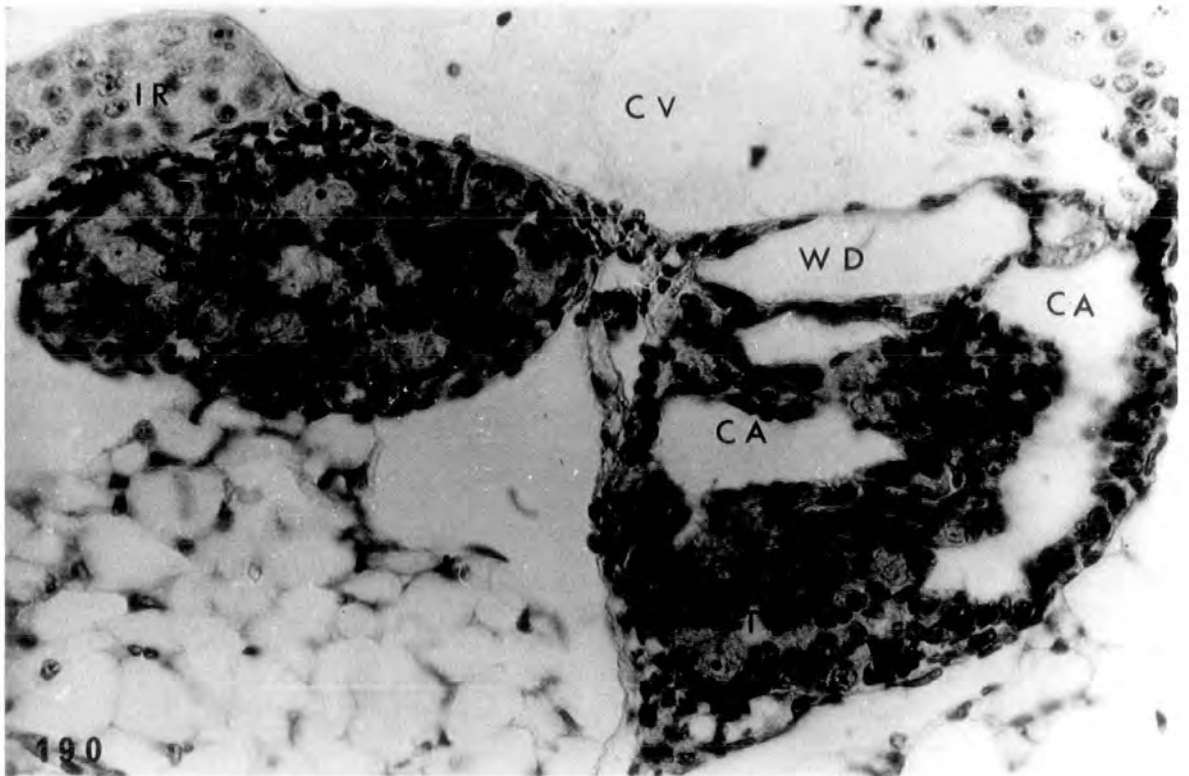
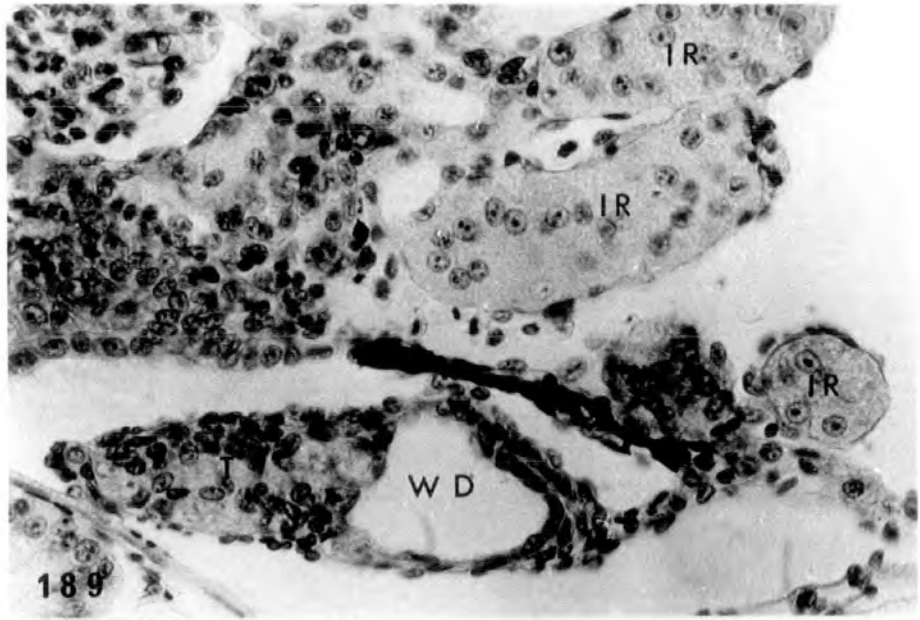
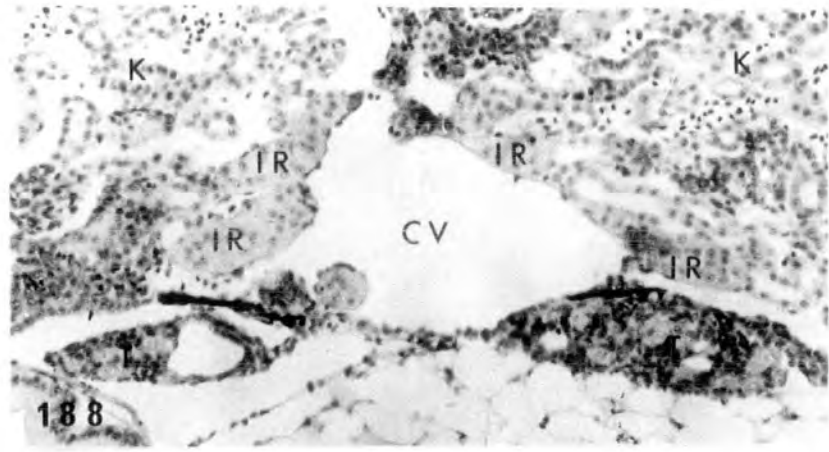
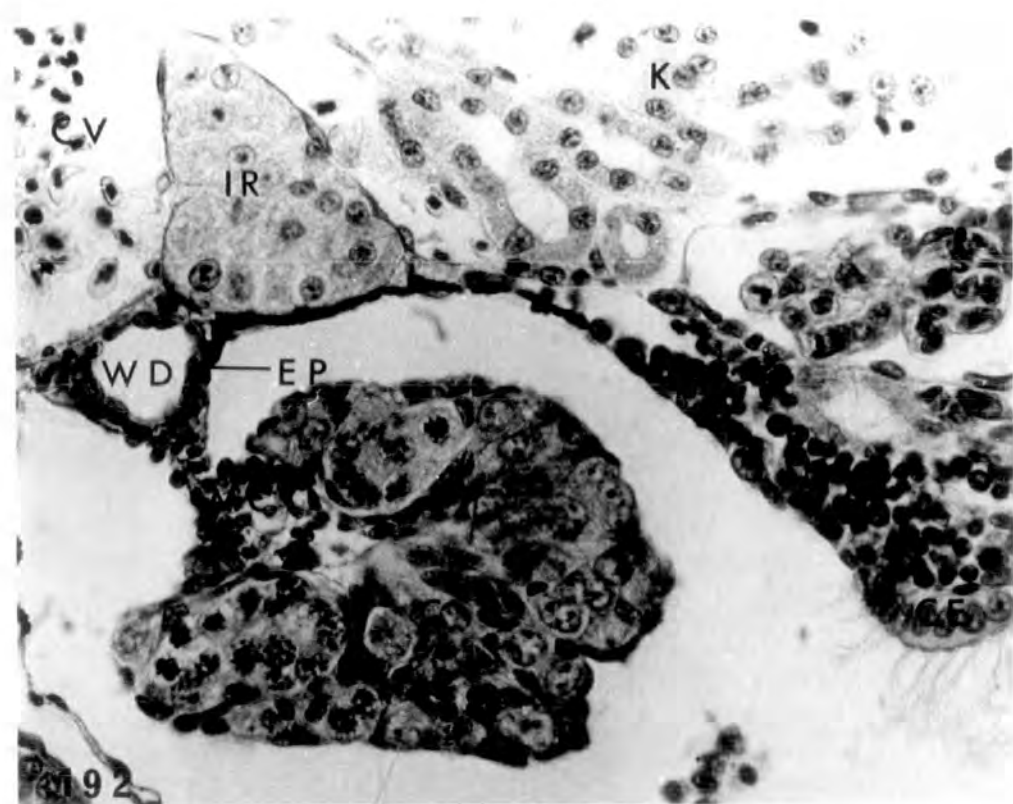
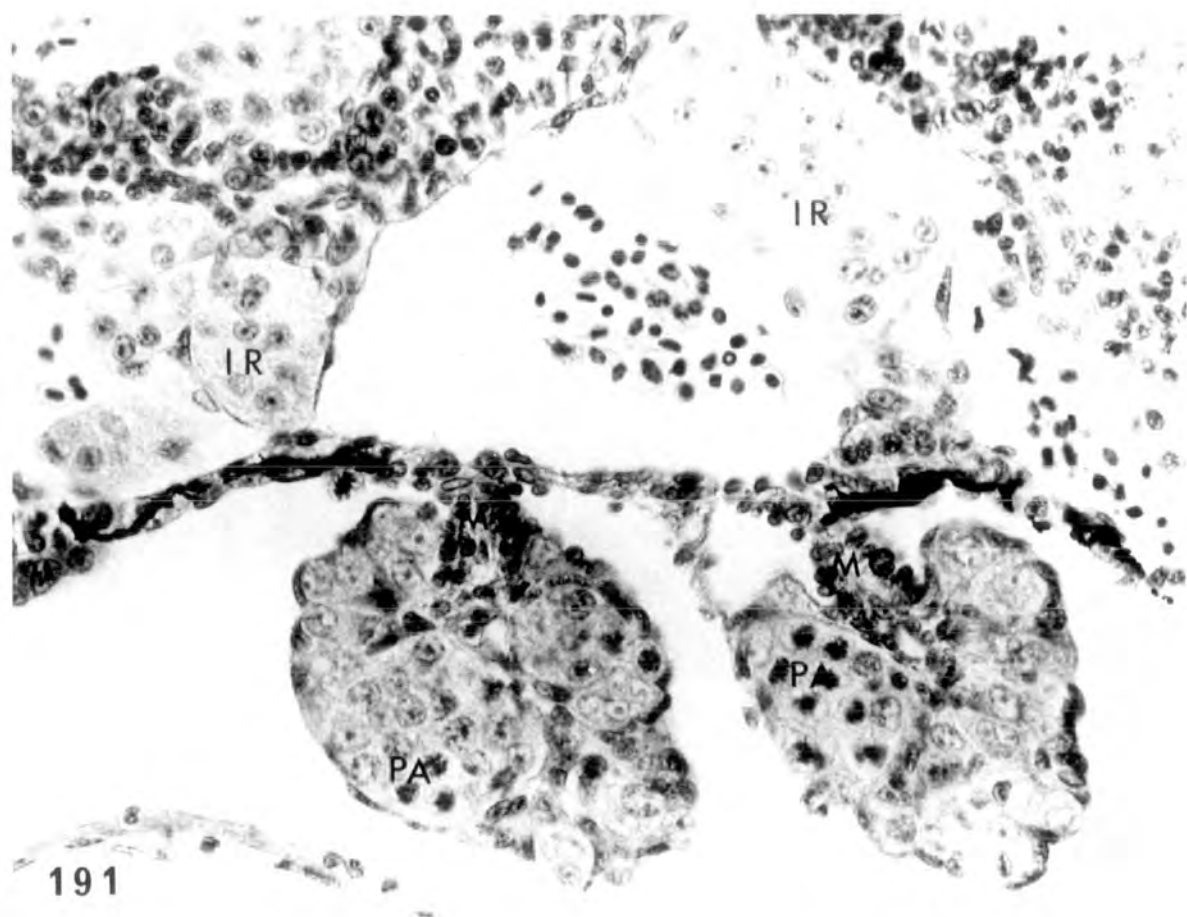


PLATE LVII

Fig. 191. Partially feminized intersexual gonads, possessing thick cortex with pachytene oocytes but instead of the ovarian cavity medullary cells are present. Interrenal islets hypertrophied. (♂-♀). x 475.

Fig. 192. Right gonad of another tadpole showing nests of pachytene oocytes in the thick cortex; no ovarian cavity, but instead medullary cells are present. At the hilum of the gonad a small cavity is present lined by a single layer of epithelium; this could be precocious Wolffian duct development. We could have ambisexual stimulation in the same gonad by the hormone. Interrenal hyperplasia and ciliated kidney epithelium evident (♂-♀). x 475.



Treatment for 26 days (st.51-57) with 25, 100,
500µg/l and 2mg/l cortisone respectively.

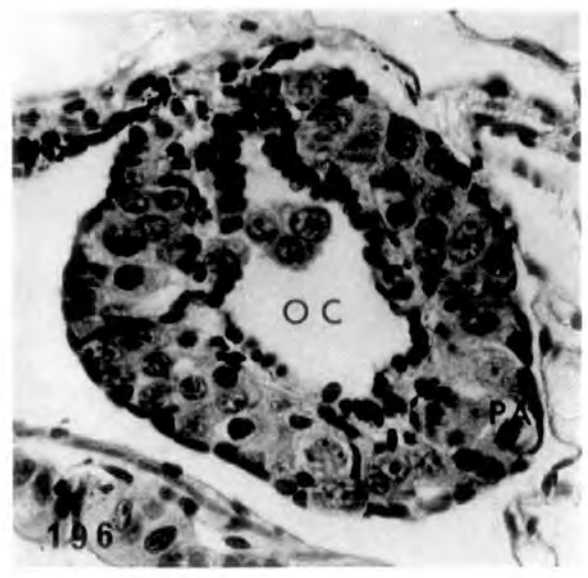
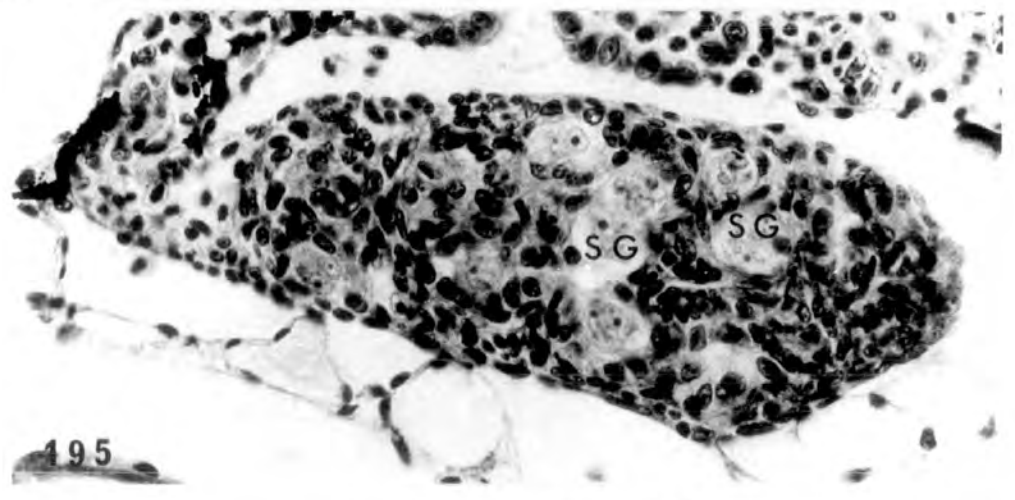
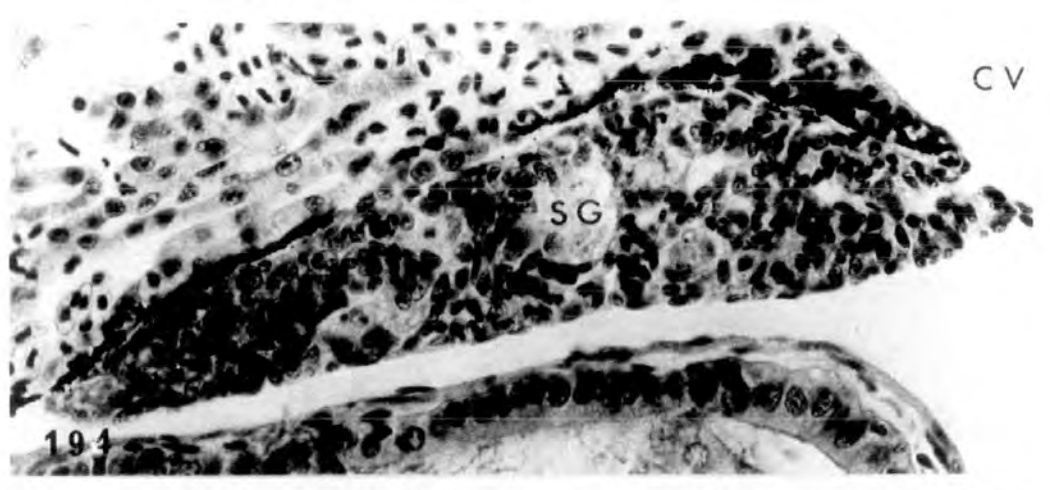
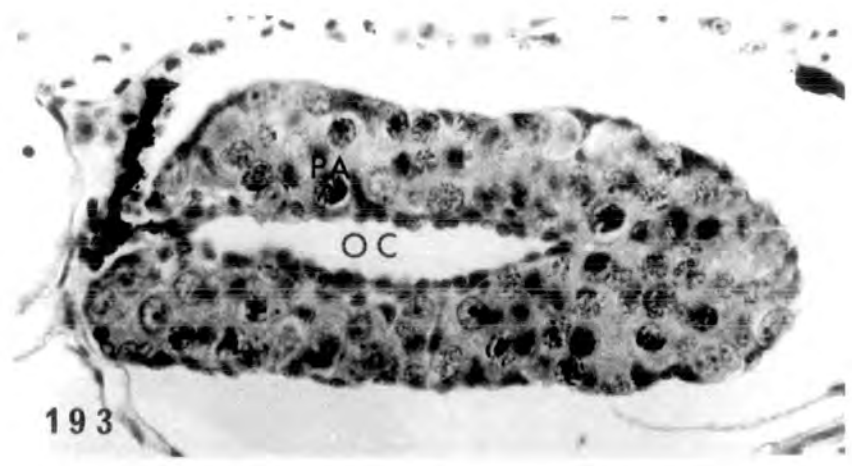
PLATE LVIII

Fig. 193. Control, alcohol treated ovary (♀ N). x 400.

Fig. 194. Control, alcohol treated testis
(♂ N). x 400.

Fig. 195. Treatment with 25µg/l normal testis
containing nests of spermatogonia
surrounded by somatic cells (♂ N).
x 400.

Fig. 196. Treatment with 25µg/l ovary
resembling control, showing pachytene
oocytes in the thick cortex (♀ N).
x 400.



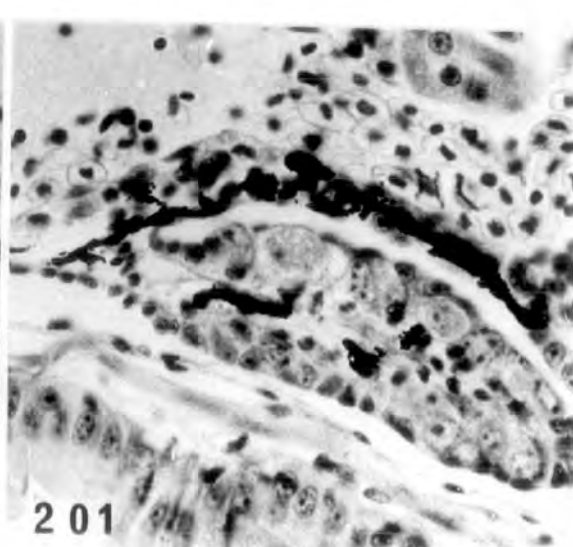
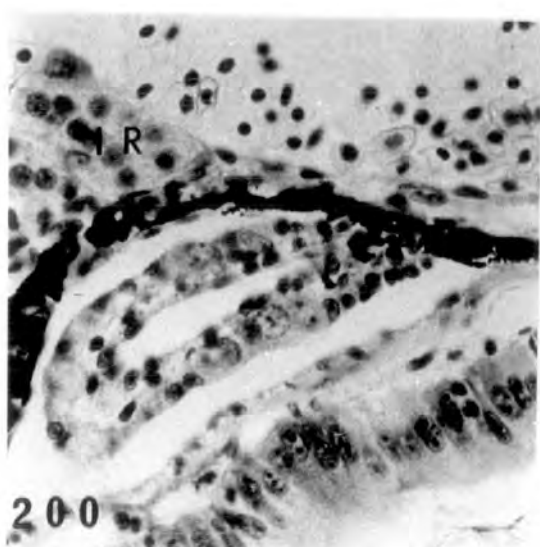
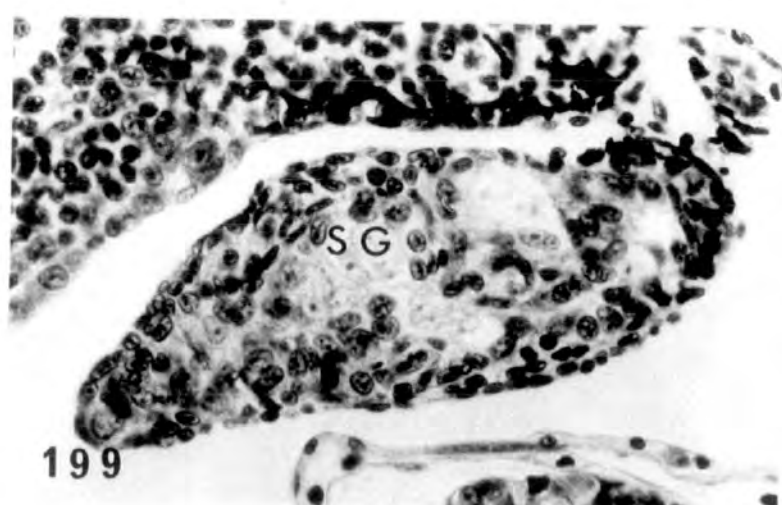
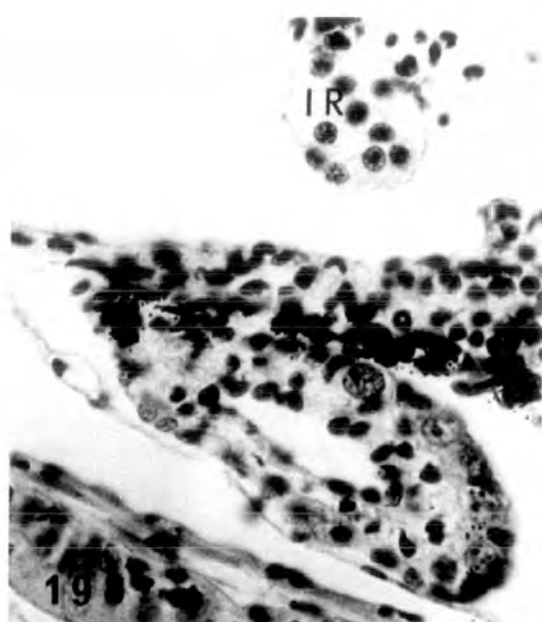
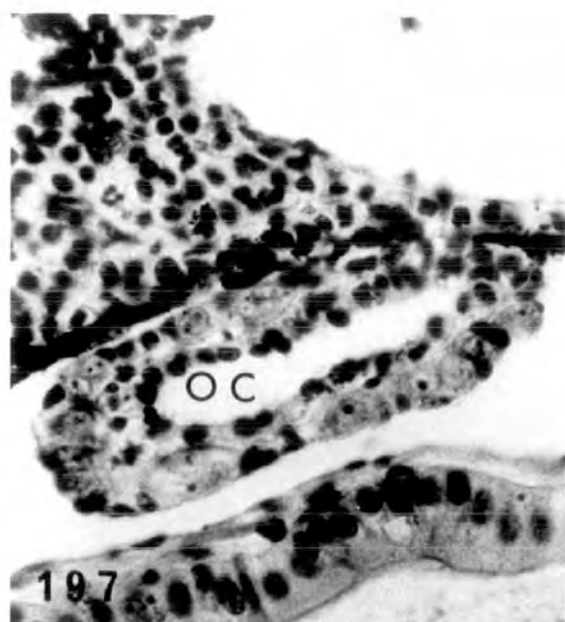
Treatment with 25µg/l and 100µg/l respectively

PLATE LIX

Fig. 197-198. Treatment with 25µg/l. Small, inhibited ovaries with no pachytene oocytes in the cortex (♀ +). x 500.

Fig. 199. Treatment with 100µg/l testis resembling control (♂ N). x 500.

Figs. 200-201. Treatment with 100µg/l. Inhibited ovaries smaller than control, no pachytene oocytes in the cortex and no obvious cavity present in the right (201) ovary (♀ +). x 500.



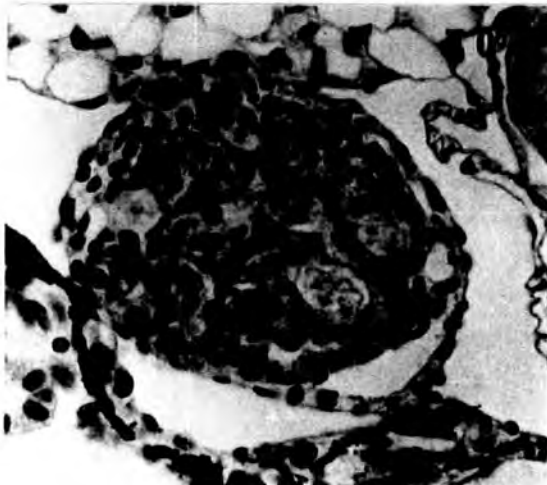
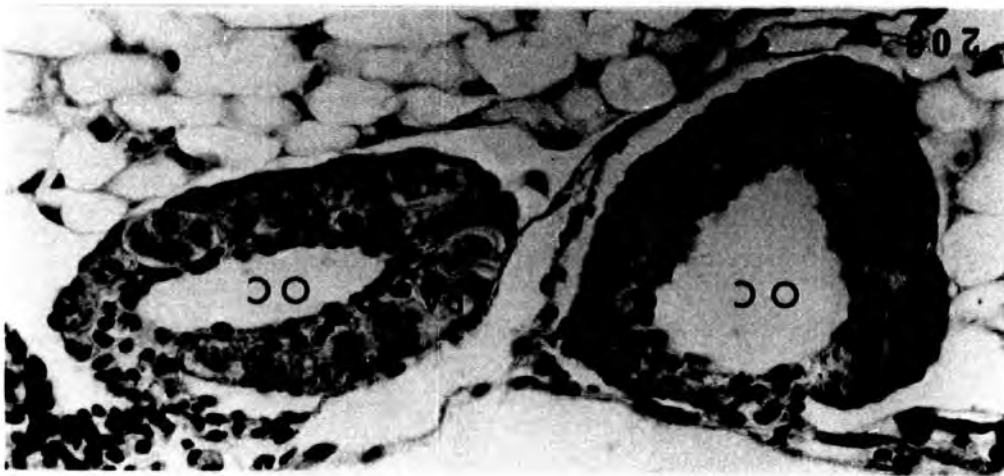
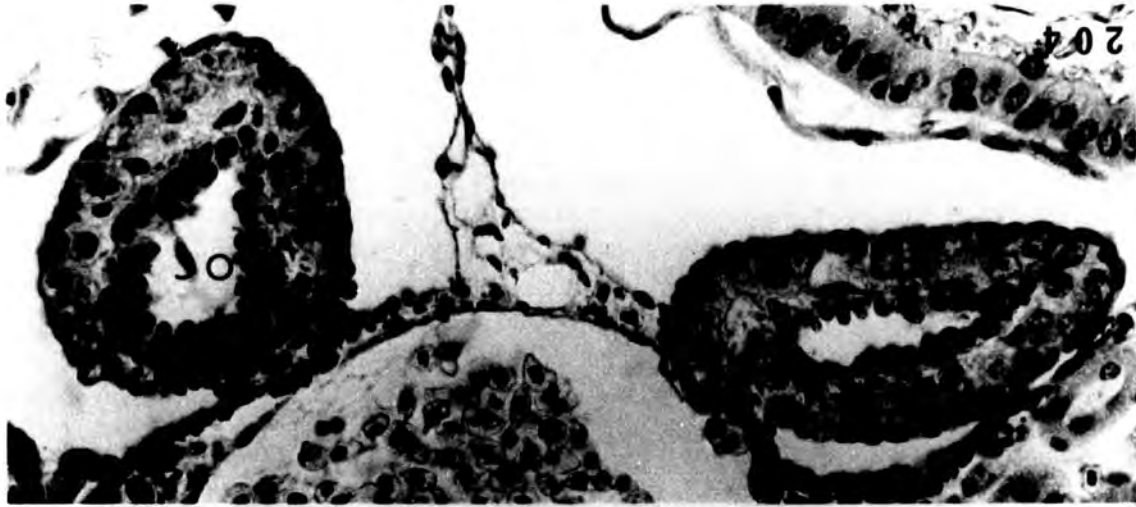
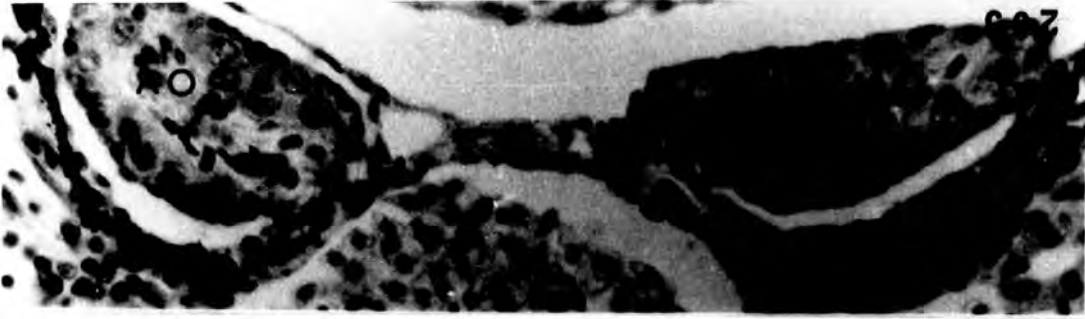
Treatment with 500µg/l

PLATE LX

Fig. 202. Testis resembling control (♂ N).
x 450.

Fig. 203. Normal ovaries with pachytene oocytes
in the cortex (♀ N). x 450.

Figs. 204-205. Anterior ovarian region showing
ovarian cavities but no pachytene
oocytes in the cortex, and posterior
ovarian region devoid of both
cavities and pachytene oocytes
(♀ +). x 450.



Treatment with 2mg/l

PLATE LXI

Fig. 206. Testes resembling control (♂^N).
x 400.

Figs. 207-209. Anterior part of the gonadal
region (207-8) showing testes with
large cavities. The cavity at the
hilum of each testis could be
precocious development of Wolffian
duct. Posterior part (209) is a
testis with a large cavity (♂^{Abn.}).
x 400.

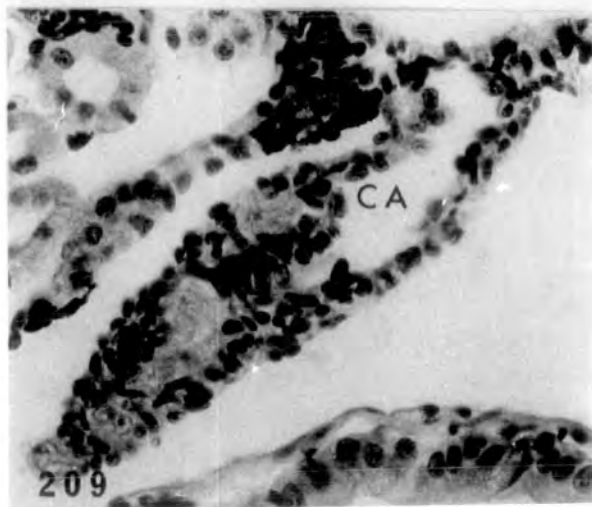
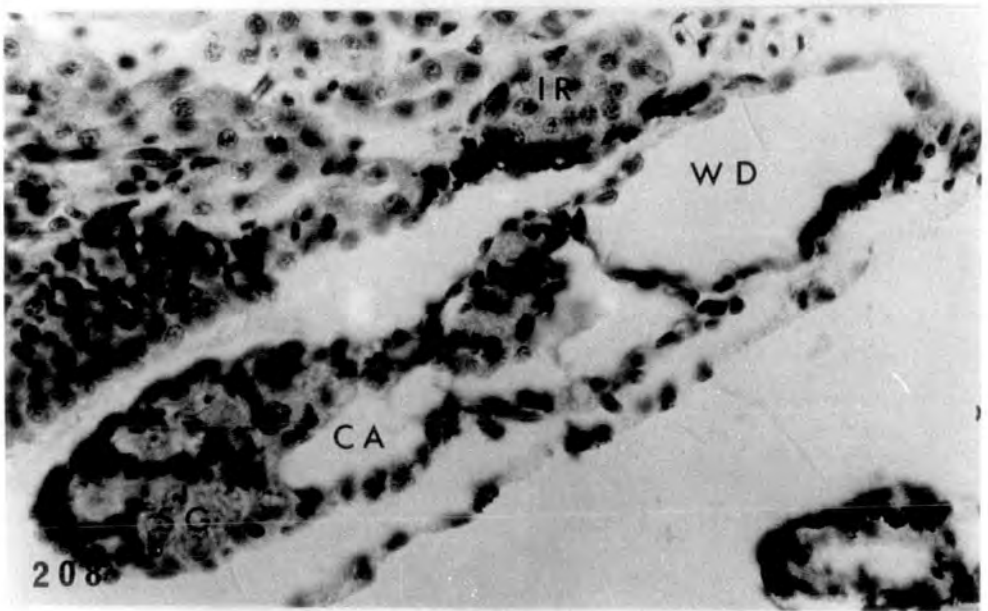
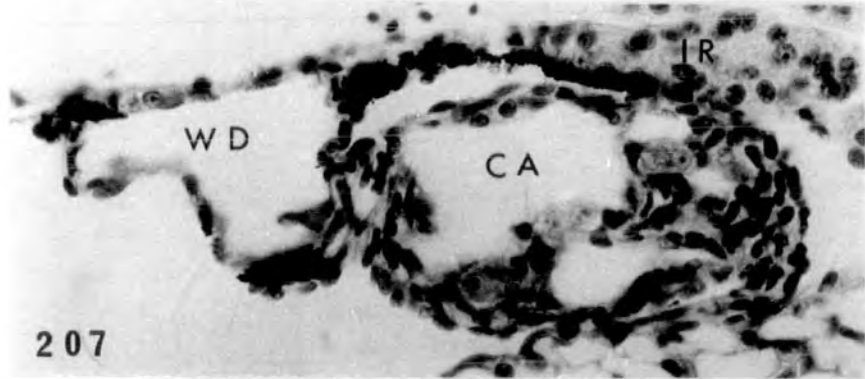
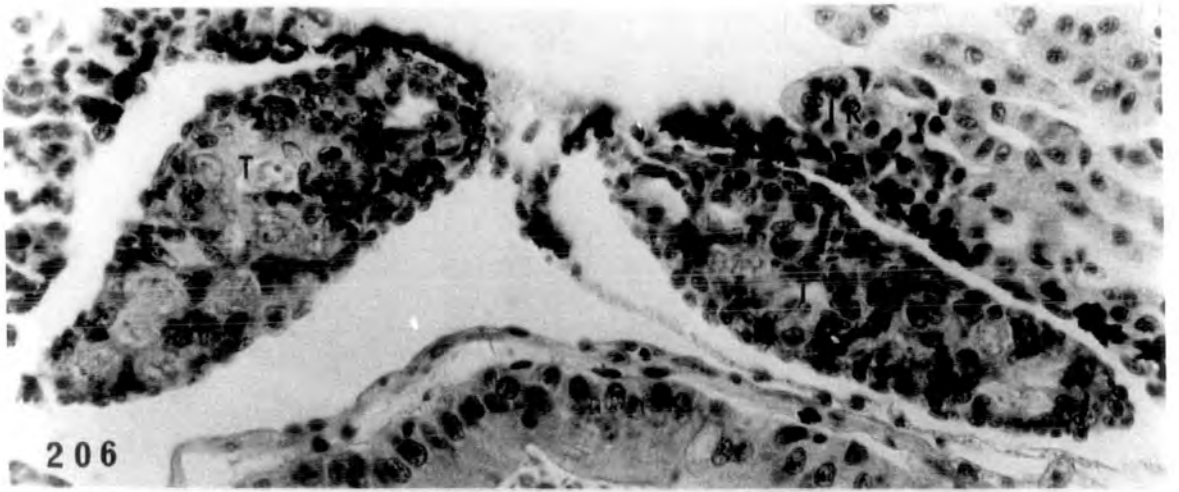
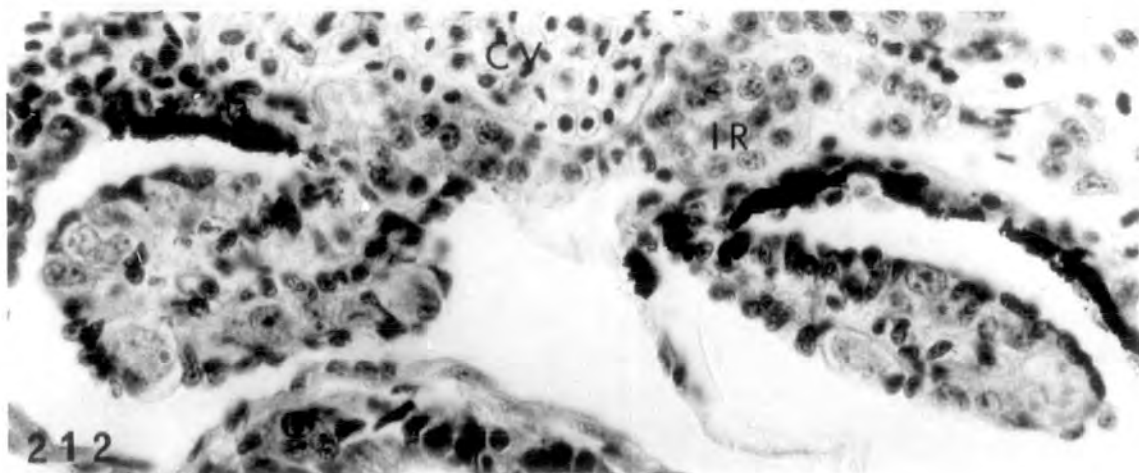
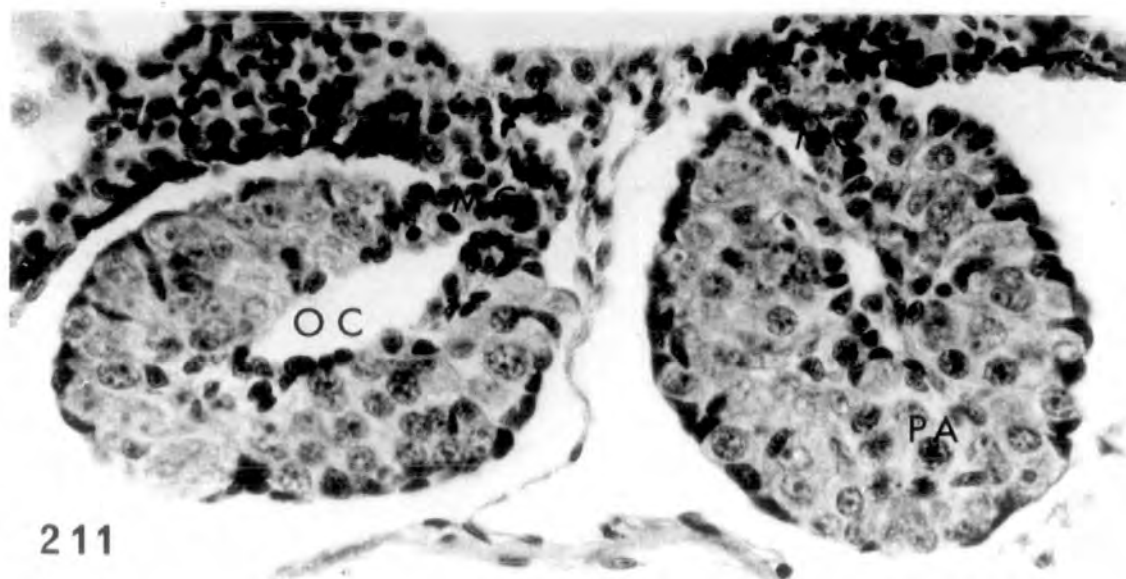
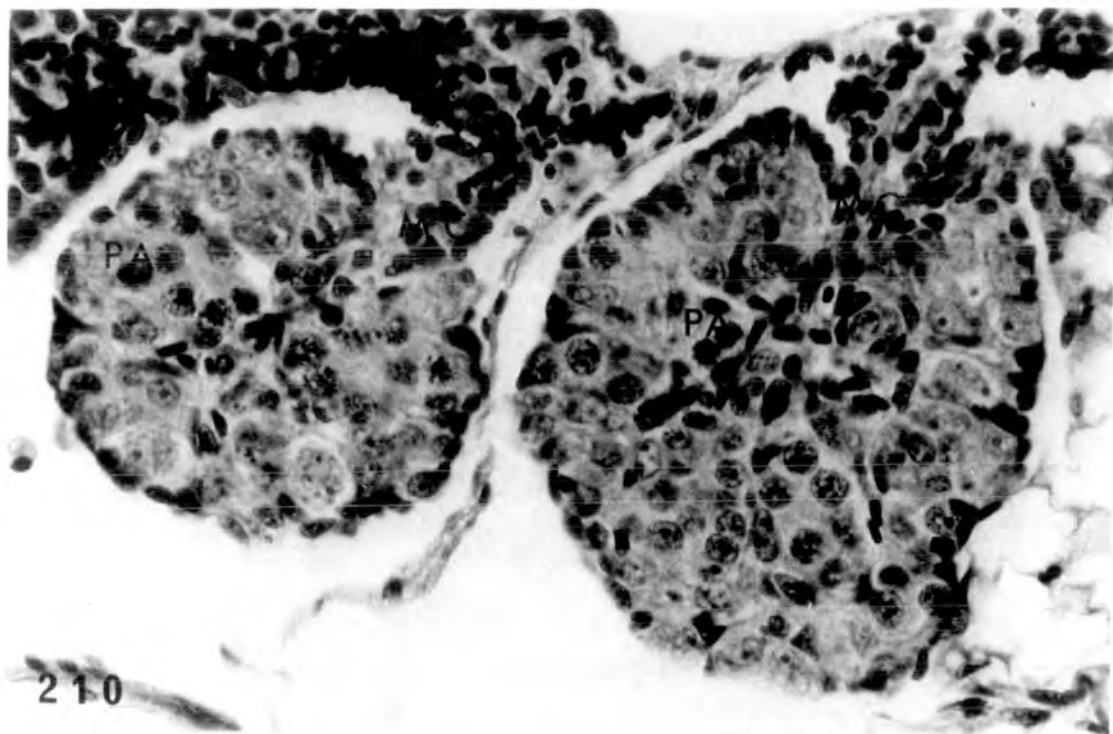


PLATE LXII

Figs. 210-212. Three sections through the gonadal region of tadpole; the anterior part (210-211) is slightly intersexualised showing ovaries with thick cortex containing pachytene oocytes, but ovarian cavity small in 211 and absent in 210. Small intersexual gonads (212) at hind end (♂-♀). x 500.



Tissue culture of gonads

Gonads maintained in vitro for 12 days with no hormone
added

PLATE LXIII

Fig. 213. Testis from st.54 showing good survival
progression to st.55. x 640.

Fig. 214. Ovaries from st.55 showing reasonable
survival but no development. x 200.

Fig. 215. Testes from st.55 well maintained and
progressed to st.56. Nests of
spermatogonia can be seen surrounded
by smaller somatic cells. x 640.

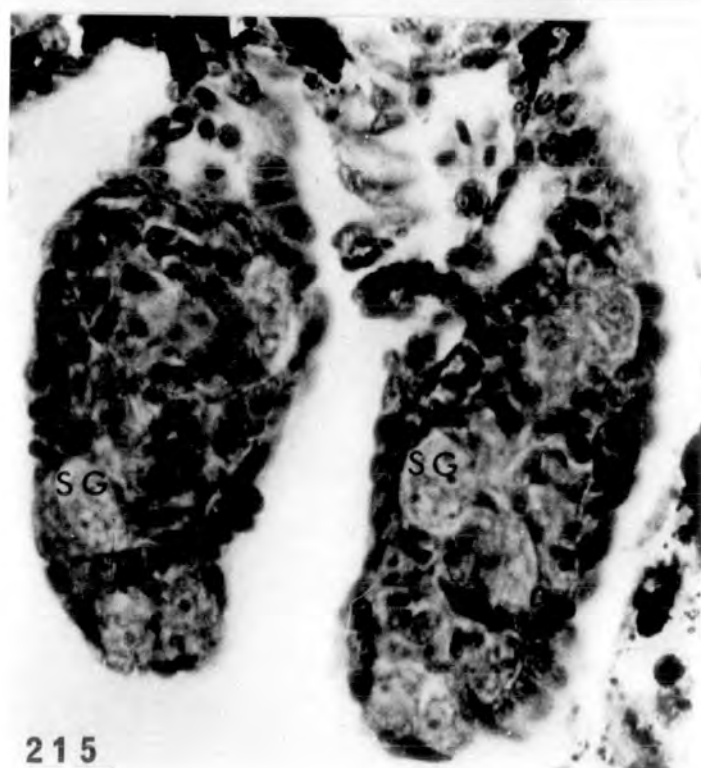
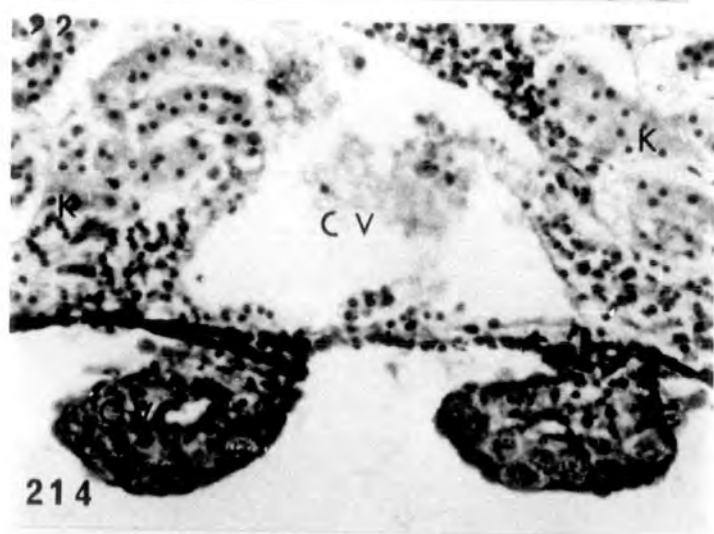
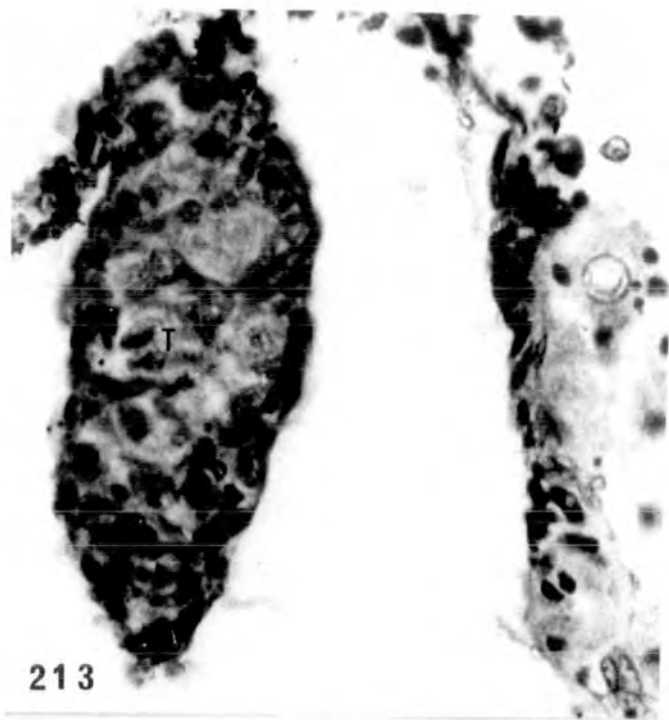


PLATE LXIV

Fig. 216-217. Longitudinal section of cultured st.56 testes. Seven segments of one testis are shown, most of them containing nests of spermatogonia. In 217 the nests of spermatogonia are obvious.

216 x 170

217 x 680.

Fig. 218. Well maintained st.56 testes.

x 680.

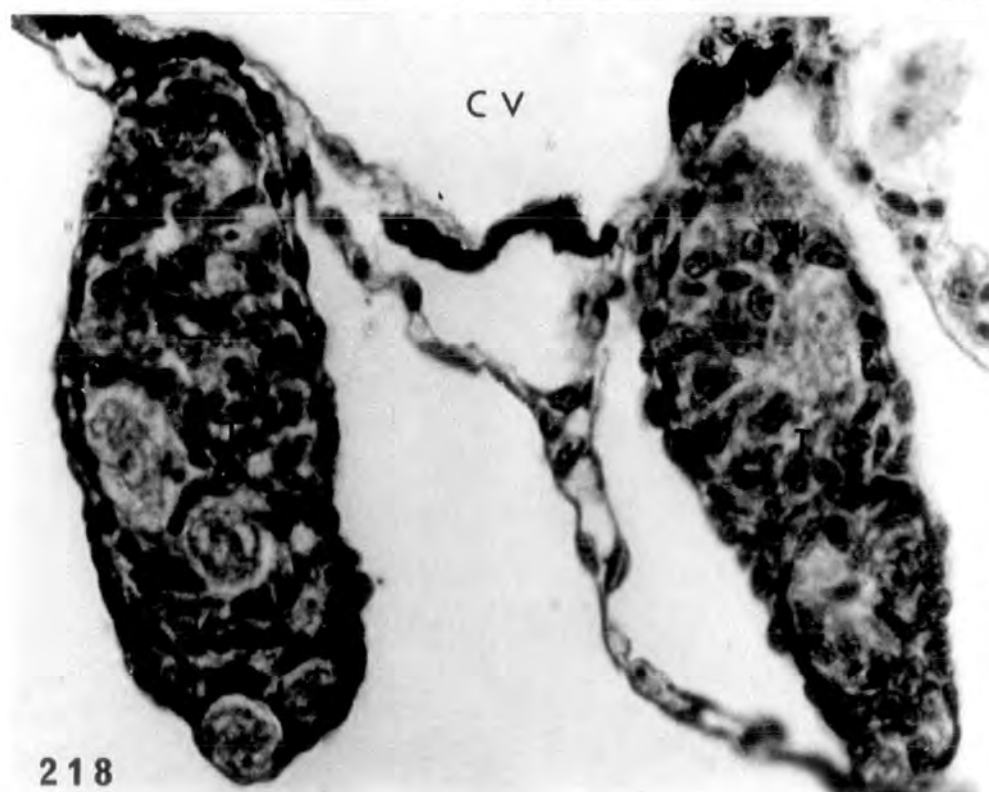
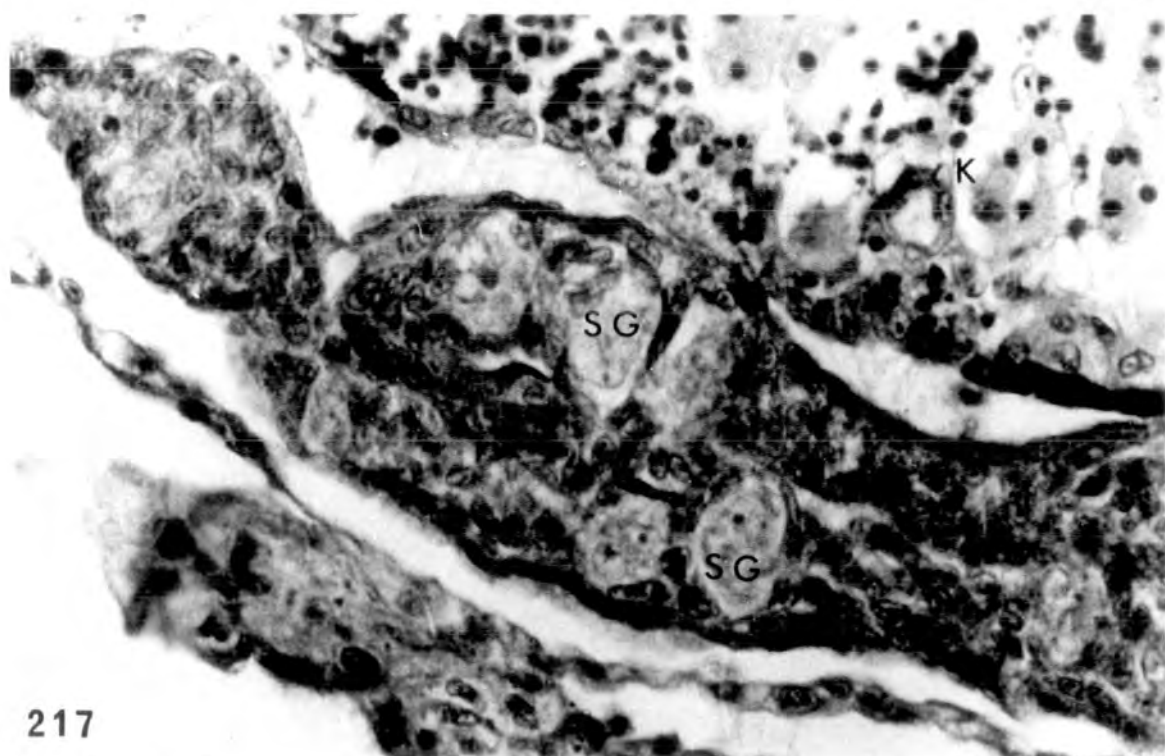
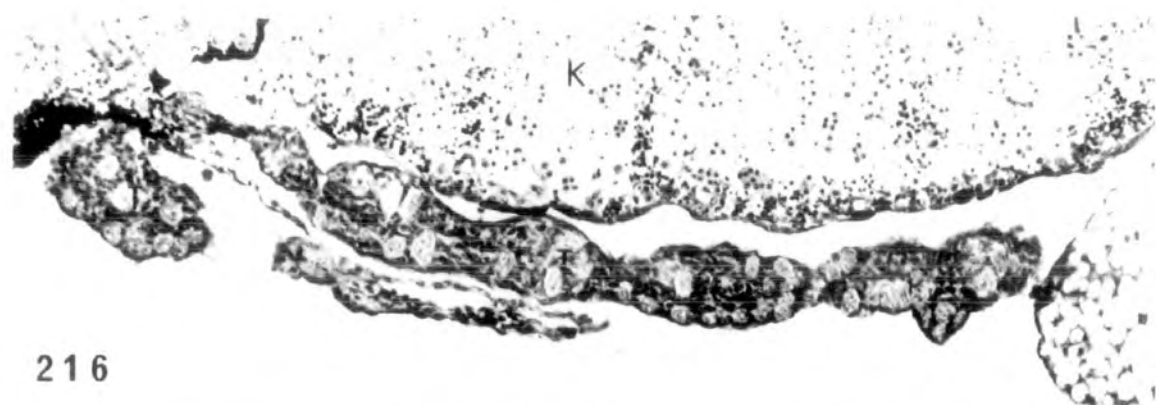


PLATE LXV

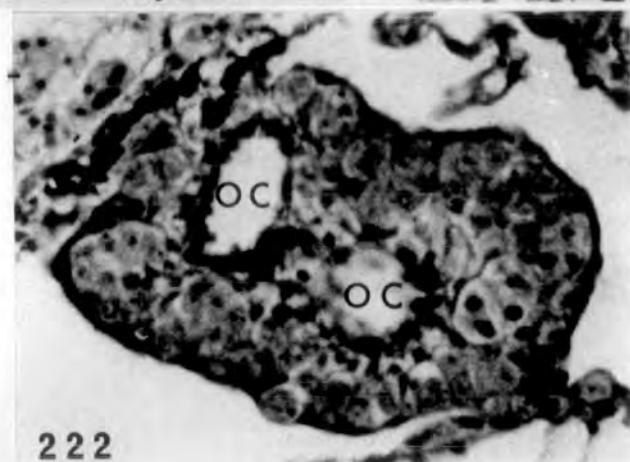
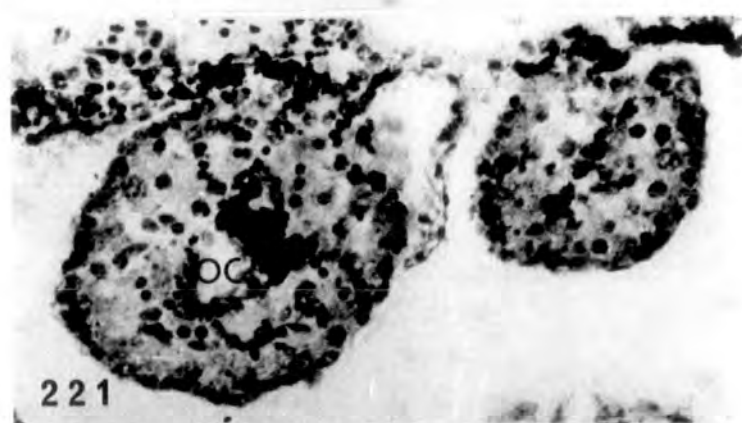
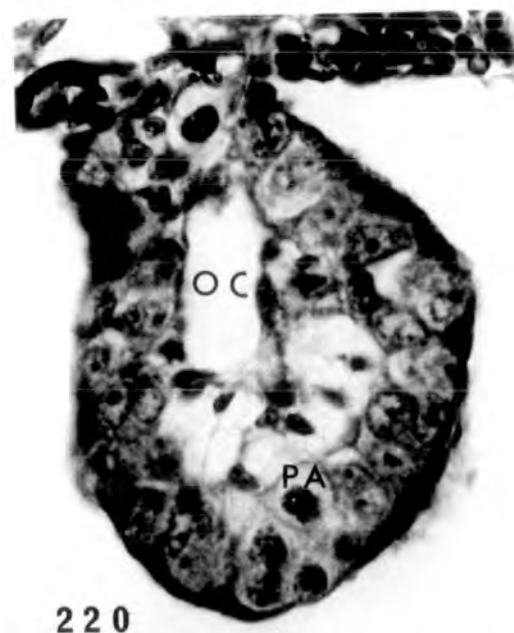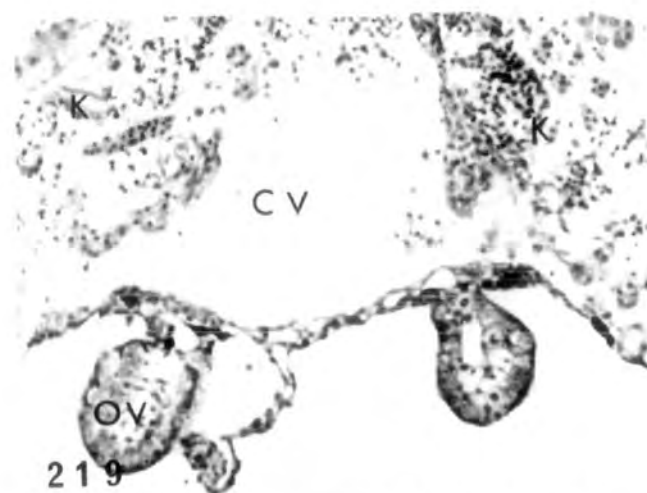Figs. 219-220. Well maintained ovaries in vitro from st.55 tadpole, progressed to st. 56. At the higher magnification the pachytene oocytes in the cortical region are obvious.

219 x 160

220 x 640

Fig. 221. Ovaries from st.56 tadpole treated with 200µg/l oestradiol not well maintained in vitro. Ovarian cavity can be seen in the left ovary. No detectable hormone effect. x 320.

Fig. 222. Ovary from st.56 larva treated with 600µg/l oestradiol. Well maintained in vitro and showing a double ovarian cavity because it was sectioned obliquely. Some pachytene oocytes can be seen in the cortex.
x 320.



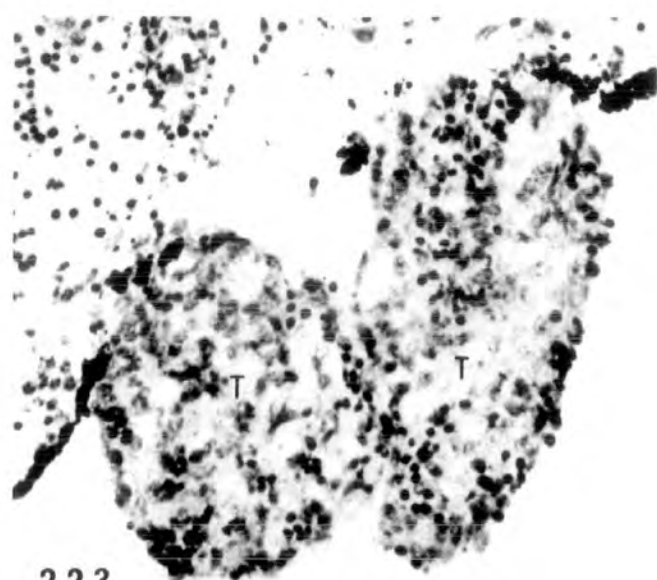
Gonads maintained in vitro for 12 days
and treated with oestradiol.

PLATE LXVI

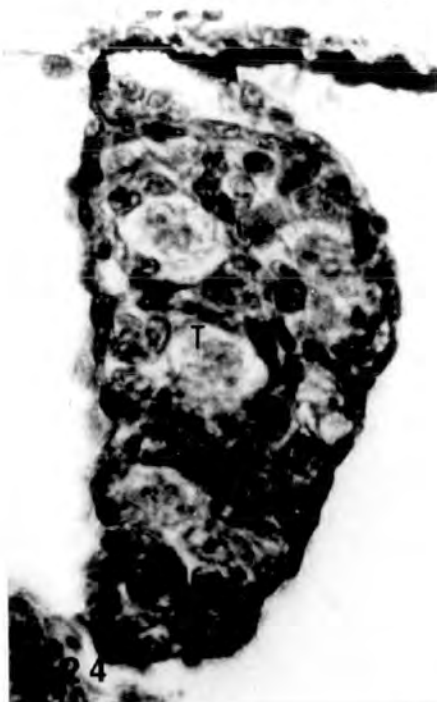Fig. 223. St.56 testes treated with 200 μ g/l oestradiol,
not well maintained. Integrity of
spermatogonia not well preserved. No
detectable hormone effect. x 320.

Fig. 224. St.56 testis treated with 200 μ g/l oestradiol,
well maintained. No detectable hormone
effect. x 640.

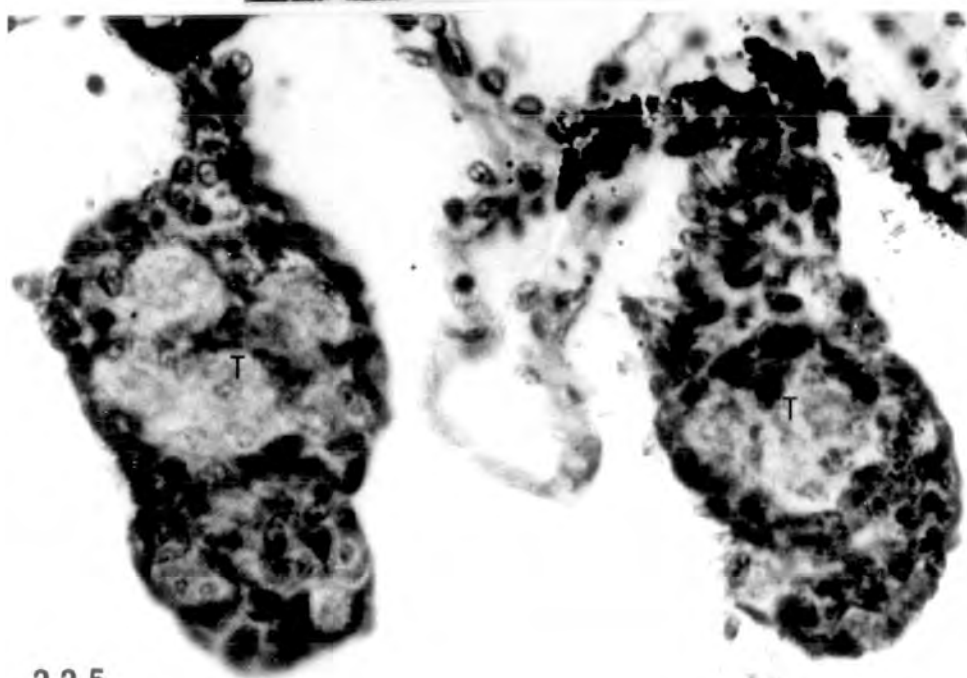
Fig. 225. St. 56 testes treated with 600 μ g/l oestradiol,
well maintained. No detectable hormone
effect. x 640.



223



224



225

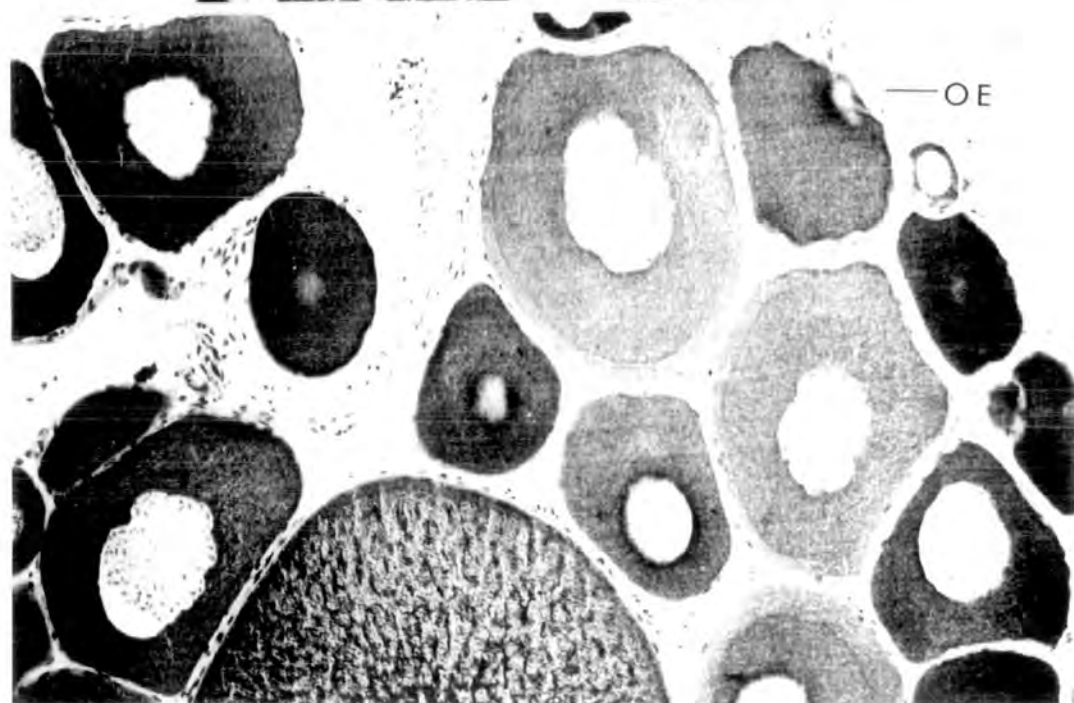
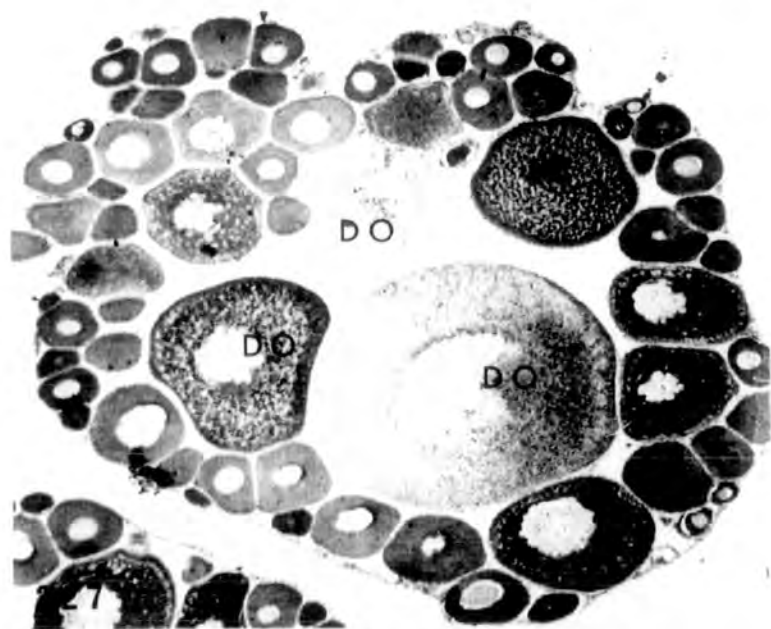
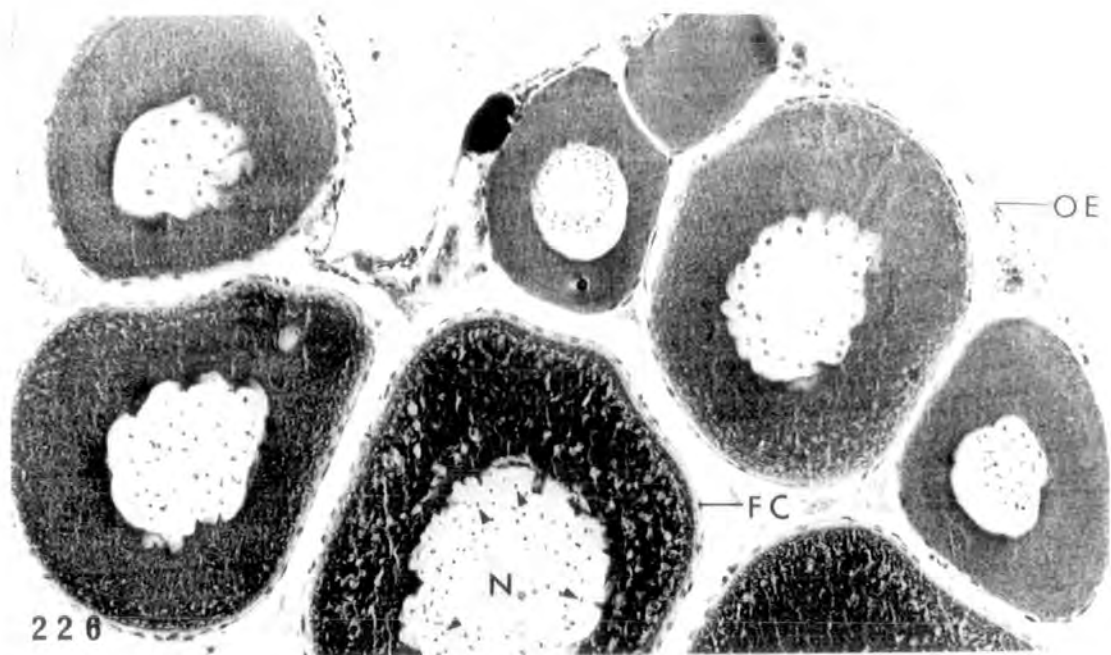
Toad ovary, 12 months old,
in vivo and in vitro respectively

PLATE LXVII

Fig. 226. Section of normal, in vivo, ovary showing previtellogenic oocytes each with a nucleus containing numerous peripherally distributed nucleoli (arrowheads). Small follicle cells are also evident. x 160.

Fig. 227. Section of cultured, in vitro, ovary for 15 days showing some degenerating oocytes in the central region. The overall structure is well maintained. x 40.

Fig. 228. Section of the ovary in vitro for 15 days at higher magnification. The epithelium around the ovary is not as well preserved as in the in vivo situation. x 160.

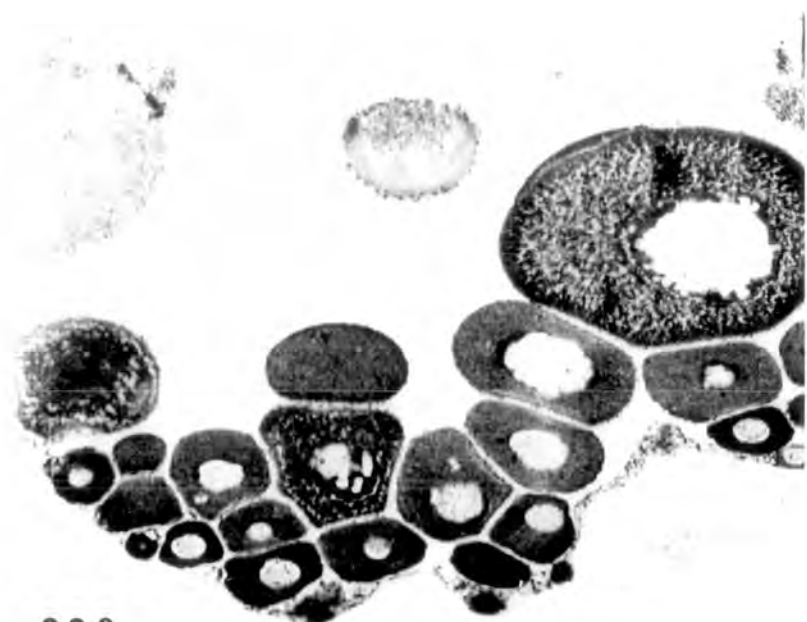


Toad ovary, 12 months old, treated in vitro
with oestradiol for 15 days.

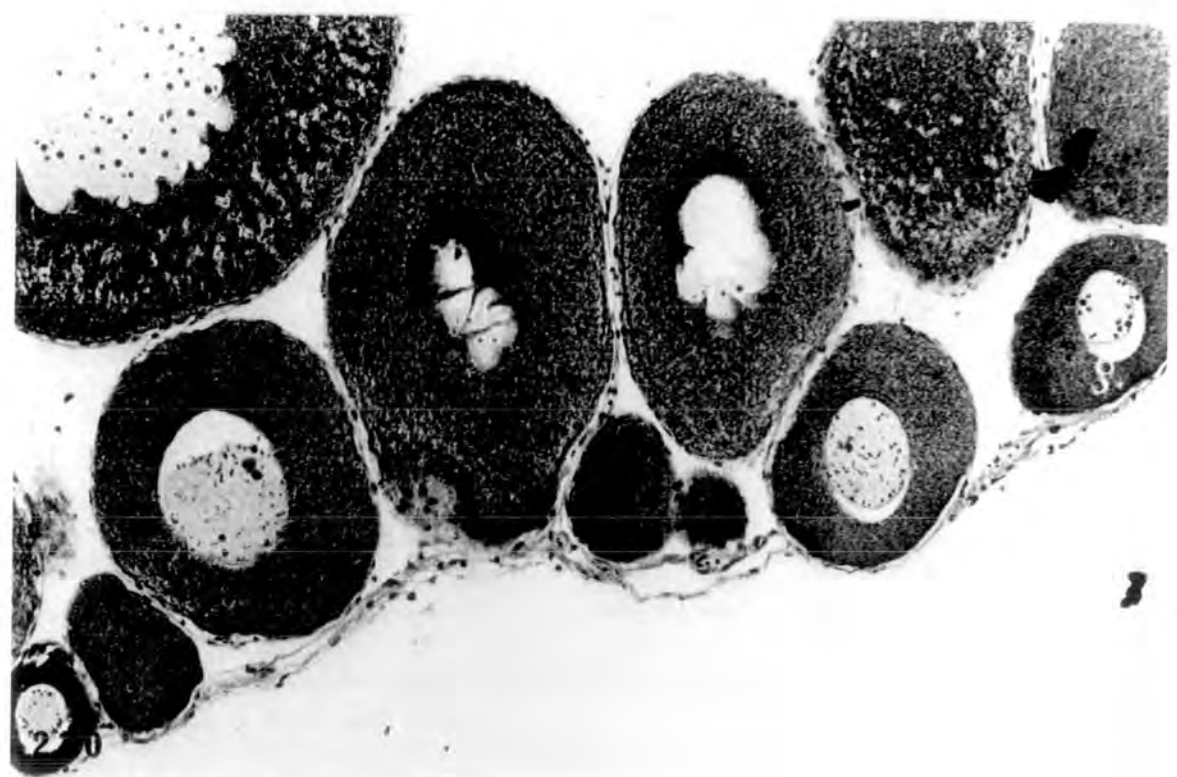
PLATE LXVIII

Fig. 229. Ovary treated with 200 μ g/l. Some degenerating oocytes are evident but no detectable hormone effect. x 64.

Fig. 230. Ovary treated with 600 μ g/l. Structure maintained well but no detectable hormone effect. x 160.



229

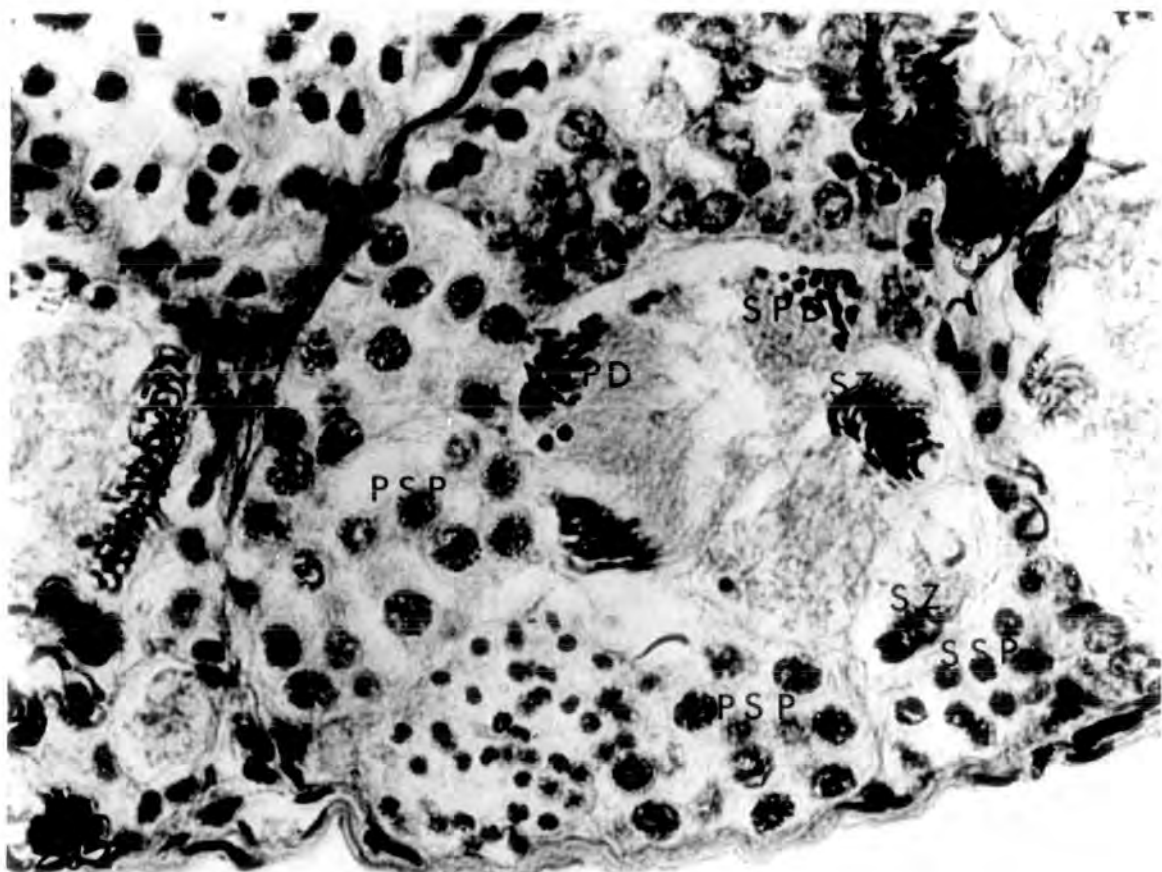
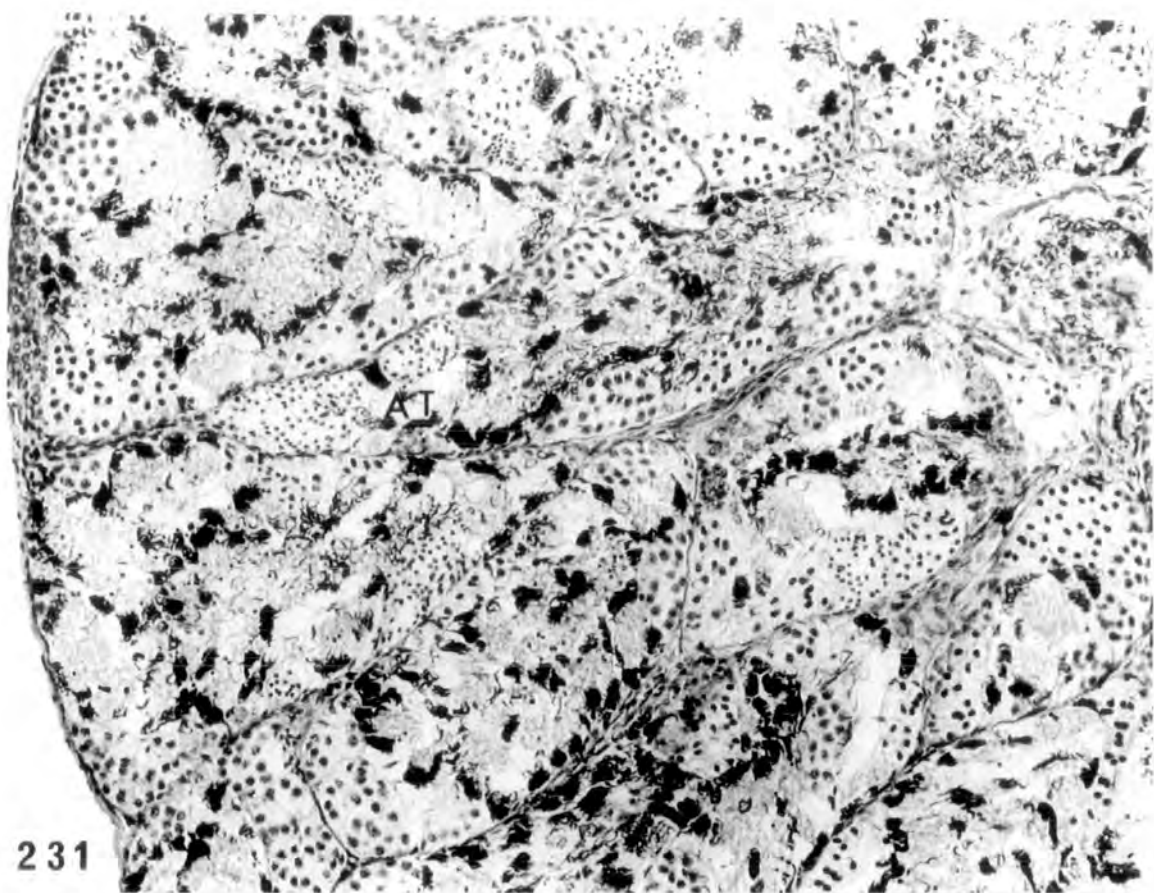


Testis of 12 month old toad in vivo

PLATE LXIX

Fig. 231. Section of testis showing arrangement of seminiferous tubules containing germinal cysts in various stages of development.
x 190.

Fig. 232. Section of the testis showing in detail the cystic appearance of the seminiferous tubules. In any one cyst all the germ cells are at the same stage of development. Cysts containing primary spermatocytes, secondary spermatocytes, spermatids and spermatozoa respectively, are evident.
x 760.



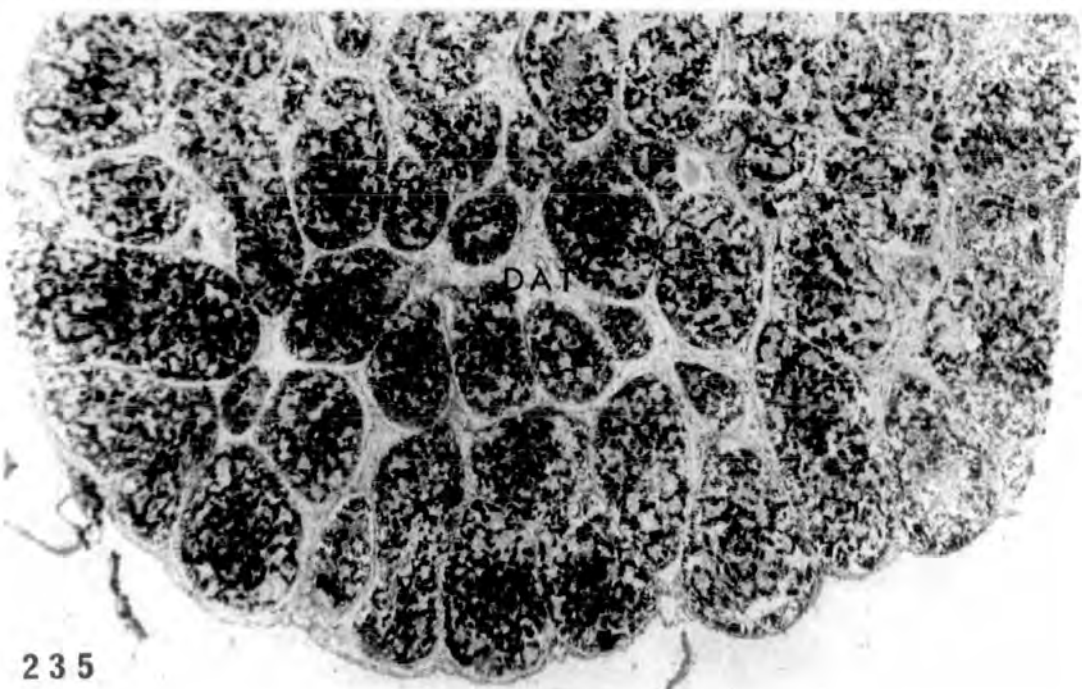
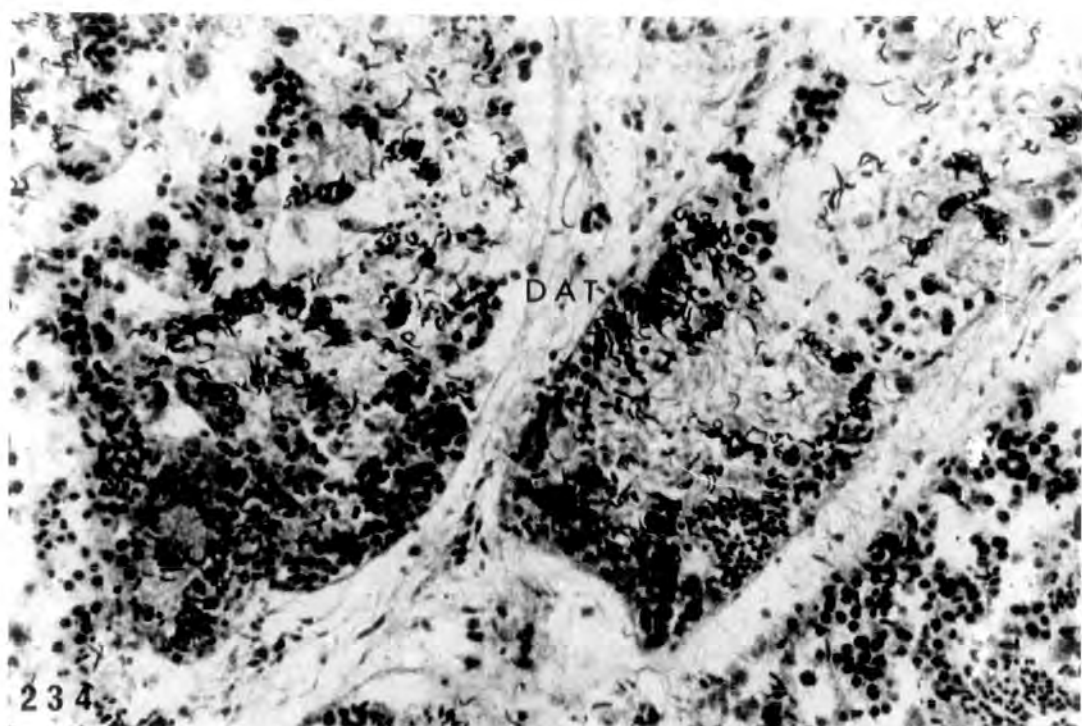
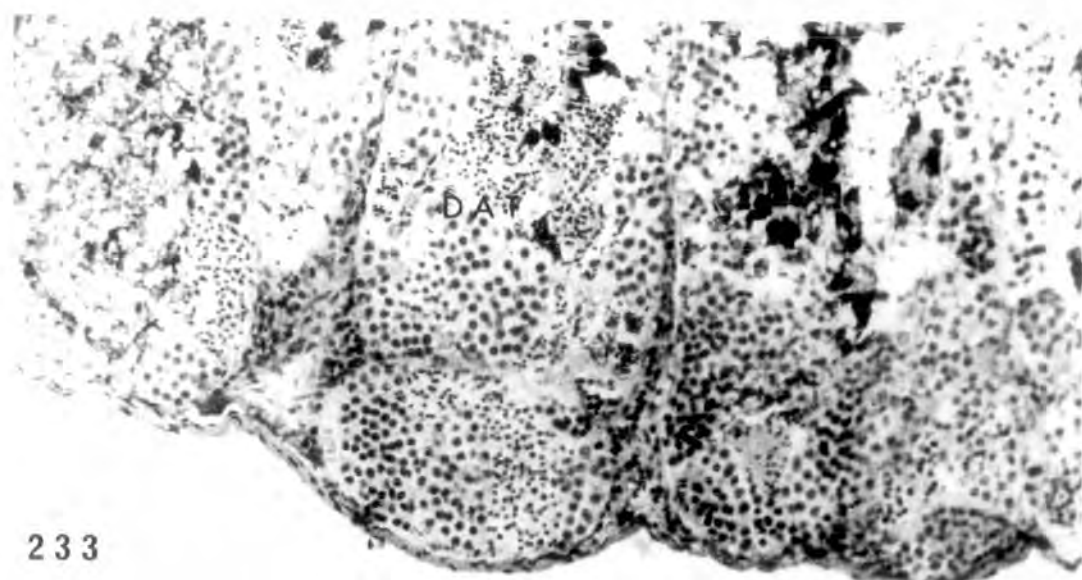
Testis of 12 month old toad in vitro
for 15 days, and treated
with oestradiol.

PLATE LXX

Fig. 233. Testicular degeneration but some cysts in the periphery of the testis appear intact. x 320.

Fig. 234. High degree of degeneration of seminiferous tubules in the middle of the testis. x 640.

Fig. 235. Testis treated with 600µg/l oestradiol. Disintegration and degeneration of the testicular structure. No detectable hormone effect. x 640.



Treatment with antibiotic with and without oestradiol
Alcohol treated and oestradiol treated controls

PLATE LXXI

Fig. 236. Control, alcohol treated in the dark,
testis at st.56 (♂ N). x 475.

Fig. 237. Control, alcohol treated in the dark,
st.56 ovary, showing pachytene oocytes
in the cortex. Ovarian cavity evident
(♀ N). x 475.

Figs. 238-239. Ovaries from two tadpoles treated
with 100µg/l oestradiol in the dark,
resembling control. (♀ N). They
show clear ovarian cavity and pachytene
oocytes in the cortex. x 475.

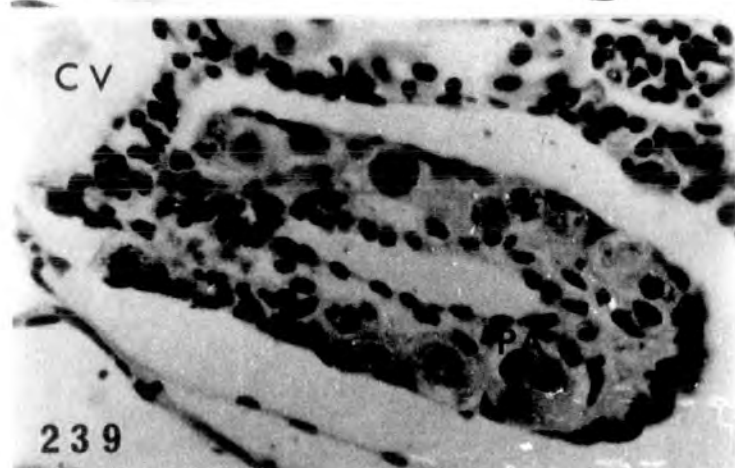
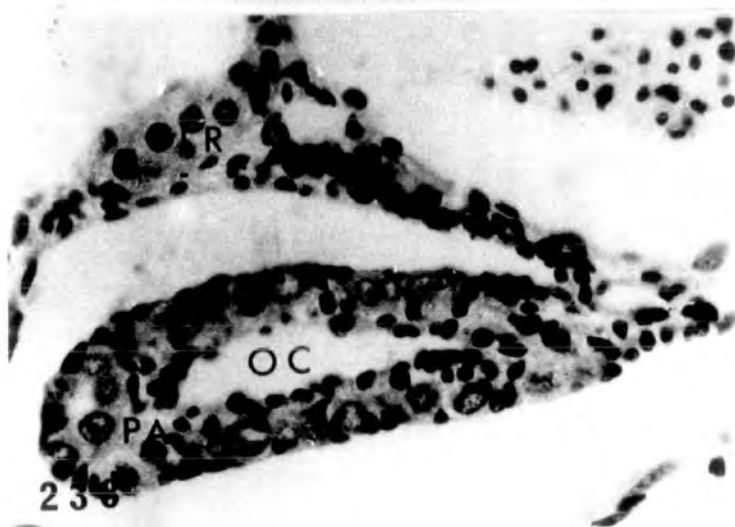
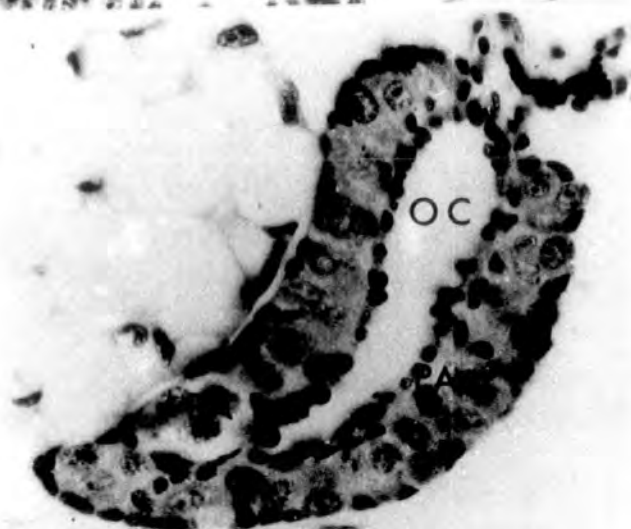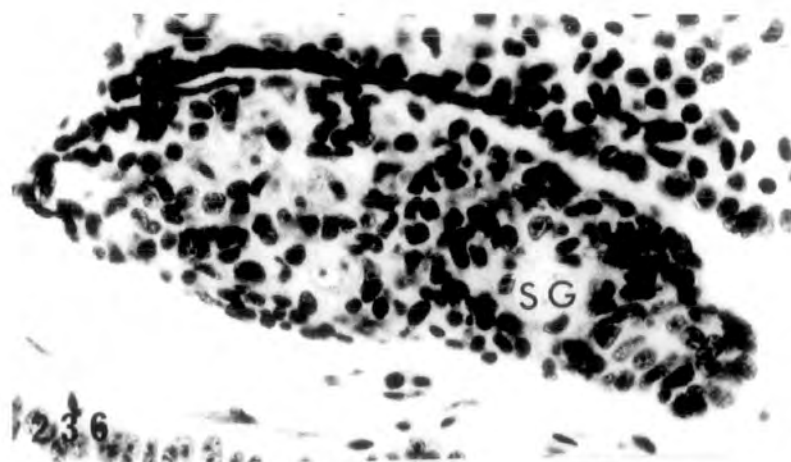
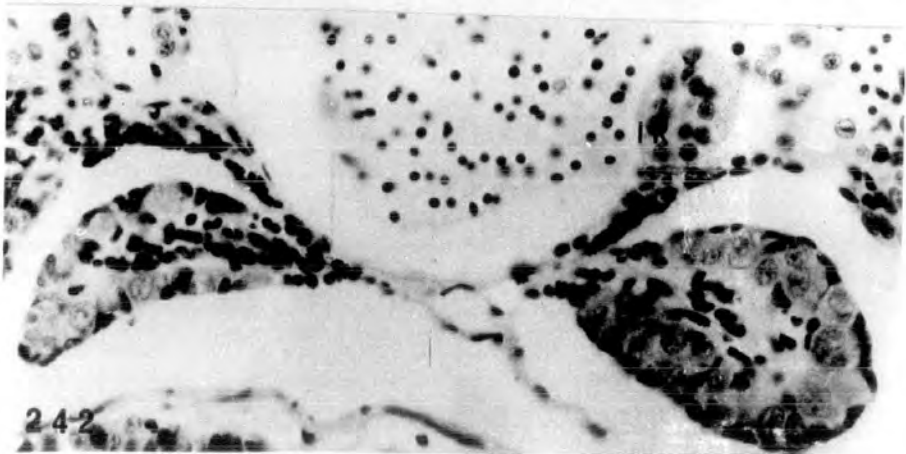
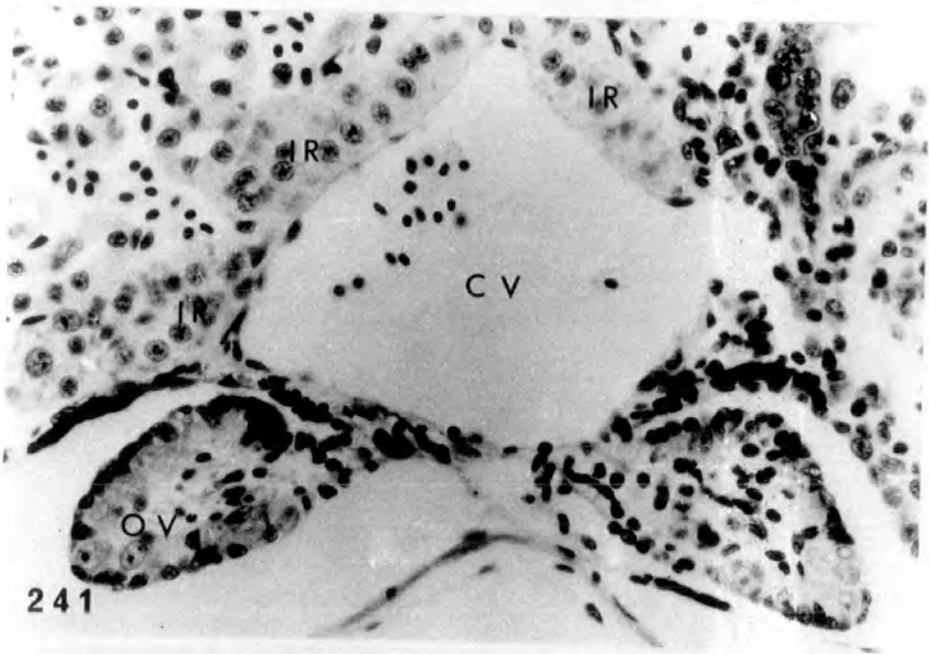
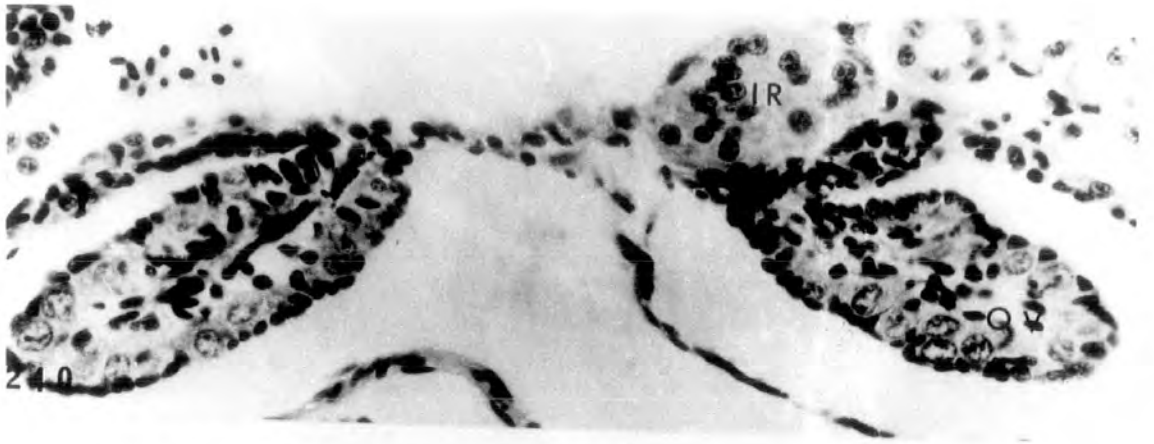


PLATE LXXII

Figs. 240-242. Treatment with 100µg/l oestradiol
in the dark. Inverted testes resembling
inhibited ovaries (♀) from three
larvae which were probably genetic
males inverted to phenotypic females
by the hormone treatment (see page 102 Vol. 1).
There is a distinct cortex lacking
pachytene oocytes and no cavity.
Interrenal hypertrophy evident. x 400.



Treatment with antibiotic

PLATE LXXIII

Fig. 243. Treatment with 2.5mg/l actinomycin D.

Testis resembling control (♂ N).

x 400.

Fig. 244. Treatment with 2.5mg/l actinomycin D.

Ovary resembling control (♀ N).

x 400.

Fig. 245. Treatment with 5.0mg/l puromycin.

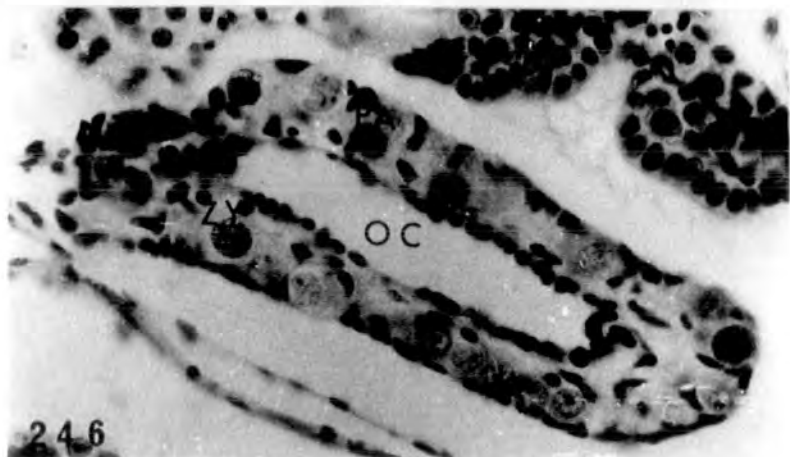
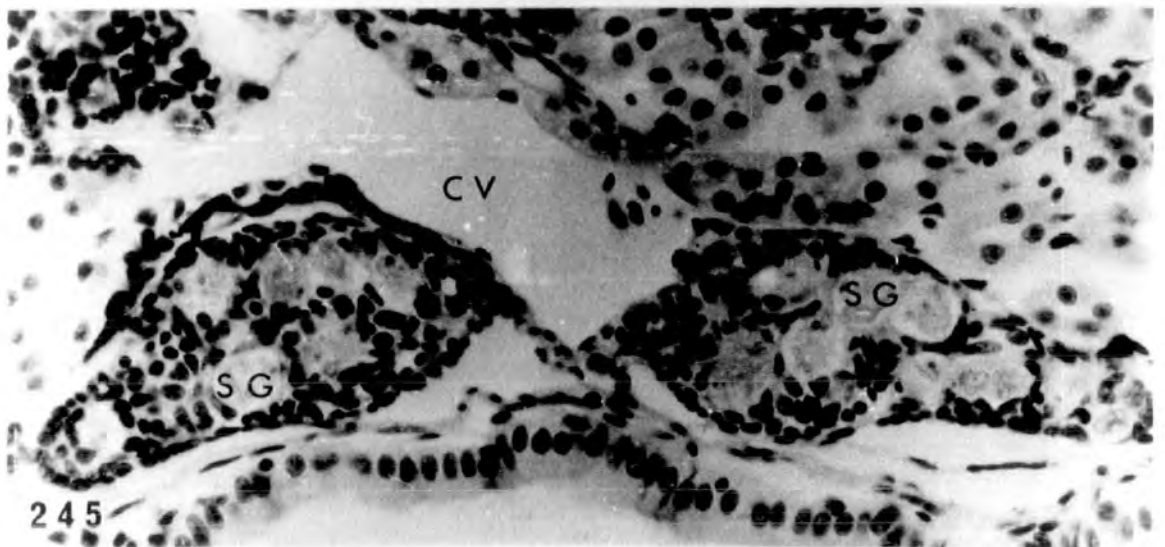
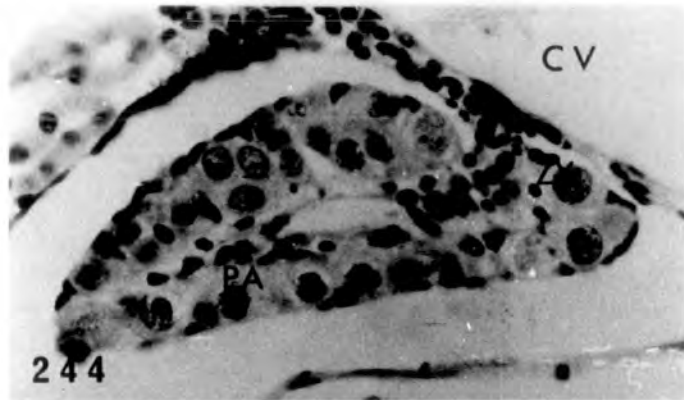
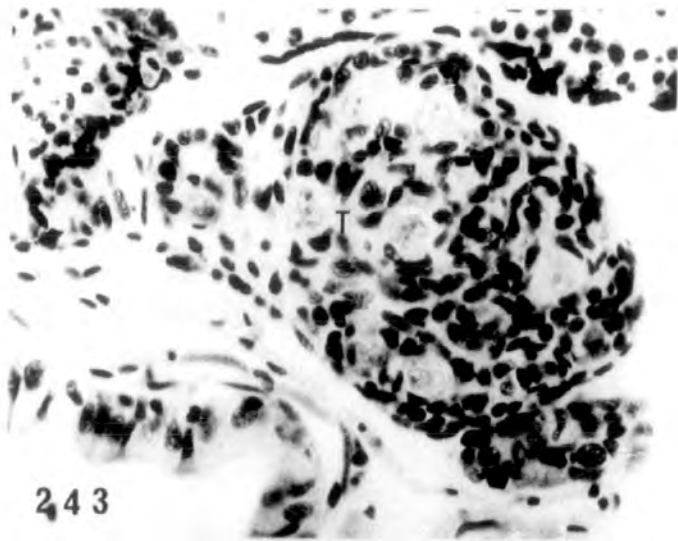
Testes resembling control (♂ N).

x 400.

Fig. 246. Treatment with 5.0mg/l puromycin.

Ovary resembling control (♀ N).

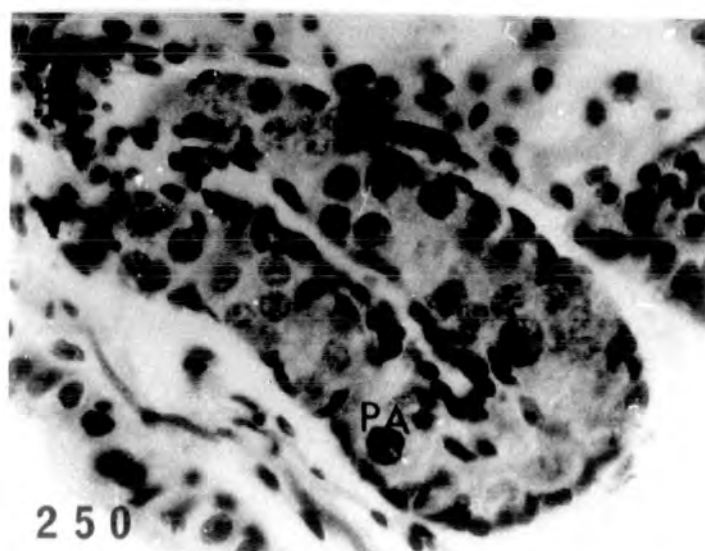
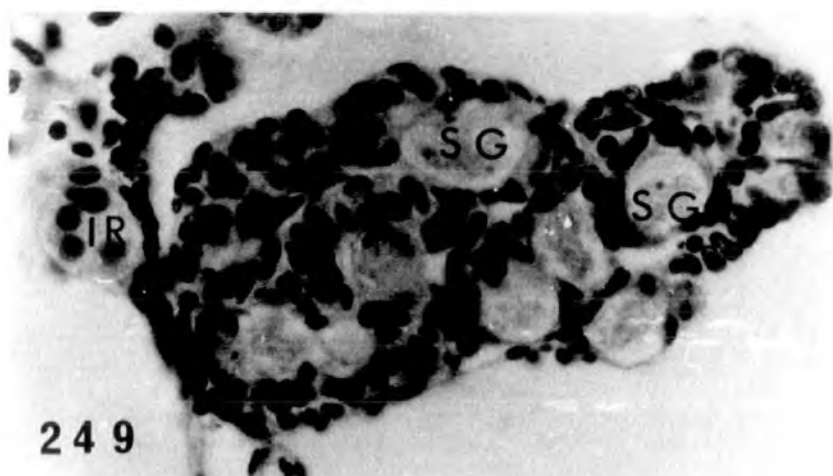
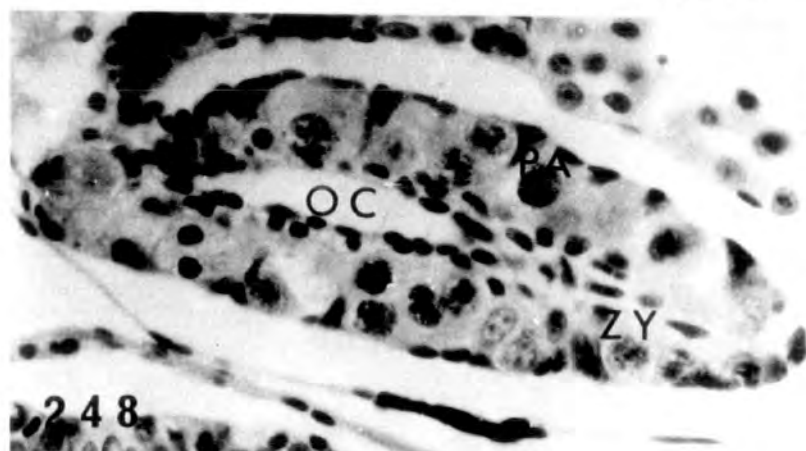
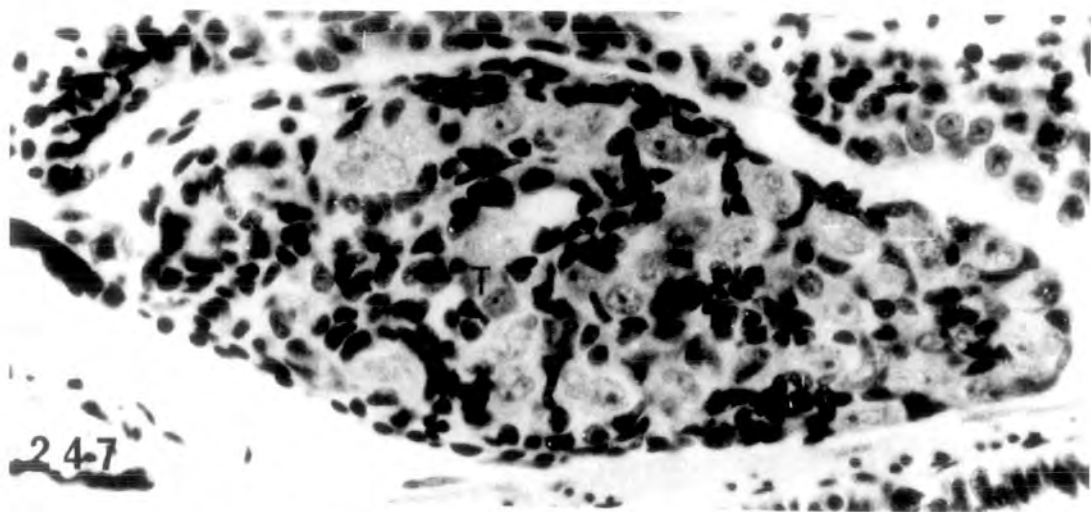
x 400.



Simultaneous administration of oestradiol and
antibiotic

PLATE LXXIV

- Fig. 247. Treatment with 100µg/l oestradiol and 2.5mg/l actinomycin D. Testis resembling control (♂ N). x 525.
- Fig. 248. Treatment with 100µg/l oestradiol and 2.5mg/l actinomycin D. Ovary resembling control, showing obvious cavity and pachytene oocytes in the cortex (♀ N). x 525.
- Fig. 249. Treatment with 100µg/l oestradiol and 5.0mg/l puromycin. Testis resembling control (♂ N). x 525.
- Fig. 250. Treatment with 100µg/l oestradiol and 5.0mg/l puromycin. Ovary resembling control (♀ N). x 525.



Demonstration of Δ^5 -3 β -HSDH activity

PLATE LXXV

Figs. 251-253. Formazan deposits in the interrenal
tissue of control untreated st.49,
st.51 and st.55 tadpoles respectively.
x 250.

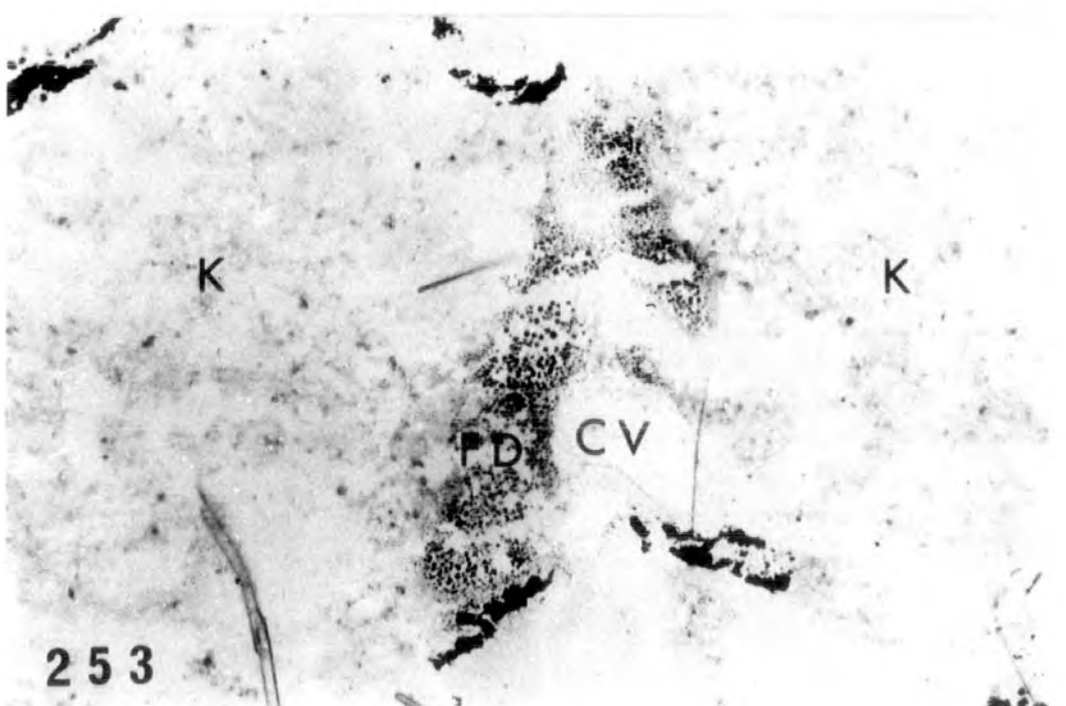
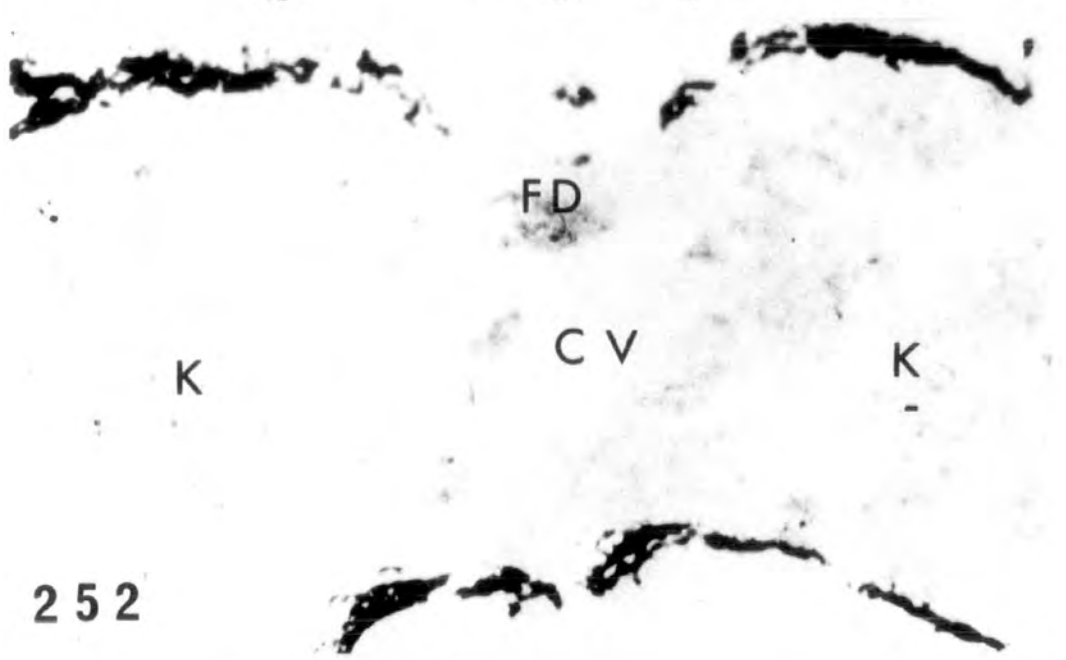

PLATE LXXVI

Figs. 254-255. Formazan deposits in the interrenal,
around some of the proximal mesonephric
tubules and in the testis of st.56
tadpole. At higher magnification
patches of formazan deposits are clearly
seen in the testicular soma.

254 x 160

255 x 640.

Fig. 256. Formazan deposits in the interrenal,
some of the proximal mesonephric tubules,
in the fat body and in the ovary (arrowheads)
of st.56 tadpole. x 400.

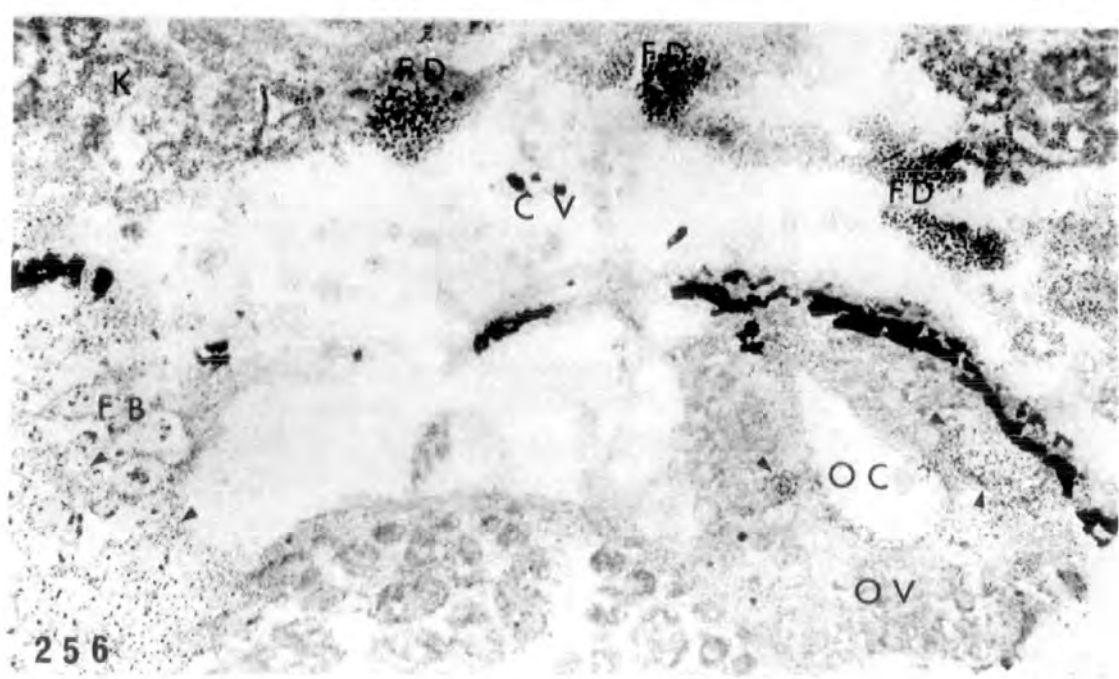
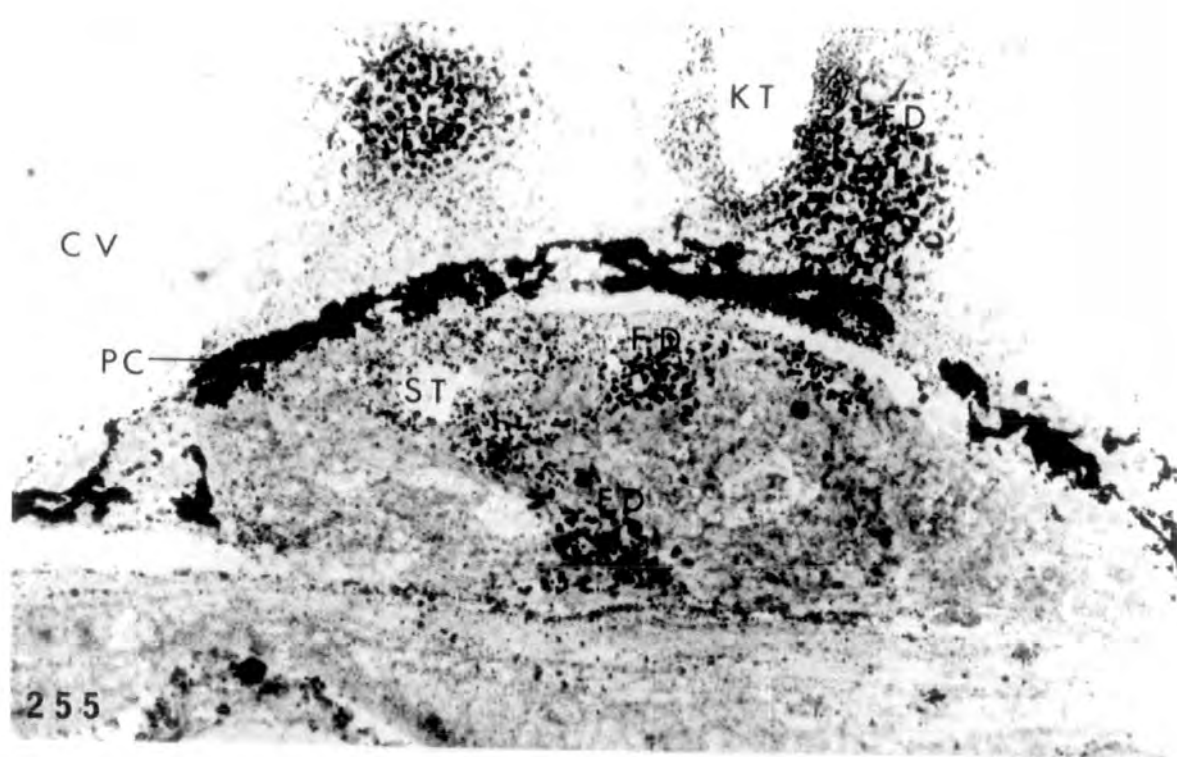
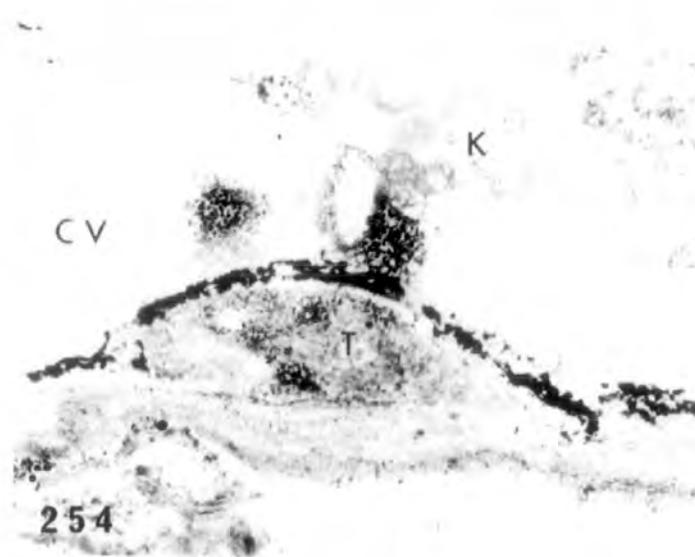


PLATE LXXVI

Figs. 257-258. Higher magnification of the st. 56 ovary seen in 256 showing patches of formazan deposits in the cortical region. The deposits seem to surround the oocytes. Some deposits are seen in the fat body of the same larva as shown in the lower photograph.

257 x 720

258 x 450

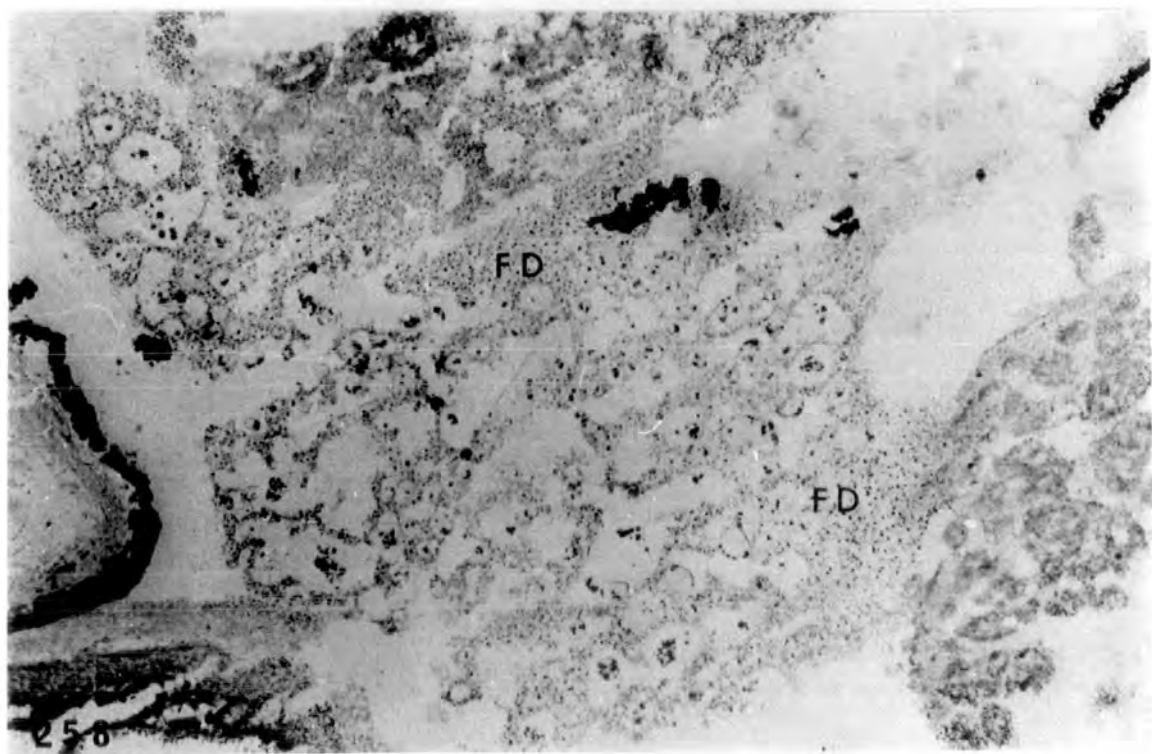
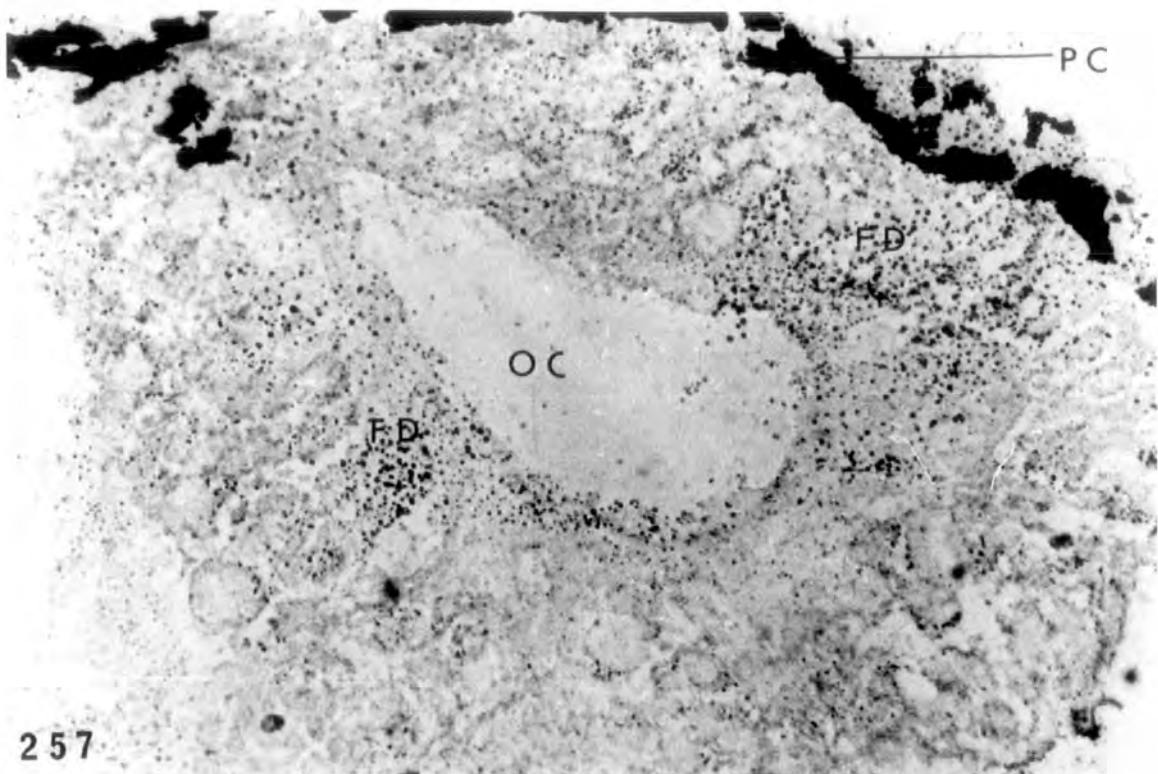


PLATE LXXVII

Fig. 259. Formazan deposits in interrenal
and ovaries (arrowheads) of another
st. 56 larva. x 400.

Fig. 260. Formazan deposits in the testis of
a st.57 larva. x 640.

Fig. 261. Formazan deposits in the interrenals,
in some of the mesonephric tubule wall
and in the ovaries, of a st.57 larva.
x 400.

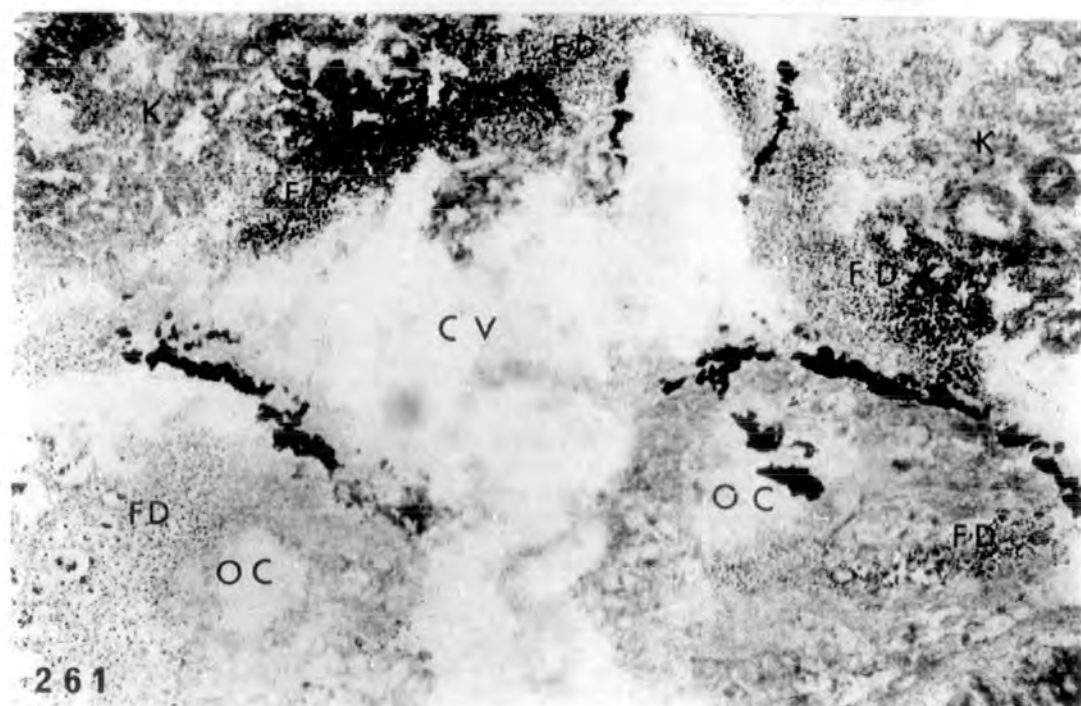
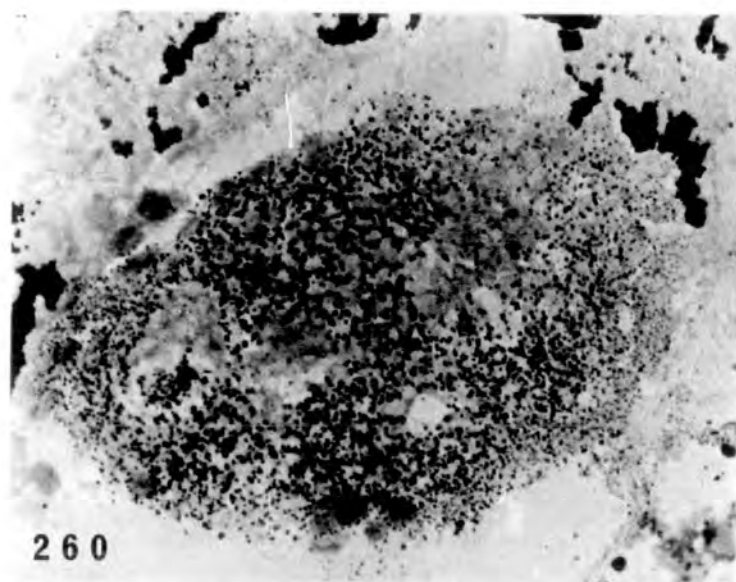
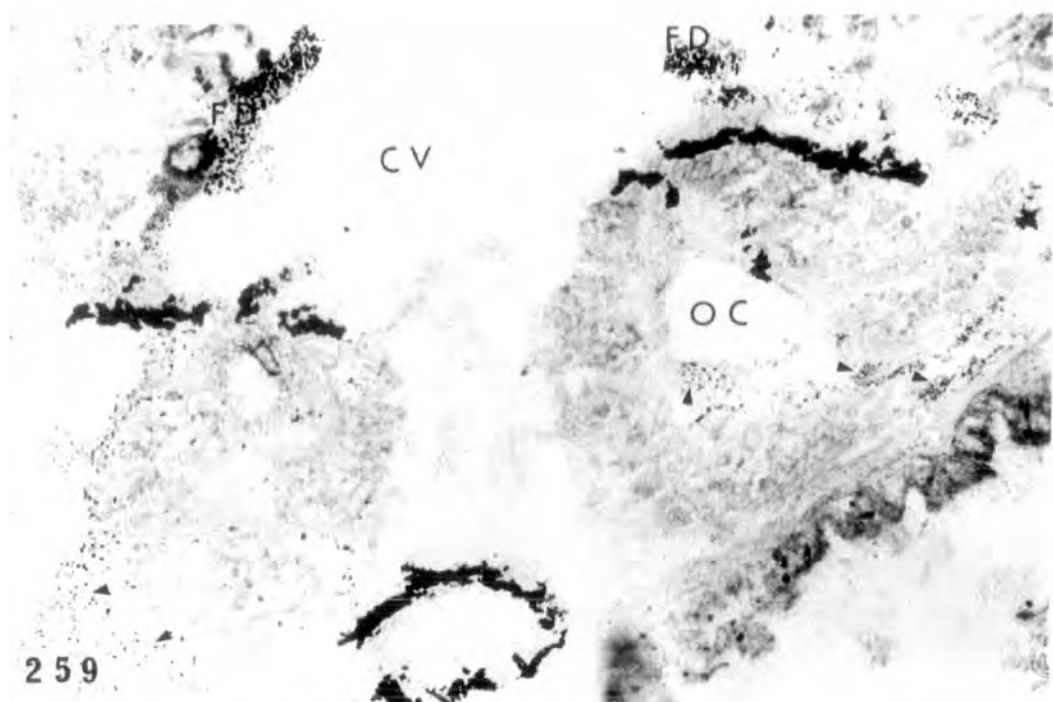


PLATE LXXVIII

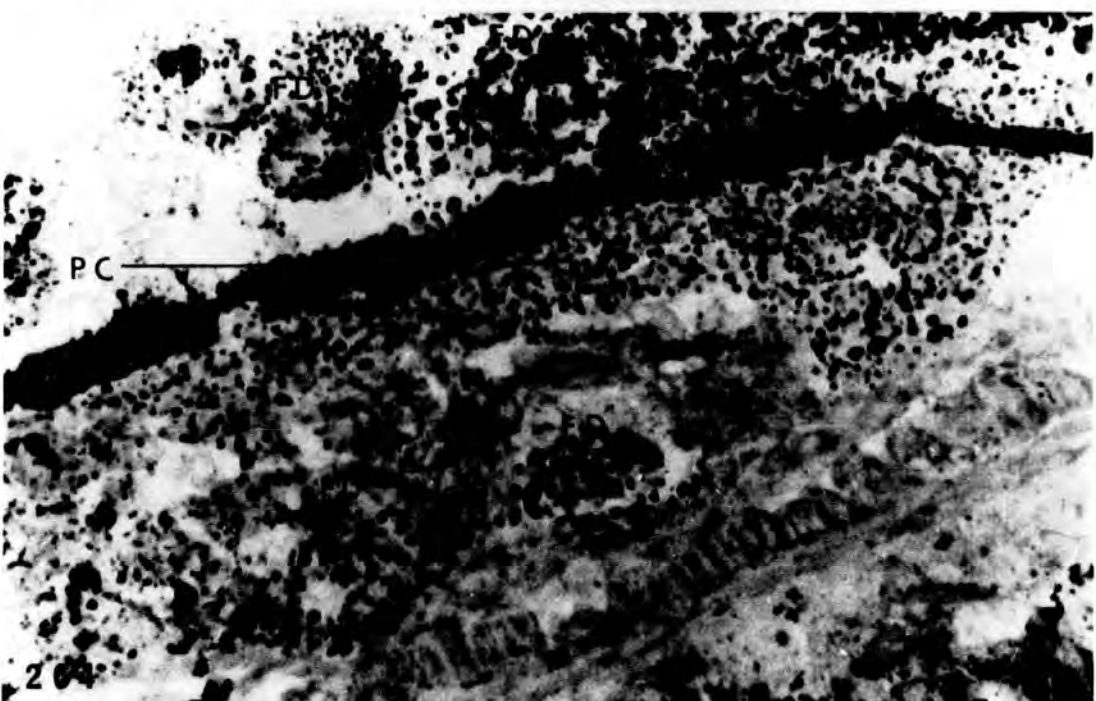
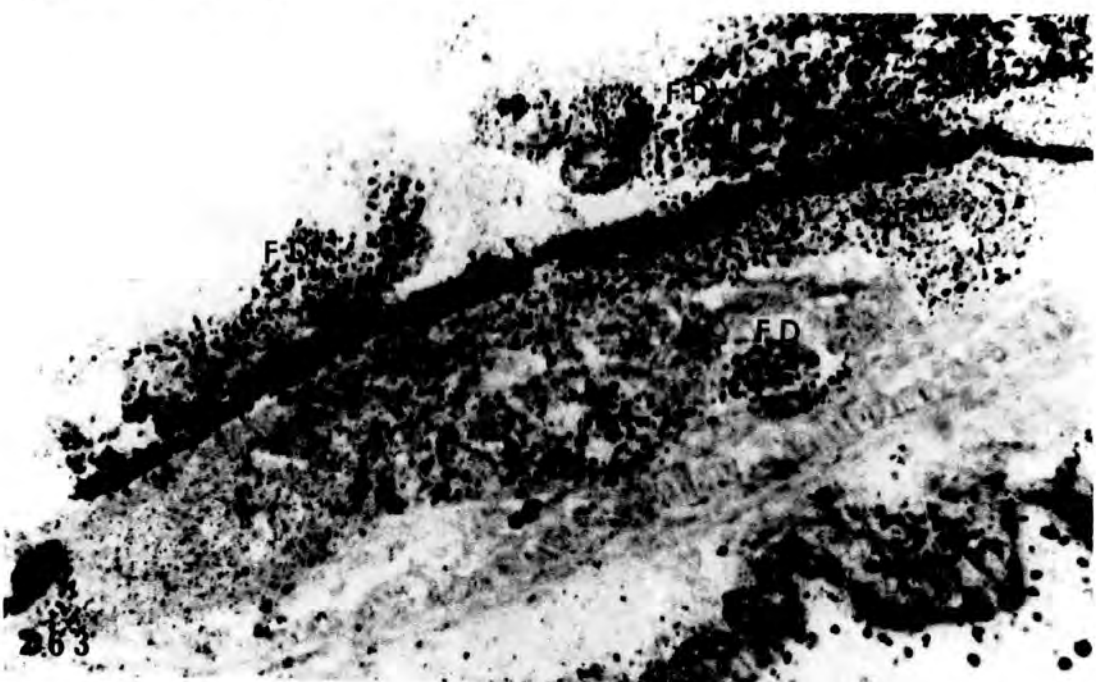
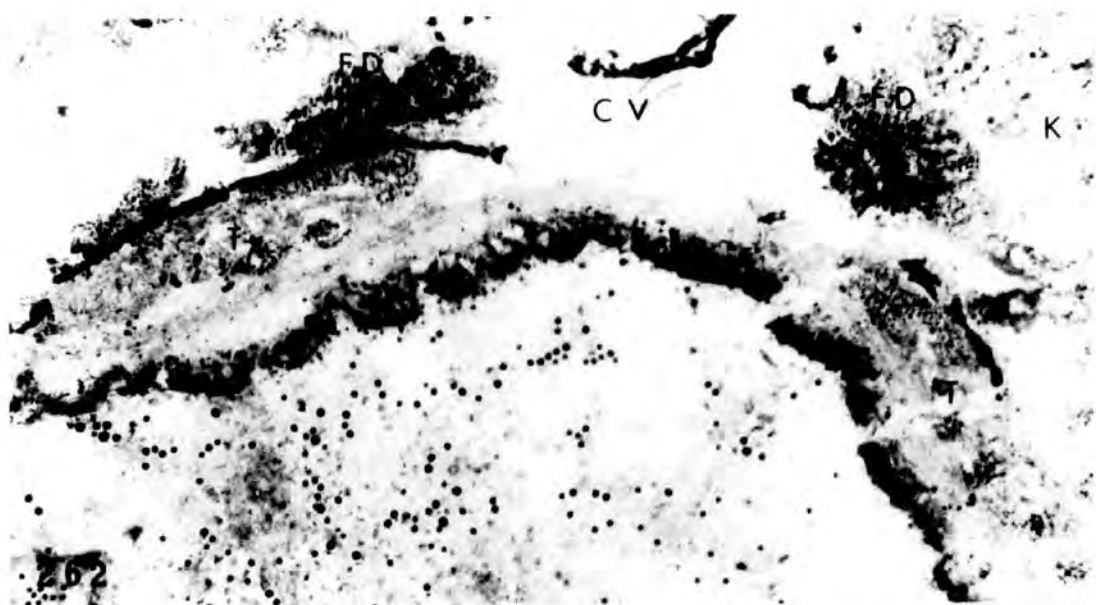
Figs. 262-264. Formazan deposits in the
interrenals and testes of a st.

58 tadpole.

262 x 160

263 x 400

264 x 640



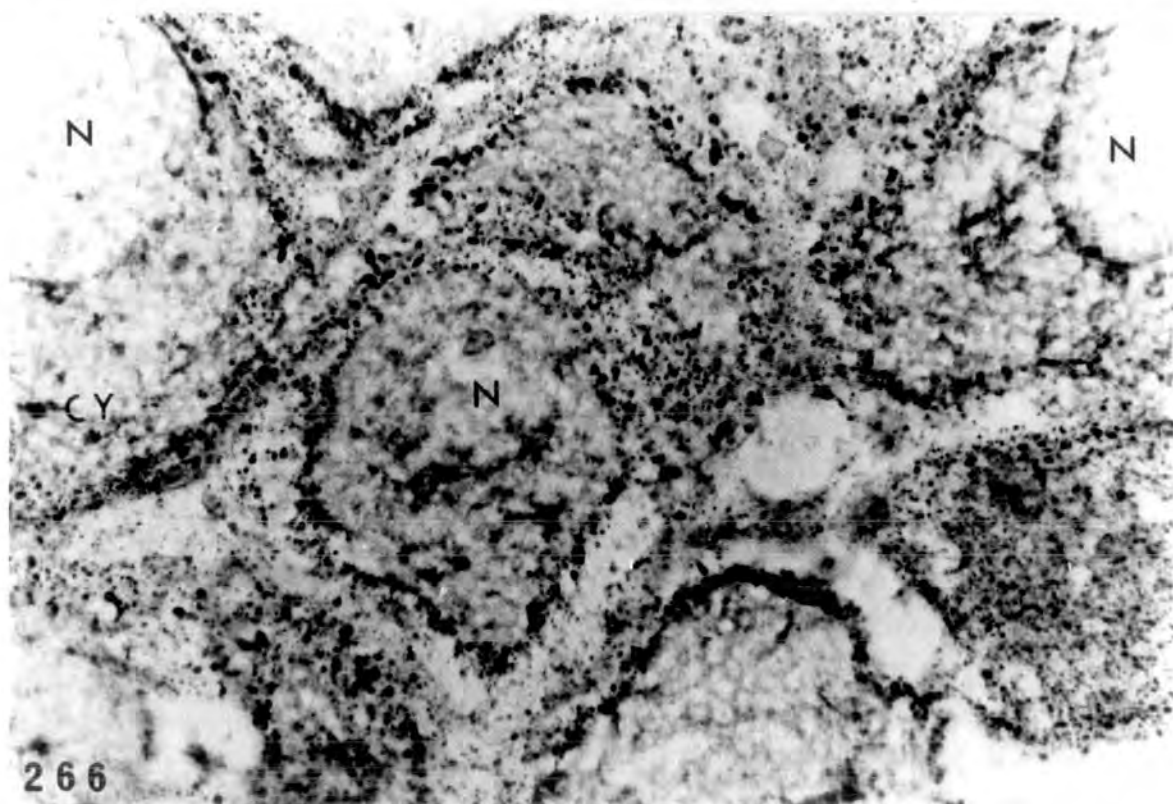
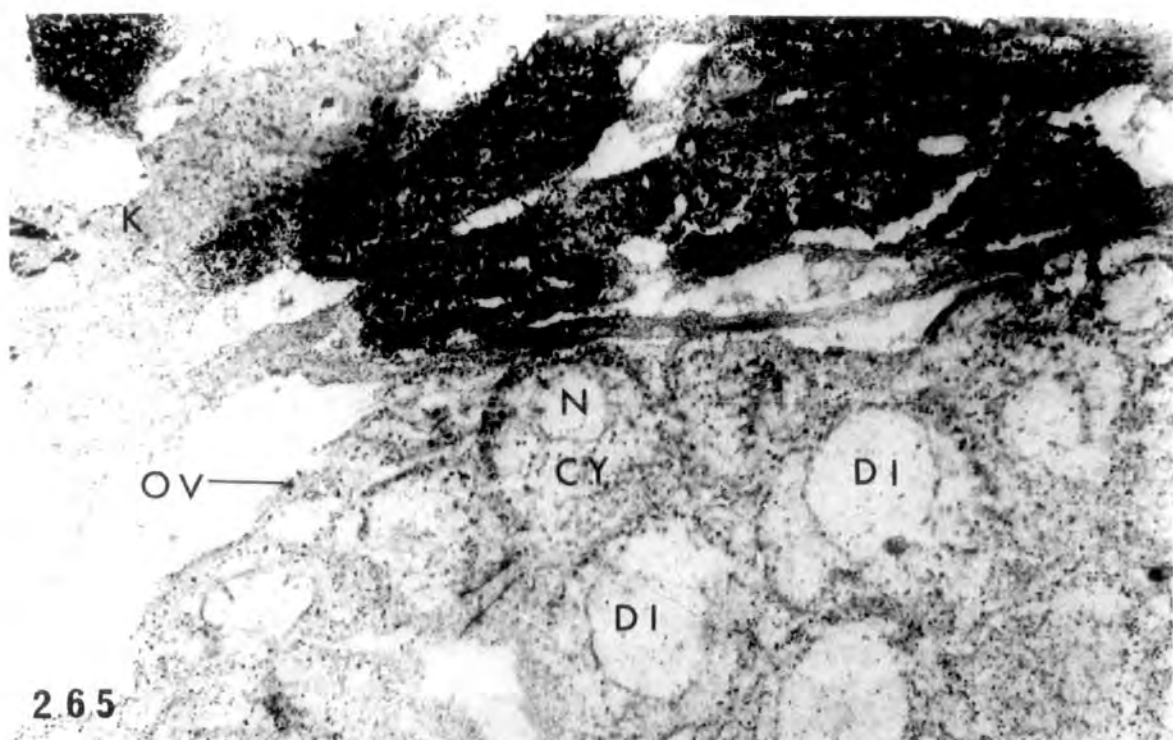
Demonstration of Δ^5 -3 β -HSDH activity in a late
stage tadpole of *Rana catesbeiana*.

PLATE LXXIX

Figs. 265-266. Intense formazan deposits are present in the interrenals. In the ovary weaker deposits are found concentrated in the nuclear and cytoplasmic membranes of the diplotenic oocytes and occur also to a limited degree in the cytoplasm of these oocytes and in the somatic tissue of the ovary.

265 x 190

266 x 475




Effect on Δ^5 - 3β -HSDH activity of 26 day treatment
with 2mg/l oestradiol

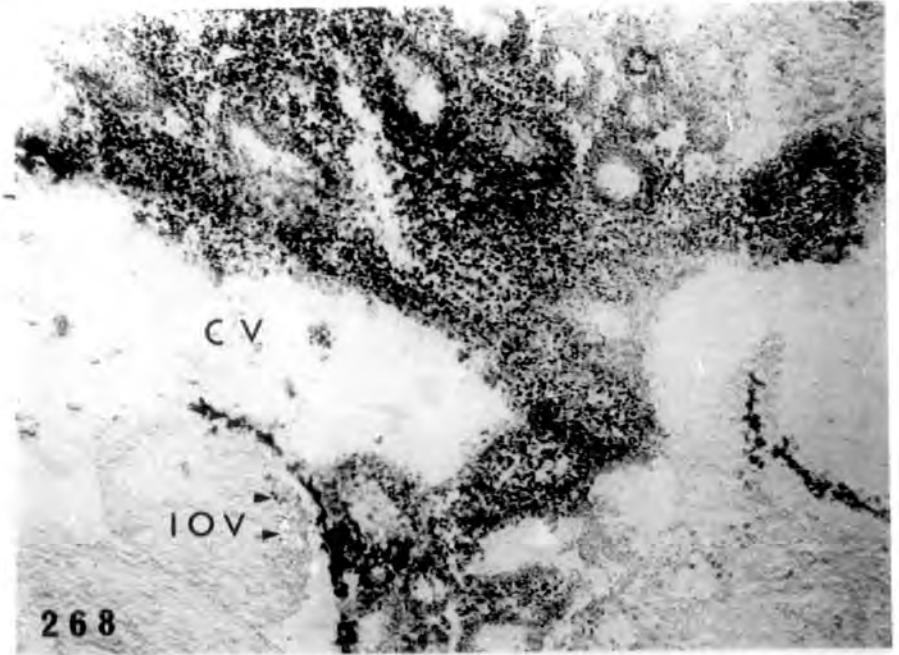
PLATE LXXX

Fig. 267. Formazan deposits present throughout the hypertrophied interrenal but none in the testis. x 160.


Figs. 268-269. Other sections from the same tadpole showing extensive formazan deposits in the hypertrophied interrenal. Minute amount of formazan deposits is present in the cortex of the inhibited ovary (arrowheads). x 400.



267



268



269

Demonstration of Δ^5 - 3β -HSDH activity in the
gonads and interrenals of 2 year old toads.

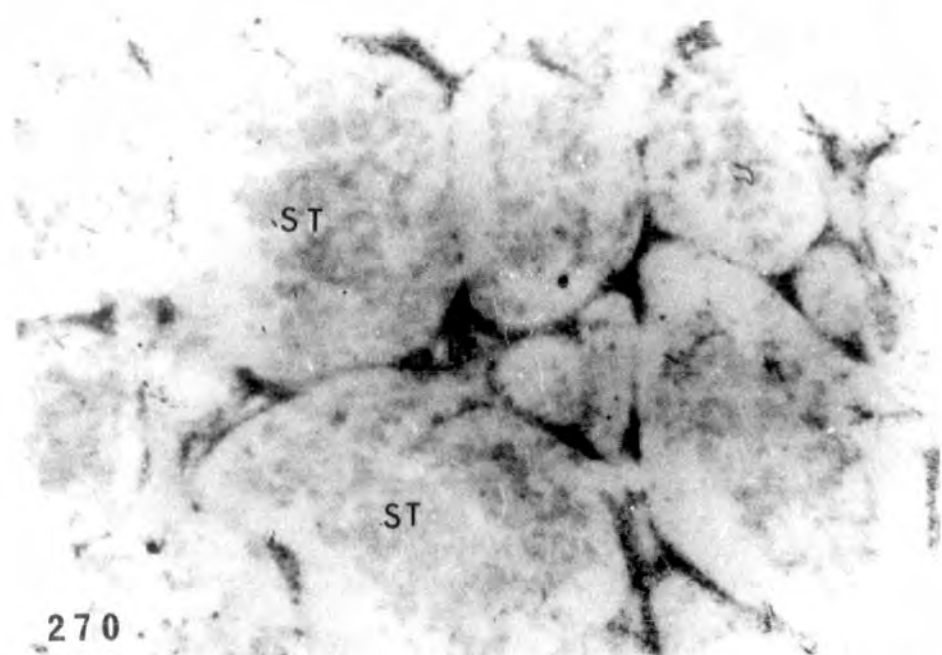
PLATE LXXXI

Figs. 270-271. Formazan deposits in the interstitial tissue of an adult male. At the higher magnification the deposits in the interstitial tissue indicated by arrowheads.

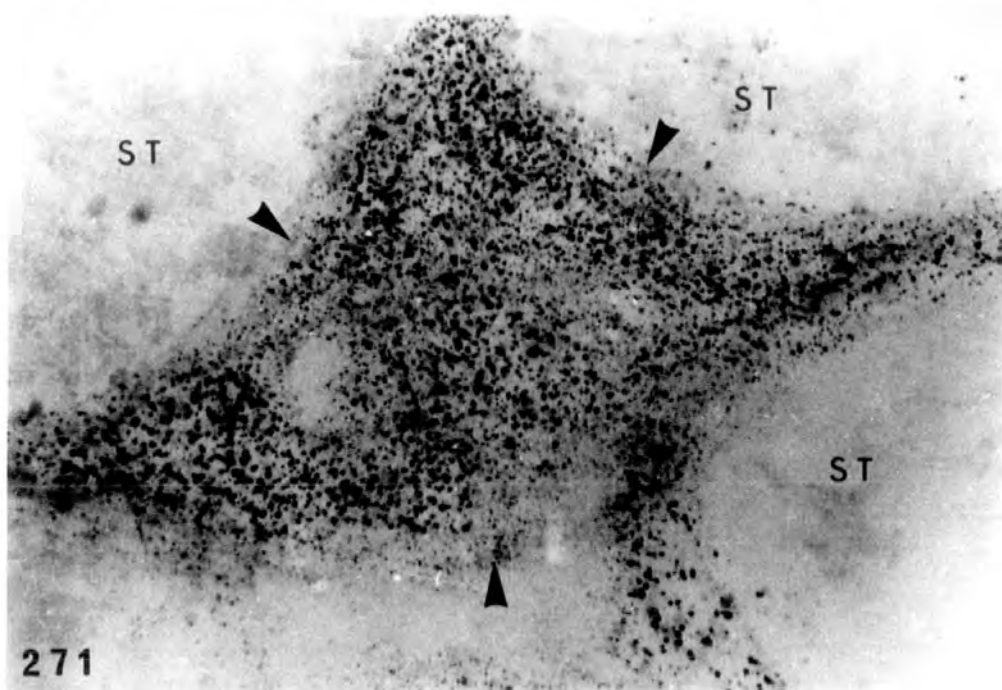
270 x 64

271 x 400

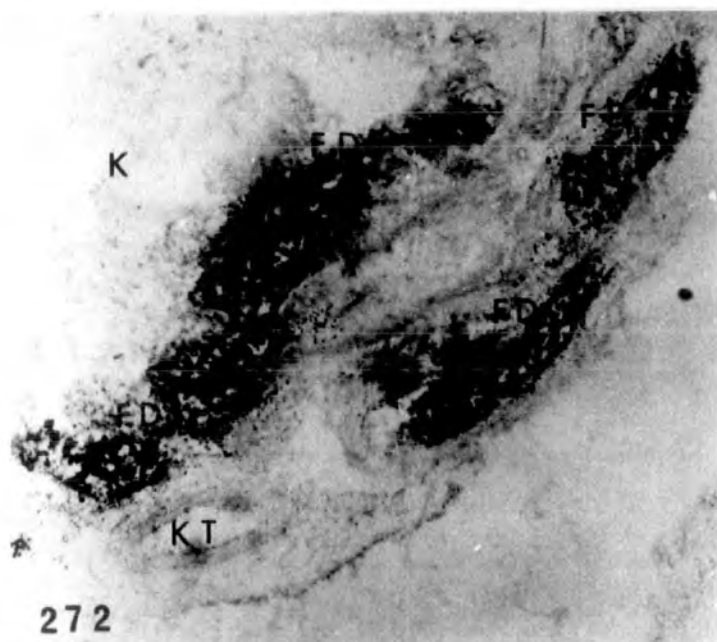
Fig. 272. Intense formazan deposits in the interrenals of the same adult male.
x 160.



270



271

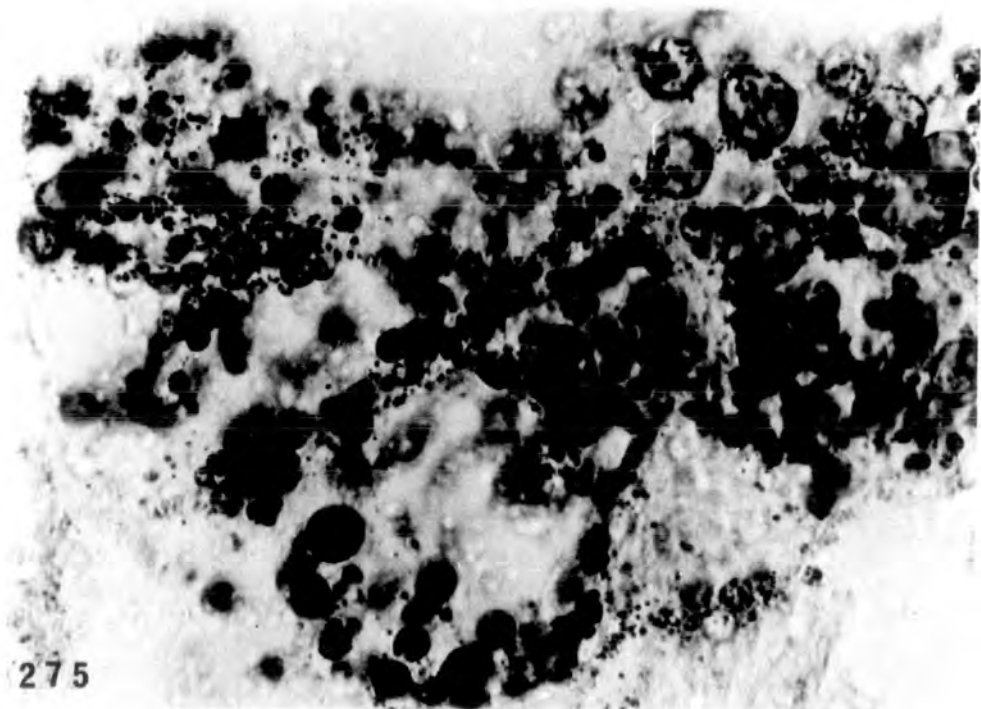
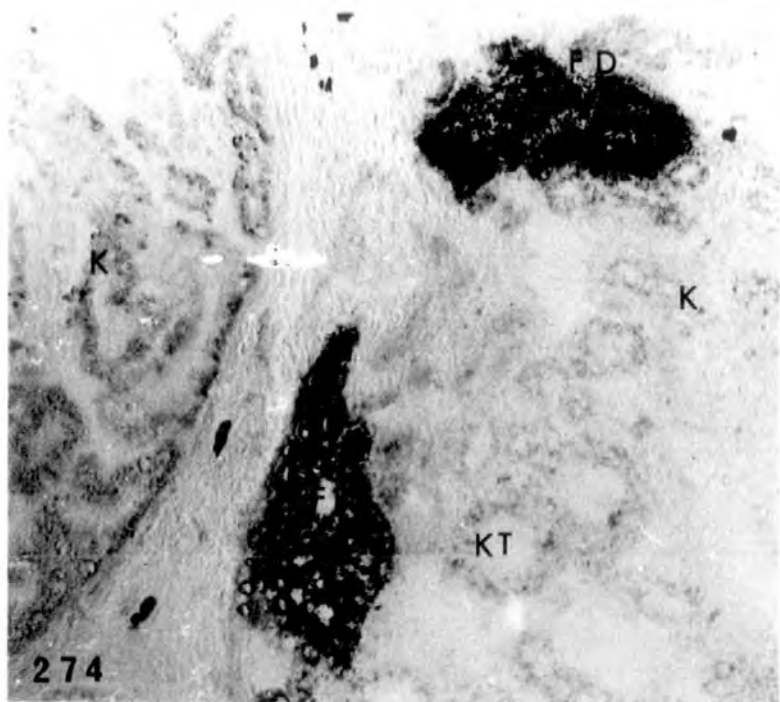
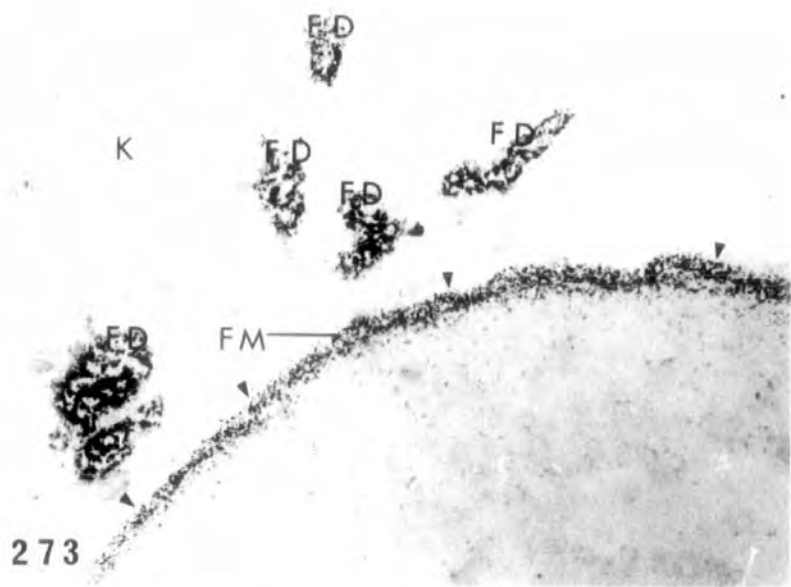


272

PLATE LXXXII

Fig. 273. Formazan deposits in the interrenals
and the ^{ovarian} membrane (arrowheads)
of an adult female.
x 160.

Figs. 274-275. Intense formazan deposits in the
interrenals of another adult female.
274 x 400
275 x 640



Demonstration of G-6-PO₄ DH activity

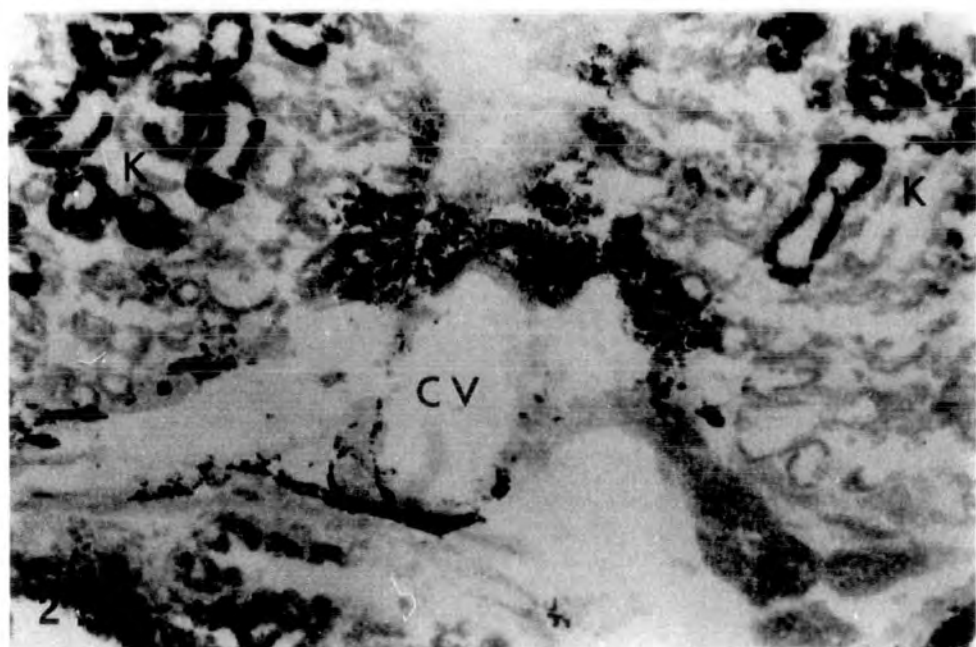
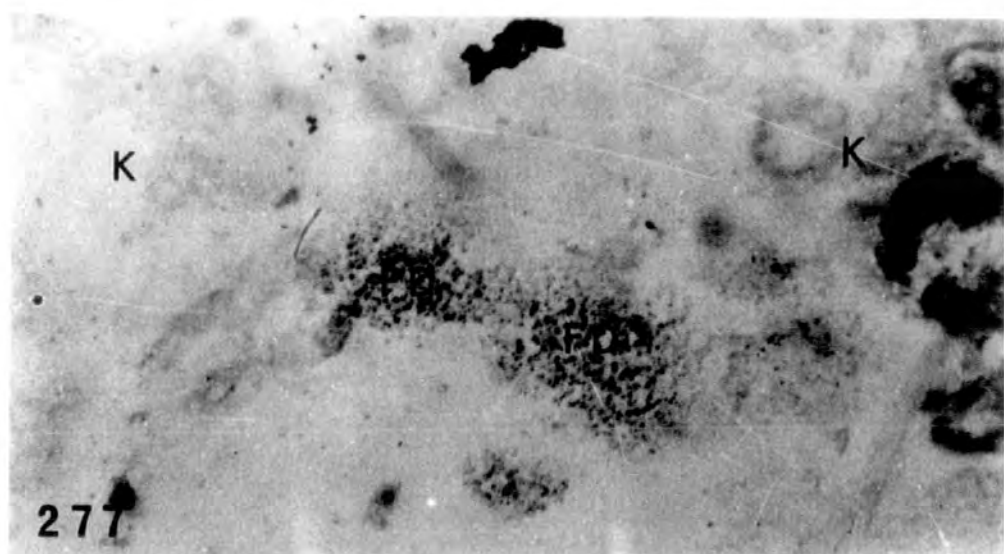
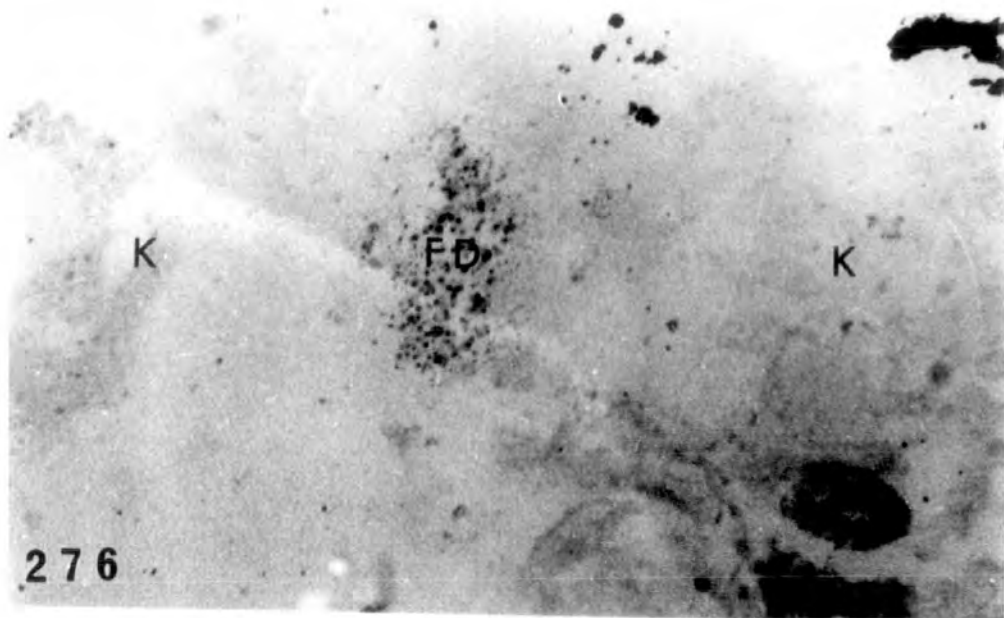
PLATE LXXXIII

Figs. 276-278. Formazan deposits in the interrenals of st.49, st.52 and st.56 larvae respectively. Intensity of interrenal deposits is increased in the last of these stages.

276 x 210

277 x 210

278 x 84




Effect of 26 day treatment (st.51-57) with 2mg/1
oestradiol on G-6-PO₄ DH activity.

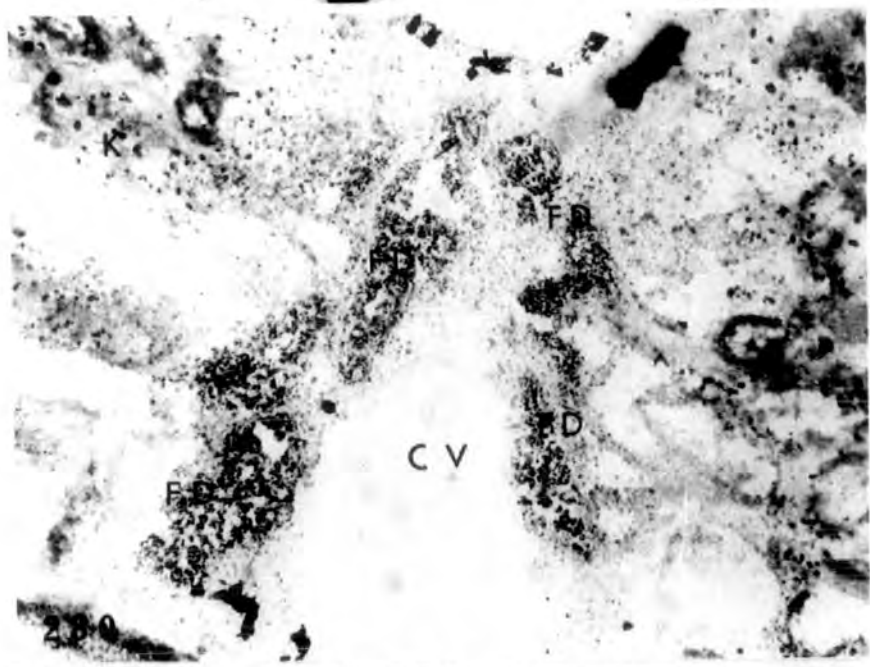
PLATE LXXXIV

Fig. 279. Intense formazan deposits in the interrenal of the alcohol treated control. Formazan deposits are also found in the testis (arrowheads). x 160.

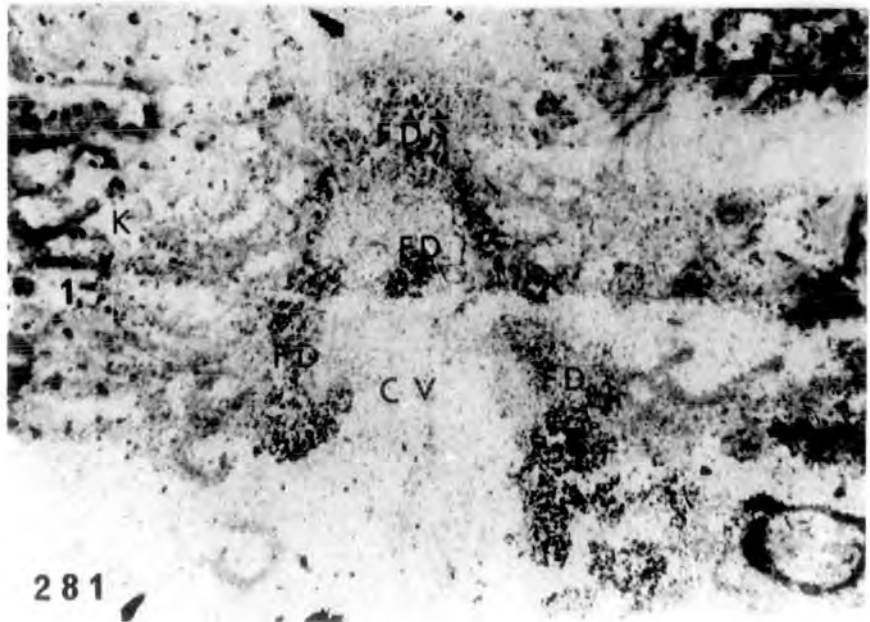
Figs. 280-281. Hormone treated individuals showing less intense deposits in the interrenals than in control. x 160.



279



280




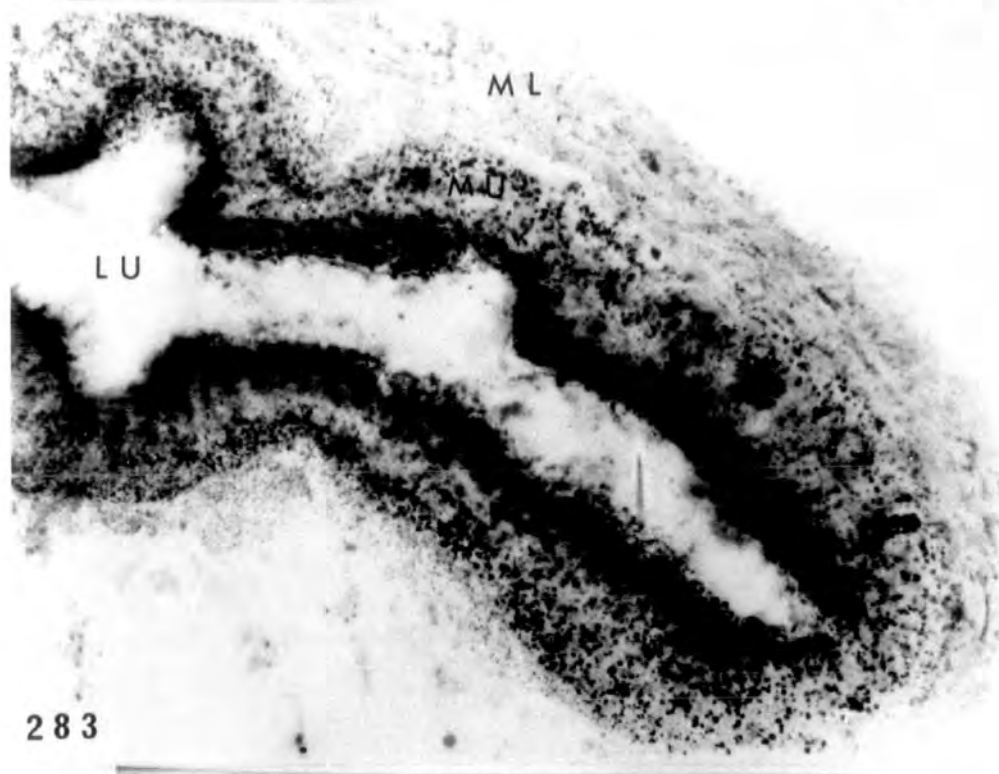
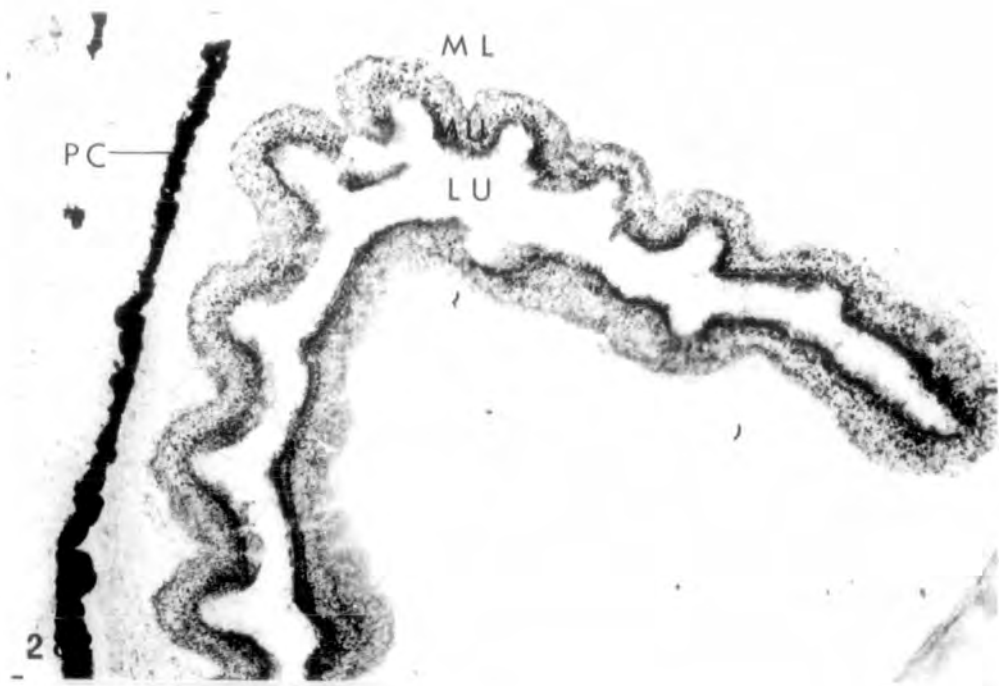
281

Demonstration of enzyme activity in the duodenum
of tadpole

PLATE LXXXV

Figs. 282-283. Formazan deposits of Δ^5 -3 β -HDSH
in the mucosa of the duodenum of a st.
56 tadpole.
282 x 160
283 x 400

Fig. 284. Formazan deposits of G-6-PO₄DH activity
in the mucosa of the duodenum of a st.56
tadpole. x 640



Demonstration of enzyme activity in 2 year
old adult toad.

PLATE LXXXVI

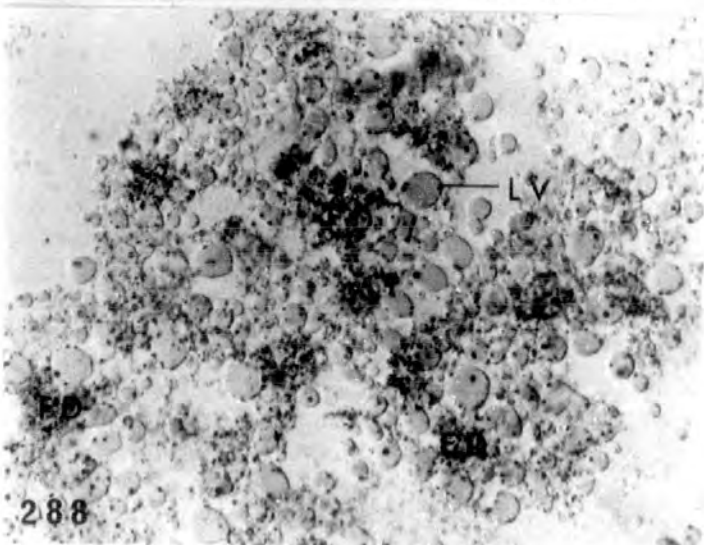
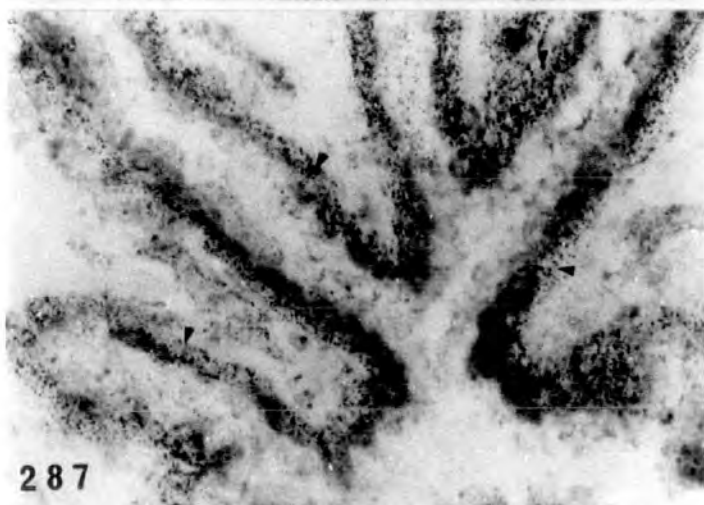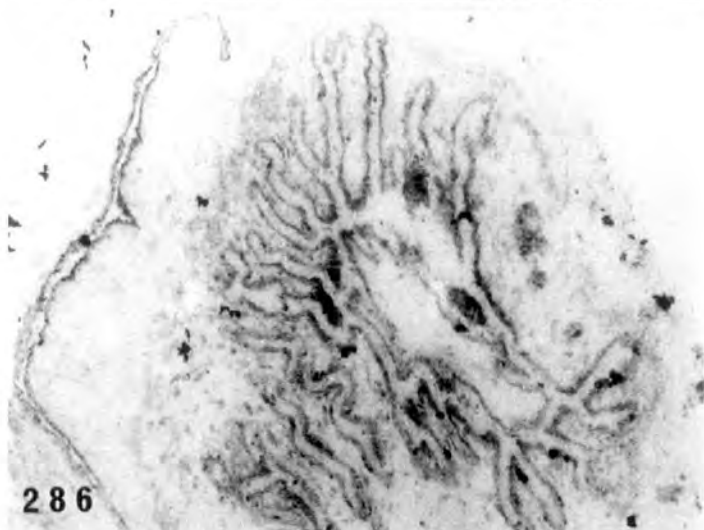
Fig. 285. Formazan deposits of Δ^5 -3 β -HSDH activity
in the wall of the Mullerian duct
(arrowheads). x 160.

Figs. 286-287. Formazan deposits of G-6-PO₄DH
activity in the wall of the Mullerian
duct. The location of these deposits is
more obvious at the higher magnification
(arrowheads).

286 x 64

287 x 400

Fig. 288. Formazan deposits of Δ^5 -3 β -HSDH activity
in the liver of the adult female. The
formazan deposits are found around the
lipid vacuoles. x 400.



Demonstration of lipid material with Sudan Black B.

PLATE LXXXVII

Figs. 289-291. Sudanophilic droplets in the interrenals (arrowheads) of st.54, st.55 and st.56 larvae are shown respectively. At the latter stage the droplets are more closely packed together.

289 x 400

290 x 400

291 x 160

Figs. 292-293. Treatment for 26 days (st.51-57) with 2 mg/l oestradiol. The first photograph shows sudanophilic droplets in the interrenals of the st.57 alcohol treated control. The second one shows interrenal sudanophilic droplets in the hormone treated larva. The droplets are indicated by the arrows.
x 160.

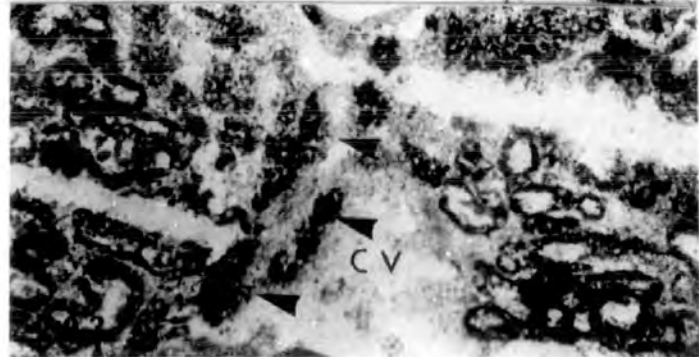
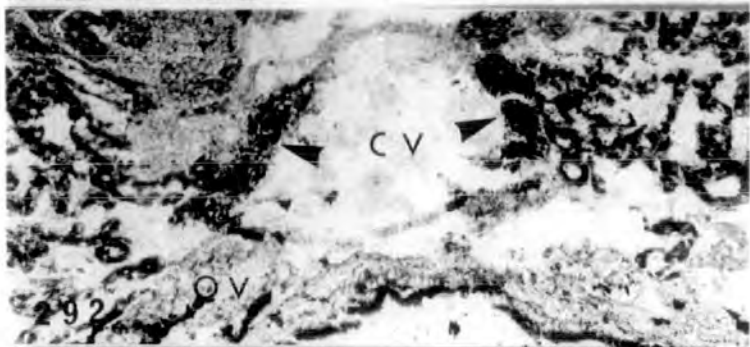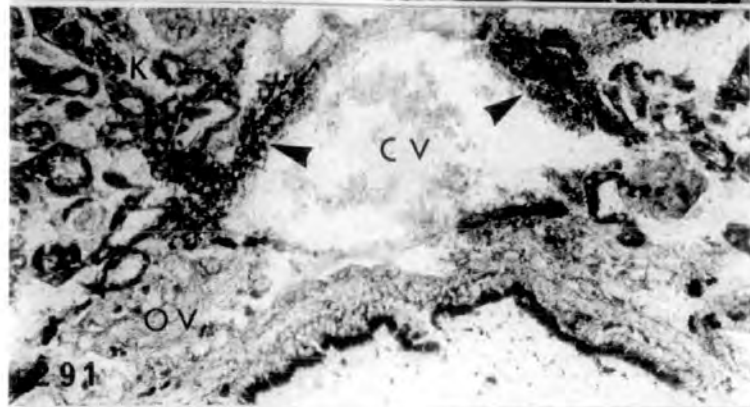
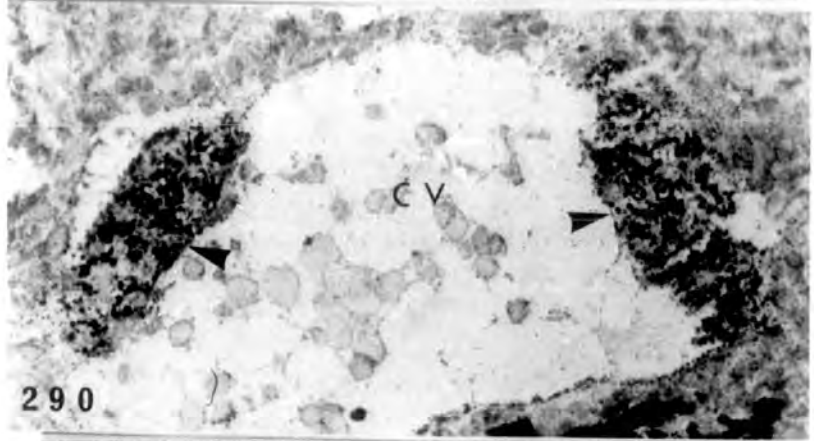
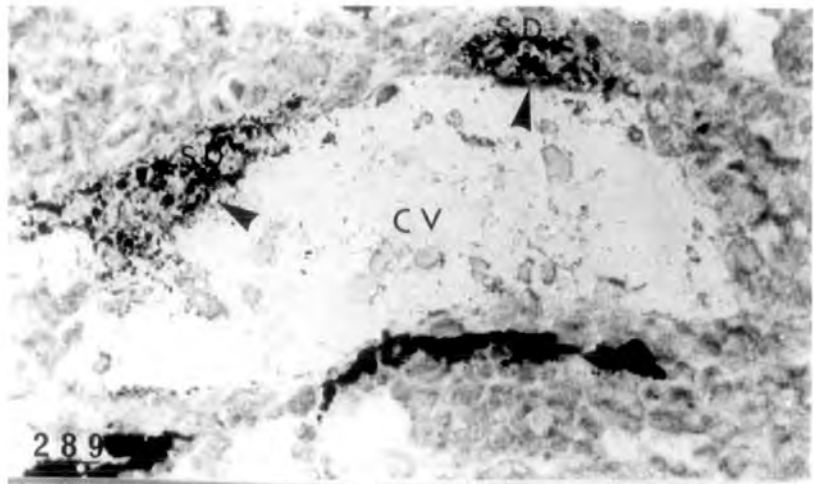


PLATE LXXXVIII

Figs. 294-295. Sudanophilic granules in the
interstitial tissue of a 2 year adult
male.

294 x 84

295 x 210.

Fig. 296a. Large sudanophilic droplets in the
interrenals of a 2 year old adult
female. x 210.

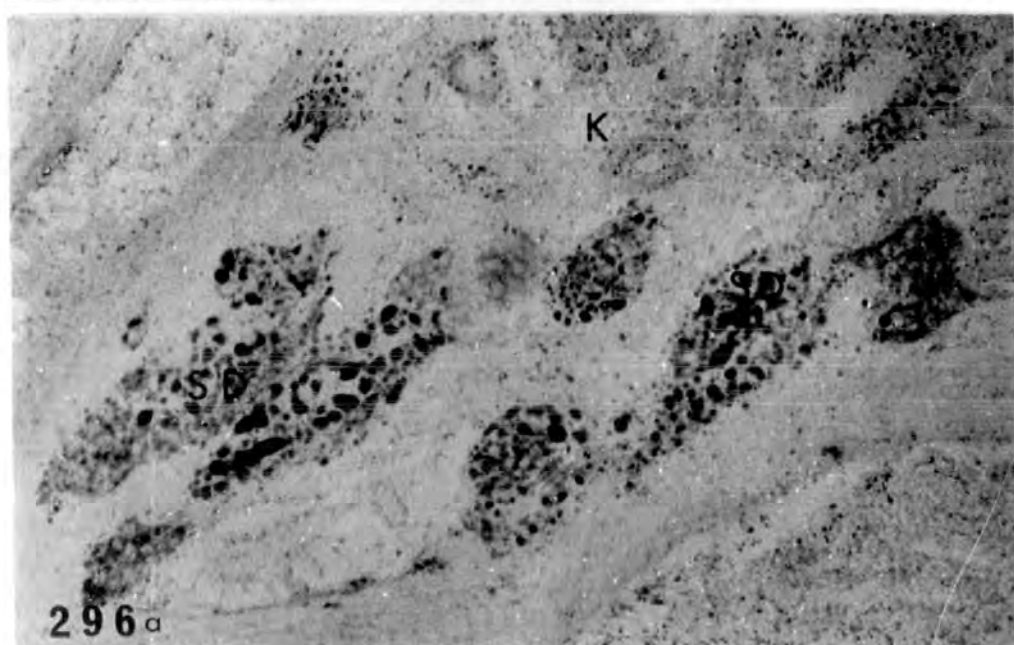
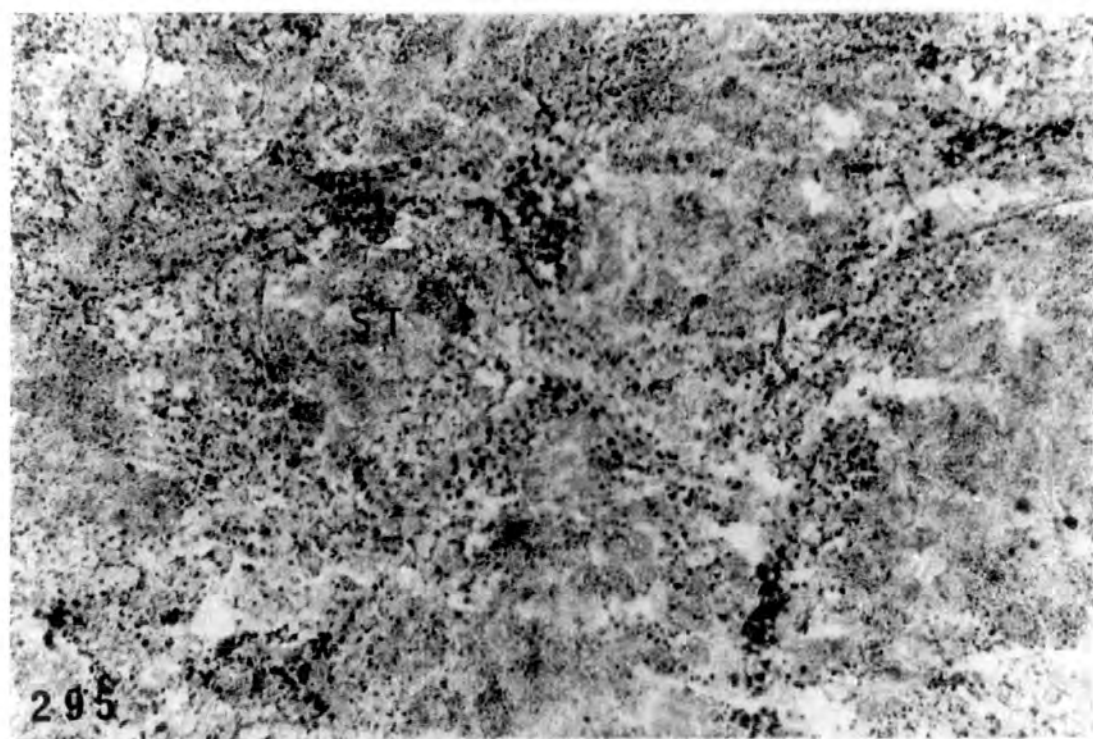
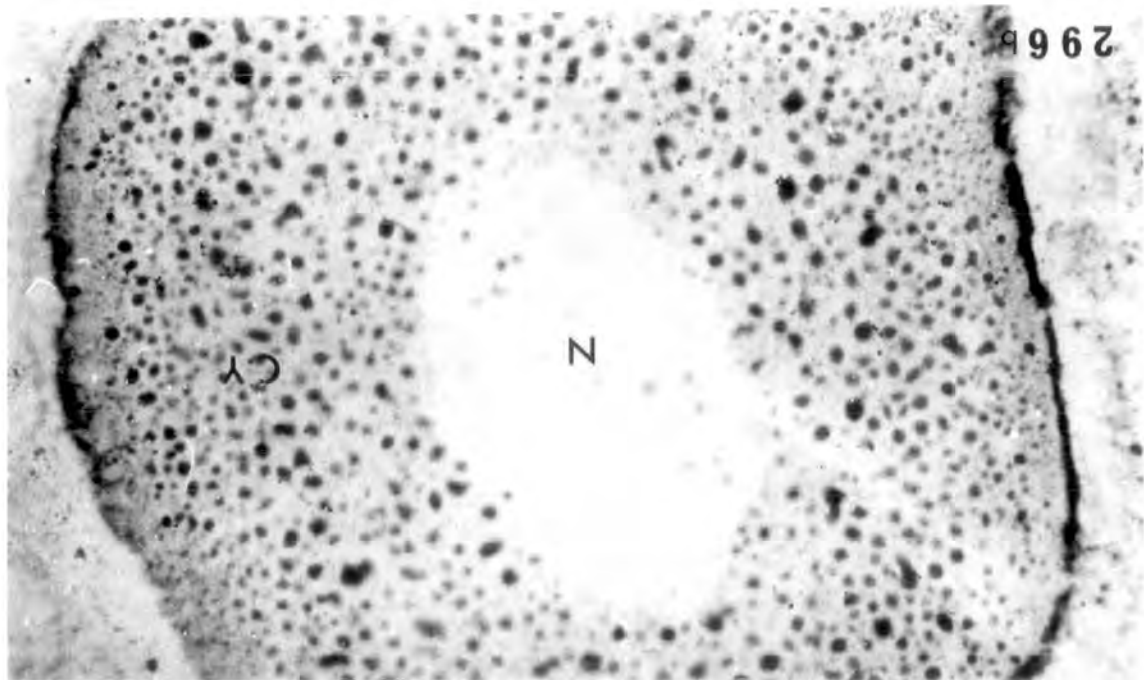
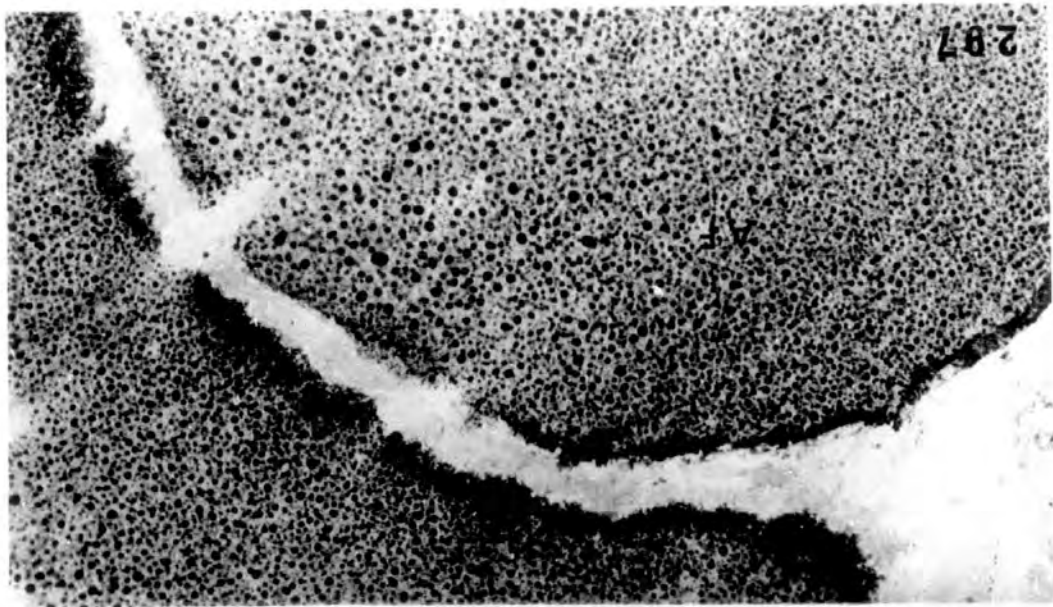
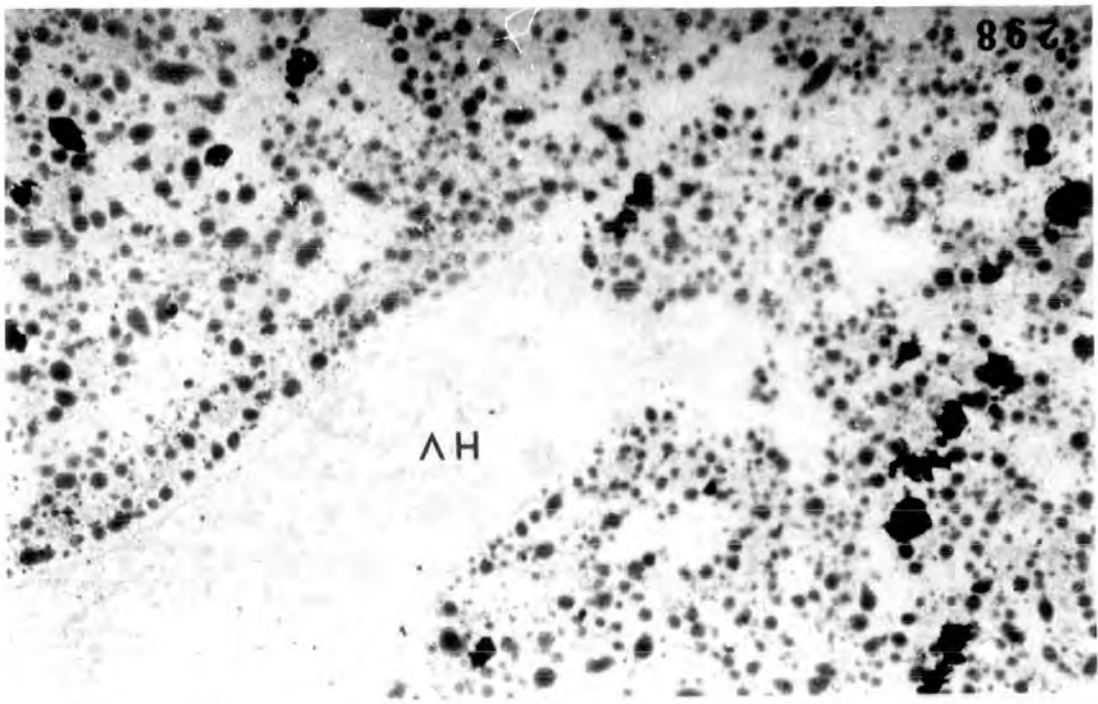


PLATE LXXXIX

Fig. 296b. Oocyte from 2 year old female showing large sudanophilic droplets in the cytoplasm, with smaller droplets around the periphery near the oocyte membrane. x 210.

Fig. 297. Lipid droplets in the soma of atretic follicles of a 2 year old adult female. x 210.

Fig. 298. Lipid droplets in the liver of the same adult female. x 210.



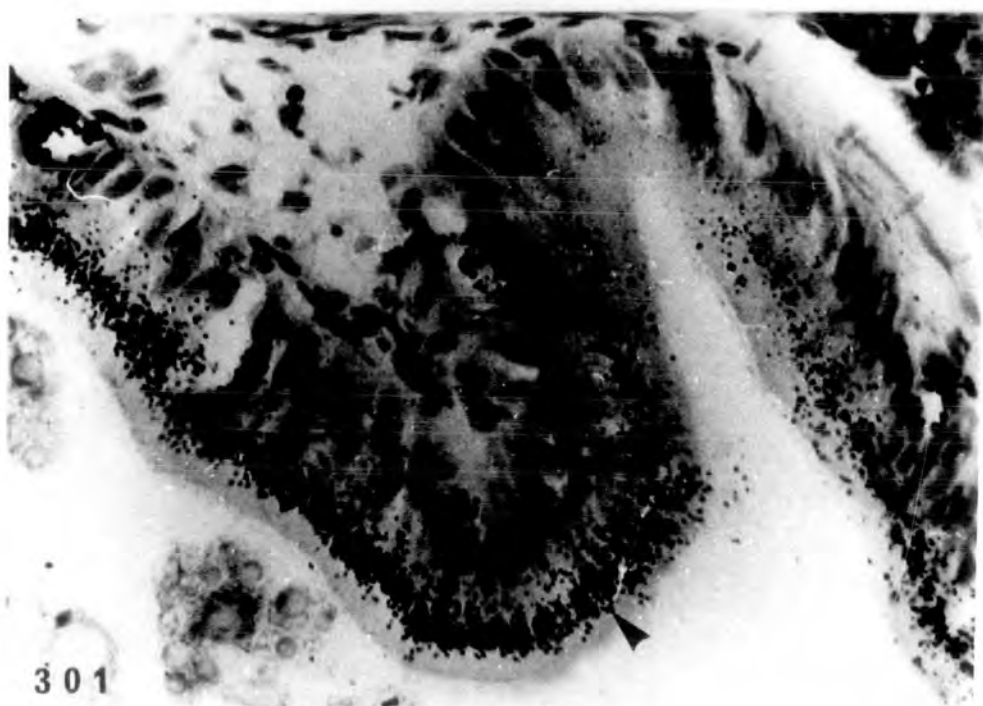
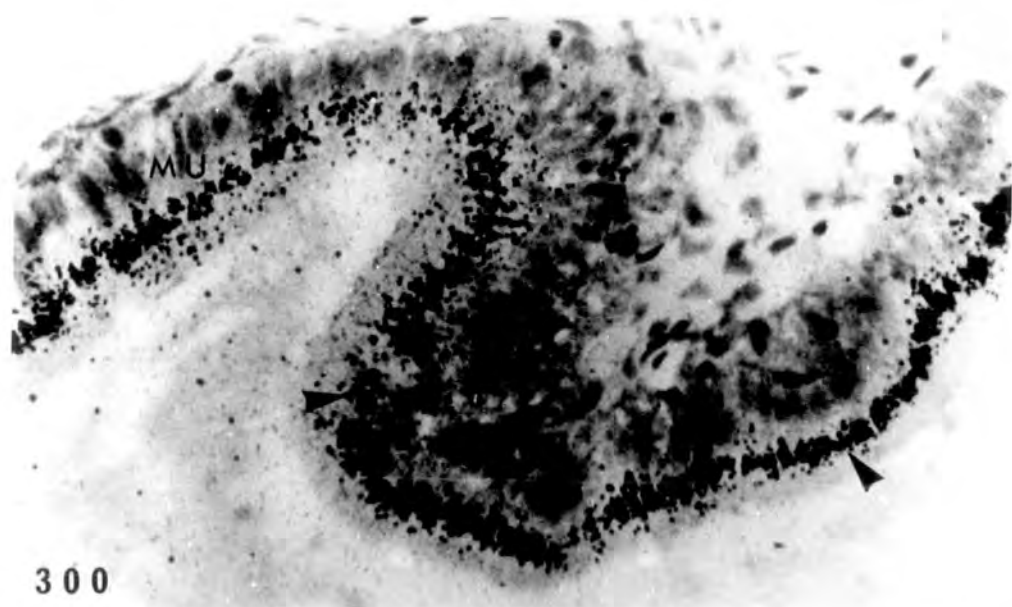
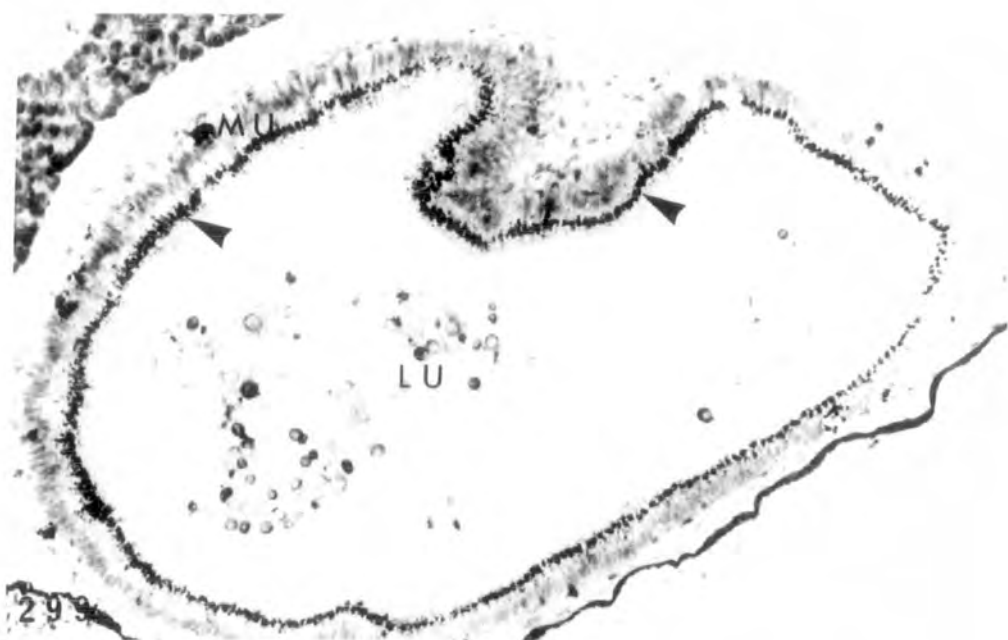St.56 larvae raised in 400ml of water with
15 μ Ci of | 6,7-³H | - oestradiol.

Figs. 299-300. Autoradiographs of larva after
4½ hours in culture showing accumulation
of silver (Ag) grains in the mucosa
(arrowheads) of the duodenum.

299 x 64

300 x 400

Fig. 301. Autoradiograph of larva after 24 hours
in culture, showing again accumulation
of Ag grains in the mucosa of the
duodenum (arrowhead). x 400.



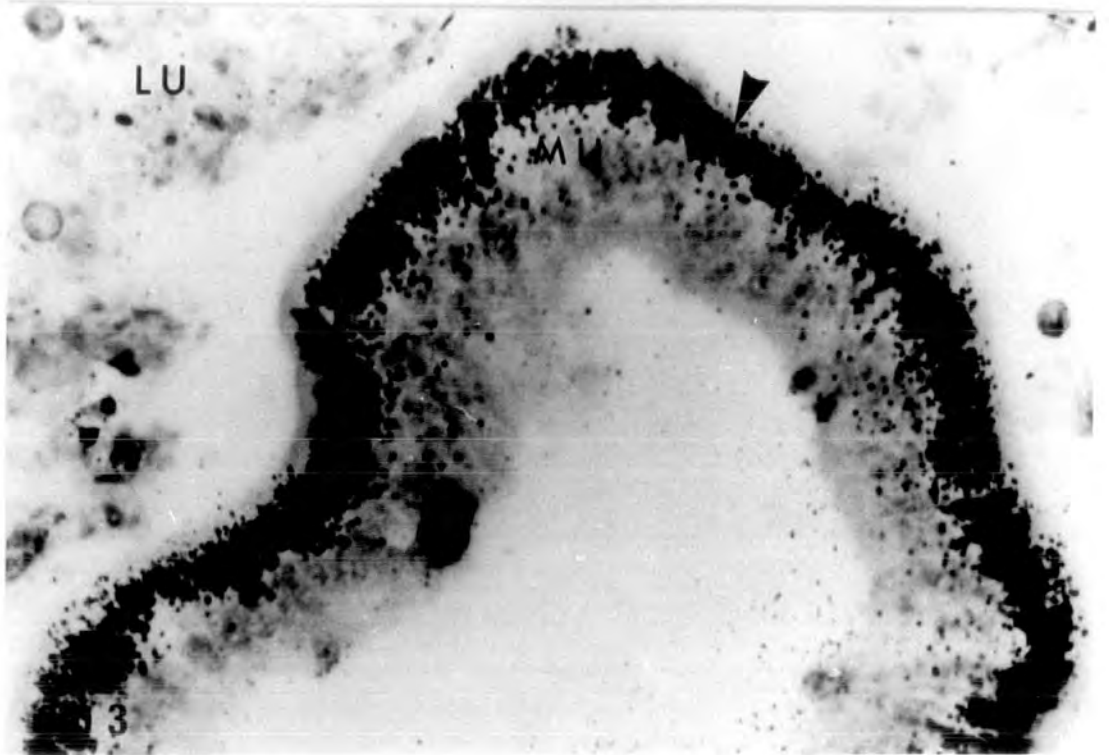
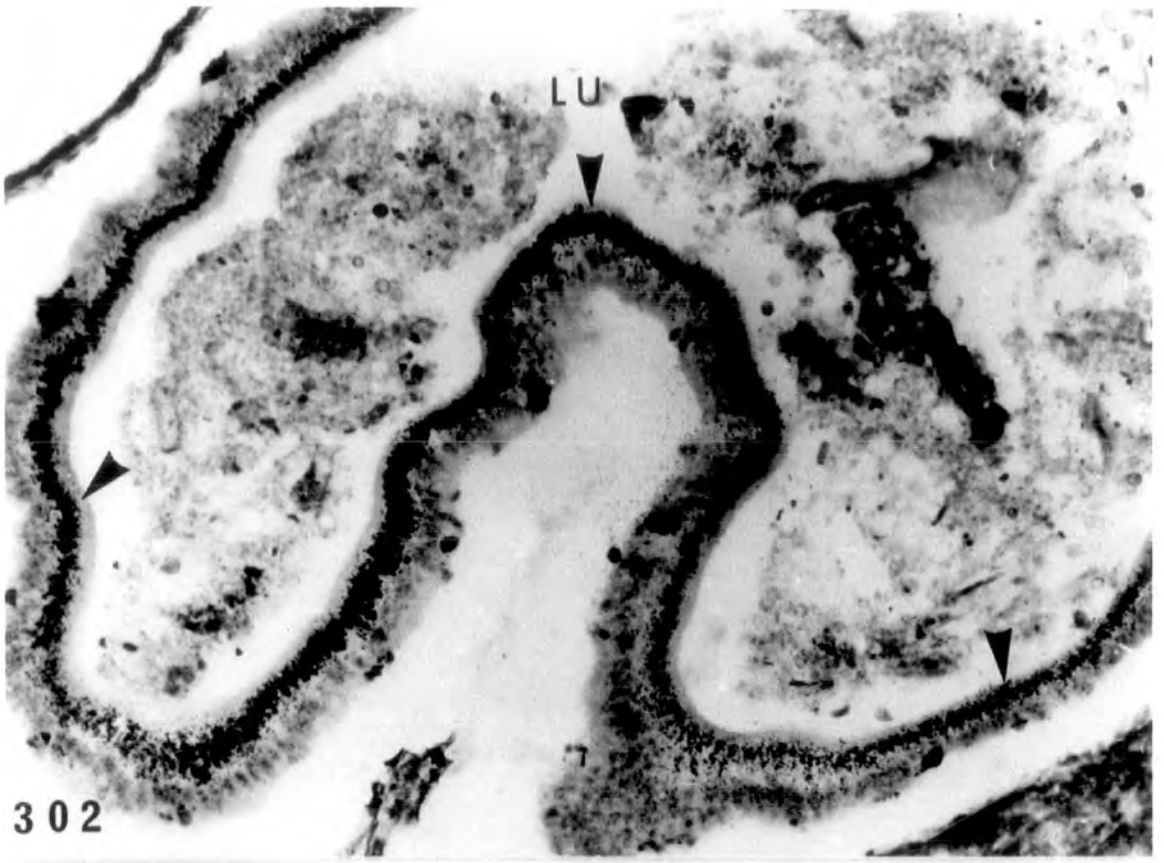
Injection of 5 μ Ci/10 μ l/st.56 larva |6,7-³H|-oestradiol

PLATE XCI

Figs. 302-303. The mucosa of the duodenum showing
accumulation of Ag grains (arrowheads)
1 hour after injection.

302 x 210

303 x 525.



Ag grains in the liver after injection of 5 μ

ci/10 μ l/larva |6,7-³H| -oestradiol

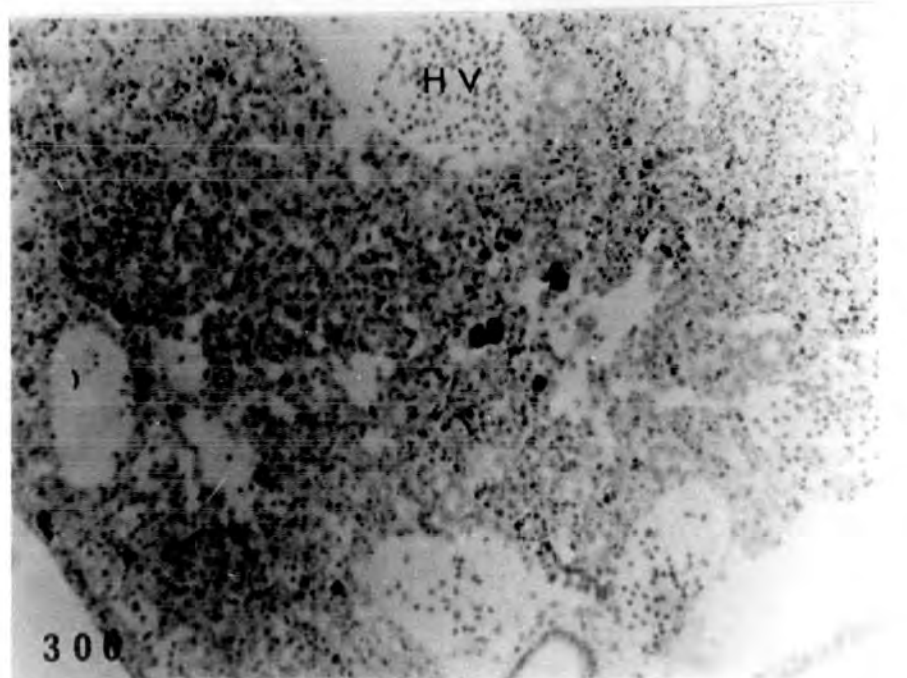
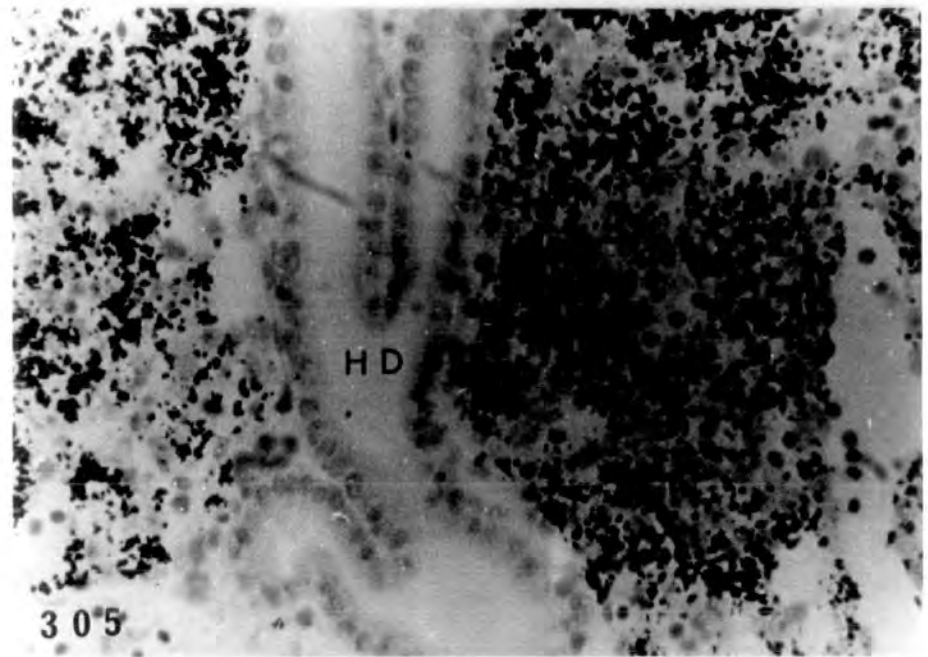
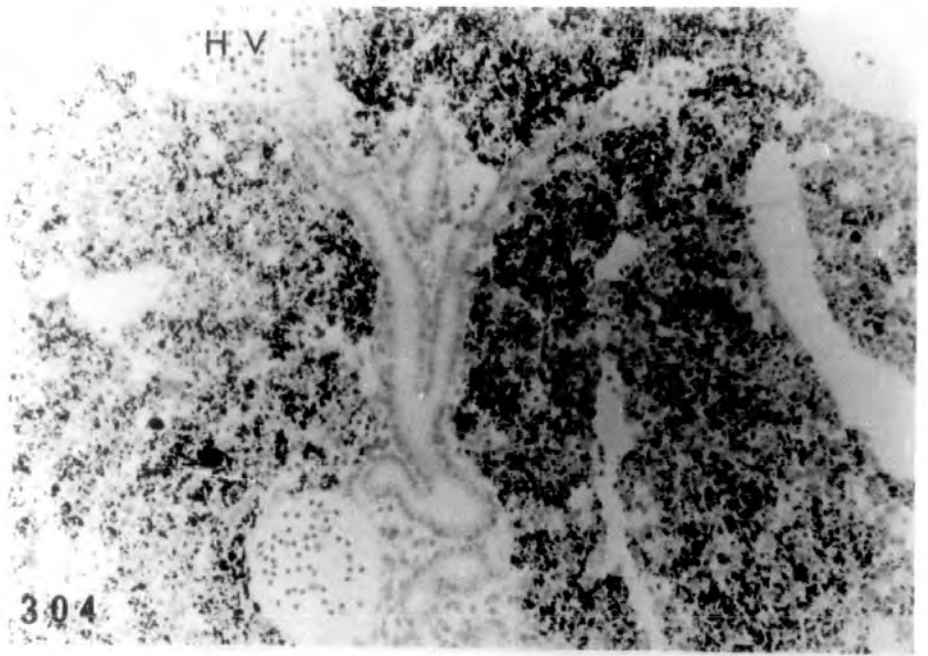
PLATE XCII

Figs. 304-305. Autoradiograph of a st.56 larva showing accumulation of Ag grains in the liver, 3 minutes after injection of the tritiated hormone.

304 x 190

305 x 475

Fig. 306. Autoradiograph of a st.55 larva showing small numbers (as compared to the above) of Ag grains in the liver 15 minutes after injection. x 190



Distribution of injected |6,7-³H|-oestradiol
(5 μ Ci/10 μ l/st.57 larva) following 26 days pre-
treatment with cold oestradiol

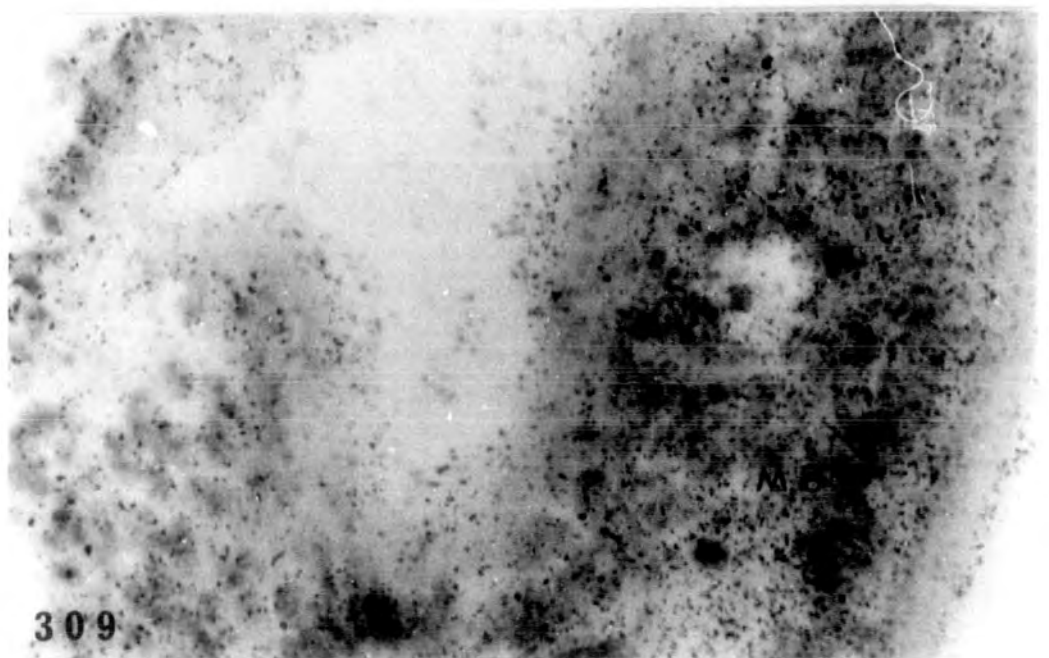
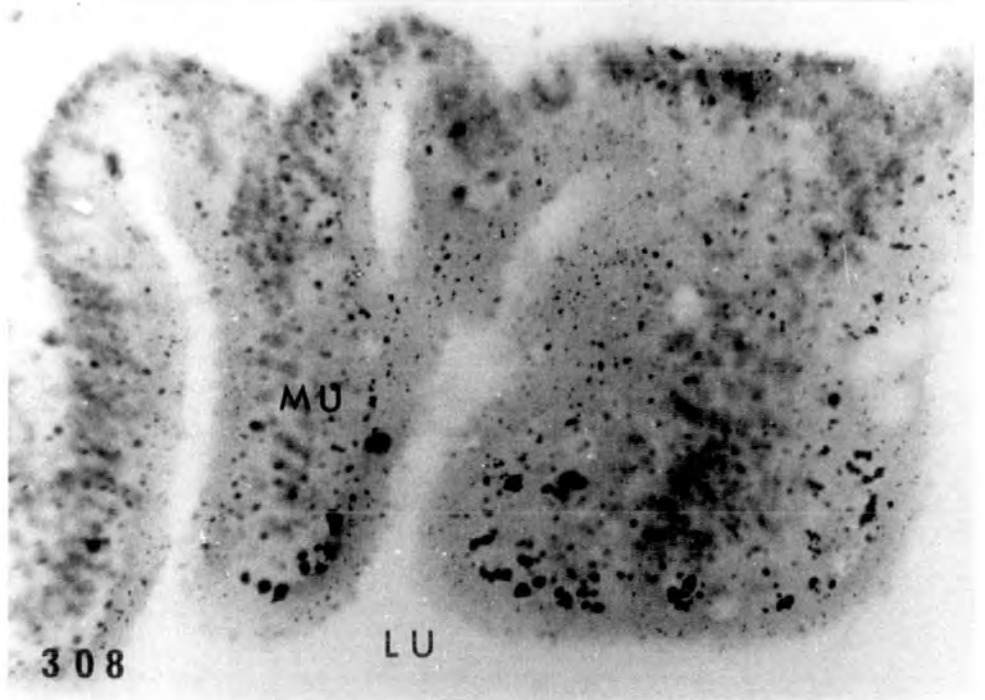
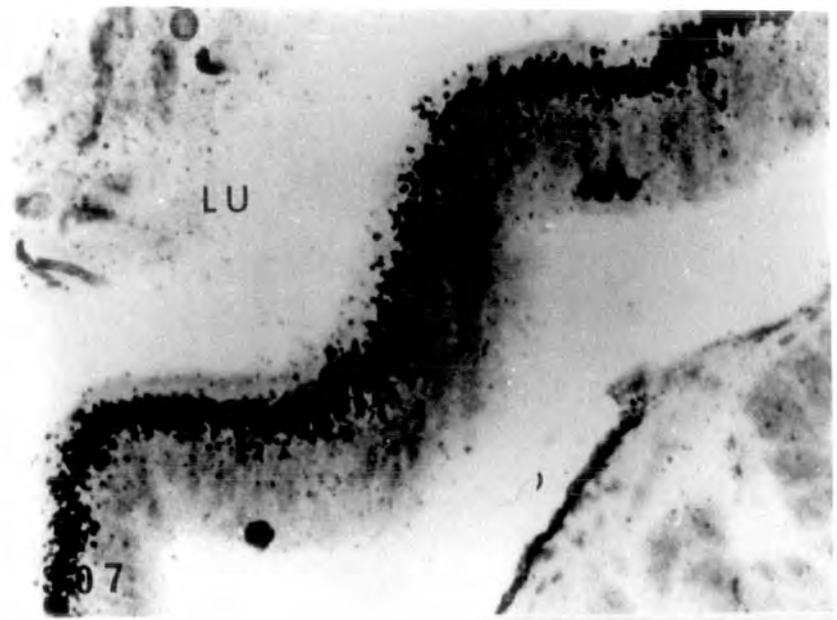
PLATE XCIII

Fig. 307. Autoradiograph of a st.57 larva showing accumulation of Ag grains in the mucosa of the duodenum 5 hours after injection of tritiated oestradiol. The larva was pretreated with alcohol solution for 26 days. x 500.

Figs. 308-309. Autoradiograph of st.57 larva pretreated with cold oestradiol for 26 days, showing decreased numbers (than the control above) of Ag grains in the mucosa of the duodenum 5 hours after injection.

308 x 500

309 x 800



Distribution of injected |5,6-³H| -uridine
(5 μ Ci/10 μ l/st.56 larva) following 26 days
pretreatment with cold oestradiol

PLATE XCIV

Figs. 310-313. Autoradiograph of st.56 larva control pretreated for 26 days with alcohol solution, showing Ag grains in the interrenal, fat body, ovarian cortex and mesonephric blastema 4.5 hr after injection of tritiated uridine. The last mentioned tissue shows more accumulation of grains than the others.

310 x 160

311-313 x 400

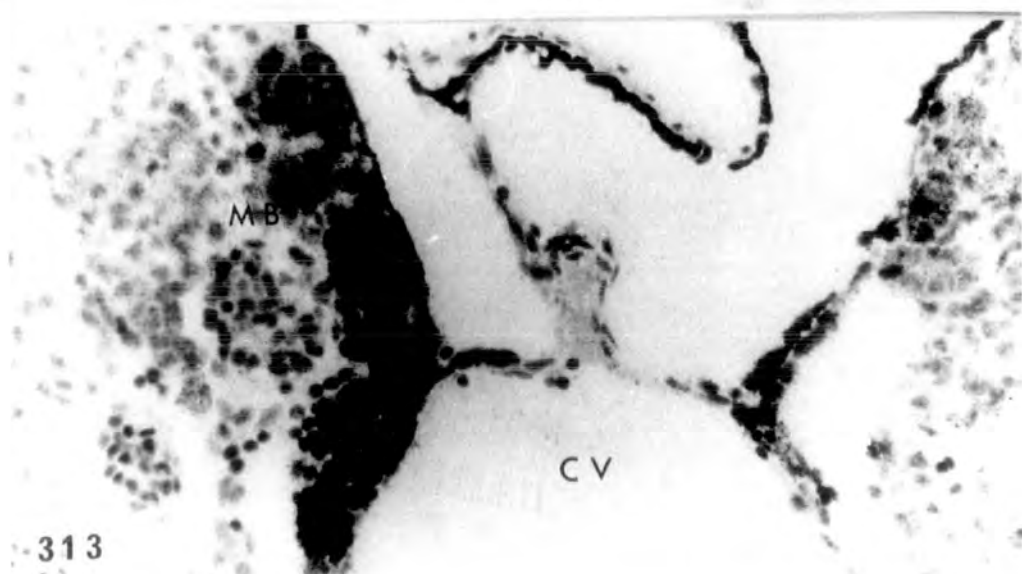
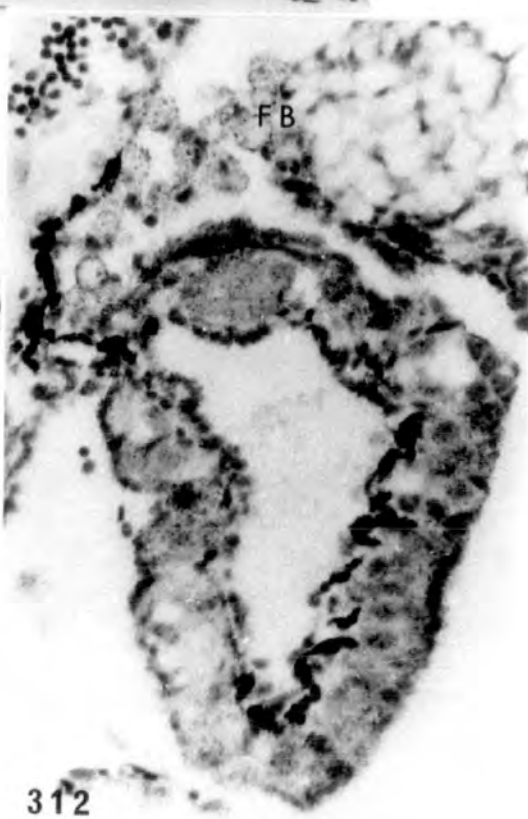
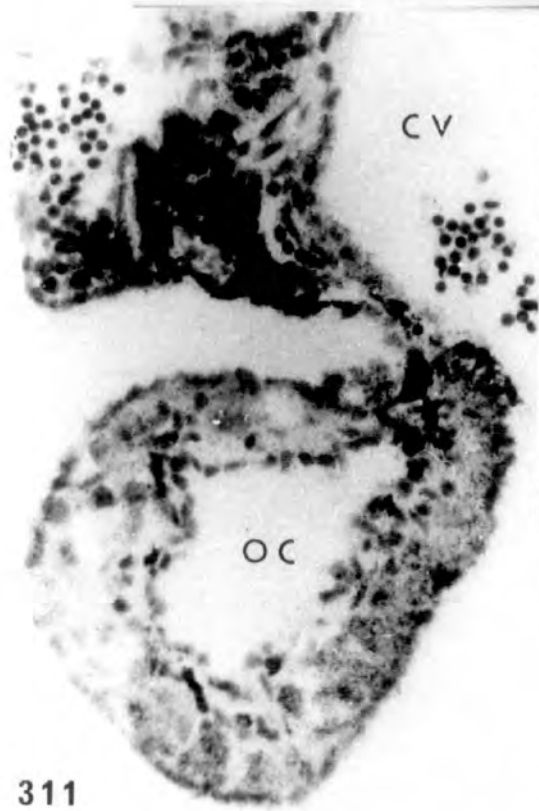
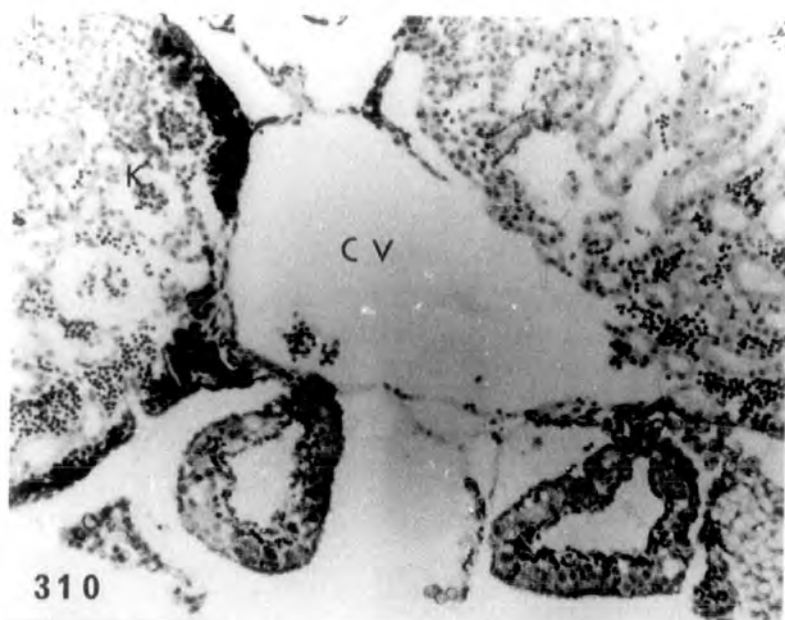
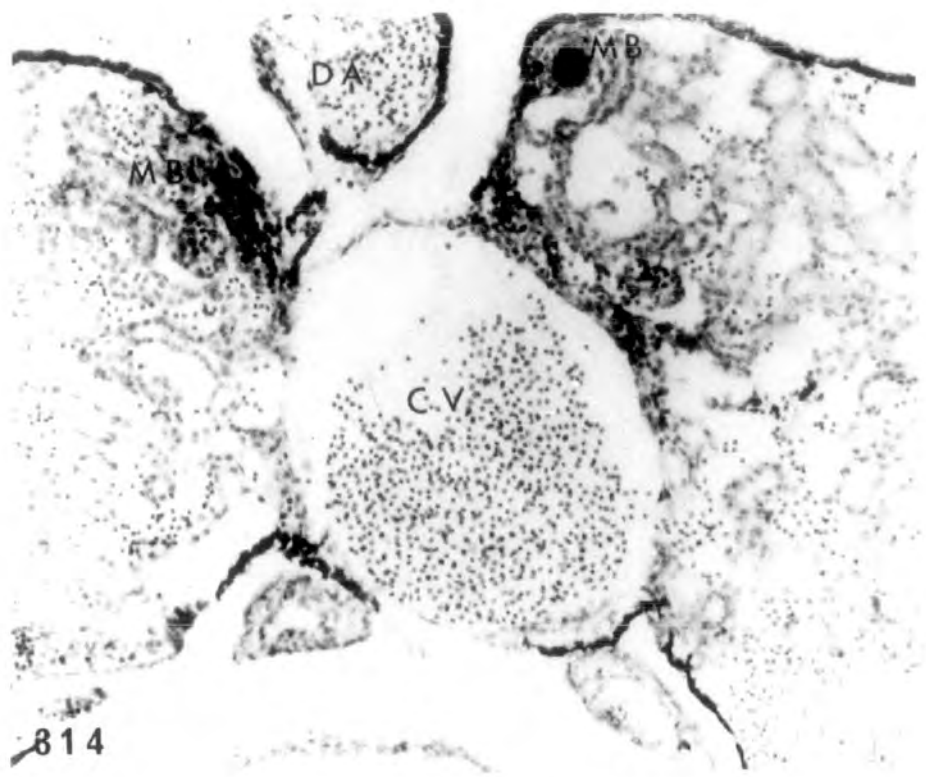


PLATE XCV

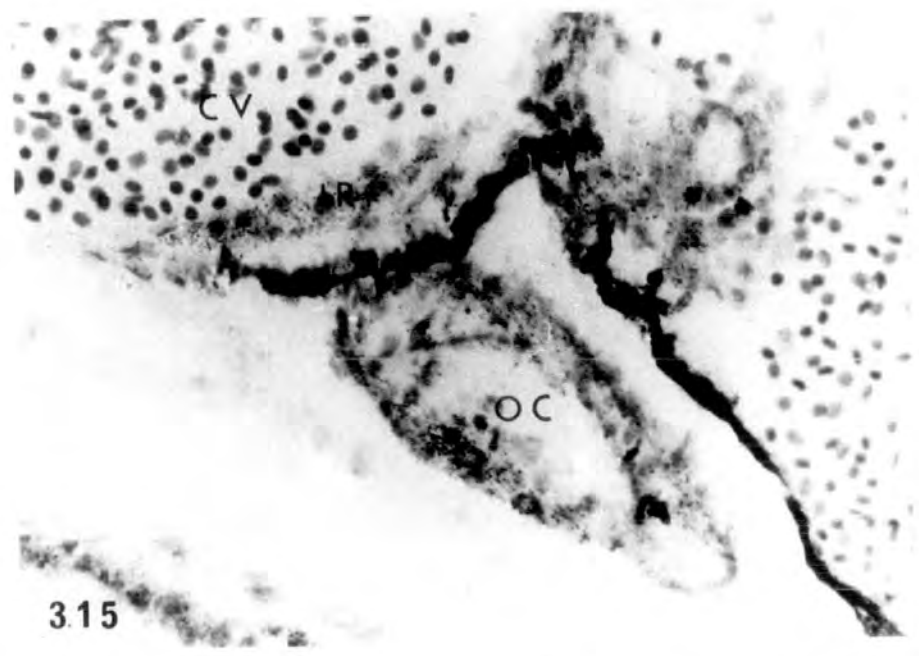
Figs. 314-316. Autoradiograph of st.56 larva pretreated for 26 days with 100µg/l oestradiol, showing Ag grains in the interrenal, ovarian cortex and mesonephric blastema 4.5 hr after injection. The last tissue again shows greater accumulation of grains than the other two tissues.

314 x 170

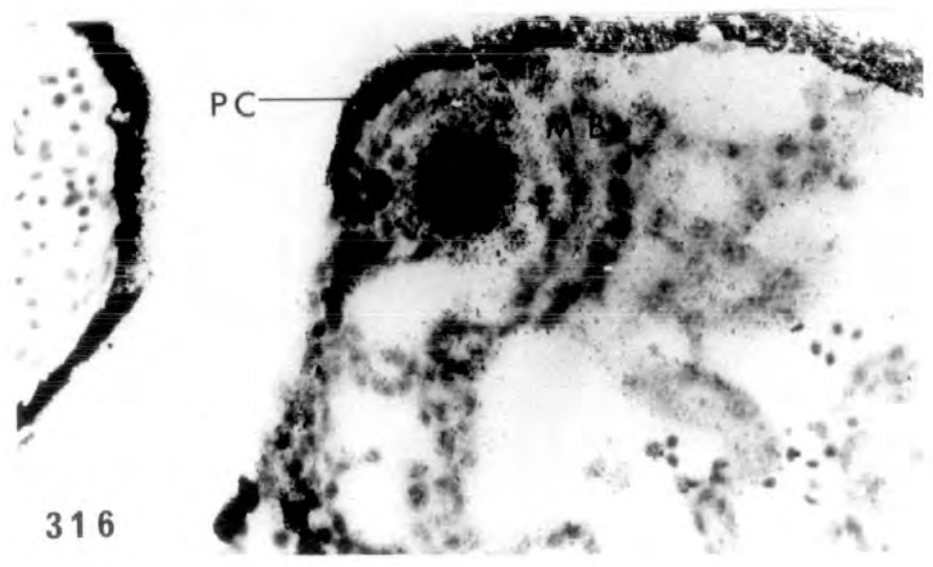
315-316 x 425



314



315



316

PLATE XCVI

Figs. 317-319. Autoradiograph of a st.56 control larva pretreated for 26 days with alcohol solution, showing Ag grains in the testis and mesonephric blastema 24 hr after injection of the tritiated uridine. The mesonephric blastema shows higher degree of aggregation of grains than the testis.

317 x 160

318-319 x 400

Fig. 320. Testis of another st.56 control larva showing Ag grains in the testicular soma 24 hr after injection of tritiated uridine. x 400.

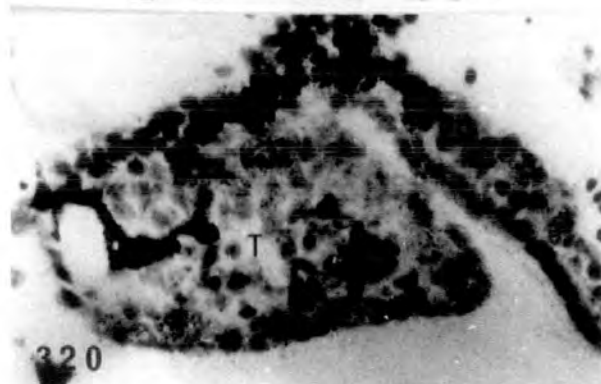
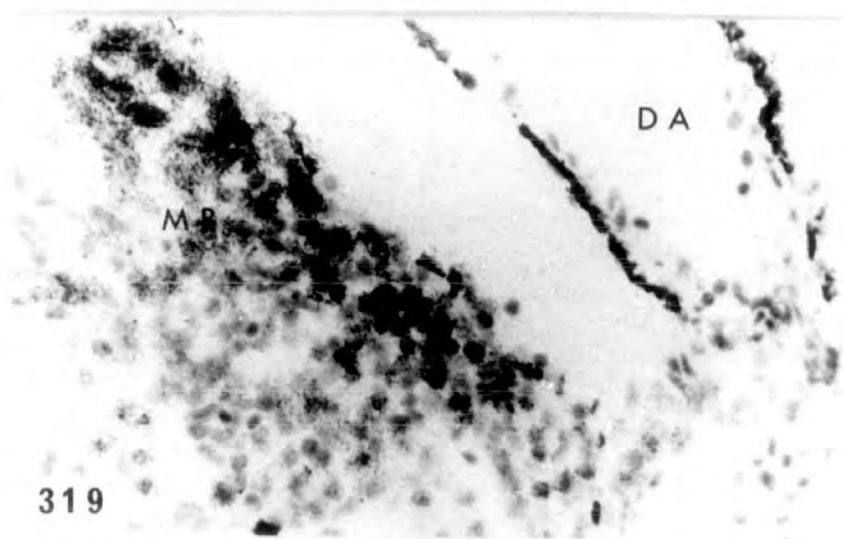
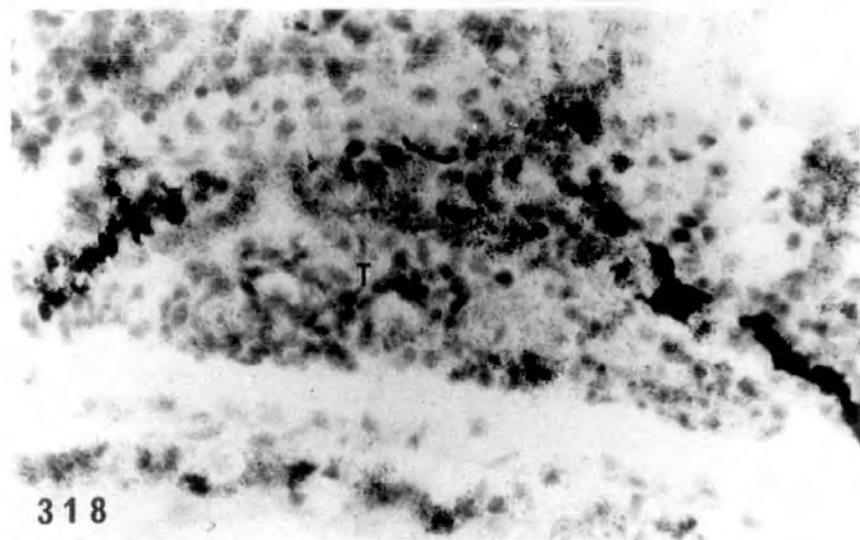
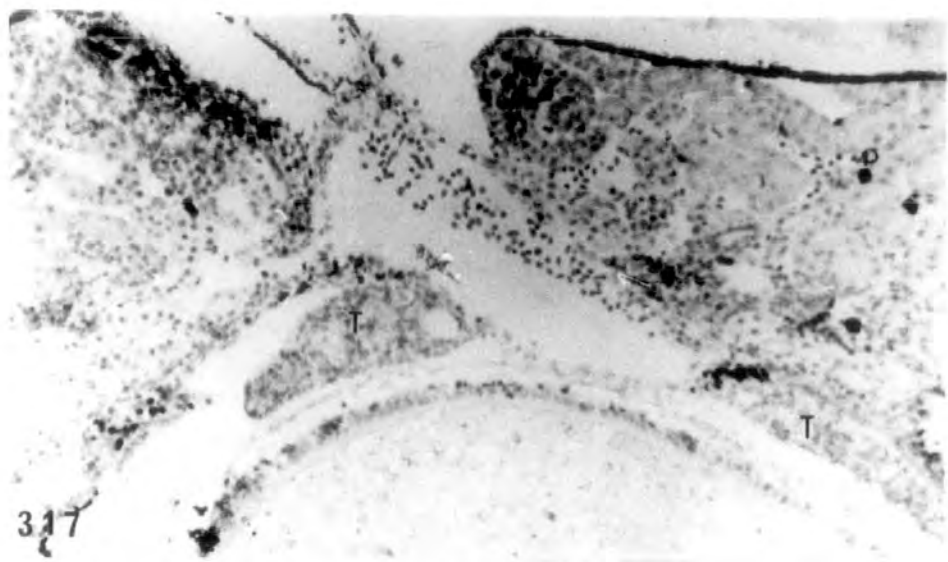
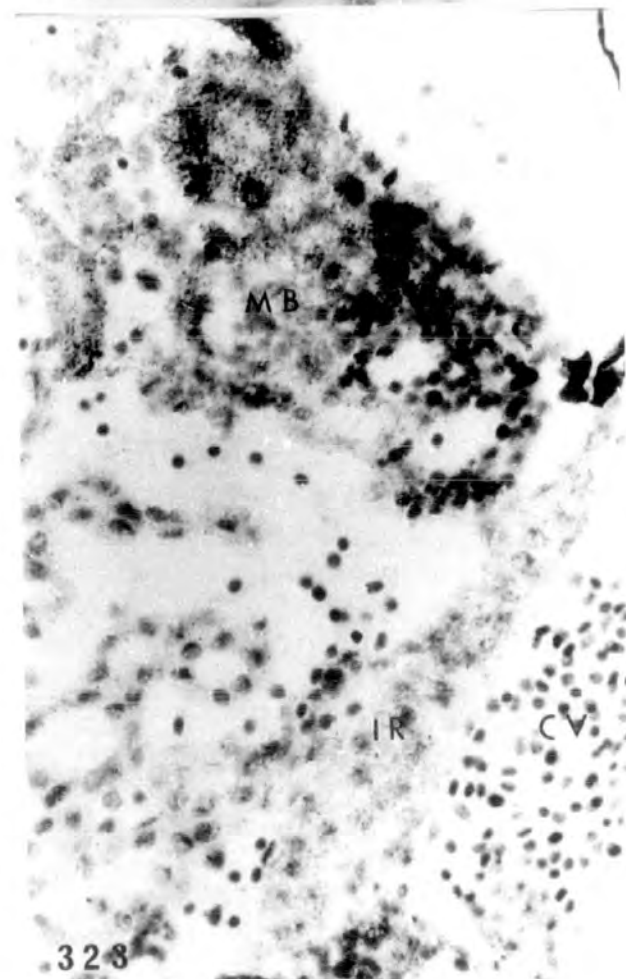
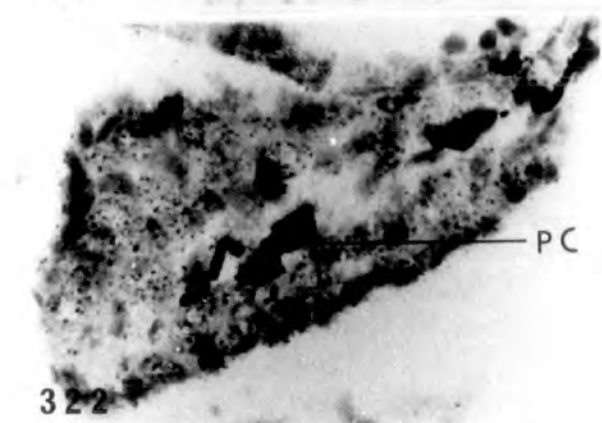
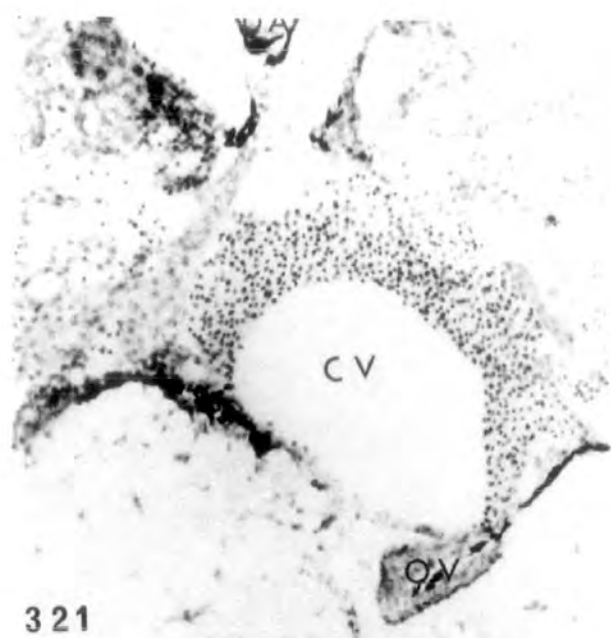


PLATE XCVII

Figs. 321-323. Autoradiograph of a st.56 larva pretreated for 26 days with 100µg/l oestradiol, showing Ag grains in the interrenal, ovarian cortex and mesonephric blastema, 24 hr after the injection of tritiated uridine. The mesonephric blastema shows higher degree of aggregation of the grains than the other tissues.

321 x 160

322-323 x 640.



Injected $6,7\text{-}^3\text{H}$ -oestradiol (5 $\mu\text{Ci}/10\mu\text{l}/\text{juvenile}$)
in 7 month old Xenopus.

PLATE XCVIII

Fig. 324. Autoradiograph showing numerous Ag grains in the large hepatic vein, of a juvenile male 5 min after the injection of tritiated oestradiol. x 160.

Figs. 325-326. Autoradiograph showing the left lobe of the kidney with Ag grains in the wall of the kidney tubules of the same male, 5 hours after the injection of the tritiated oestradiol. Ag grains are also present in the renal blood vessel.

325 x 160

326 x 400.

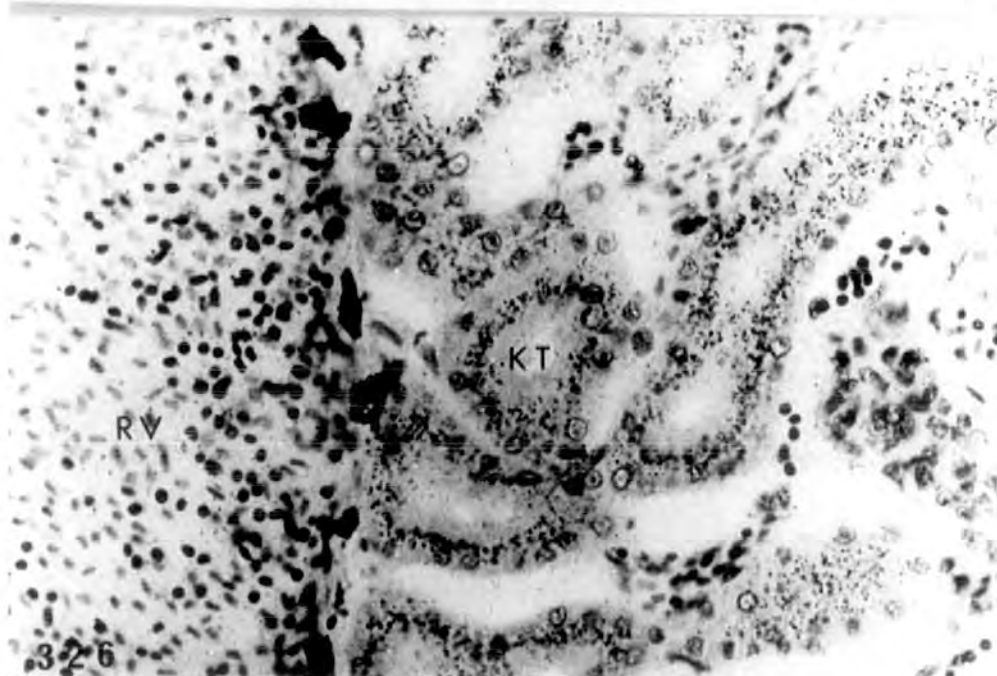
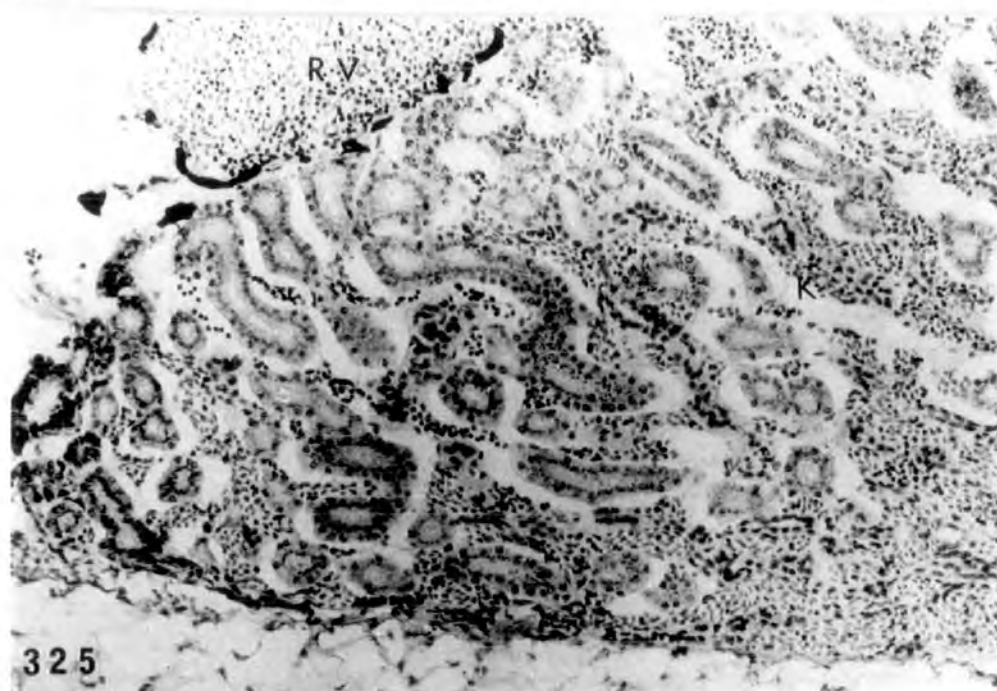
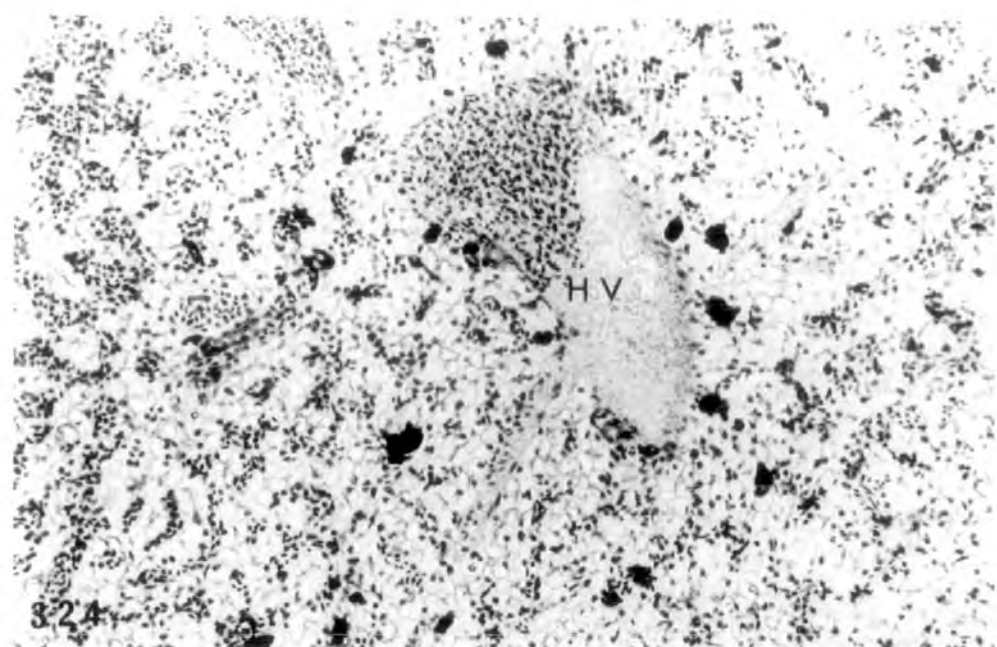


PLATE XCIX

Figs. 327-328. Autoradiograph showing some
Ag grains in the duodenal mucosa
of a juvenile male, 5 hr after
injection of tritiated oestradiol.

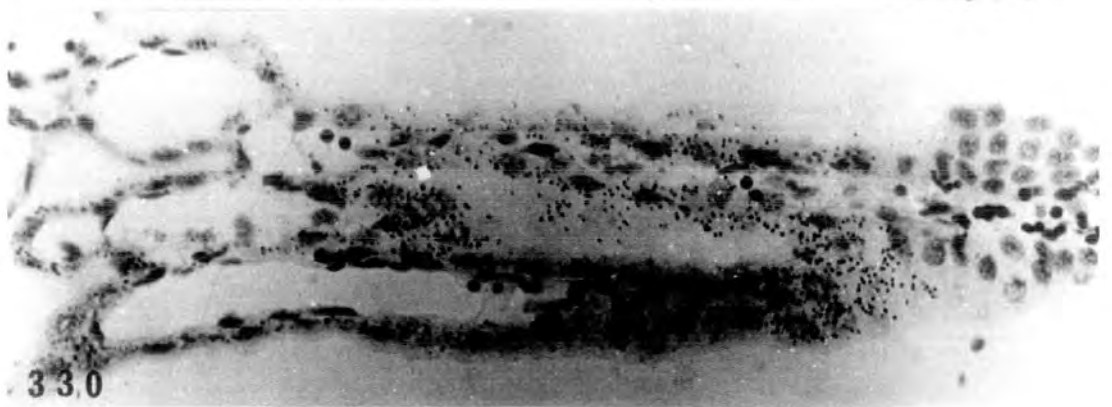
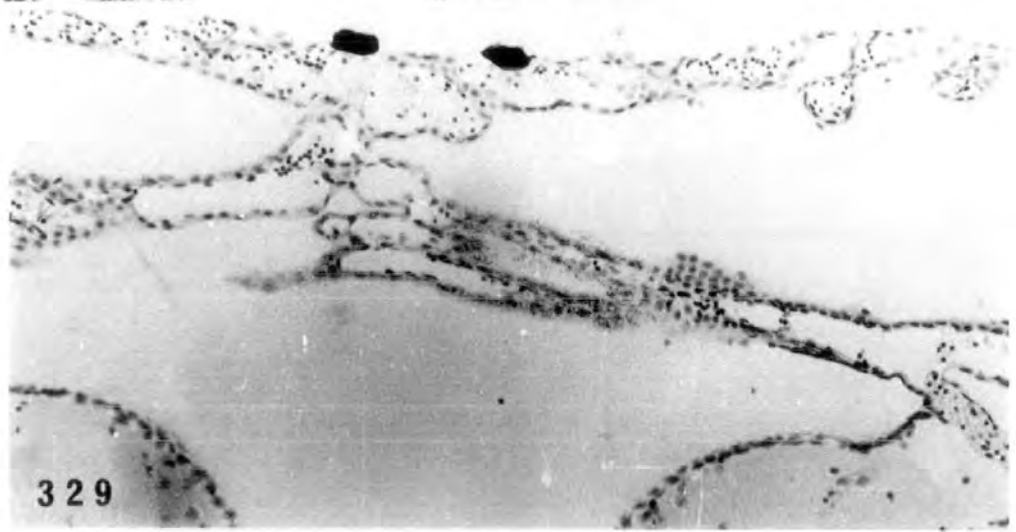
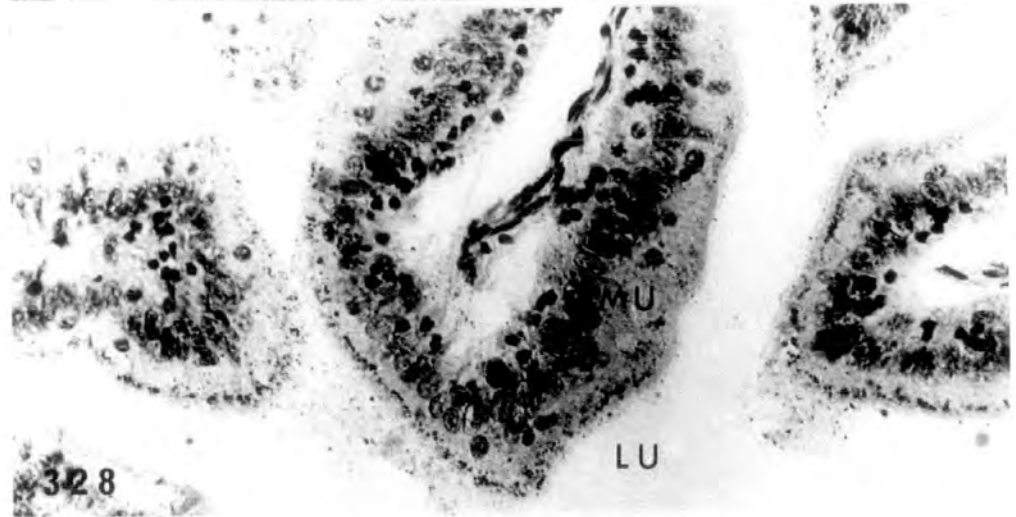
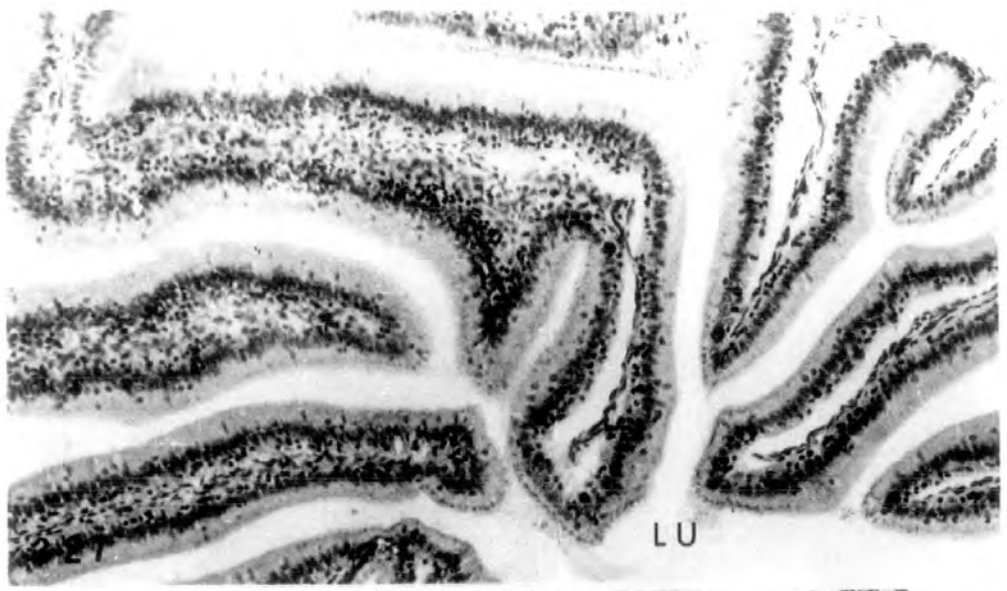
327 x 160

328 x 400

Figs. 329-330. Autoradiograph of another male
showing Ag grains in the choroid
plexus of the brain, 24 hr after
injection of the tritiated
oestradiol.

329 x 160

330 x 400



Injected |1,2,6,7-³H| -progesterone in larvae
(5 μ Ci/10 μ l/ st.56 larva)

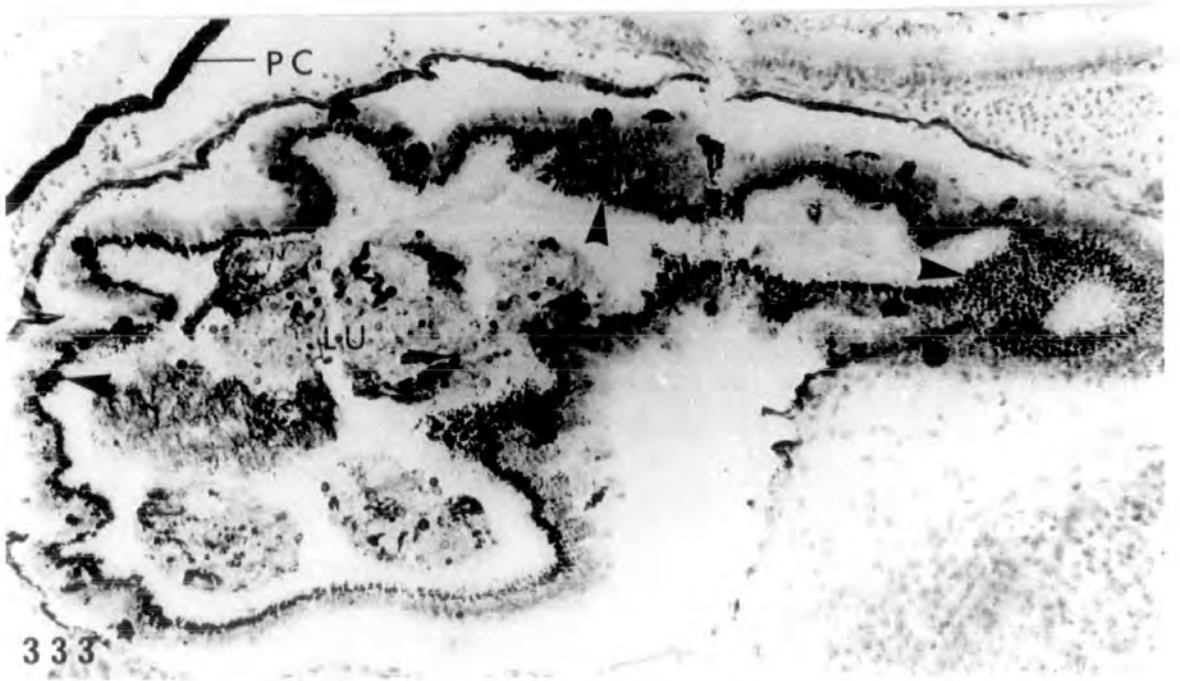
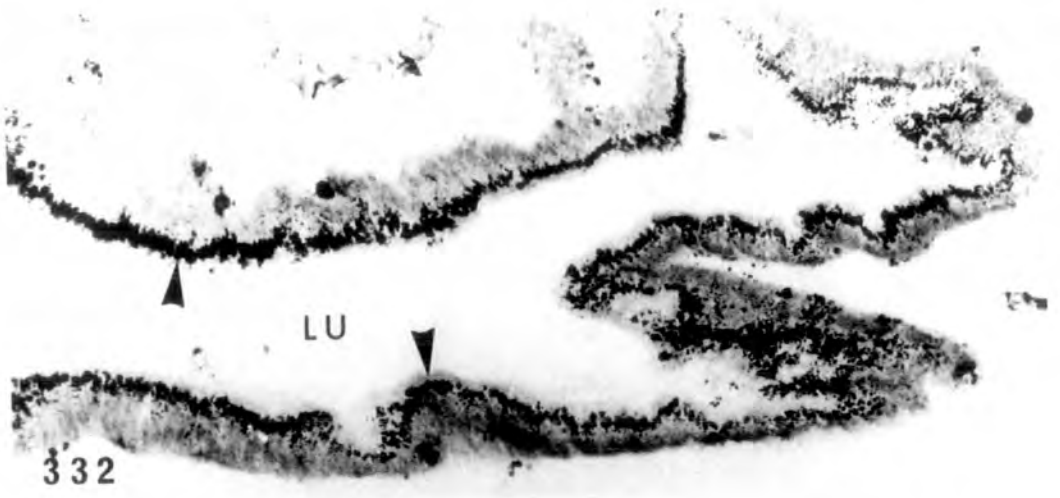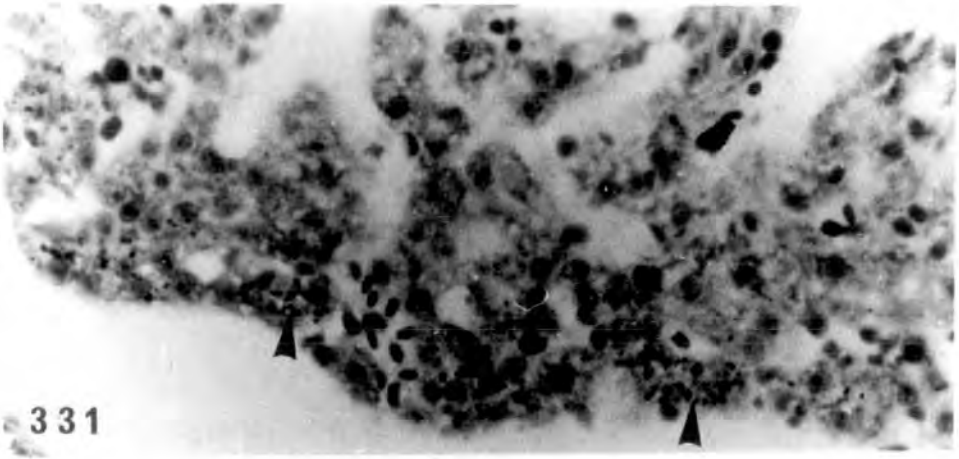
PLATE C

Fig. 331. Autoradiograph showing very few Ag grains (arrowheads) in the liver of a st.56 larva three min after the injection of the tritiated progesterone.
x 400.

Figs. 332-333. Autoradiograph showing intense accumulation of Ag grains (arrowheads) in the mucosa of the duodenum of a st.56 larva, 24 hr after the injection of the tritiated progesterone.

332 x 160

333 x 400.



Injected |1,2,6,7-³H| -progesterone in 7 month
old juvenile (5 μ Ci/10 μ l/juvenile)

PLATE CI

Figs. 334-335. Autoradiograph showing Ag grains
in the hepatic vein of the liver of a
young female five months after
injection. At the higher
magnification Ag grains can be seen
in the sinusoids.

334 x 160

335 x 400

Fig. 336. Autoradiograph showing Ag grains in the
wall of the kidney tubules and in the
renal blood vessel of the same female
5 min after injection. x 400.

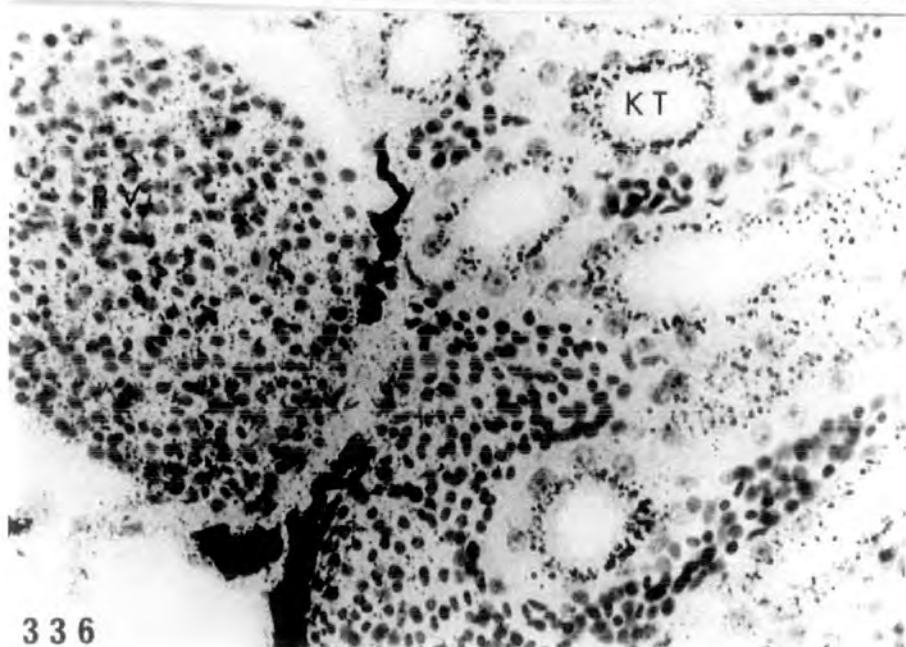
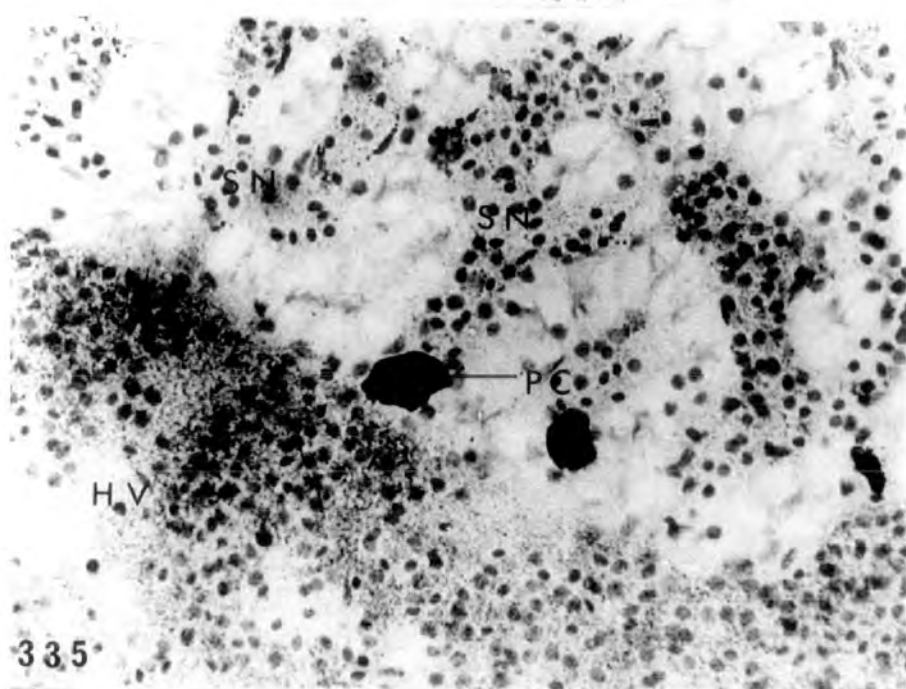
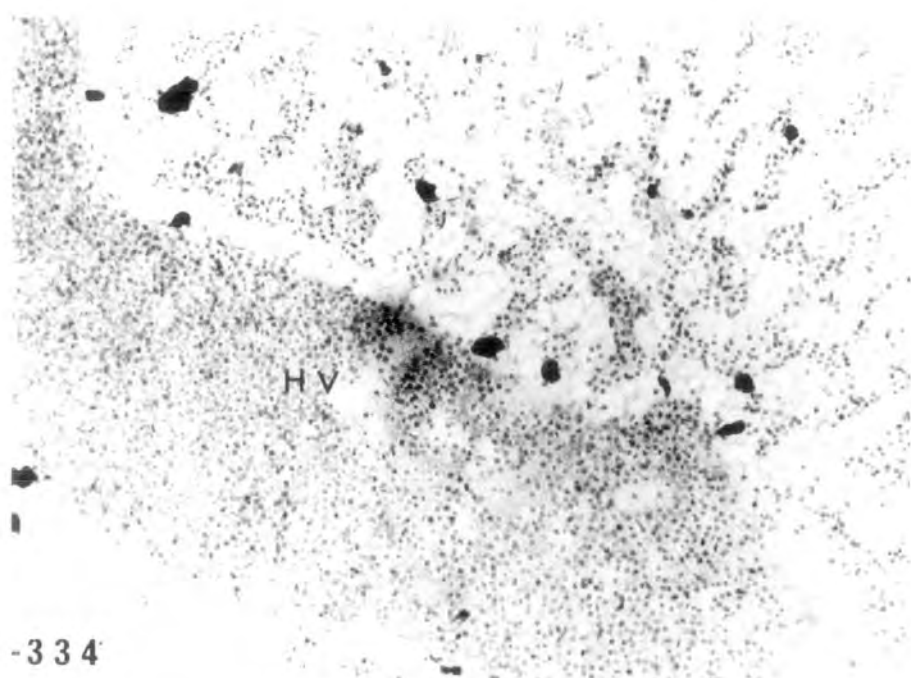


PLATE CII

Fig. 337 Autoradiograph showing a small number of Ag grains in the duodenal mucosa of the same female, five min after injection of tritiated progesterone. x 475.

Figs. 338-339. Autoradiograph showing Ag grains in the choroid plexus of the brain in the same female, five min after injection.

338 x 190

339 x 475



