

Durham E-Theses

A study of the reinnervation of stretch receptors in cat muscle following nerve injury

Alan Boddy

How to cite:

Boddy, Alan (1983) A study of the reinnervation of stretch receptors in cat muscle following nerve injury. Doctoral thesis, Durham University.

Use policy

The full-text may be used and/or reproduced, and given to third parties in any format or medium, without prior permission or charge, for personal research or study, educational, or not-for-profit purposes provided that:

- a full bibliographic reference is made to the original source
- a <https://etheses.durham.ac.uk/id/eprint/7249/> is made to the metadata record in Durham E-Theses
- the full-text is not changed in any way

The full-text must not be sold in any format or medium without the formal permission of the copyright holders.

Please consult the [full Durham E-Theses policy](#) for further details.

A STUDY OF THE REINNERVATION OF STRETCH RECEPTORS

IN CAT MUSCLE FOLLOWING NERVE INJURY

A thesis presented in candidature for the degree

Doctor of Philosophy

by

Alan Boddy, B.Sc. (Dunelm)

Department of Zoology, University of Durham.

Durham, April 1983.

Vol II

The copyright of this thesis rests with the author.
No quotation from it should be published without
his prior written consent and information derived
from it should be acknowledged.



28. NOV 1983

PLATES AND FIGURES

The copyright of this thesis rests with the author.
No quotation from it should be published without
his prior written consent and information derived
from it should be acknowledged.



28. NOV 1983

Thesis

1983 / BOD

Fig.2.1

Apparatus for silver staining.

The muscle(m) is suspended in solution (s) by a nylon thread(n) to which a label is attached. The label is hooked into a slot in the ring(r). The ring has the capacity to hold up to 6 muscles. The ring sits in the neck of a glass jar which has a screw-top lid(s). Transfer of muscles between bottles is achieved by moving the ring.

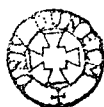


Fig2.1

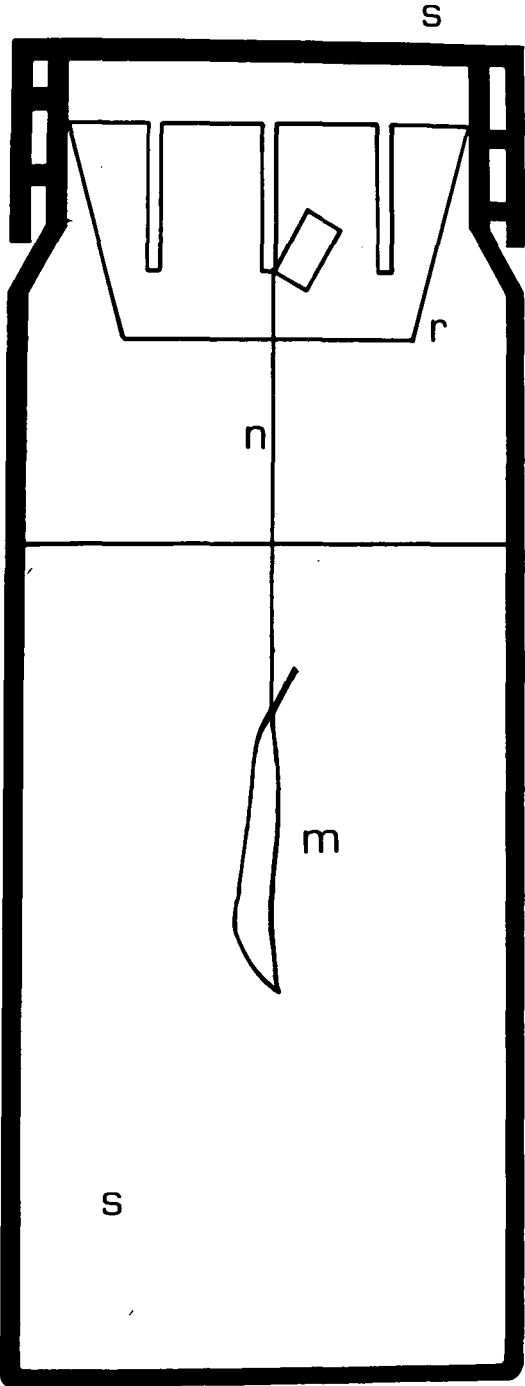


Fig 2.2.

Apparatus for silver staining.

During the washing stage, the muscle(m) is suspended from another plastic ring(r), hung from the lid of a large jar. The washing solution is siphoned from a 30 l. aspirator, at a rate which allows the process to continue for up to 24h. The jar is cooled by running tap water.(c)

Fig2.2

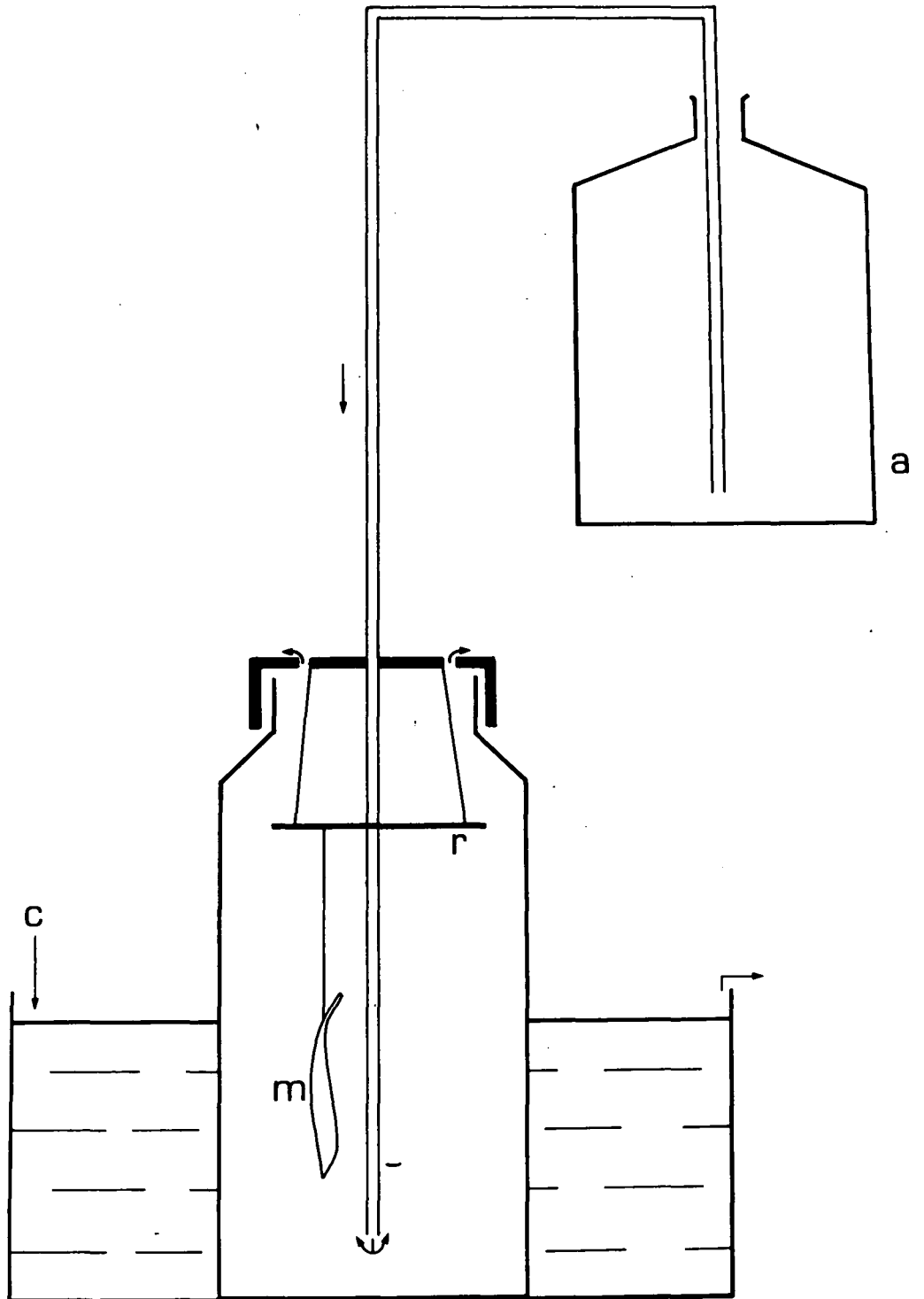


Fig 2.3.

Hypothetical sequence of events within a muscle
on immersion in silver nitrate solution.

The graphs A&B represent the conditions at time intervals a-g after immersion, with respect to pH and silver ion concentration. Only at time (d) do the correct conditions obtain, and this occurs at position (D) on the radius. This would give a ring of adequately stained material on a transverse section of the muscle.

Fig2.3

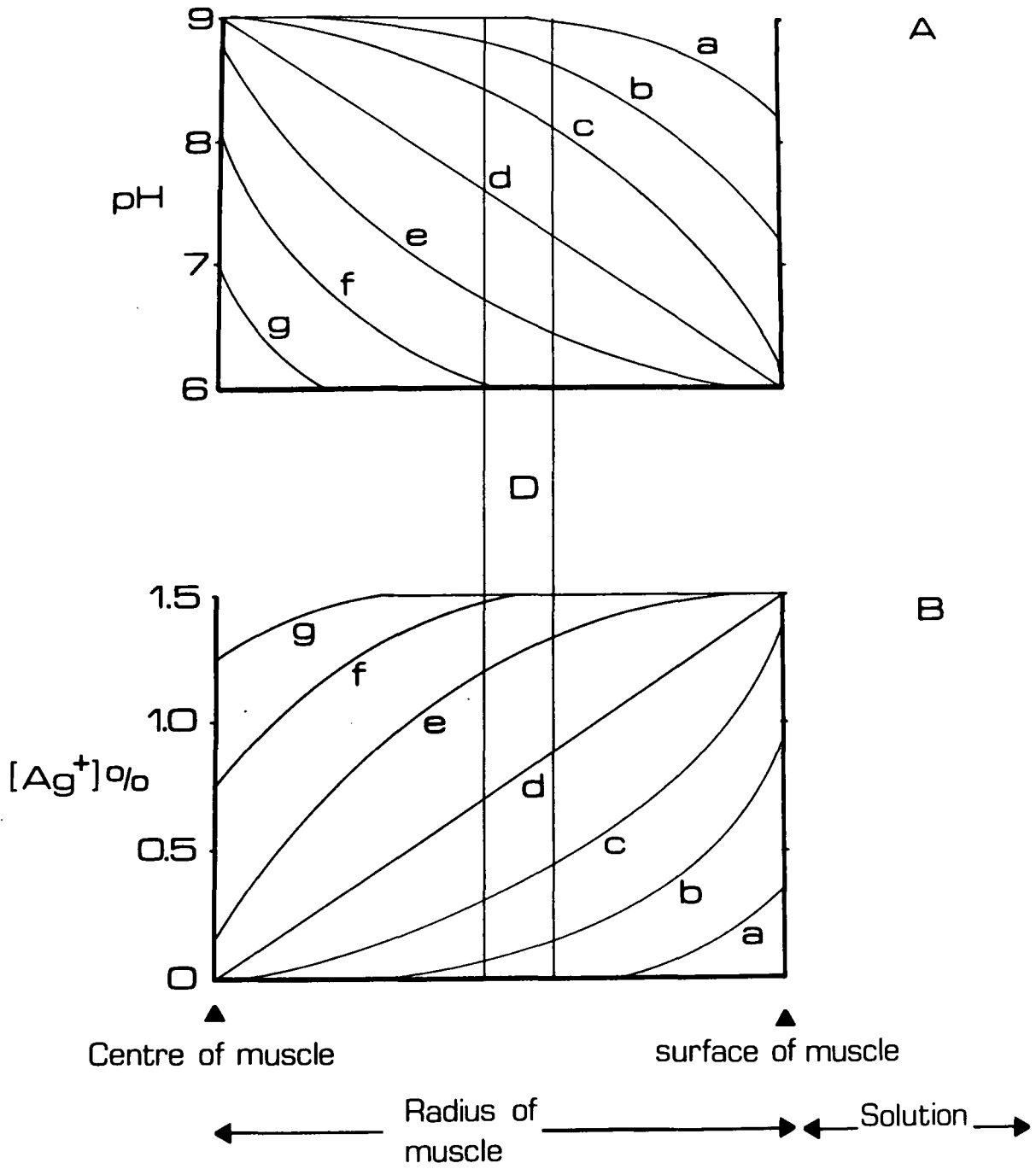


Fig 2.4

Hypothetical sequence of events within a muscle
with a diffusion barrier.

It is suggested that the presence of a diffusion barrier will reduce both the pH gradient and silver ion concentration gradient, within the muscle. This effect could be utilised to increase the volume of muscle within which adequate staining takes place.

Fig 2.4

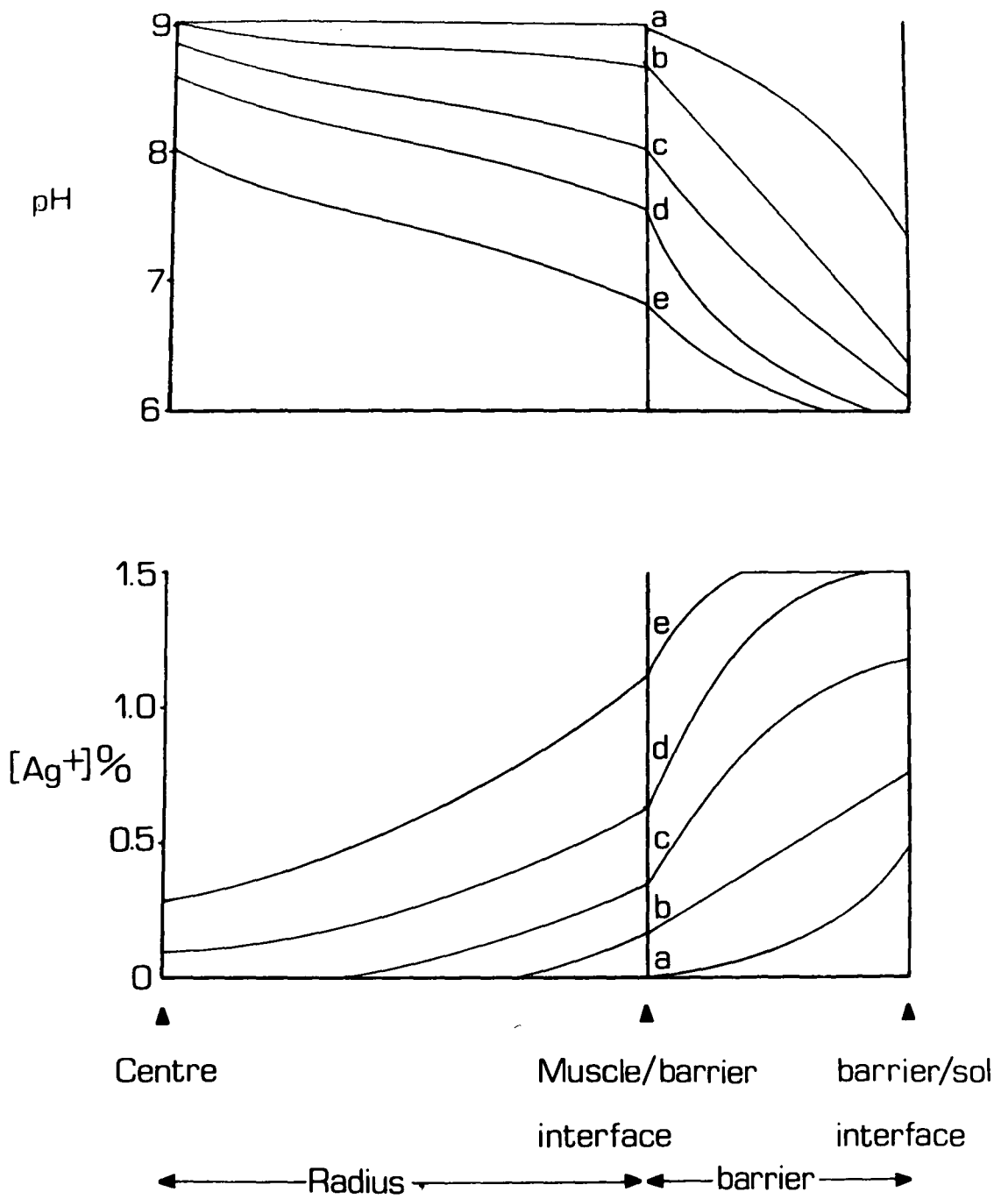
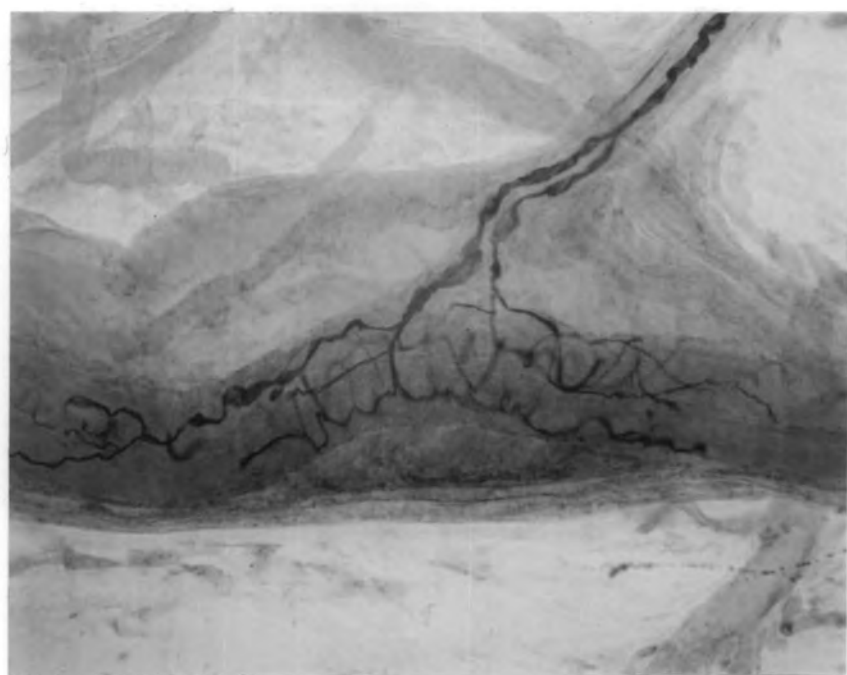


Plate 2.1

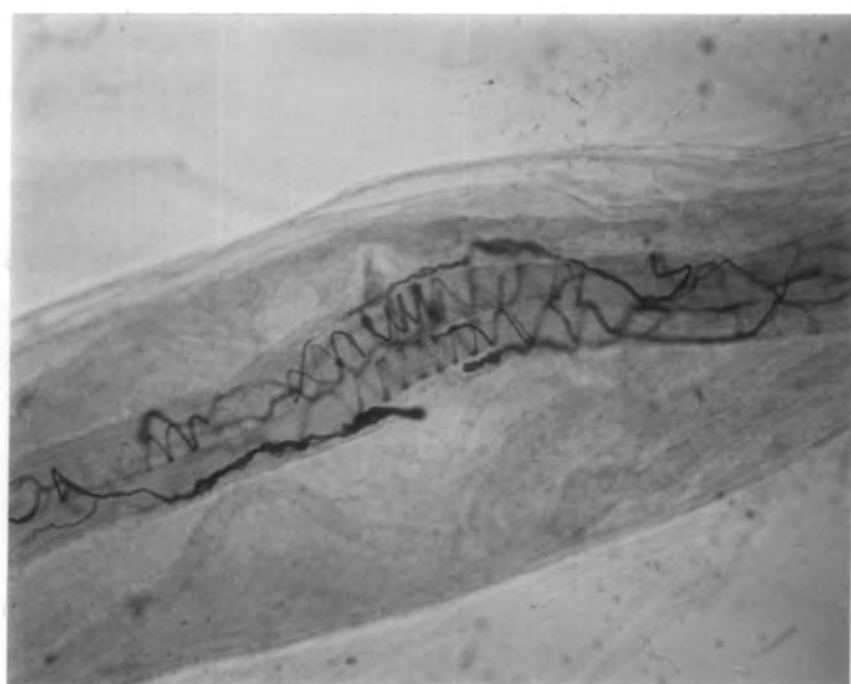Examples of silver staining.

- A) The primary region of a reinnervated spindle in the cat. The branching of the Ia axon can clearly be seen. Features of reinnervation which are present are: the small extent of the ending, and the scarcity of regular spirals or bands.
- B) The primary region of a normal spindle in the rabbit. Unfortunately, the supplying Ia axon has been torn off during the teasing process, but the regular spiralling of the primary ending is evident.



A

50 μ m



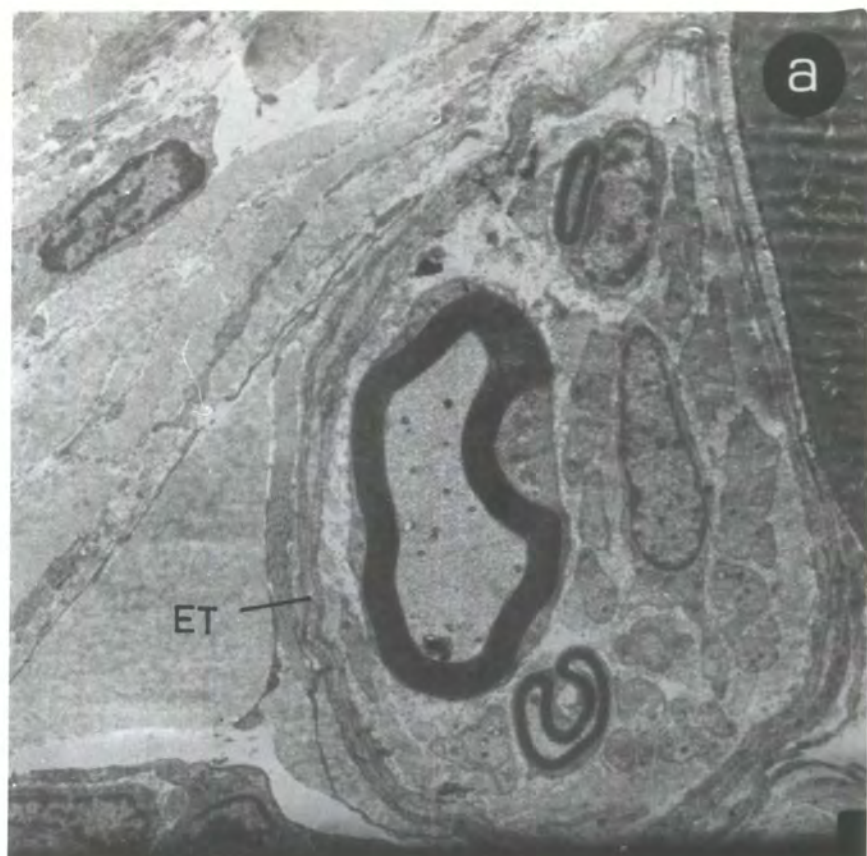B

50 μ m

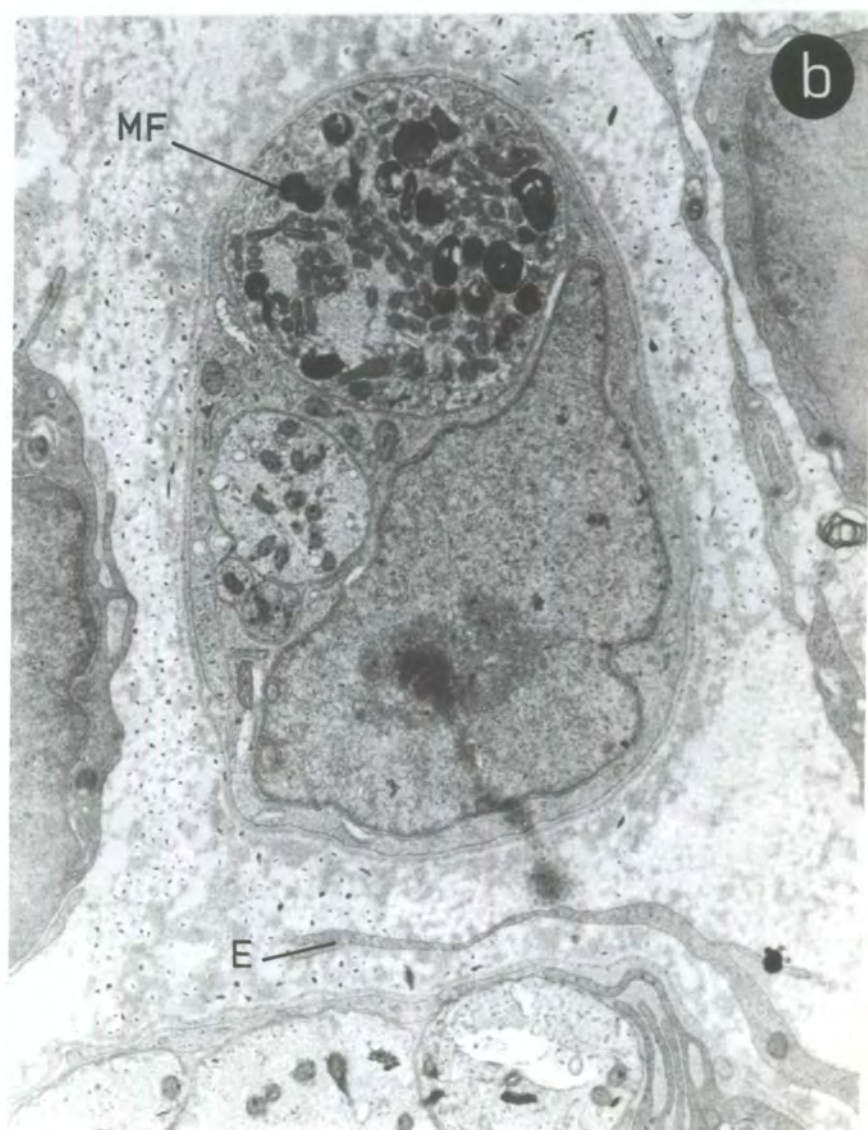
Plate 3.1

A. T.S. of the peroneal nerve 5 weeks after the crush operation, taken distally to the site of the lesion. It can be seen that three myelinated and several non-myelinated axons are all contained within one endoneurial tube (et).

B. T.S. of the peroneal nerve one week after the peroneal crush taken slightly distally to the crush site. Myelin fragments (mf) are clearly visible indicating degeneration of the axon. It is noteworthy that the endoneurium (e) is not continuous around the axons and Schwann cell (c.f. Plate 3.1 A).



X 7000



X 22000

Plate 3.2

- A. The characteristic well ordered, wave pattern seen in longitudinal wax sections of peripheral nerve. This is taken from the peroneal nerve proximal to the nerve crush.

- B. A longitudinal section from the same nerve taken distally to the lesion. Amidst the debris of the degeneration process, very fine regenerating axons are present.

- C. The crush site (cs) can be seen clearly with its parallel arrangement of axons. The disorganised distal part of the nerve is shown below the site of the lesion.

- D. The presence of growth cones (gc) is detectable in the distal part of the nerve. Their most distal positions were measured from the crush site to calculate the regeneration rate of the fastest growing axons.

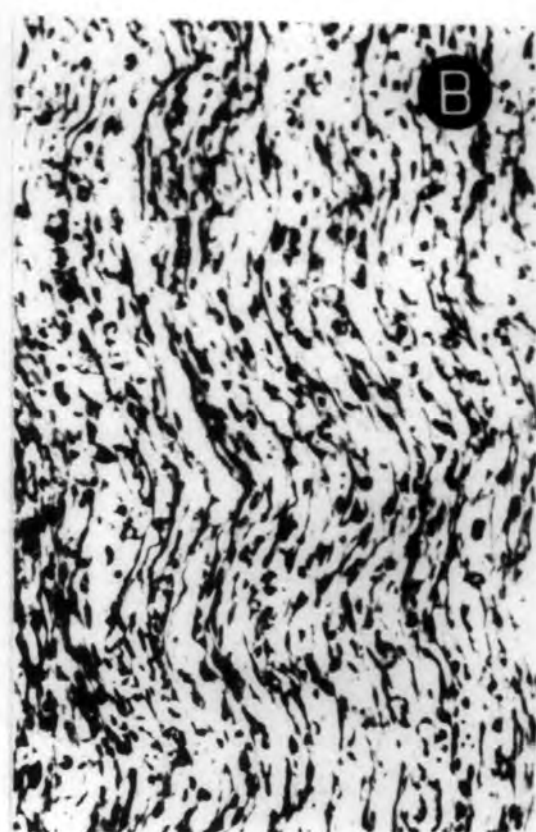

Plate 3.3

- A. Part of a primary ending in the form of a spiral around a chain fibre, after 11 days R.T. in P.L. muscle. Its supplying Ia axon has a diameter of 2.8 μm .
- B. The form of an early restoration of the primary ending to a bag₂ fibre in P.L. muscle after 11 days R.T. The ring may indicate that some abortive terminals may already be being resorbed. The equatorial nucleation in the bundle of intrafusal muscle fibres containing the bag₂ and chain fibres can be seen.
- C. The early restoration of a primary ending in P.L. muscle , 11 days R.T. Here the ending is distributed almost entirely to the bag₂ fibre.

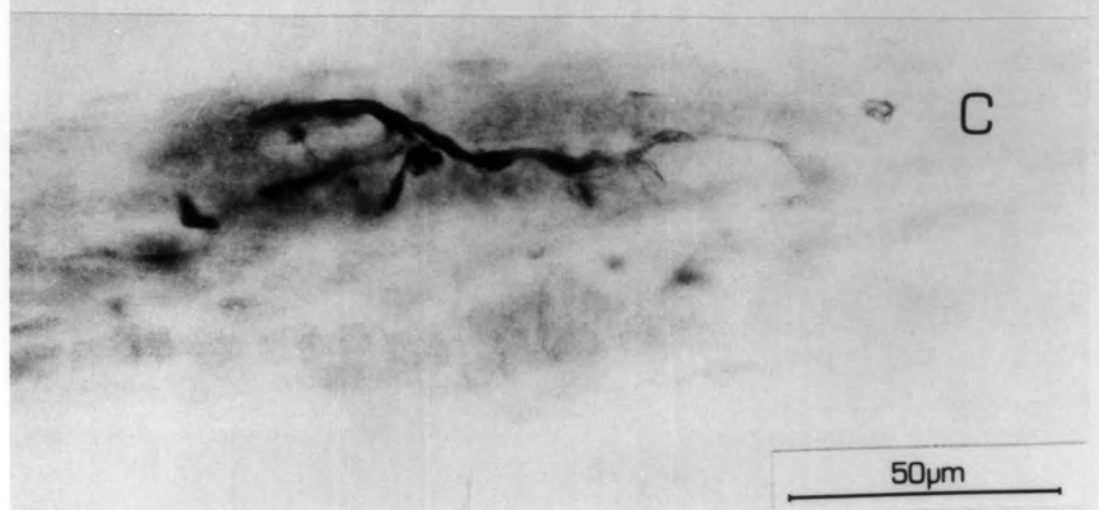
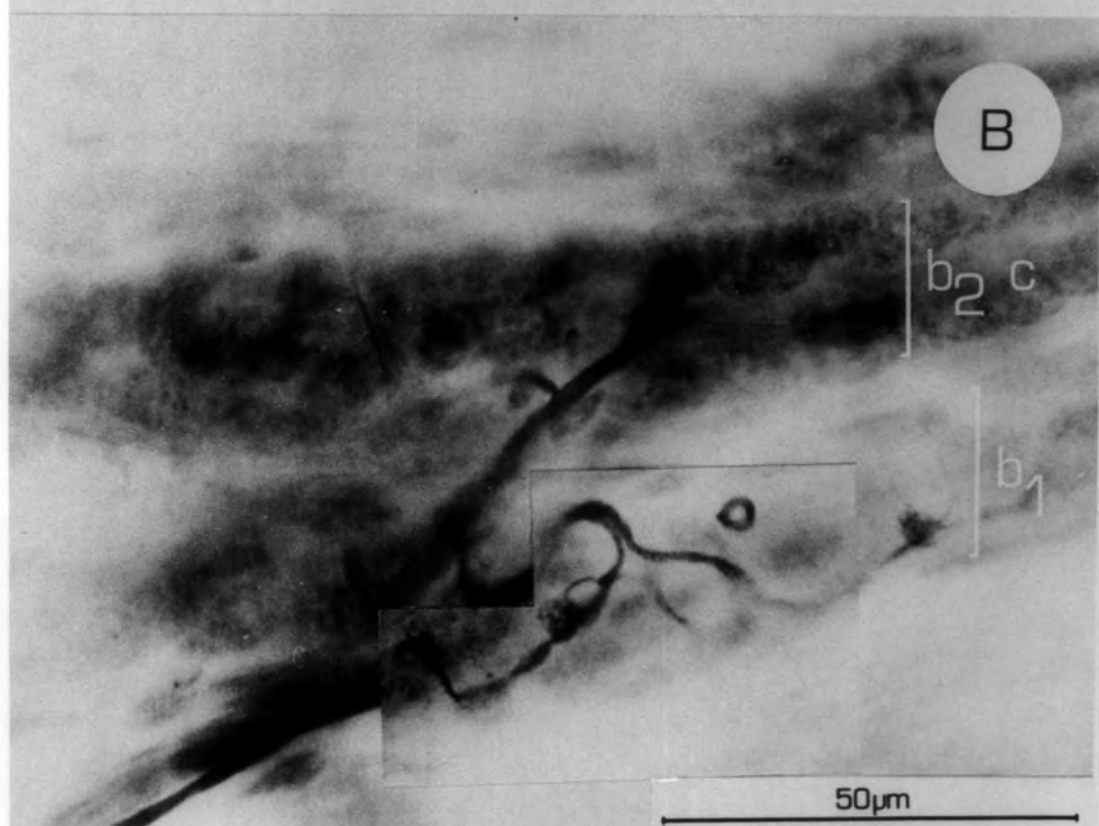
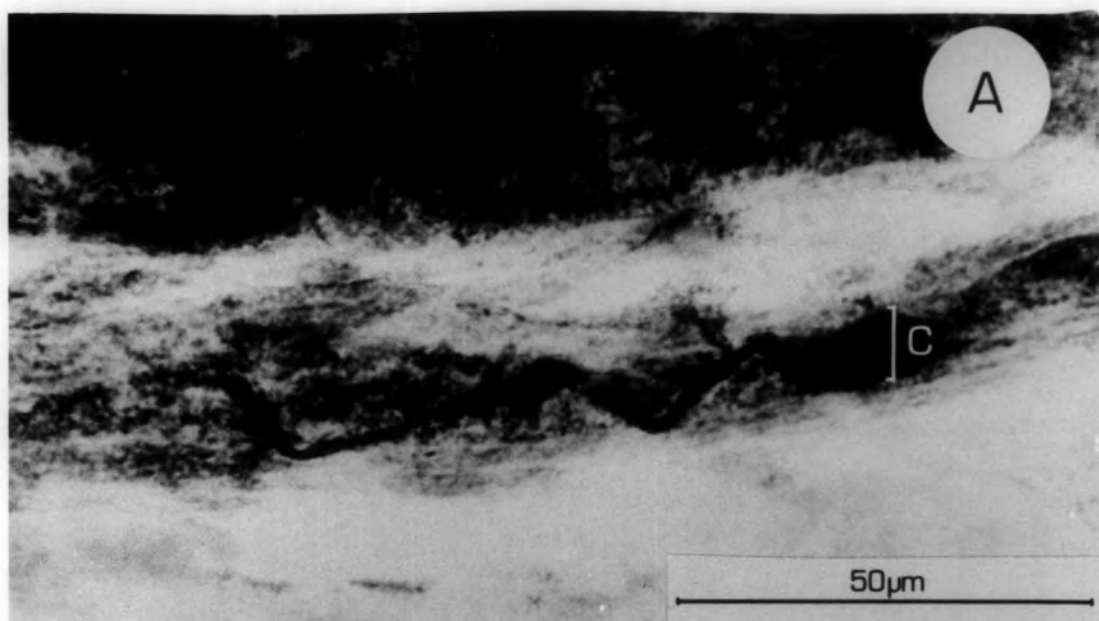


Plate 3.4

- A. Presumed sympathetic axon passing through the capsule of a spindle 21 days R.T.

- B. Axons which traverse the equatorial region without making contact with the intrafusal bundle, in the absence of reinnervation by Ia fibre.

- C. Examples of presumed motor axons which pass through the equatorial region before terminating in the poles. The arrow shows an axon which does not deviate from a straight course, whereas the axon which spirals round the intrafusal bundle can be seen clearly.

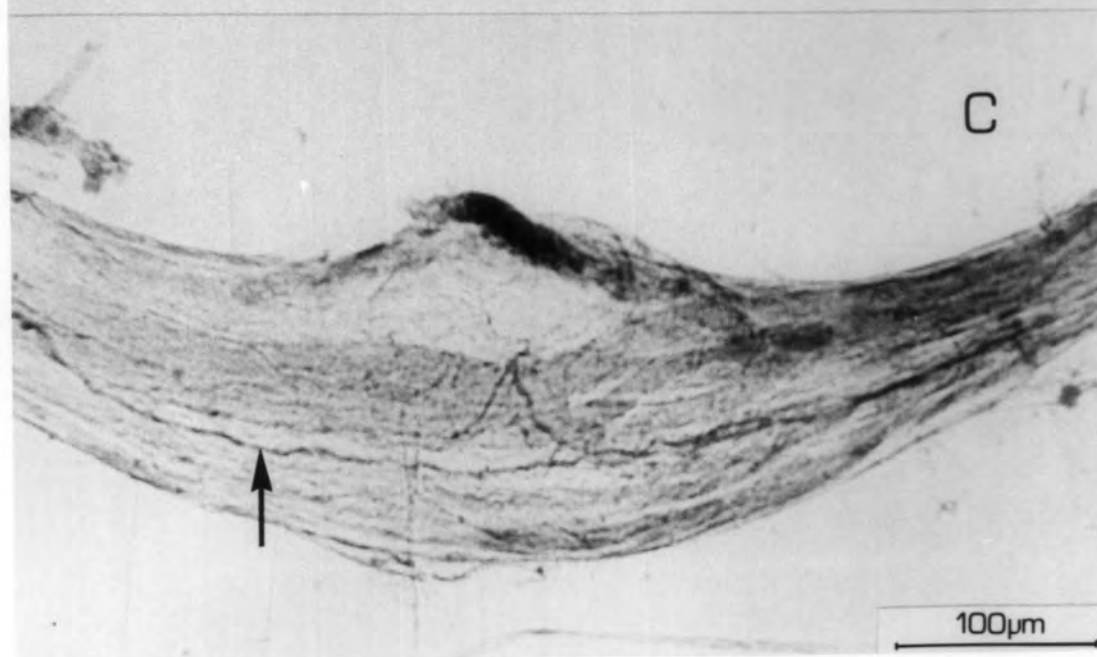
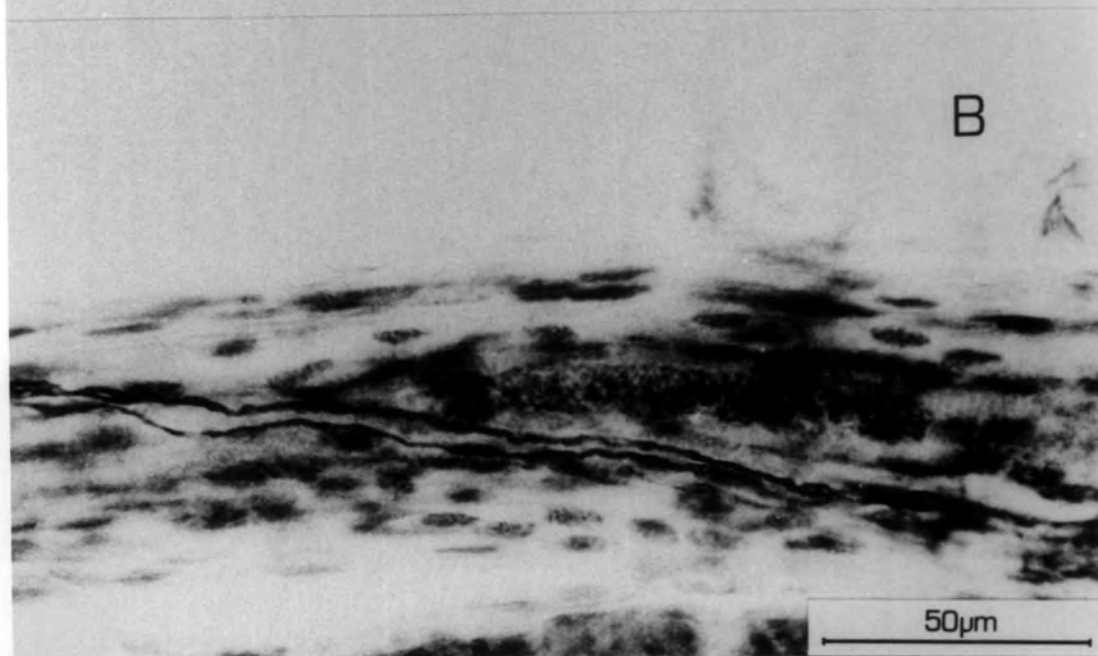
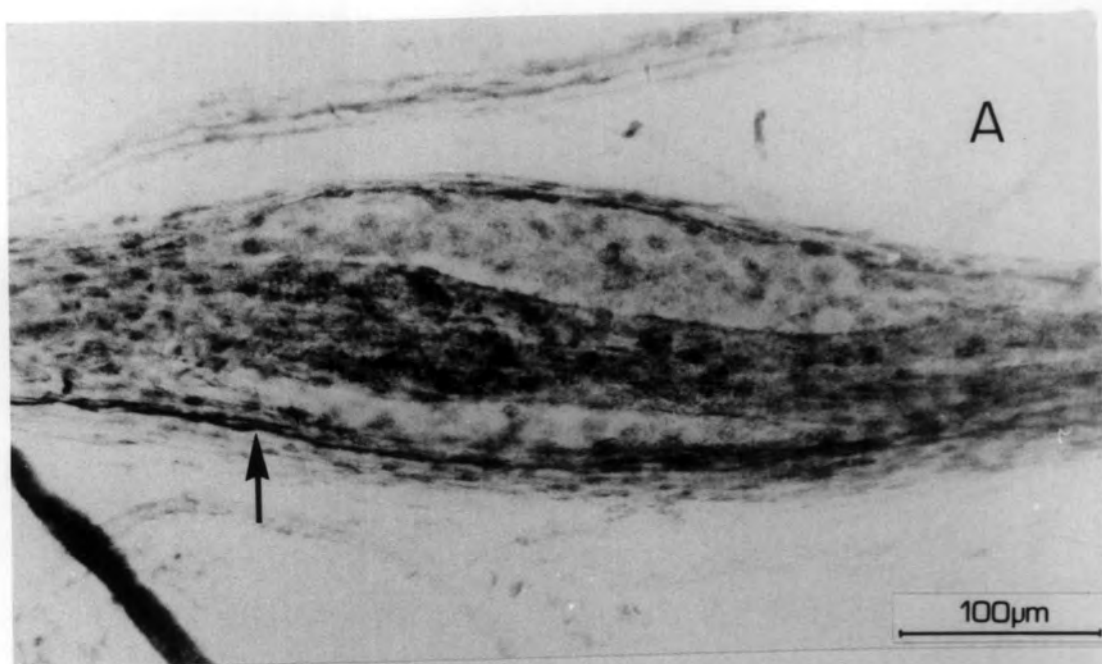


Plate 3.5

- A. The best restoration of a primary ending after 18 days R.T.
The terminal is distributed to bag₁, the upper of the two bag fibres marked , to bag₂, the lower, and to the chain fibres .
- B. An example of a more rudimentary primary terminal after 18 days R.T. No regular spirals can be seen.

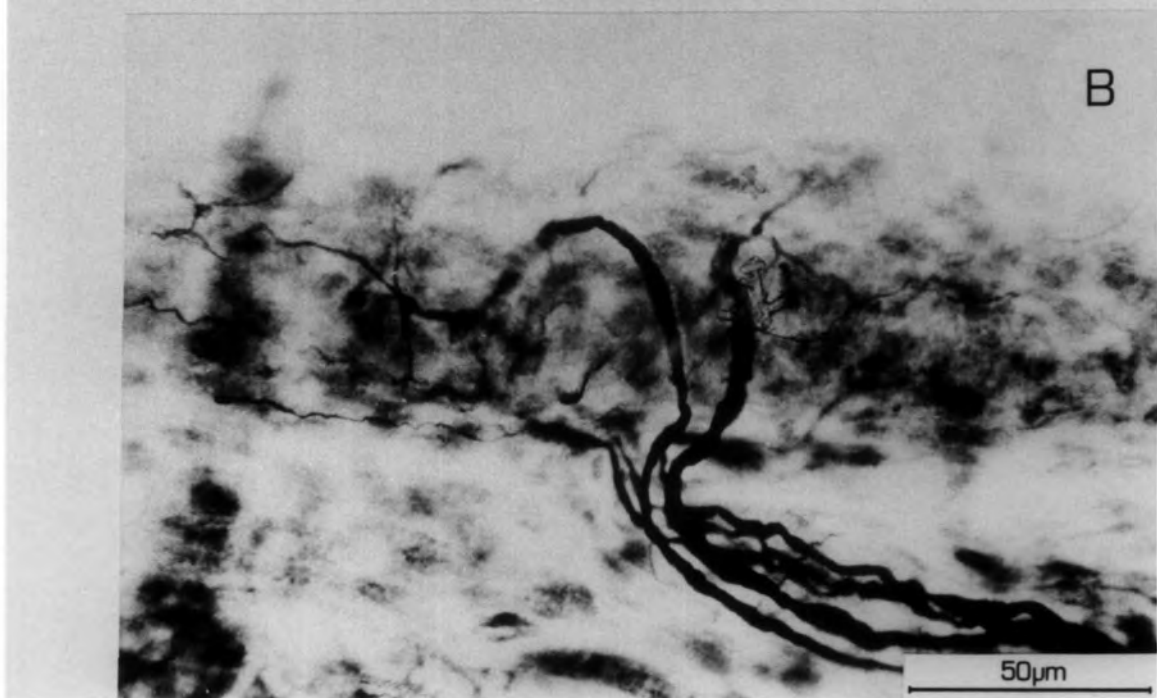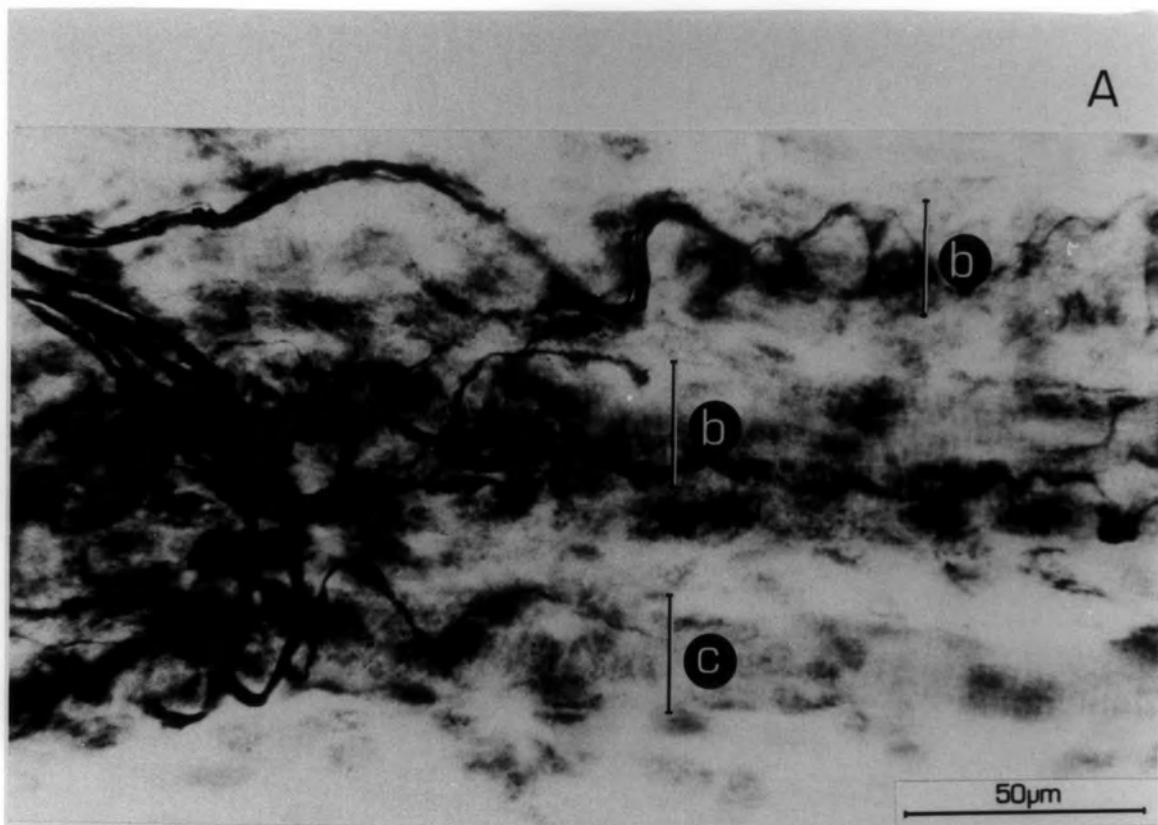


Plate 3.6

- A. A primary ending after 25 days R.T. The ending is well supplied to the bag₂ and chain fibres, and one of the bag₁ fibres, but the bag₁ fibre seen at the bottom right (arrowed) is excluded from the innervation.
- B. A primary ending after 186 days R.T. The separation of the bag₁ fibre can be seen. The spirals on both bag fibres are more widely spaced than normal.

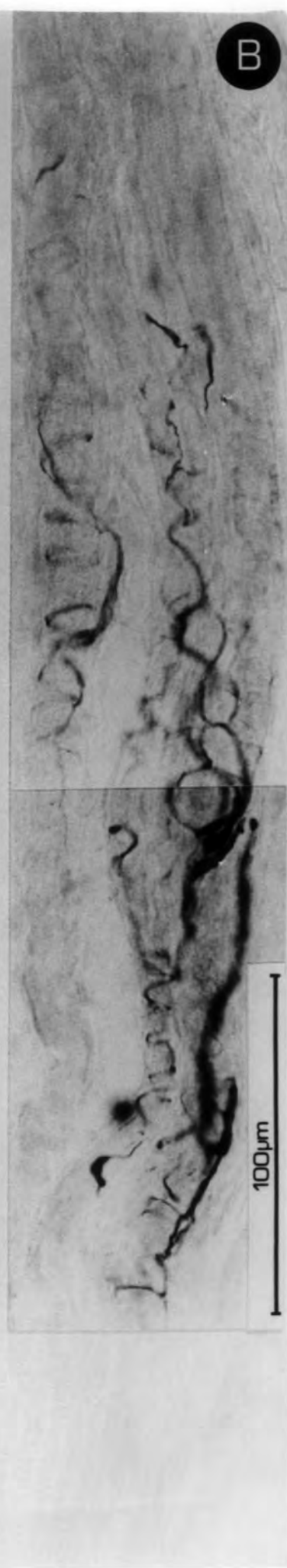
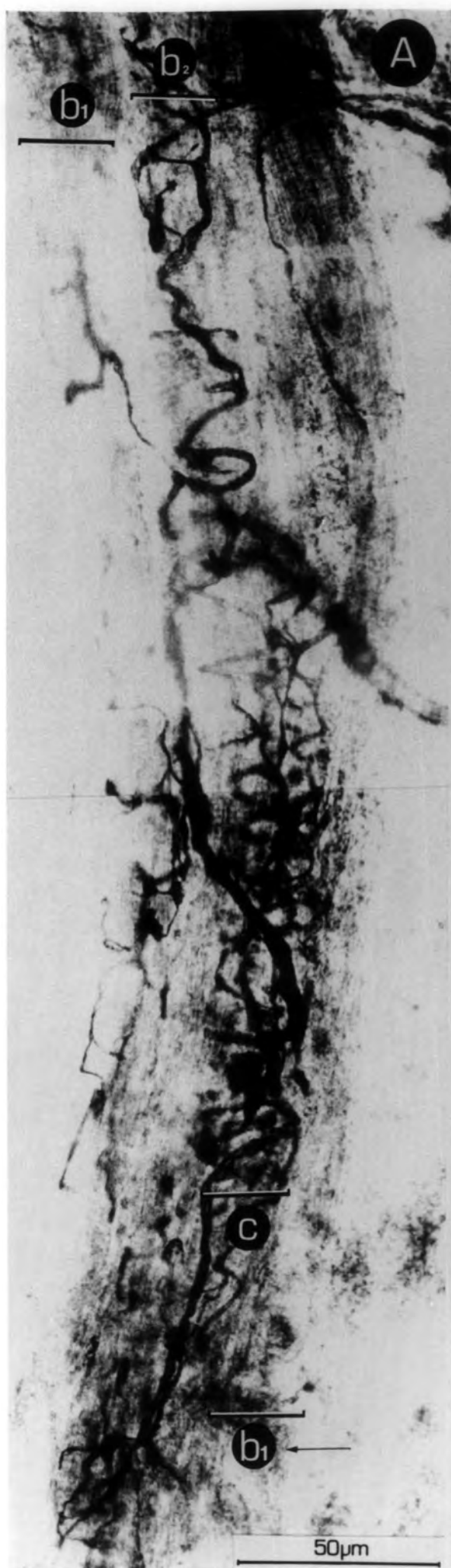
Plate 3.7

- A. A primary ending after 25 days R.T. It can be seen that the regular spirals of the normal spindle primary have not formed, although separate bag and chain systems are present.

- B. Another primary ending after 25 days R.T. Again separate bag systems are discernible but the disordered nature of the ending can be seen.

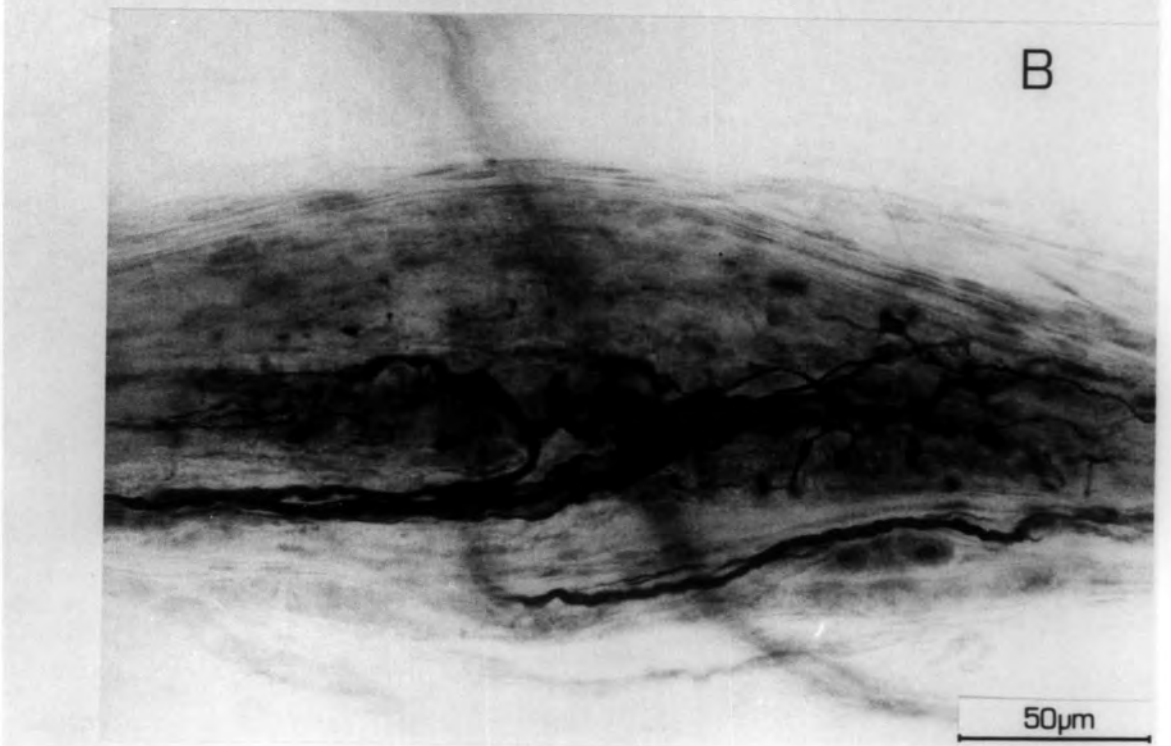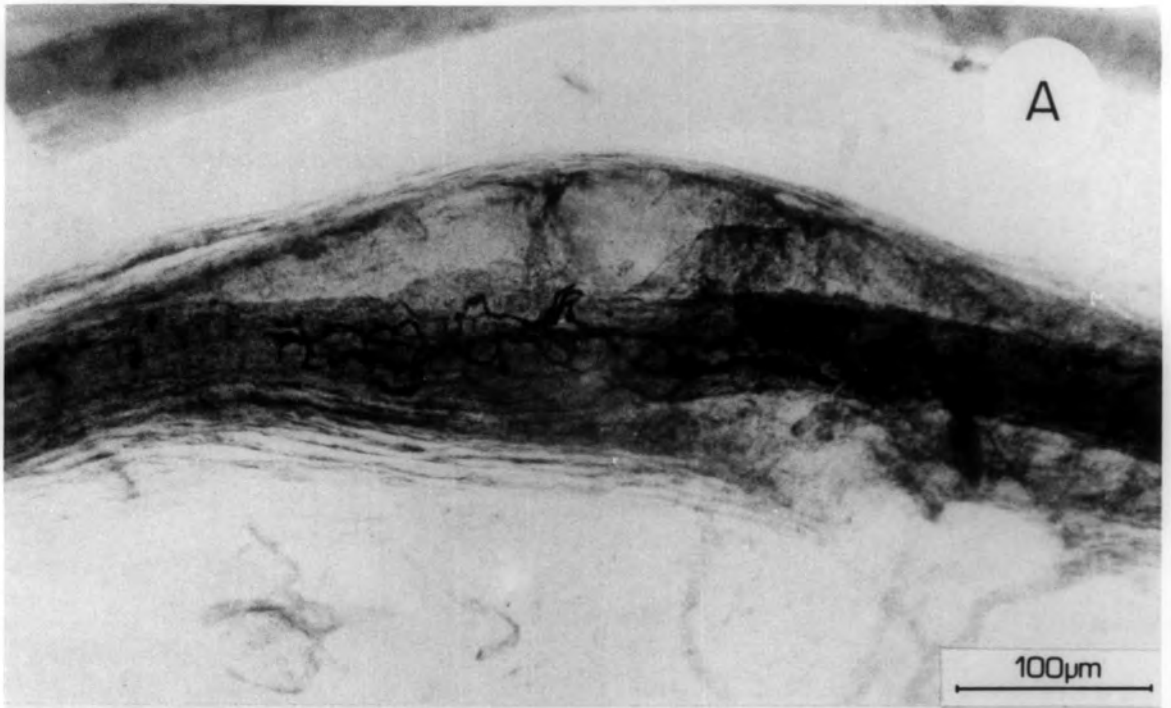


Plate 3.8

- A. A well restored primary ending after 39 days R.T. Regular spirals can be seen on both bag and chain fibres.
- B. Primary restoration after 53 days R.T. The equatorial nucleation is well stained in the separate bag₁ fibre, and it can be seen that the innervation is confined to this region.
- C. Part of a double primary after 130 days R.T., showing the separate bag₁ fibre with spirals more widely spaced than normal.

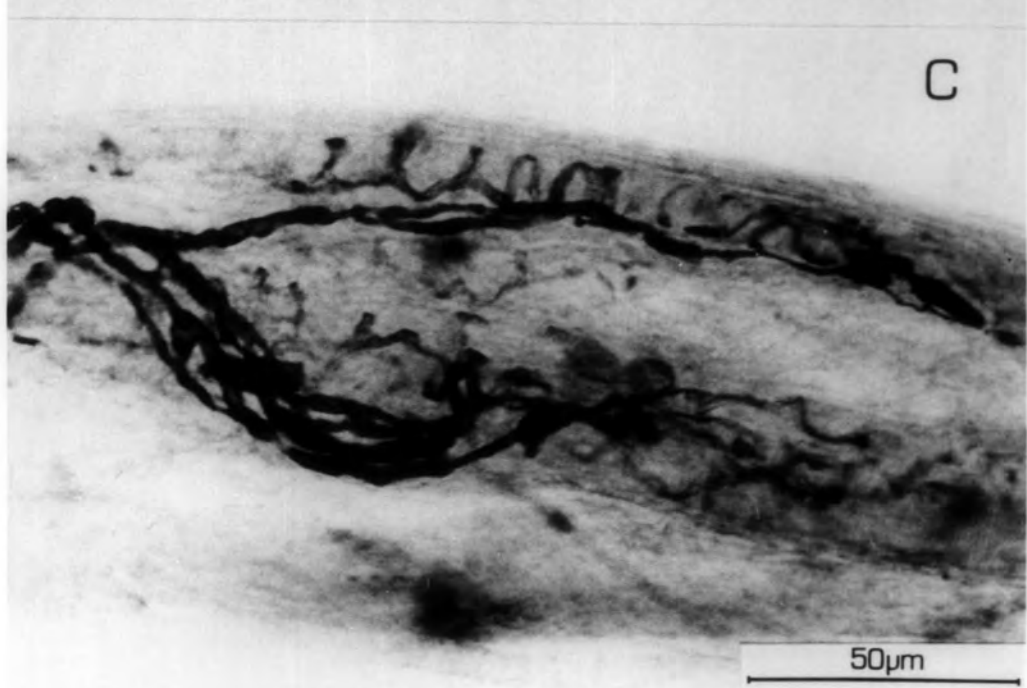
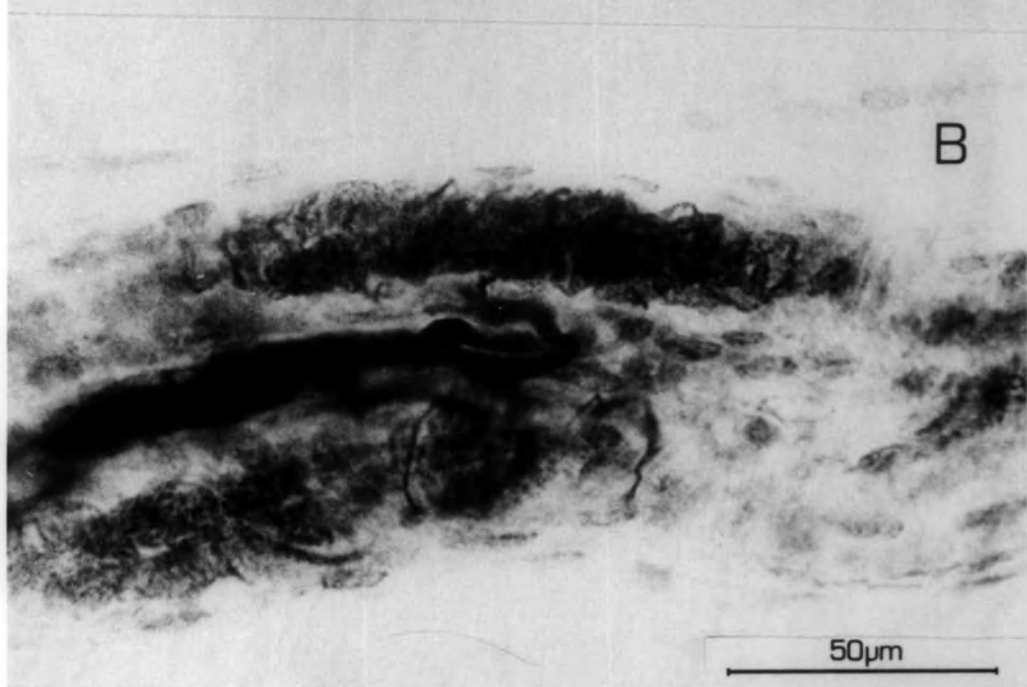
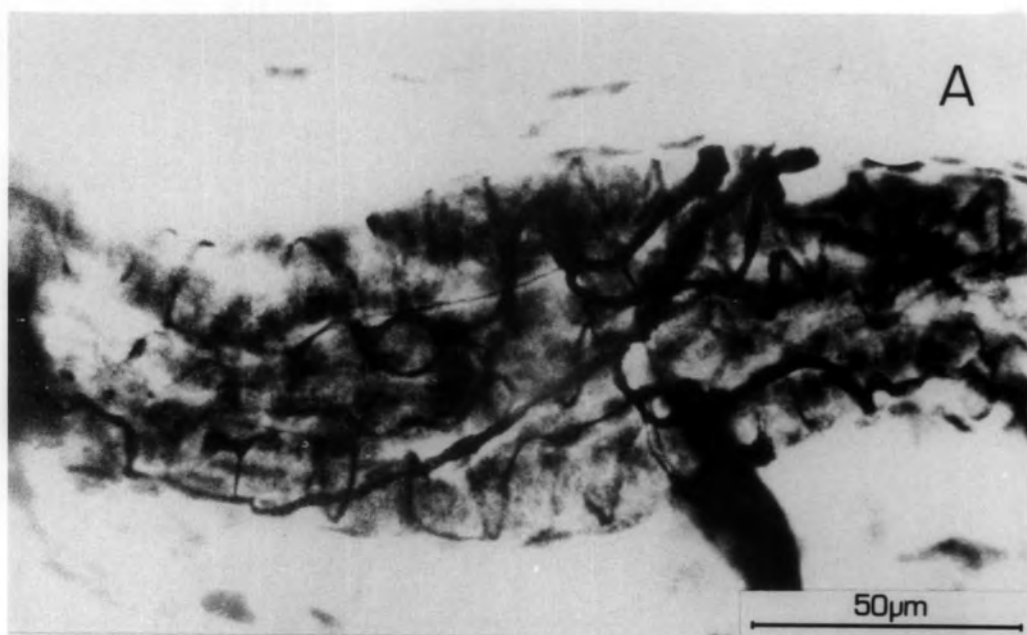


Plate 3.9

- A. Aberrancy in a primary ending after 120 days R.T. The lozenge-shaped swelling seen between the lines is situated on a chain fibre.
- B. A successfully regenerated primary after 240 days R.T. The spirals are regular and distributed to all the intrafusal muscle fibres, although the ending is not as extensive on the bag fibres as normal.

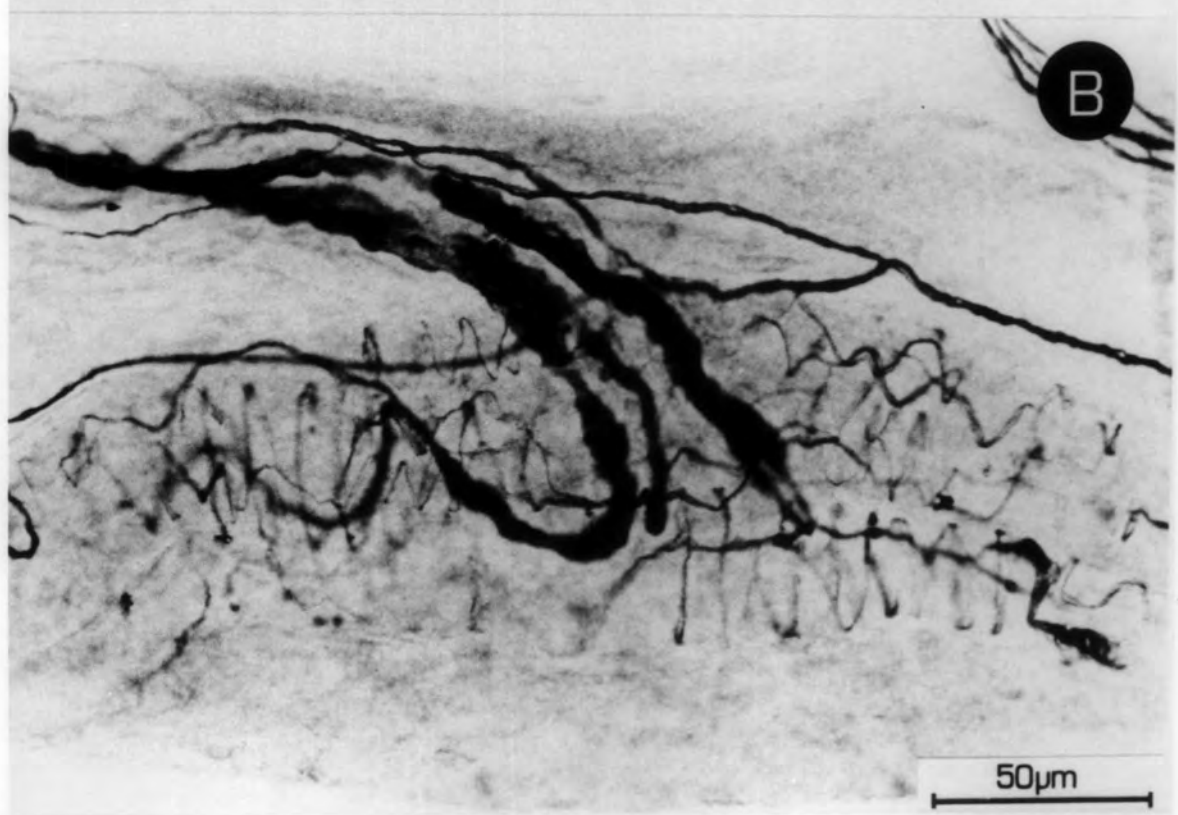
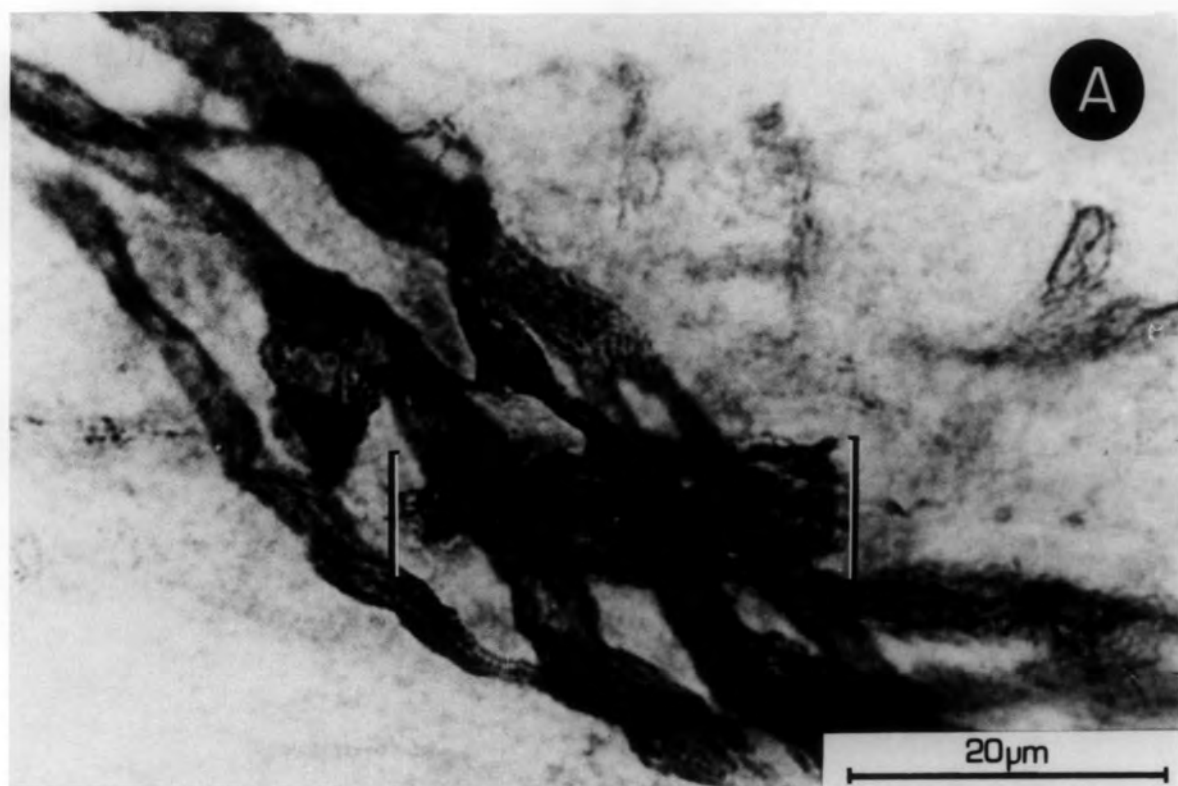


Plate 3.10

A well-restored primary ending , 240 days R.T. It is supplied by three Ia axons all separate as far back into the nerve trunk as can be traced. Regular spirals can be seen in the centre of the terminal. All the fibres of the intrafusal bundle receive an innervation which is normal in appearance.

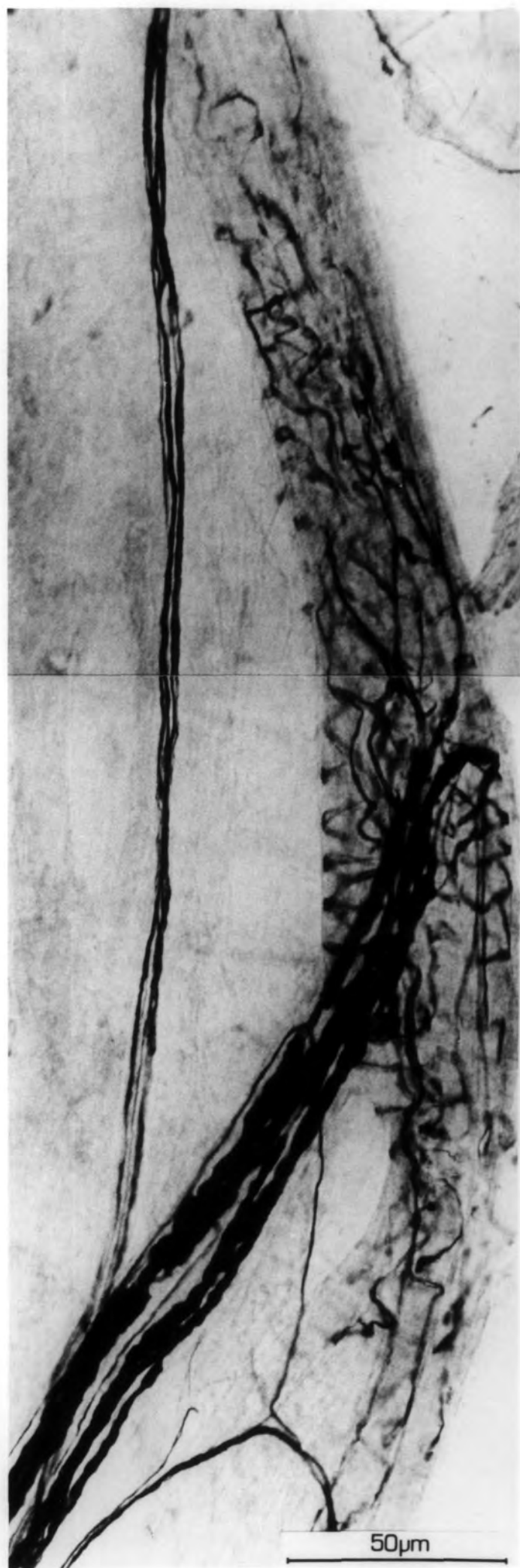


Fig. 3.1

Graph of the return of Ia fibres, expressed as the percentage of spindles receiving this innervation, against the reinnervation time in days.

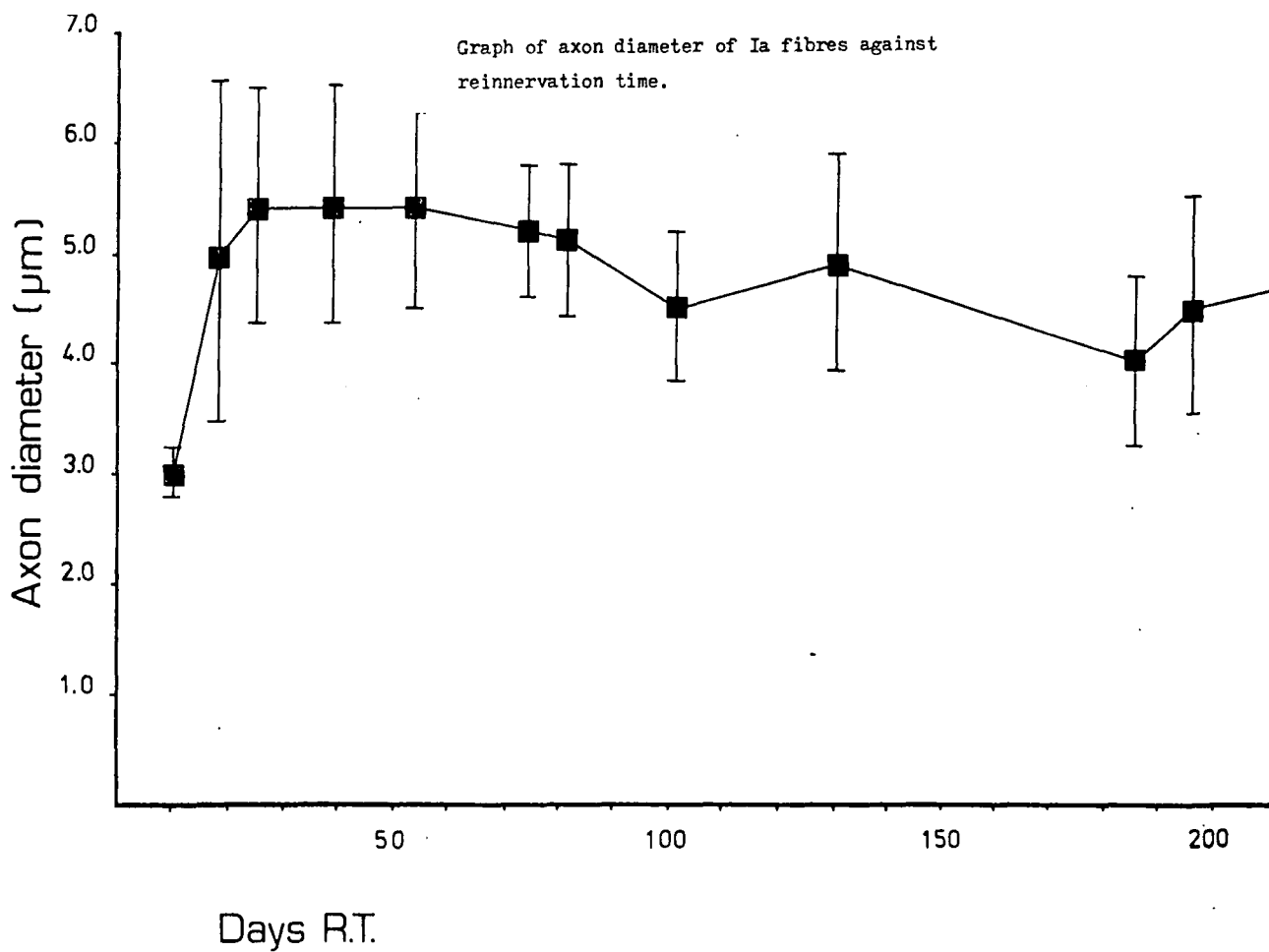
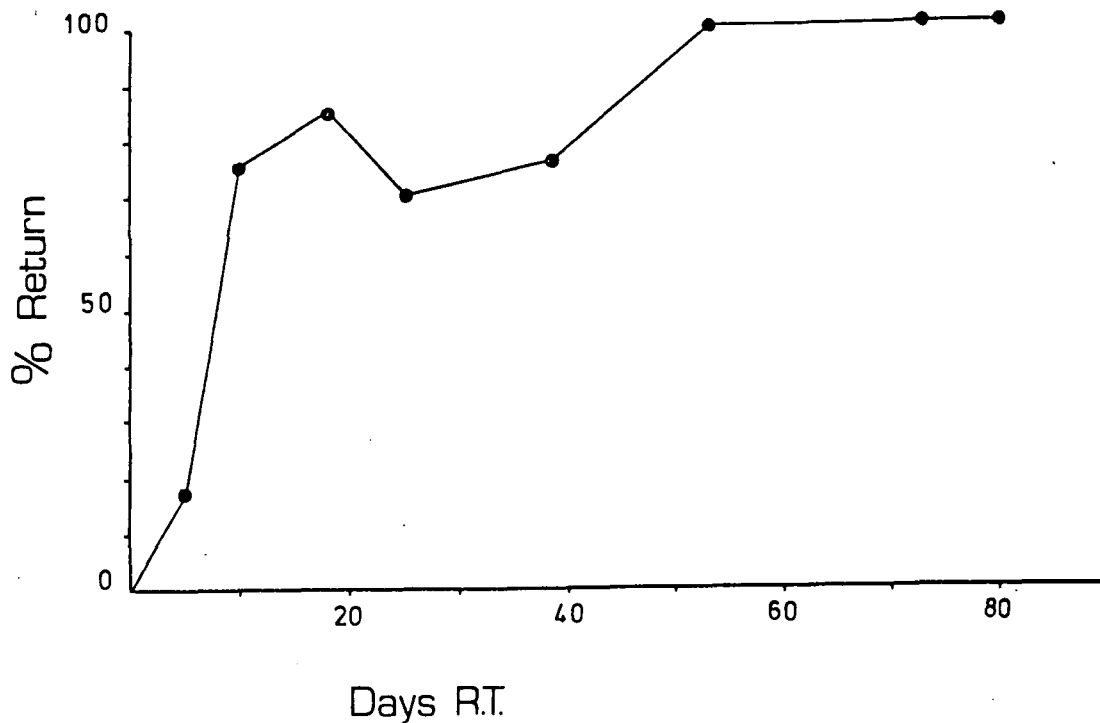


Plate 3.11

- A. Trichoidal formation on a spindle 186 days R.T. These are present on many spindles and can obscure the terminals. They are presumably formed by numerous branchings of individual motor axons.
- B. Node of Ranvier on a Ib axon present in P.L. muscle 102 days R.T. This plate shows the well-developed myelin sheath at this stage and the difference in diameters measured at the node to measurements taken over the sheath.
- C. Axons supplying the primary ending of a spindle 102 days R.T. One thick axon is accompanied by three more of smaller diameter.
- D. Capillary accompanied by a ^{presumed} sympathetic axon in P.L. muscle 11 days R.T.

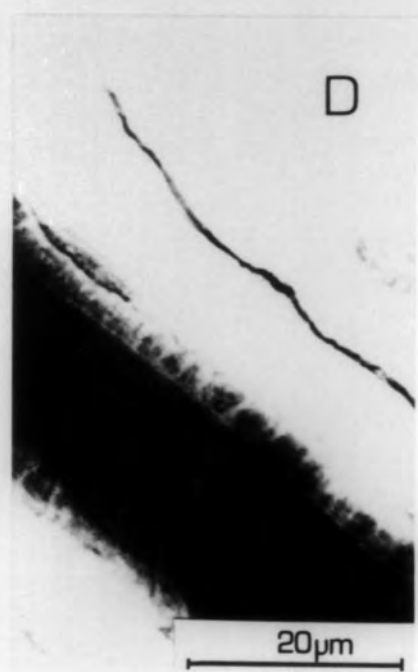
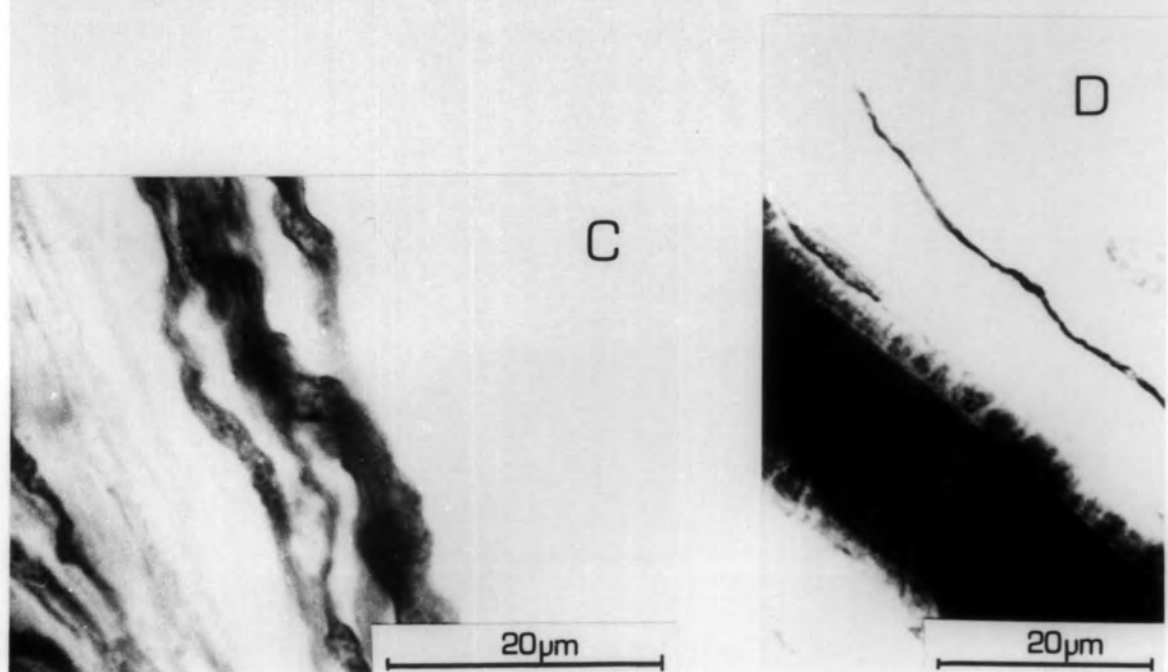
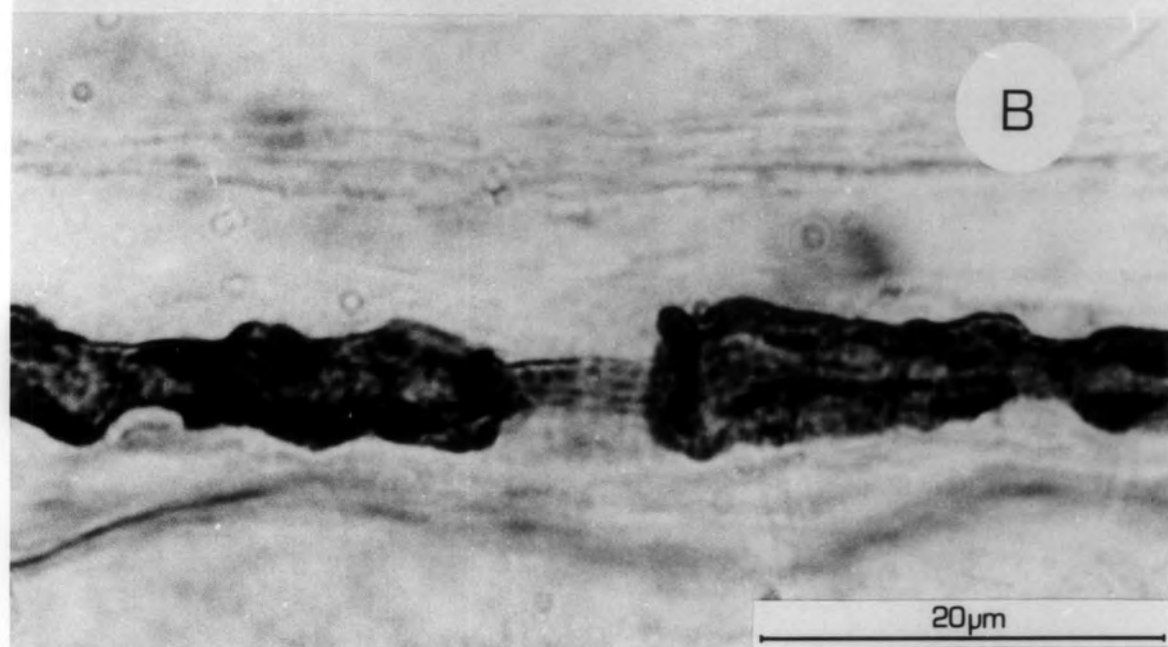
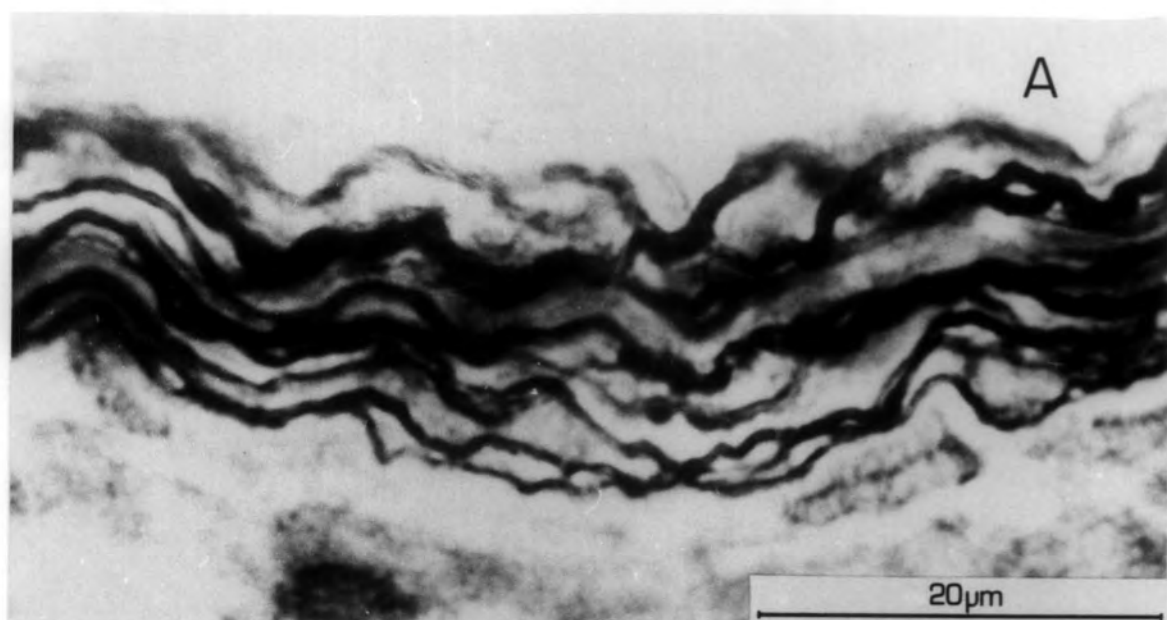


Plate 3.12

A & B

Seven presumed motor axons enter the equatorial region in the absence of a primary ending, and terminate in club-shaped or spherical swellings, both in the region of equatorial nucleation (arrow y) and in the myotube region (arrow x). 18 days R.T.

C.

Another example where seven presumed motor axons enter the equatorial region and form spheres, clubs and brush-like endings in the region of equatorial nucleation. 18 days R.T.

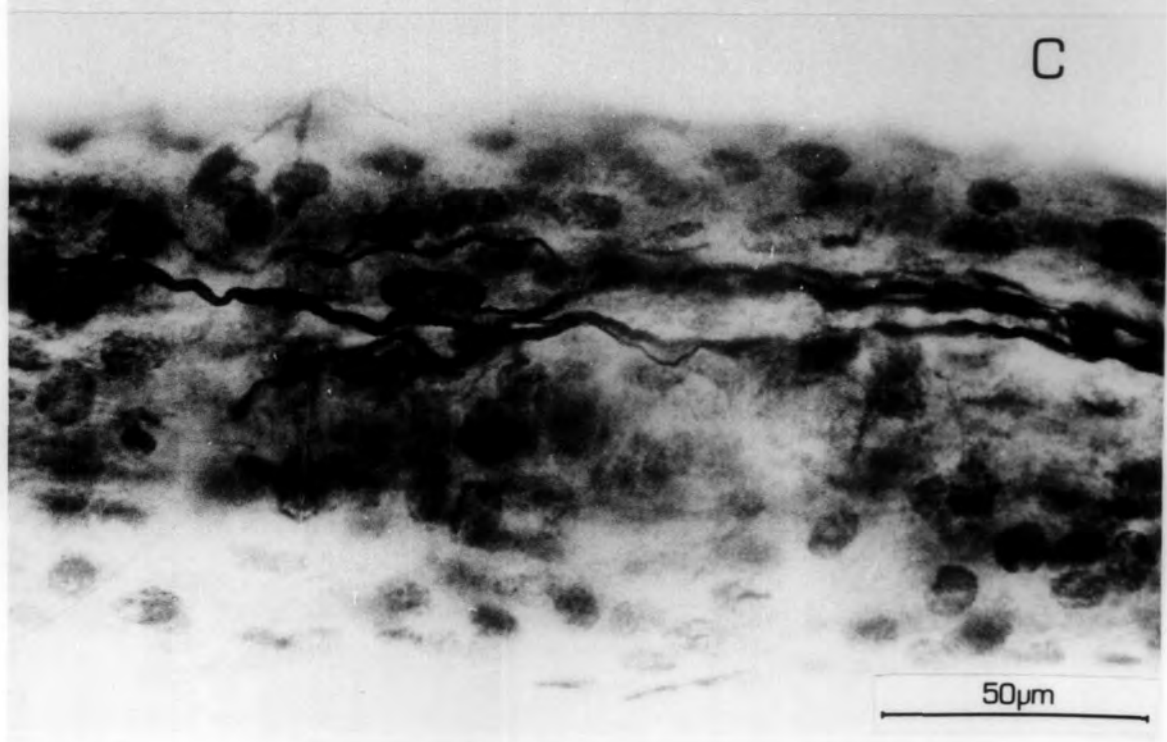
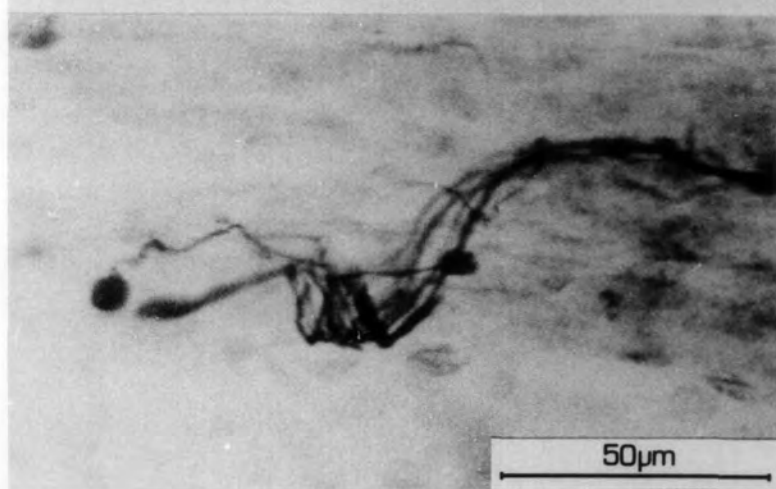
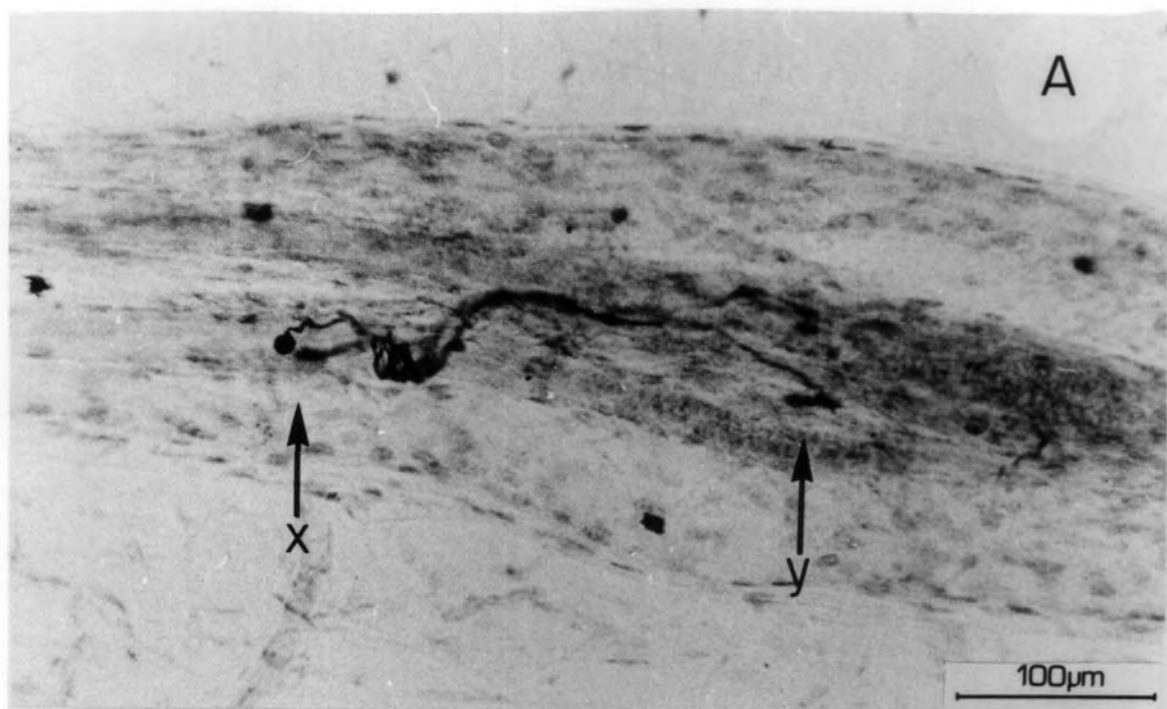


Plate 3.13

A. Examples of terminal lozenges and rings formed by presumed motor axons in the juxtaequatorial region after 25 days R.T.

B. A sphere formed by a branch of an axon which enters the equatorial region and terminates in a spray-like ending on a bag fibre. The main axon however leaves the spindle after having made an abortive ending in the pole. 25 days R.T.

C&D. Examples of terminal swellings and rings from presumed motor axons in the myotube region of a spindle. 25 days R.T.

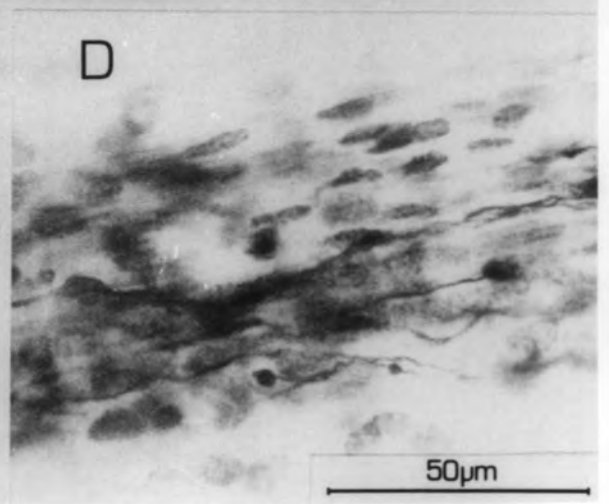
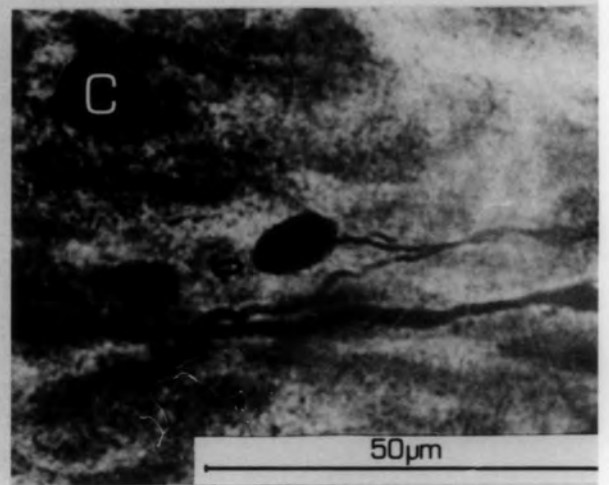
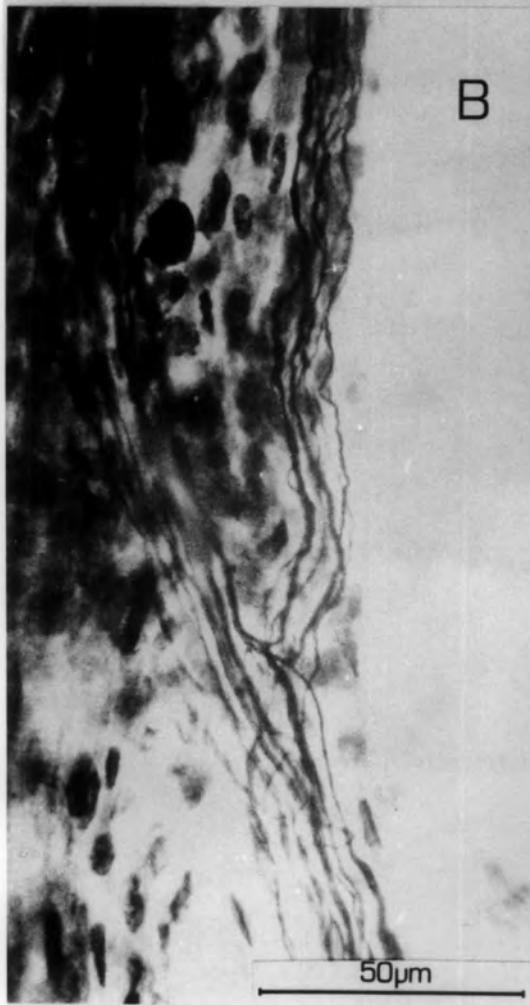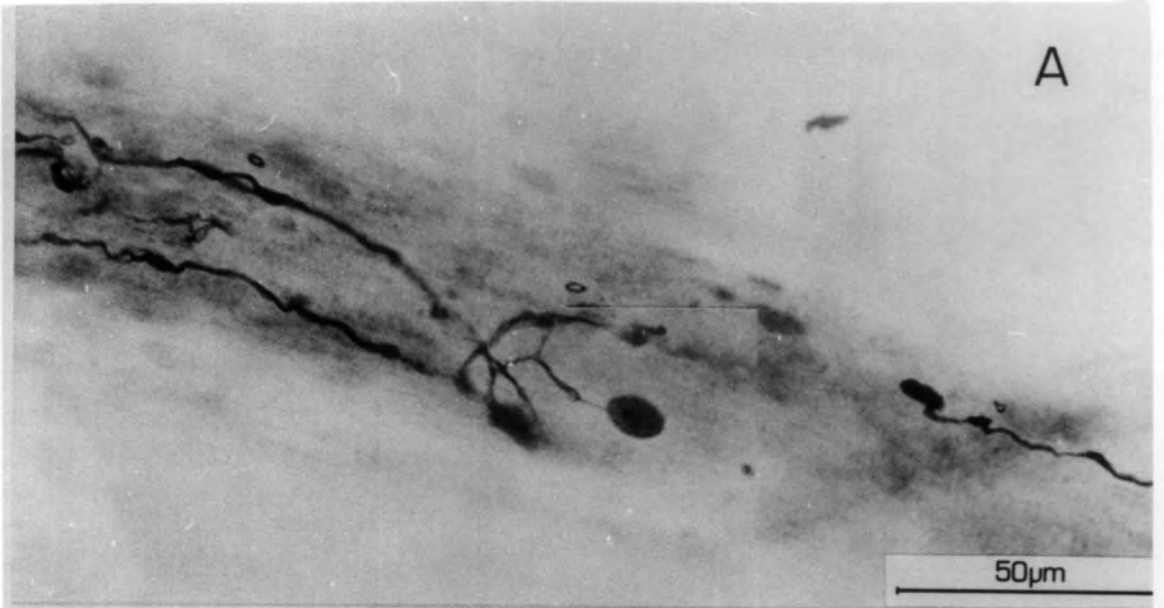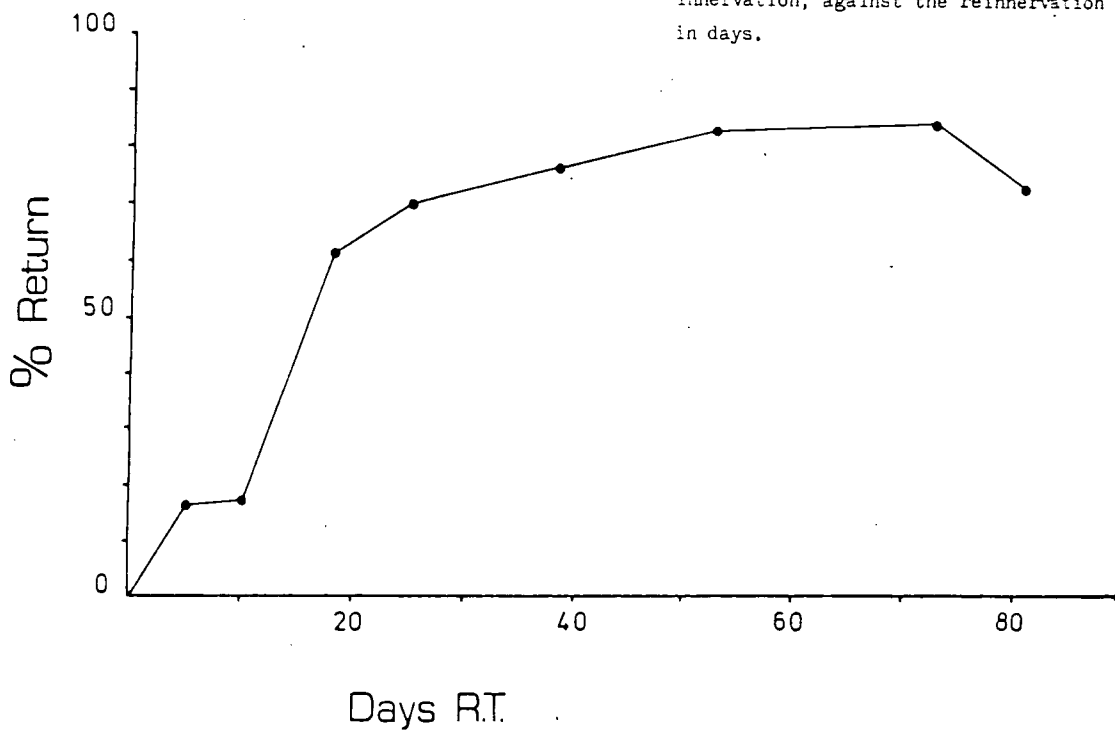


Fig. 3.2

Graph of the return of II fibres, expressed as the percentage of spindles receiving this innervation, against the reinnervation time in days.



Graph of axon diameter of II fibres against reinnervation time.

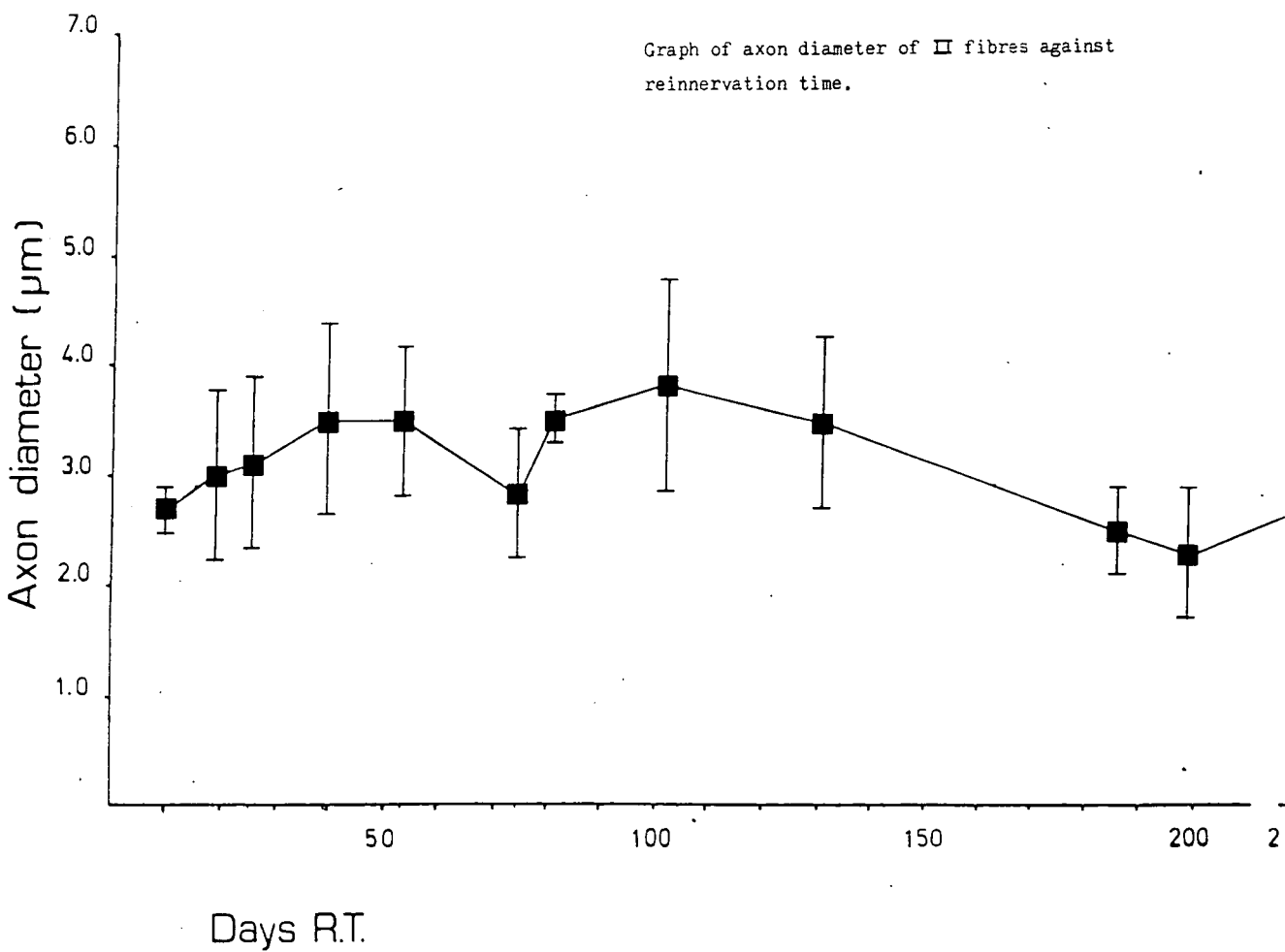


Plate 3.14

- A. An early example of a secondary ending after 18 days R.T. The extent of the terminal is shown. Very few elaborations can be seen.

- B. Part of a secondary ending distributed to a bag fibre, after 25 days R.T. The annulospiral form is not in evidence. A Ia fibre which divides into five branches is present.

- C. The typical form of a restored secondary ending. It has sparse terminals which are spray-like in form and is not greater than 200 μm in extent.

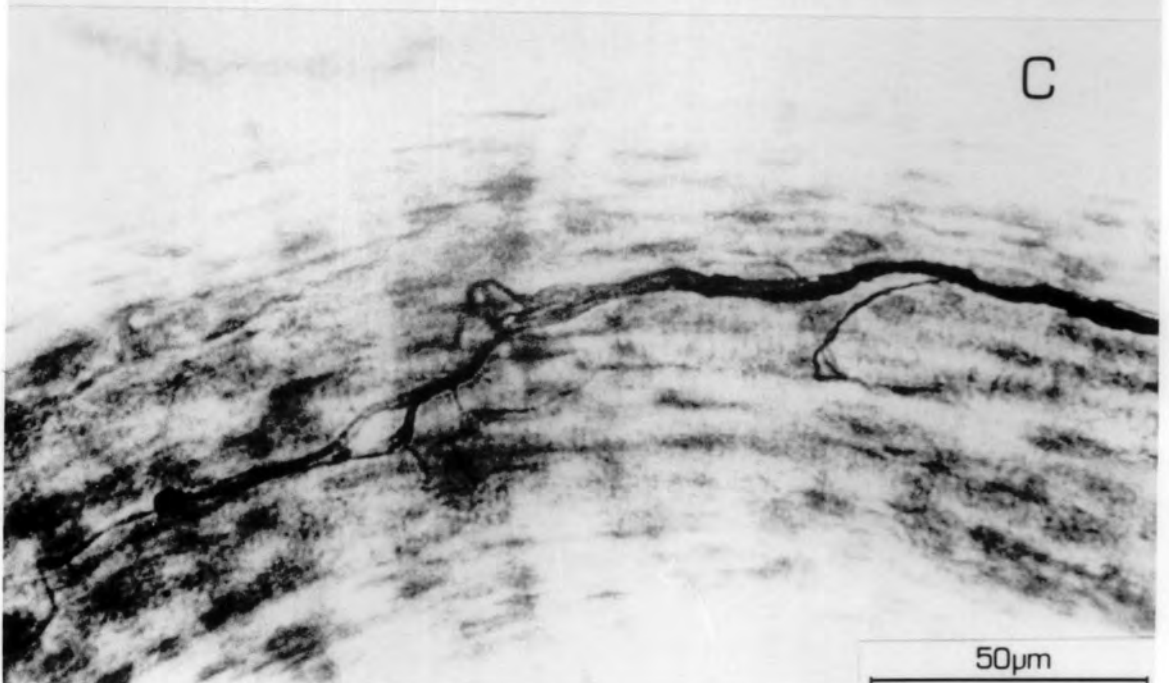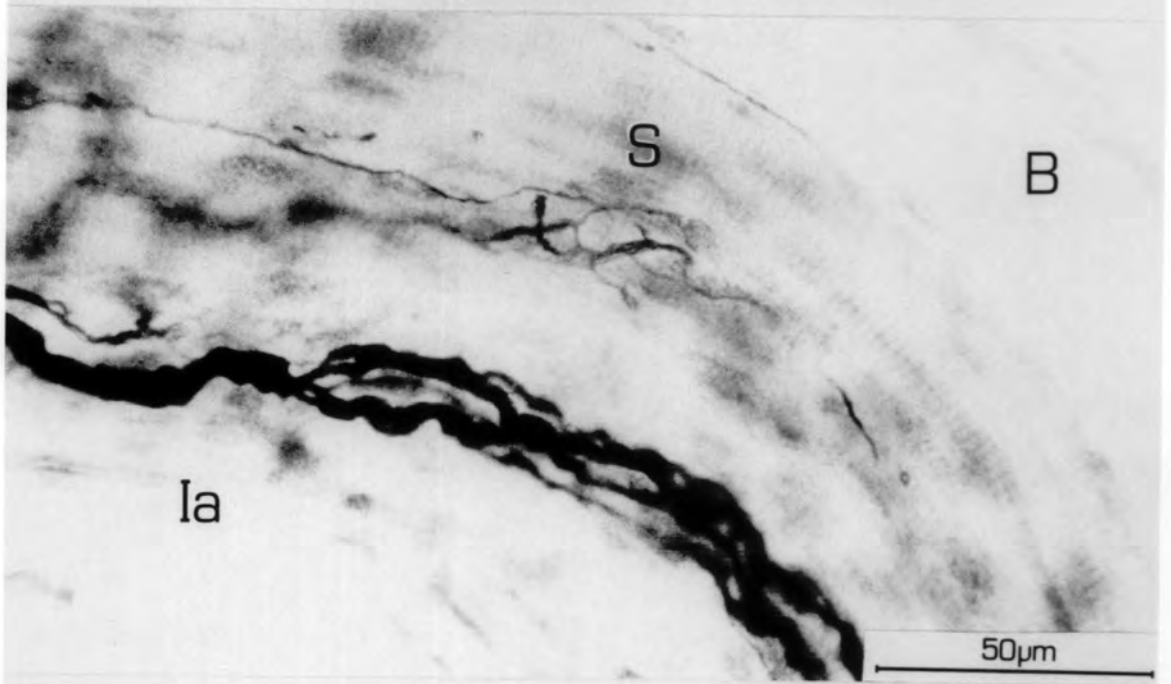
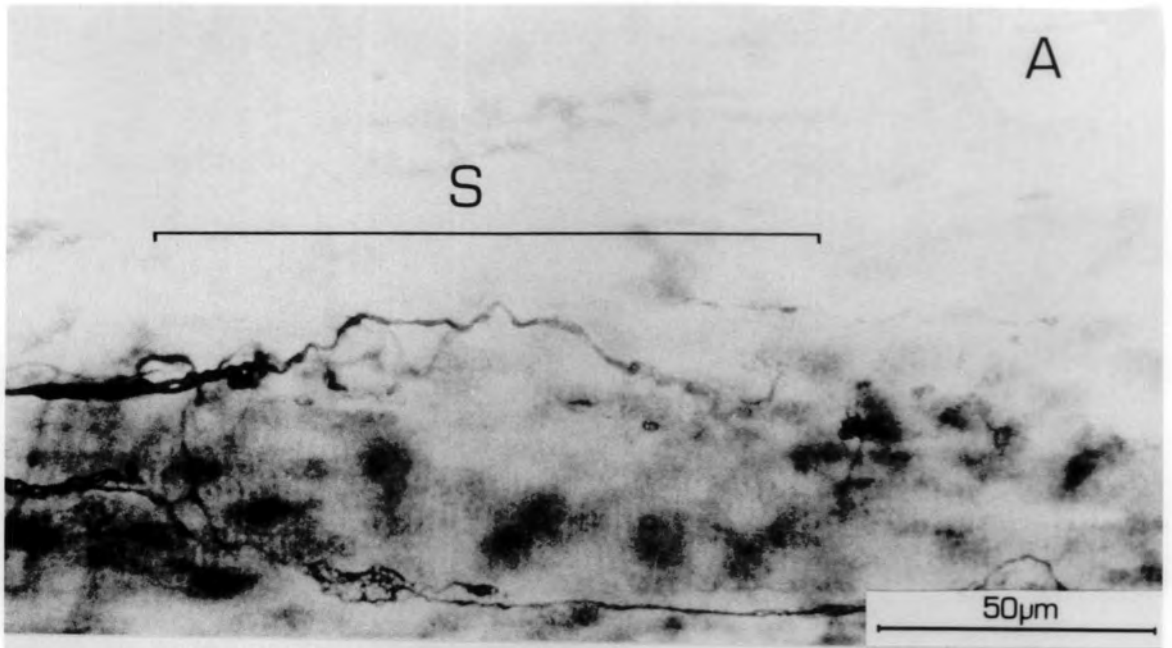


Plate 3.15

- A. A secondary ending after 25 days R.T. On the left, part of a primary ending is shown. This is well-restored and stained. The extent of the elaborations of the primary terminal contrasts sharply with those of the secondary.
- B. A secondary ending 39 days R.T. The extent of the ending is very small, less than 50 μm , and shows no spirals.

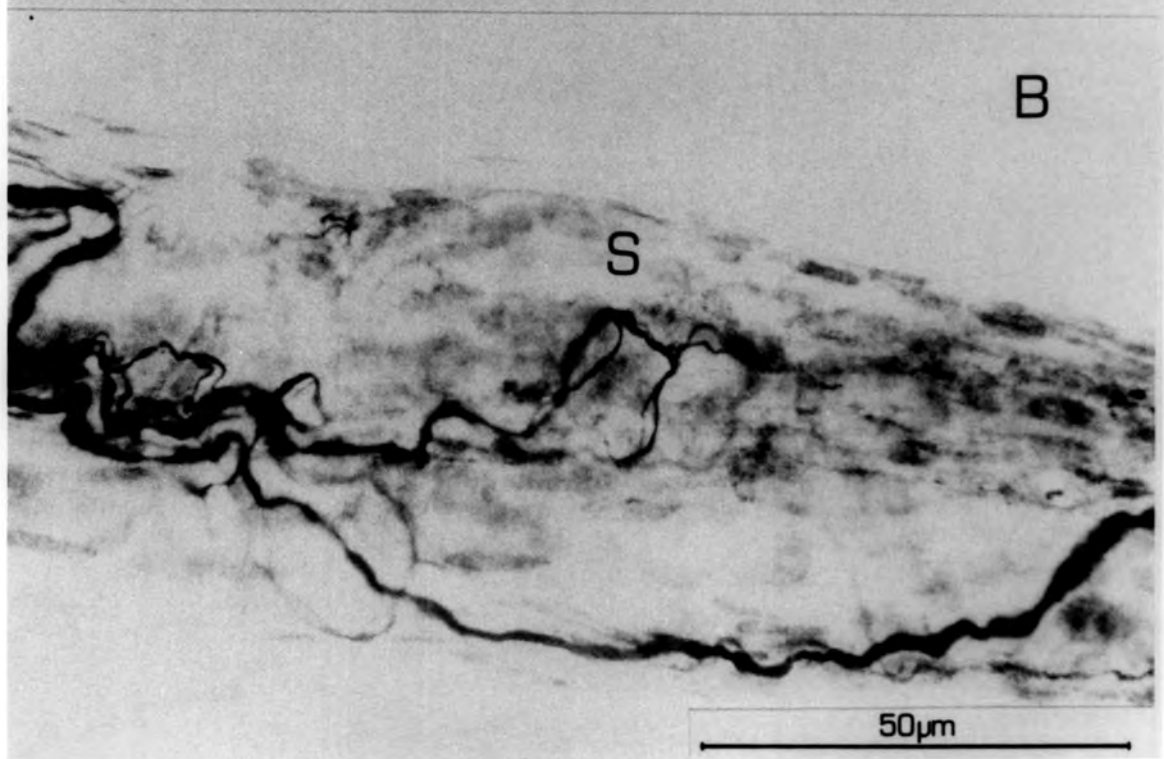
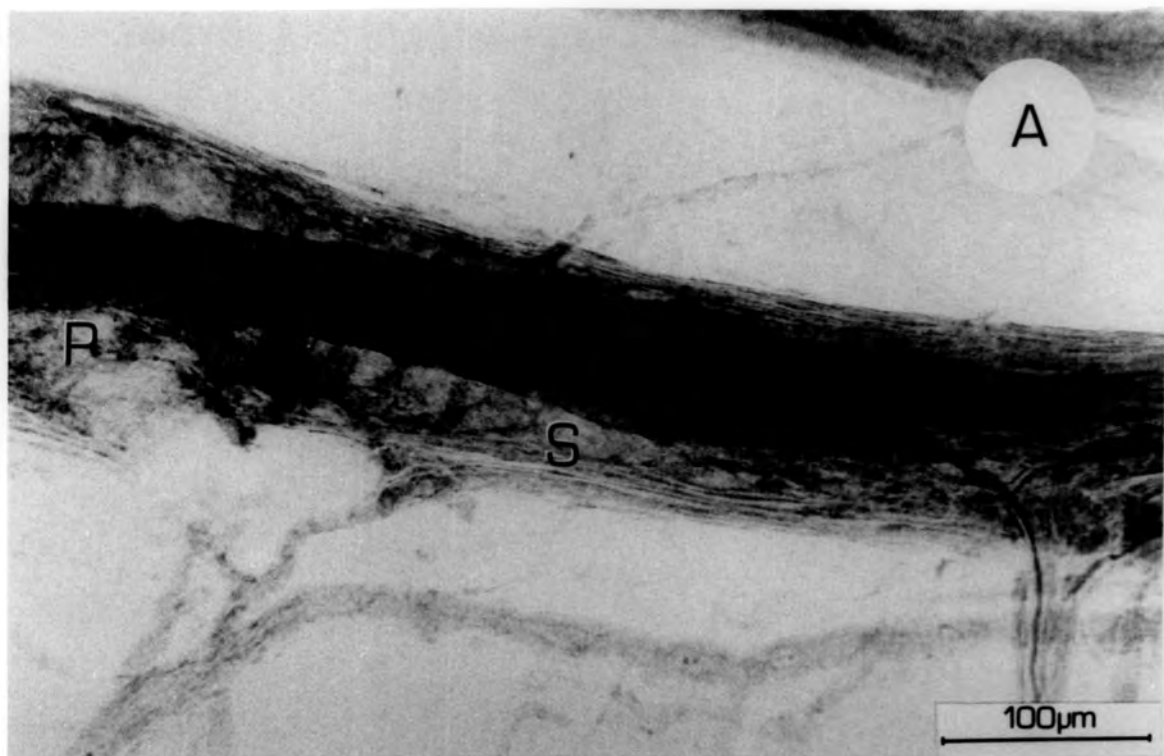


Plate 3.16

Examples of extrafusal endplates after different periods R.T.

A-C

Extrafusal endplates after 11 days R.T. showing axons starting to branch in the sole plate.

D, E & G

Extrafusal endplates at 74, 53 and 39 days R.T. respectively. The ending is elaborating at 39 days R.T., but at 53 days and 74 days, the endplate has a normal appearance.

F. An extrafusal endplate after 39 days R.T. showing the hooked and club-like swellings indicative of degeneration.

H. An extrafusal endplate in profile, showing the axon growing into the sole plate.

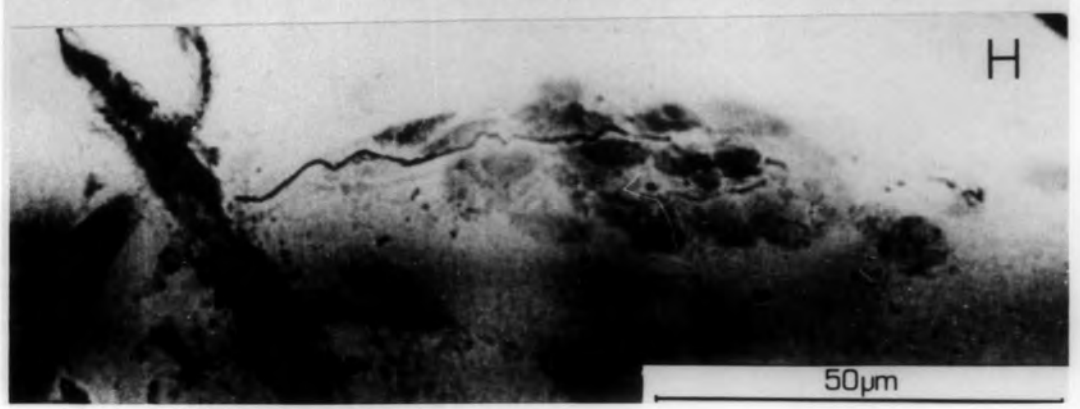
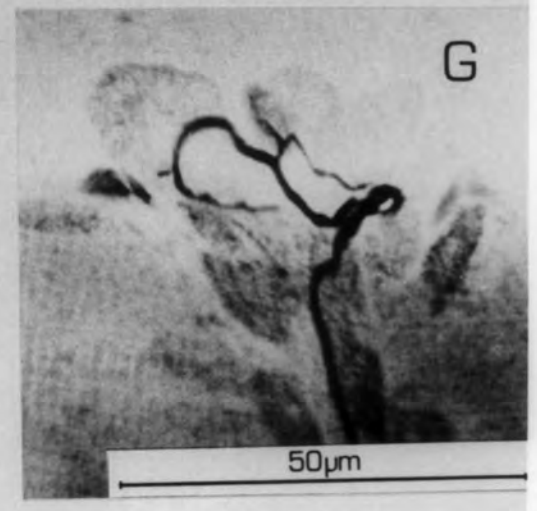
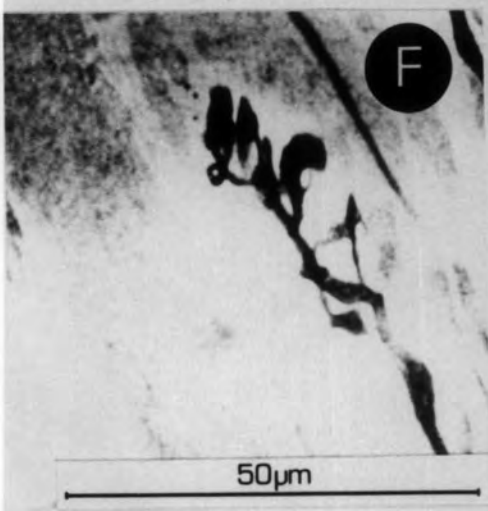
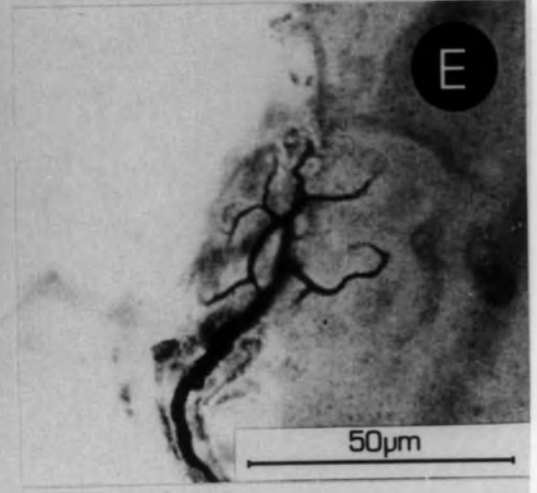
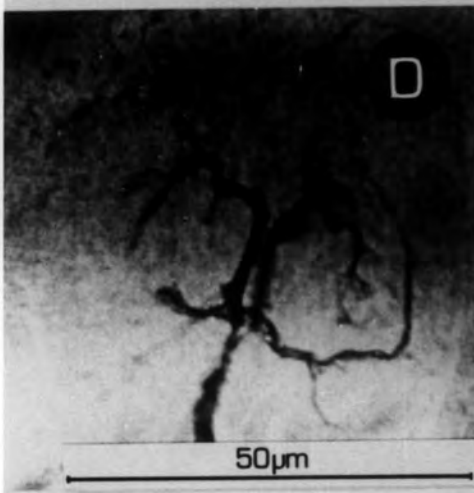
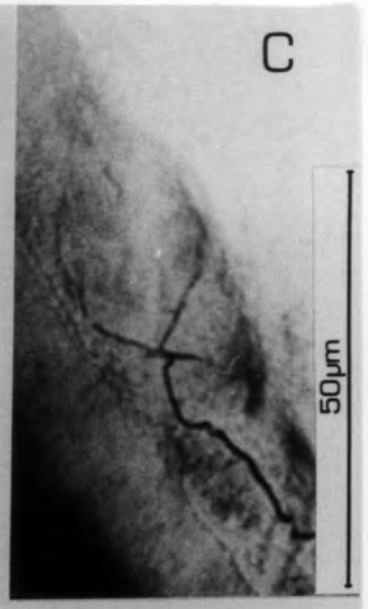
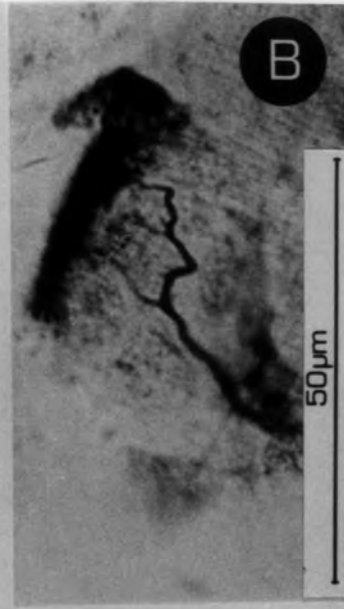
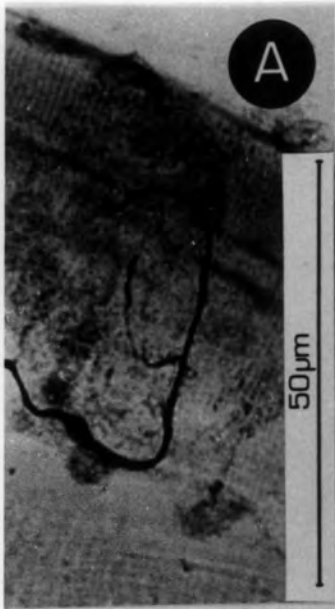Plate 3.17

- A. A pair of p_1 plates showing early signs of reinnervation after 5 days R.T. The axons have just started to branch on the sole plate.
- B. A p_1 plate in profile after 18 days R.T. The sole plate and the sole plate nuclei can be seen.
- C. A poorly restored p_1 plate after 186 days R.T. Although the supplying axon is relatively thick, the ramification within the sole plate is very poor.
- D. Axons entering a p_1 plate and forming terminal swellings 25 days R.T.
- E. Another example of a poorly restored p_1 plate, this time after 39 days R.T. The supplying axon is again relatively thick and the elaboration of the endplate poor.
- F. A pair of p_1 plates, supplied by a single axon. The plates are formed on separate intrafusal muscle fibres. 102 days R.T.

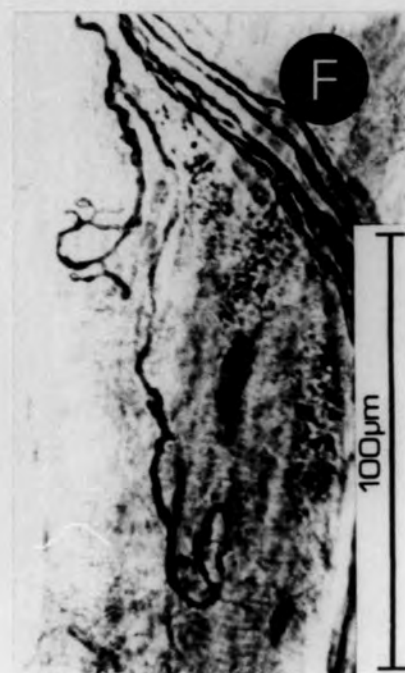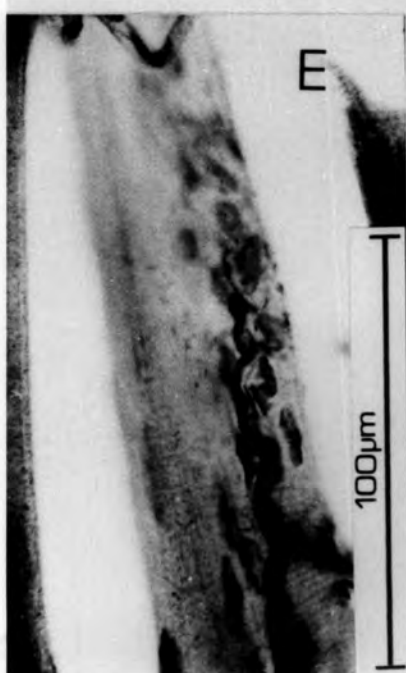

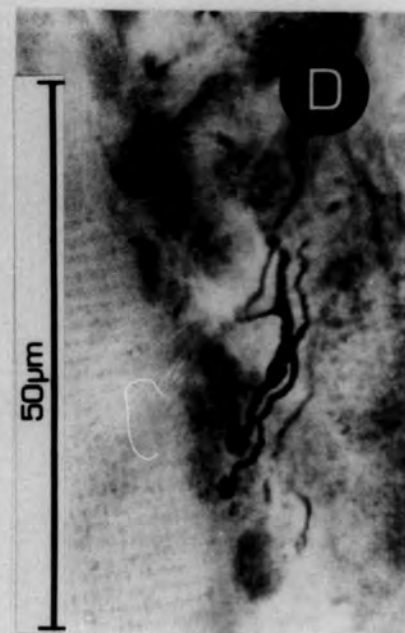
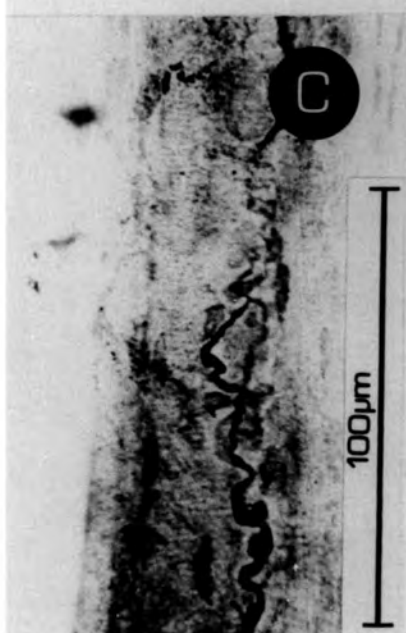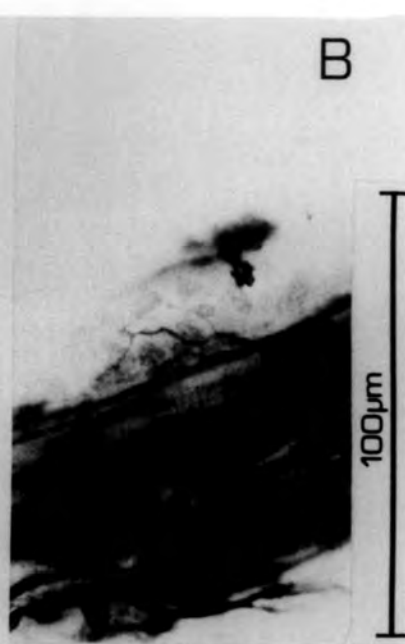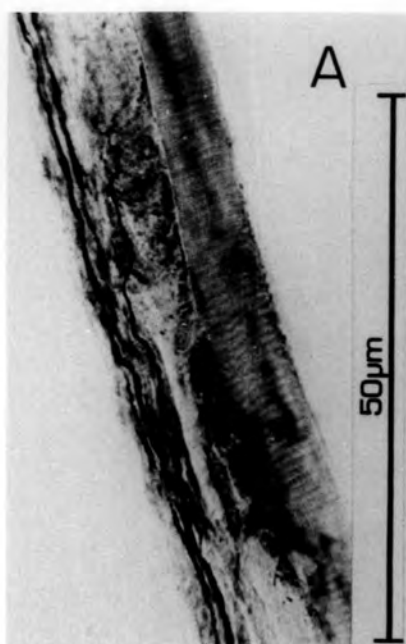Plate 3.18

p_1 endplates

- A. Extrafusal muscle fibres and spindle innervated by one axon. The extrafusal endplate (e) is supplied by an axon which has branched at (b) and goes on to form a p_1 plate on the spindle (at a site marked by P).

- B. A well-restored example of a p_1 plate after 207 days R.T., supplied by a single axon. The outlines of the sole-plate are visible.

- C. An example of a reinnervated extrafusal endplate after 74 days R.T.

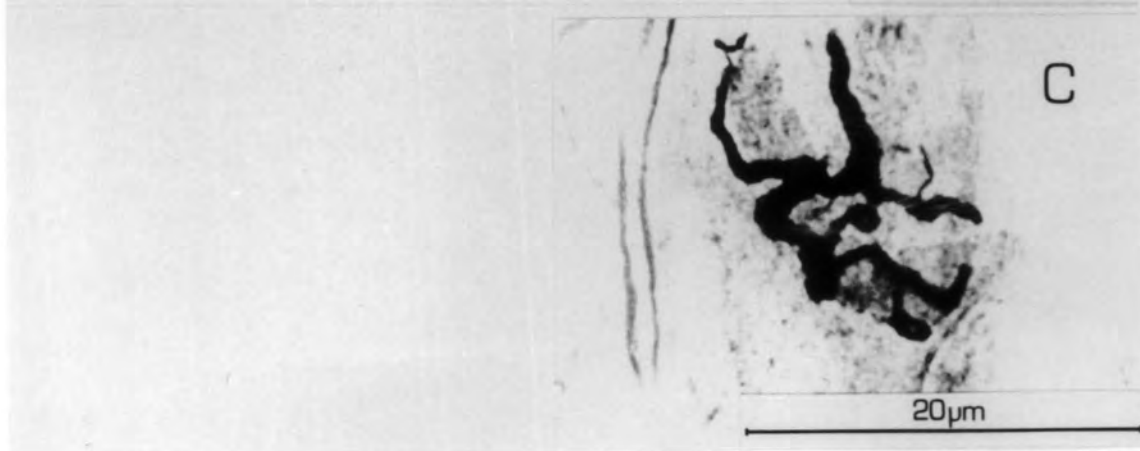
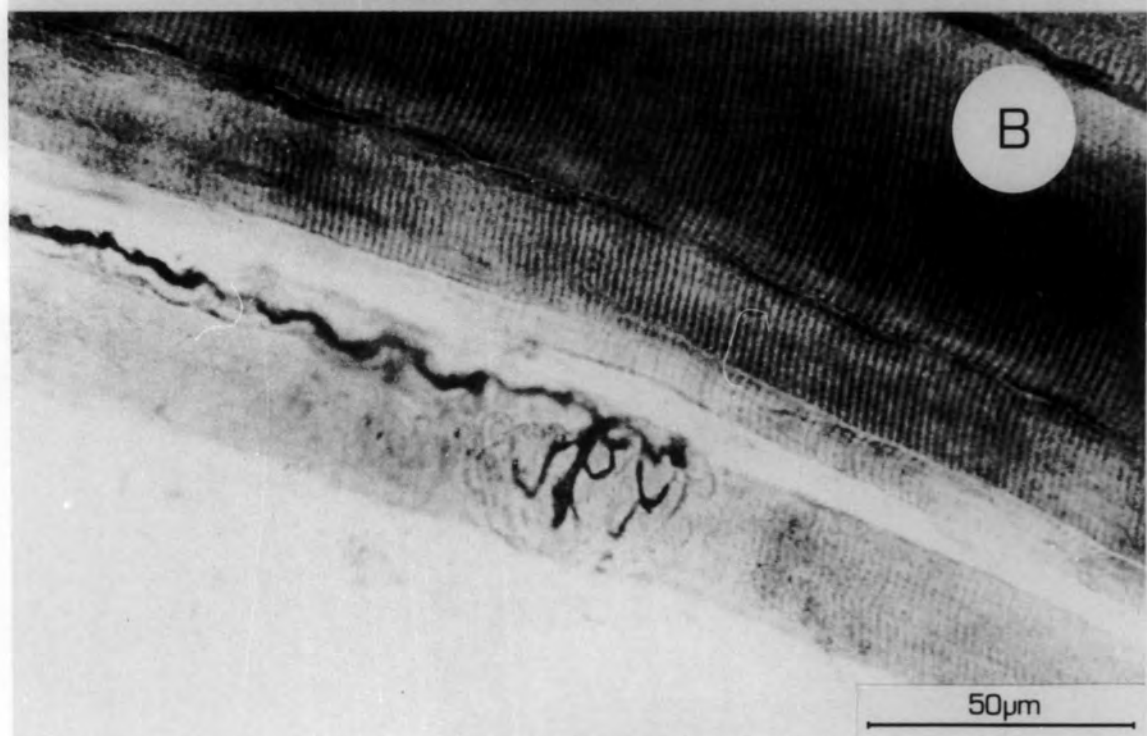
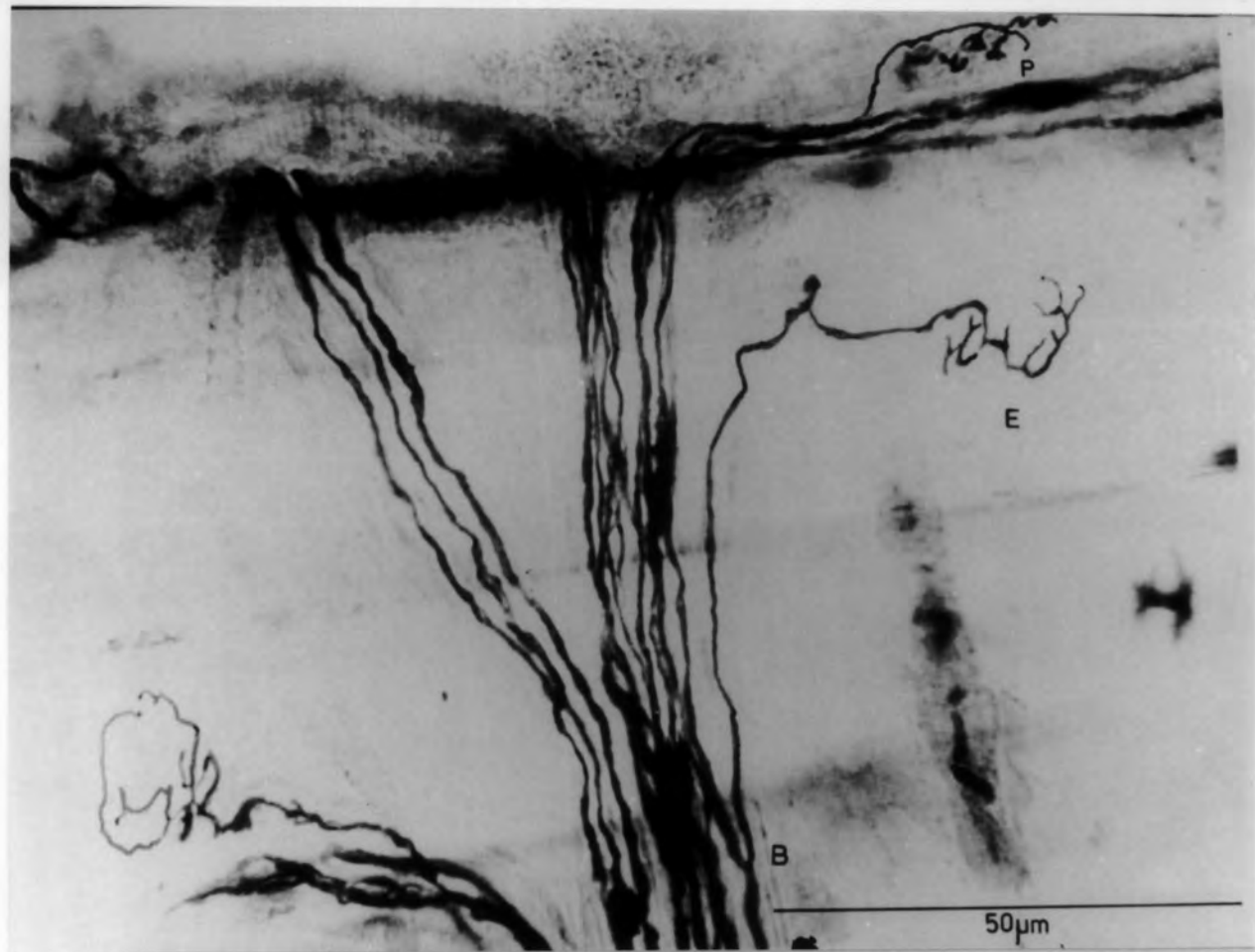


Plate 3.19

A, B & C

Examples of p_1 plates after 25, 53 and 249 days R.T. The " Y " - shaped formation is normal in appearance, and, in all three cases, both the plates are situated on the same intrafusal muscle fibre.

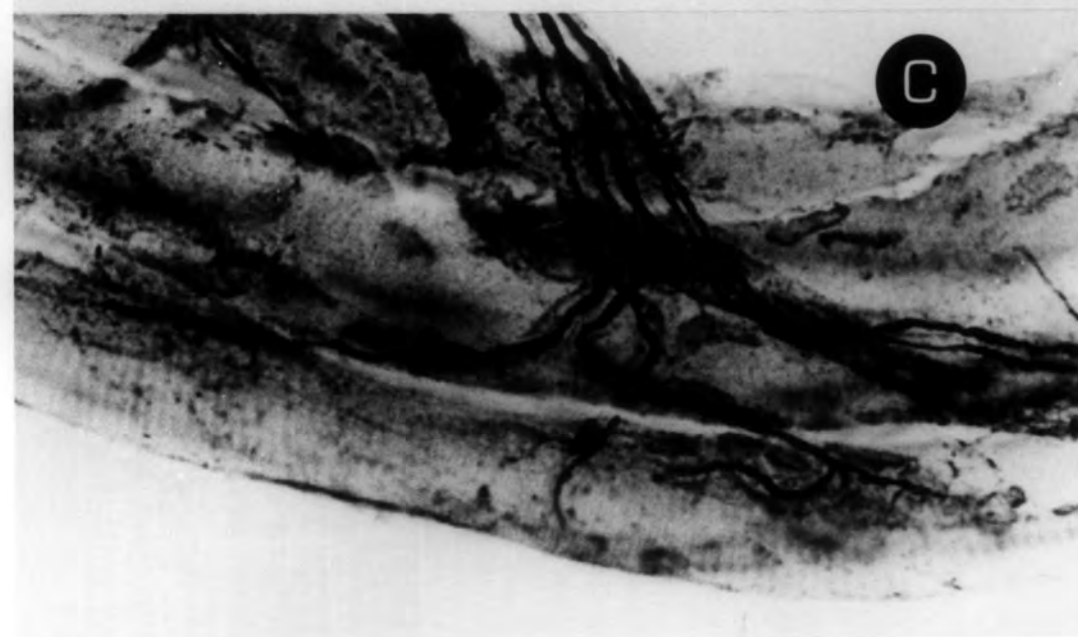
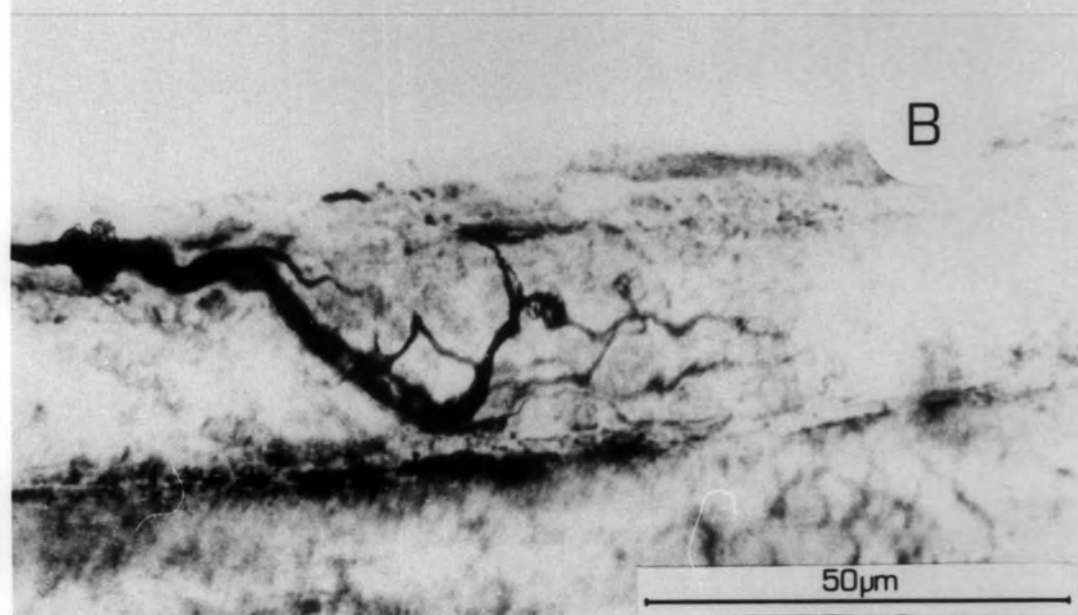
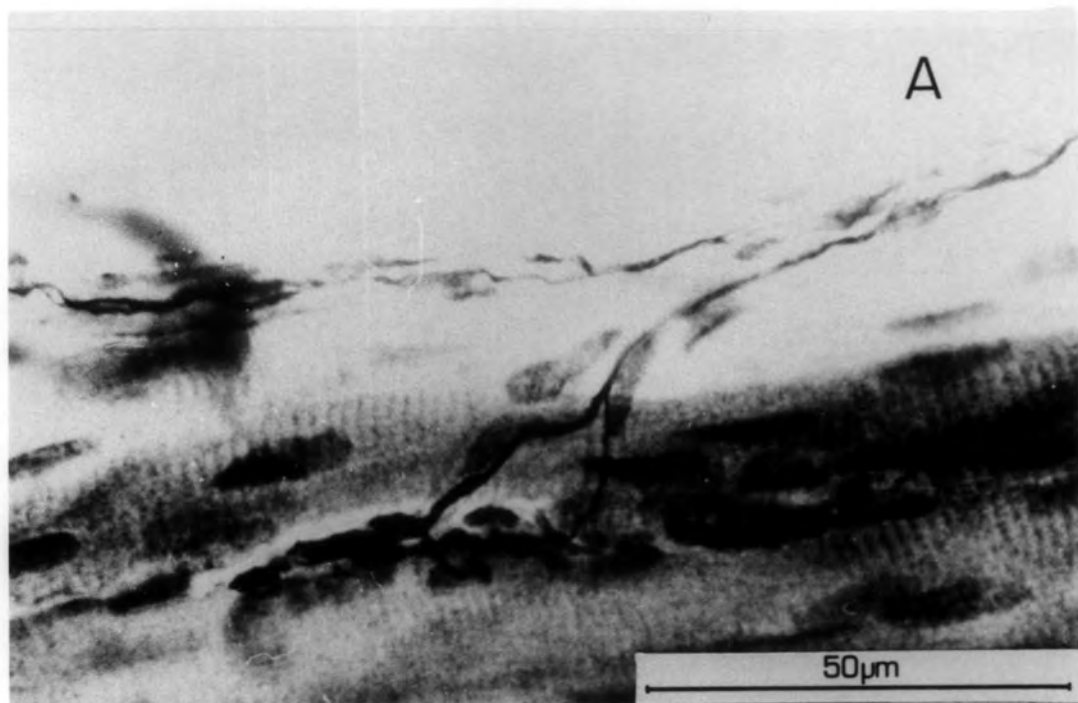


Plate 3.20

A, B & C

Examples of p_1 plate innervation after 102, 53 and 74 days R.T.

They are all examples of "Y"-shaped formations.

D. A p_1 site after 102 days R.T. which receives two axons. One produces a recognisable terminal within the endplate. The other bifurcates before entering the plate, and terminates in swellings within the endplate.

E. A p_1 site after 102 days R.T. It is innervated by three separate axons, all of which end in terminal swellings.

F. A "Y"-shaped formation of p_1 plates after 53 days R.T. Although the p_1 plates have a normal appearance, the supplying axon is accompanied by a very thin axon which terminates in a large mass close to the plates.

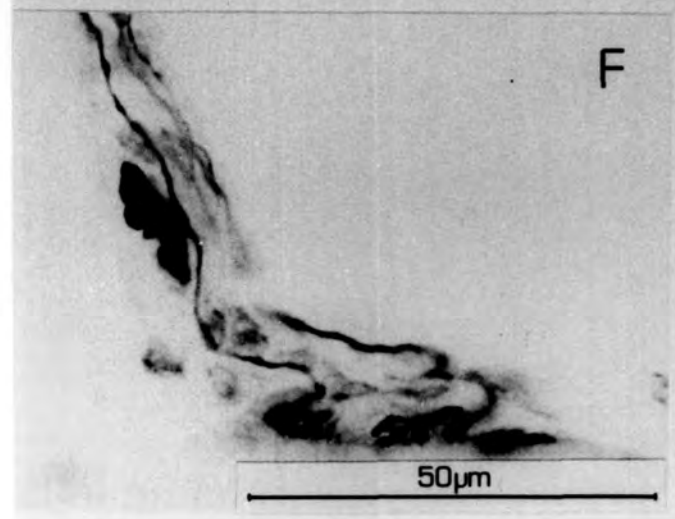
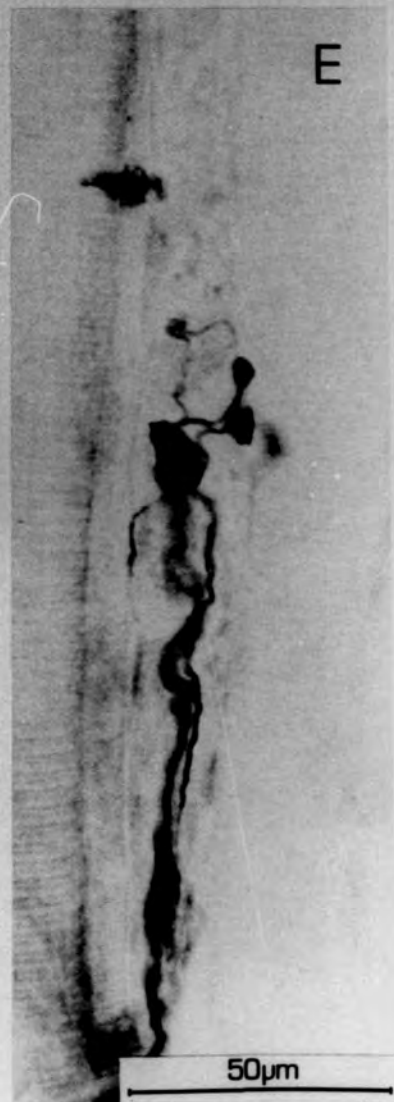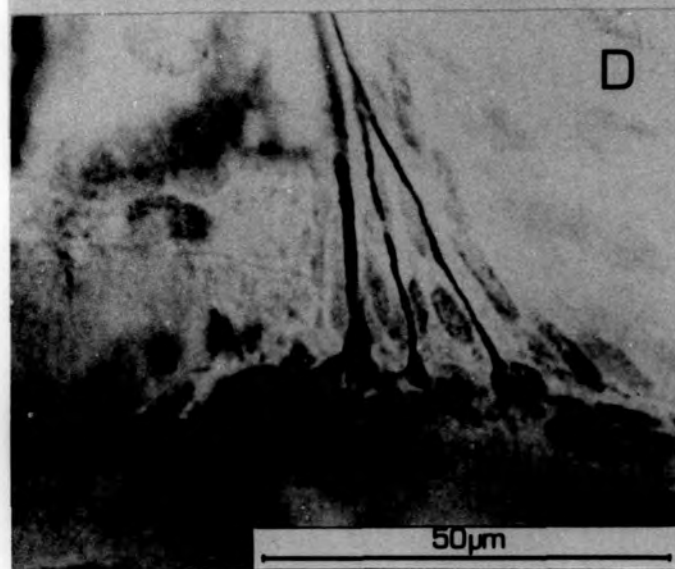
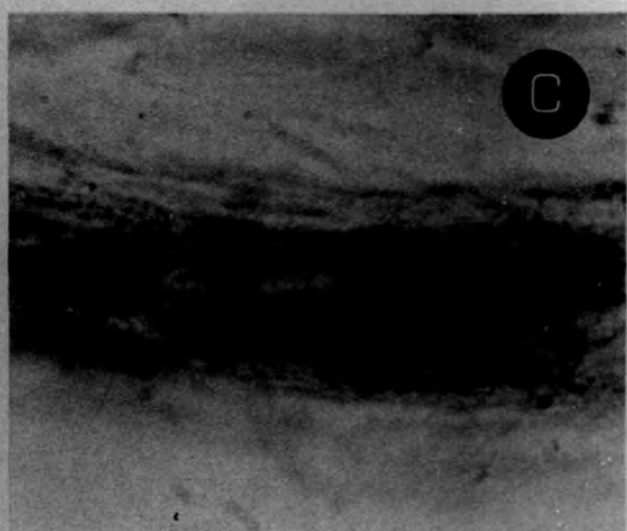
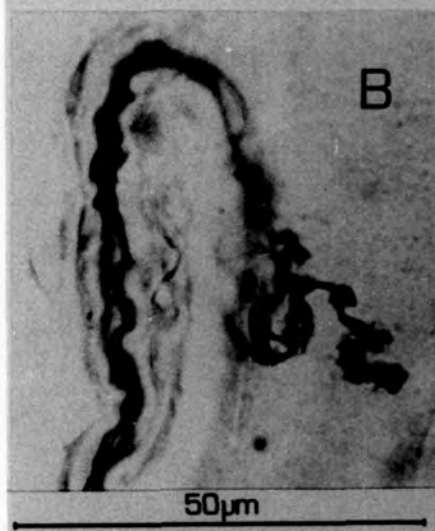
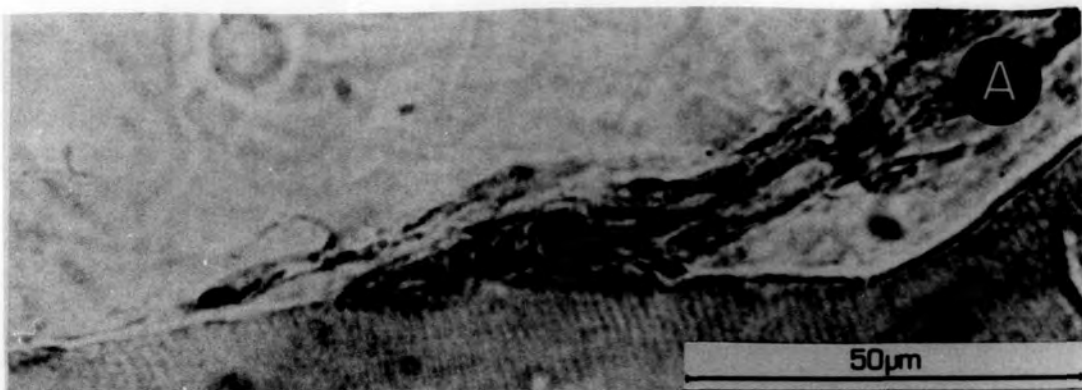


Plate 3.21

- A. A group of three p_1 plates after 207 days R.T. The upper pair is in a normal " Y "- shaped formation supplied by a single axon. However it is visited by an axon which then leaves (arrowed), returning up the supplying nerve trunk. It makes no contribution to the ending. There is a third plate (p_1) on another intrafusal fibre which is supplied by two fine axons.
- B. A group of three p_1 plates after 53 days R.T. It is supplied by one thick axon (arrowed). The two main plates on the right are situated on separate intrafusal fibres, in a " Y "- shaped formation. The third p_1 plate appears to be being formed by a ultra-terminal sprout.
- C. A group of presumed p_1 plates after 53 days R.T. The group is supplied by four fine axons. The plates are arranged in a linear formation, and it is possible they may be occupying a former p_2 plate site.

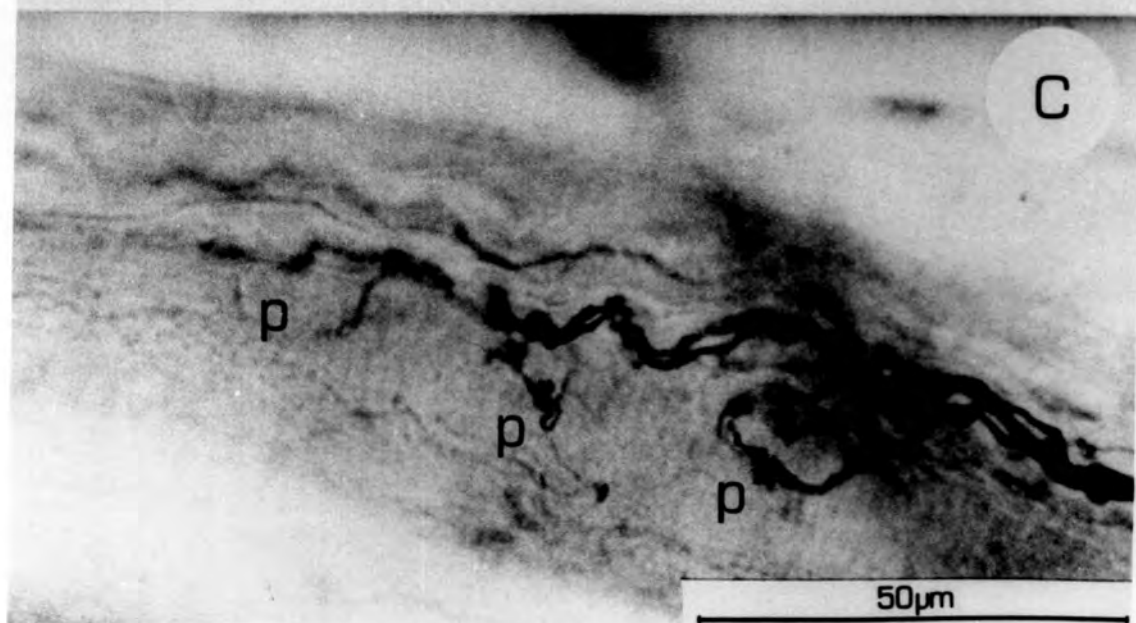
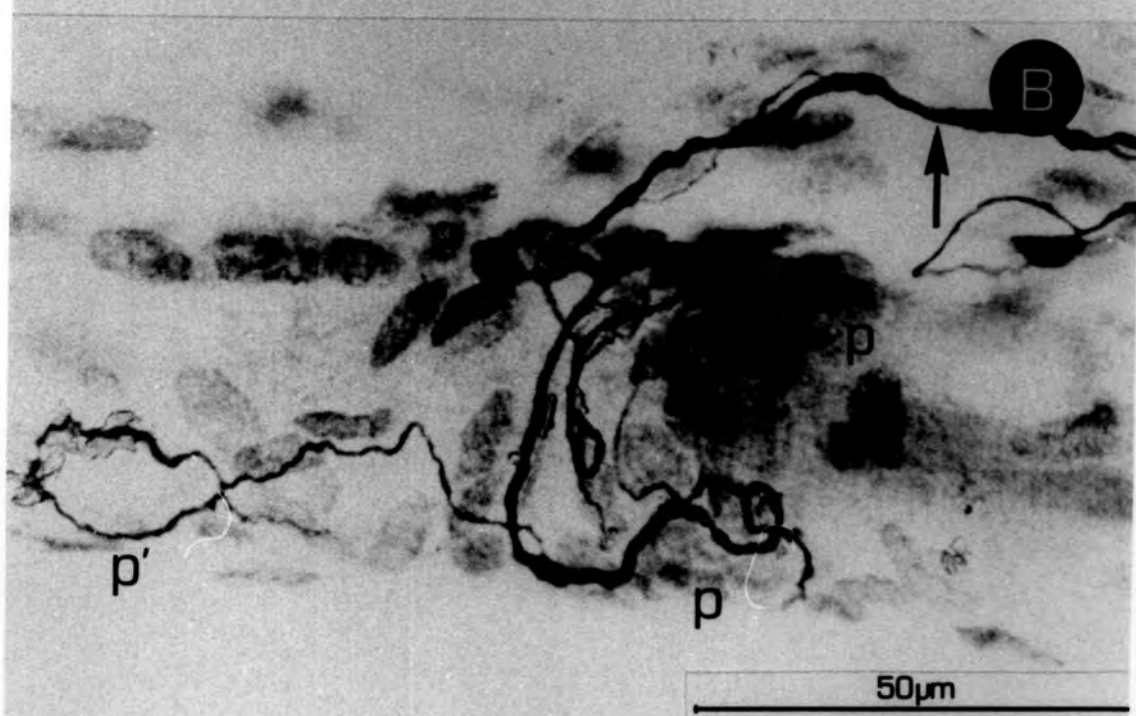
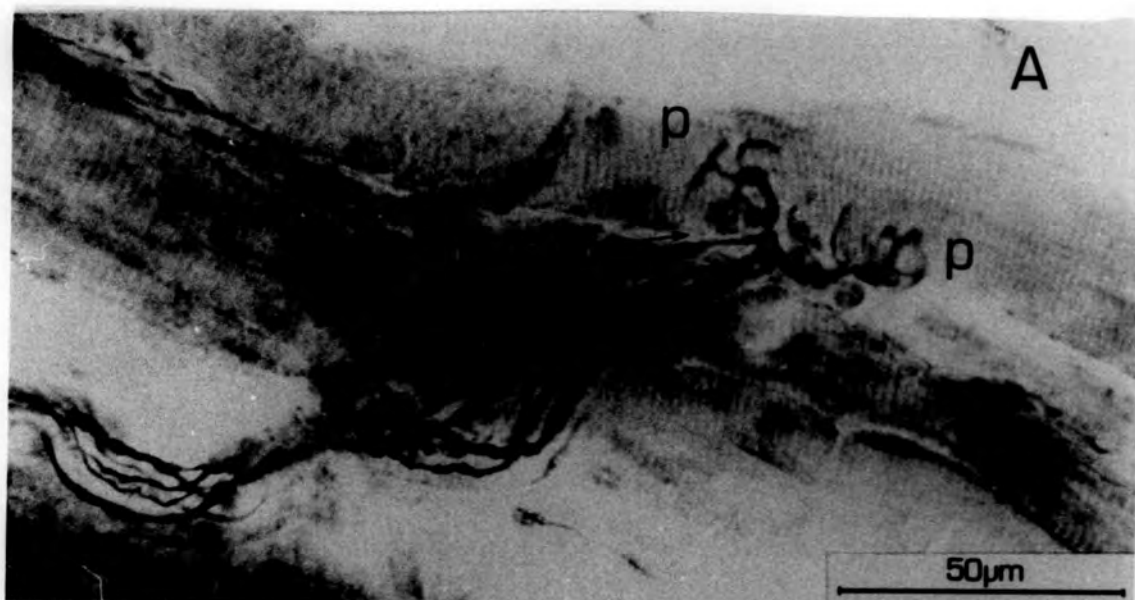


Plate 3.22

P_1 plate hyperinnervation.

A, B & C

Examples of hyperinnervated p_1 plates after 39, 102 and 249 days R.T.

In all these cases the plate is supplied by two axons of approximately equal diameter. In B a supra-terminal sprout can be seen to end in a swelling.

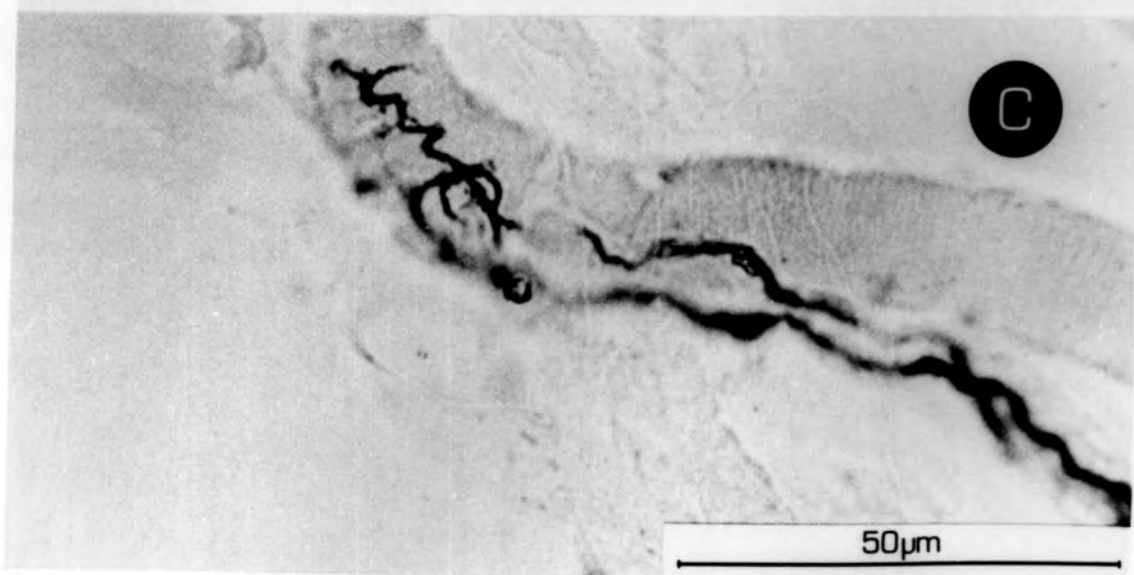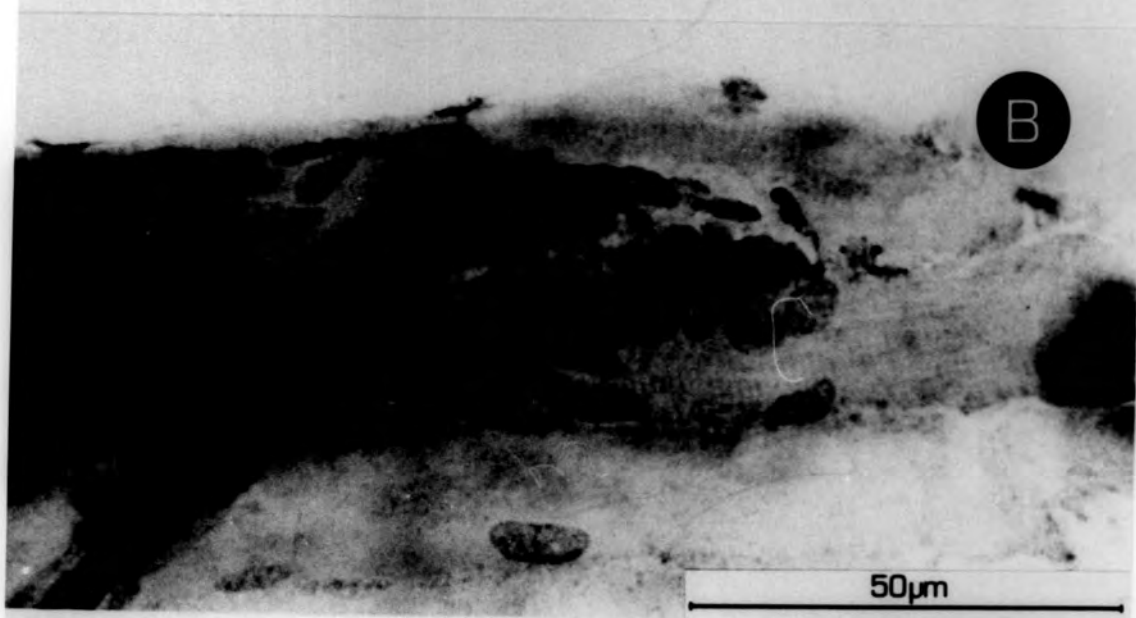
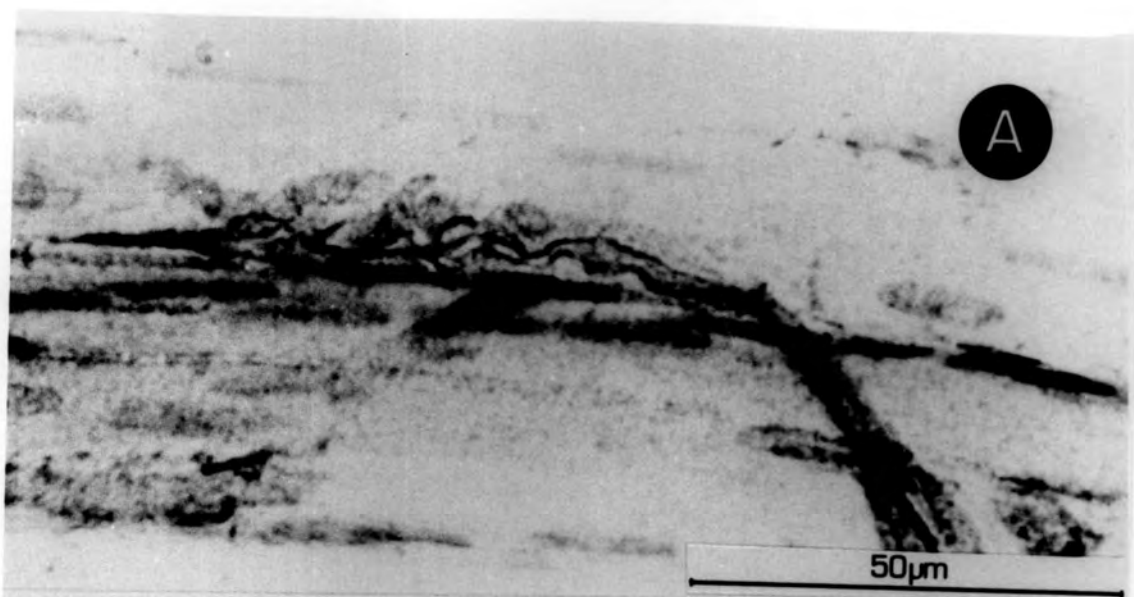


Plate 3.23

P_2 endplates

- A. An early example of a presumed P_2 plate. The terminals consist mainly of tapers. This plate is supplied by one thick axon accompanied by a much smaller one.
- B&C. Examples of restored P_2 plates after 130 and 217 days R.T. The ending at 130 days is less elaborated than at 217 days, where the ending has a very normal appearance. the flat sole-plate characteristic of P_2 plates is well stained in B.
- D&E. Examples of restored P_2 plates at 81 days and 53 days. Both show rudimentary terminals consisting mainly of tapers, and both are supplied by two axons, one much thicker than the other.
- F. A restored P_2 plate after 196 days R.T. This plate is supplied by an axon which branches before making the plate.

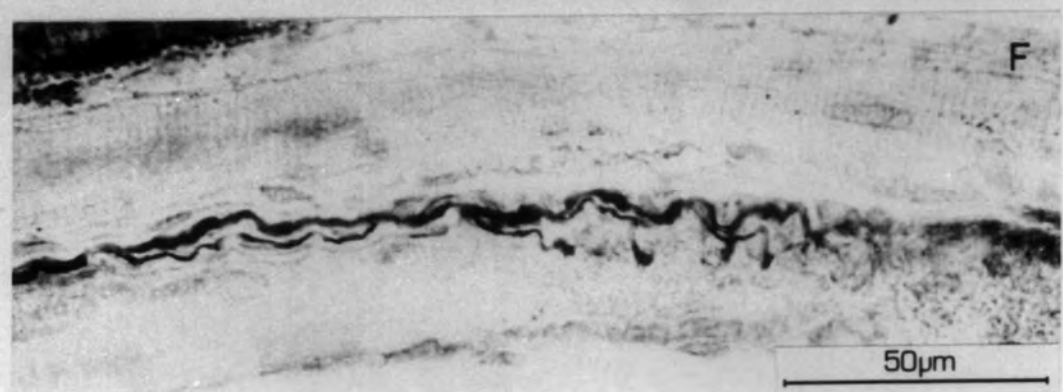
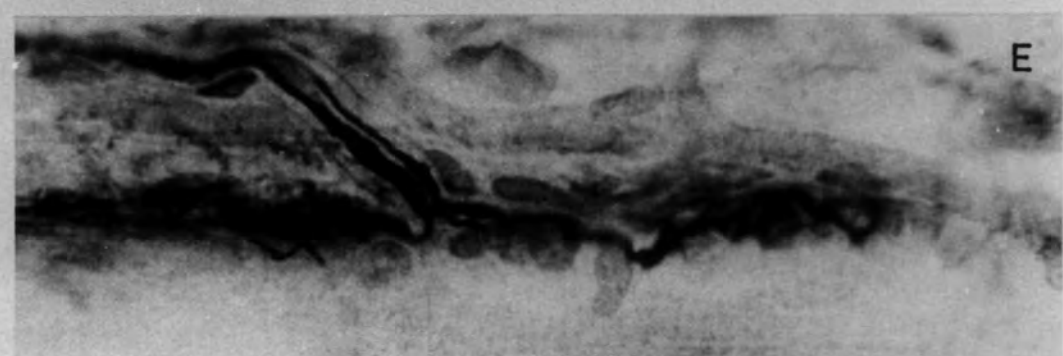
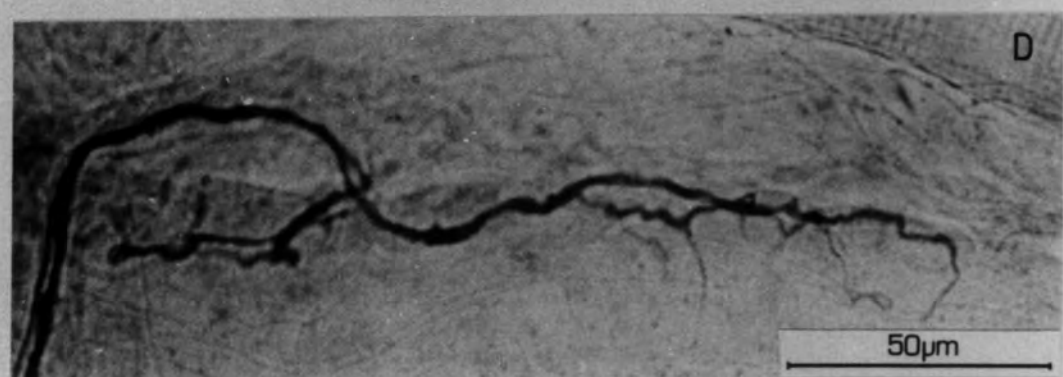
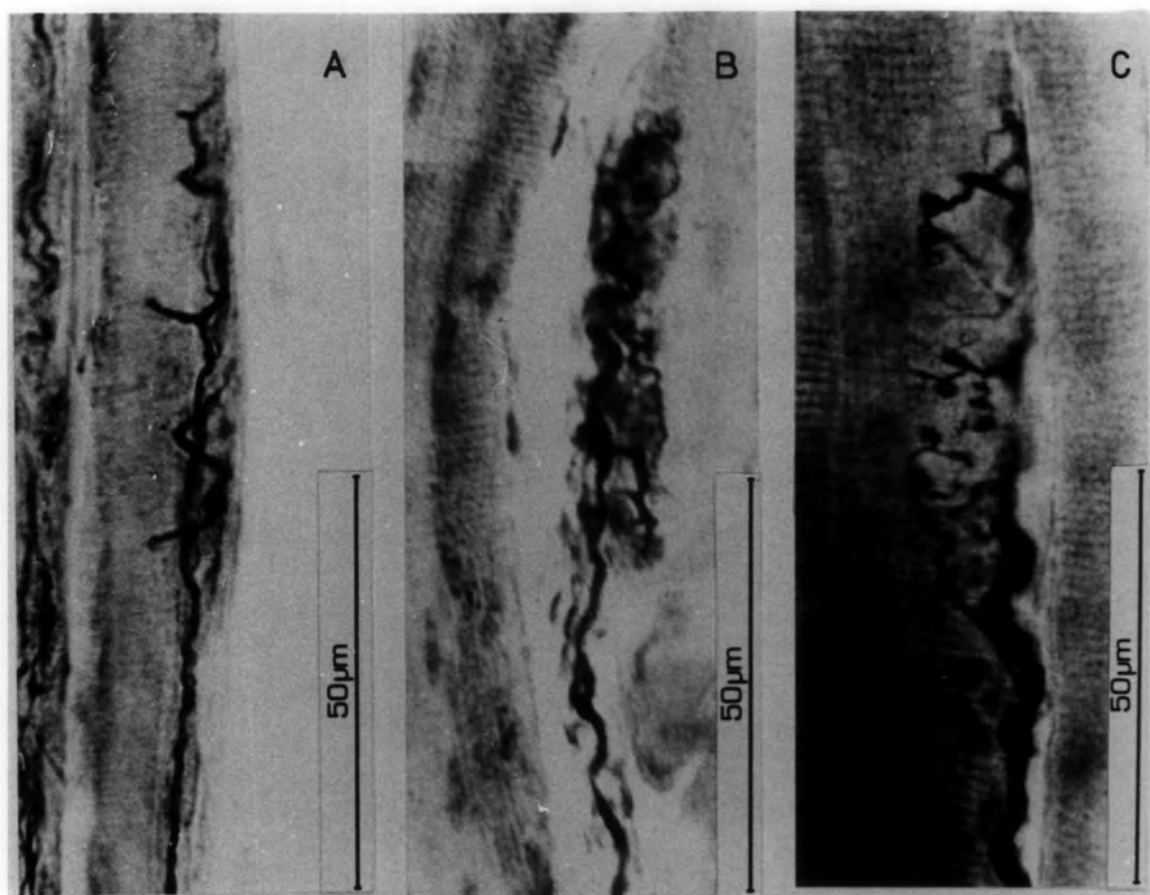


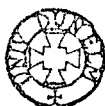Plate 3.24

A. A presumed p_2 plate site after 53 days R.T., supplied by five axons (arrowed), which form p_1 plate-like endings.

B. A presumed p_2 site after 74 days R.T. also visited by five axons. One terminates in a hook (indicated) and another enters and leaves without making a termination; the others terminate on the p_2 site.

C. A presumed p_2 site after 74 days R.T. A terminal axonal swelling occurs within the ending.

D. A presumed p_2 site after 53 days R.T. An accompanying fine axon terminates in a swelling within the plate.



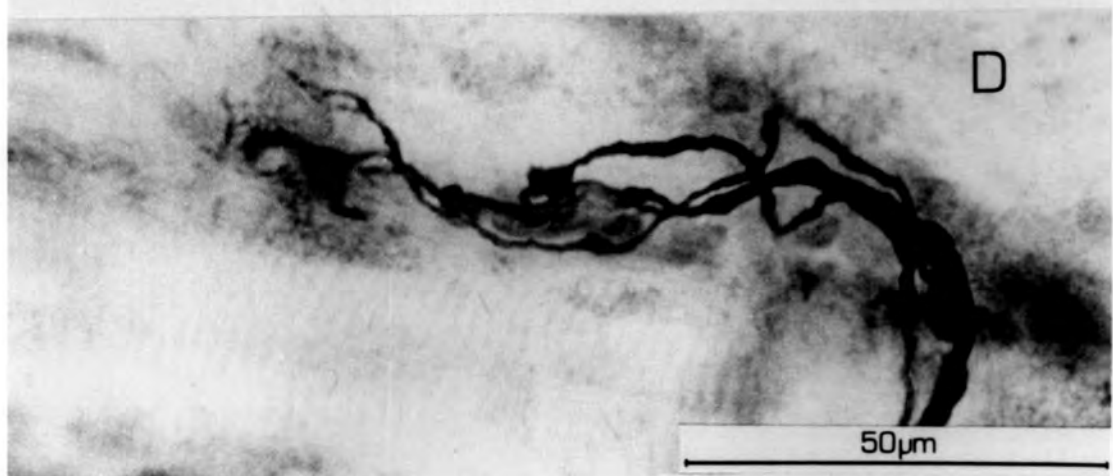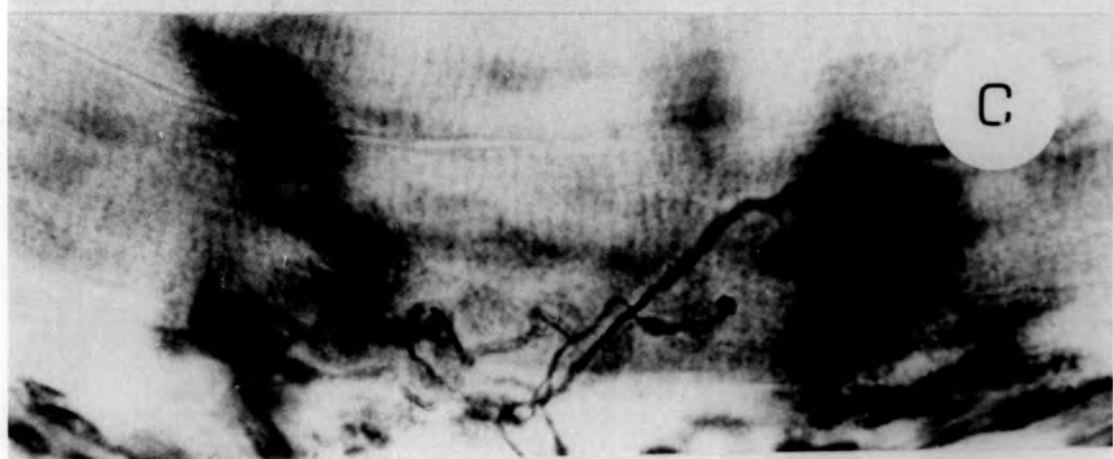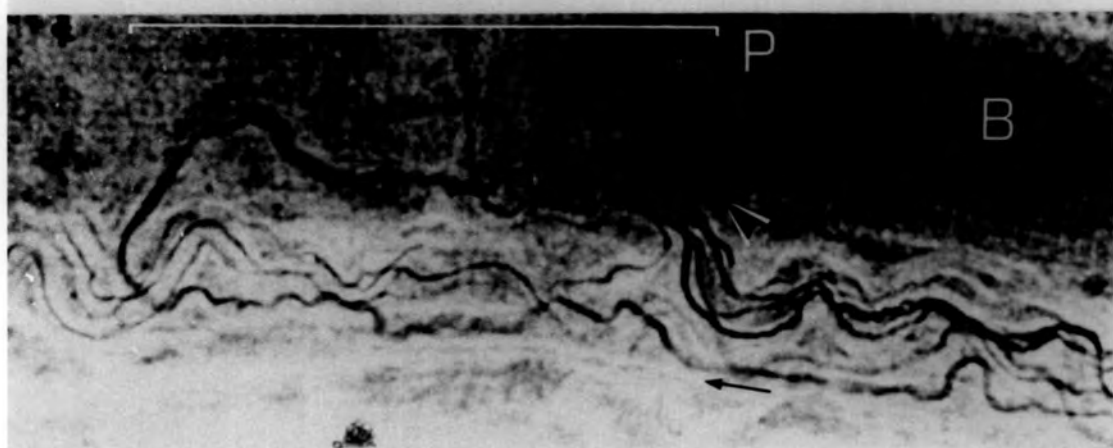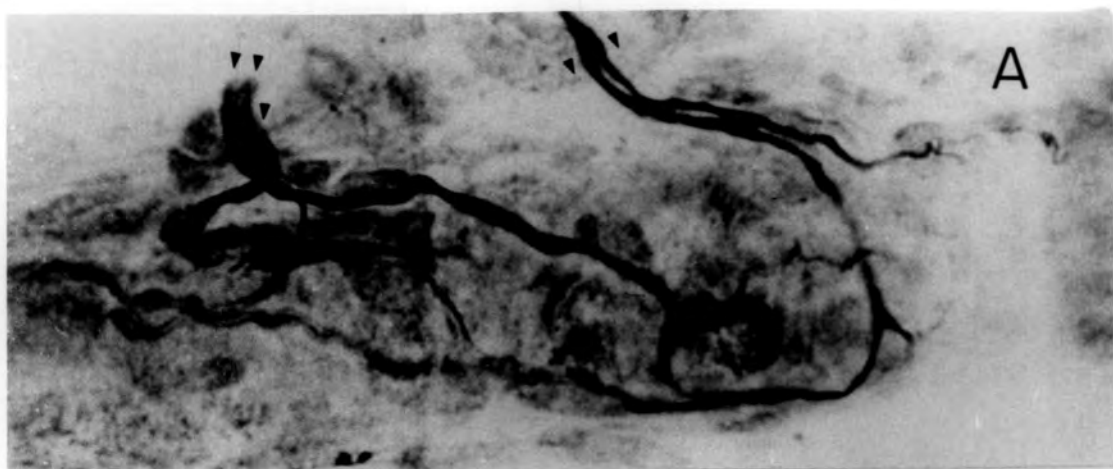


Plate 3.25

- A. Site of a poorly reformed p_2 plate, with a post-terminal run-on ending in an axonal swelling, 18 days R.T.
- B. Another example of a presumed p_2 site with an axonal swelling on a post-terminal run-on, 207 days R.T.
- C. A presumed p_2 site supplied by one axon at 207 days R.T. The terminal has not resumed a normal appearance, ending in tapers.
- D. An abnormality in the ^{terminal or} myelin sheath adjacent to a p_2 plate. The diameter of the sheath at this point is several times greater than that produced normally.

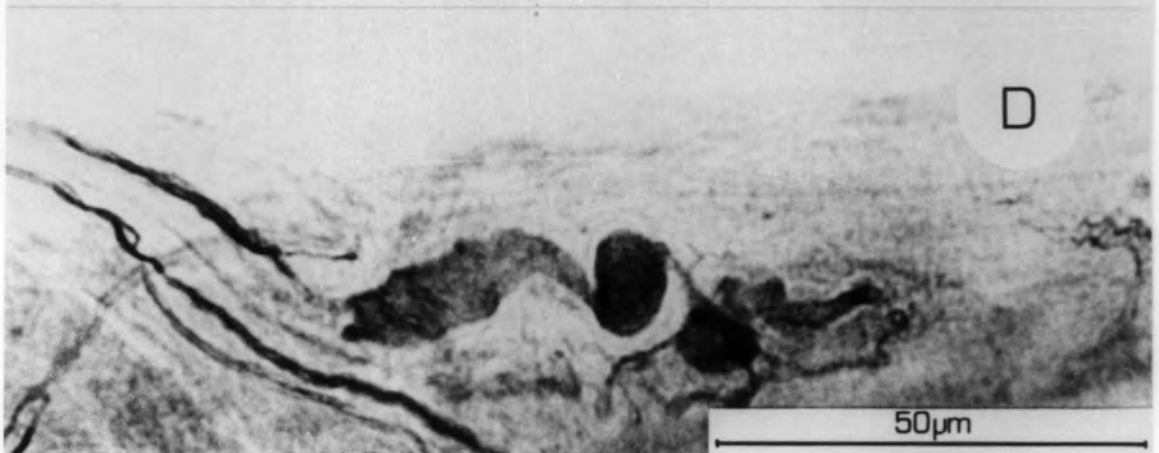
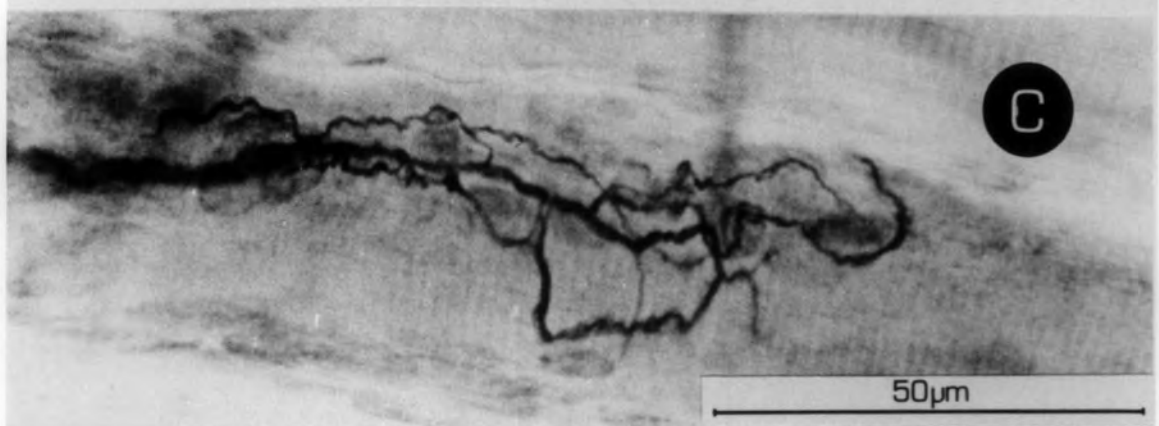
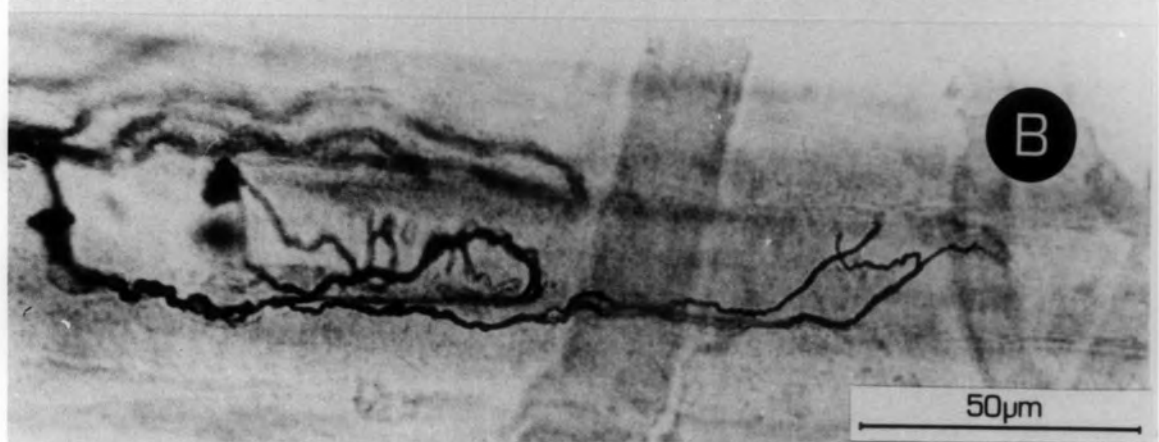
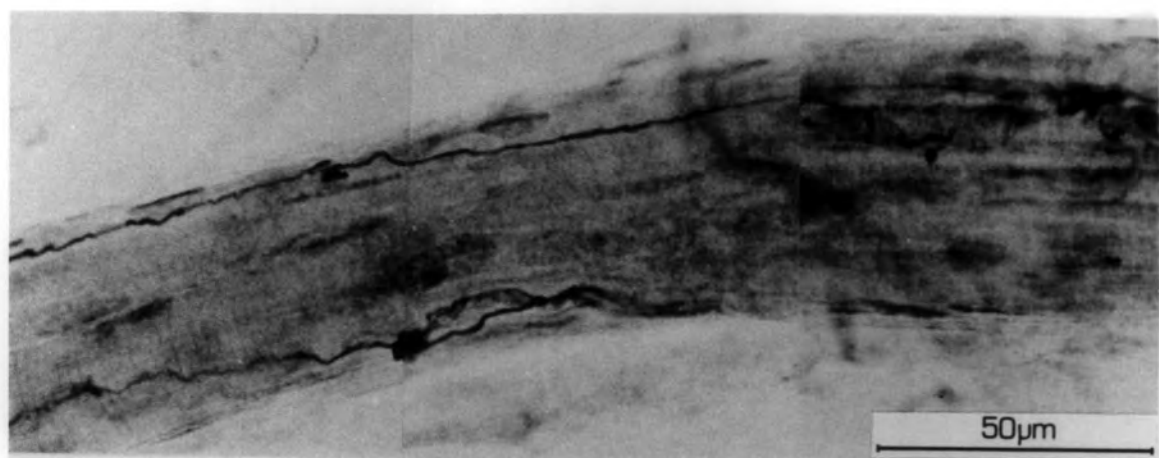


Plate 3.26

Trail ramifications at 11 days R.T.

- A. A characteristic triangular-shaped branching in the S_2 region of a spindle. These are the earliest indications that a trail-ramification is being formed.

- B. A more extensive view of an early presumed trail-ramification. The terminals are not apparent at this stage.

- C. Another example of a presumed trail-ramification in its early stage.

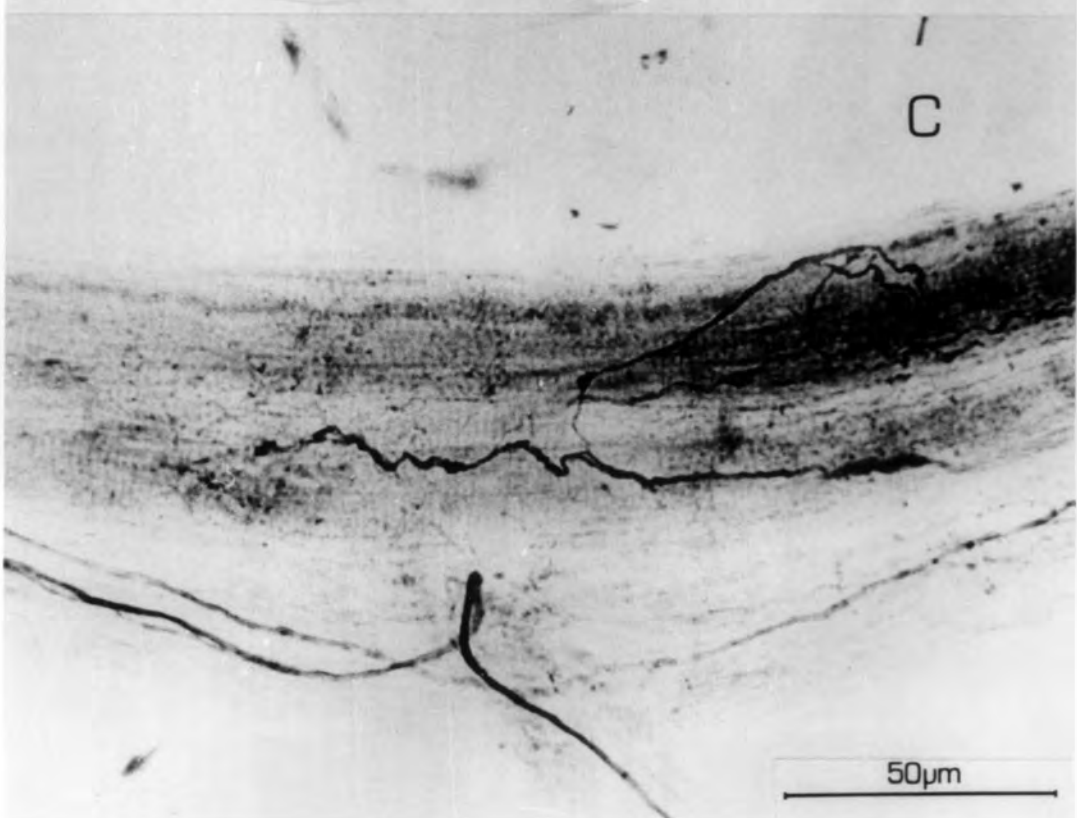
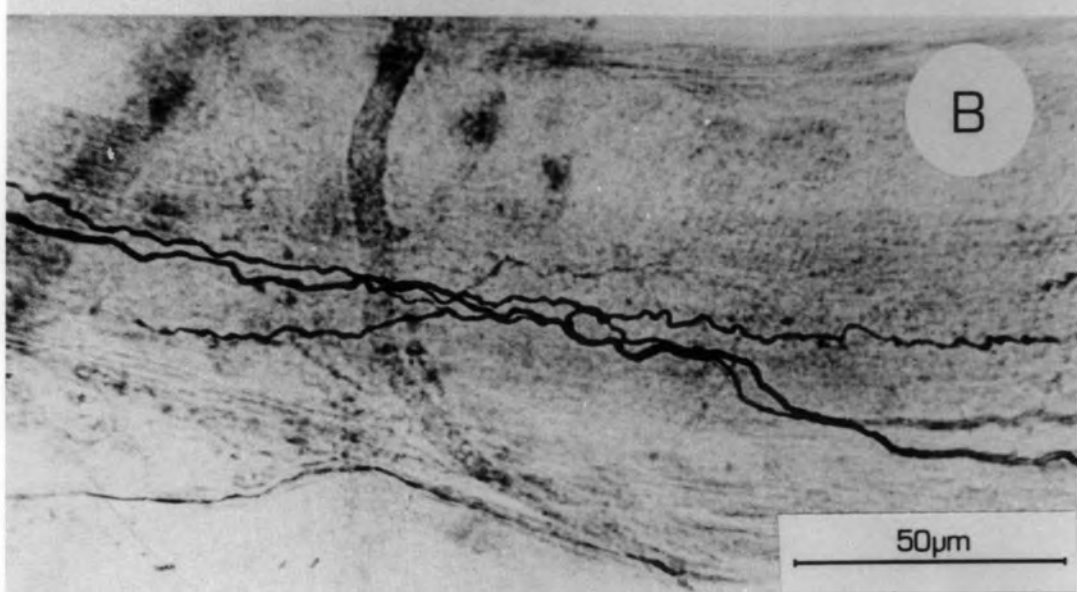
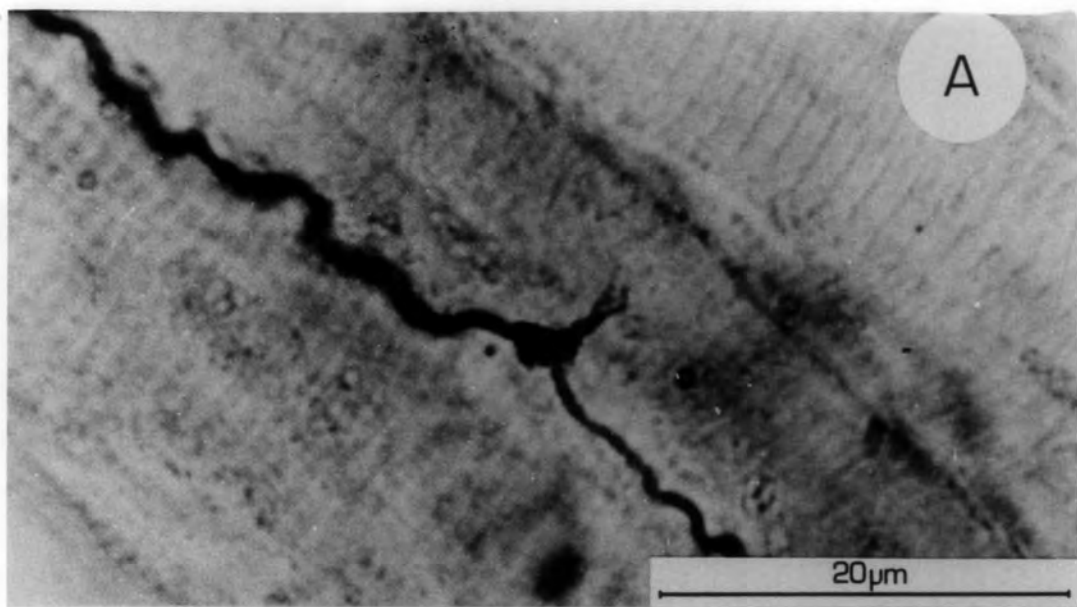


Plate 3.27

- A. Part of a trail ramification at 25 days R.T. Terminals are being formed (T), and a recurrent axon which leaves the spindle is present (A).
- B. Part of a trail ramification at 74 days R.T. Characteristic branching of the supplying axon and a well-formed terminal can be seen.

C & D

Examples of presumed trail ramifications at 81 and 130 days R.T. C shows a very sparse ending supplied by a fine non-myelinated axon. D shows part of a thickly myelinated ramification producing a bizarre terminal.

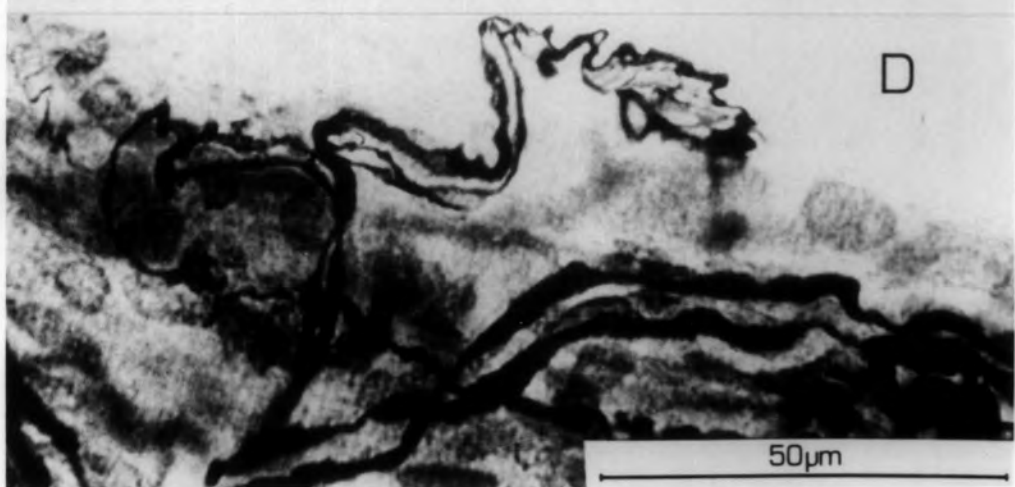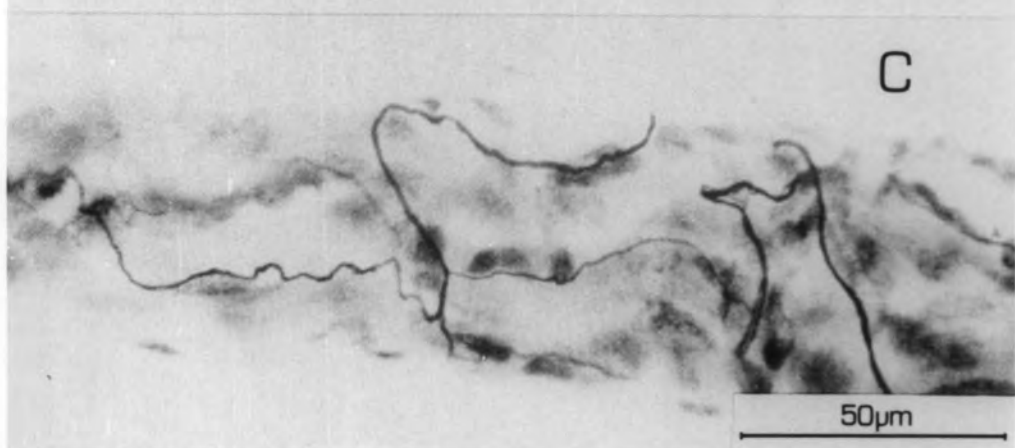
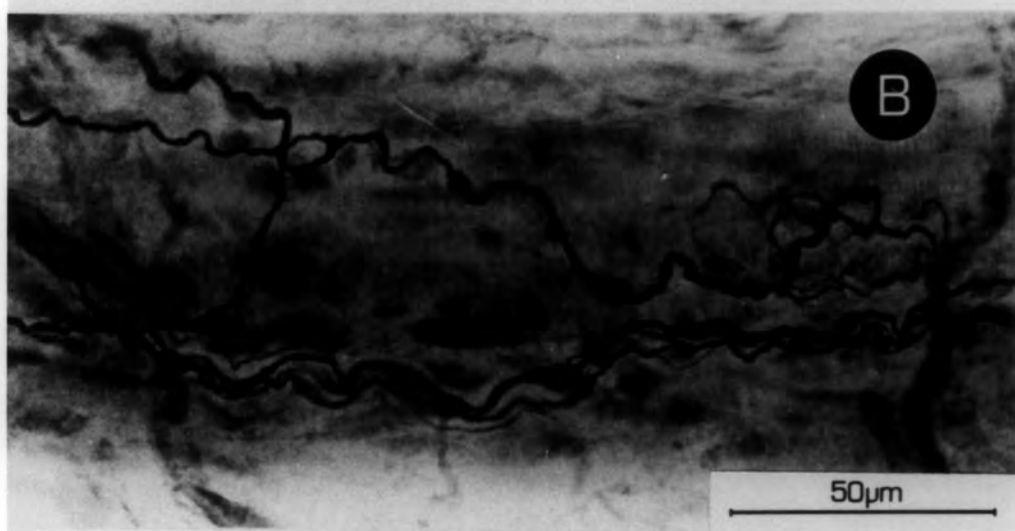
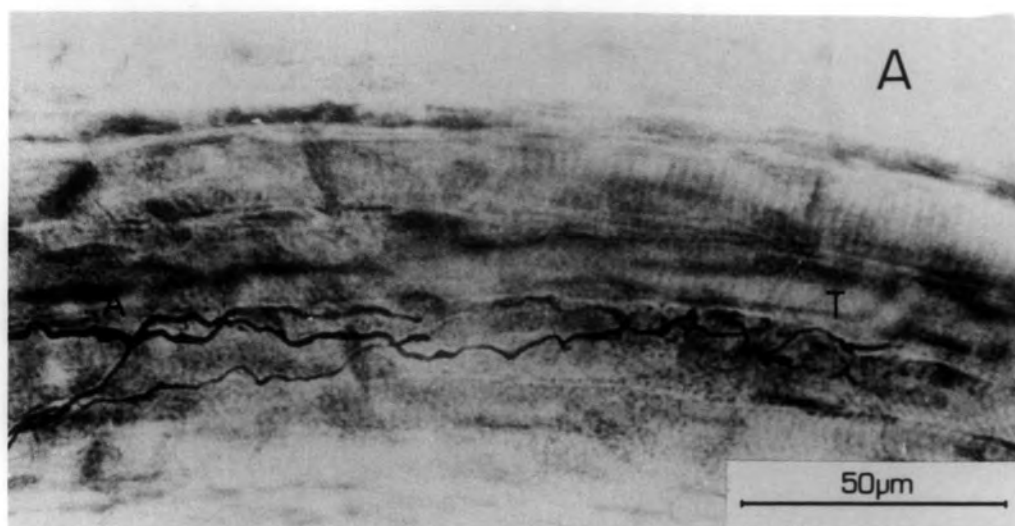


Plate 3.28

Early examples of invading axons

- A. The earliest example of an invading axon at 11 days R.T. The axon enters and leaves the spindle through the same nerve trunk, having branched and made presumed terminals.

- B. An invading axon at 18 days R.T. In this example the axon branches after making terminals and leaves the spindle as two axons, through the supplying nerve trunk.

- C. An invading axon at 18 days R.T. The axon divides and one branch leaves the spindle, the other forms a p_2 plate-like terminal and produces an ultra-terminal sprout which accompanies the axon from the first branch, out of the spindle.

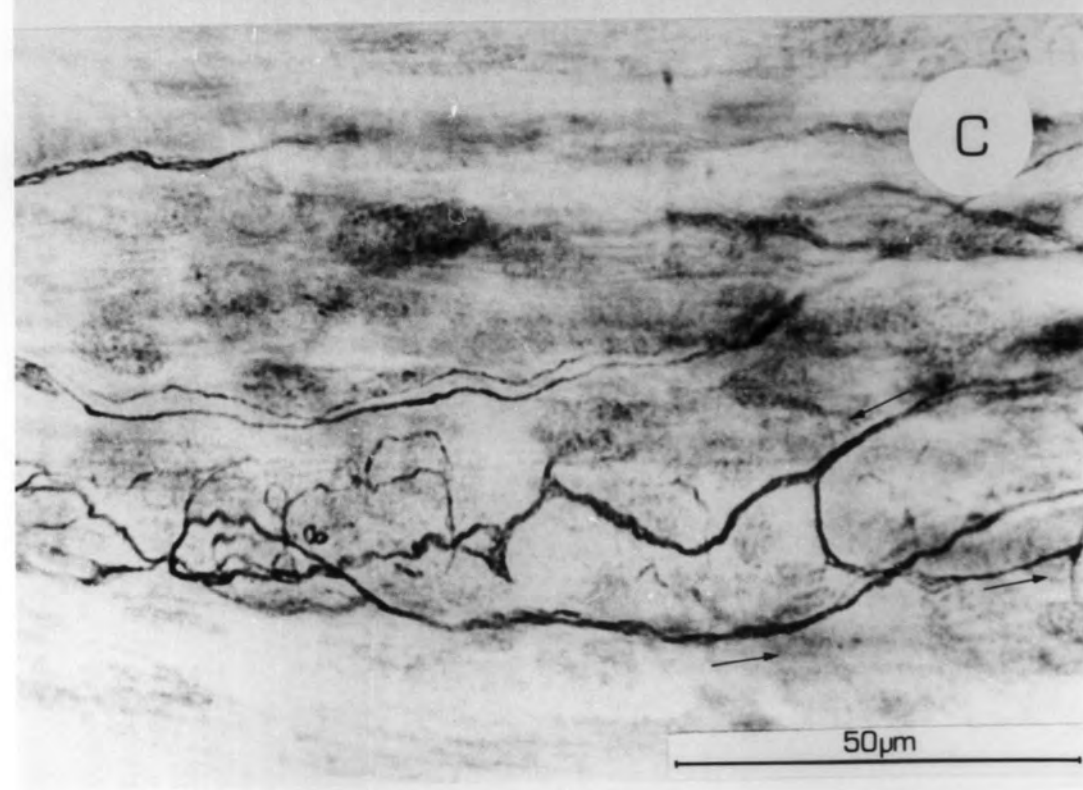
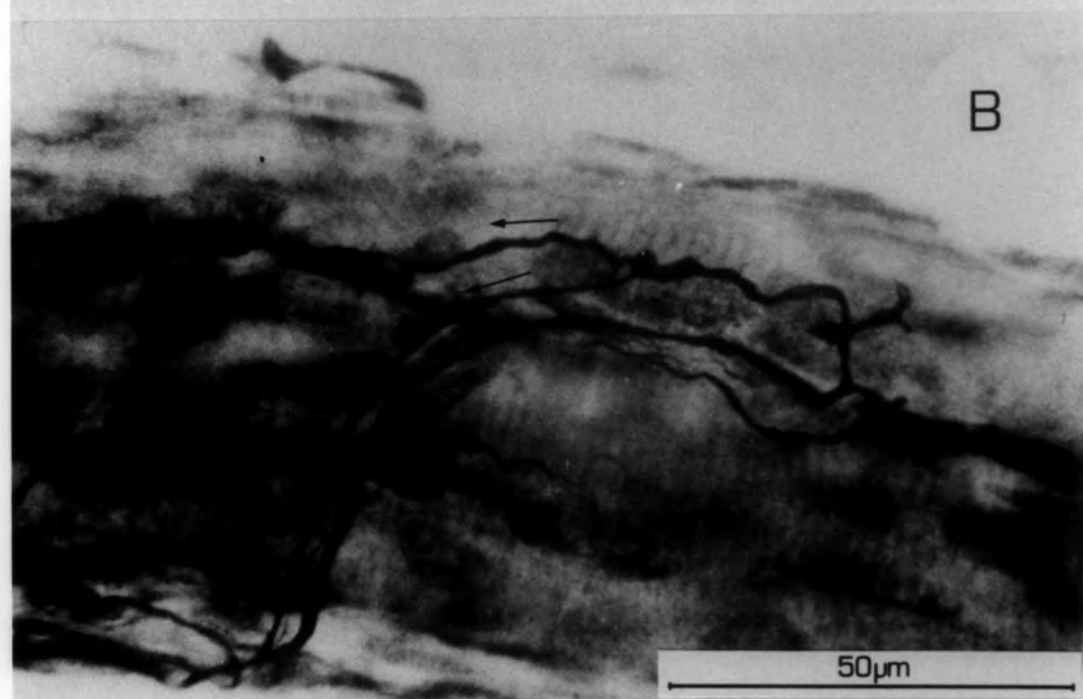
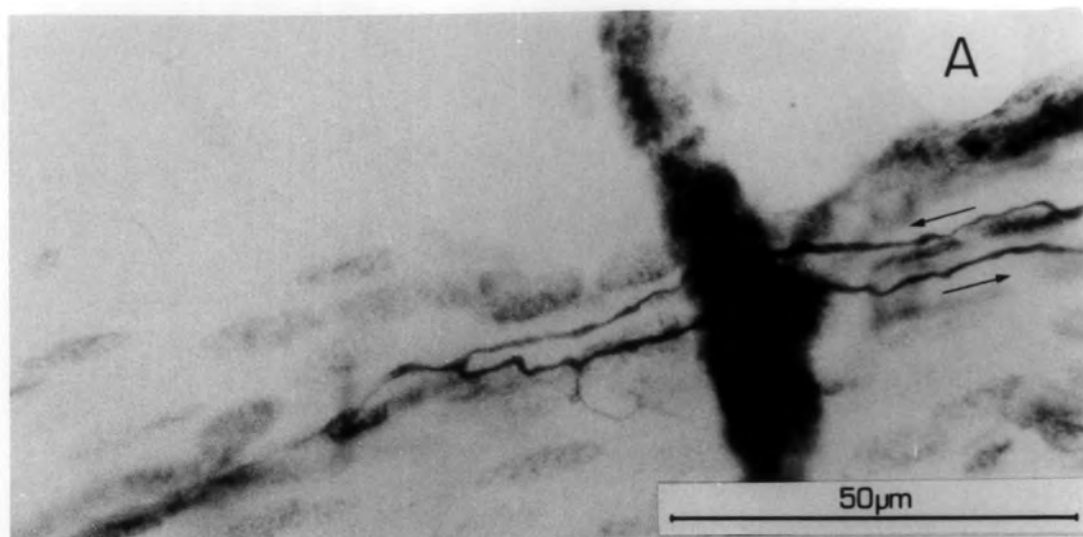


Plate 3.29

Invading axons

- A. An invading axon after 25 days R.T. In this case the axon divides and leaves the spindle as two axons returning up the supplying nerve trunk.
- B. An invading axon at 39 days R.T. This time the axon divides and leaves the spindle as two axons; one returning up the supplying nerve trunk, while the other takes a different route.
- C. An example of two pairs of P_1 plates at 53 days R.T., supplied by one axon, but formed on different intrafusal fibres. At x a branch from an invading axon can be seen approaching one of the p_1 sites.

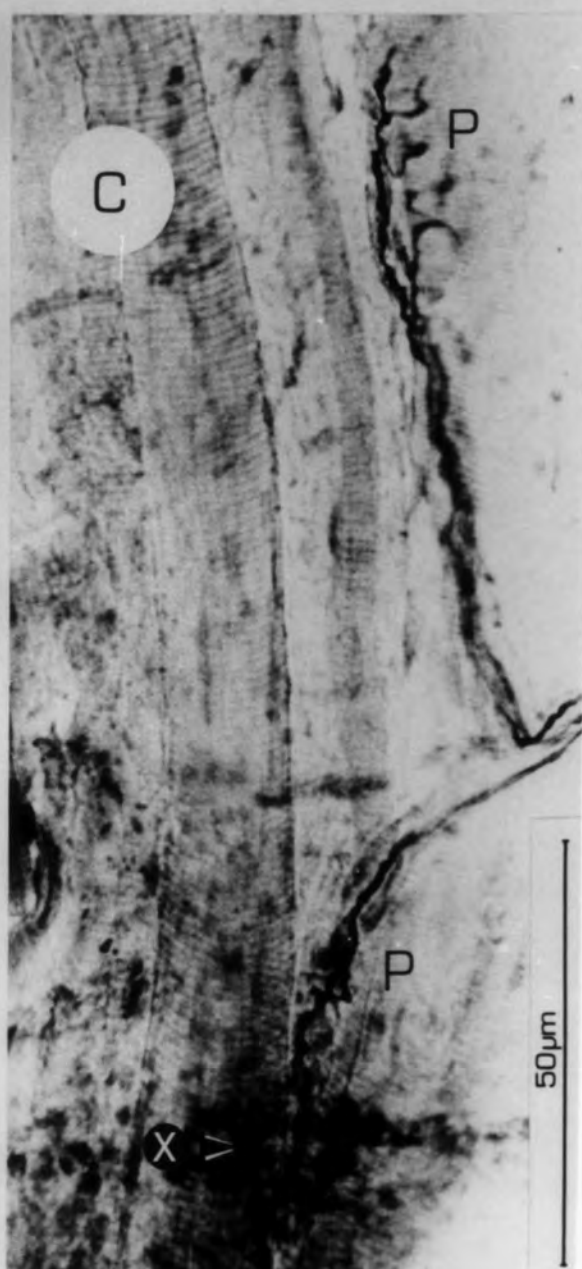
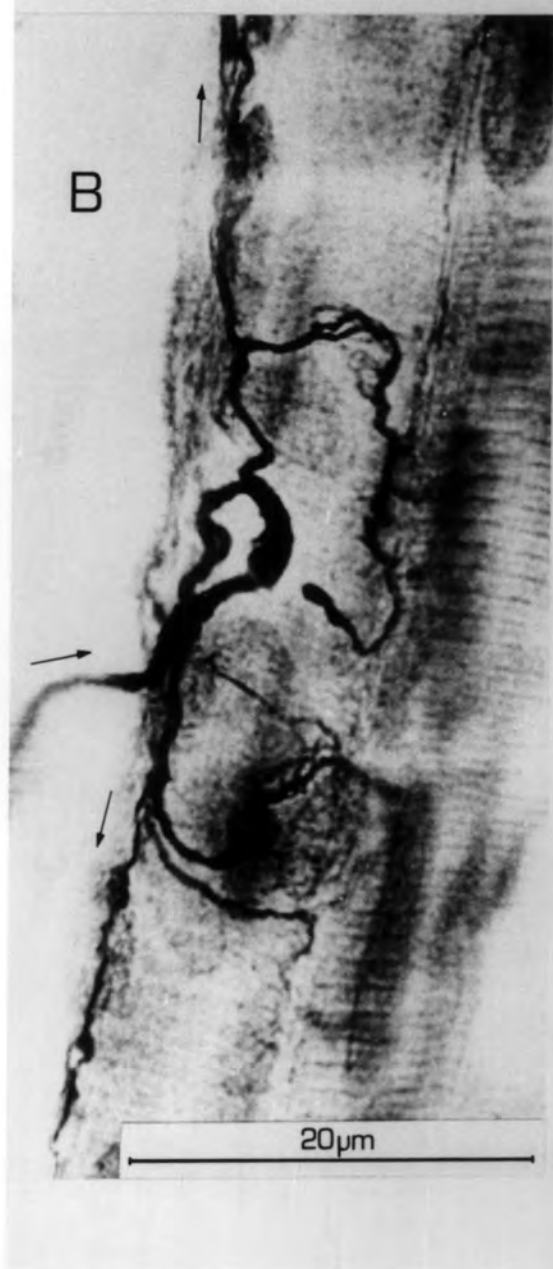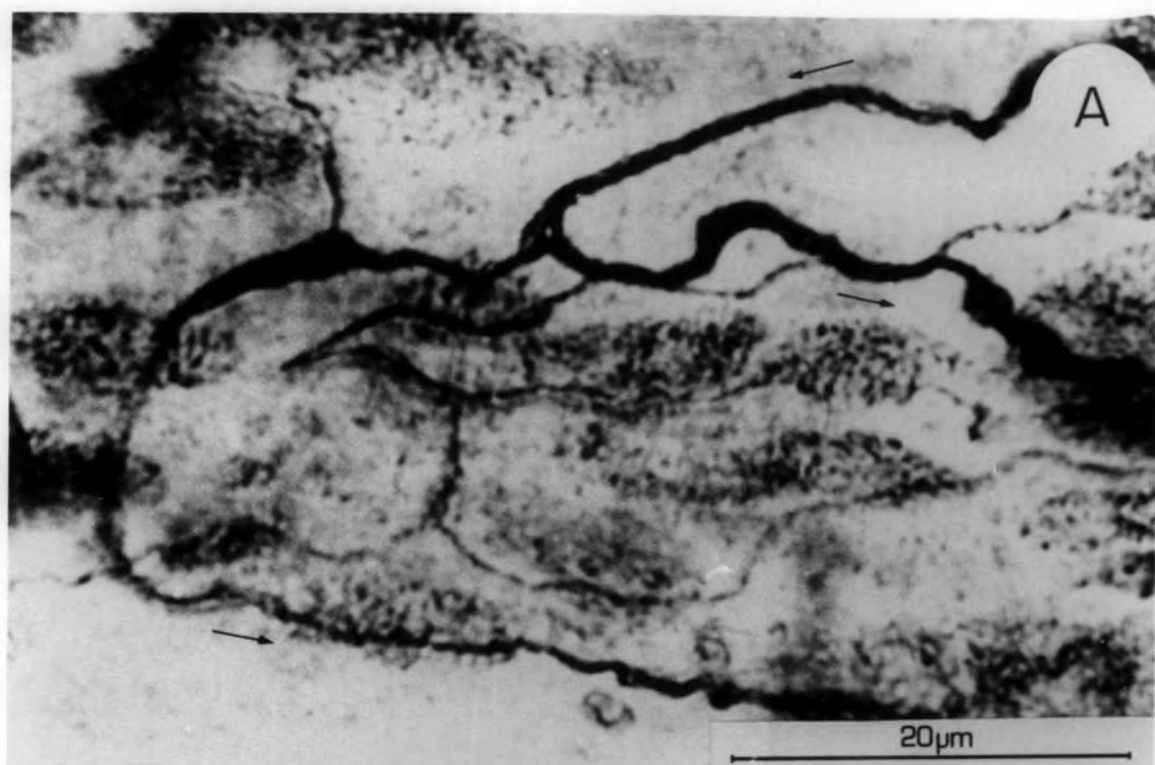


Plate 3.30

Invading axons

These plates show examples of invading axons. In each case an axon arrives in a spindle, makes terminals (T) then leaves. The routes taken by these axons are arrowed.

Plates A, B & D are from spindles 74 days R.T., and Plate C is from a spindle 102 days R.T.

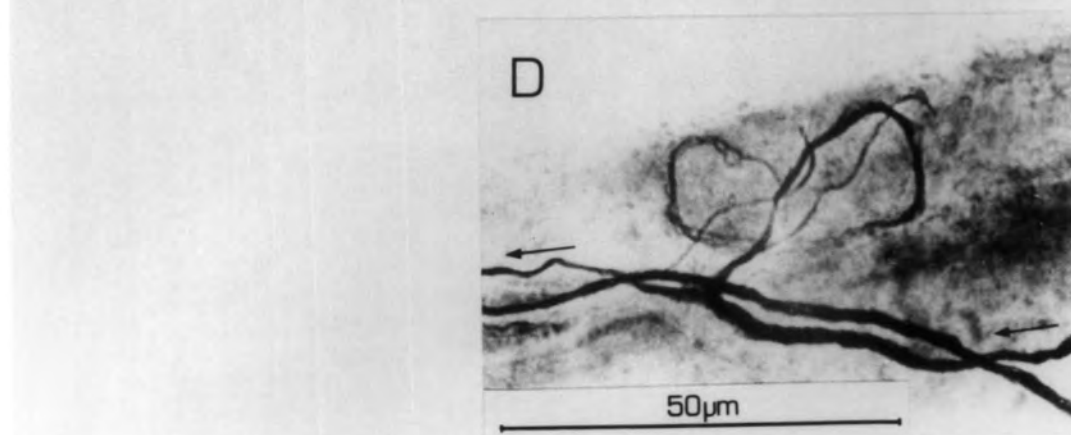
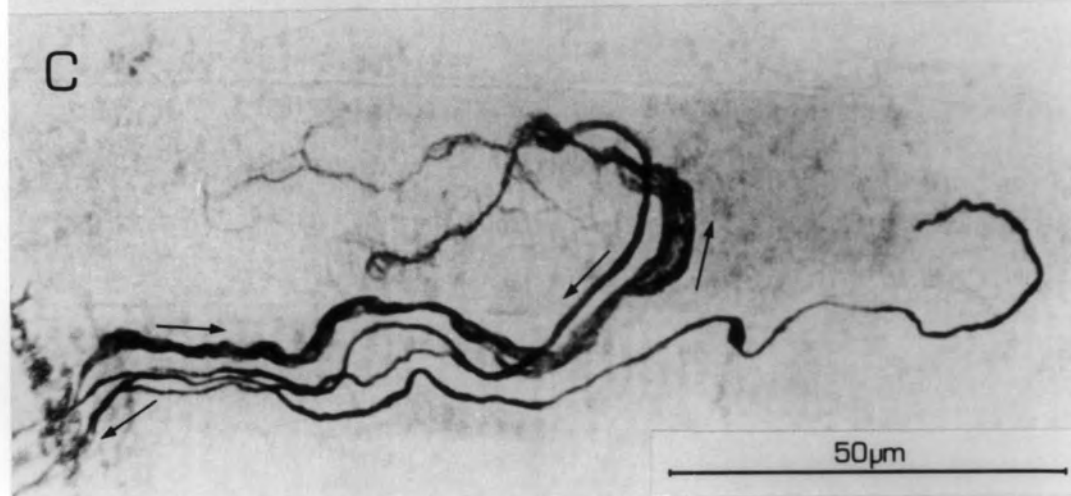
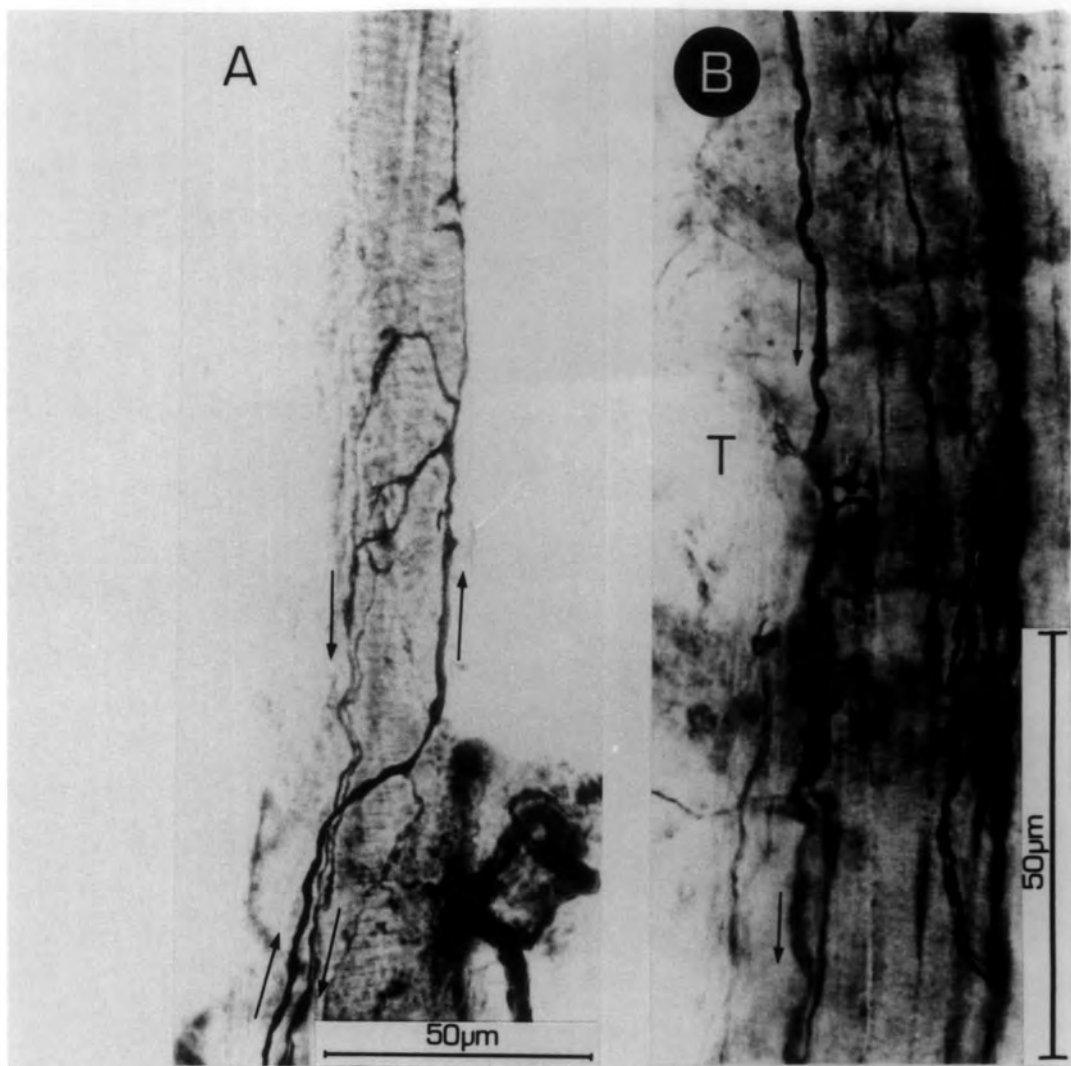


Plate 3.31

Reinnervated Golgi tendon organs

- A. 25 days R.T. The form of the ending has an entirely normal appearance, being supplied by a single unbranched Ib axon and having flower-spray type endings.

- B. Another example of a normally restored tendon organ 102 days R.T.

- C. A slightly unusual restoration of a tendon organ in that the branches of the Ib stay closer together within the capsule than usual; compare with the two examples above.

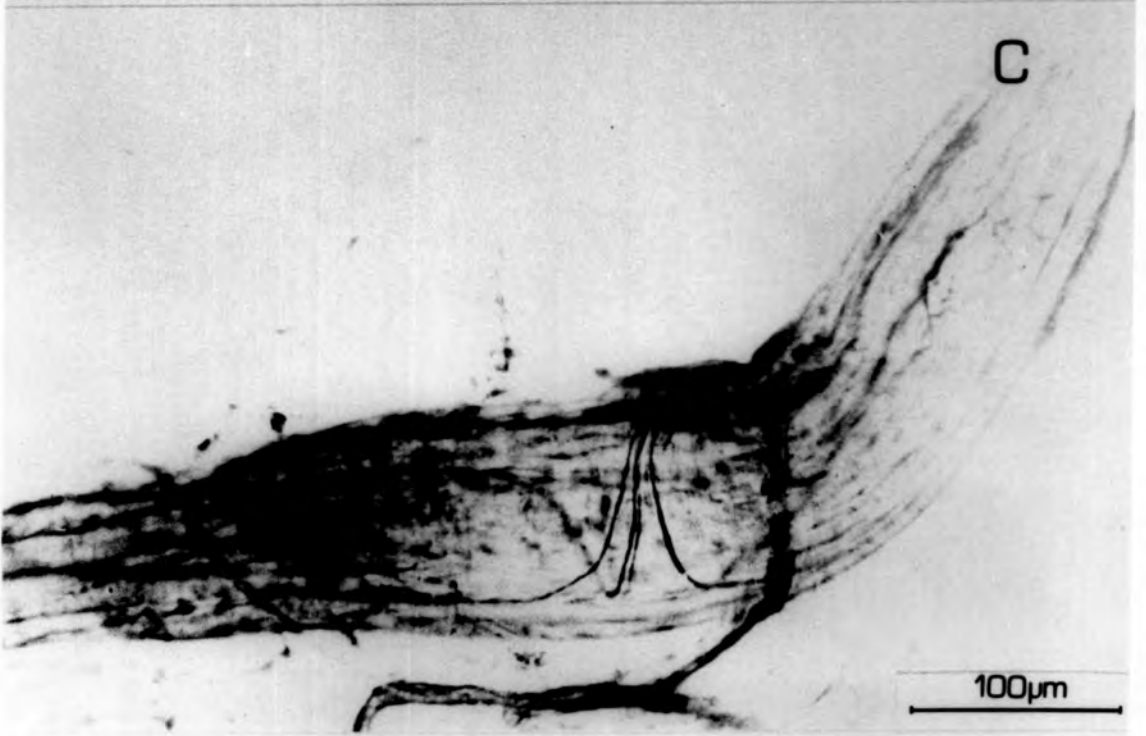
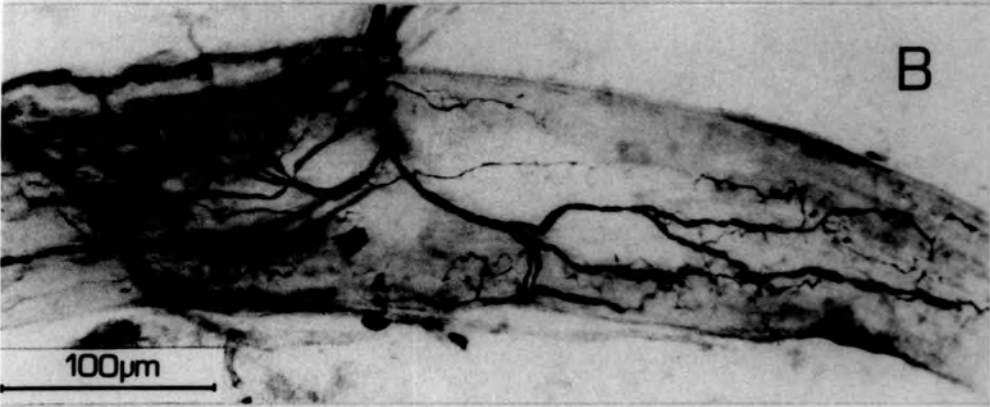
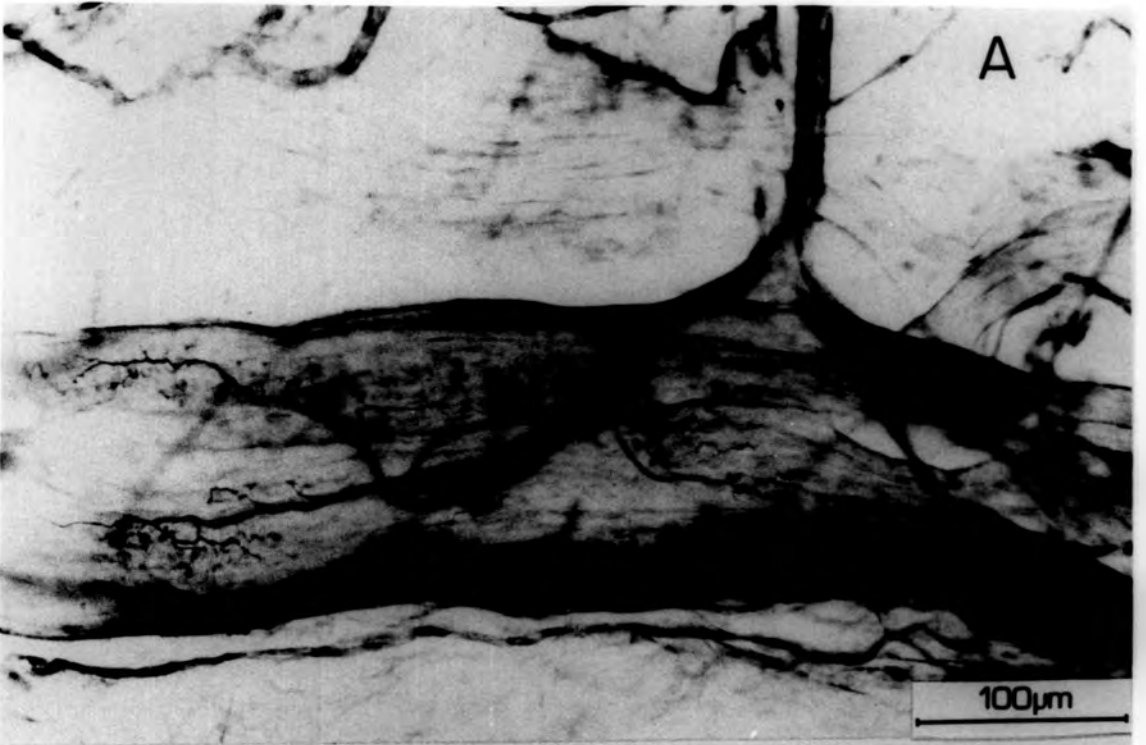
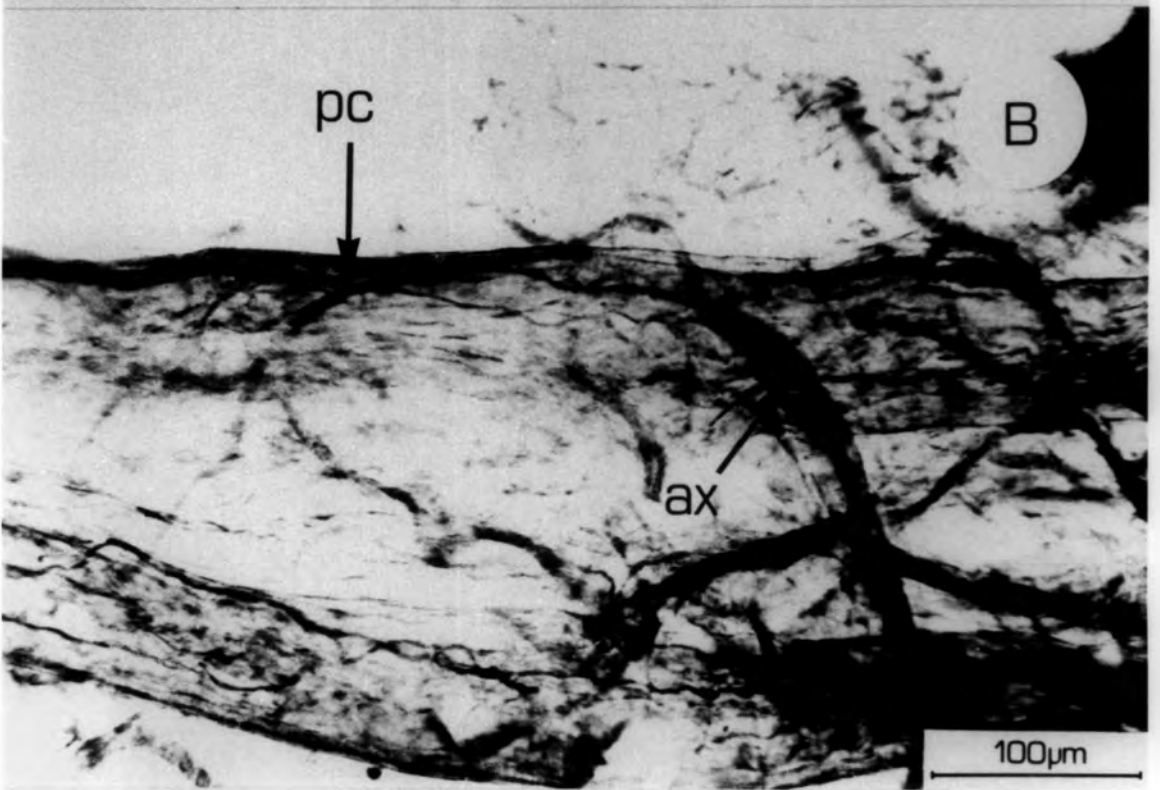
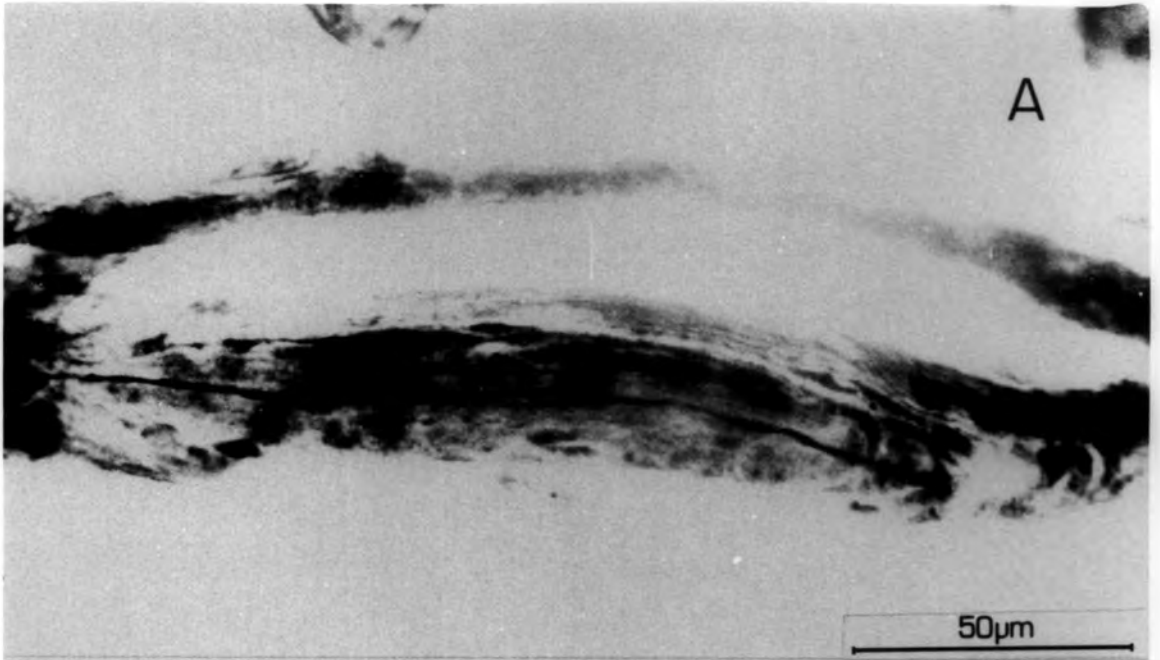


Plate 3.32

- A. A paciniform corpuscle after 25 days R.T. It has an entirely normal appearance, being cylindrical and containing a long straight axon terminal. The supplying axon has previously branched and supplies another normal paciniform corpuscle.
- B. A Golgi tendon organ and paciniform corpuscle (p.c.) after 25 days R.T. The corpuscle is innervated by a branch of an axon (ax), another branch of which forms a normal spray of endings on the tendon organ.



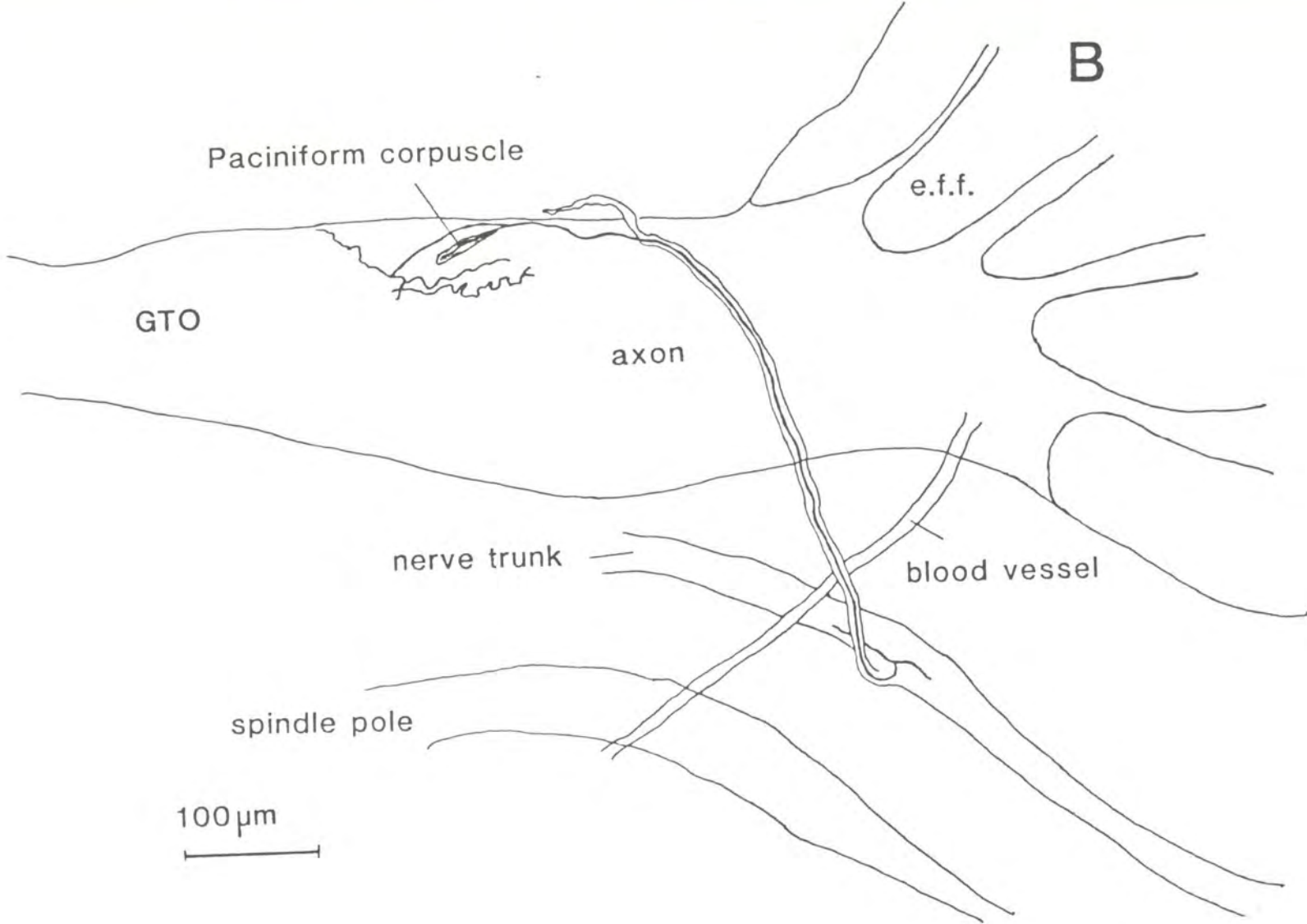


Plate 4.1

The equatorial region of spindles after nerve cut.

- A. The typical overall appearance of the equatorial region, 12 weeks after nerve cut. Numerous very fine axons can be seen coursing over the entire area. There are some half-rings (arrow) recognisable on a bag fibre.
- B. A higher magnification of the primary terminals shown in A. It shows a longitudinally disposed axon, producing, at regular intervals, half-rings which wrap around the intrafusal bag fibre.
- C & D. Axonal dispositions, 30 and 16 weeks P.O., in the equatorial region . No recognisable form of termination is evident.

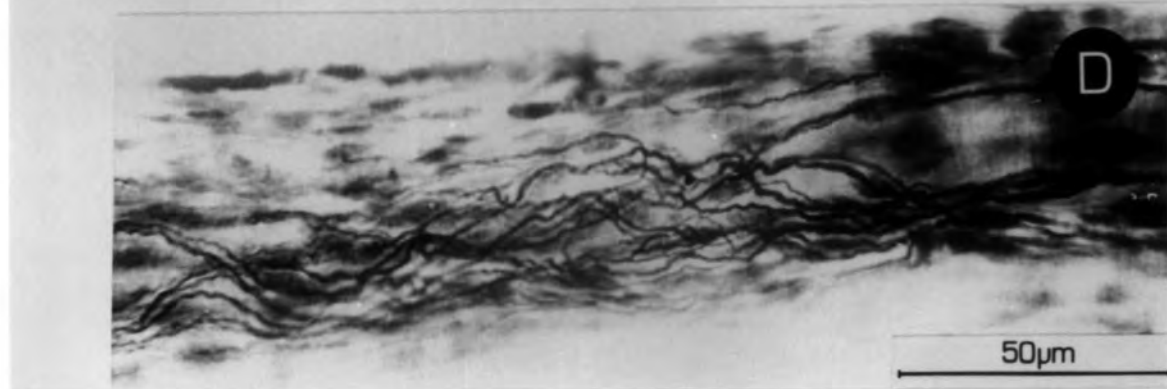
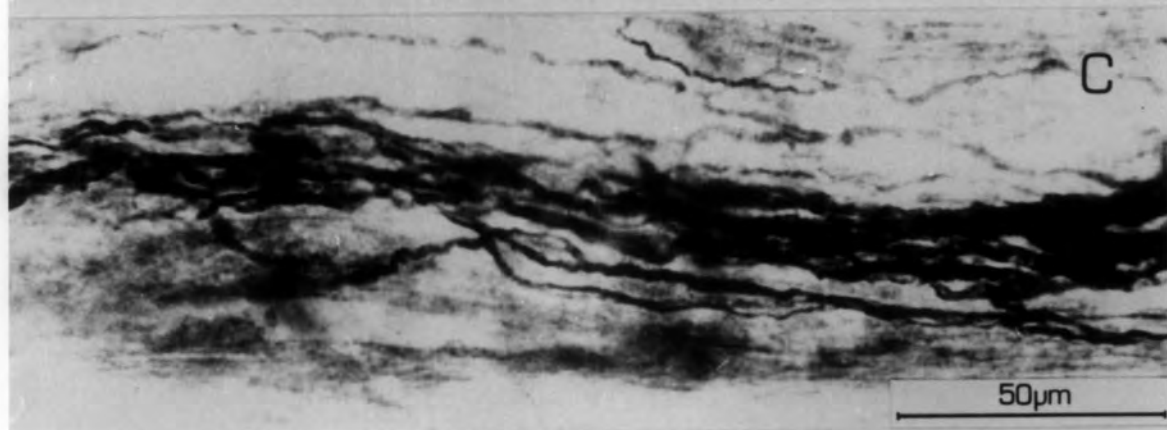
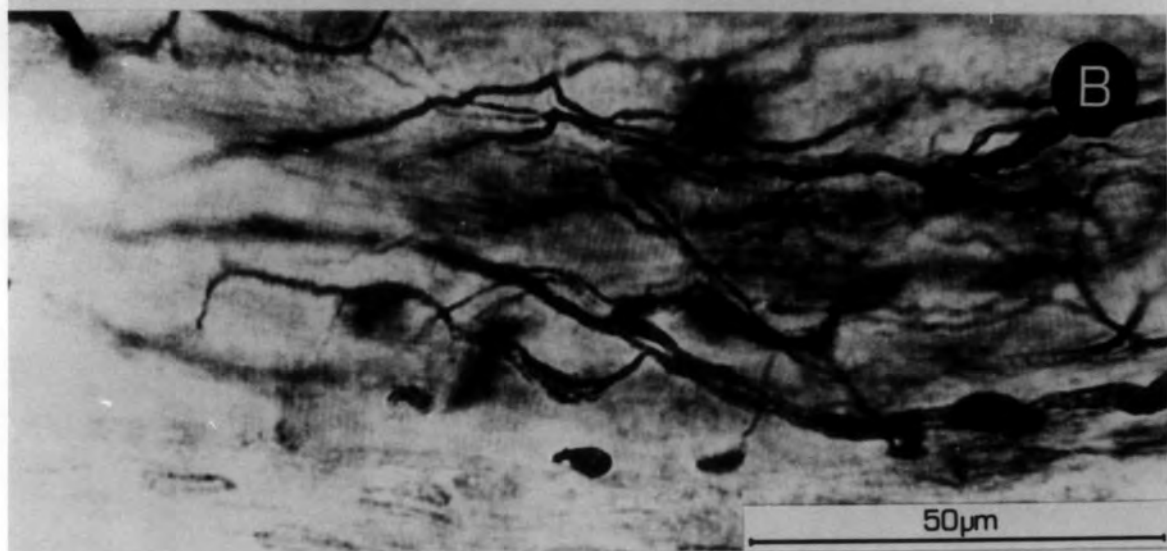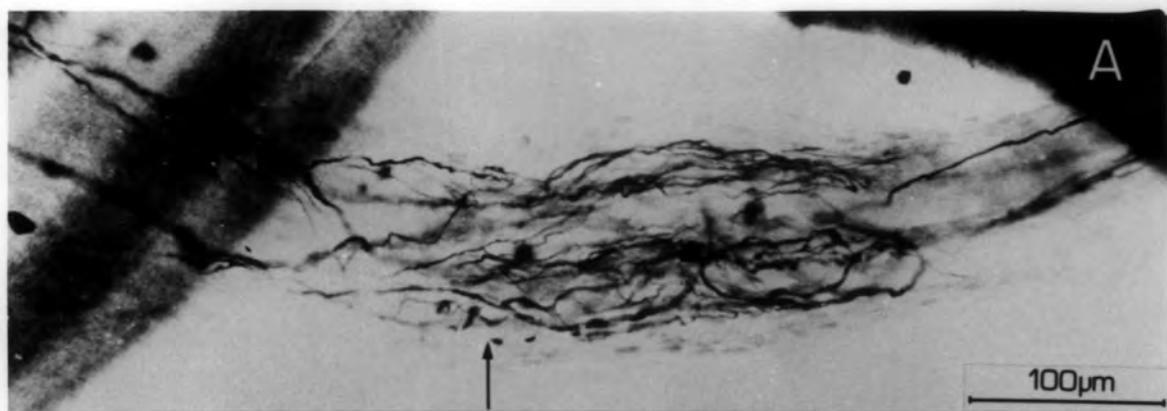


Plate 4.2

- A. A Golgi tendon organ, 30 weeks P.O. It is supplied by a single axon which bifurcates before entering the receptor.

- B. A Golgi tendon organ, 30 weeks P.O. This example is supplied by five axons which remain separate, as far as they can be traced in the nerve trunk.

- C. Axonal varicosities after 6 weeks P.O. These are frequently seen at other periods of time P.O.

- D. A presumed sensory axon at 30 weeks P.O. This example is accompanied by five much thinner axons which contribute to the chaotic formations in the equatorial region.

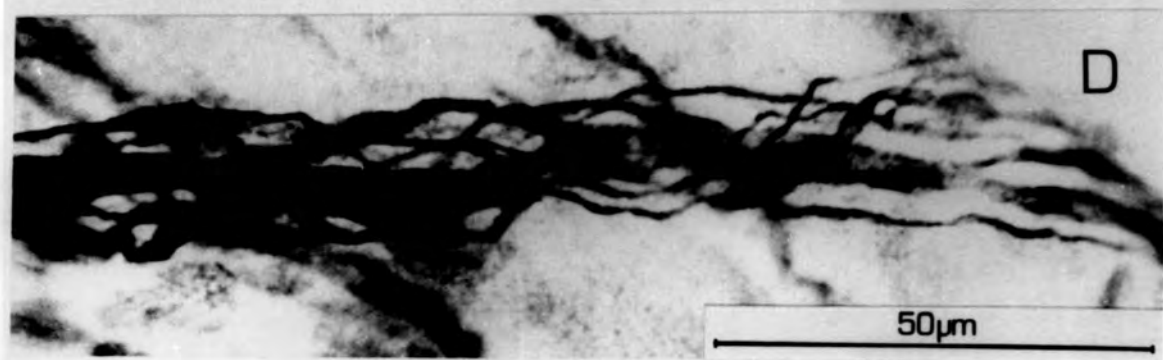
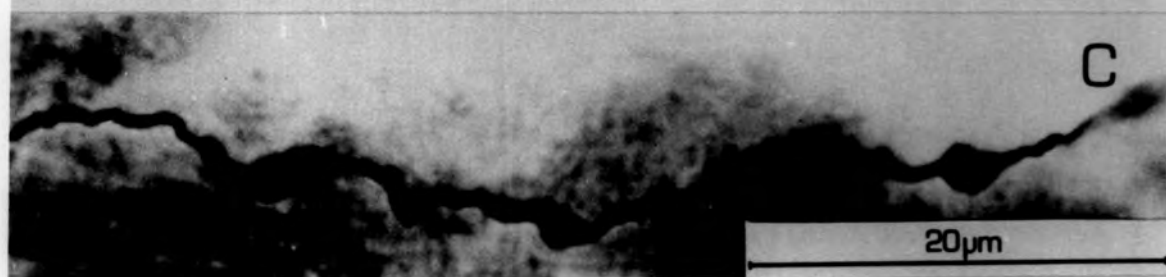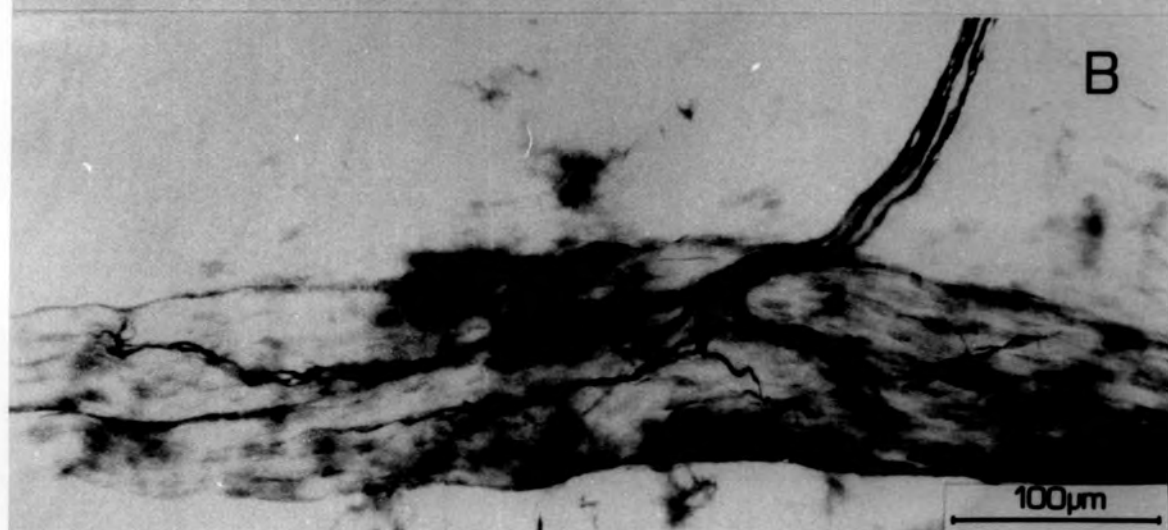
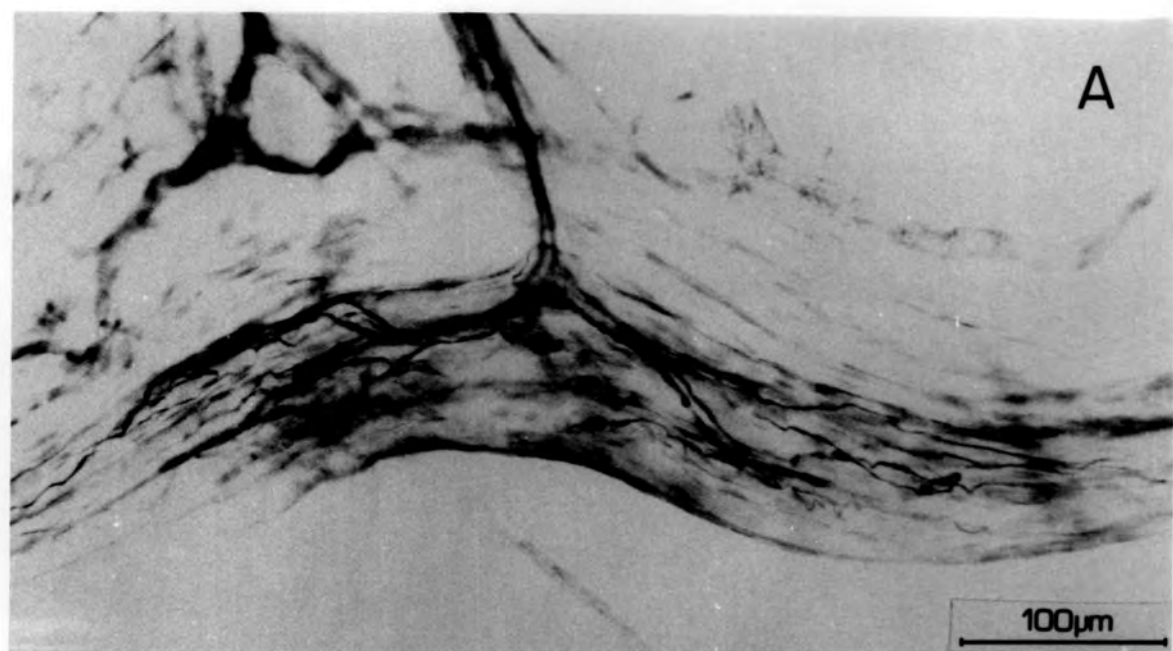


Fig. 4.1

A CCTV tracing showing the course of an axon over the pole of a spindle, 8 weeks after nerve section. This relatively large axon (diameter $4.7 \mu\text{m}$) enters the spindle juxta-equatorially, and travels polar, only to turn around and leave the spindle by the same route. This axon is probably not a Ia axon, as no attempt is being made at elaborating terminals or even branching. A more probable explanation is that it is supplying a GTO or a paciniform corpuscle. This axon would then be considered to be an afferent invader.

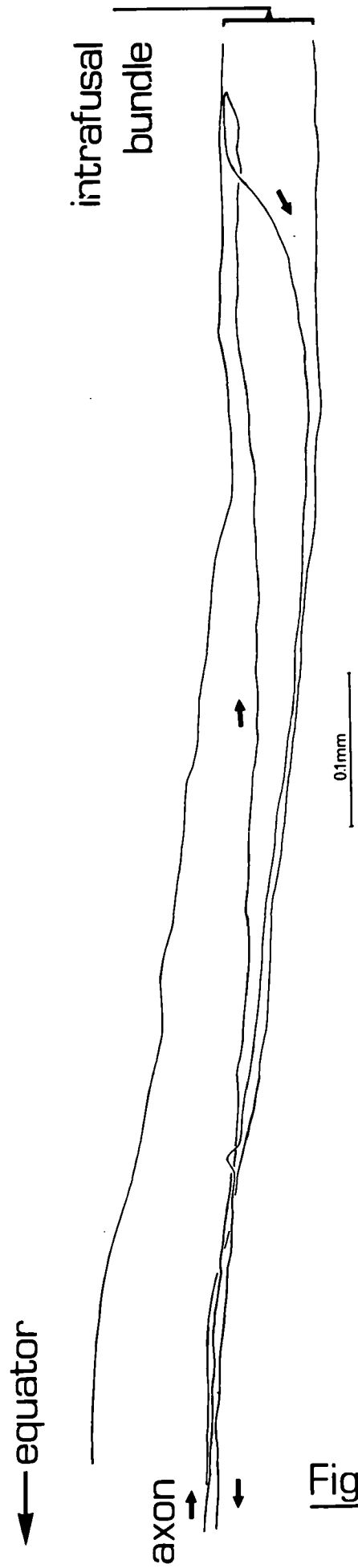


Fig 4.1

Plate 4.3

- A. Example of a large-diameter recurrent axon within the equatorial region after 8 weeks P.O.

- B. Large terminal swellings situated on extrafusal muscle fibres, 12 weeks P.O.

- C. Paired, clubbed terminations seen intrafusally after 6 weeks P.O. This is a common configuration in post-cut material.

- D. Equatorial configuration of axons after 30 weeks P.O. Some spiralling of axons is present (arrow).

- E. Equatorial region after 12 weeks P.O. Occasional small bulbous terminations are seen, as shown.

The thick axons , of which an example is shown in A., are not considered to be Ia axons, as they make no branches over the spindle. The size of the axon is indicative that it has made a successful reinnervation, and it is known that GTOs are successfully restored. For this reason, such axons are presumed to be Ib axons. It is however possible that these axons are innervating, for example, a paciniform corpuscle.

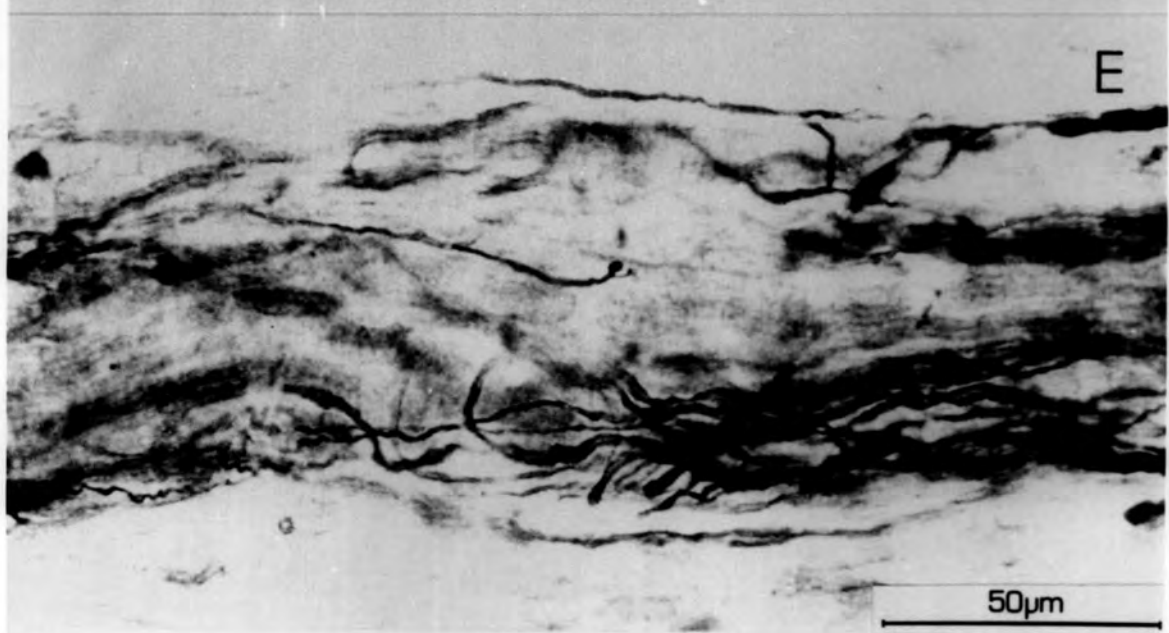
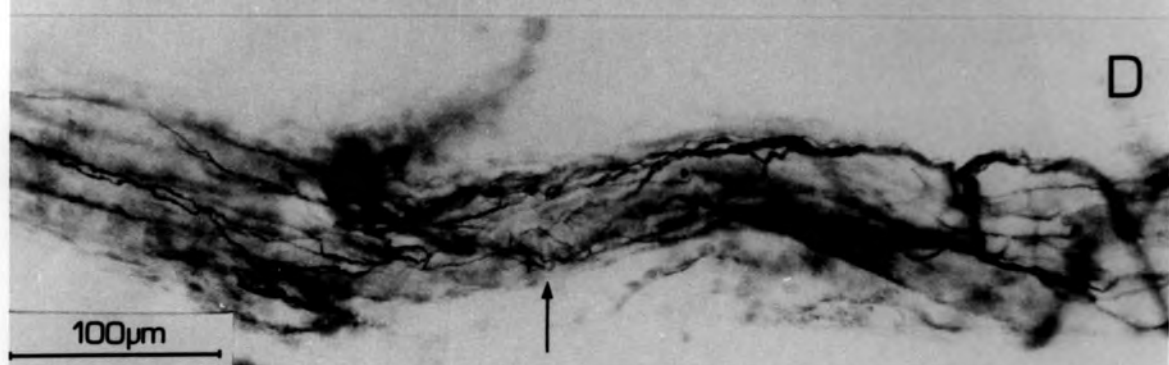
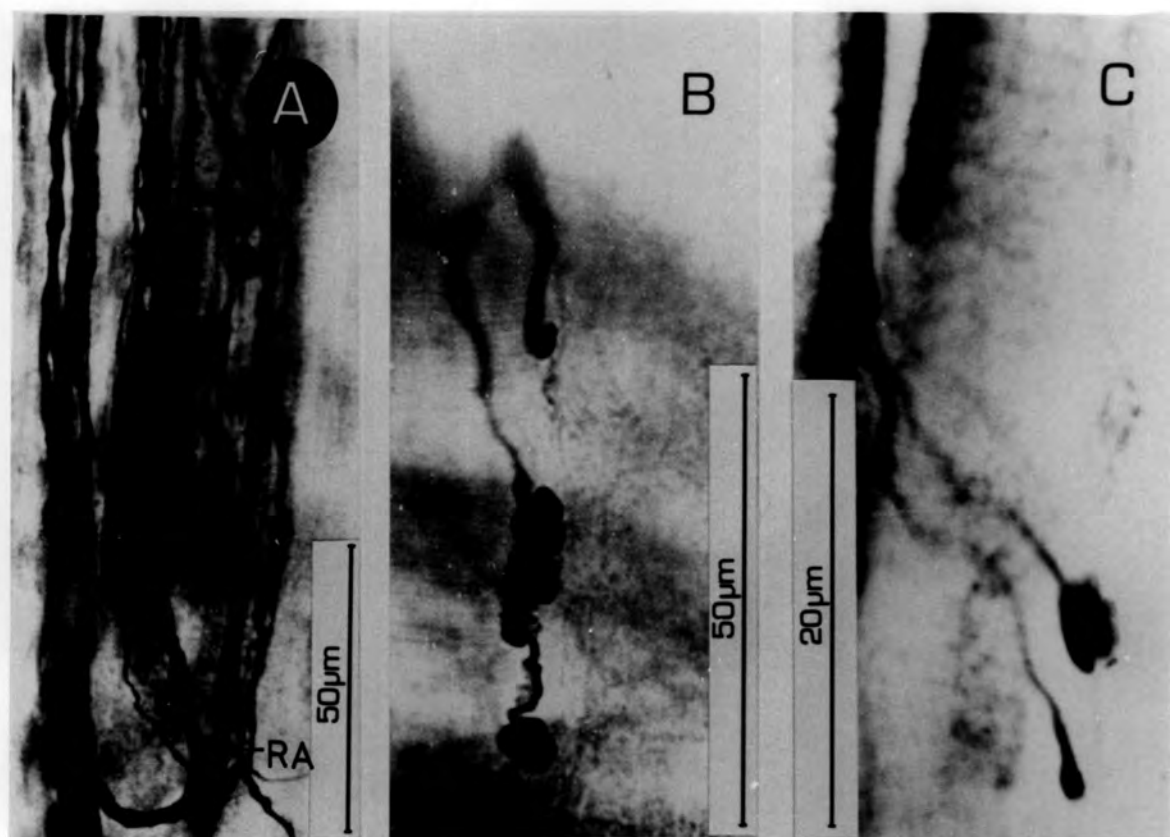
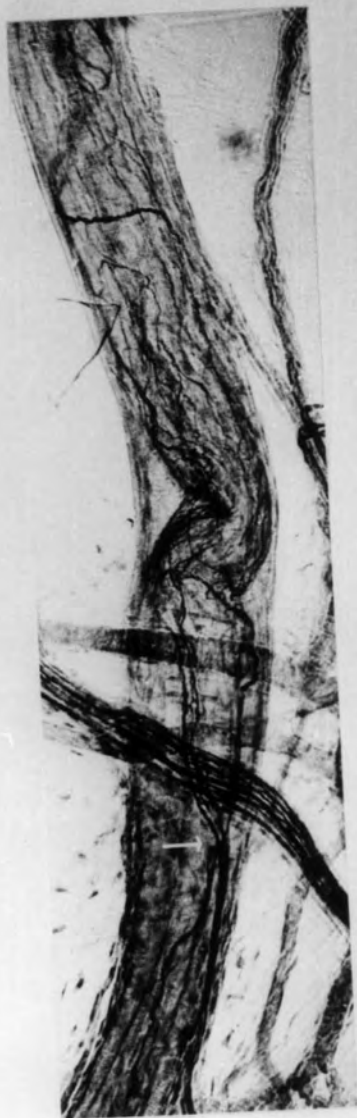

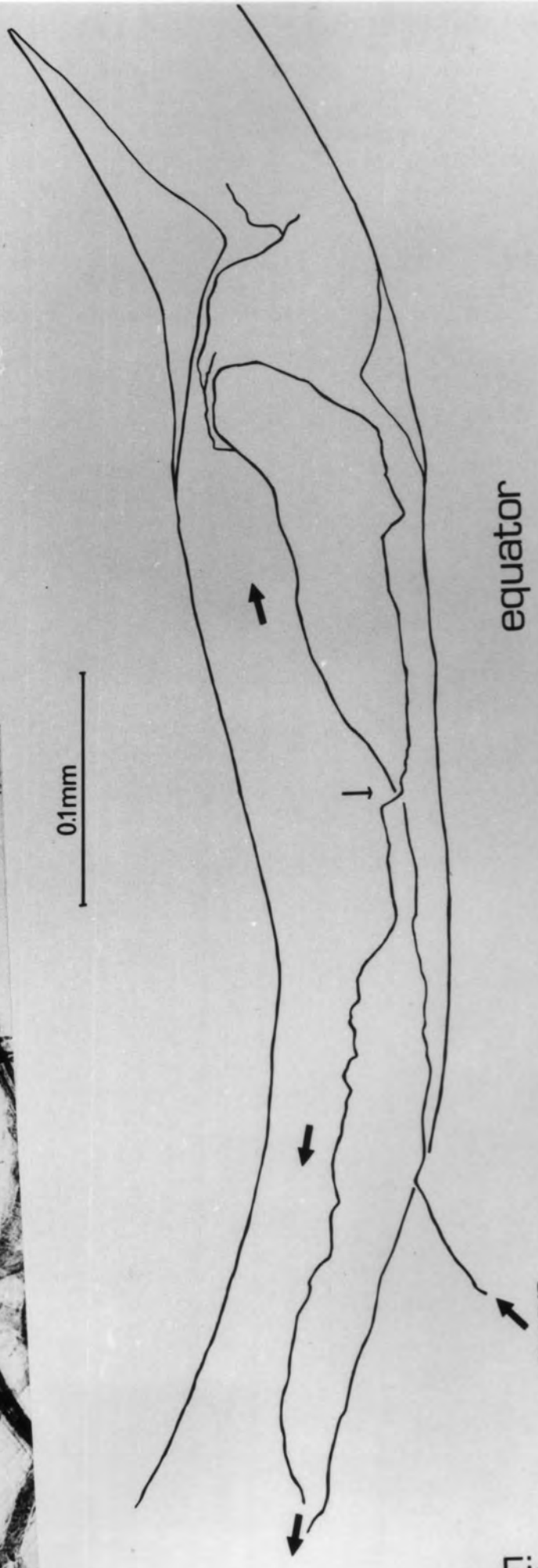
Fig. 4.2

A CCTV tracing made of a muscle spindle 30 weeks after the cut operation, with photomicrograph inset. The white small-headed arrow on the inset marks the point where the axon crosses itself, and corresponds to the equivalent black arrow on the tracing.

The axon can be seen to branch three times over the equatorial region, but recognisable endings are not evident. One branch leaves the spindle via the pole. It can be seen that the peri-axial space is greatly reduced. The fact that this axon is branching over the equatorial region may indicate that it is a Ia axon. It is classified as a rejected Ia axon as one branch leaves the spindle.



0.1mm



equator

axon

Fig 4.2

Fig. 4.3

A CCTV tracing showing the course of an axon on a spindle from 30 week cut P.L. This thick axon enters the spindle, turns and returns to its point of entry via its original route. As it is thick, this implies that it has functional connections elsewhere. For the reasons given for the axon shown in Fig. 4.1 , it is considered to be an afferent invader.

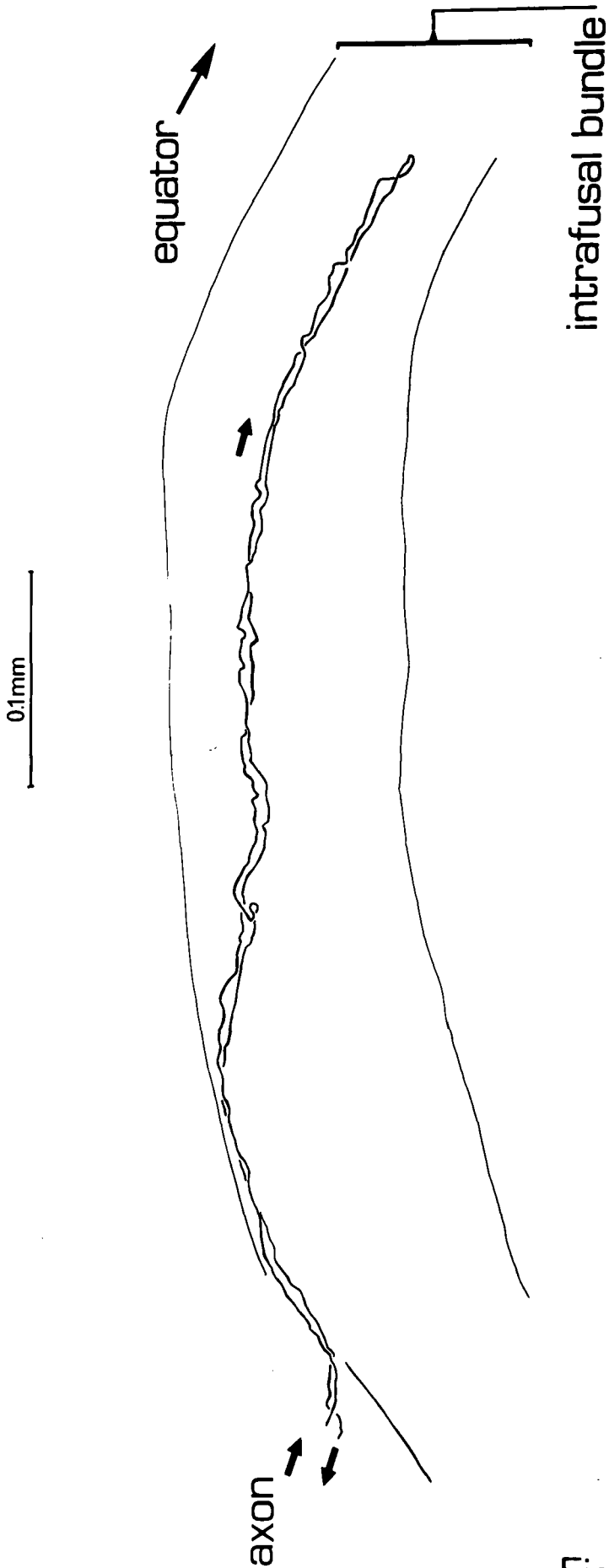


Fig 4.3

Fig. 4.4

A tracing from a photographic montage showing the course taken by a large-diameter axon in the juxta-equatorial region of a spindle, 30 weeks after the section operation. It is considered to be a rejected Ia axon which is not elaborating an ending, despite repeated attempts at restoration.

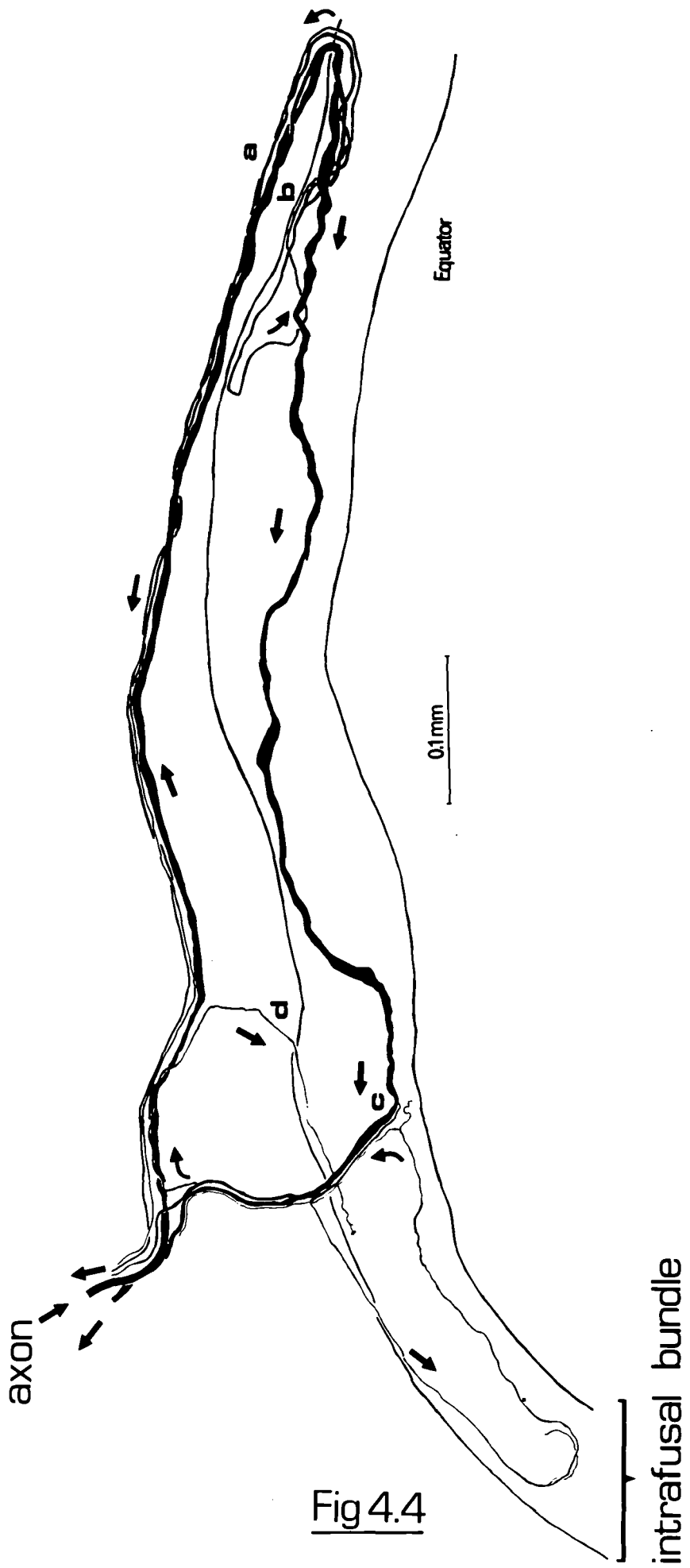


Fig 4.4

Plate 4.4

- A & B. Extrafusal endplates after 8 weeks and 30 weeks P.O. respectively. Both examples show terminal sprouting.
- C. A large axonal swelling situated extrafusally (arrow), 8 weeks P.O.
- D. A p_1 plate after 8 weeks P.O. Ultra-terminal sprouting to an adjacent intrafusal fibre can be seen. Inset is a tracing of the axon and terminals.
- E & F. Extrafusal endplates after 8 weeks and 30 weeks P.O. At 8 weeks P.O. there is a simple fork within the sole-plate. At 30 weeks P.O. there are still only three rudimentary branches.

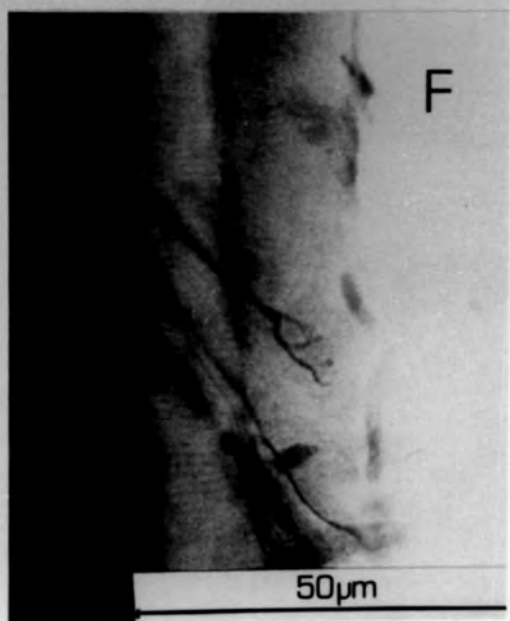
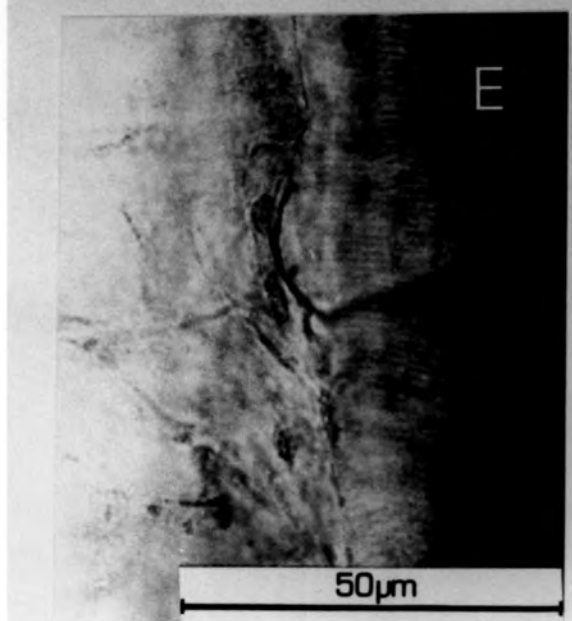
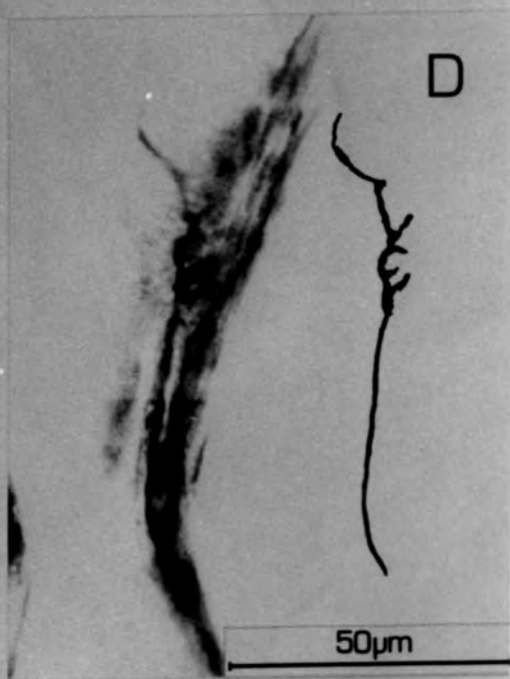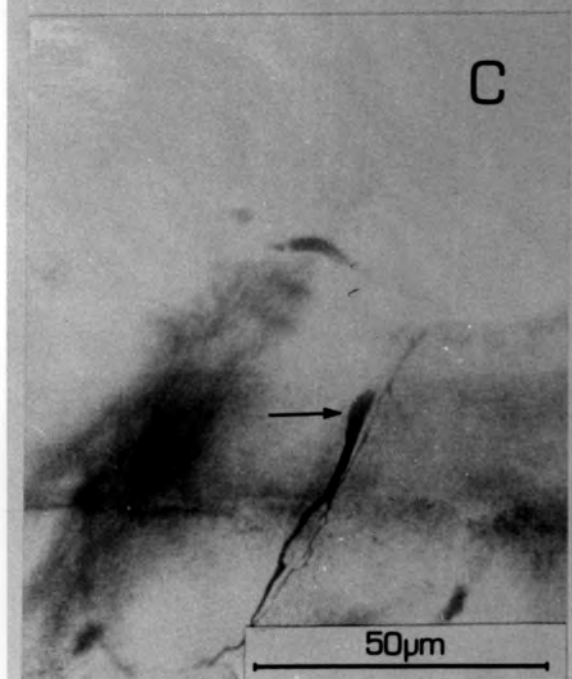
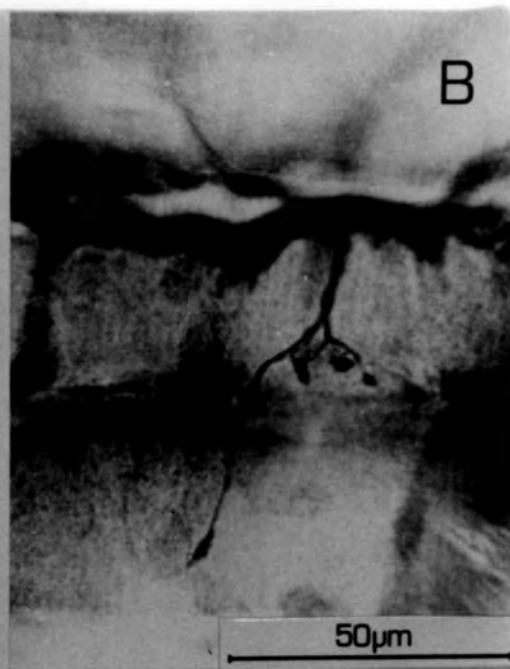
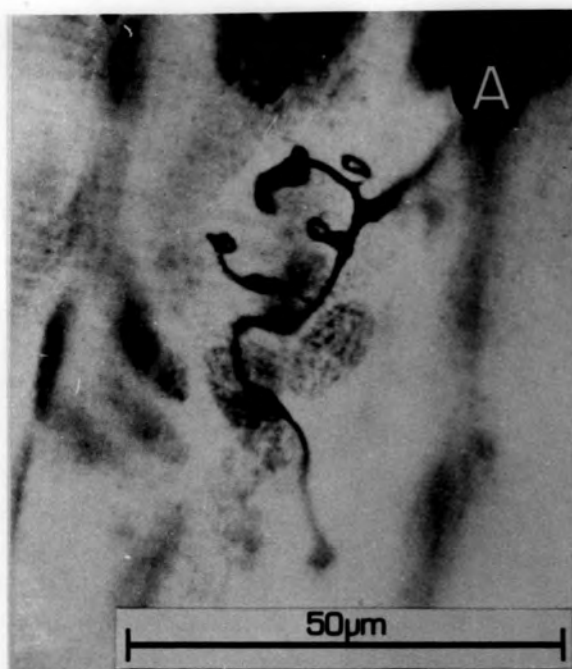


Fig. 4.5

Axonal dispositions in the poles of a spindle after nerve section.
A CCTV tracing of the course of an axon 8 weeks after nerve section.
It is reasoned that this axon is motor, because of its small diameter and its disposition. The fact that none of the normal intrafusal motor endings are elaborated may indicate that this is an alpha invader.

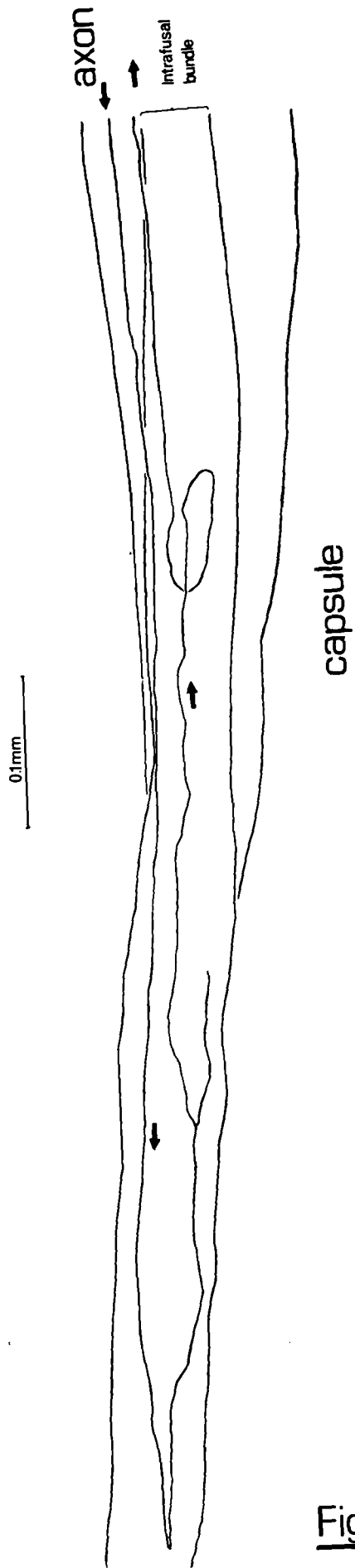


Fig 4.5

Fig. 4.7

Axonal dispositions in the poles of a spindle after nerve section. CCTV tracings of an axon from the poles of a spindle 30 weeks after nerve section. The lower tracing is at a higher focal plane. It can be seen that the axon branches profusely and terminals are apparently disposed over several sites on the intrafusal bundle, and leaves the spindle by five different routes. It is considered to be an alpha invader for the same reasons as for the axons in Figs 4.5 and 4.6.

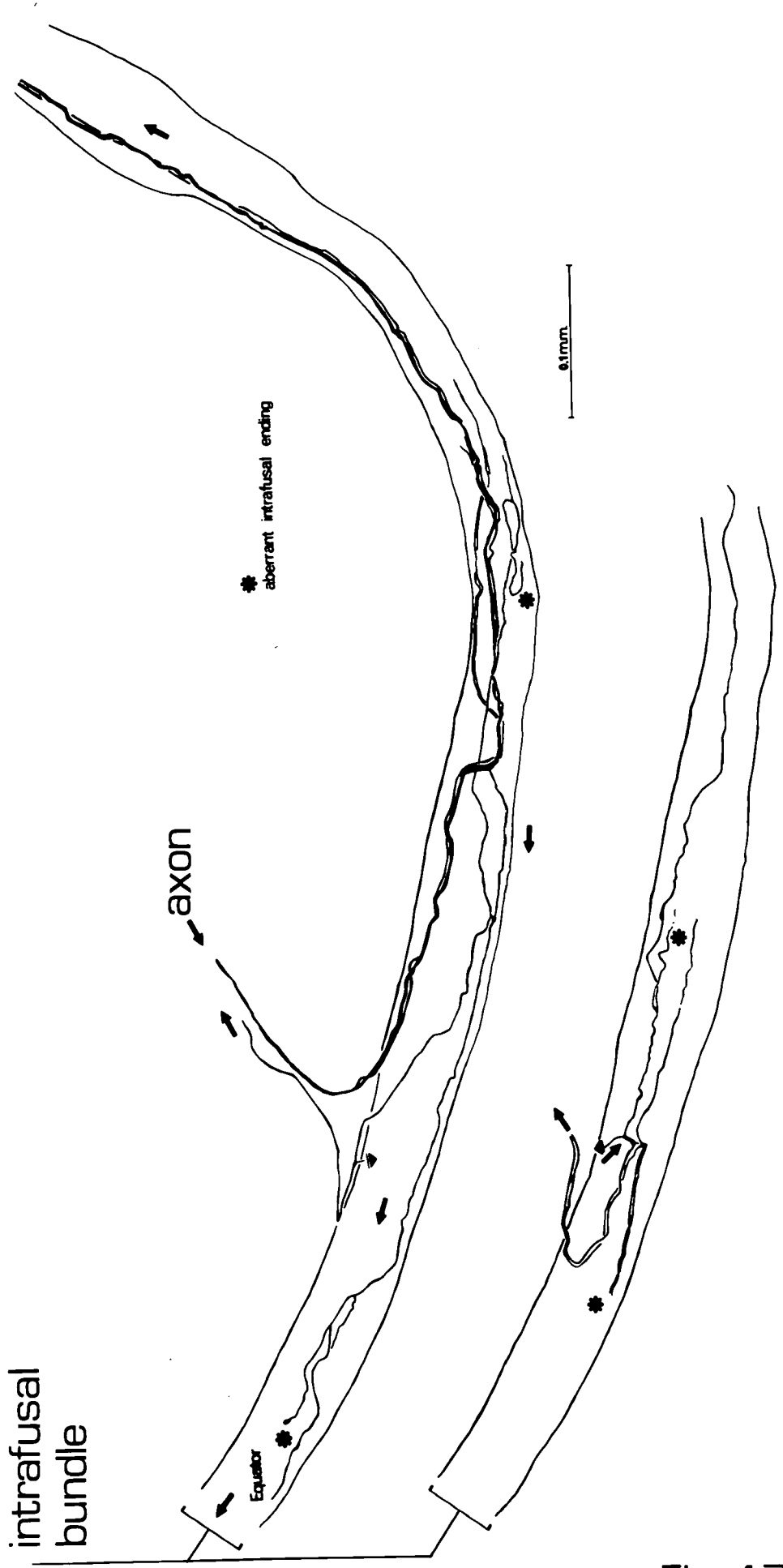


Fig 4.7

Fig. 4.8

A CCTV tracing showing the formation produced by an axon in the polar region, 30 weeks after nerve section. The single axon can be seen to branch before entering the spindle. Three branches leave the spindle through a separate trunk, one branch returns up the supplying nerve trunk. One of the branches forms a presumed extrafusal endplate on an extrafusal muscle fibre and a collateral branch from the axon is disposed to an adjacent extrafusal muscle fibre. It is presumed that this is an alpha invader.

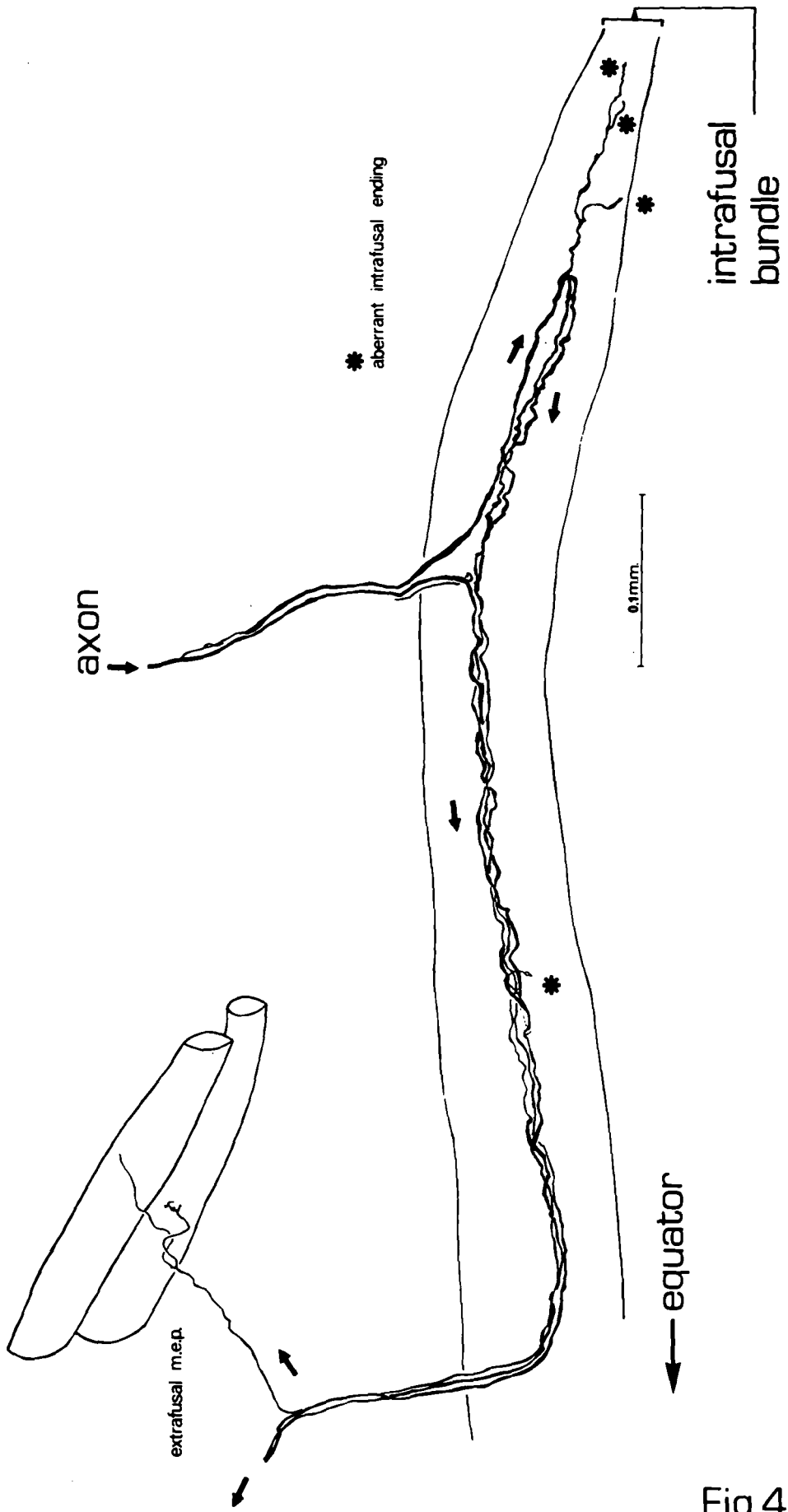


Fig 4.8

Plate 4.5

- A. The only example of a p_2 plate found in the de-afferentation and cut material, 8 weeks after the operation.
- B. An intramuscular nerve trunk 10 weeks after the de-afferentation and cut operation. A solitary axon can be seen with a growth cone (g) in the nerve trunk (n). No axons were found in the muscle spindle at this stage.
- C. An intramuscular nerve trunk 13 weeks after the de-afferentation and cut operation. Although no axons were found in any spindles at this stage, several axons are visible within the nerve trunk.
- D. A nerve trunk in peroneus longus 3 weeks after the ventral root crush and peroneal crush operation. Only one axon is visible in this intramuscular nerve trunk, and no muscle spindles or tendon organs were found which had any innervation.
- E. The first example of innervation in a spindle 5 weeks after the ventral root crush and peroneal crush operation. It consists of a very fine axon which travels longitudinally on the intrafusal bundle (ib), but no terminals are visible.
- F. An intramuscular nerve trunk from the ventral root crush and peroneal crush material, 5 weeks P.O. Again only one axon is present, but its diameter suggests it is sensory in origin as would be expected.

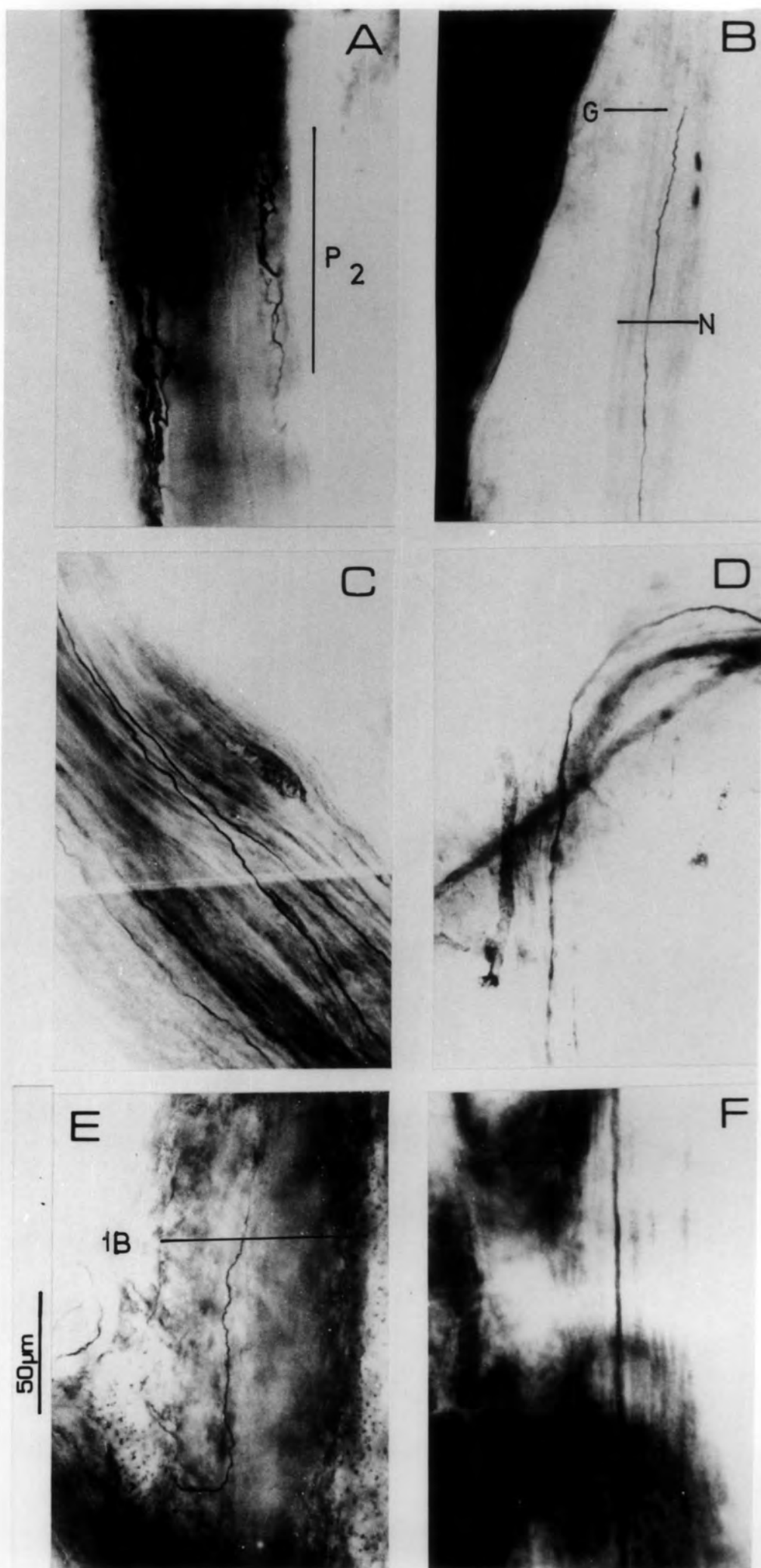
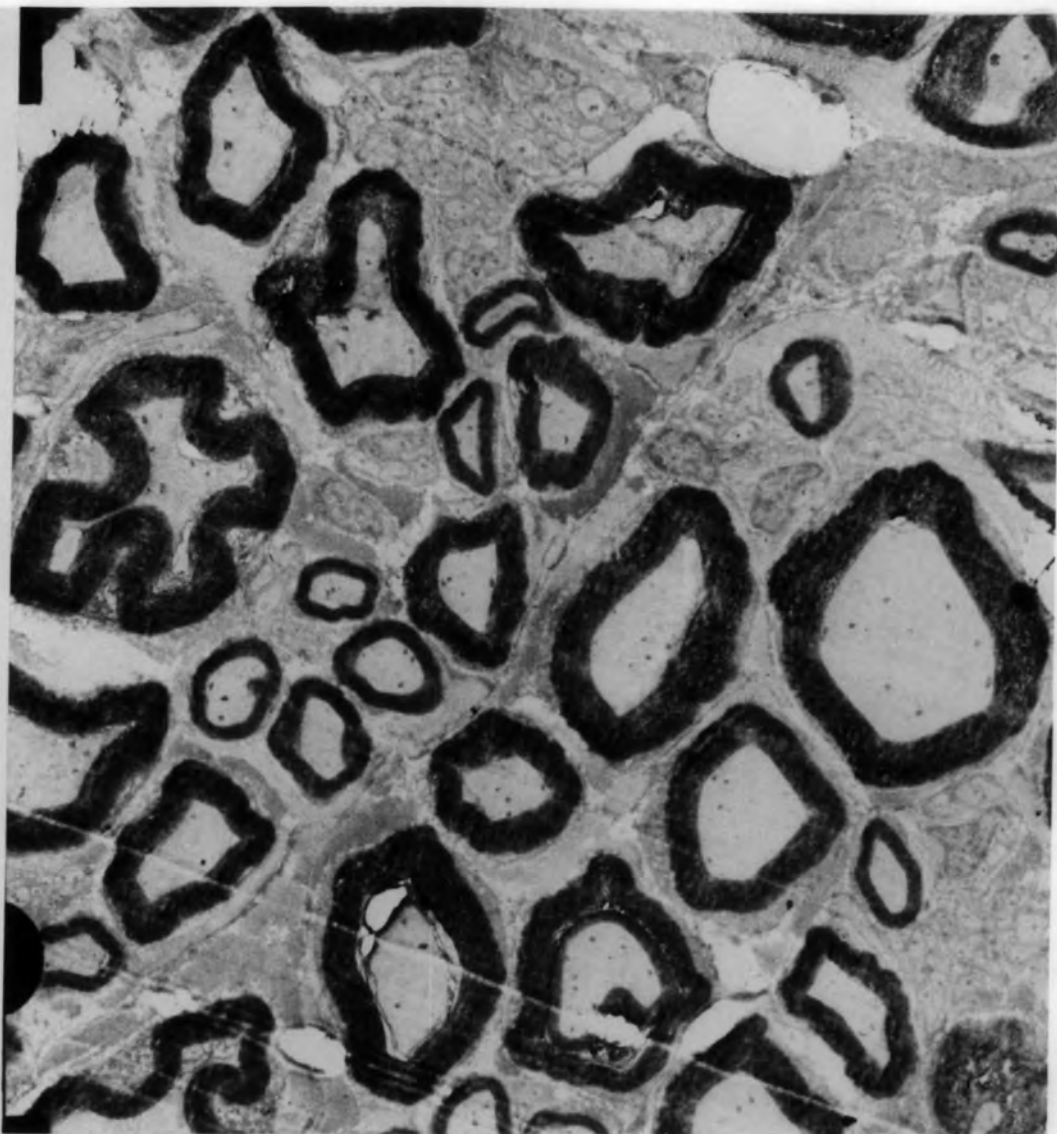


Plate 4.6

Electron micrographs of the common peroneal nerve

- A. This shows myelin profiles present in the normal nerve. It can be seen that the thickness of the myelin sheath is thin on small-diameter axons and thick on large-diameter axons.
- B. The typical myelin profiles seen in the peroneal nerve, distal to the site of freeze injury, 4 weeks after the freeze operation. It can be seen that all the myelin sheaths are thin, no matter what the size of the axon. No examples were seen of normal myelin profiles, indicating total success of the freezing technique.

A



X 7000

X 7500

B

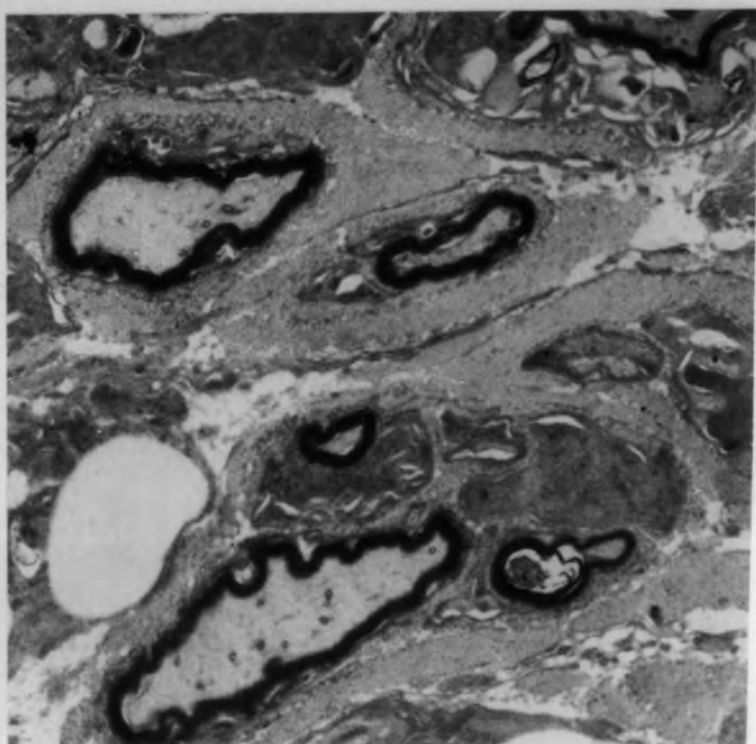
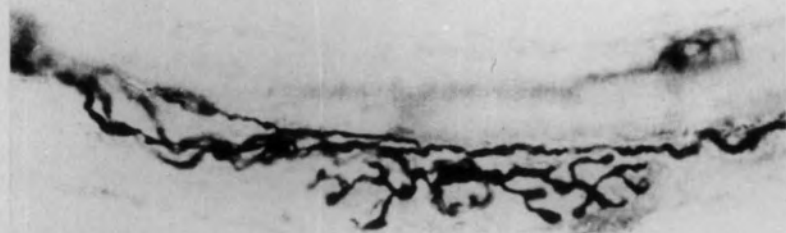


Plate 4.7

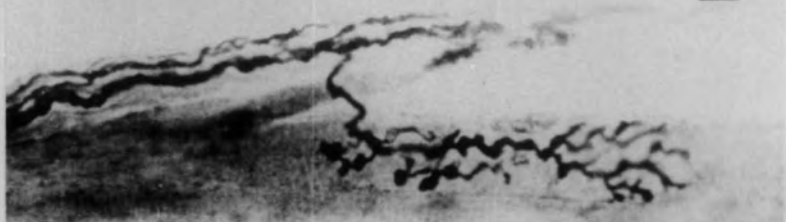- A. A p_2 endplate after 19 days R.T. It is supplied by a single axon, and has a characteristically normal appearance with clubbed endings.
- B. A p_2 plate of normal form and distribution after 19 adys R.T. The supplying axon has branched (b), but its final destination cannot be determined.
- C. An example of the p_1 innervation after 19 days R.T. It shows the classical " Y "-shaped formation, both plates disposed on a single bag fibre.
- D. Another p_2 plate after 19 days R.T. The single supplying axon (a) branches at (b), immediately prior to forming the plate. The branch (c) then travels along the intrafusal bundle to form another p_2 plate (not shown) on another intrafusal fibre.

A



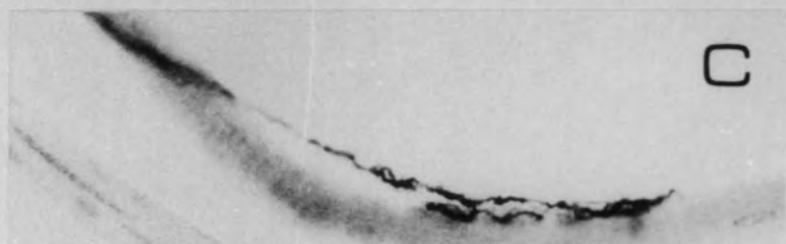
50 μ m

B



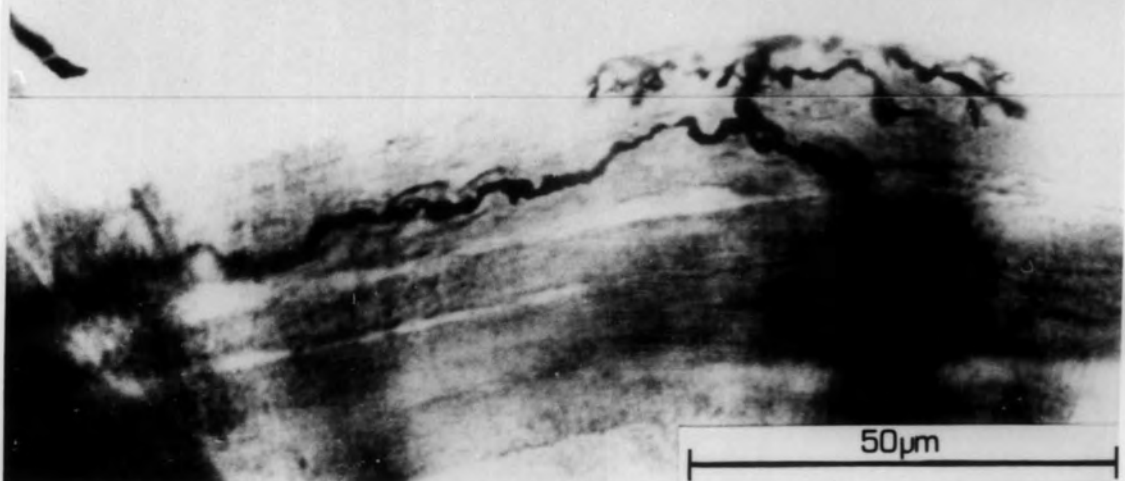
50 μ m

C



50 μ m

D

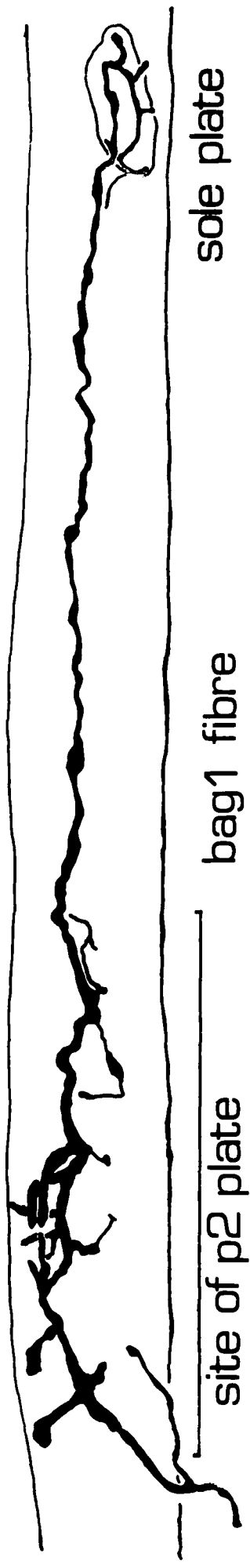


50 μ m

Fig. 4.9

A tracing from a photographic montage from freeze material. The axon produces branches, some of which terminate in clubbed swellings characteristic of a p_2 plate. The overall disposition is also that of the p_2 plate. The ultra-terminal sprout extends to a recognisable sole plate where some branching occurs.

← equator



site of p2 plate

bag1 fibre

sole plate

50µm

Plate 4.8

Muscle spindles from P.L., 8 weeks after the nerve freeze operation.

A. A muscle spindle with two primary endings (p and p'). Both the supplying axons have been torn off during the teasing process, though it can be seen that they approached the equator from opposite directions, This implies that the formation has not occurred due to the sprouting of a single Ia axon, but rather that this is a restoration of a pre-existing situation. The separation into two bundles can be seen where the primary (p') is formed, though it does form terminals on the other bundle. Two secondary endings (s) are also present. None of the sensory endings on this spindle show the characteristic form of their ending, though they are distributed normally.

B. The intrafusal bundle showing a primary (p) and a secondary (s) ending. It can be seen that the primary ending does not form regular spirals, though half-ring formations are present. The secondary terminal is poorly developed. No peri-axial space was present in this spindle. (This is not shown, as the contrast between the bundle and the capsule was too great.)

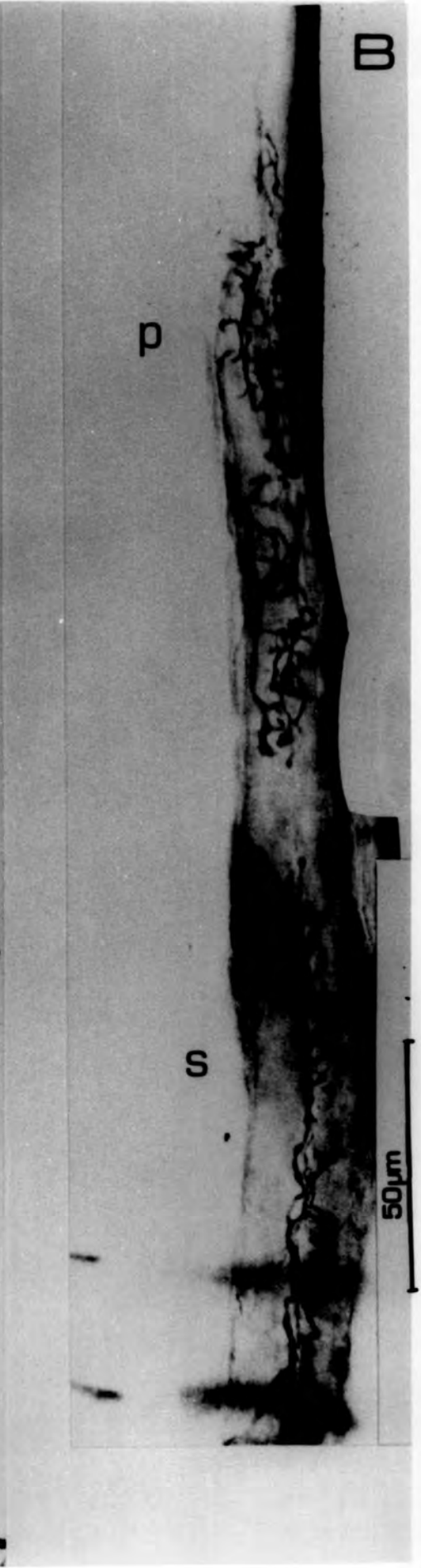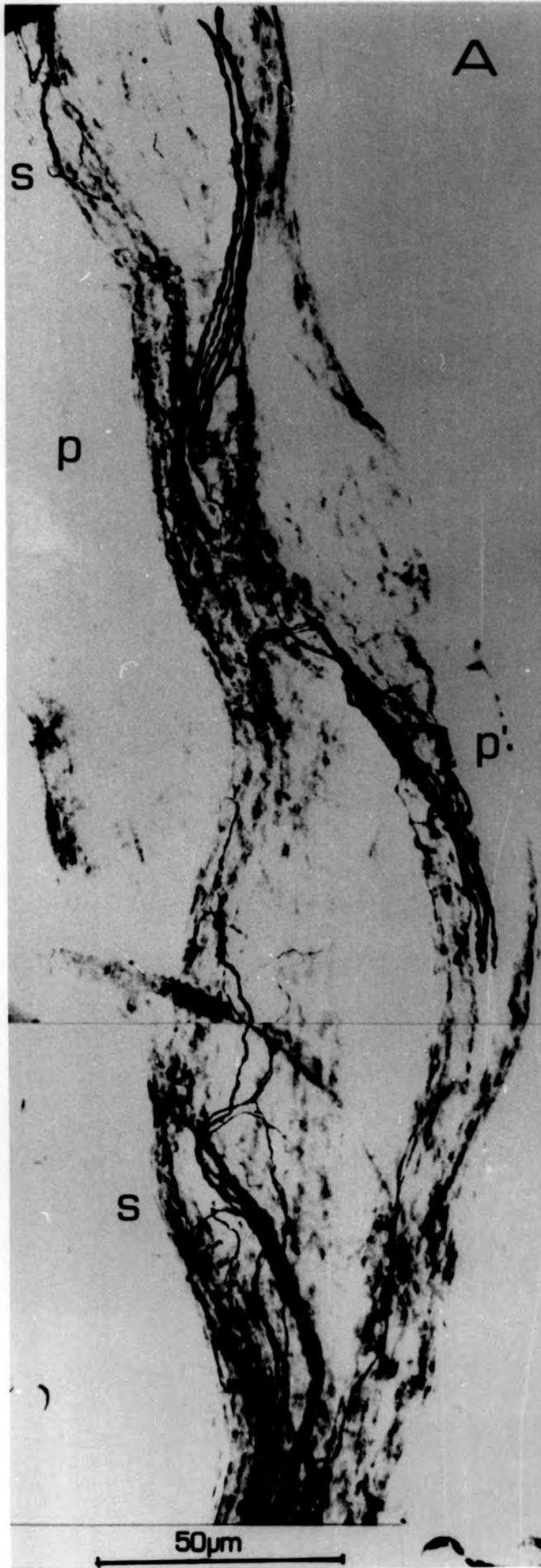
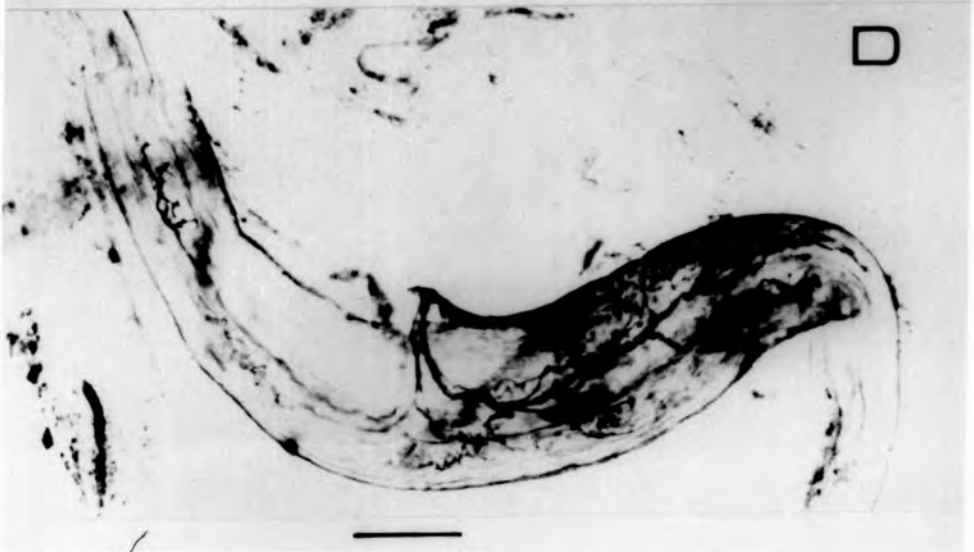
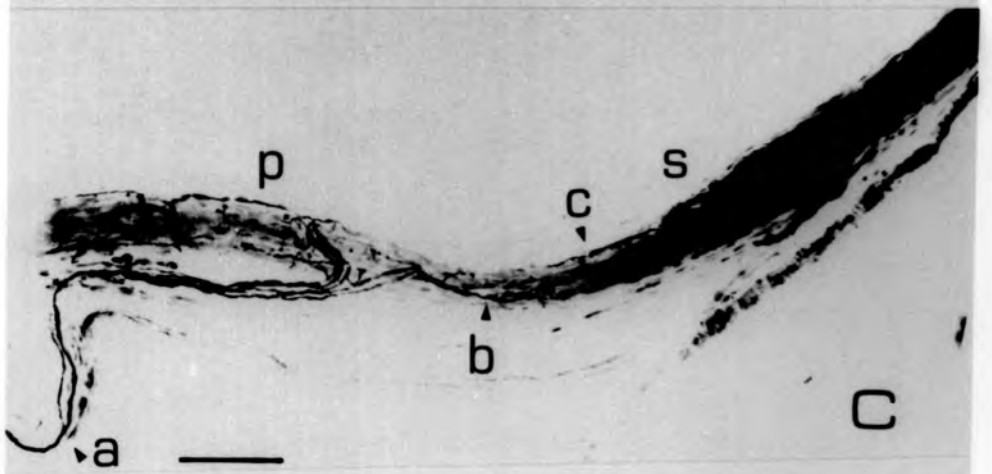
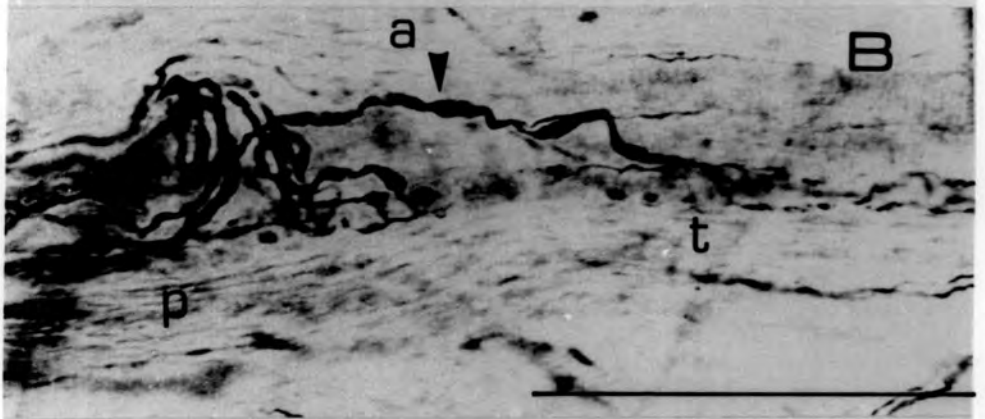
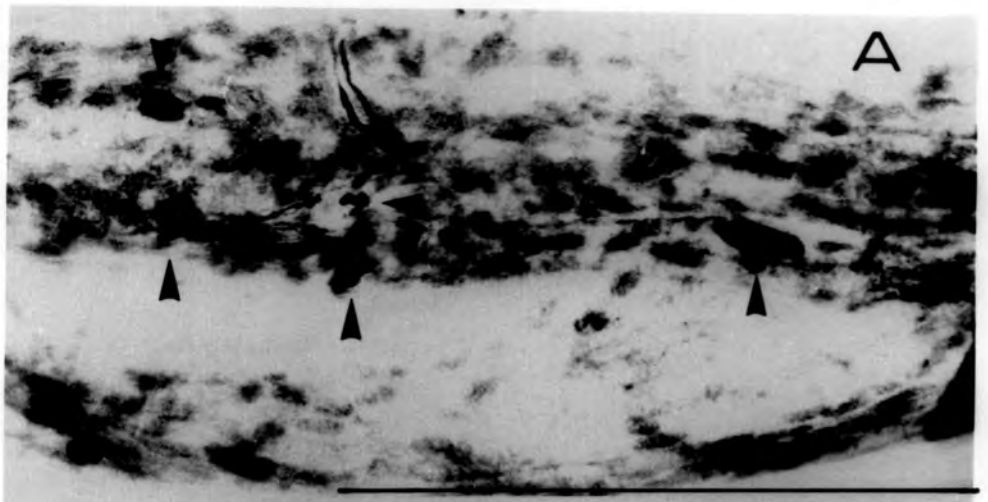


Plate 4.9

Muscle spindles from P.L., 8 weeks after the nerve freeze operation.

- A. The equatorial region of a spindle. It is supplied by a single axon which branches within the capsule. The branches end in lozenge-shaped swellings (arrowed), distributed over the intrafusal bundle.
- B. The equatorial region of a spindle. The primary terminal is restored (p), but there is a branch (a) which forms terminals (t) ending in the S_1 position.
- C. The equatorial and juxta-equatorial regions of a muscle spindle. The Ia axon branches (a). The larger of the two branches supplies the equatorial region directly. The smaller diameter branch travels to the S_1 position. It branches at (b). One branch terminates in an axonal swelling within the secondary elaboration at (s), the other returns to the primary ending (c).
- D. A GTO showing a normal restoration.



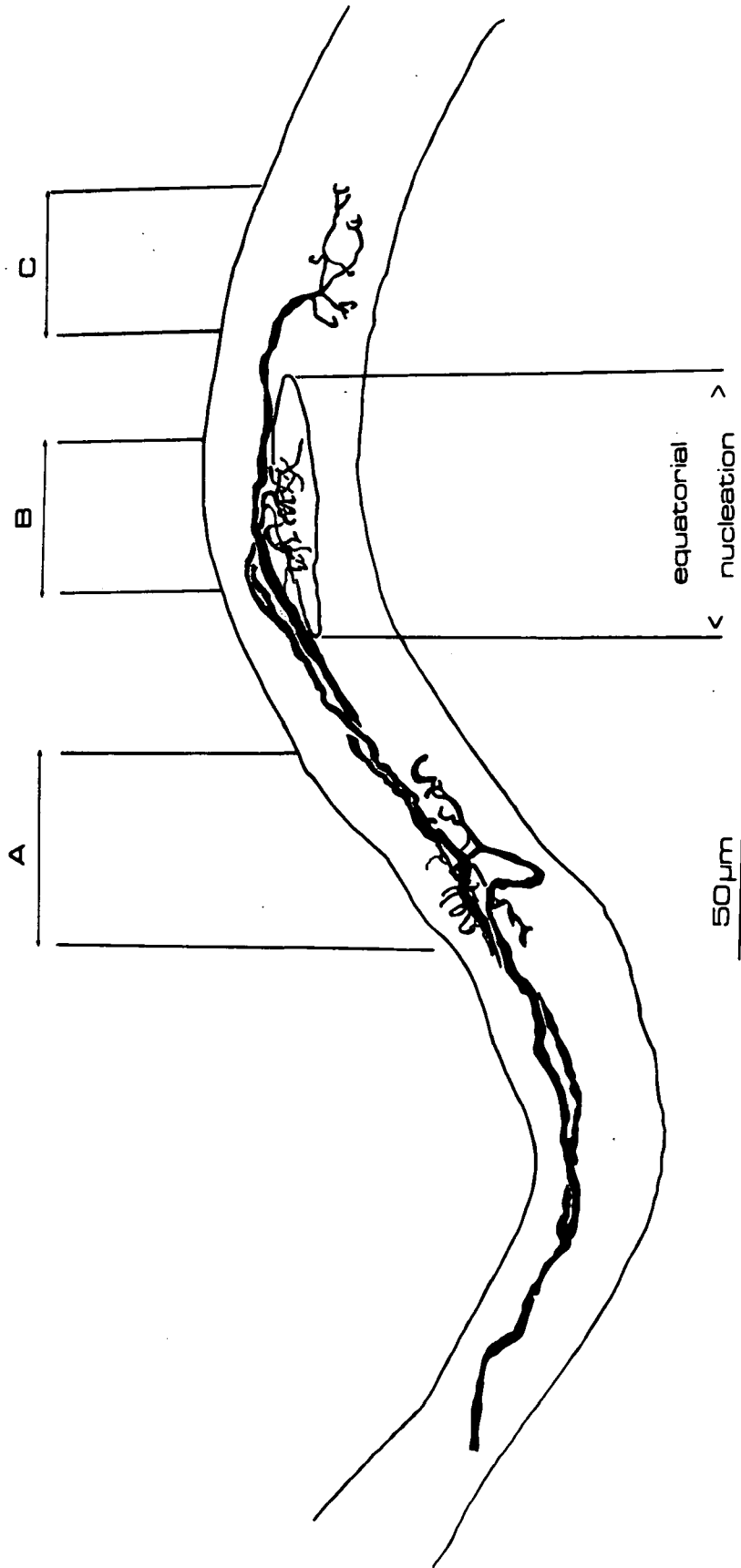
Bar = 50 μ

Fig. 4.10

Sensory endings in a muscle spindle 8 weeks post freeze

An axon approaches the equatorial region of the spindle from the pole. It divides, and one branch forms terminals in the S_1 position (A). The other branch divides again above the terminals at A. One of these branches traverses the equatorial region and forms a poorly-restored secondary terminal (C); the other divides again before it forms terminals over the equatorial nucleation (B), mainly on bag₂ and chain fibres.

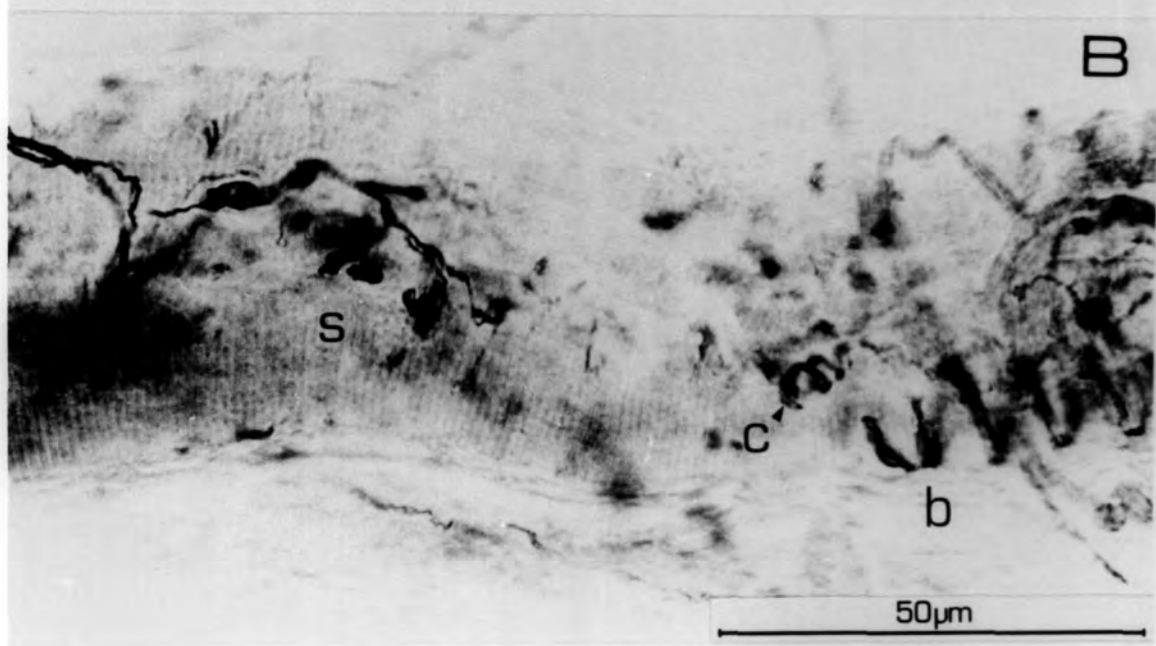

This is presumed to be a group II axon because its most extensive terminals are secondary endings and it approaches the equatorial region from the pole. This indicates that the site-type specificity of sensory innervation is breaking down.



Fig

Plate 4.10

- A. The primary restoration from P.L. muscle, 21 days after nerve entry crush. Terminals can be seen to be restored on both bag₁ and bag₂ fibres. Regular spiralling of normal pitch/ diameter ratio is visible on the bag₁ fibre. The dark staining within the spiralling axons is the myonuclear bundle.
- B. The juxta-equatorial region from the same spindle as above. A secondary ending in the form of a flower-spray terminal is distributed mainly to the chain fibres (s). Part of the primary ending can be seen to be forming regular spirals on a chain fibre (c).



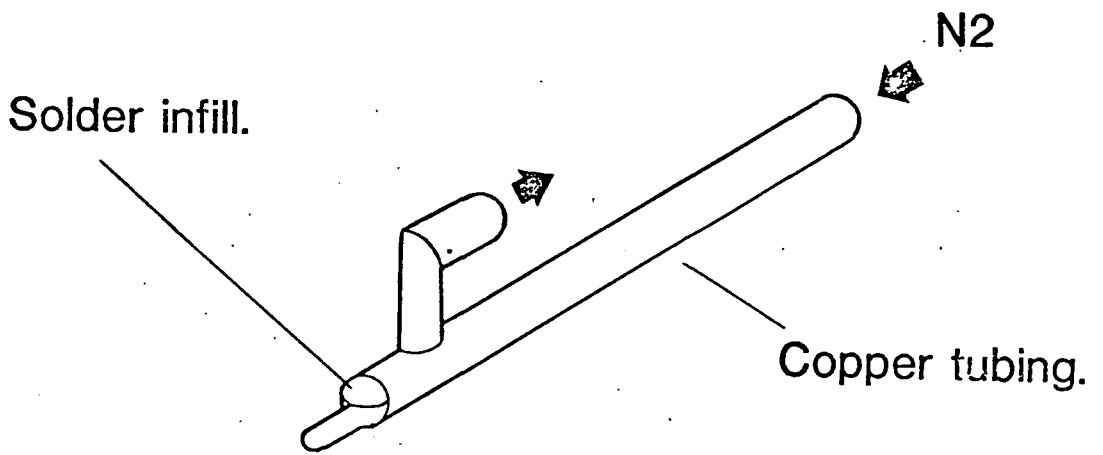


Figure 1a shows the detail of the cryode tip. The width of the tip was $\frac{1}{2}$ mm, and it was 7mm long.

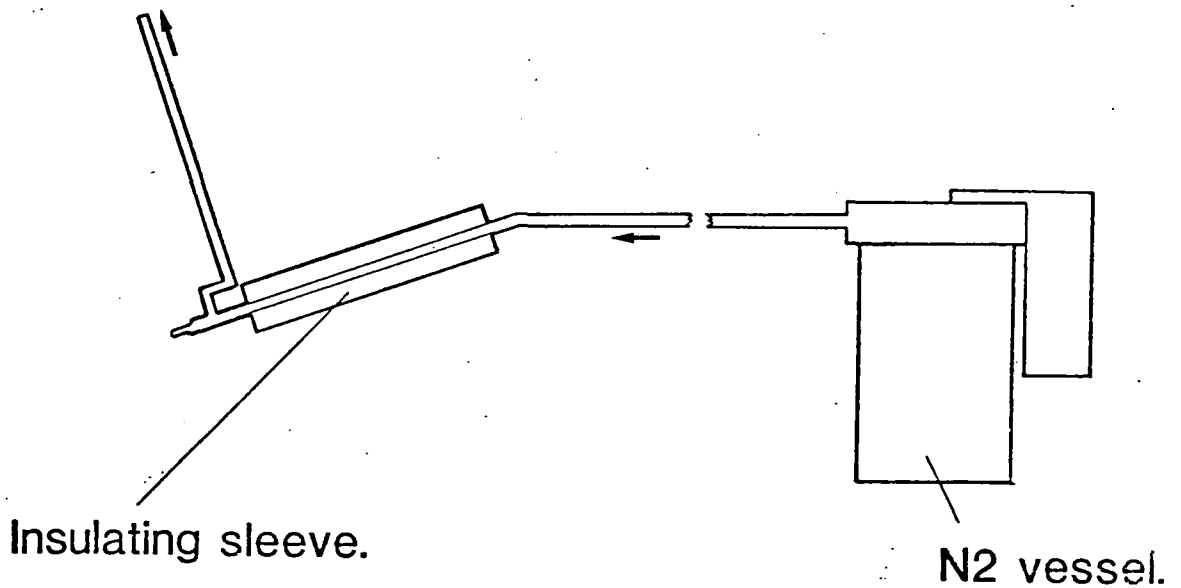


Figure 1b shows the arrangement of the equipment. The cryode was connected to the N2 cannister by flexible polythene tubing, and the gas was exhausted through a similar tube. Insulation was effected by a thick rubber sleeves.

Fig. A.2.

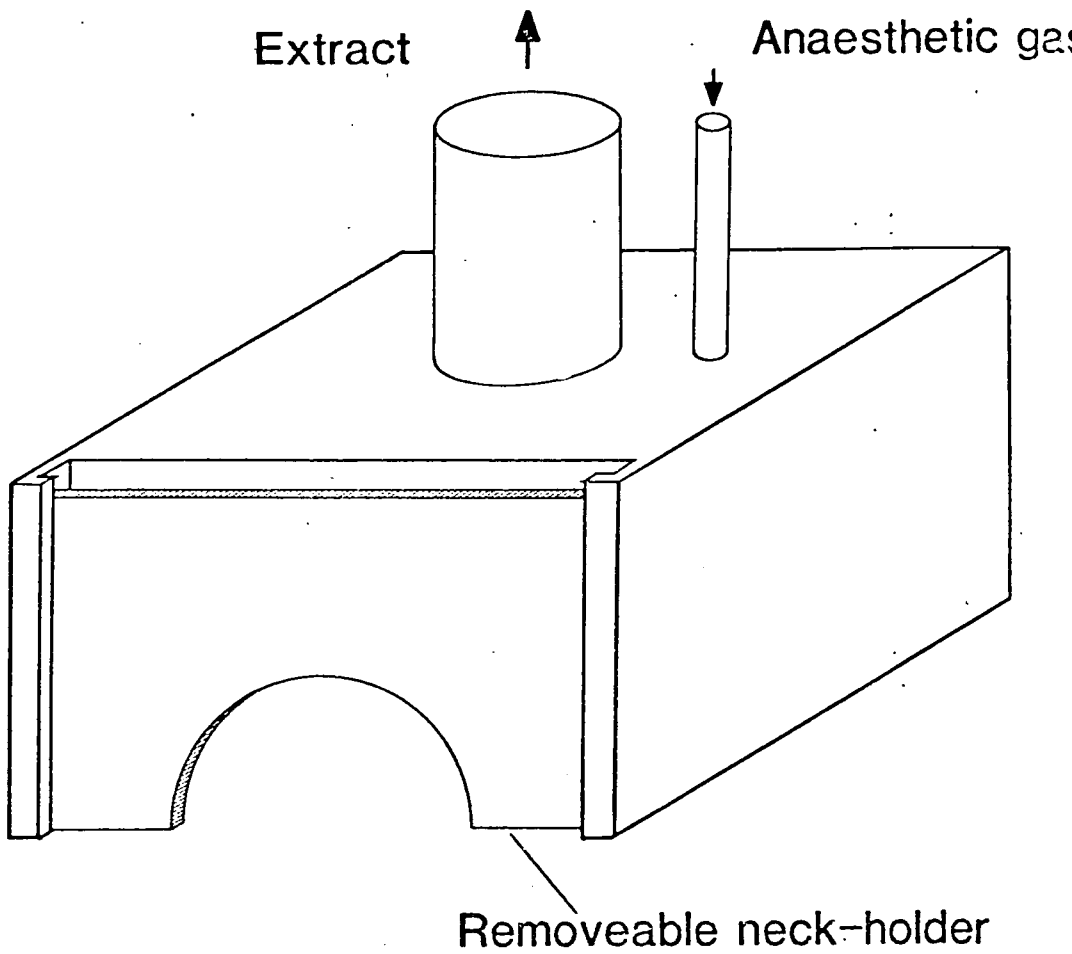


Figure 2a shows the anaesthetic box. The flap is positioned in the face of the box opposite the neck holder.

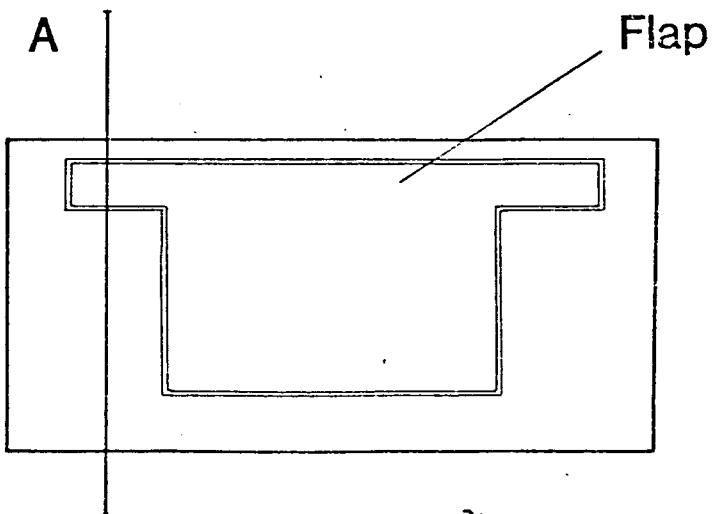


Figure 2b shows the face of the box containing the flap, and the level (A), at which the sectional view is taken. (see Fig. 3)

Fig. A.3.

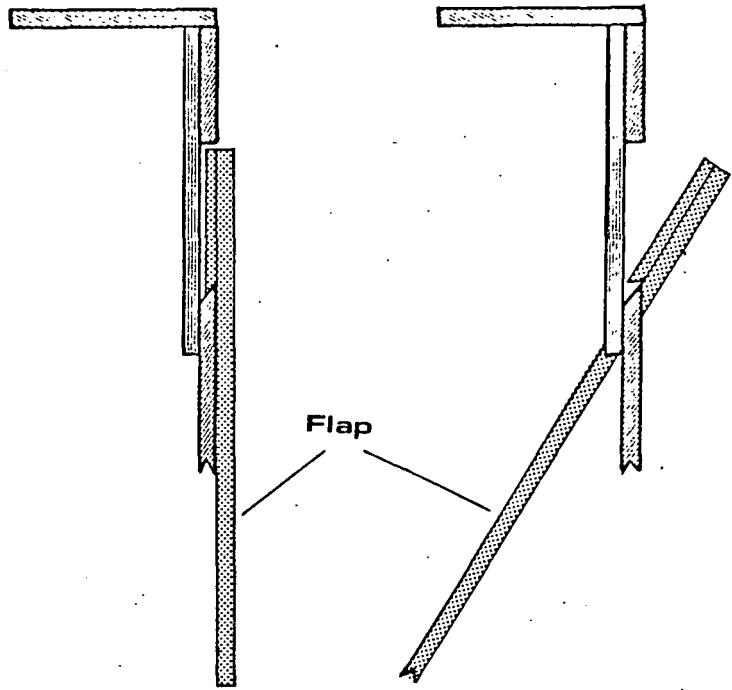


Figure 3a shows the operation of the flap on the anaesthetic box. This is a sectional view at level A. (see Fig. 2)

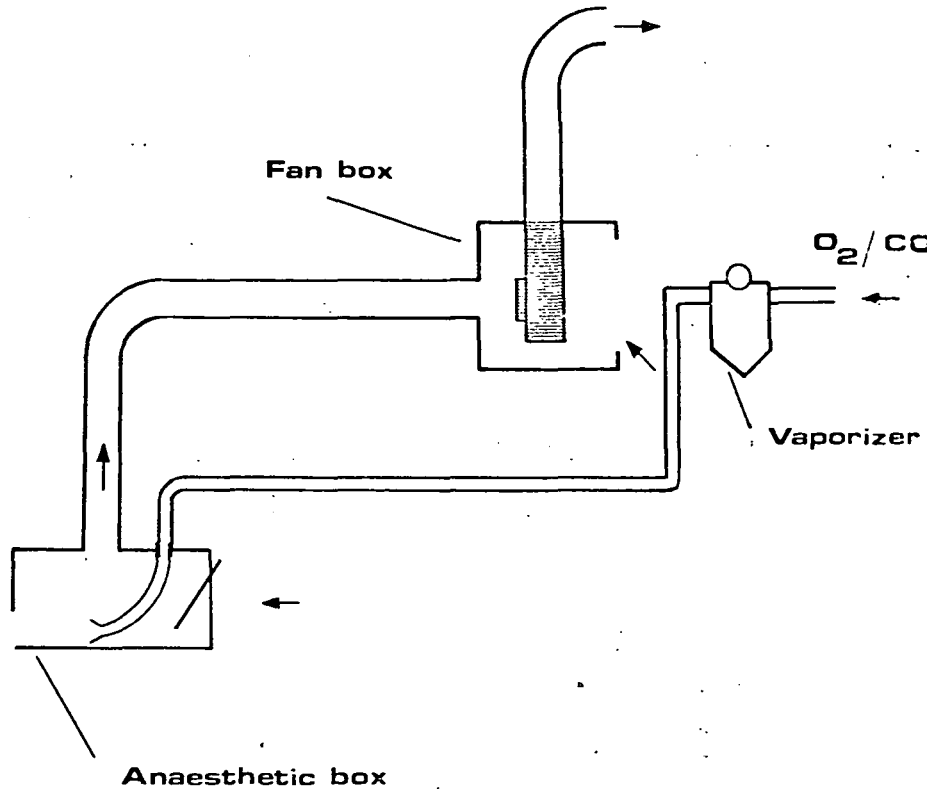


Figure 3b shows the arrangement of the anaesthetic equipment. The vaporizer is positioned next to the Fan box to remove any escaping gas.

