

## Durham E-Theses

---

*The effects of ischaemia and denervation on  
mammalian muscle spindles*

Falih Hassan Diwan

### How to cite:

---

Diwan, Falih Hassan (1983) The effects of ischaemia and denervation on mammalian muscle spindles. Doctoral thesis, Durham University.

### Use policy

---

The full-text may be used and/or reproduced, and given to third parties in any format or medium, without prior permission or charge, for personal research or study, educational, or not-for-profit purposes provided that:

- a full bibliographic reference is made to the original source
- a <https://etheses.durham.ac.uk/id/eprint/7198/> is made to the metadata record in Durham E-Theses
- the full-text is not changed in any way

The full-text must not be sold in any format or medium without the formal permission of the copyright holders.

Please consult the [full Durham E-Theses policy](#) for further details.

THE EFFECTS OF ISCHAEMIA AND DENERVATION  
ON MAMMALIAN MUSCLE SPINDLES

VOL. II. FIGURES

A thesis presented in candidature for the

degree of

Doctor of Philosophy

by

Falih Hassan Diwan, B.Sc. (Basrah),

Department of Zoology, University of Durham.

Durham, June 1983

The copyright of this thesis rests with the author.  
No quotation from it should be published without  
his prior written consent and information derived  
from it should be acknowledged.



28. NOV 1983

Thesis

1983 | DIW

LIST OF ABBREVIATIONS

L	lipid droplet
M	M-line
Sc	Schwann cell
SR	sarcoplasmic reticulum
Z	Z-line
ax	axon
b <sub>1</sub>	bag <sub>1</sub> fibre
b <sub>2</sub>	bag <sub>2</sub> fibre
bl	basal lamina
c	chain fibre
cap	capsule
cf	collagen fibrils
cpl	capillary
ef	elastic fibrils
emf	extrafusal muscle fibre
en	endomysial cell
f	fibrin
hc	helical complex
lc	leucocyte
mac	macrophage
mb	myoblast
mit	mitochondrion
mnt	motor nerve terminal
mt	myotube
n	nucleus
sat	satellite cell
snt	sensory nerve terminal
v	vesicle



Fig. 3.1 Schematic diagrams illustrating the various experimental lesions.

The blood and nerve supply (open and filled channels respectively) enter soleus muscle from the right.

- A. Normal blood and nerve supply.
- B. Devascularization: series Isch.
- C. Denervation: series Dn.
- D. Devascularization and denervation:  
series Isch/Dn.
- E. Devascularization followed after 28 days  
by denervation: series Isch/Rn/Dn.  
The dotted lines represent restored  
blood supply.

3.1

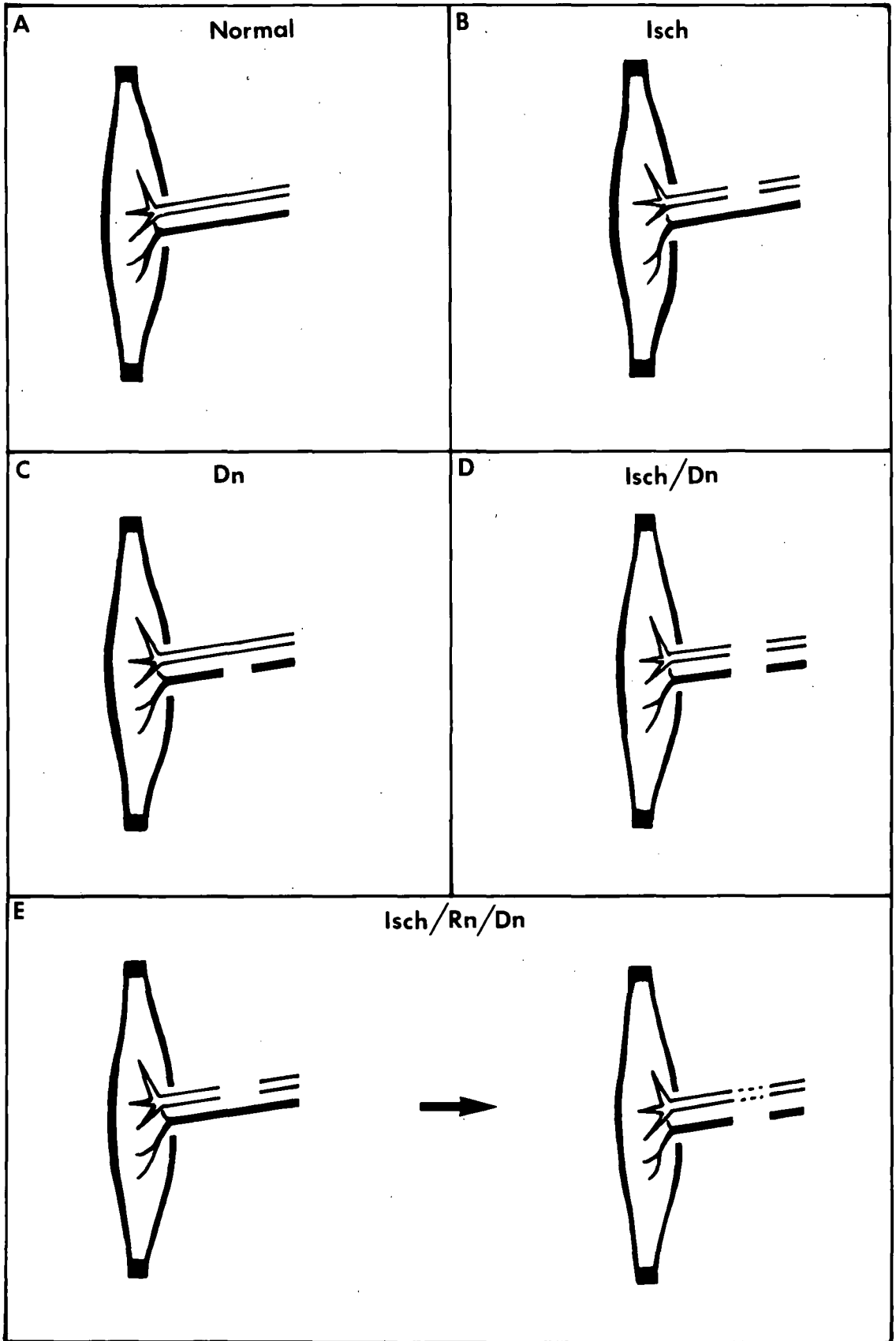


Fig. 4.1 Schematic drawing of soleus muscle of rat showing its attachments and the approximate position of the entry of the nerve and blood supply. Right-hand limb, medial aspect.

4.1

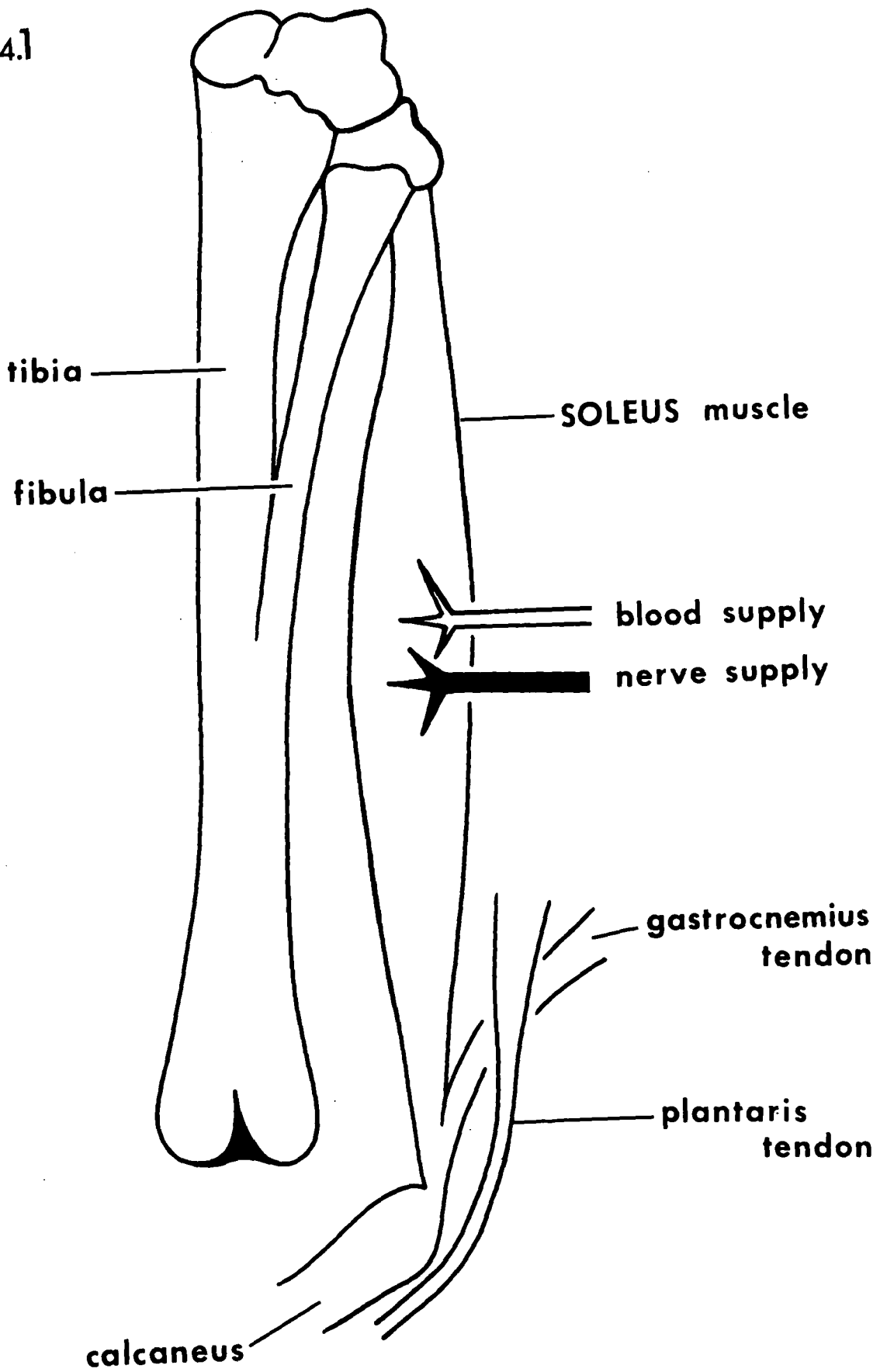


Fig. 5.1 Transverse sections of normal rat muscle  
spindles.

- A. Equatorial region. Note the diameter-differences between the intrafusal fibres. Each intrafusal fibre is enclosed by a separate compartment of the axial sheath.
  
- B. Intracapsular polar region. Note the overall increase in diameter of the intrafusal fibres particularly the chain fibres.

bars = 4 $\mu$ m

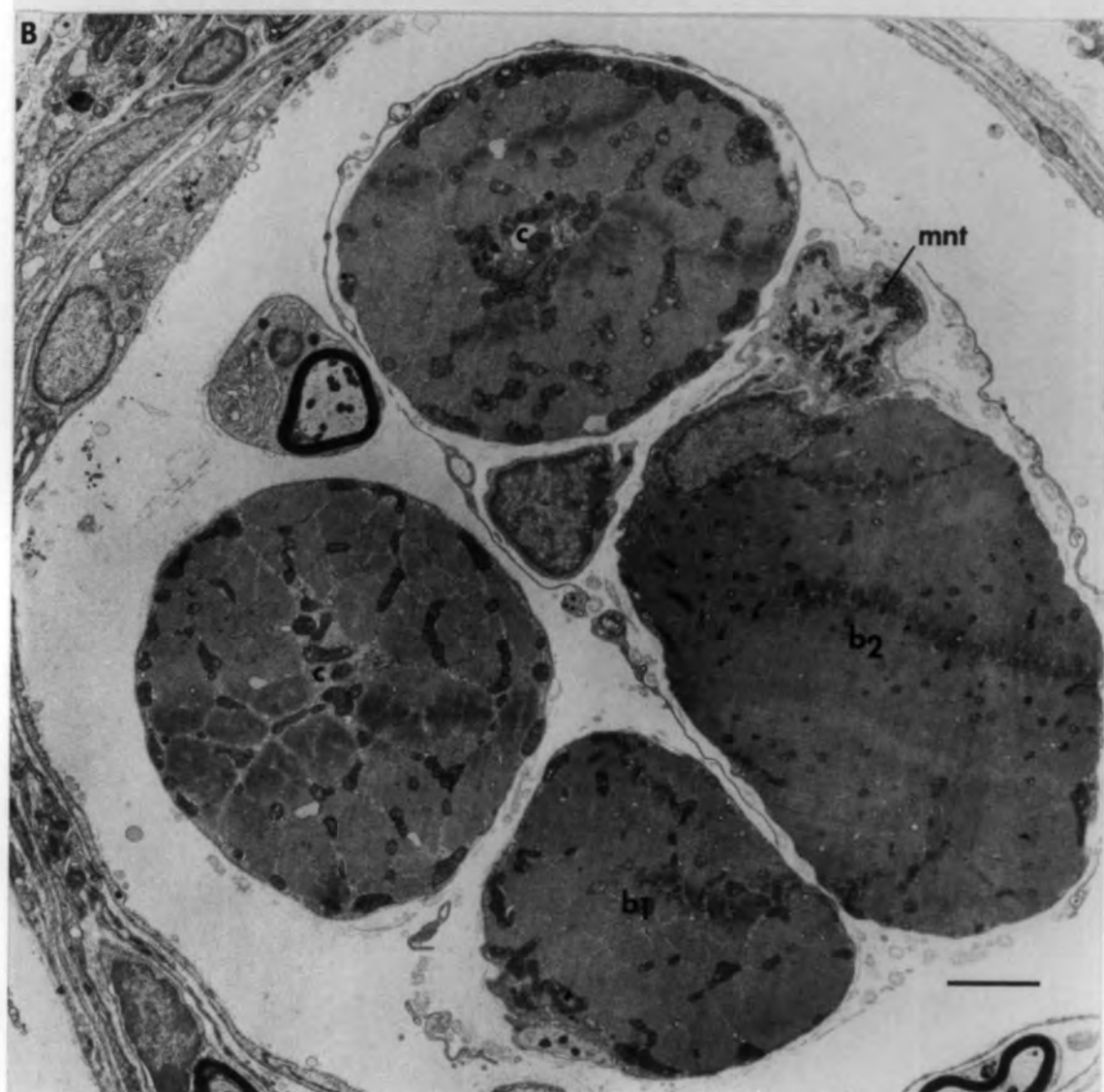
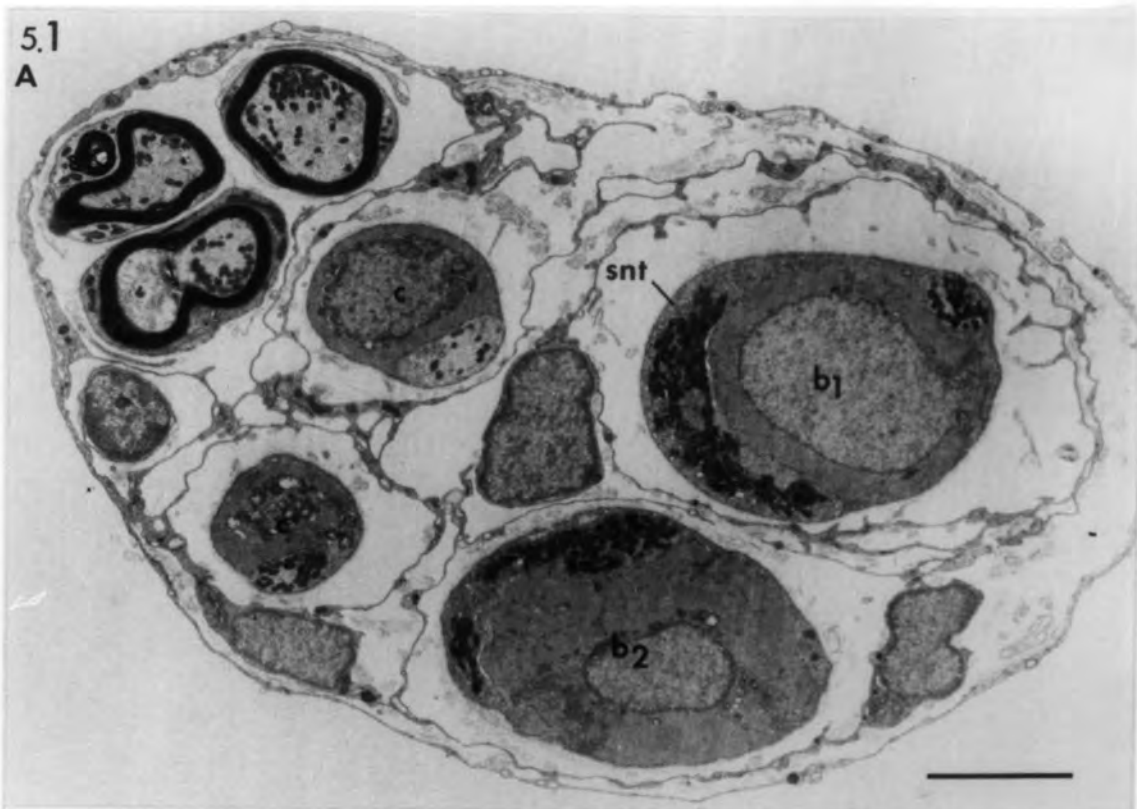


Fig. 5.2 The fine structure of normal muscle spindles

Longitudinal sections through the equatorial  
region of:

A - a chain fibre,

B - a bag<sub>1</sub> fibre,

C - a bag<sub>2</sub> fibre.

Note the differences in the M-line condition  
and in the size and distribution of the  
mitochondria. Arrows point to sensory terminals.

bars = 1  $\mu$ m

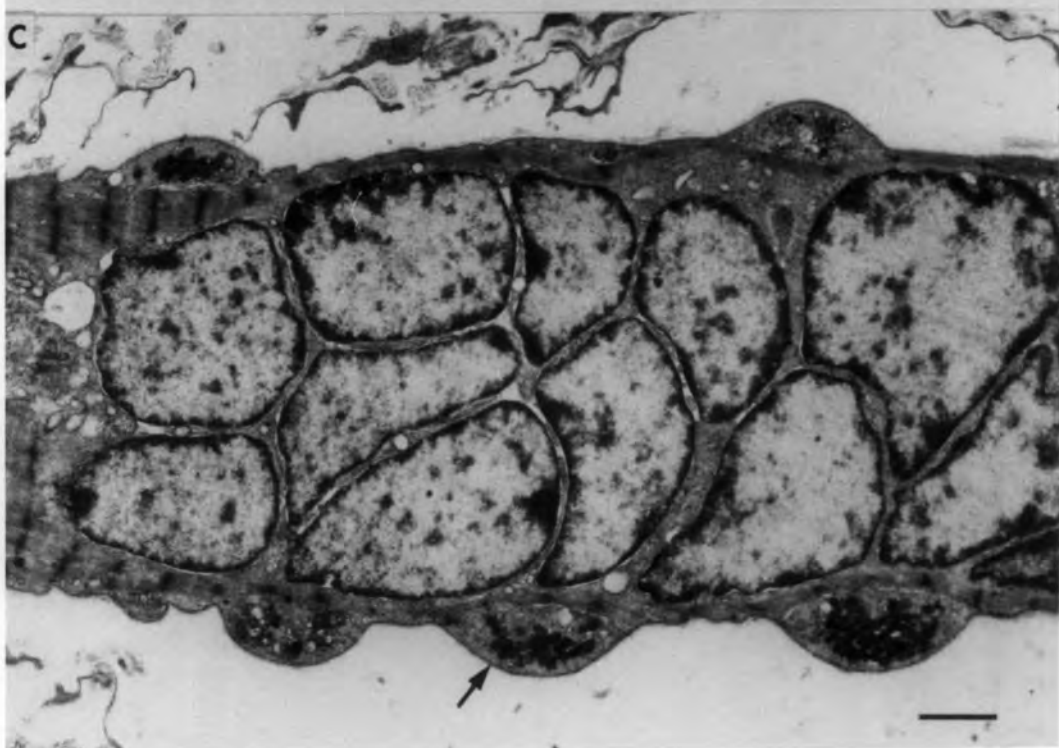
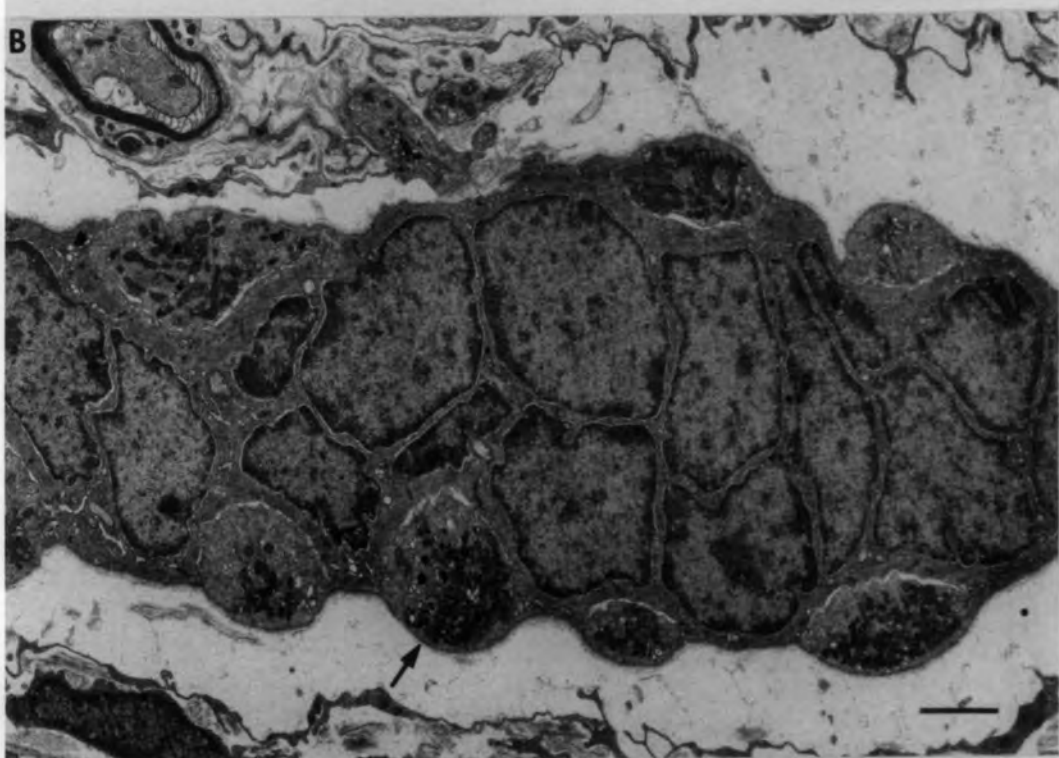
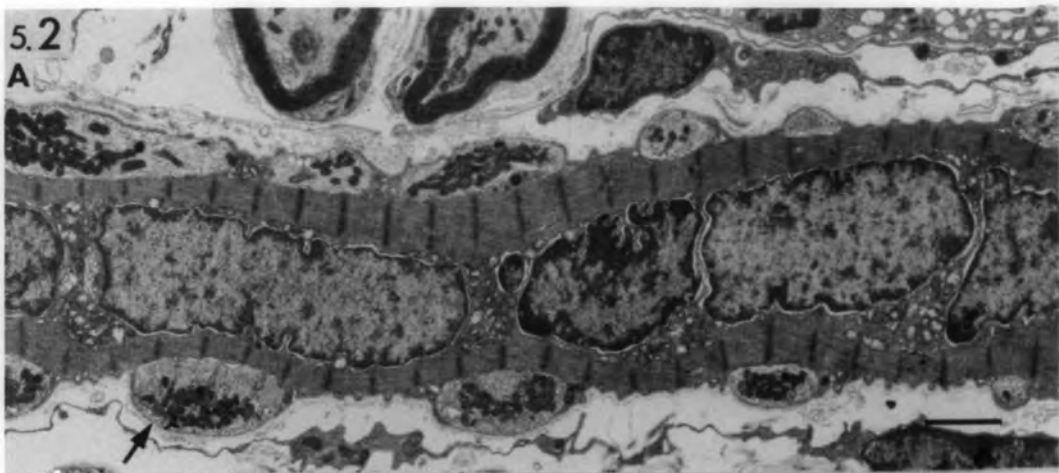


Fig. 5.3 The fine structure of normal muscle  
spindles.

Longitudinal sections through the  
intracapsular polar region of:

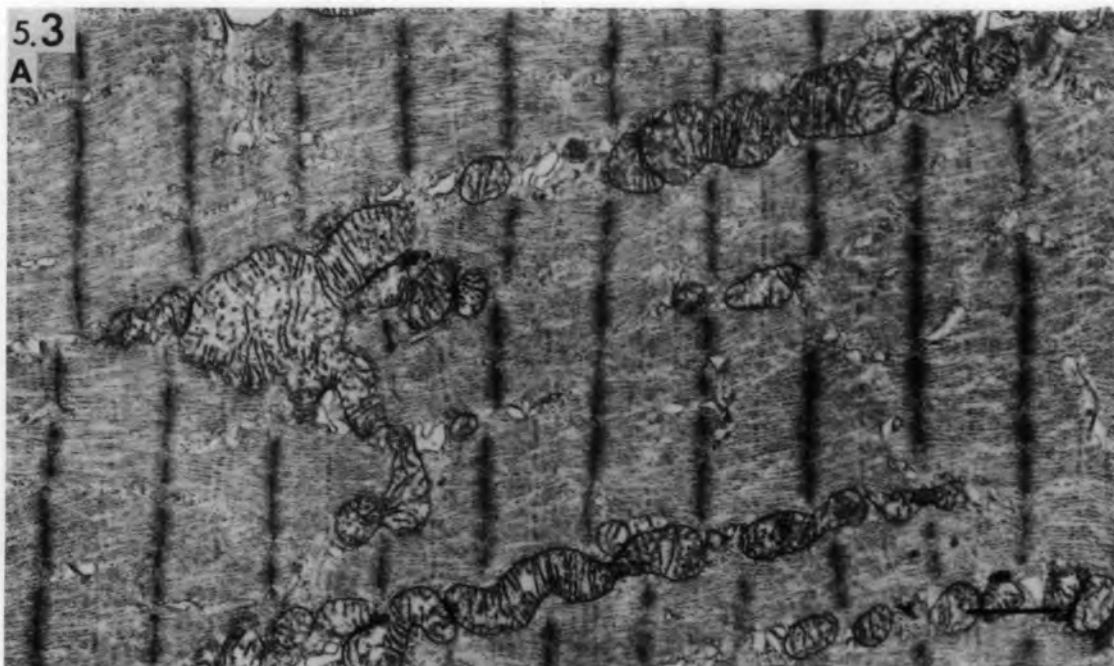
- A. a chain fibre,
- B. a bag<sub>1</sub> fibre,
- C. a bag<sub>2</sub> fibre.

Note the differences in the M-line  
condition and in the size and distribution  
of the mitochondria.

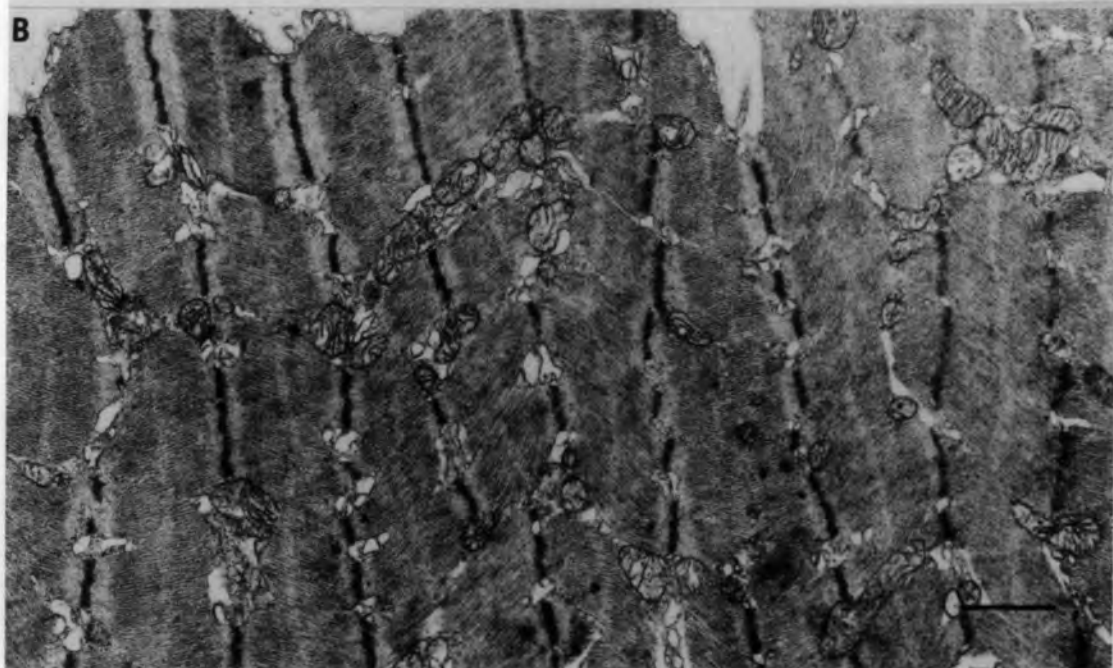
bars = 1 $\mu$ m

5.3

A



B



C




Fig. 5.4 Normal muscle spindles.

Transverse section at the end of the myotube region showing association between the two bag fibres and between the two chain fibres. Note the cross sensory nerve terminal (arrow) between the two bag fibres.

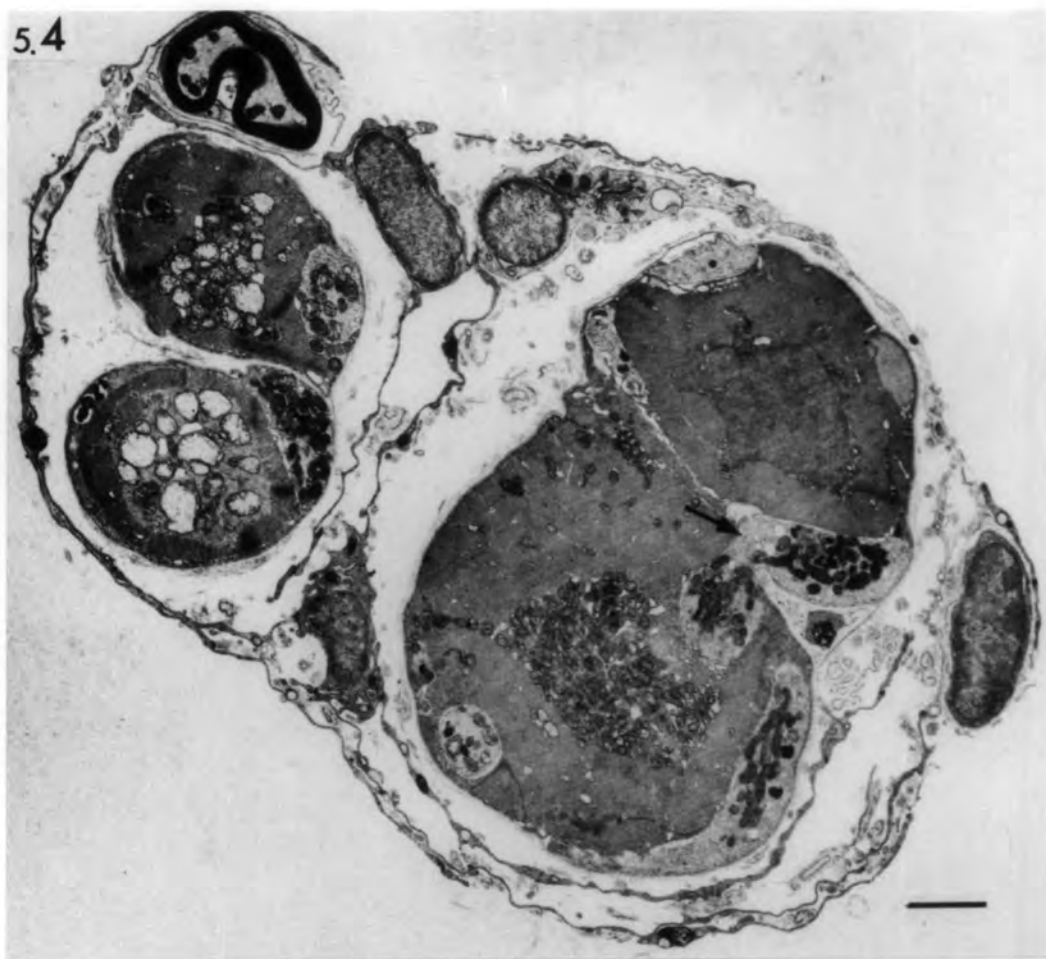
bar = 2 $\mu$ m

Fig. 5.5 Normal muscle spindles.

Longitudinal section at the end of the myotube region showing association between the two bag fibres. Note the satellite cell(sat) and myonucleus (n) at the region of association.

bar = 2 $\mu$ m

5.4



5.5

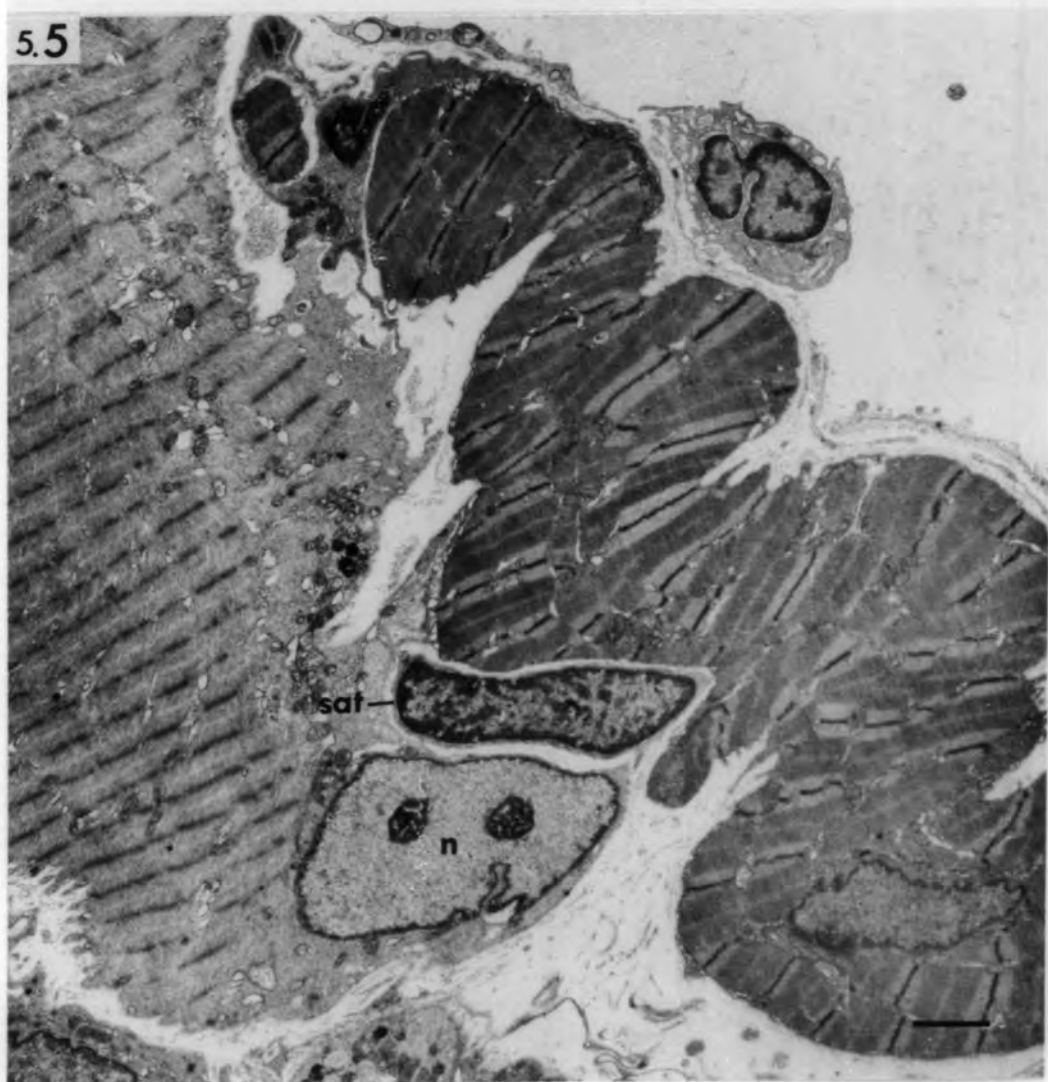

Fig. 5.6 The fine structure of normal muscle  
spindles.

Longitudinal sections of the capsule cells:

- A. Note the unmyelinated axons (ax) and elastic fibrils (ef). A nucleus of a capsule cell may be seen in the lower centre.
  
- B. Note the collagen fibrils (cf). Arrow indicates a double layer of capsule cells without intervening basal laminae.

bars = 1 $\mu$ m

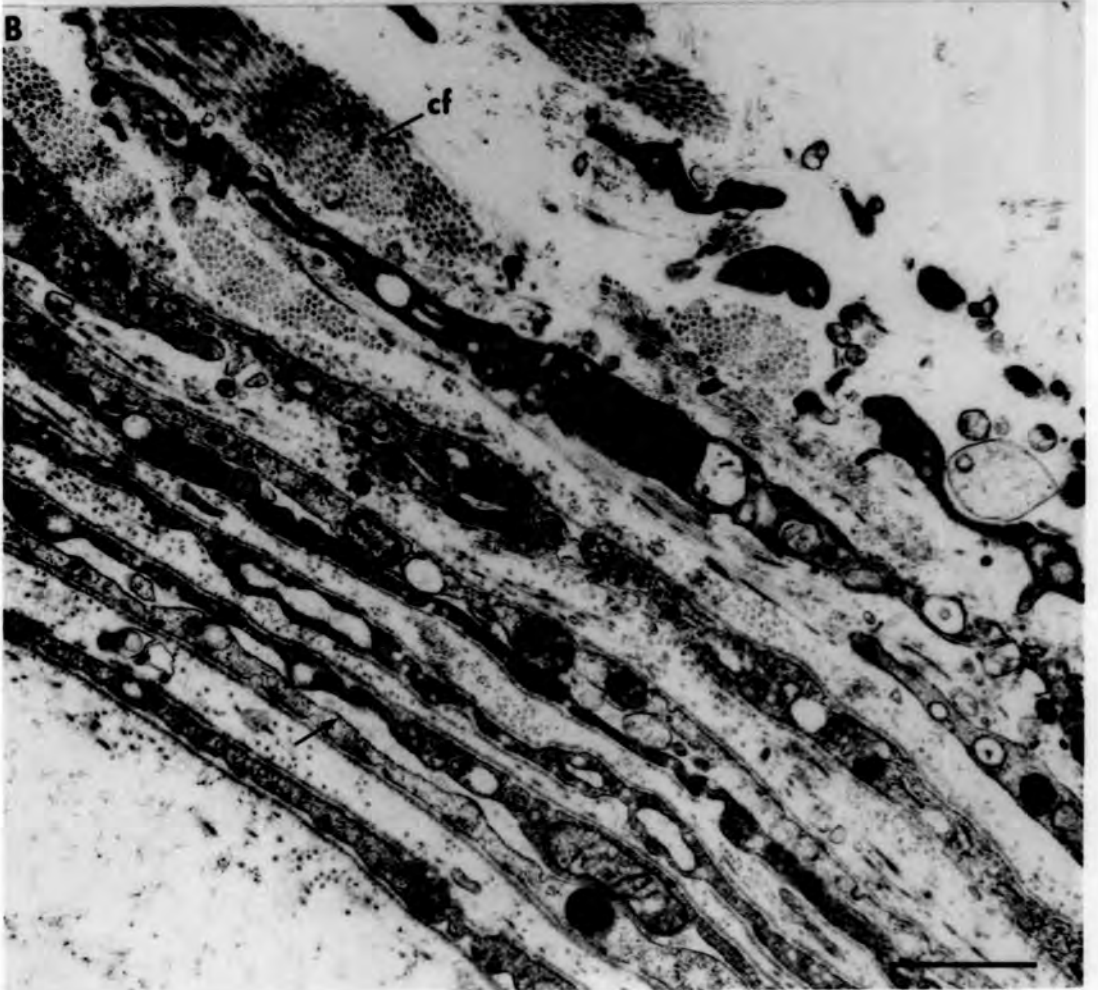
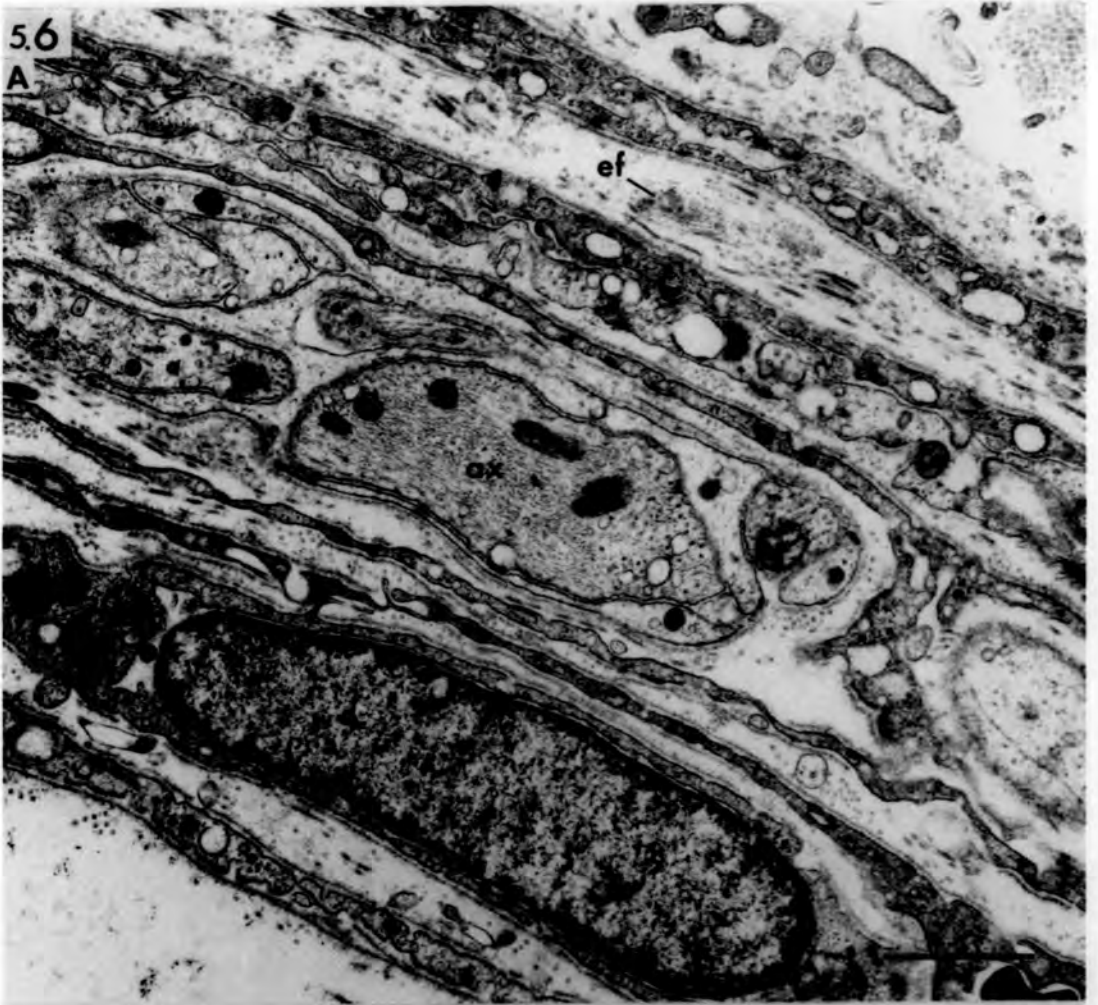

Fig. 5.7 The fine structure of normal muscle  
spindles.

Longitudinal sections of the axial -  
sheath cells.

- A. Note the basal lamina profiles (bl).
  
- B. Note the elastic (ef) and collagen  
fibrils (cf). Arrows point to areas  
of close contact.

bars = 1 $\mu$ m

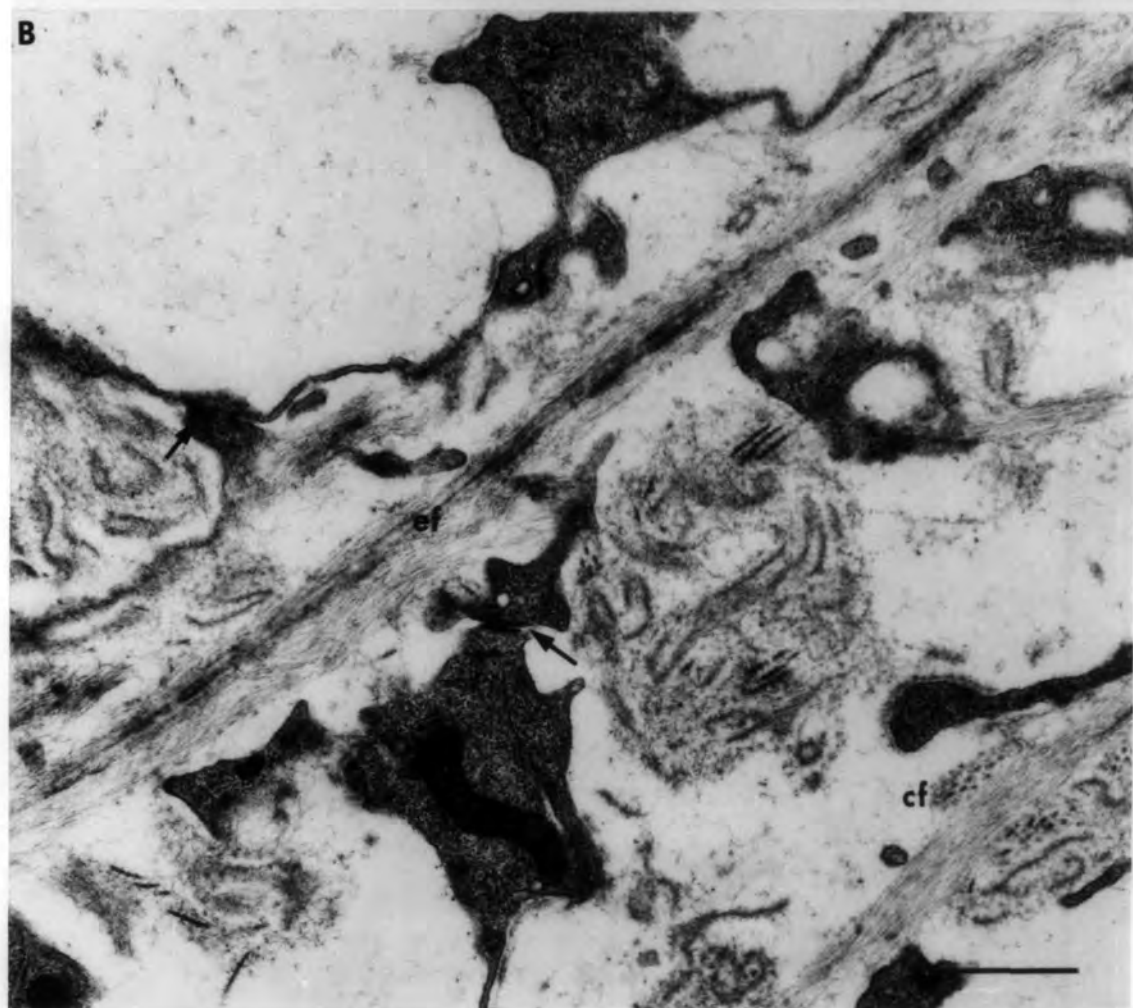
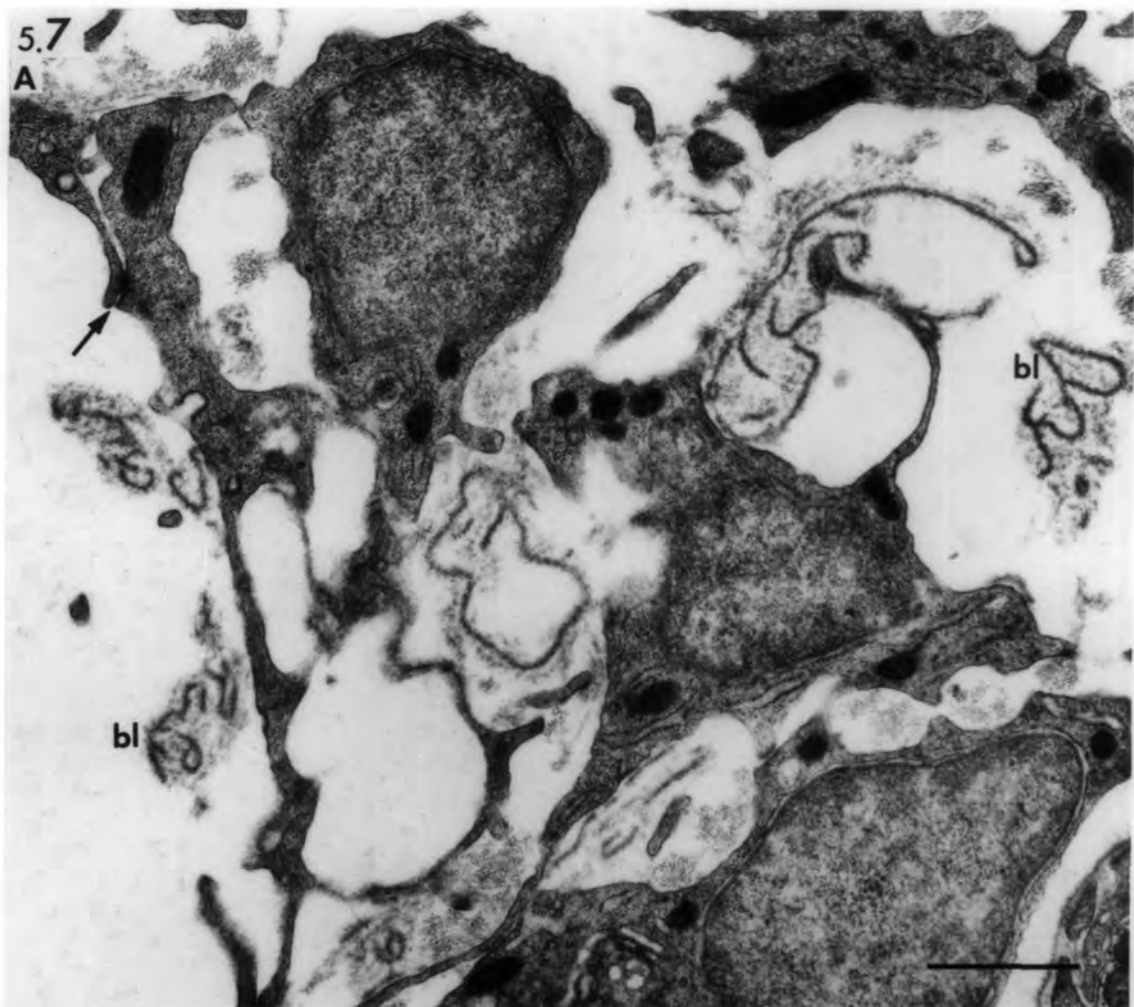


Fig. 5.8 The fine structure of normal muscle spindles.

Transverse sections at the equator showing sensory nerve terminals on intrafusal fibres.

A. Incomplete-ring shaped terminal.

B. Lenticular-shaped terminal.

bars= 1µm

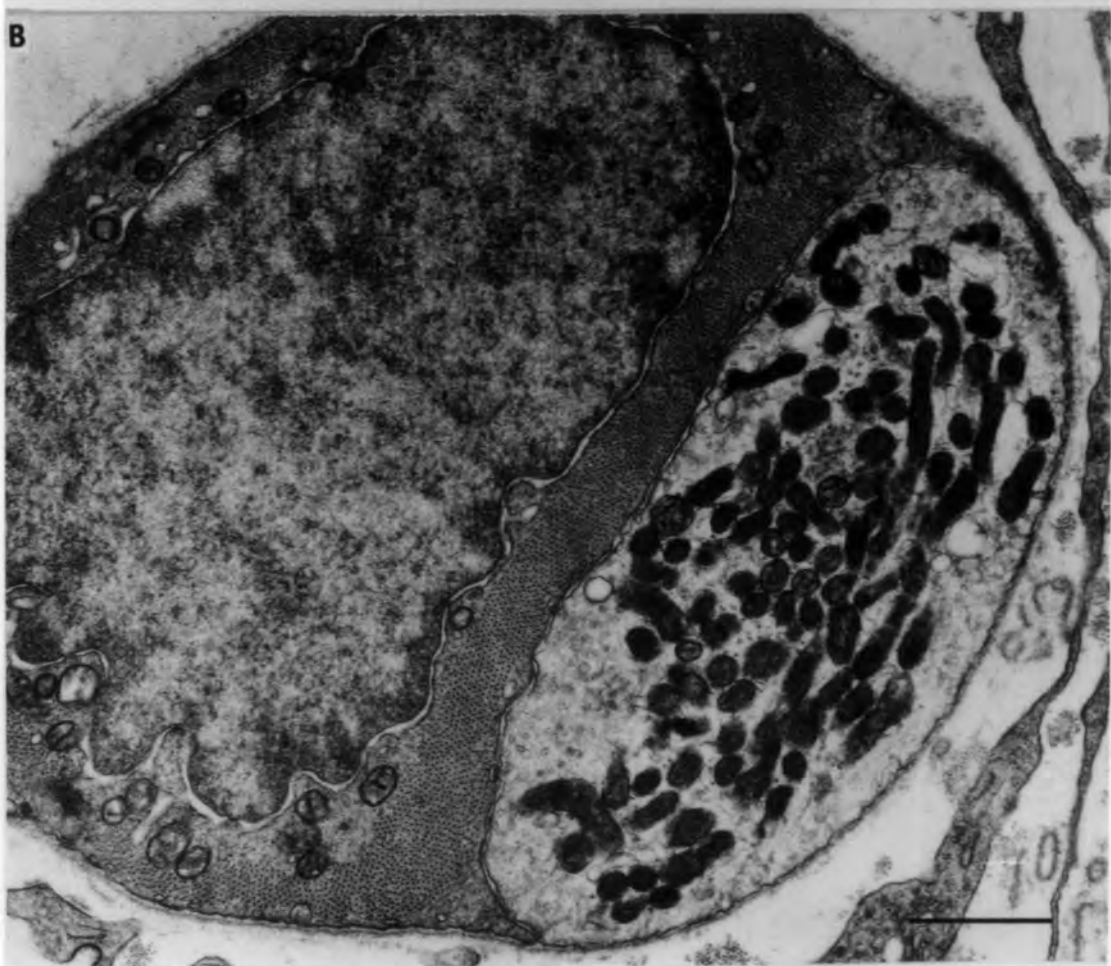
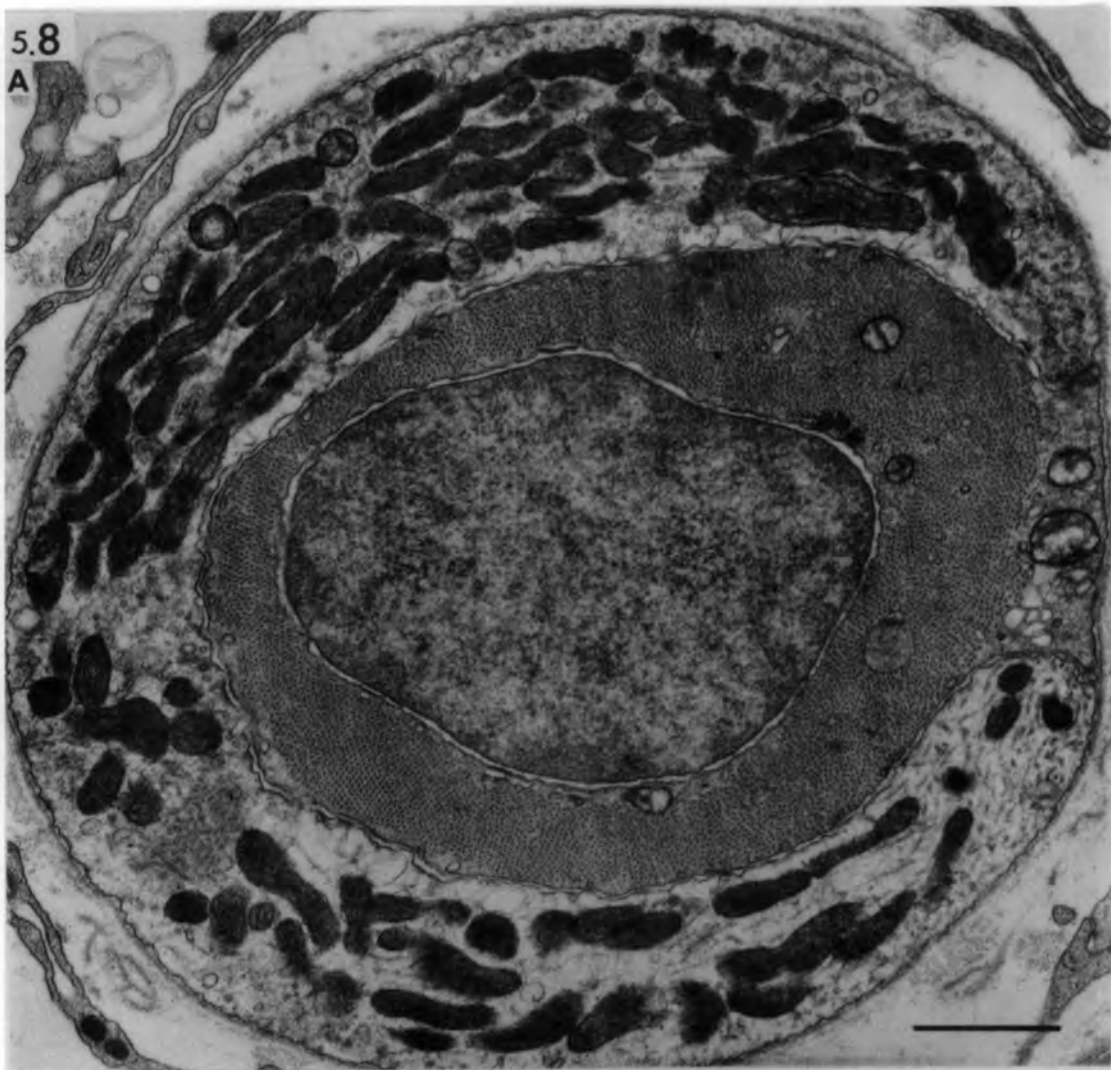


Fig. 5.9 The fine structure of normal muscle  
spindles.

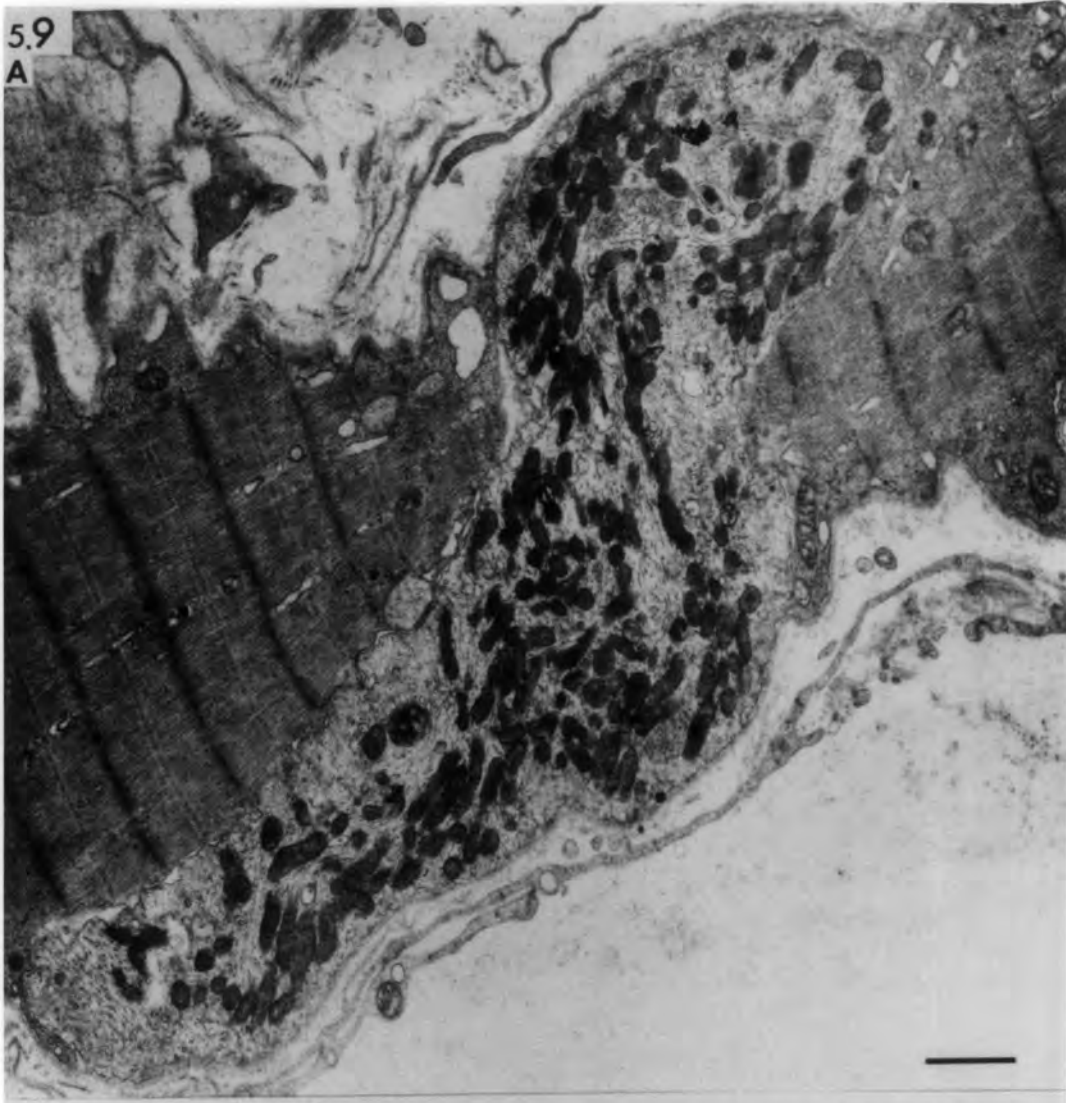
Longitudinal sections at the equator  
showing sensory nerve terminals on  
intrafusal fibres.

- A. A sensory nerve terminal crossing  
the width of a chain fibre.
  
- B. A sensory nerve terminal completely  
enclosed by sarcoplasm.

bars = 1 $\mu$ m

5.9

A



B

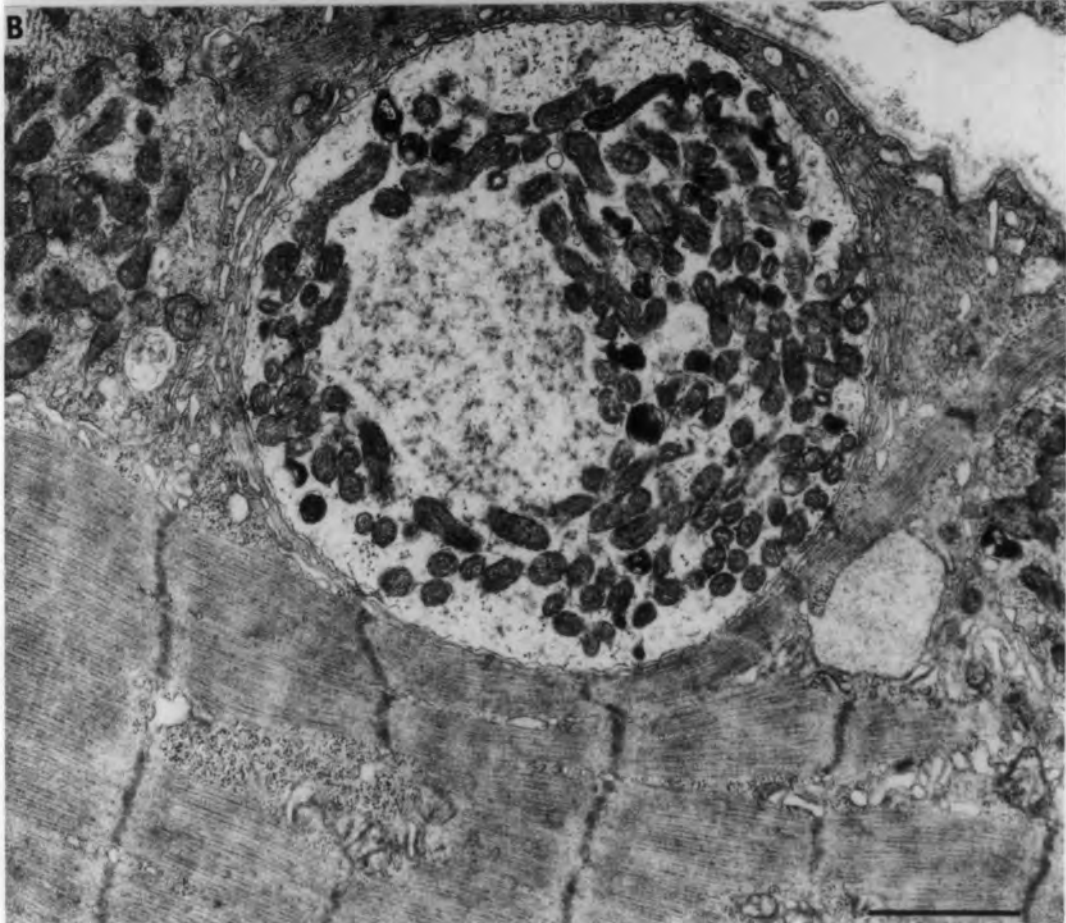


Fig. 5.10 The fine structure of normal muscle spindles

Longitudinal sections showing sensory  
cross-terminals:

- A. between two associated bag fibres
- B. between two associated chain fibres.

bars = 2 $\mu$ m

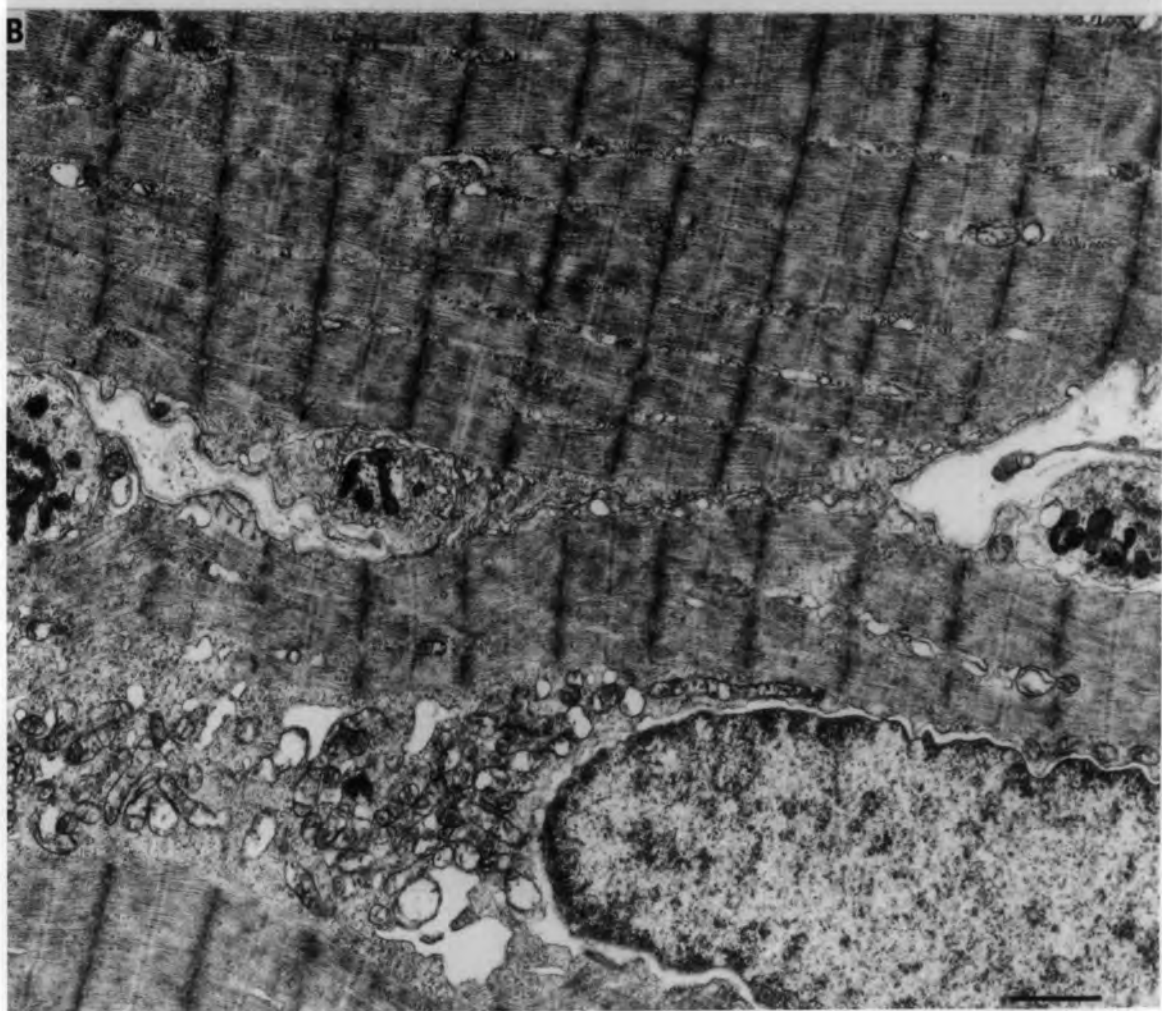
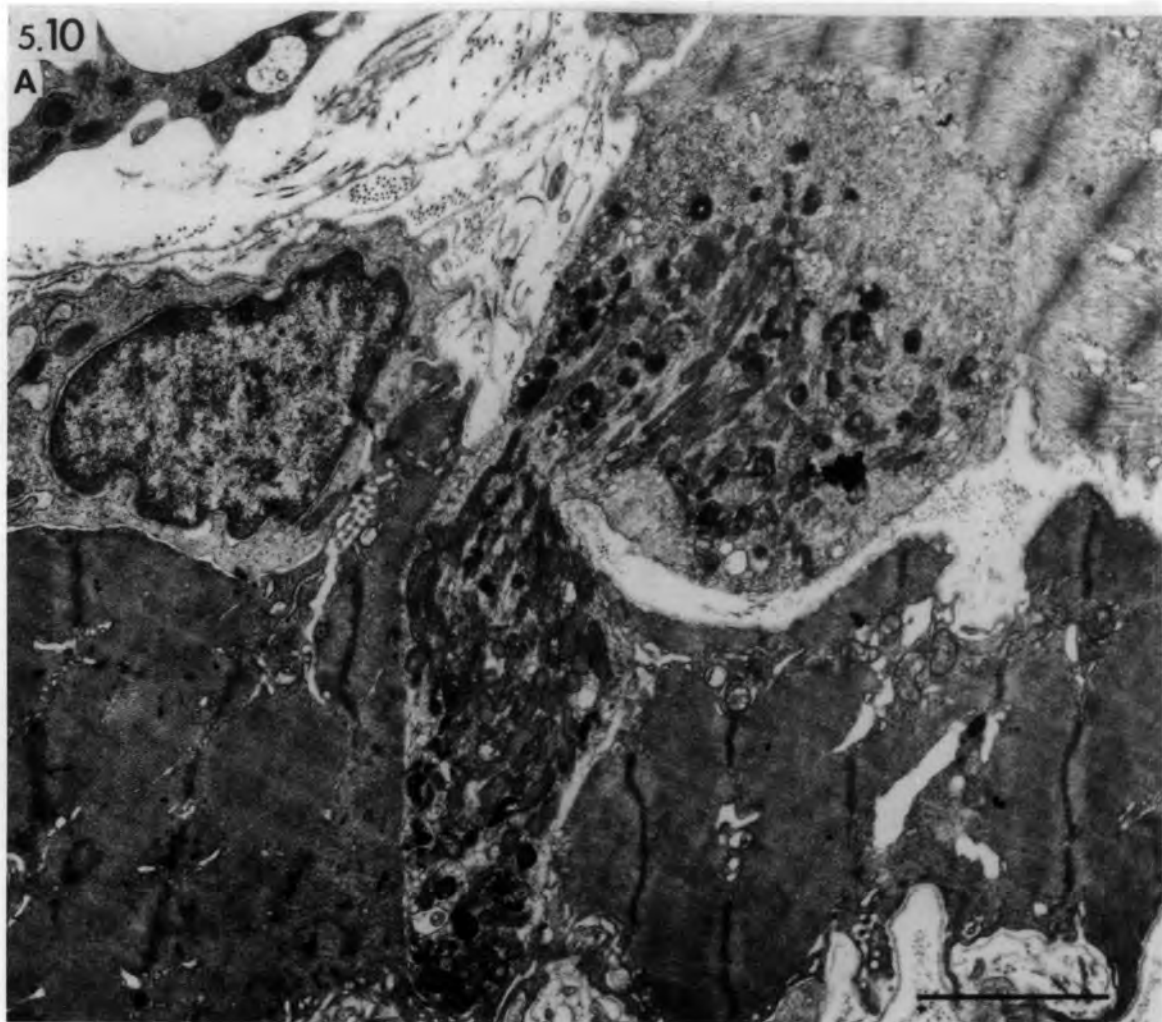

Fig. 5.11 The fine structure of normal muscle  
spindles.

Longitudinal section of a chain fibre  
showing a motor end-plate. Note the  
few shallow postjunctional folds  
(arrows) and the well-developed  
sole-plate.

bar = 4 $\mu$ m

5.11



Fig. 5.12 The fine structure of normal muscle spindles.

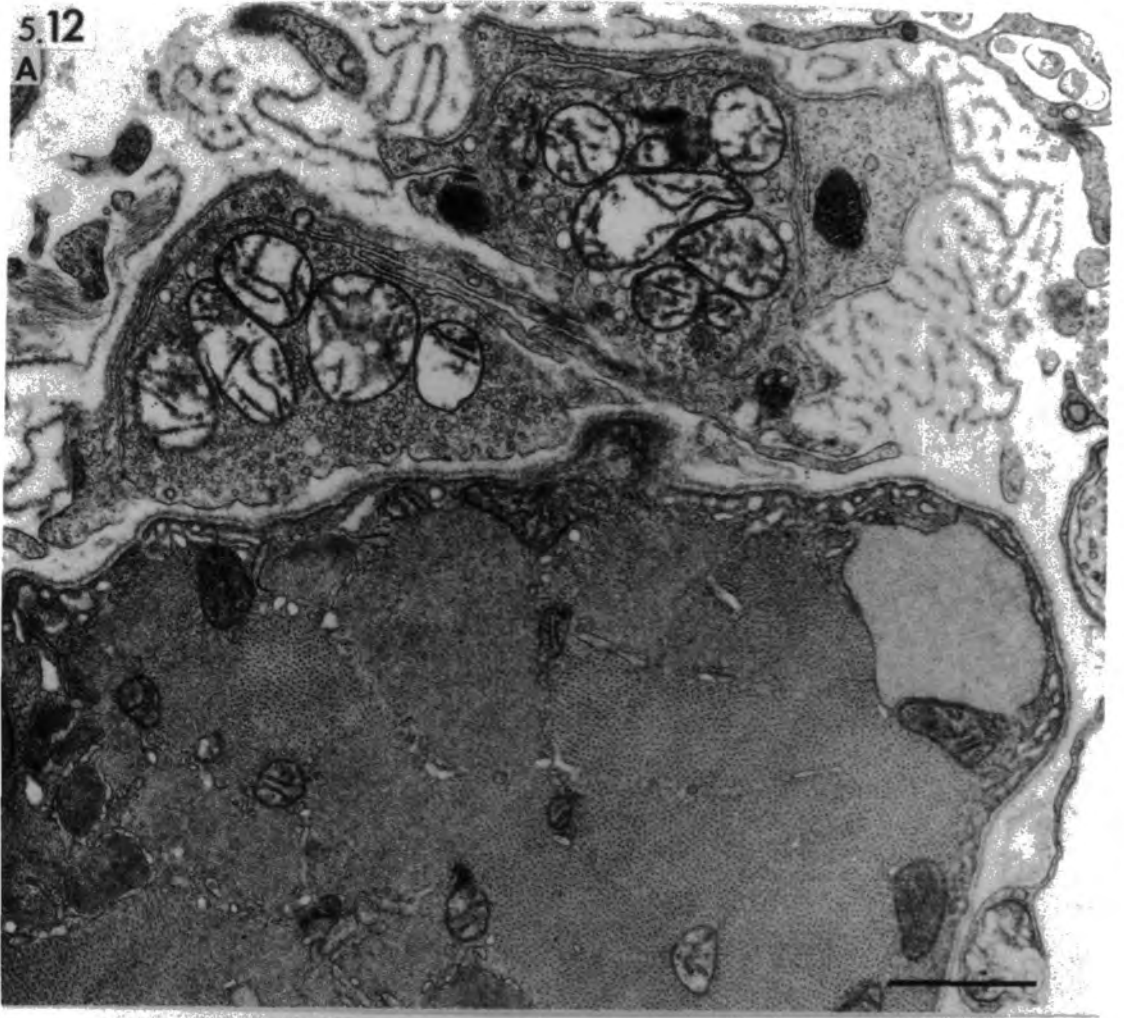
Motor nerve endings on bag<sub>1</sub> fibres.

- A. Transverse section in the intracapsular polar region. Note the absence of a sole-plate.
  
- B. Transverse section in the extracapsular polar region. Note the postjunctional folds (arrows) and sole-plate.

bars = 1  $\mu$ m

5.12

A



B

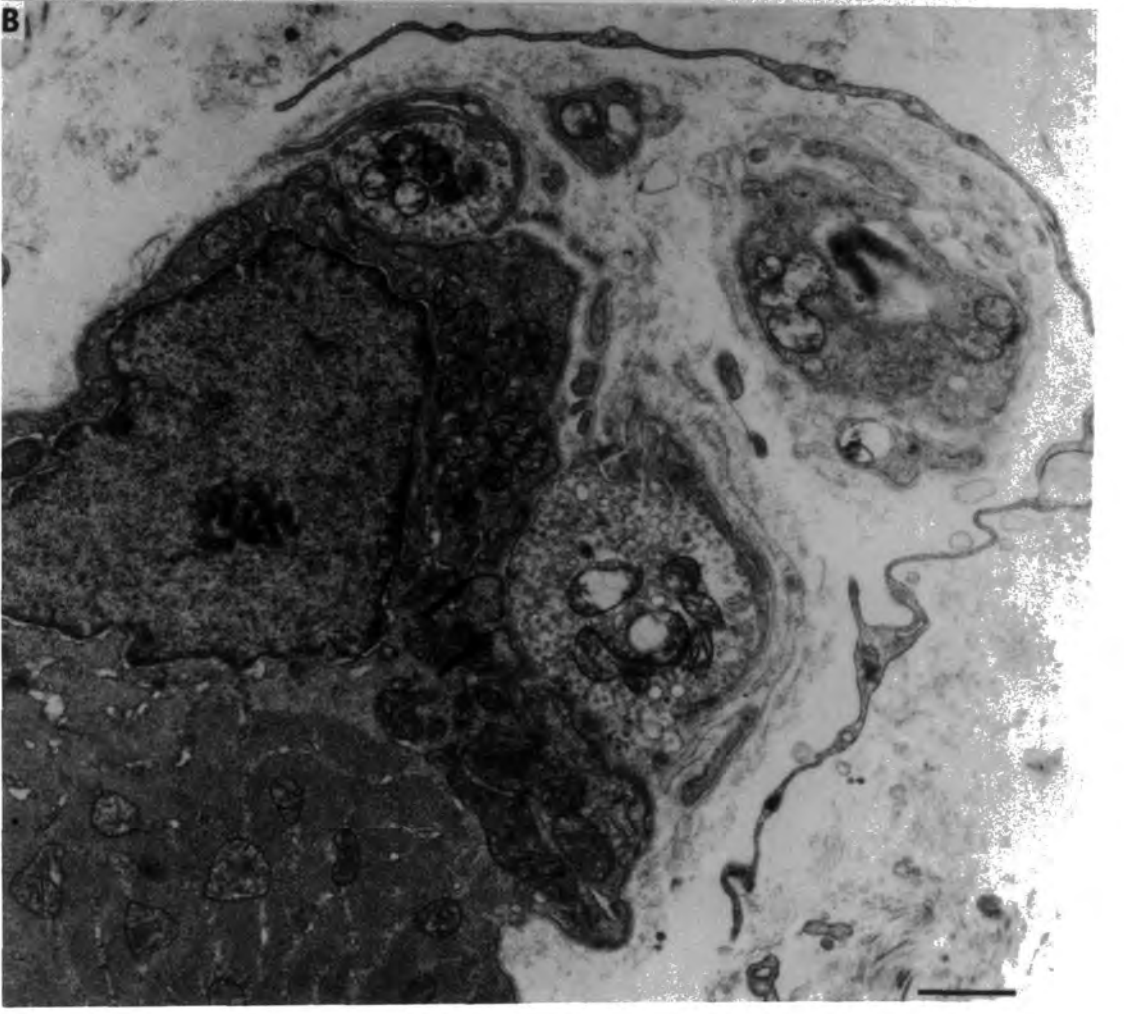


Fig. 5.13 The fine structure of normal muscle  
spindles.

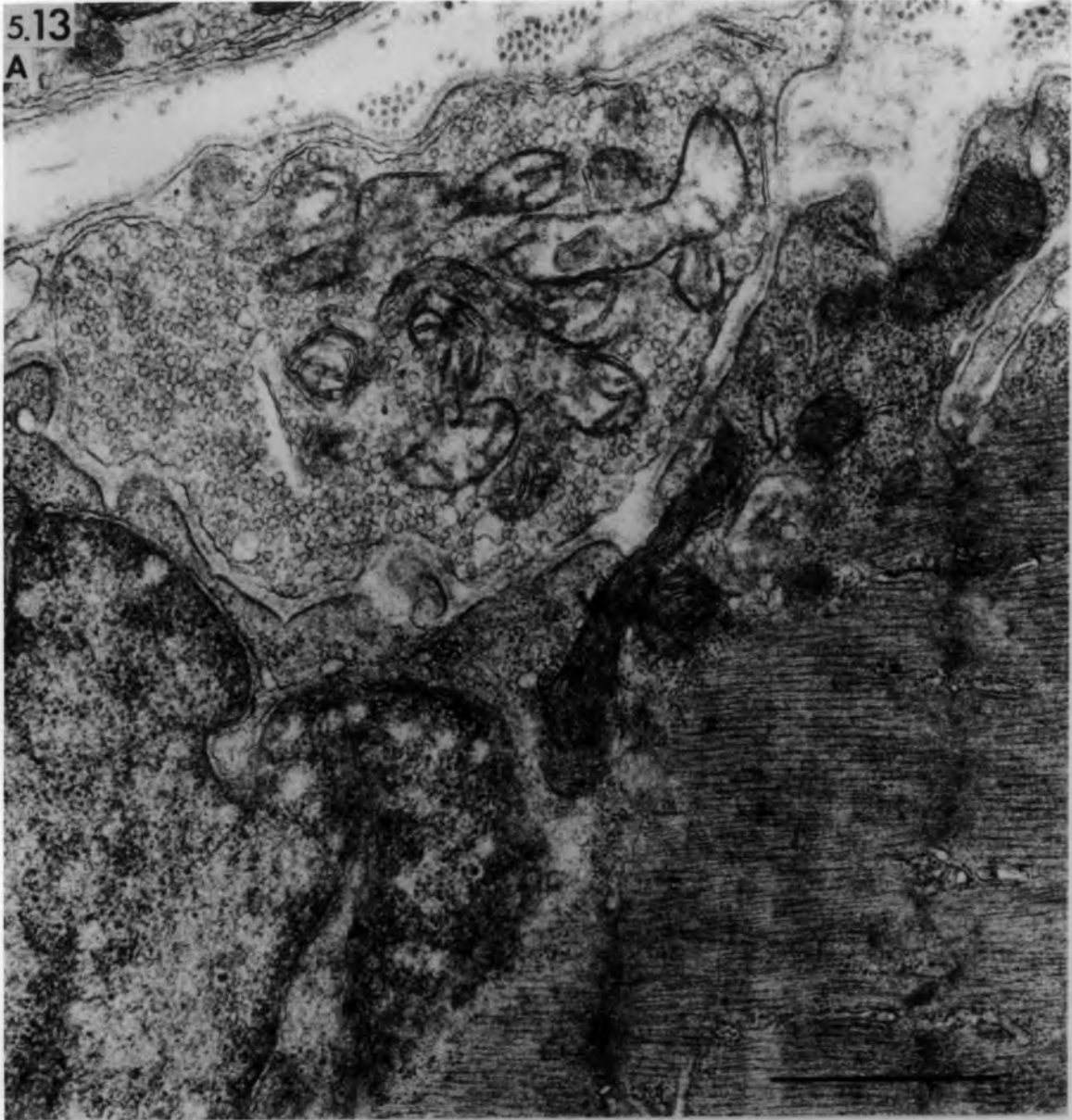Longitudinal sections at the intracapsular  
polar region showing motor nerve endings  
on bag<sub>2</sub> fibres.

- A. Note the poorly-developed sole-plate.
- B. Note the absence of any subneural  
specialization.

bars = 1µm

5.13

A



B

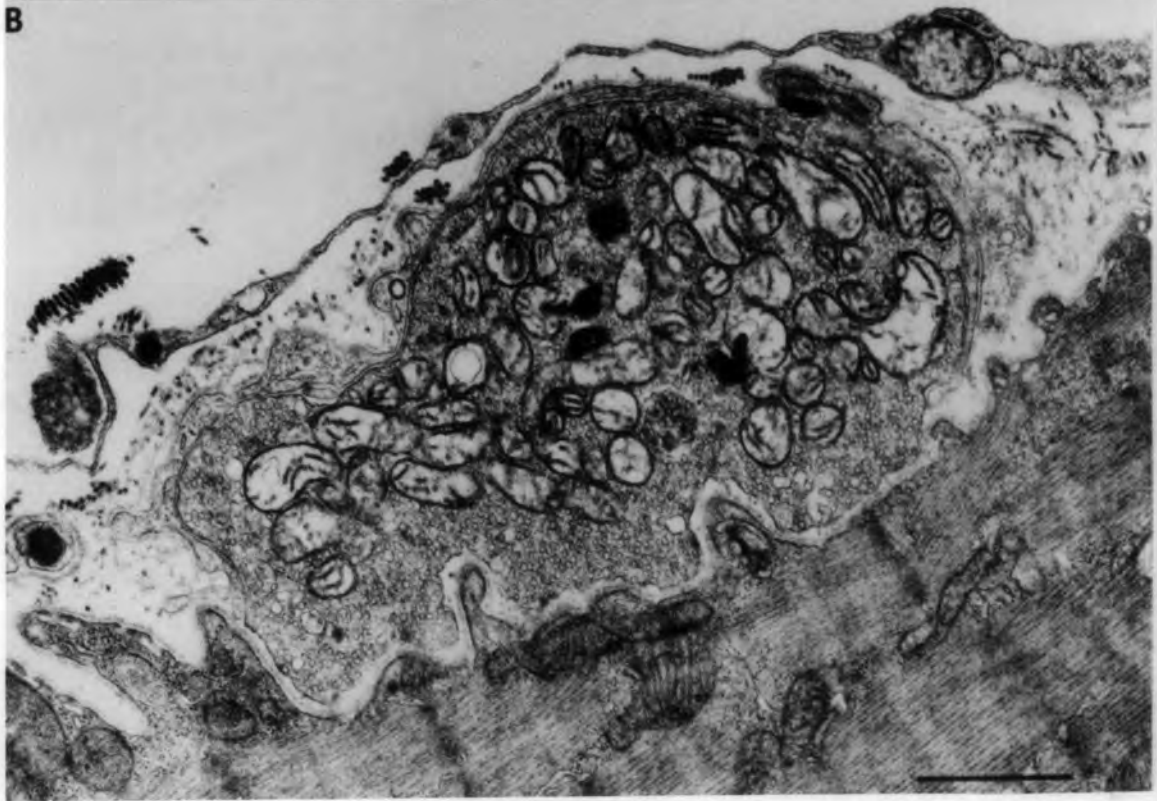


Fig. 6.1 Transverse section of soleus muscle 4 days after  
devascularization.

A. Low power of whole muscle shows three distinct zones of muscle fibres:

- (1) preserved superficial fibres
- (2) internal zone of regenerating muscle cells occupies most of the cross-sectional area
- (3) central zone of degenerating hyaline muscle fibres.

B. High power to show three distinct zones as above.  $1\mu\text{m}$  section stained with Toluidine blue.

bars =  $200\mu\text{m}$

6.1  
A

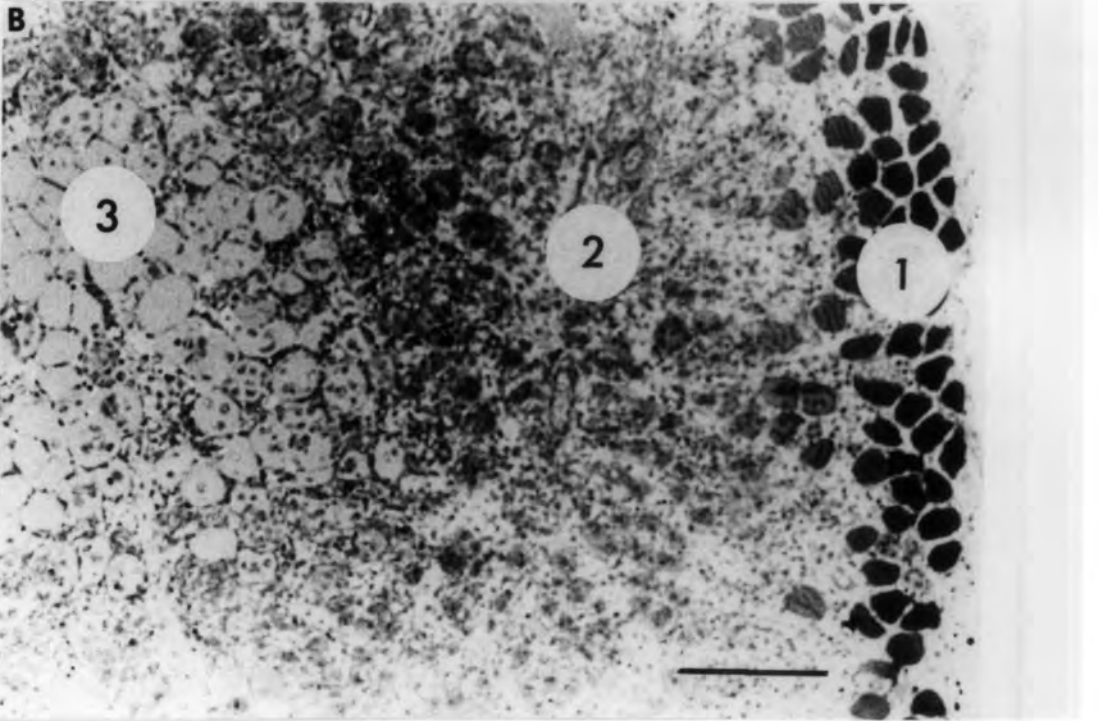
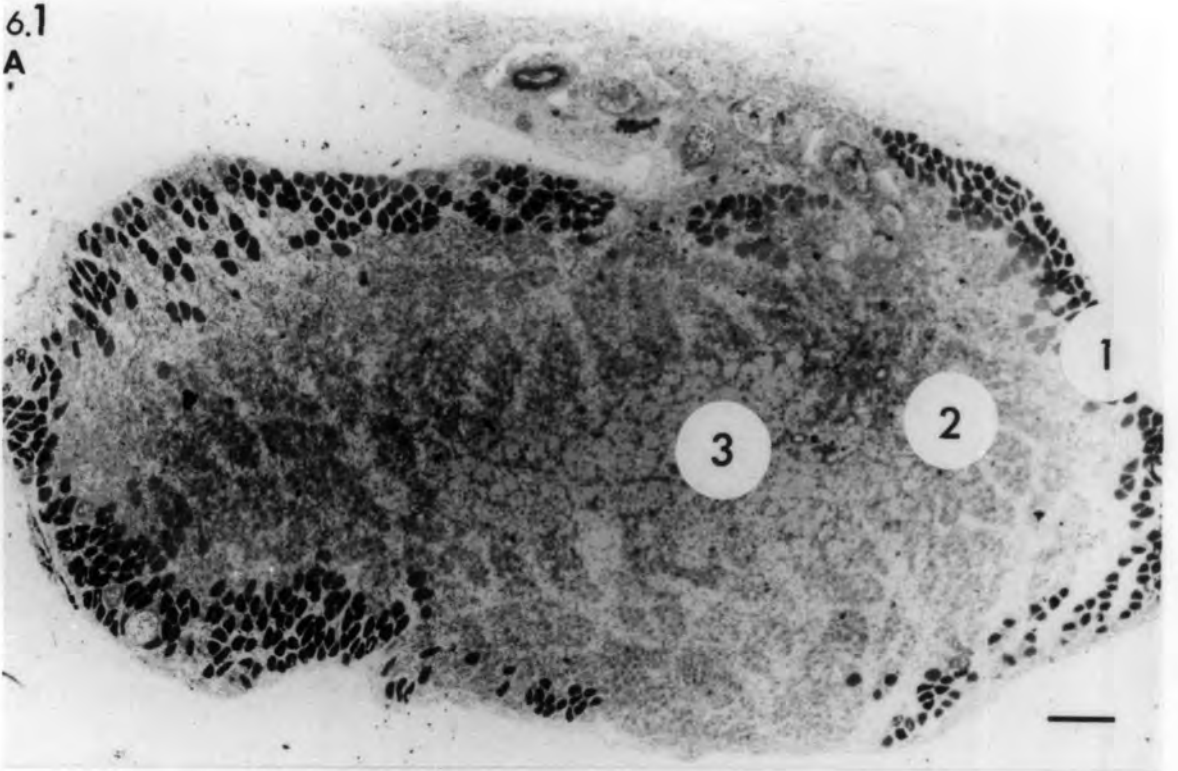


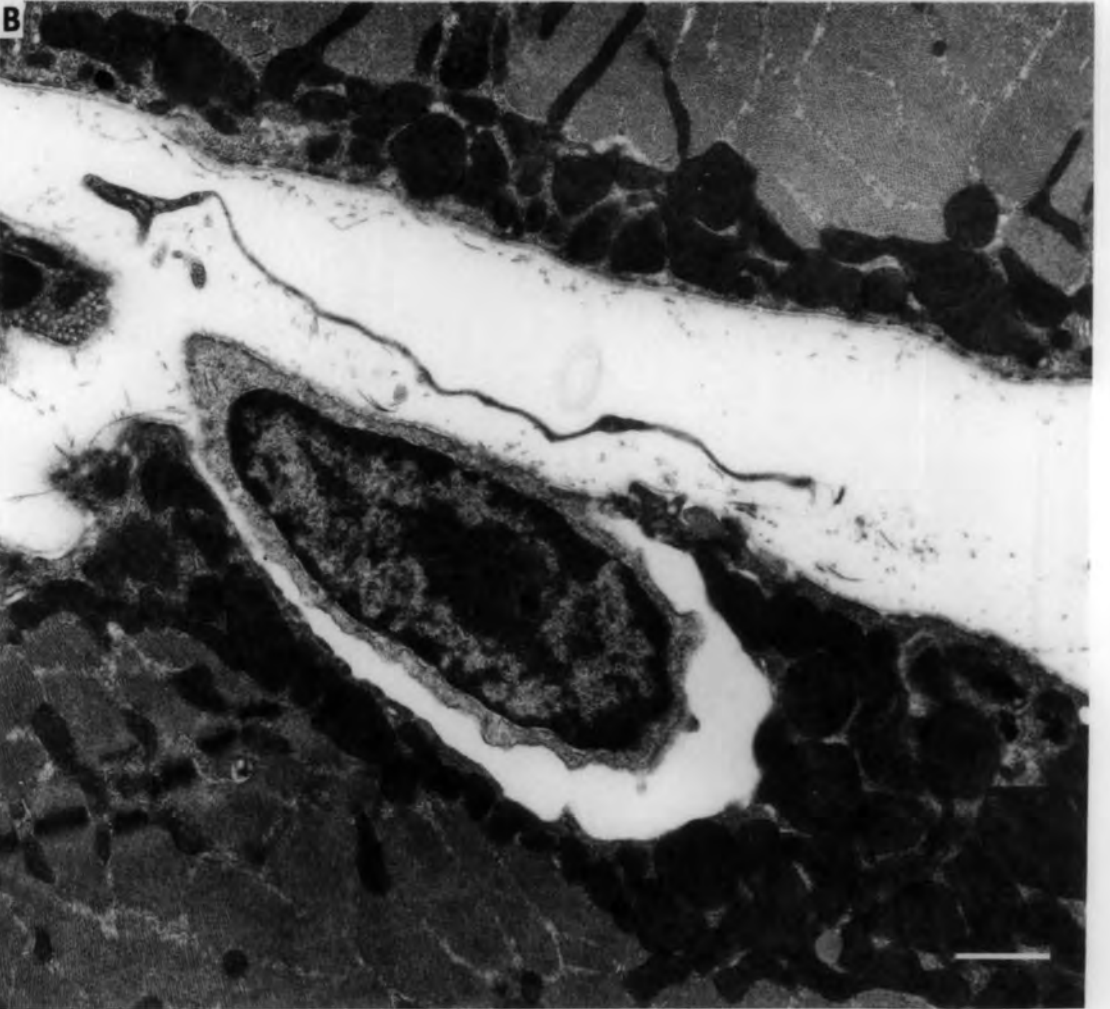
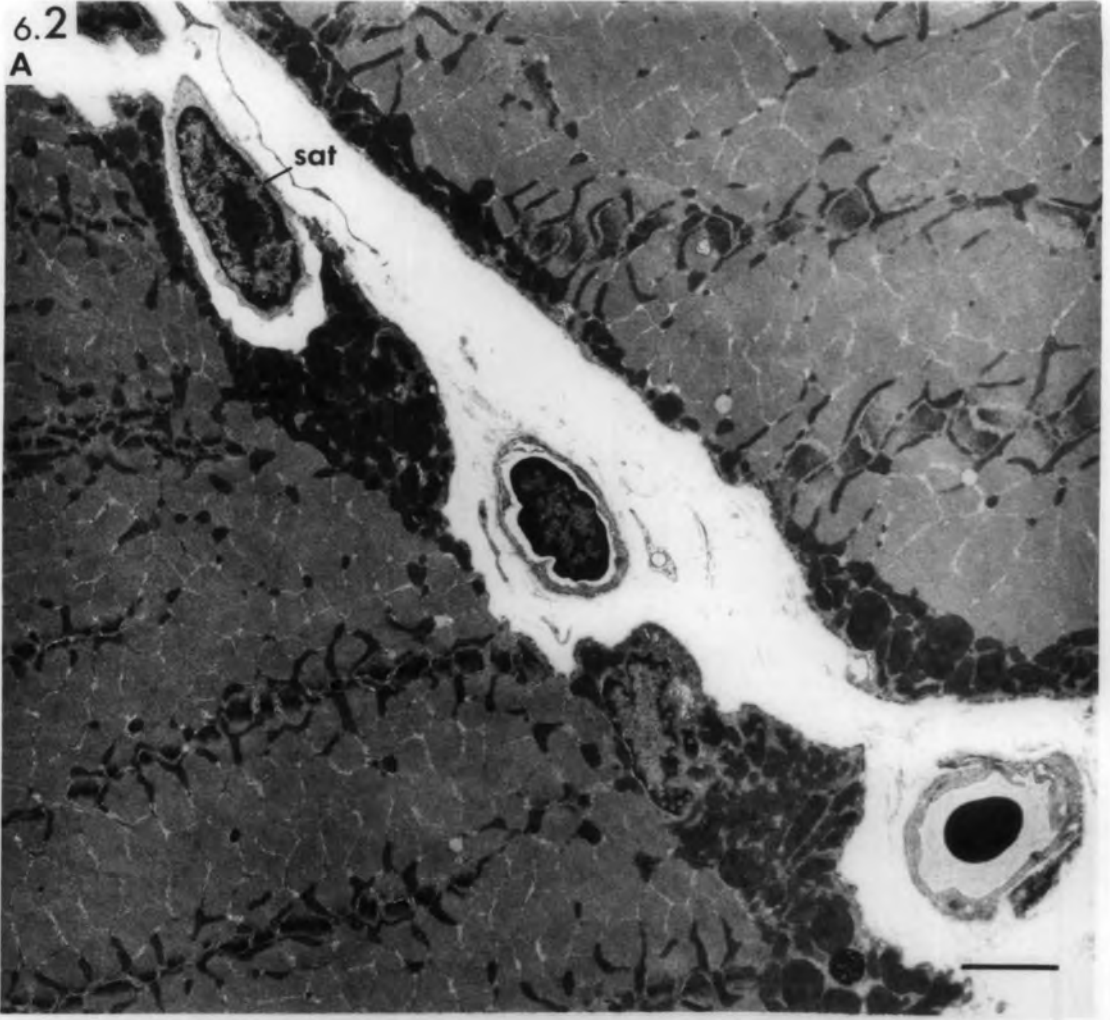
Fig. 6.2 Ischaemic muscle: Transverse section of  
extrafusal muscle fibres, 30 minutes after  
devascularization.

- A. Note the enlarged mitochondria accumulated  
at the muscle-fibre periphery.
  
- B. Higher power electron micrograph of the  
satellite cell (sat) shown in A. Note the  
empty cleft between the satellite cell and  
the muscle fibre.

bars= 1 $\mu$ m

6.2

A



Figs. 6.3, 6.4 Ischaemic muscle: transverse section of  
extrafusal muscle fibres 3 hours after  
devascularization.

6.3 Enlarged mitochondria with rod-like structures. Note the absence of sarcolemma from the two muscle fibres.

6.4 Note the absence of peripheral myofibrils. The Z-line is absent from other myofibrils. Note the pyknotic myonucleus (n), fragmented sarcolemma (arrow) and vesicularized sarcoplasmic system (SR).

bars = 1 $\mu$ m

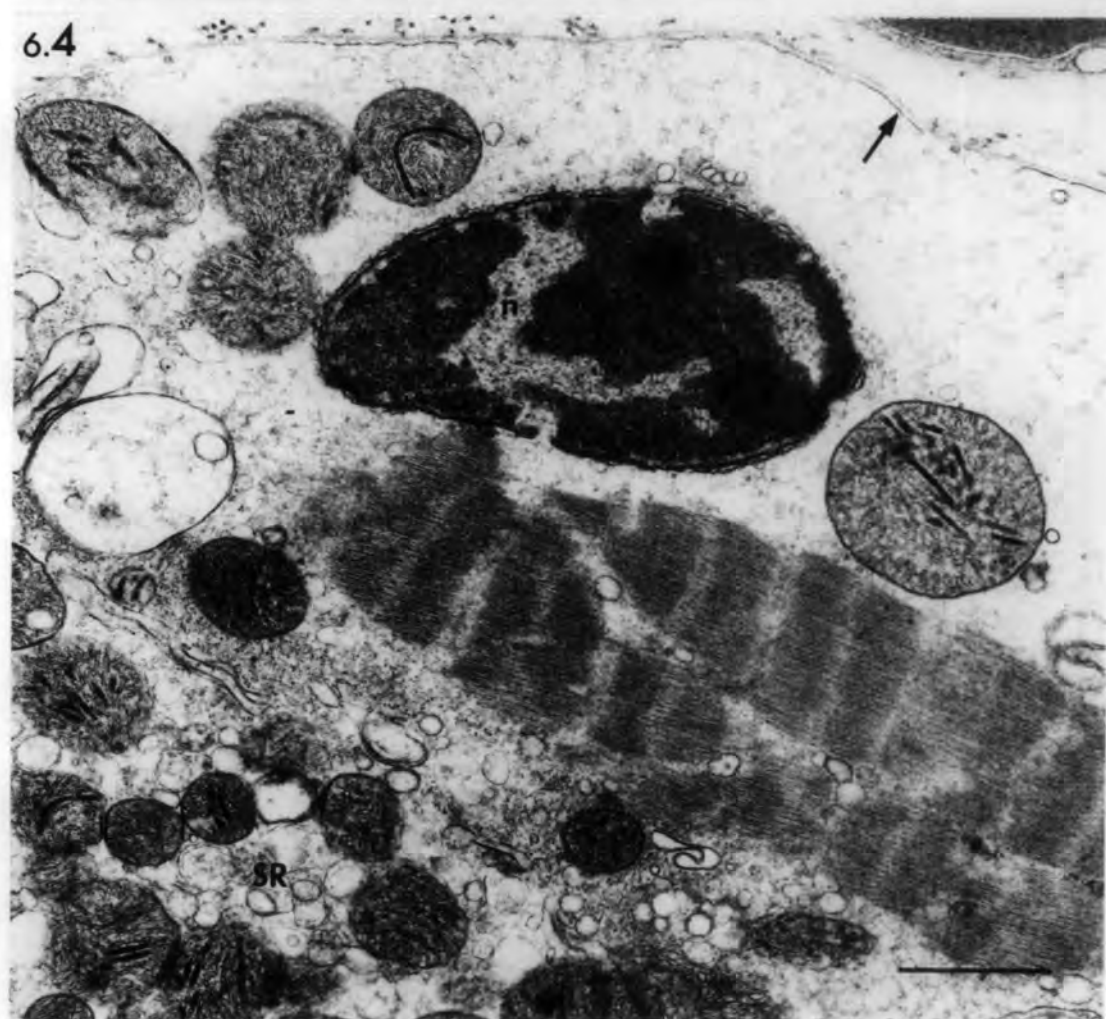
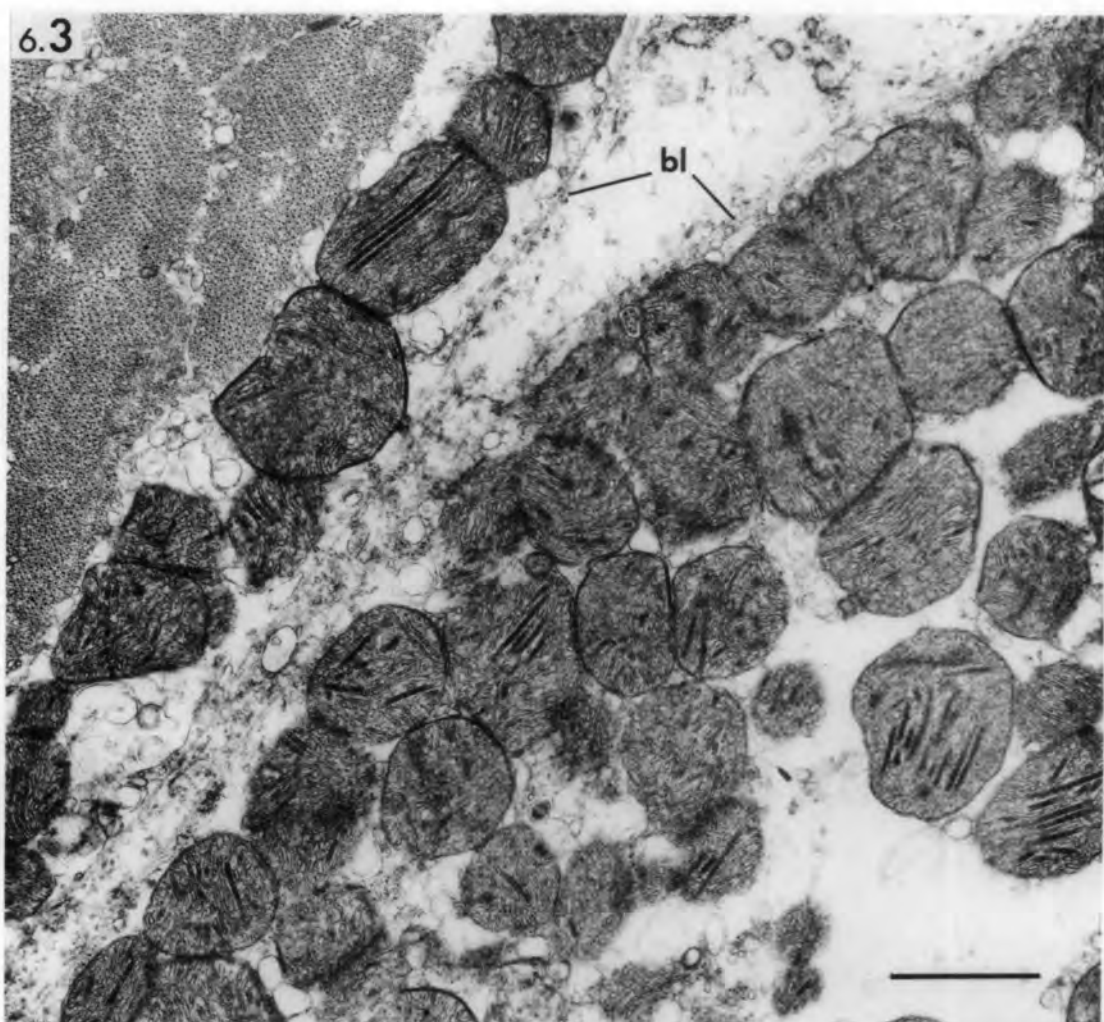


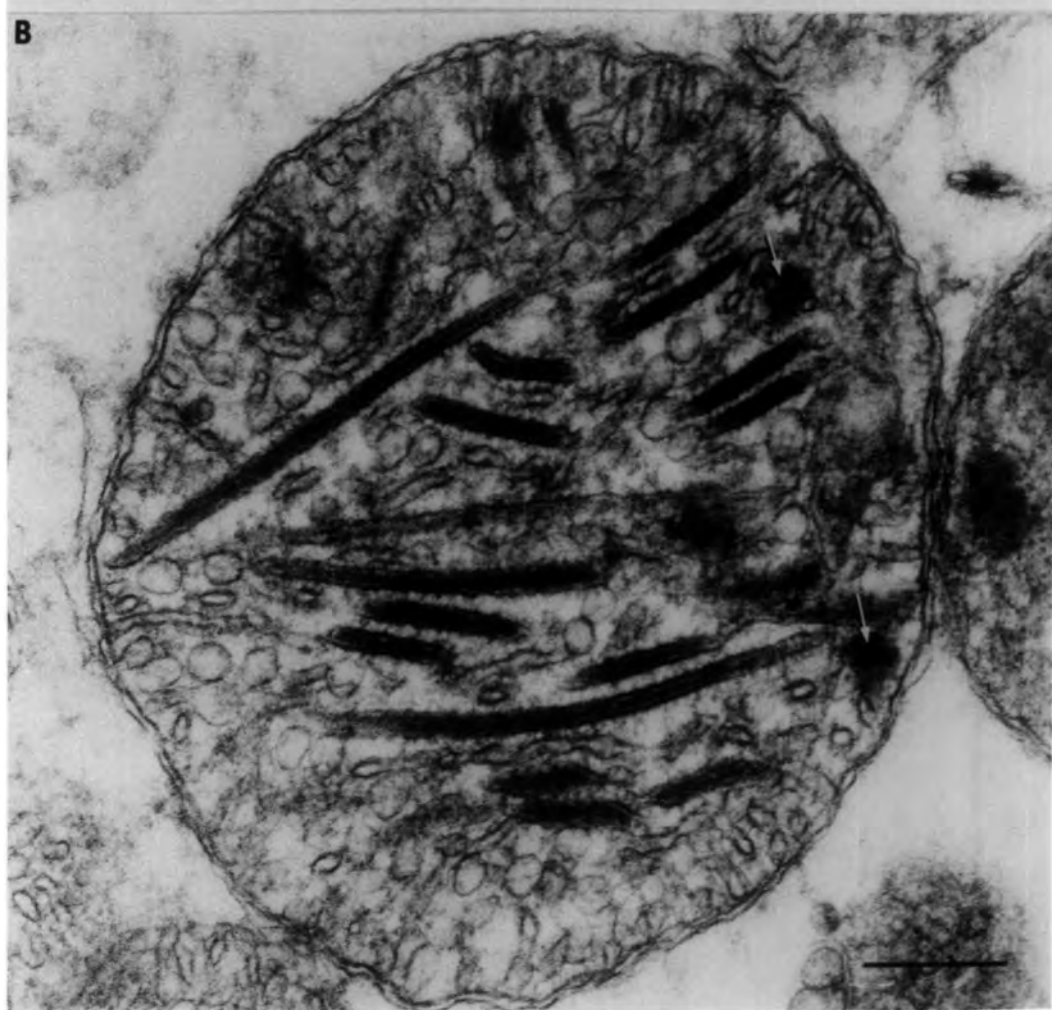
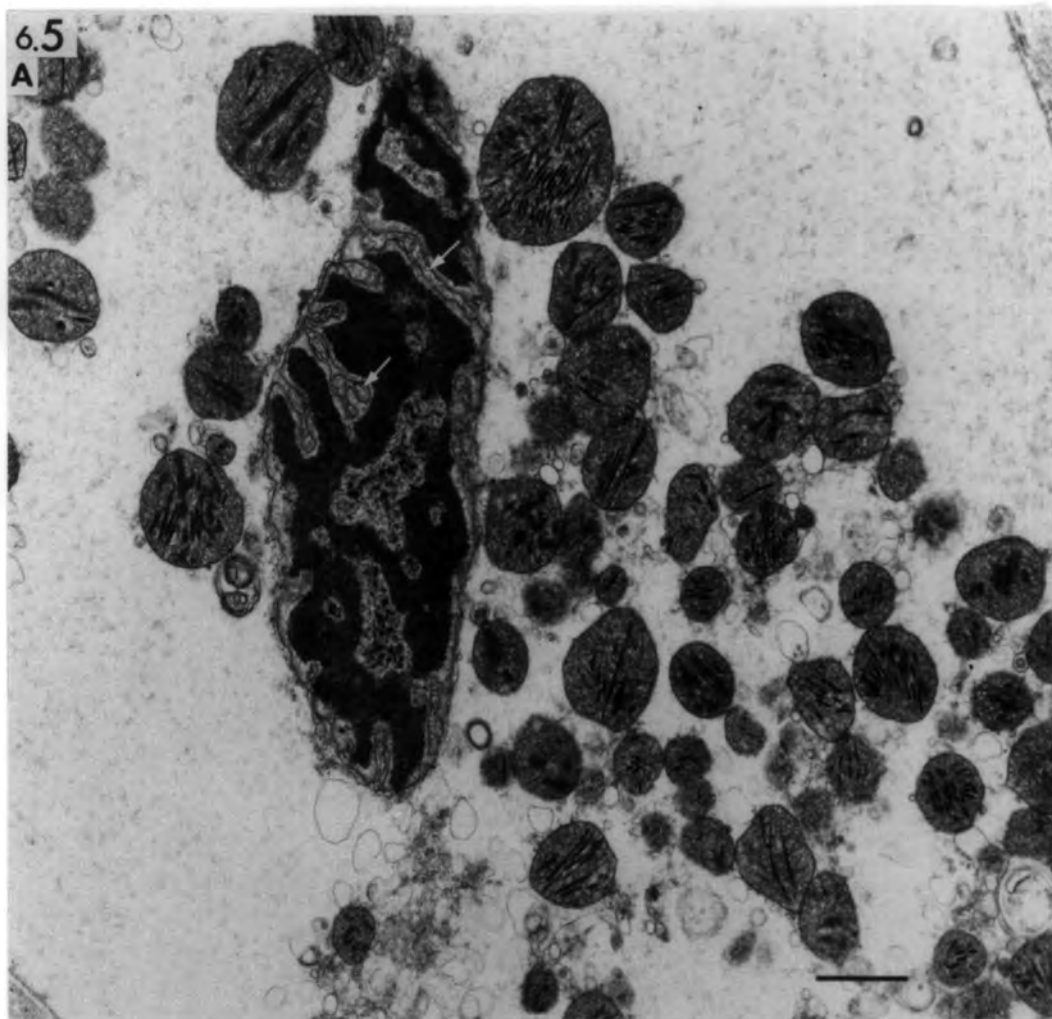
Fig. 6.5 Ischaemic muscle: transverse section of  
extrafusal muscle fibre 3 hours after  
devascularization.

- A. Note the absence of myofibrils and the  
invagination of the inner membrane of the  
pyknotic nucleus (arrows).

bar = 1 $\mu$ m

- B. High power of enlarged mitochondria. Note  
the altered cristae, rod-like structures  
and the dense osmiophilic bodies (arrows).

bar = 0.25 $\mu$ m



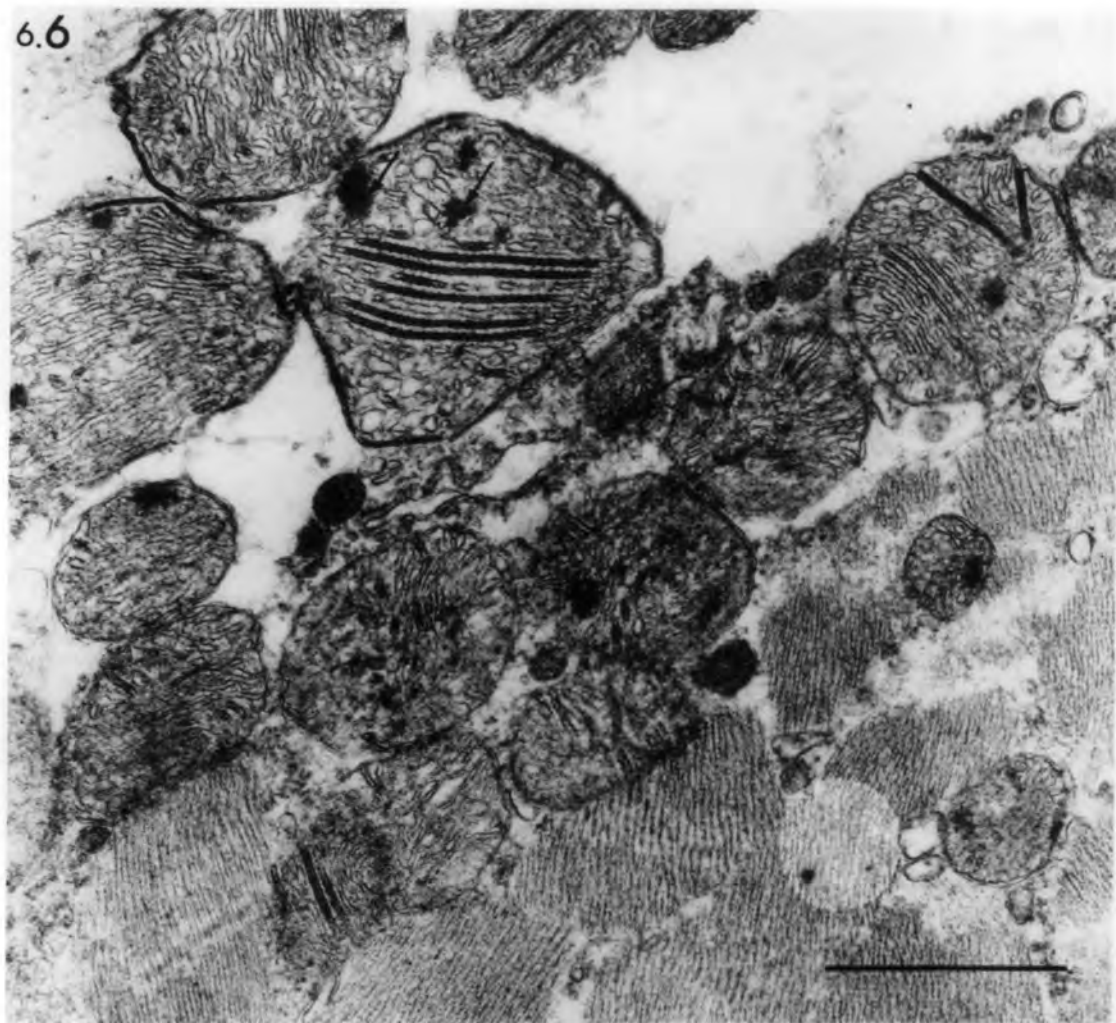
Figs. 6.6, 6.7 Ischaemic muscle: transverse section of  
extrafusal muscle fibres 6 hours after  
devascularization.

6.6 Enlarged mitochondria with rod-like structures and dense osmiophilic bodies (arrows). Note the disorganized myofibrils.

6.7 Rod-like structures in sarcotubules (arrows).

bars= 1 $\mu$ m

6.6



6.7

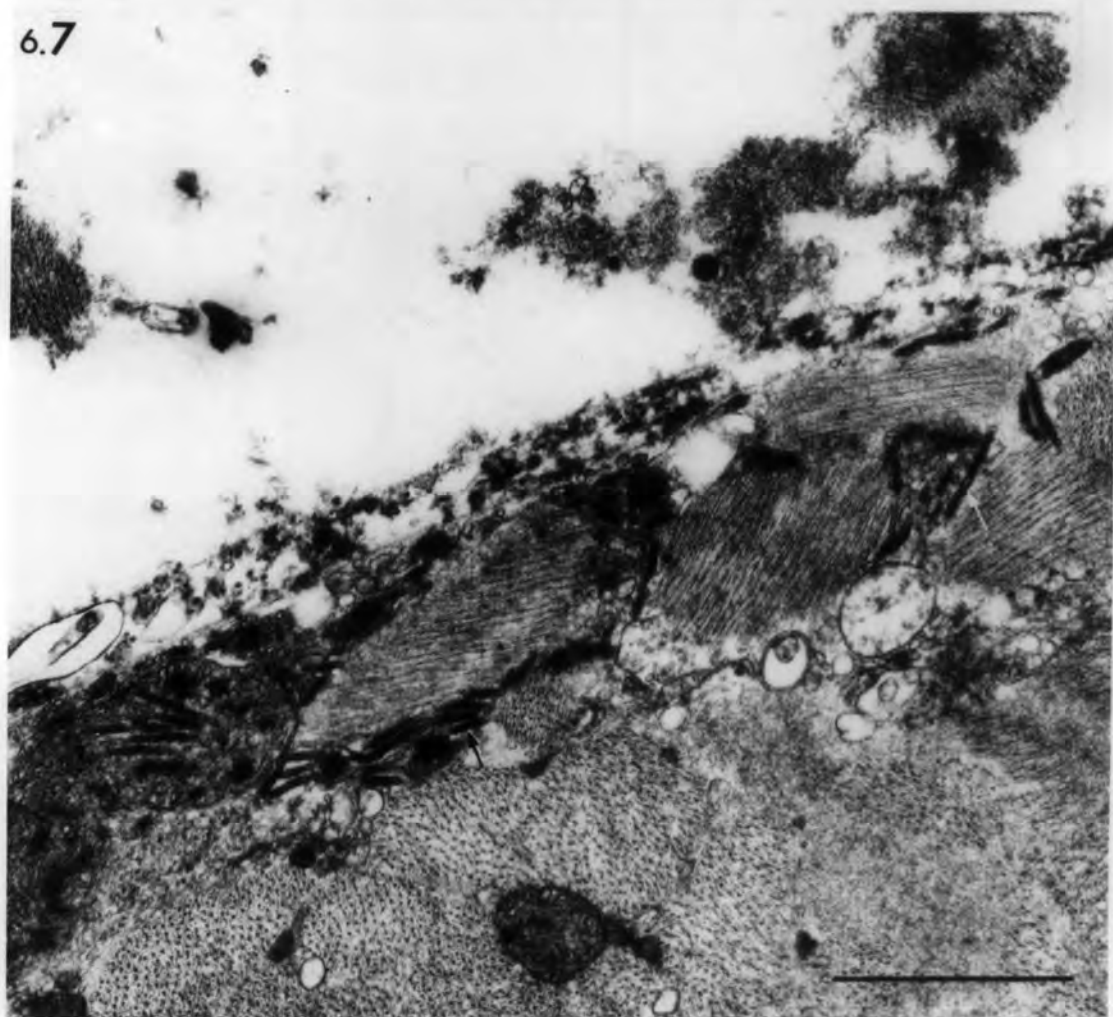


Fig. 6.8 Ischaemic muscle: transverse section of extrafusal muscle fibres 6 hours after devascularization.

- A. The lower muscle fibre shows Z-line streaming and disintegration (arrows). Altered mitochondria are present at the periphery of the upper muscle fibre.
  
- B. High power of (A) showing whorls of membrane and tubules in sub-laminal position of the muscle fibre.

bars = 1 $\mu$ m

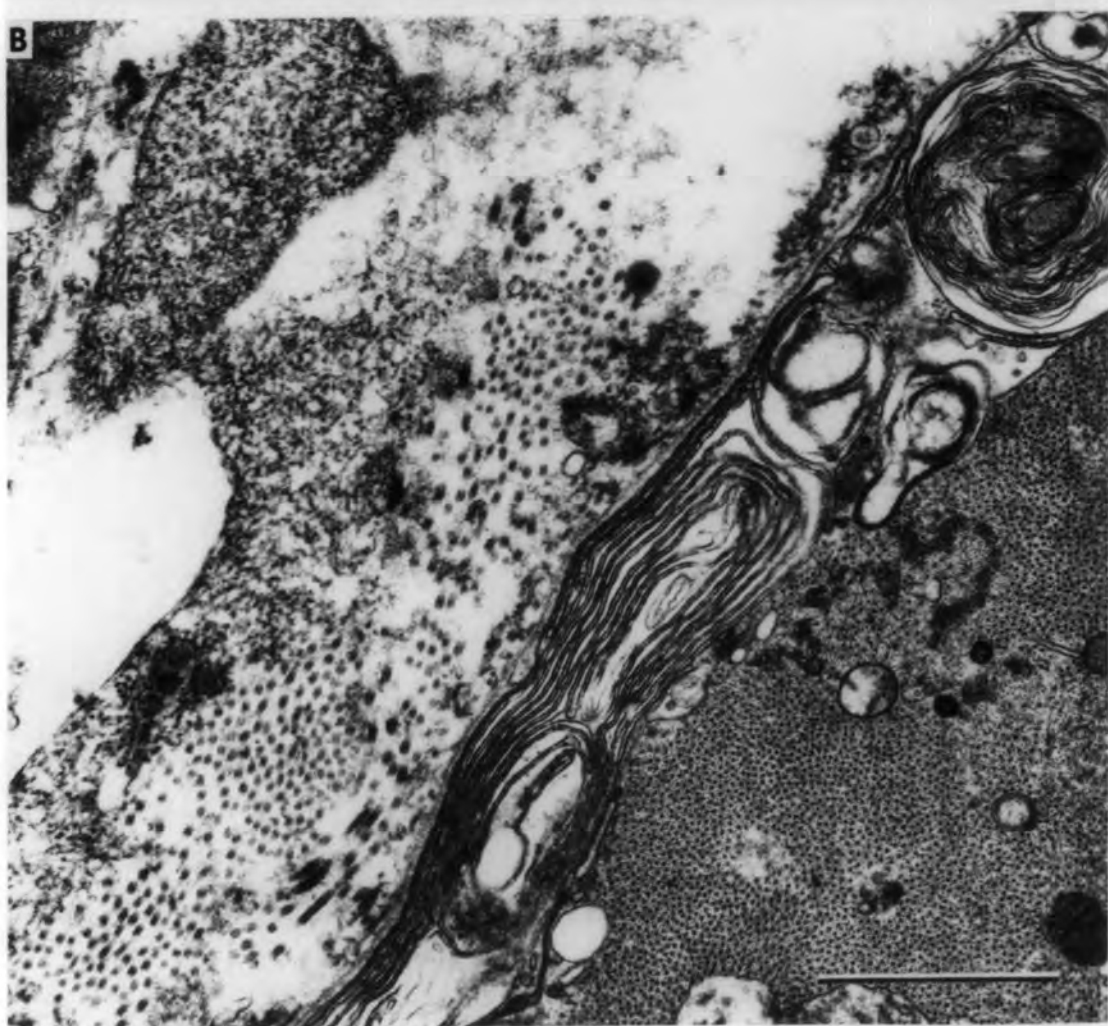
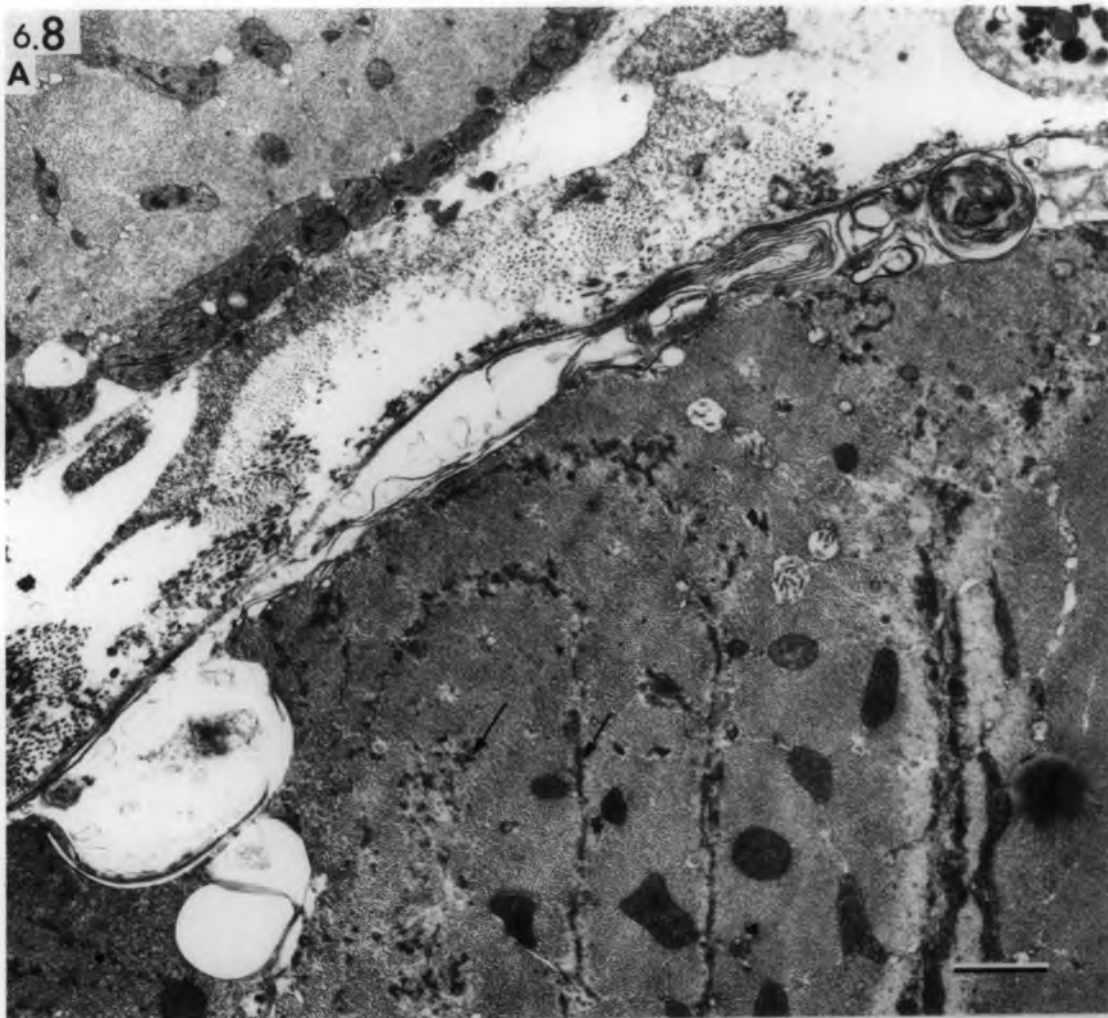

Fig. 6.9 Ischaemic muscle: transverse section of  
extrafusal muscle fibres 6 hours after  
devascularization.

Note the hyaline sarcoplasm in A & B, the  
pyknotic nucleus (n) in A and the invading  
granular leucocyte (arrow) in B.

bars = 1 $\mu$ m

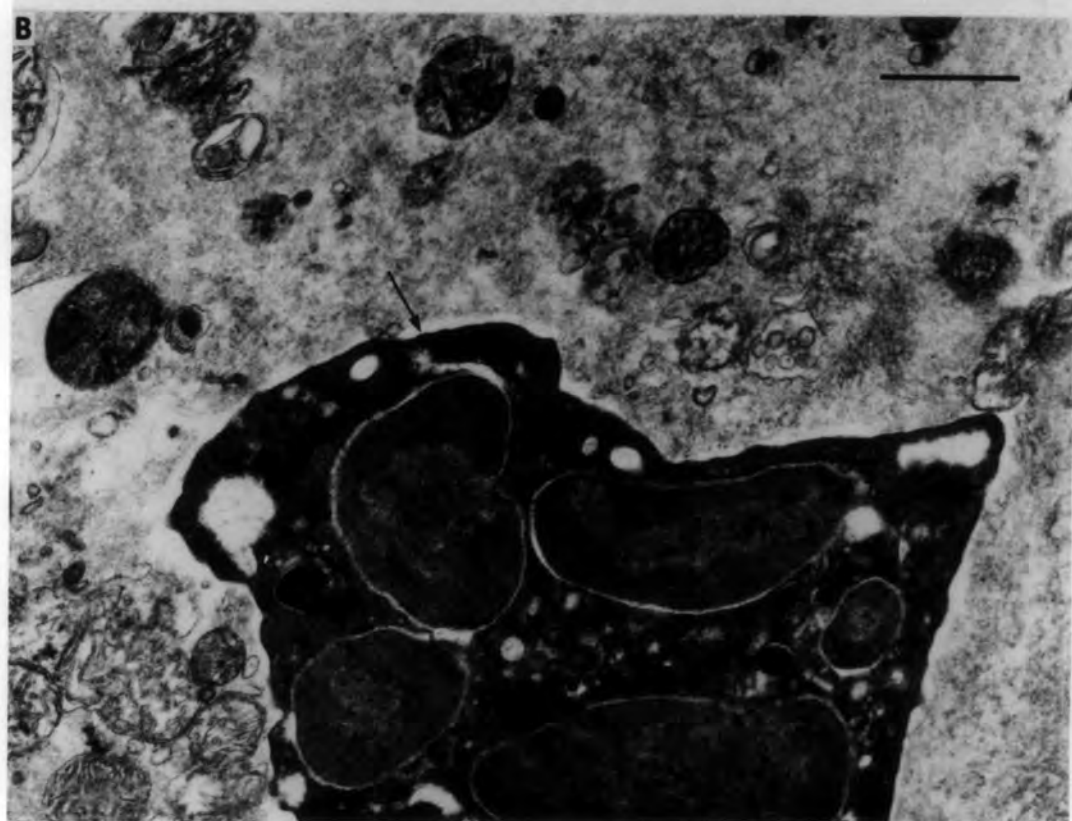
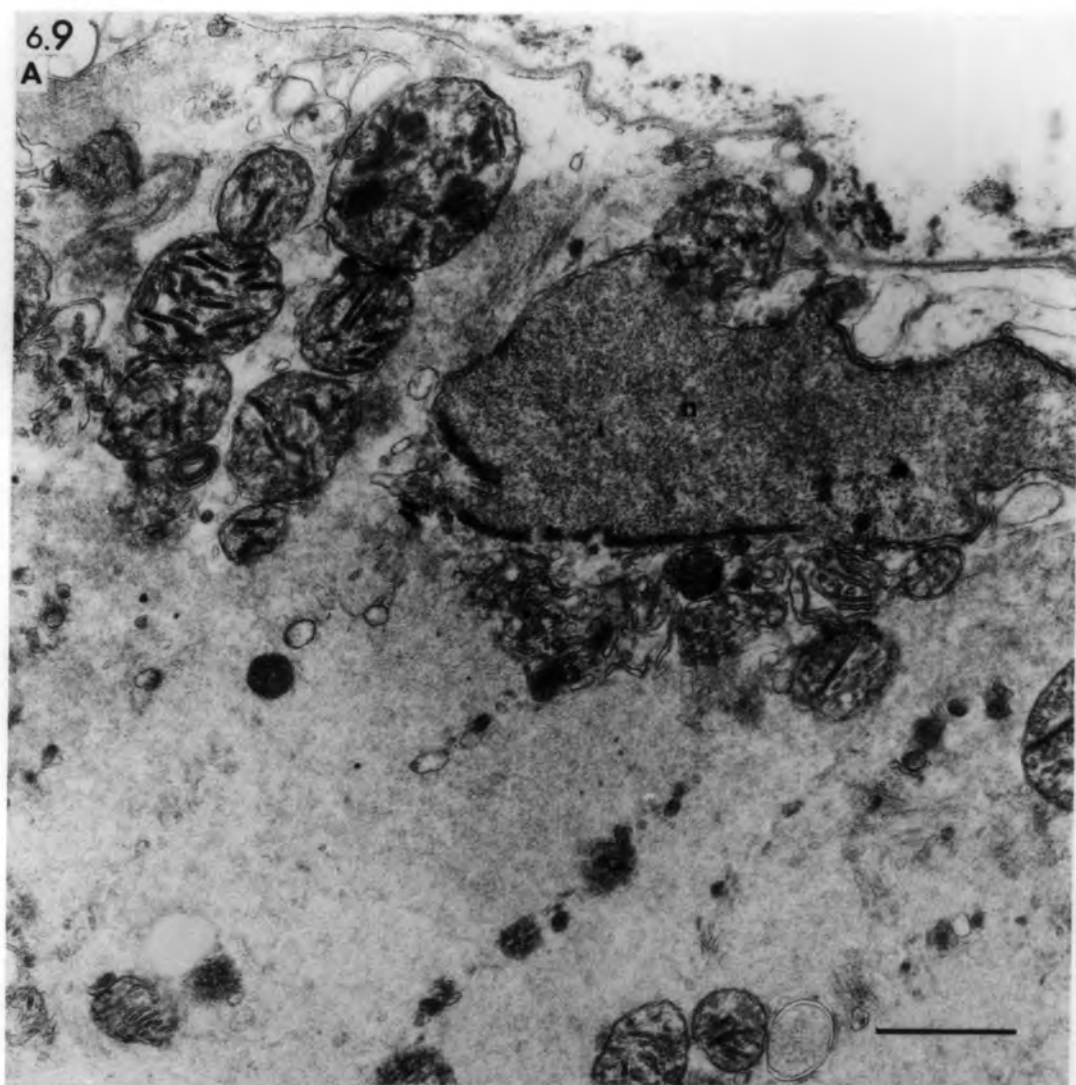


Fig. 6.10 Ischaemic muscle; transverse section of  
extrafusal muscle fibre 6 hours after  
devascularization.

A tube of preserved basal lamina (bl)  
contains remnants of degenerated sarcoplasm.

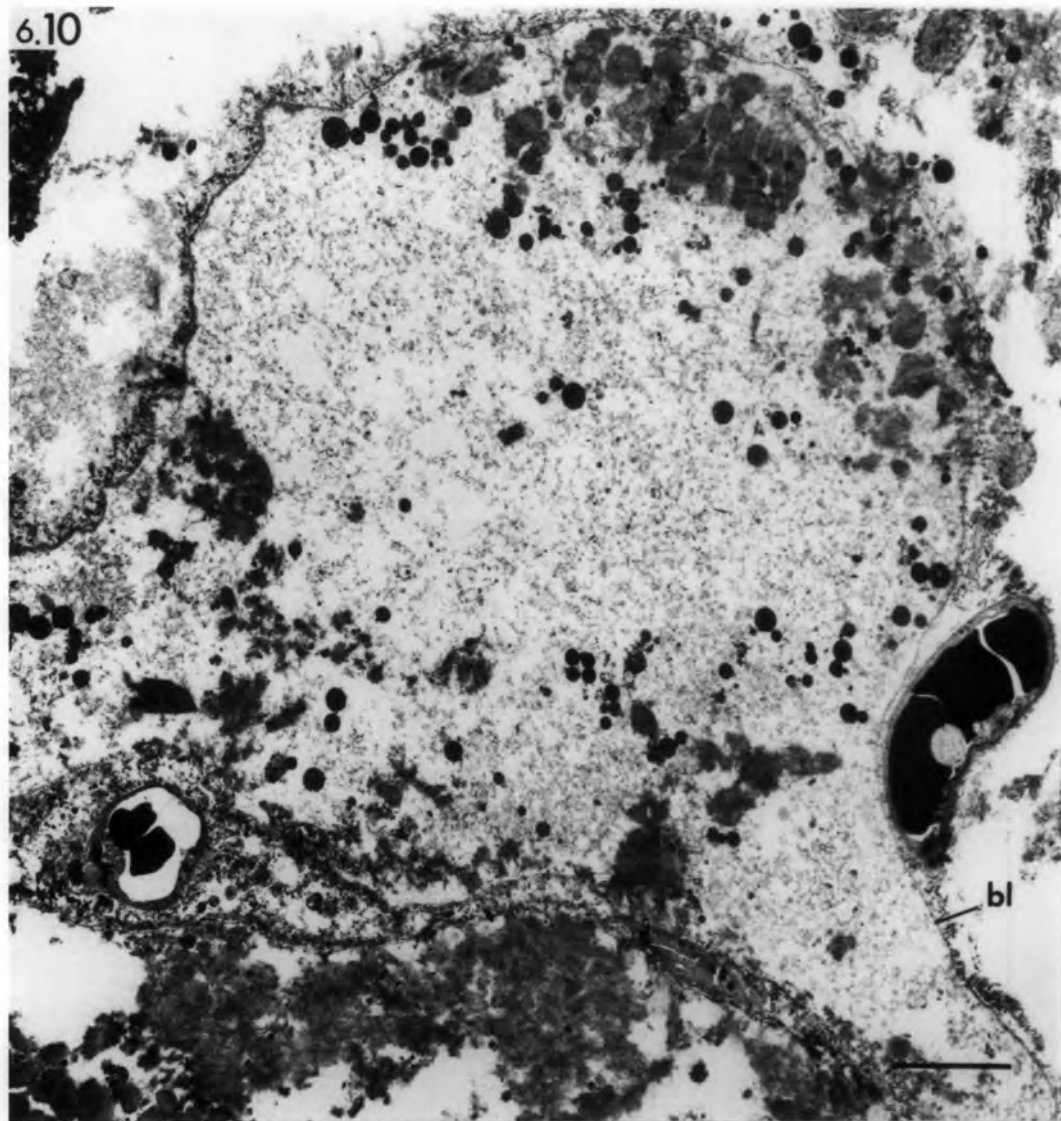
bar = 5 $\mu$ m

Fig. 6.11 Ischaemic muscle; transverse section of  
extrafusal muscle fibres 6 hours after  
devascularization.

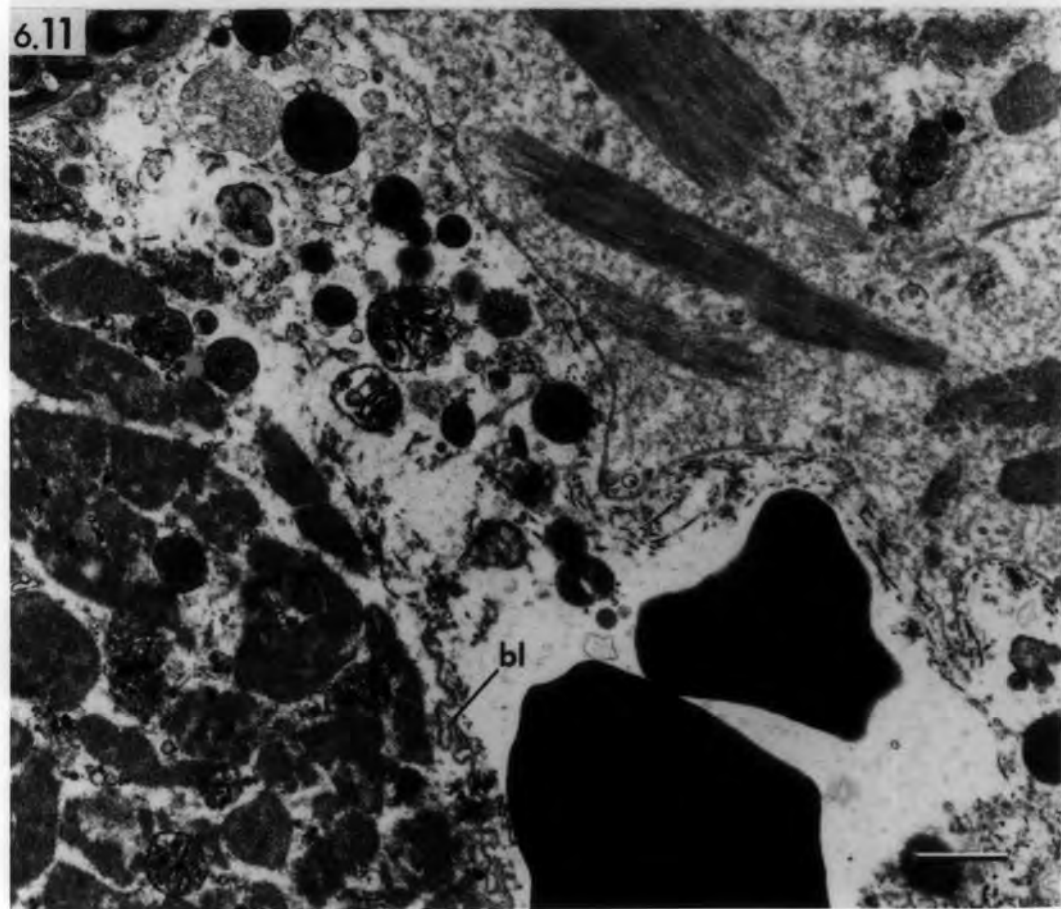
Note the broken basal lamina (bl) of the  
lower muscle fibre and the spilled sarcoplasm.

bar = 1 $\mu$ m

6.10



6.11

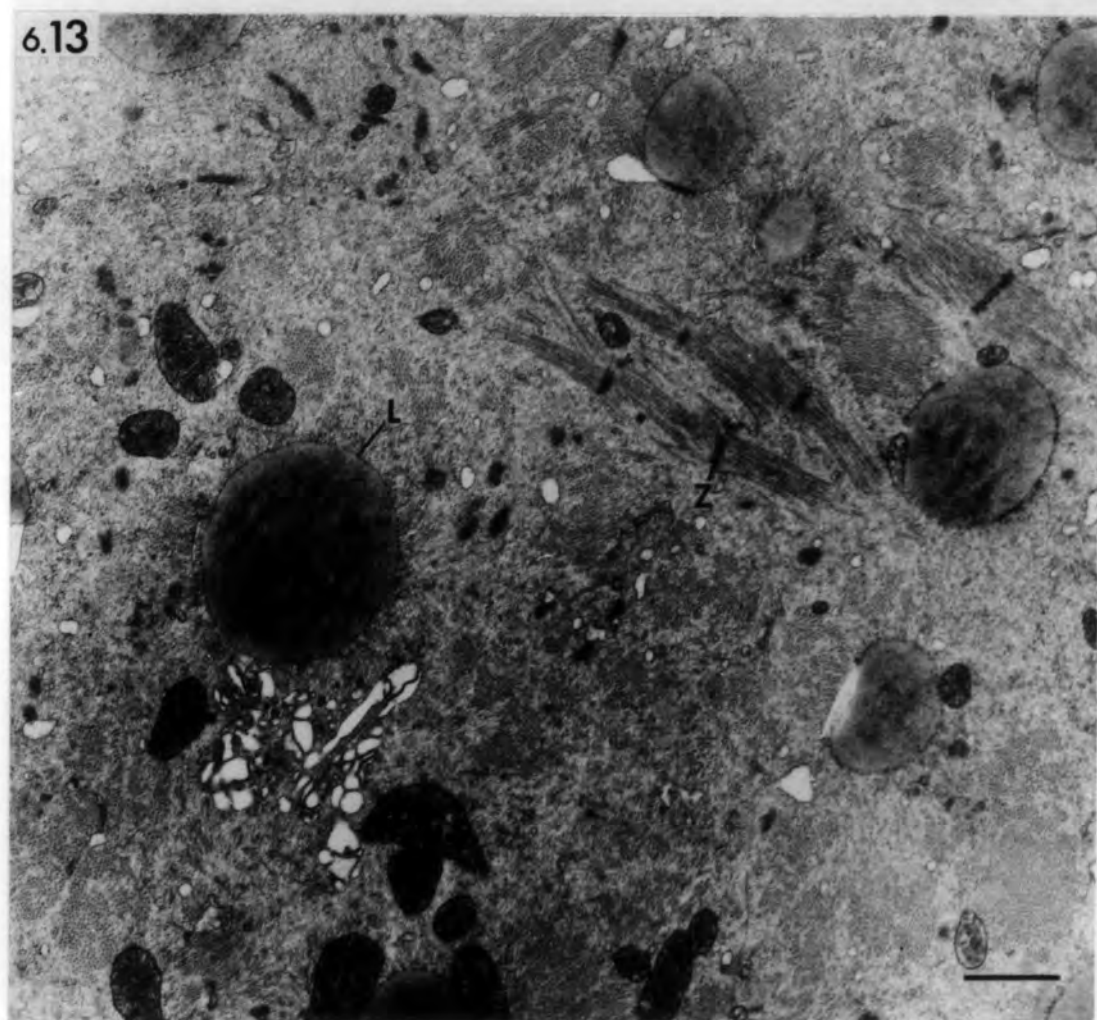
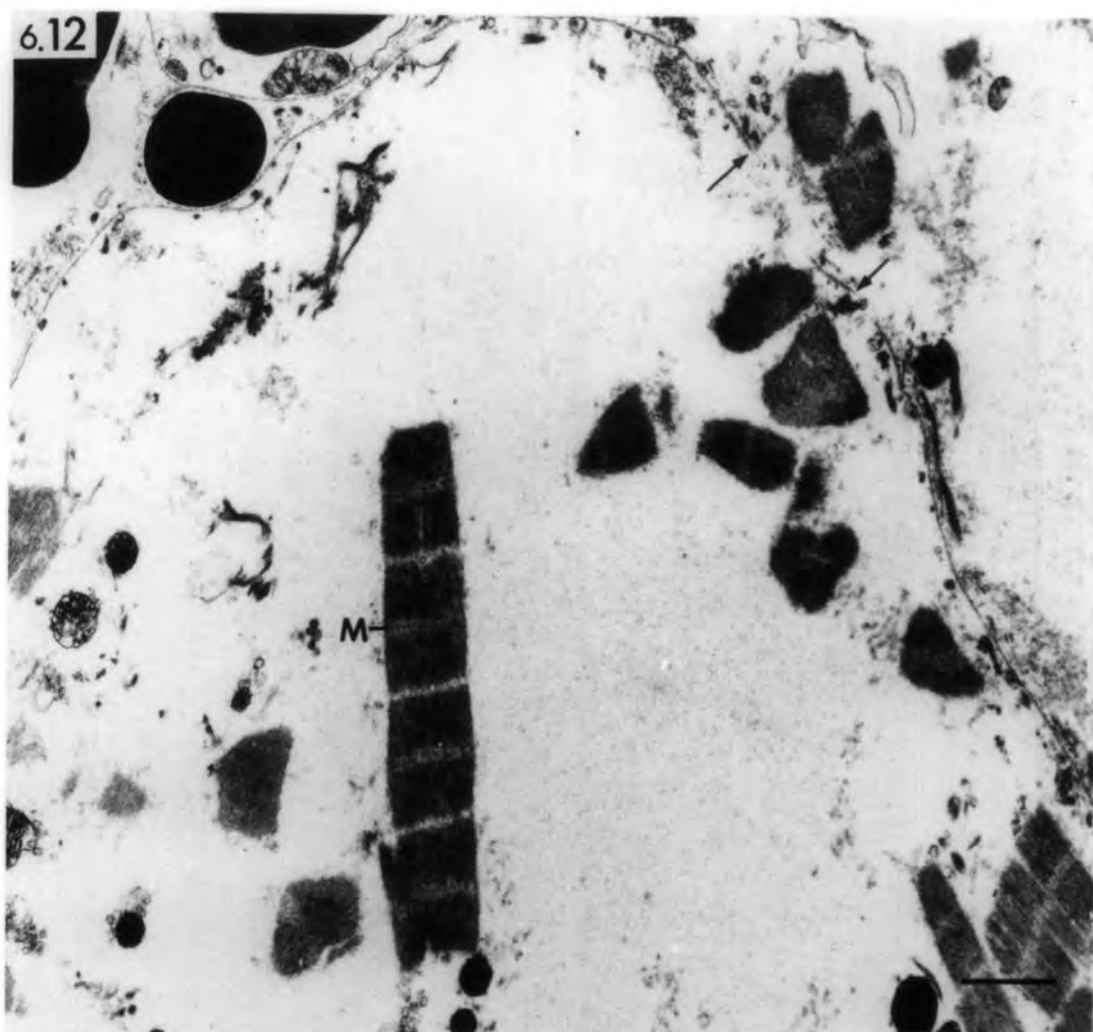


Figs. 6.12, 6.13 Ischaemic muscle: transverse section  
of extrafusal muscle fibres 2 days after  
devascularization.

6.12 Z-lines are absent from the  
persisting myofibrils but M-lines  
are present. Note the broken  
basal lamina (arrows)

6.13 Bundles of myofilaments are bound  
by preserved Z-lines.

bars = 1  $\mu$ m



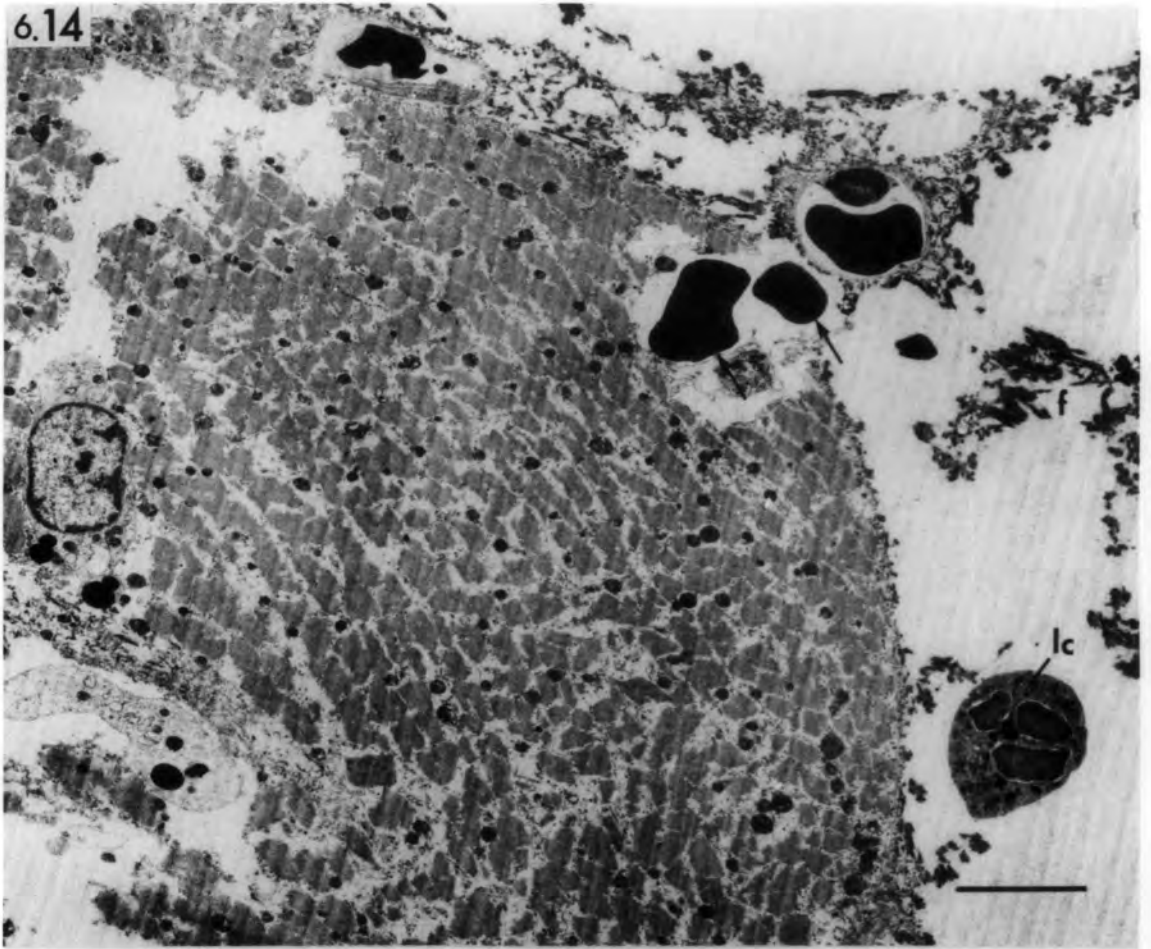
Figs. 6.14, 6.15 Ischaemic muscle: transverse sections of  
extrafusal muscle fibres 2 days after  
devascularization.

6.14 Erythrocytes (arrows) invading the  
muscle fibre through a break in the  
basal lamina. Note the fibrin  
deposits (f) in the interstitial  
space.

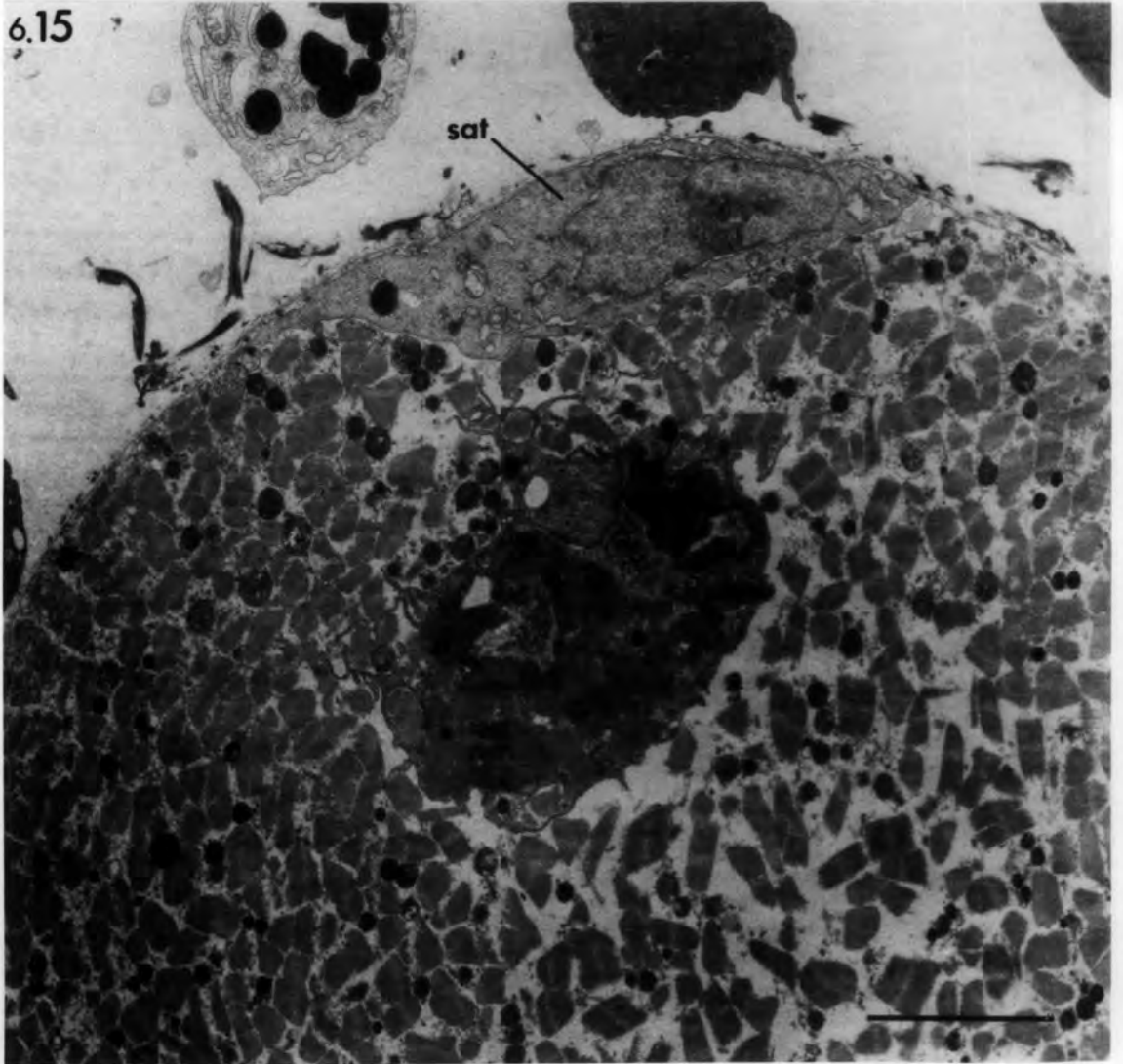
6.15 A macrophage engulfing contractile  
material. Note the activated  
satellite cell (sat).

bars = 5 $\mu$ m

6.14



6.15



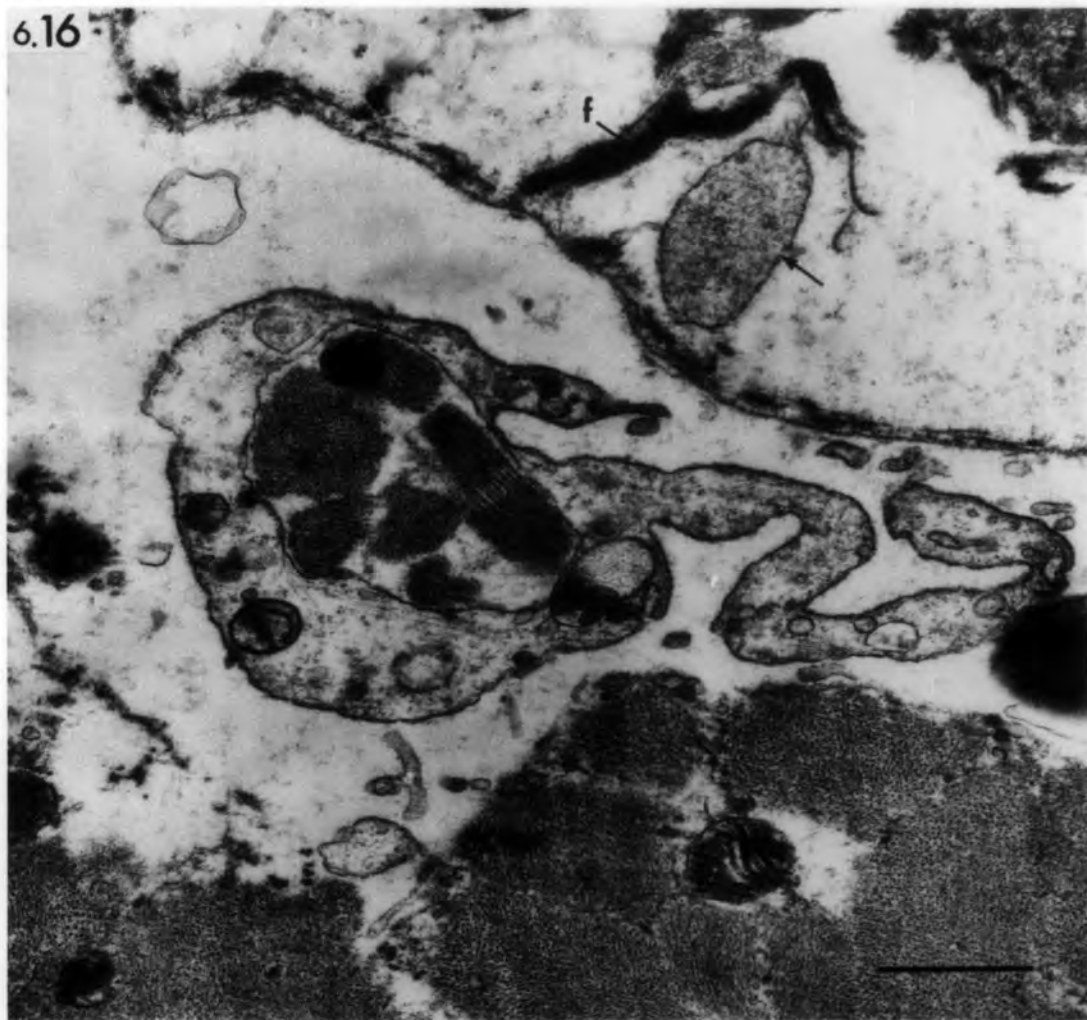
Figs. 6.16, 6.17 Ischaemic muscle.

6.16 Transverse section of extrafusal muscle fibre 2 days after devascularization showing contractile material engulfed by macrophage processes. Note the fibrin (f) and platelet (arrow) in the interstitial space.

6.17 Transverse section of extrafusal muscle fibre 6 hours after devascularization showing a granular leucocyte engulfing contractile material.

bars = 1 $\mu$ m

6.16



6.17

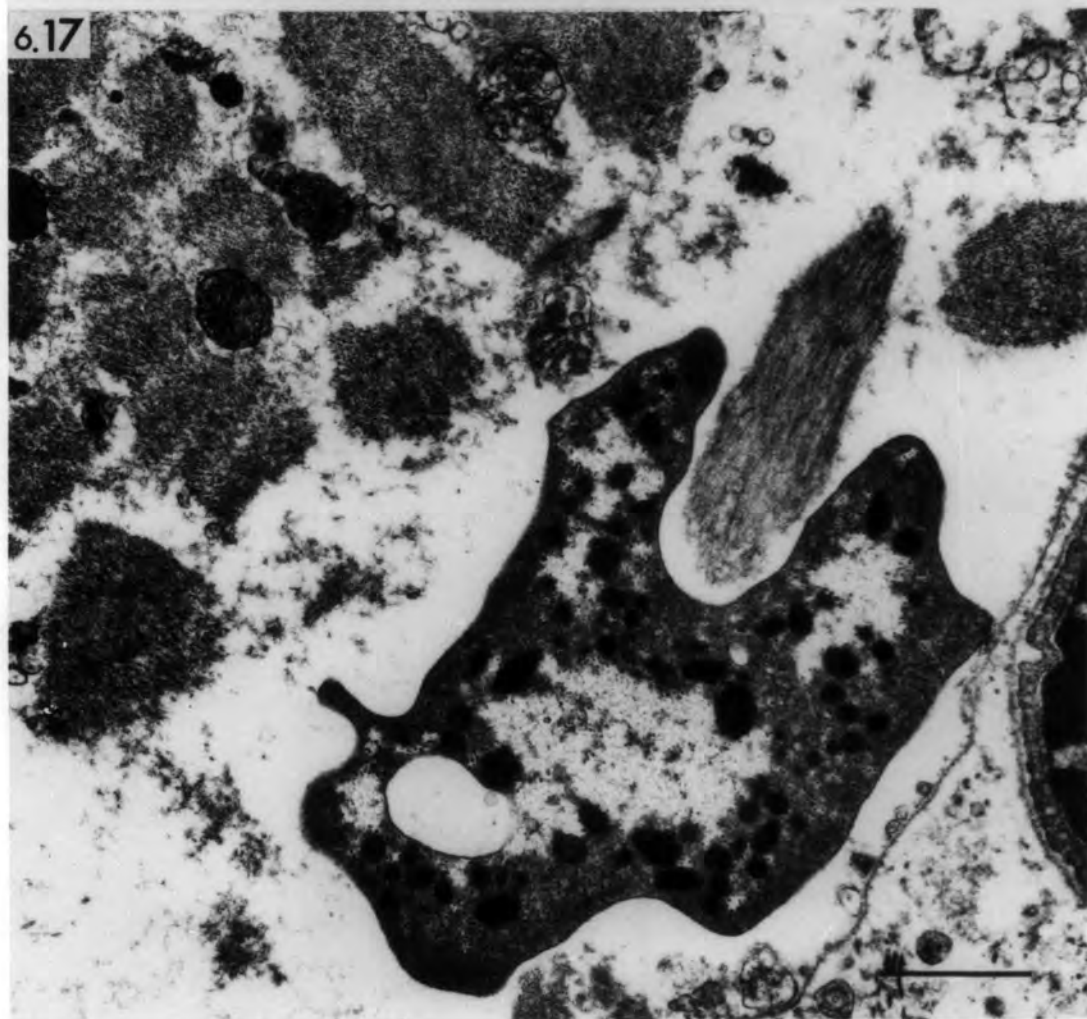


Fig. 6.18 Ischaemic muscle: 6 hours after devascularization.

Transverse section of degenerating extrafusal  
motor ending.

A. The folded basal lamina (arrows) represents the original post-junctional folds. The motor terminal is retracted and engulfed by a Schwann cell (Sc).

B. High power showing motor terminal debris within the Schwann cell.

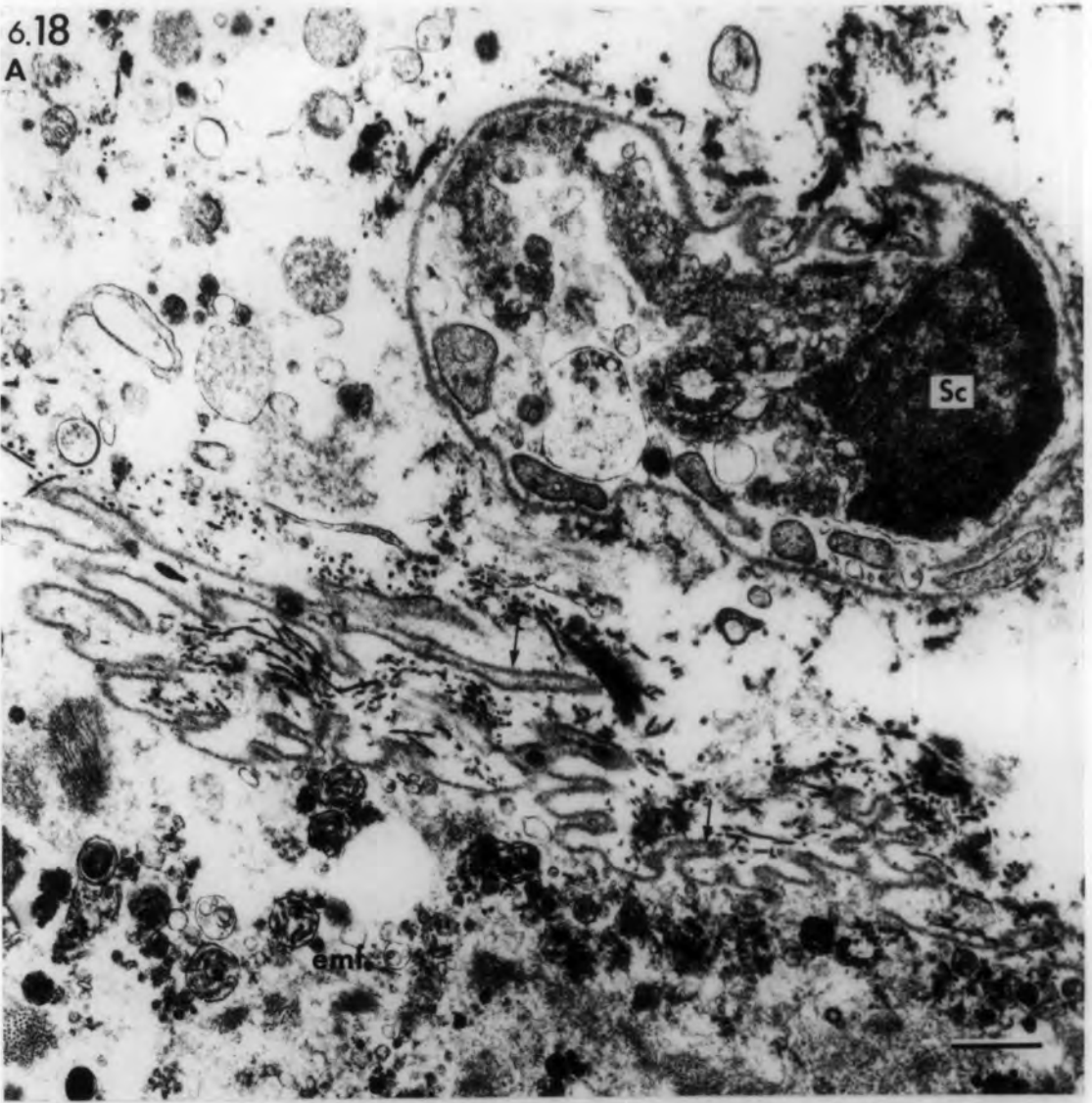
v: synaptic vesicles

bl: basal lamina of Schwann cell

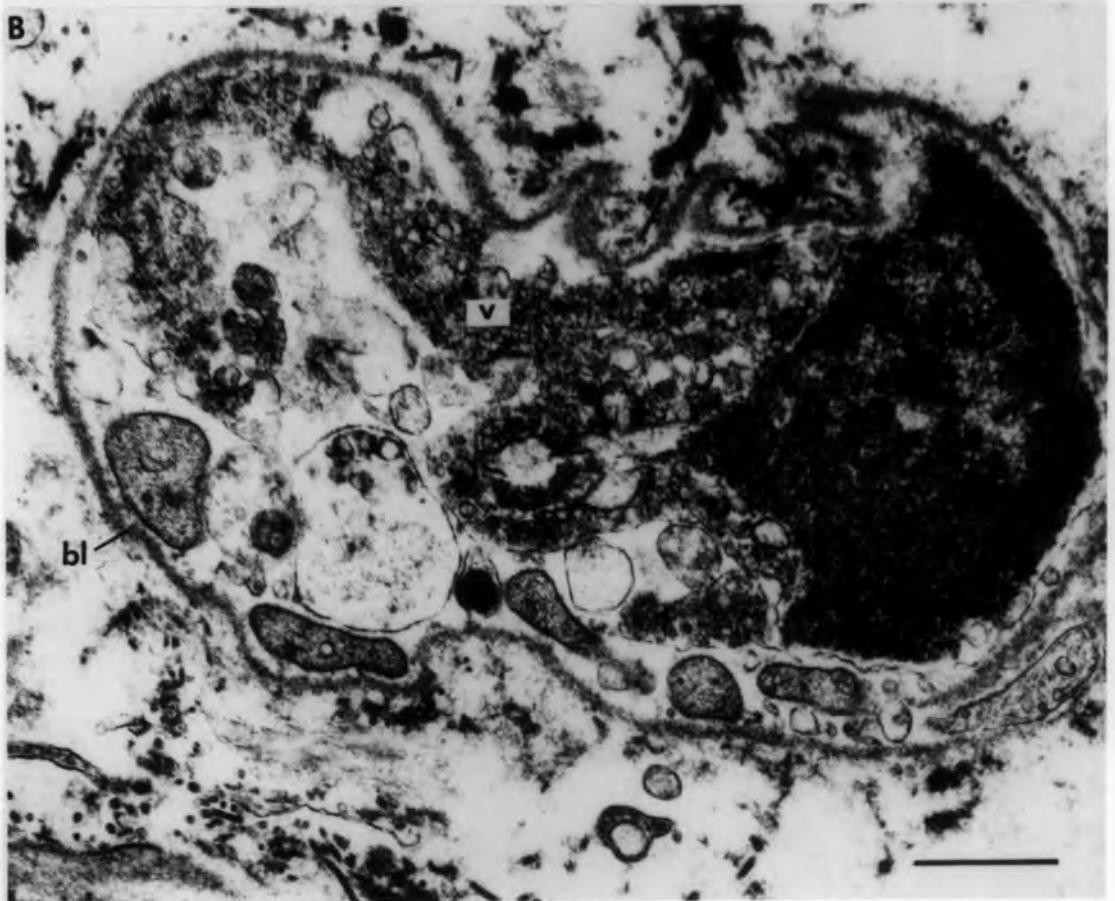bars = 1 $\mu$ m

6.18

A



B



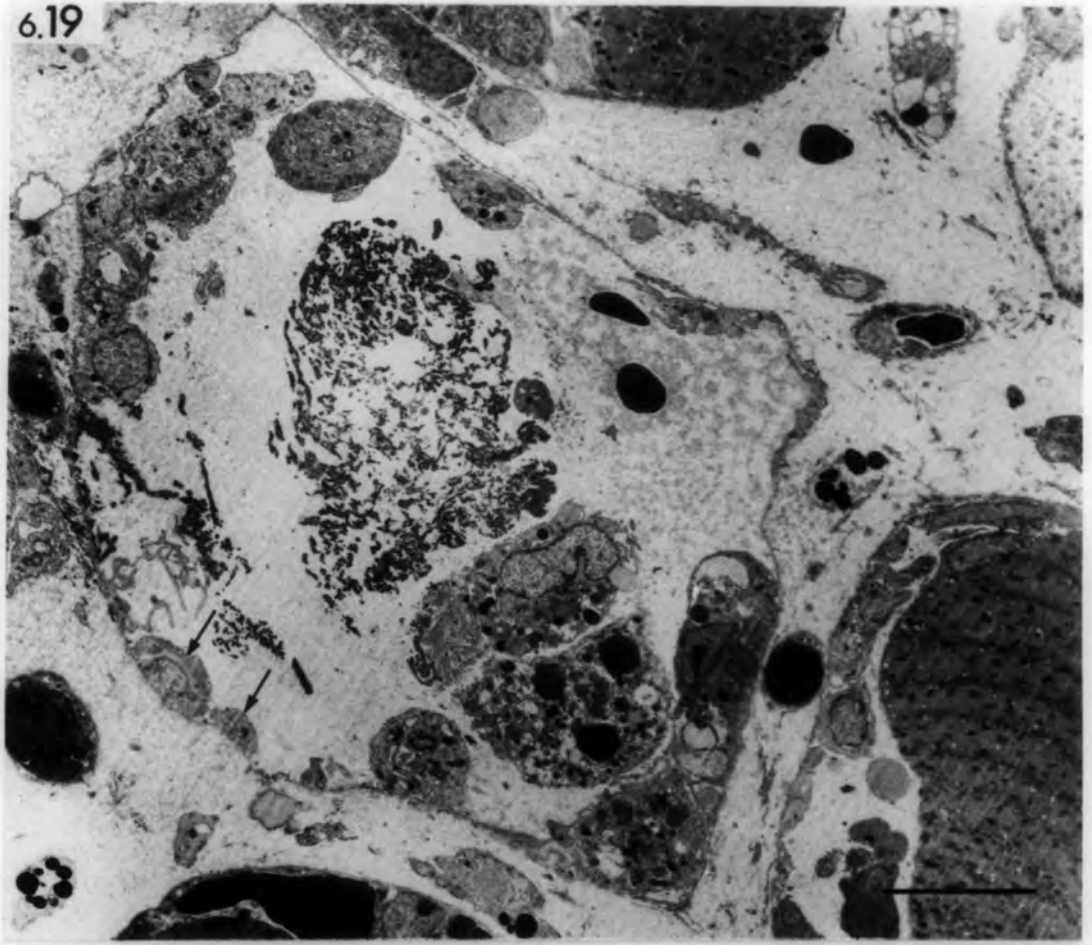
Figs. 6.19, 6.20 Ischaemic muscle: transverse sections  
of degenerated extrafusal muscle fibres  
3 days after devascularization.

6.19 A tube of basal lamina contains necrotic debris, inflammatory cells and myoblasts (arrow). The micrograph also shows three partially-damaged extrafusal fibres in which myoblasts are present.

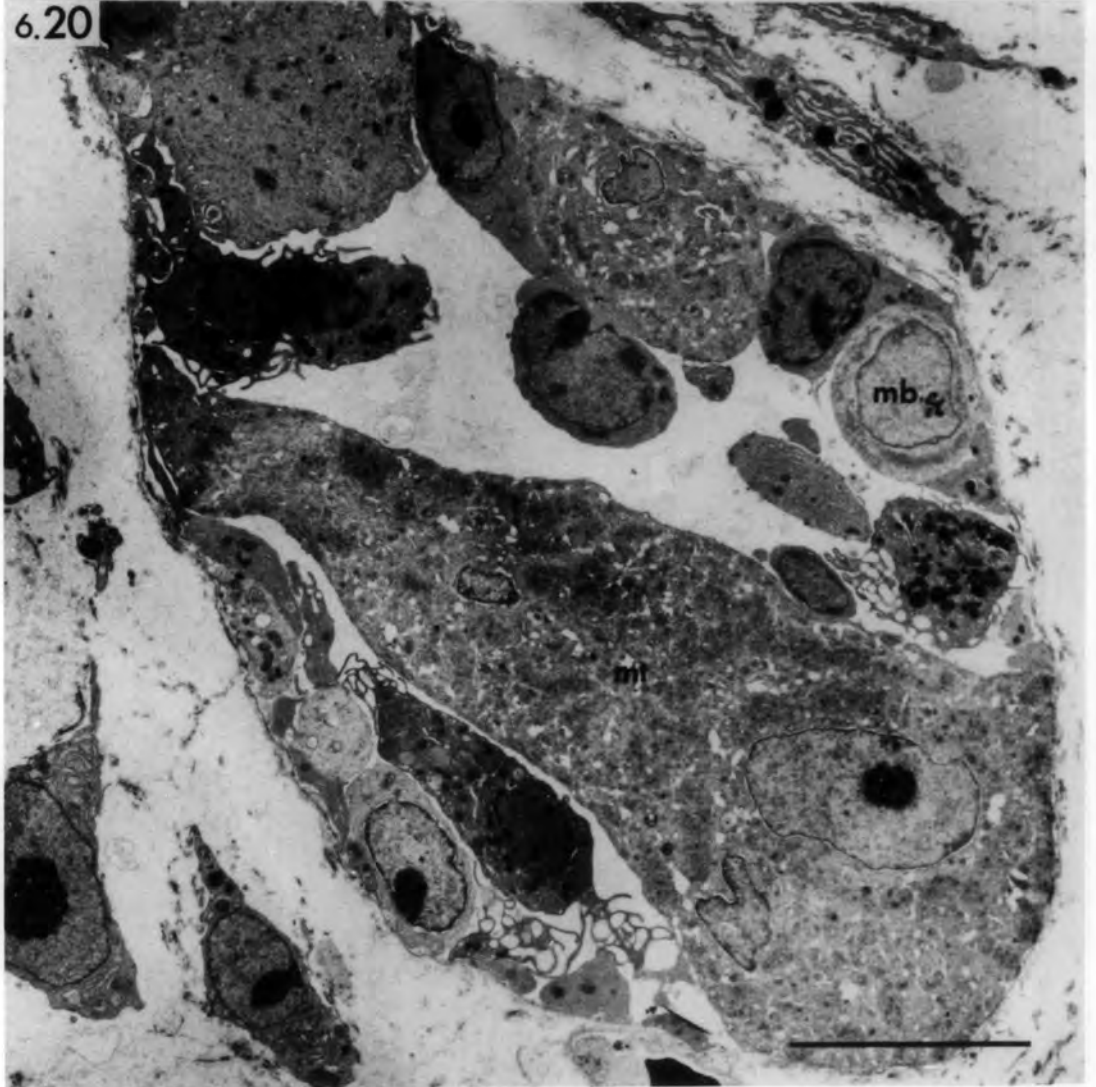
6.20 Necrotic debris is absent from this basal lamina tube and regeneration is more advanced. Both myoblasts (mb) and myotubes (mt) are present.

bars = 10 $\mu$ m

6.19



6.20



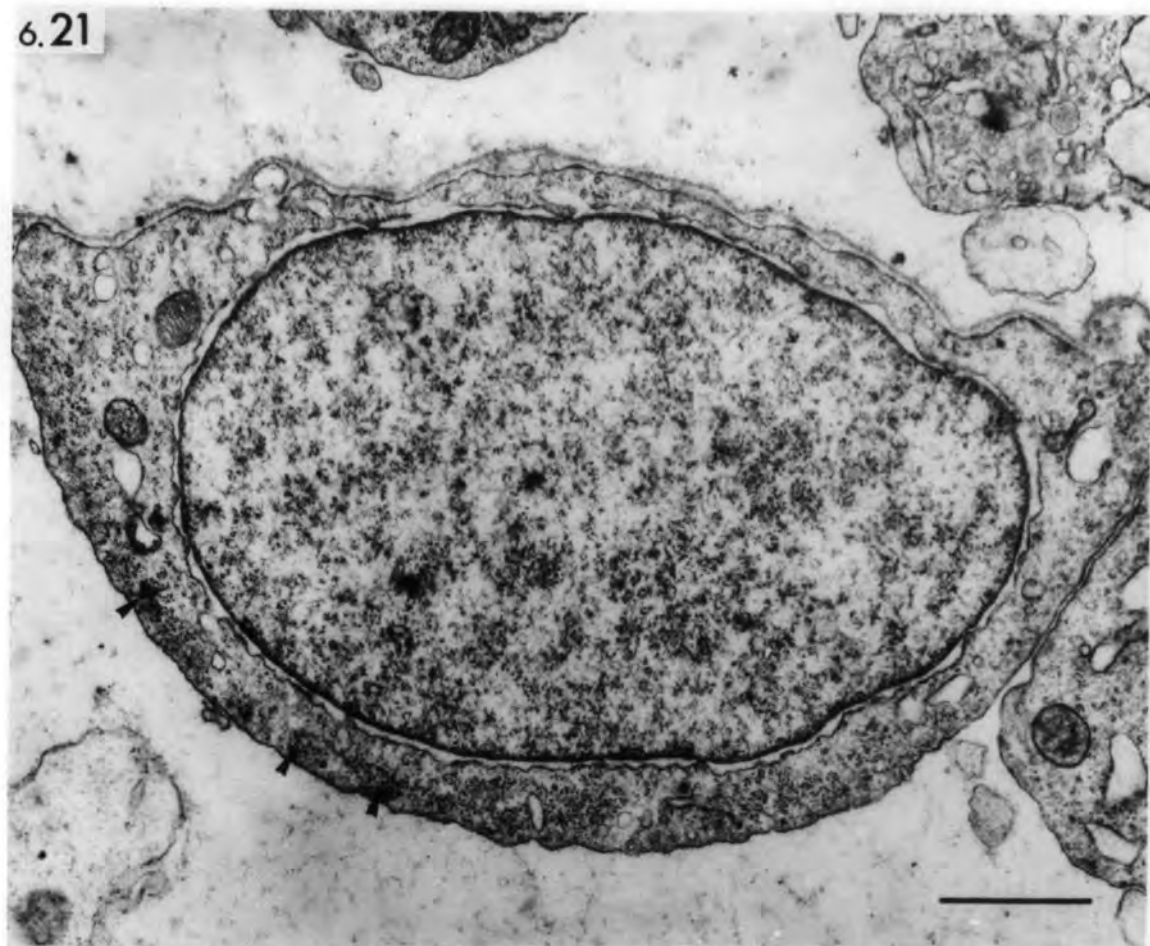
Figs. 6.21,6.22 Ischaemic muscle: transverse sections of  
regenerating extrafusal muscle fibres 3  
days after devascularization.

6.21 shows the ultrastructure of a presumptive myoblast. Note the high nucleo-cytoplasmic ratio. Early formation of myofilaments (arrowheads) may be observed at the cell's periphery.

6.22 shows a mass of cytoplasm containing four round nuclei.

bars = 1µm

6.21



6.22

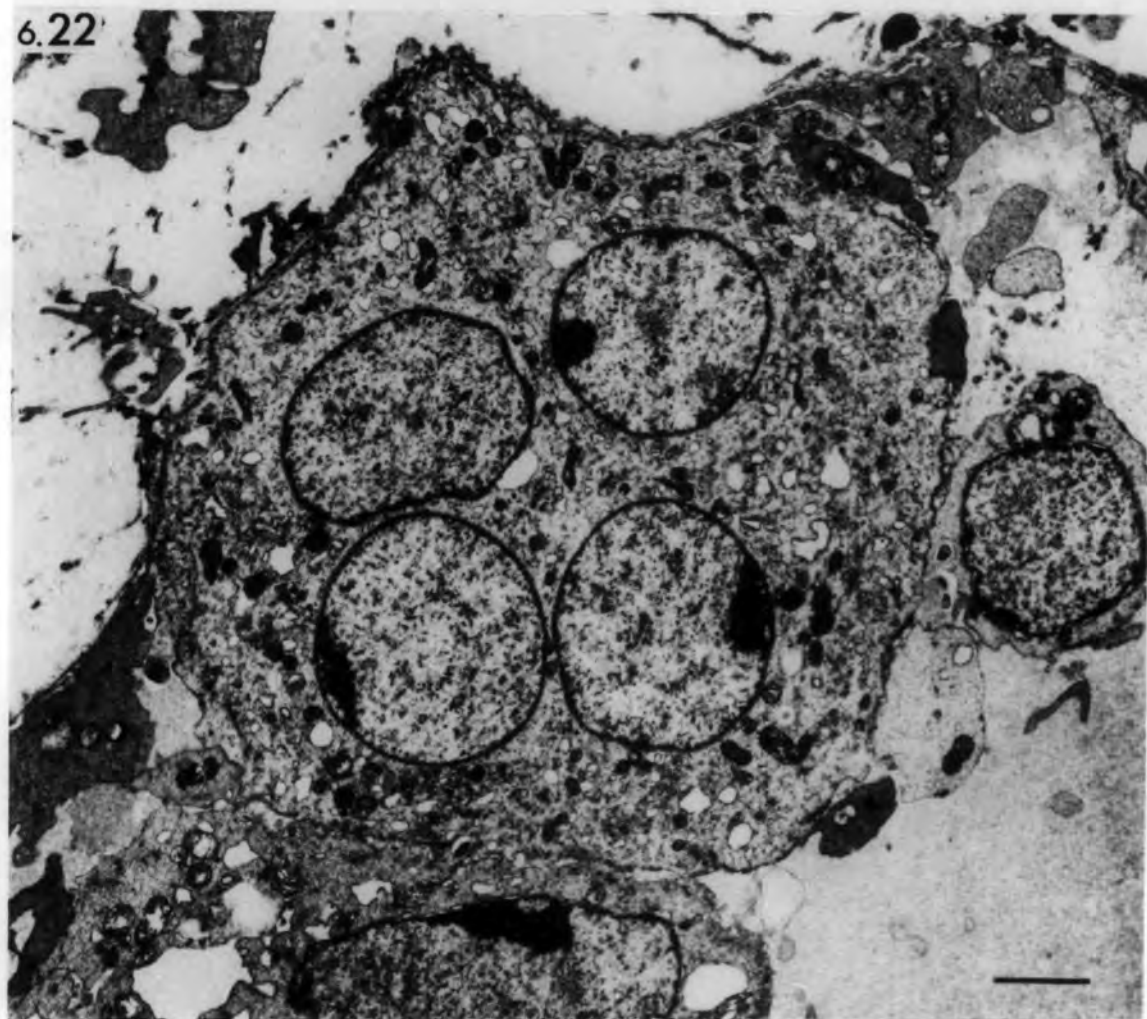


Fig. 6.23 Ischaemic muscle.

Transverse section of regenerating extrafusal muscle fibres 4 days after devascularization. A basal lamina tube contains three myotubes at different stages of regeneration. Two macrophages (mac) are still present. Folds of basal lamina (arrows) enclose necrotic debris. Some of these folds probably develop into the rings shown in Fig. 9.43.

bar = 5 $\mu$ m

6.23

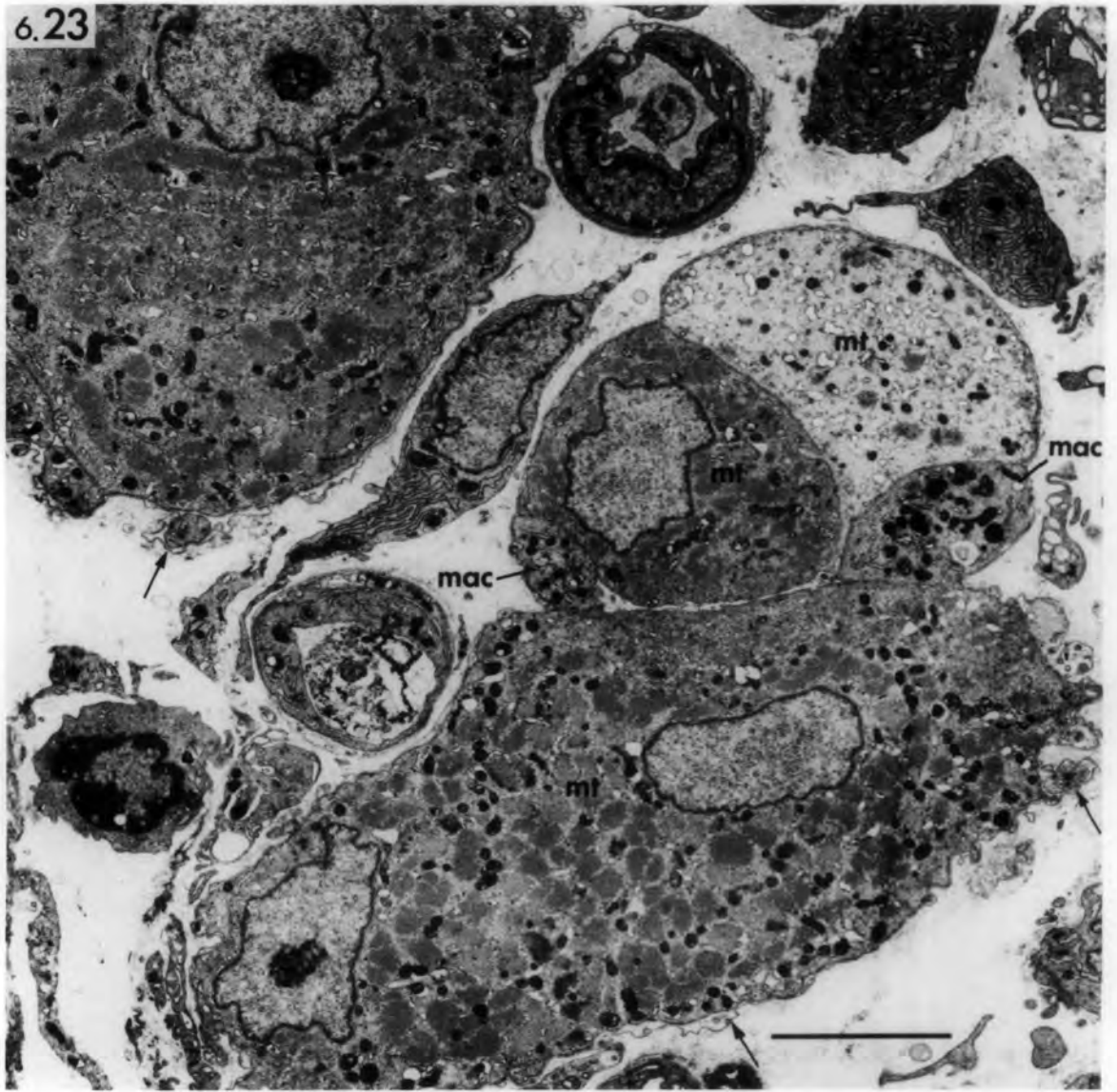

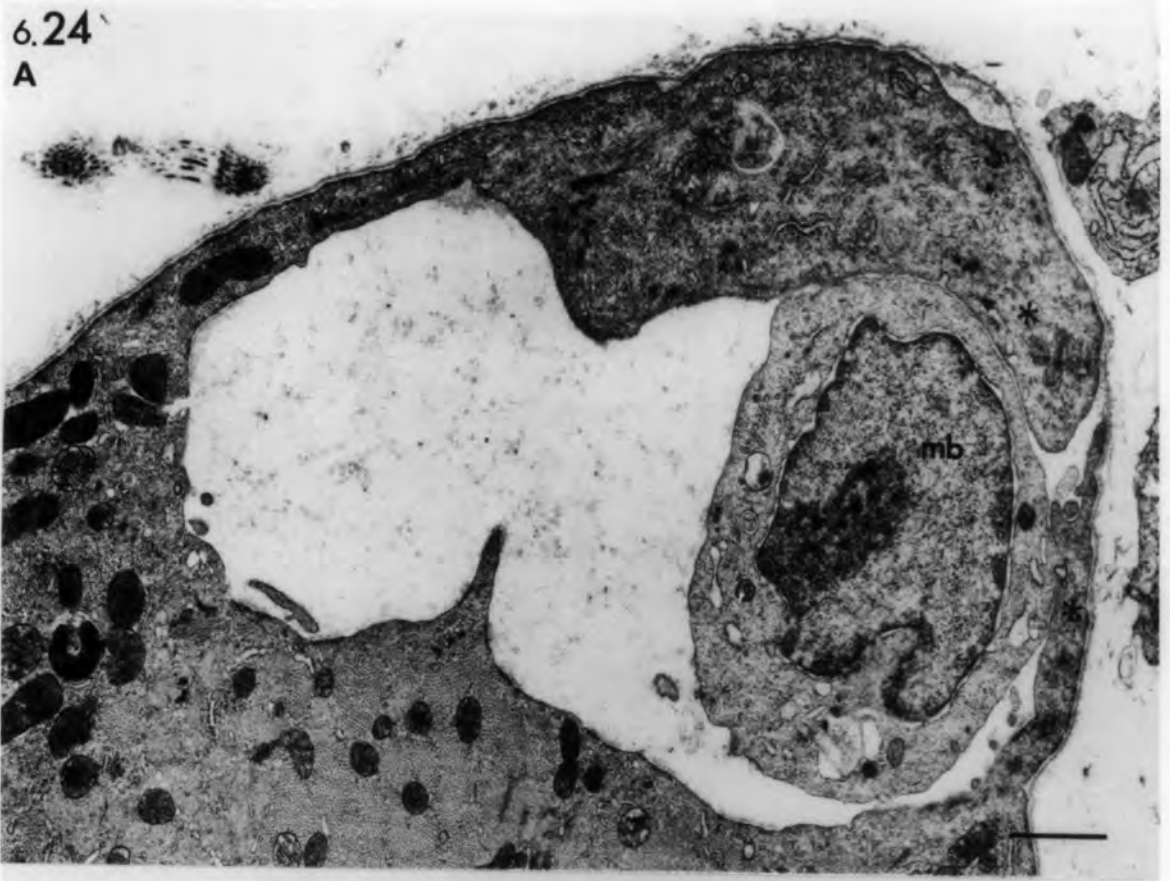Fig. 6.24 Ischaemic muscle: transverse sections of  
partially-damaged extrafusal muscle fibres  
3 days after devascularization.

- A. Continuous regeneration is shown here  
by the sarcoplasmic extensions (asterisks).  
A presumptive myoblast is also present (mb).
- B. A nascent myotube (mt) is present in the  
damaged area.

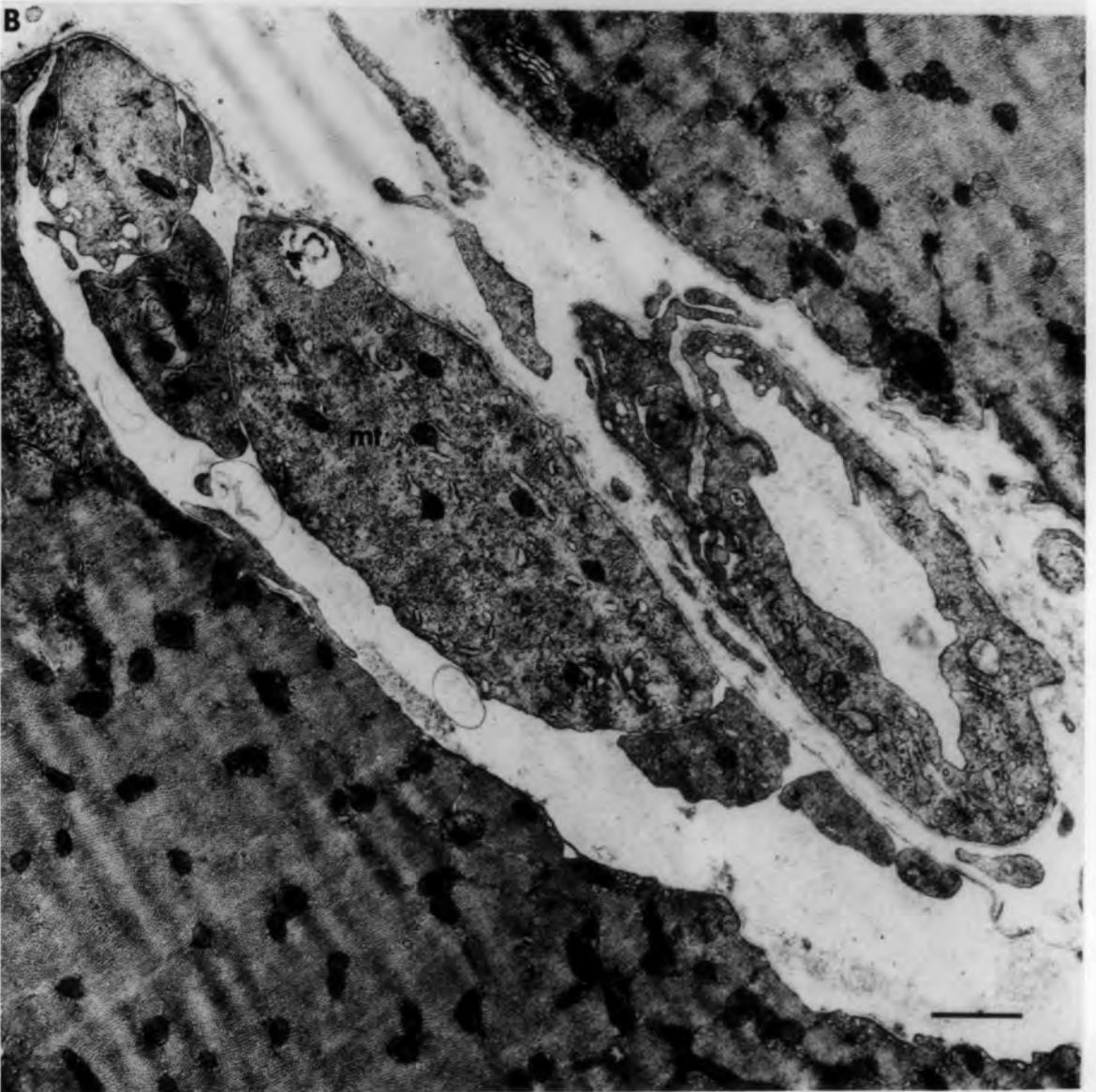
bars = 1 $\mu$ m

6.24'

A



B



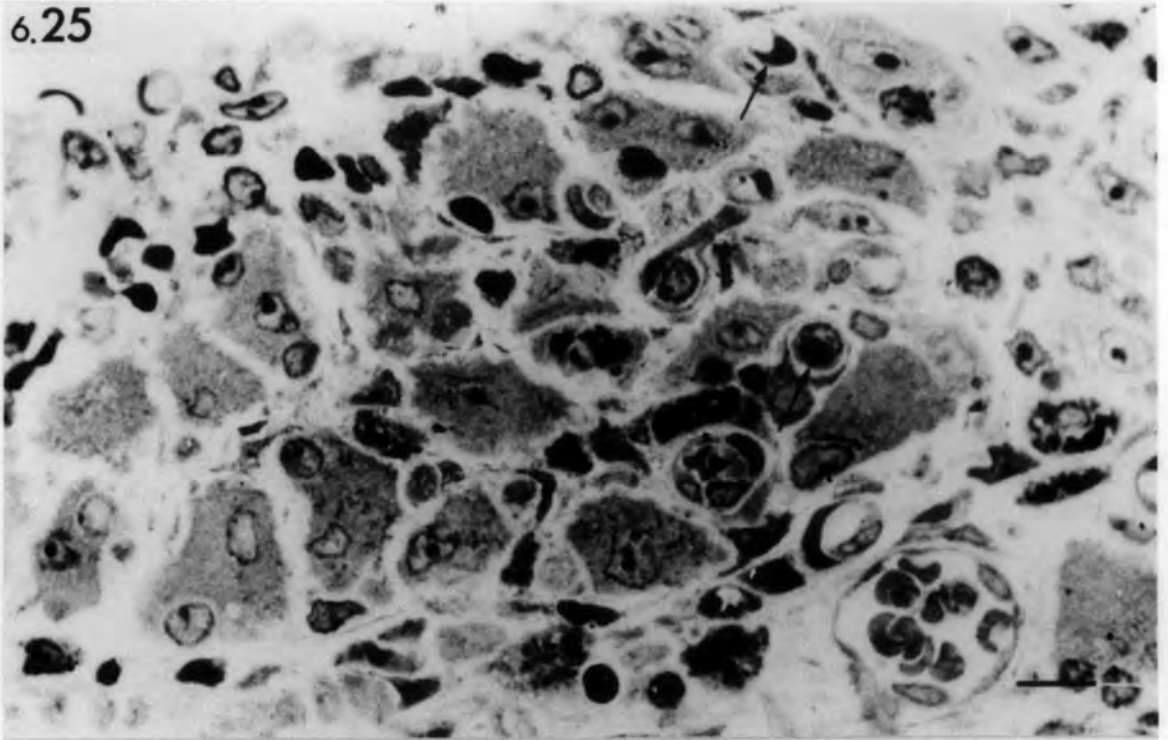
Figs. 6.25, 6.26 Ischaemic muscle: 5 days after  
devascularization.

6.25 Light micrograph of transverse section of irregularly-shaped regenerating extrafusal muscle fibres. Note the presence of many capillaries (arrows).  
1µm section stained with Toluidine blue.

6.26 Electron micrograph of transverse section of regenerating extrafusal muscle fibres showing well-formed myotubes enclosed by folded preserved basal lamina (arrow heads). Small cells in the interstitial space (arrows) resemble myoblasts.

bars = 10µm

6.25



6.26

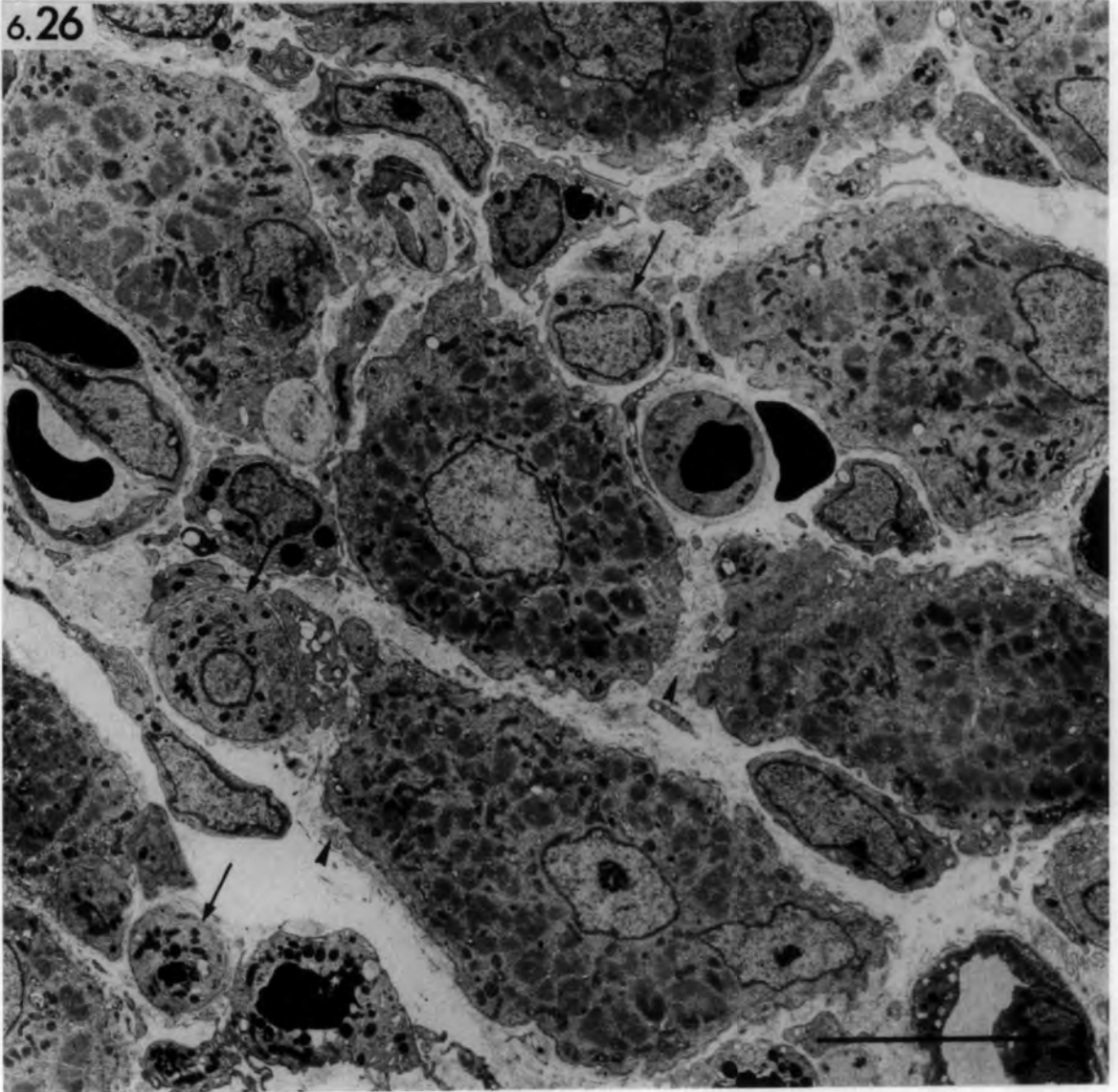


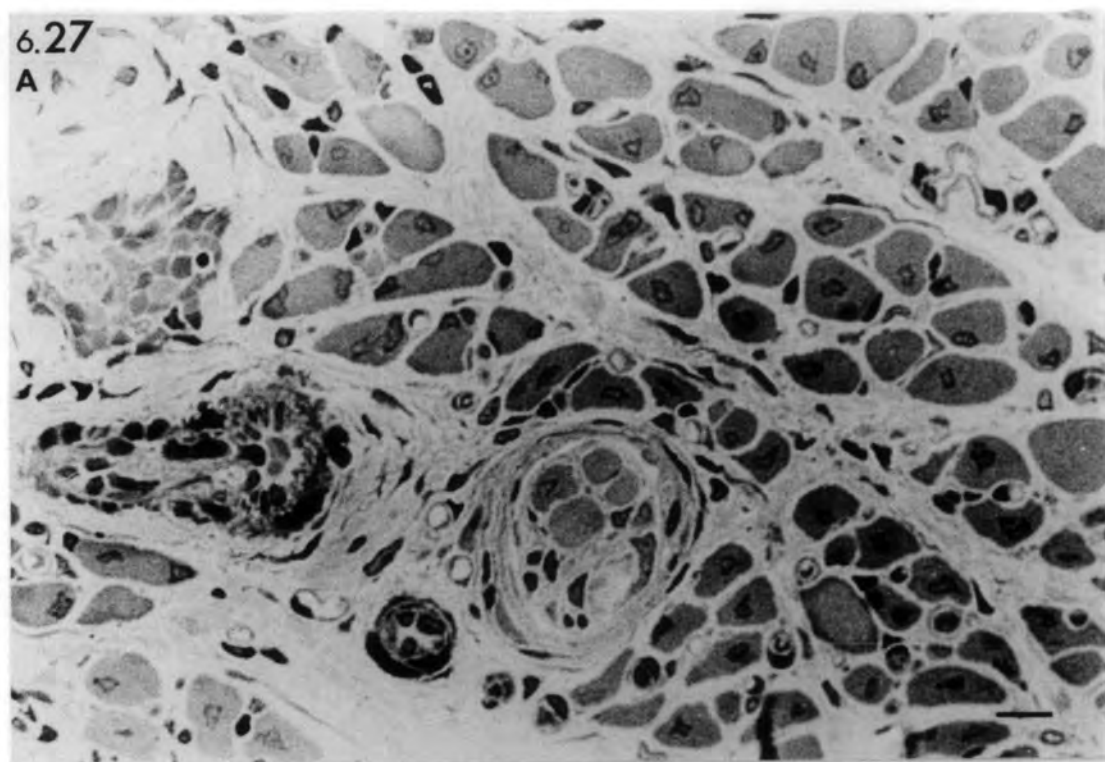
Fig. 6.27A & B Ischaemic muscle: 14 days after  
devascularization.

Light (A) and electron micrographs (B)  
of transverse sections of regenerating  
extrafusal muscle fibres. Note the  
irregularly-shaped, well-formed muscle  
fibres and the central nuclei.

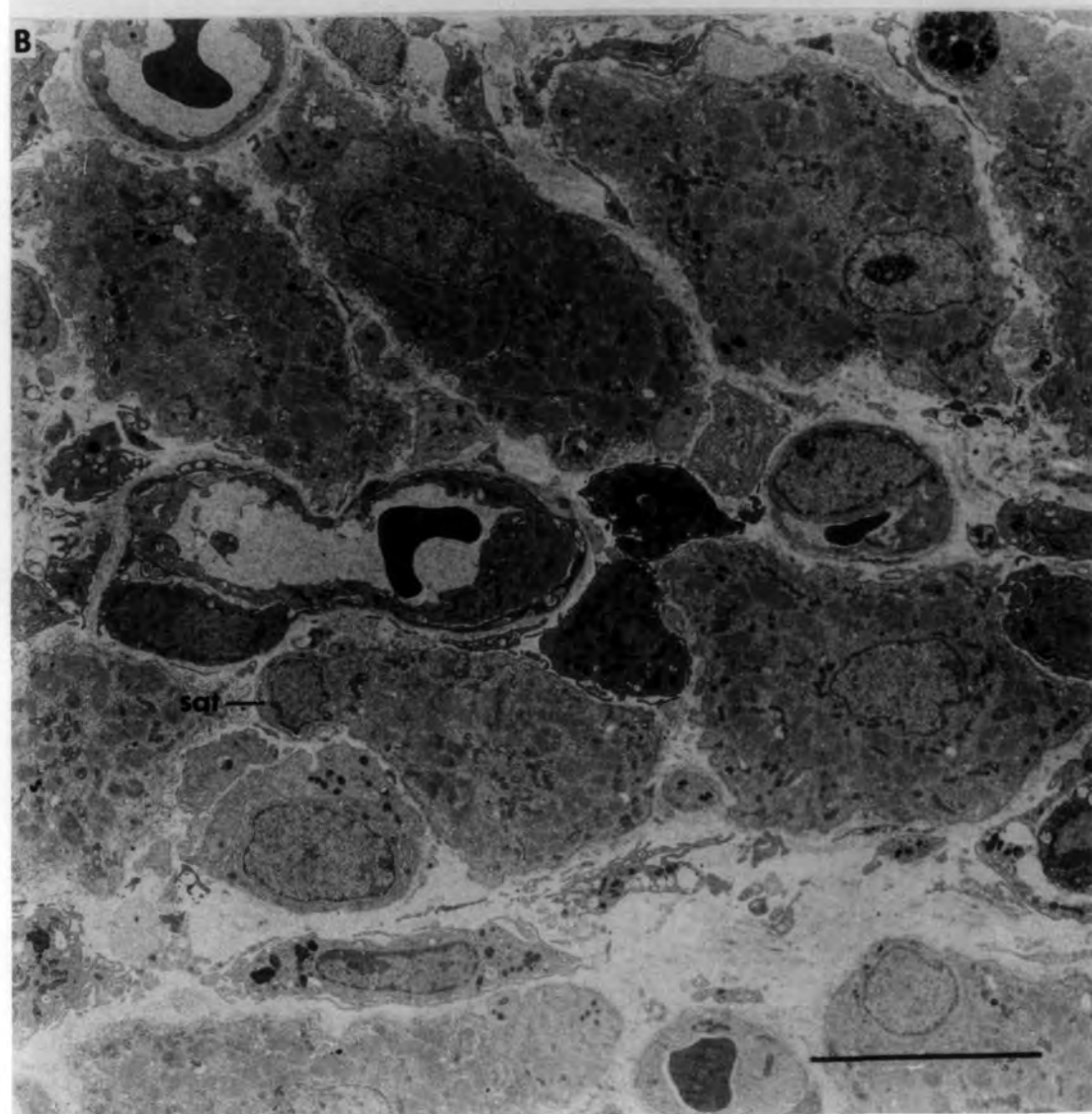
A. 1 $\mu$ m section stained with Toluidine blue.

bars = 10 $\mu$ m

6.27  
A



B

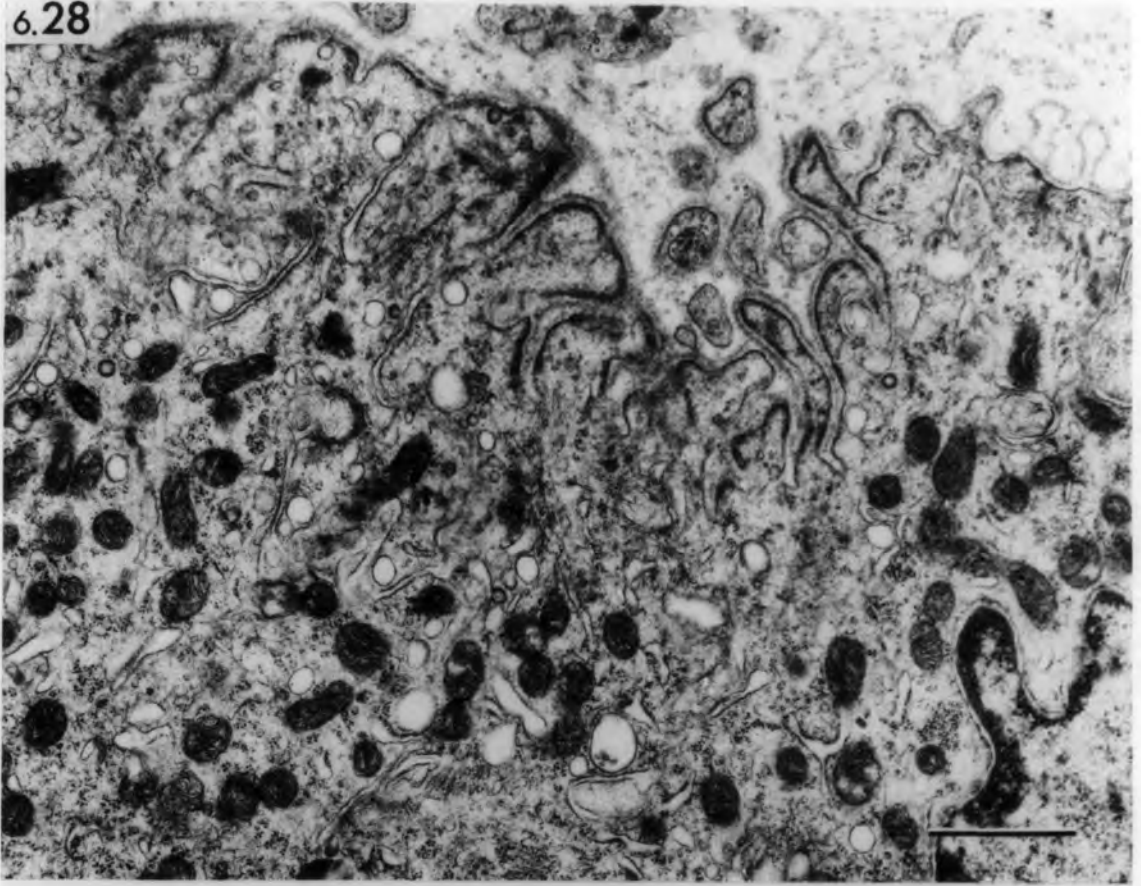


Figs. 6.28, 6.29 Ischaemic muscle

- 6.28 Transverse section of an  
extrafusal muscle fibre 5  
days after devascularization  
showing regenerating sole-  
plate in the absence of axon  
terminals. The post-junctional  
folds and sole-plate are well  
developed.
- 6.29 Transverse section of an  
intramuscular nerve trunk 5  
days after devascularization  
containing collagen fibrils (cf)  
and degenerating Schwann cells  
(Sc). The perineurial epithelium  
is well preserved.

bars = 1  $\mu$ m

6.28



6.29

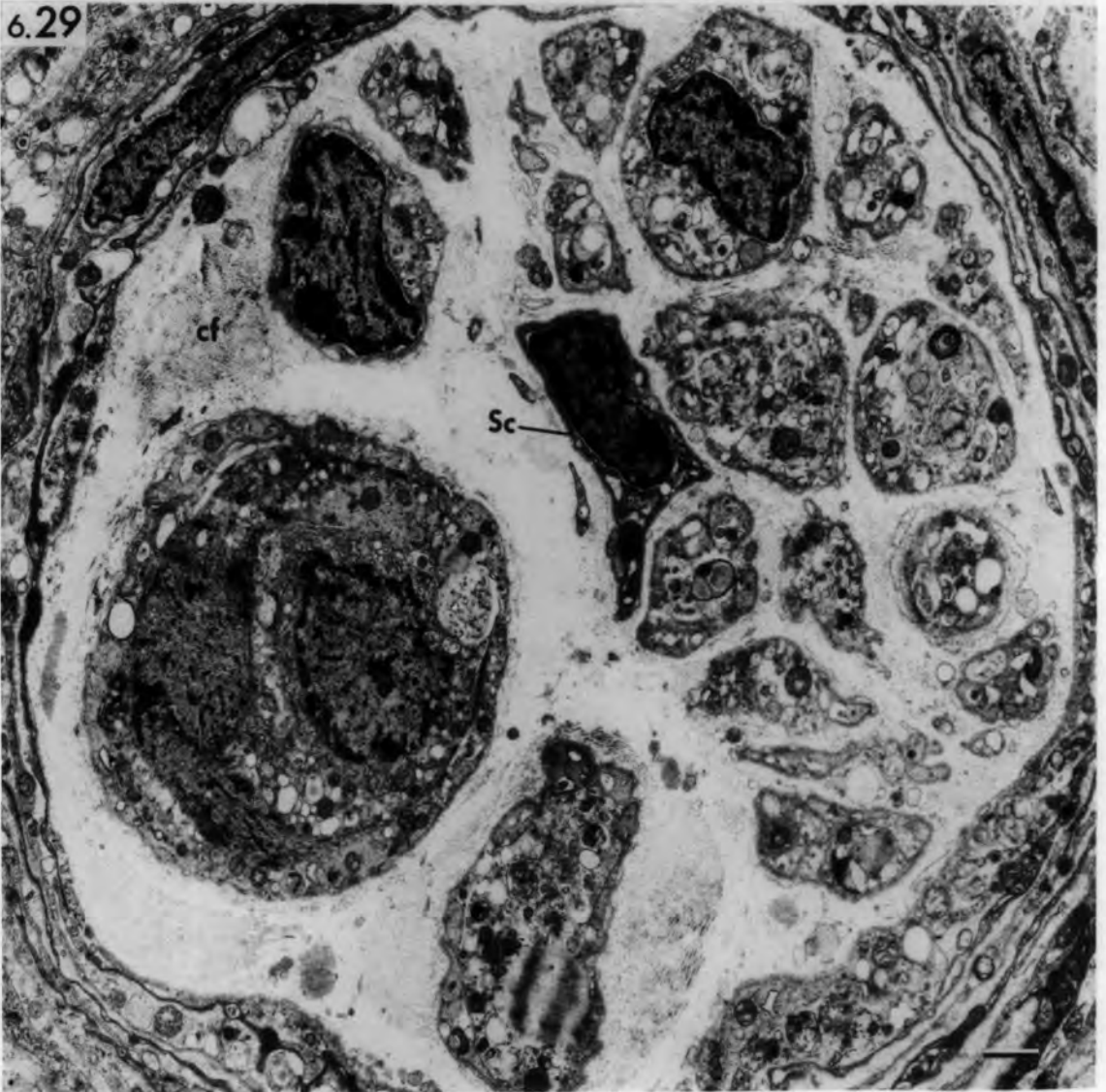


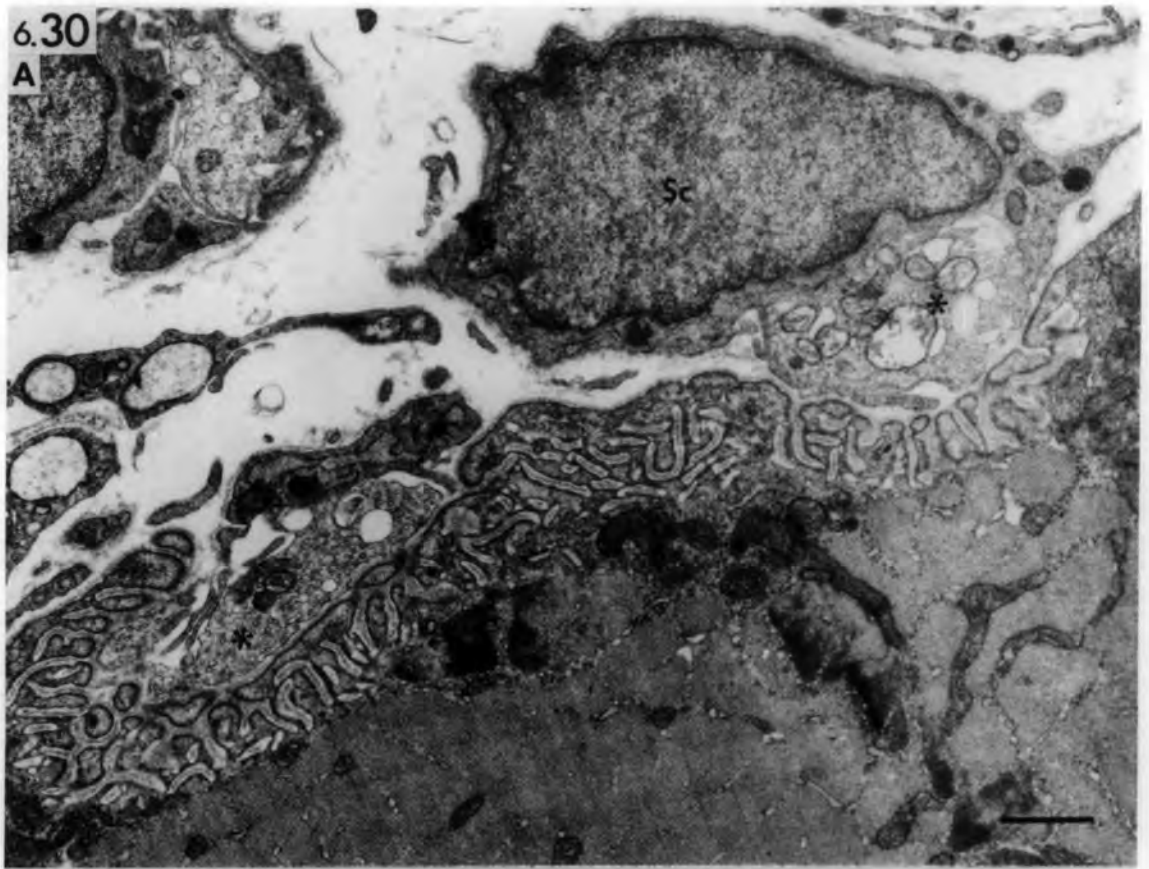Fig. 6.30 Ischaemic muscle: transverse sections of  
regenerated extrafusal muscle fibres 21  
days after devascularization showing  
reinnervating motor axon terminals.

- A. Two small axon terminals (asterisks) reinnervating a well-developed post-junctional complex.
  
- B. The fine structure of a reinnervating motor nerve terminal. Note the wide gap in some areas separating the terminal and muscle fibre. Arrow points to myelin figure.

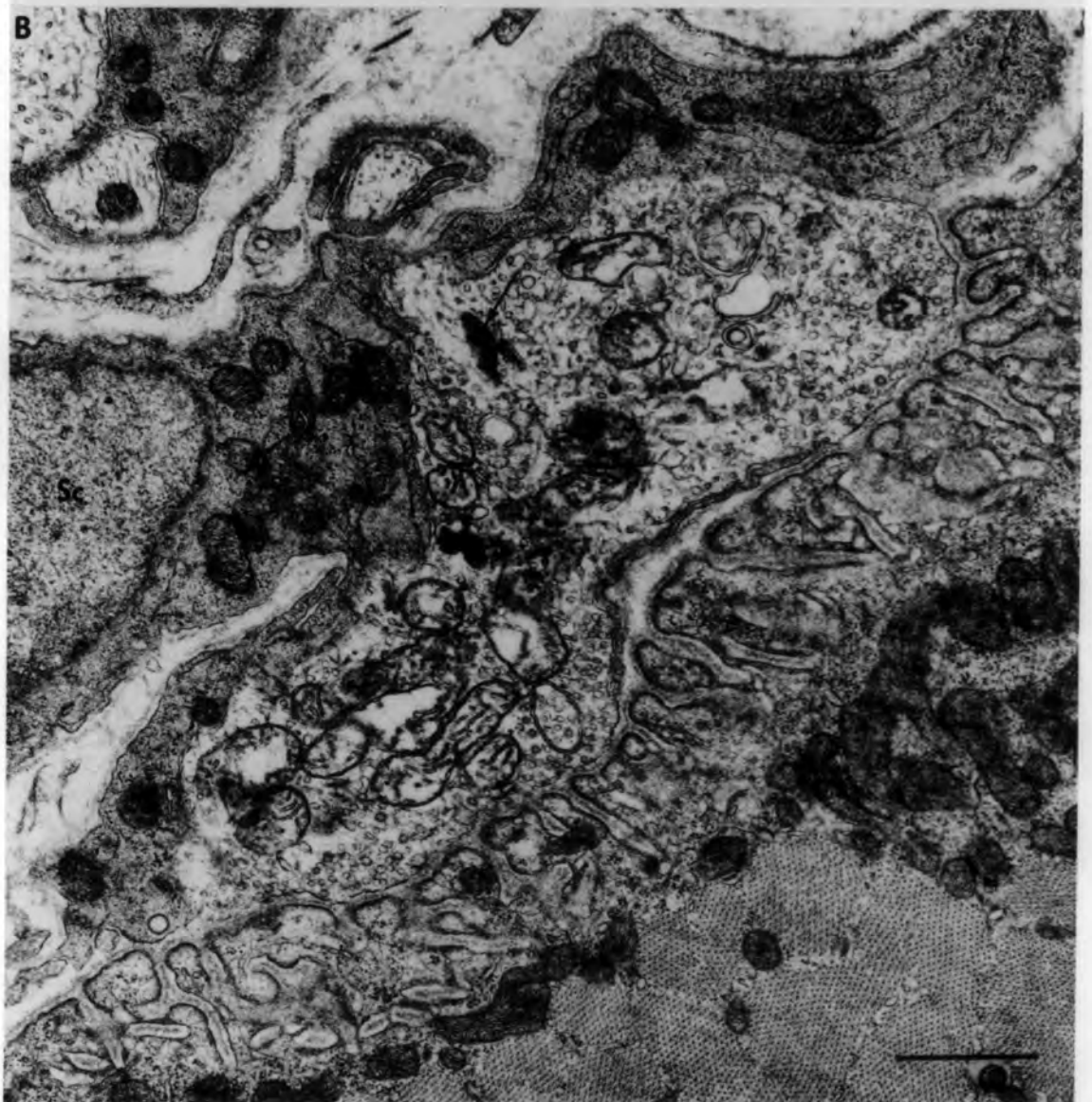
bars = 1  $\mu$ m

6.30

A



B



Figs. 6.31, 6.32 Ischaemic muscle: 28 days after  
devascularization.

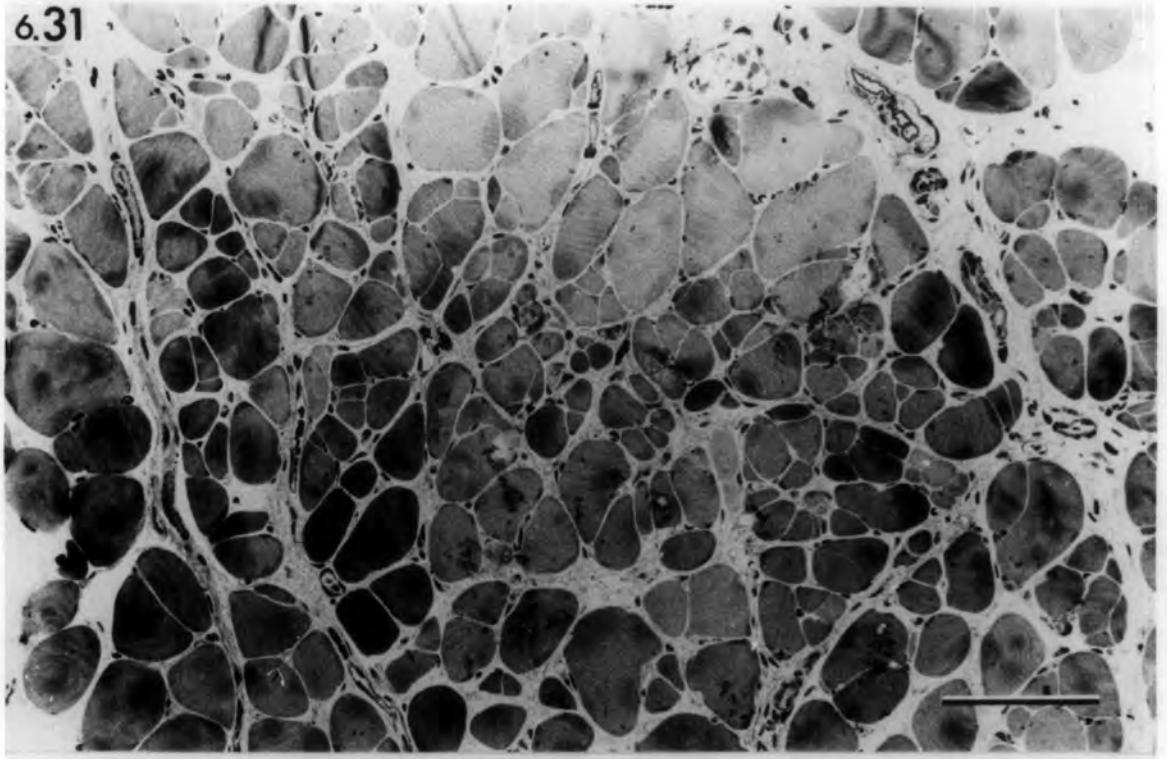
6.31 Transverse section of  
regenerated extrafusal  
muscle fibres. Many fibres  
have attained a normal  
diameter whilst others are  
small and appear as fragments  
of muscle fibres.  $1\mu\text{m}$  section  
stained with Toluidine blue.

bar =  $100\mu\text{m}$

6.32 Transverse section of  
regenerated extrafusal muscle  
fibres showing normal well-  
established motor ending.

bar =  $1\mu\text{m}$

6.31



6.32

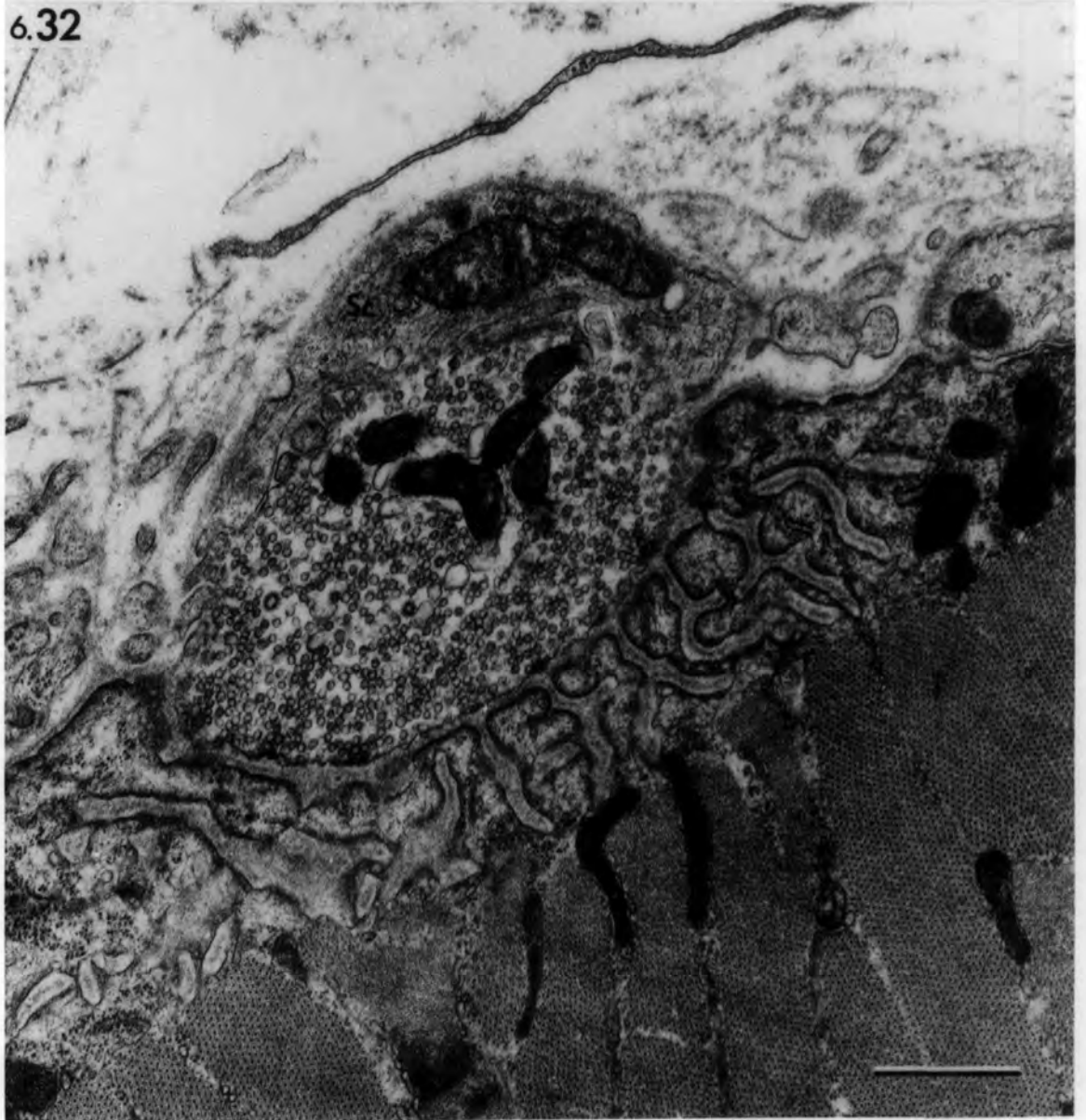

Fig. 6.33 Ischaemic muscle: 182 days after  
devascularization.

- A. Transverse section of an abnormal  
extrafusal muscle fibre undergoing  
fragmentation and cellular invasion.
  
- B. Higher power of the invaginated area.

bars = 1 $\mu$ m

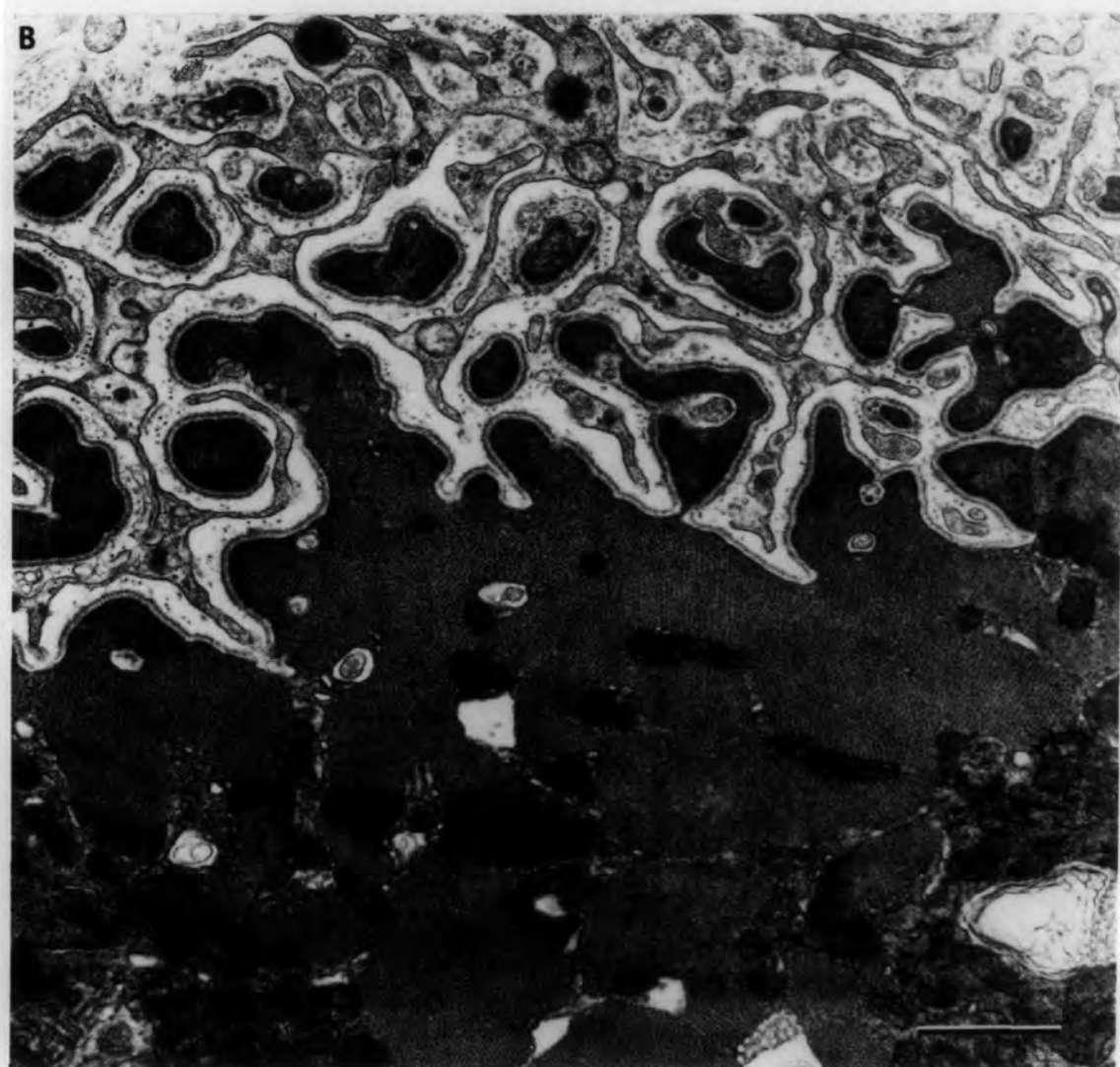
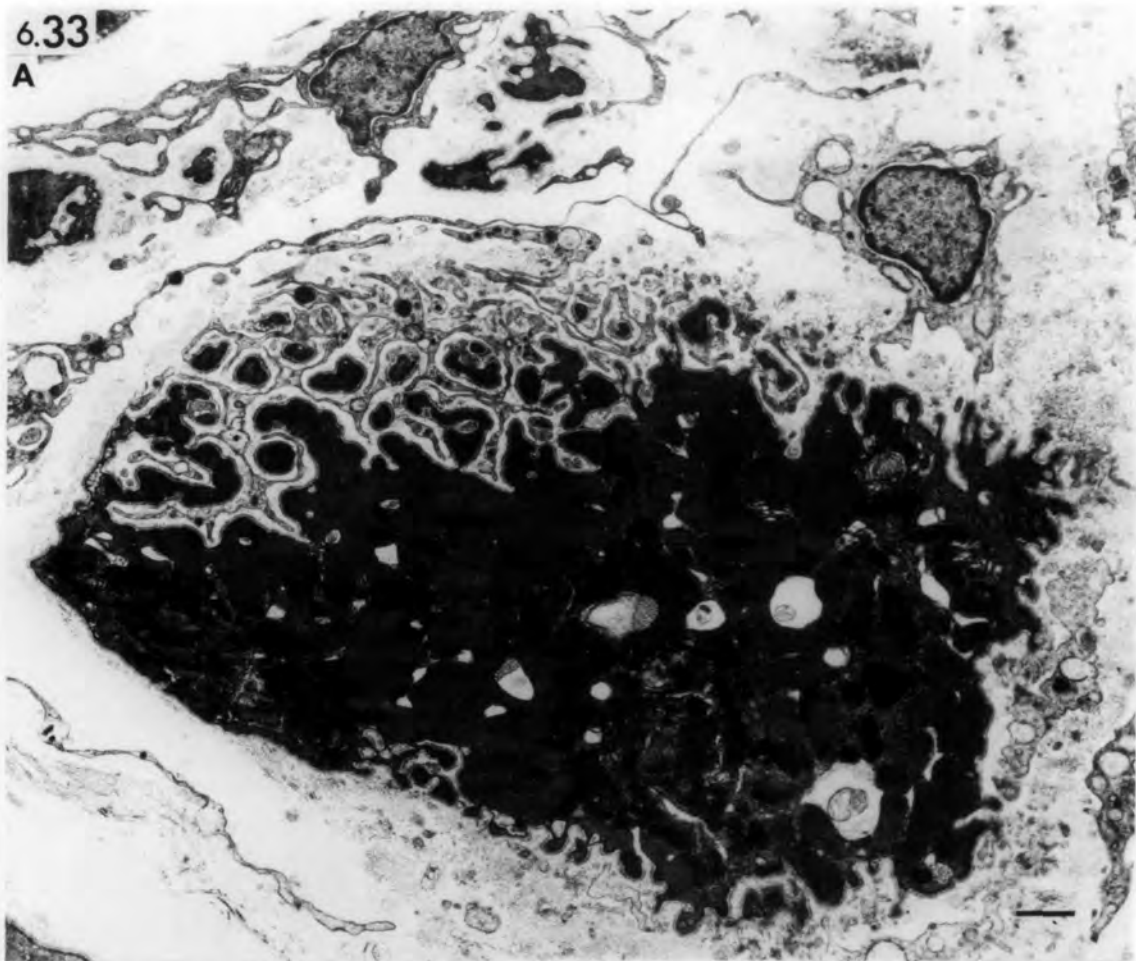
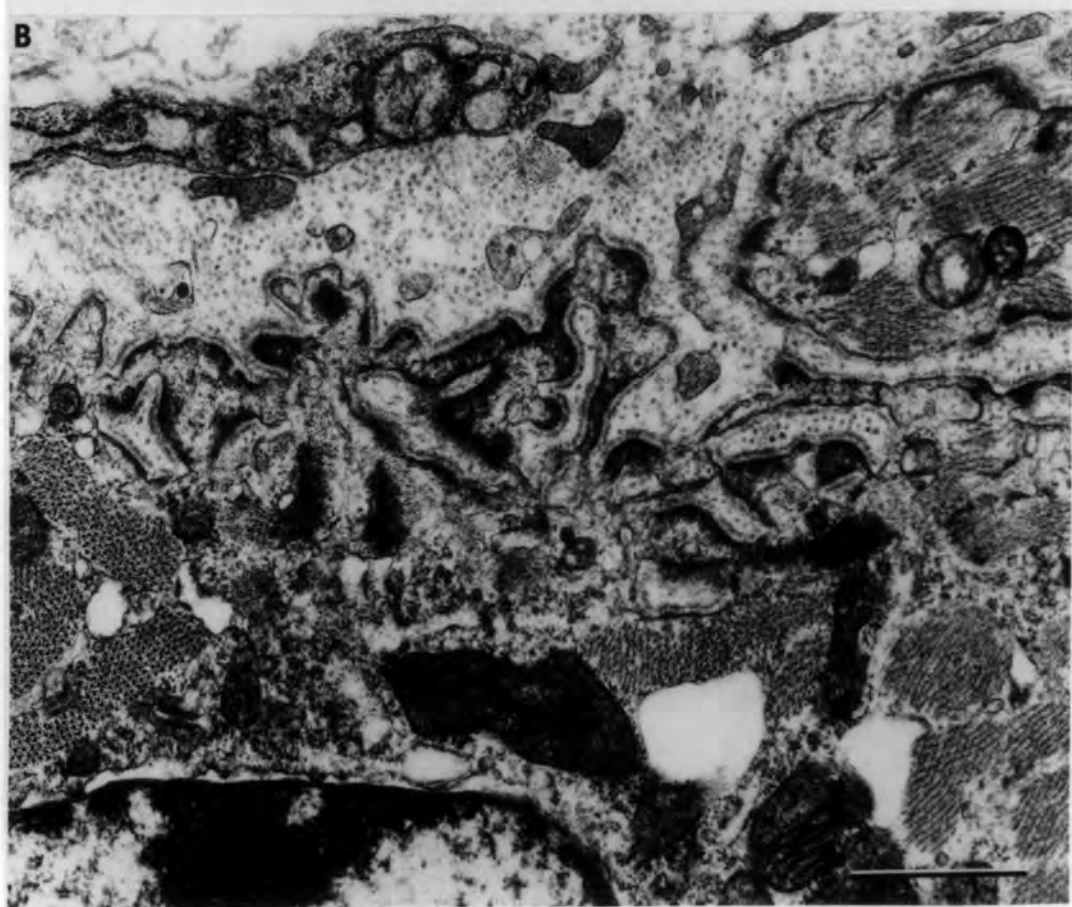
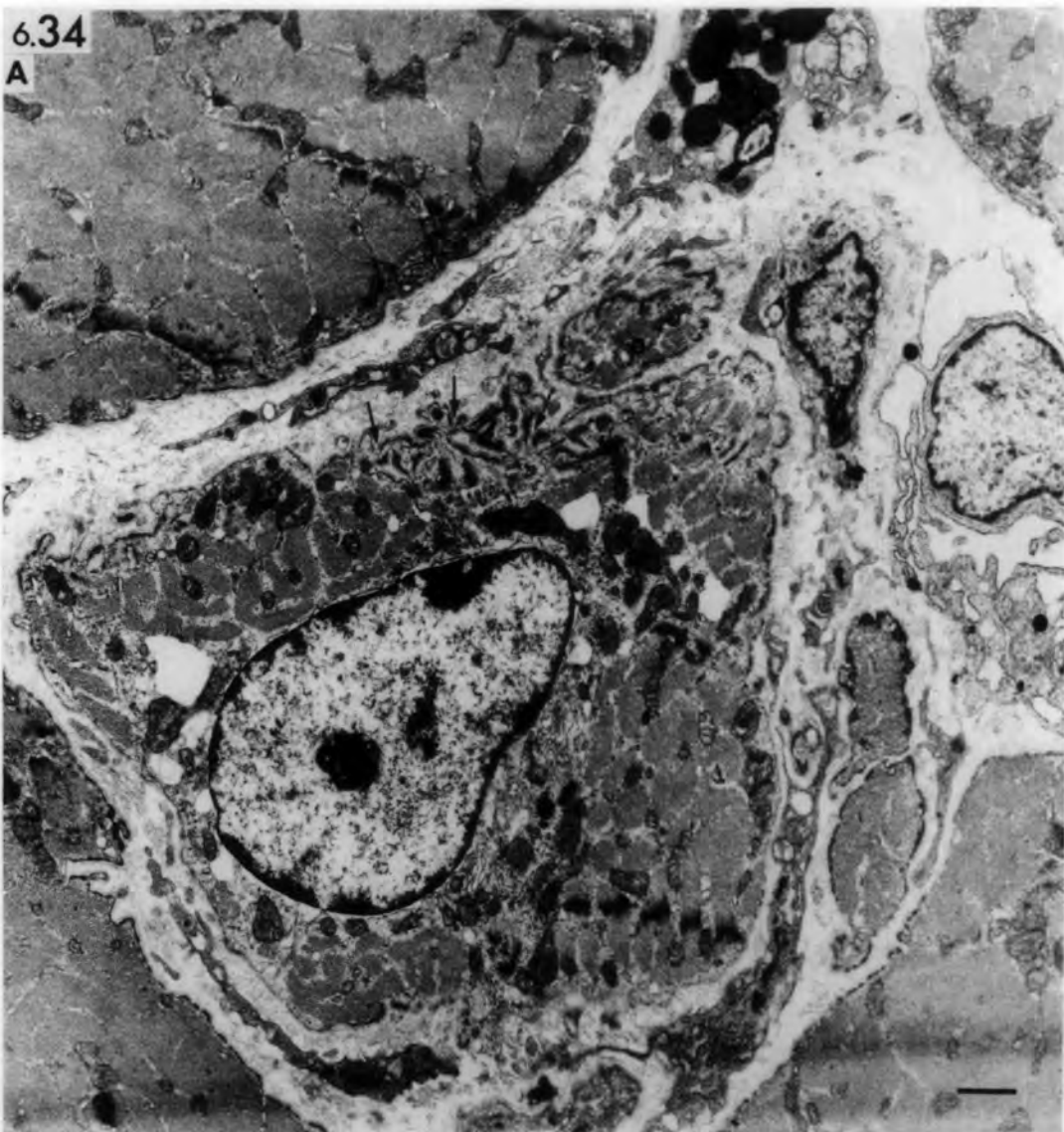
Fig. 6.34 Ischaemic muscle: 56 days after  
devascularization.

Transverse section of abnormal extrafusal  
muscle fibre undergoing denervation  
atrophy.

- A. Invaginations of the sarcolemma (arrows)  
resemble regenerated postjunctional  
folds.
  
- B. High power of sarcolemmal invaginations.

bars = 1µm



Figs. 6.35, 6.36 Ischaemic muscle: transverse sections  
of atrophied extrafusal muscle fibres  
182 days after devascularization.

6.35 The redundant basal lamina (arrows) is folded and invaded by an endomysial cell (en). A new basal lamina (arrow heads) is formed in places where the muscle fibre is widely separated from its old basal lamina.

6.36 Helical complexes (hc) and tubular masses (arrow heads) are present.

bars = 1 $\mu$ m

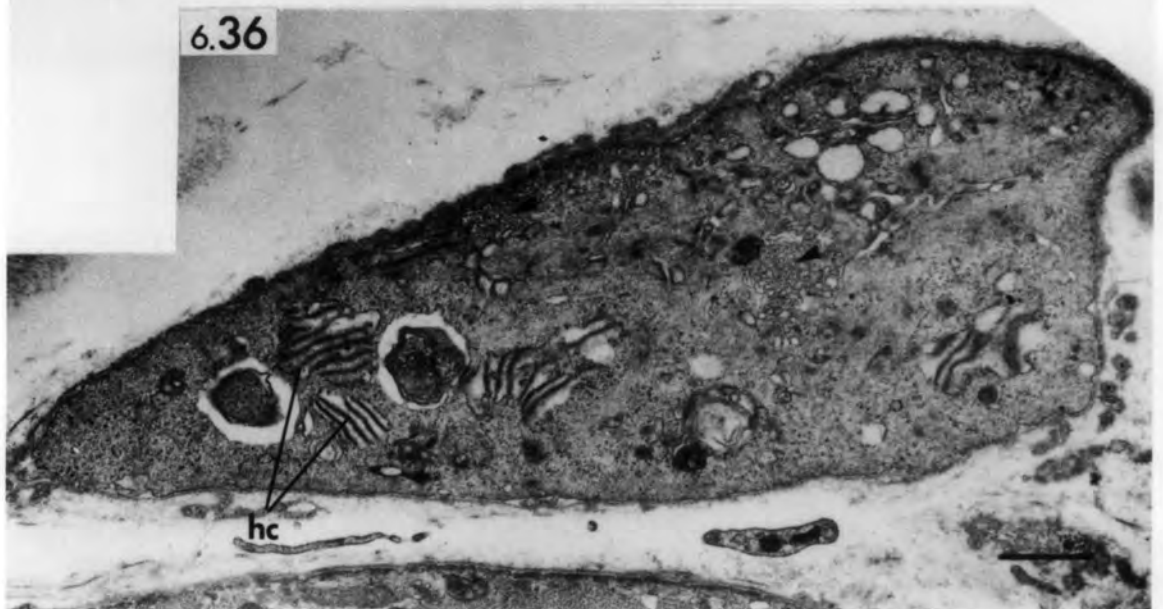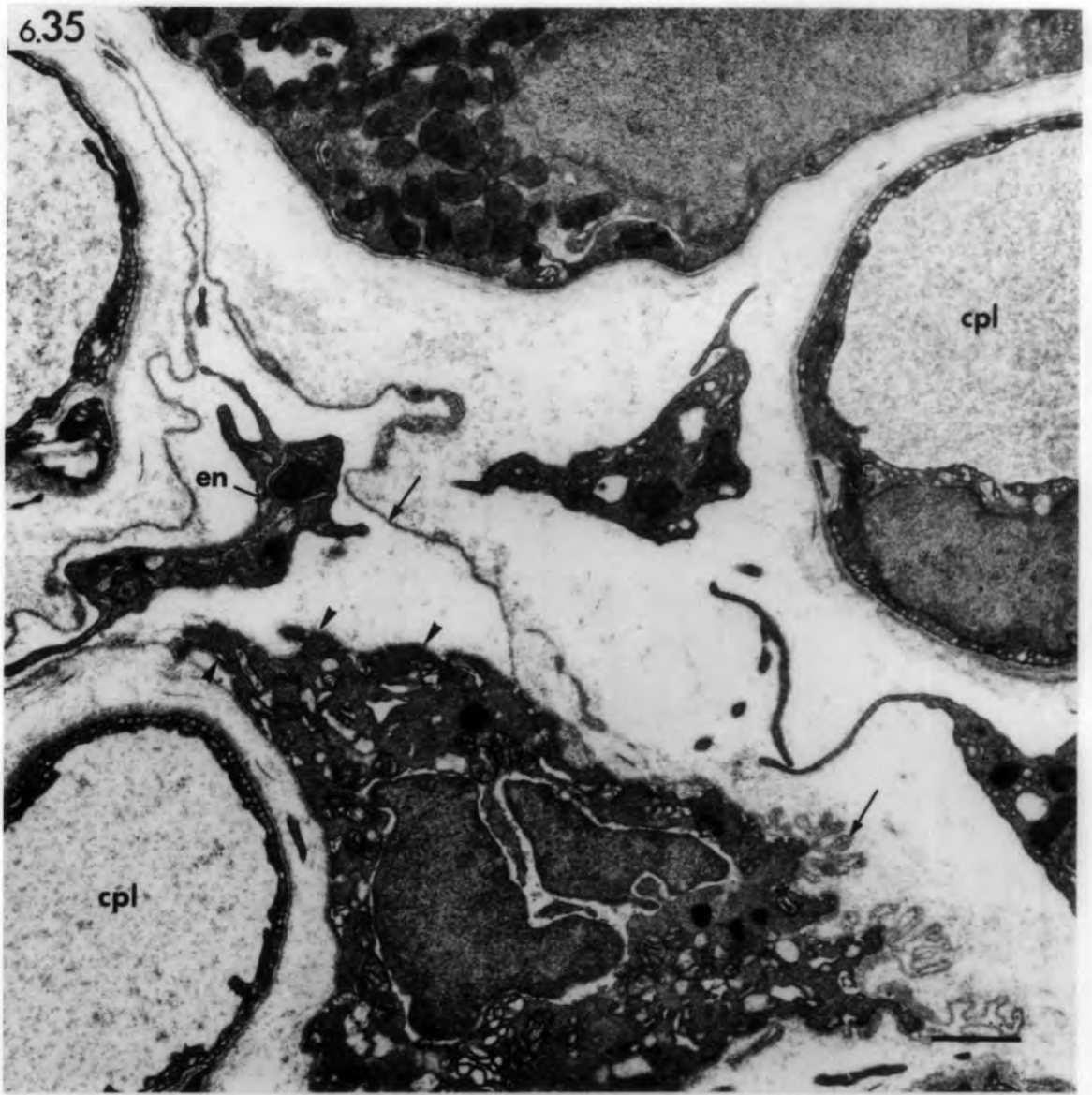


Fig. 6.37 Ischaemic muscle: transverse section of  
an atrophied extrafusal muscle fibre 182  
days after devascularization.

Various stages of sarcolemmal invagination  
and cellular invasion.

A. Low-power micrograph shows peripheral and  
deep sarcolemmal invaginations (arrows).

B. High-power micrograph of deep invagination  
in Fig. A. Arrow heads point to Z-line  
fragments.

bars = 1 $\mu$ m

6.37  
A

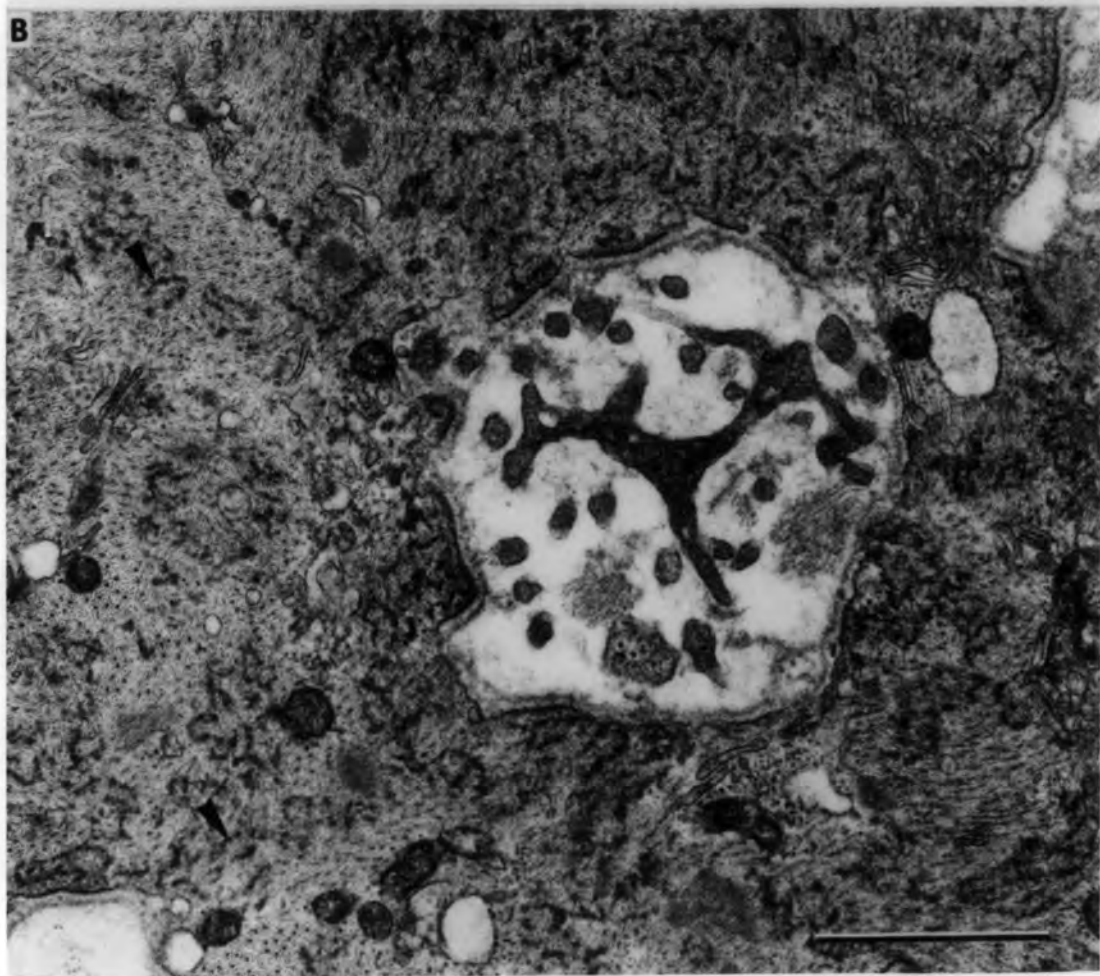
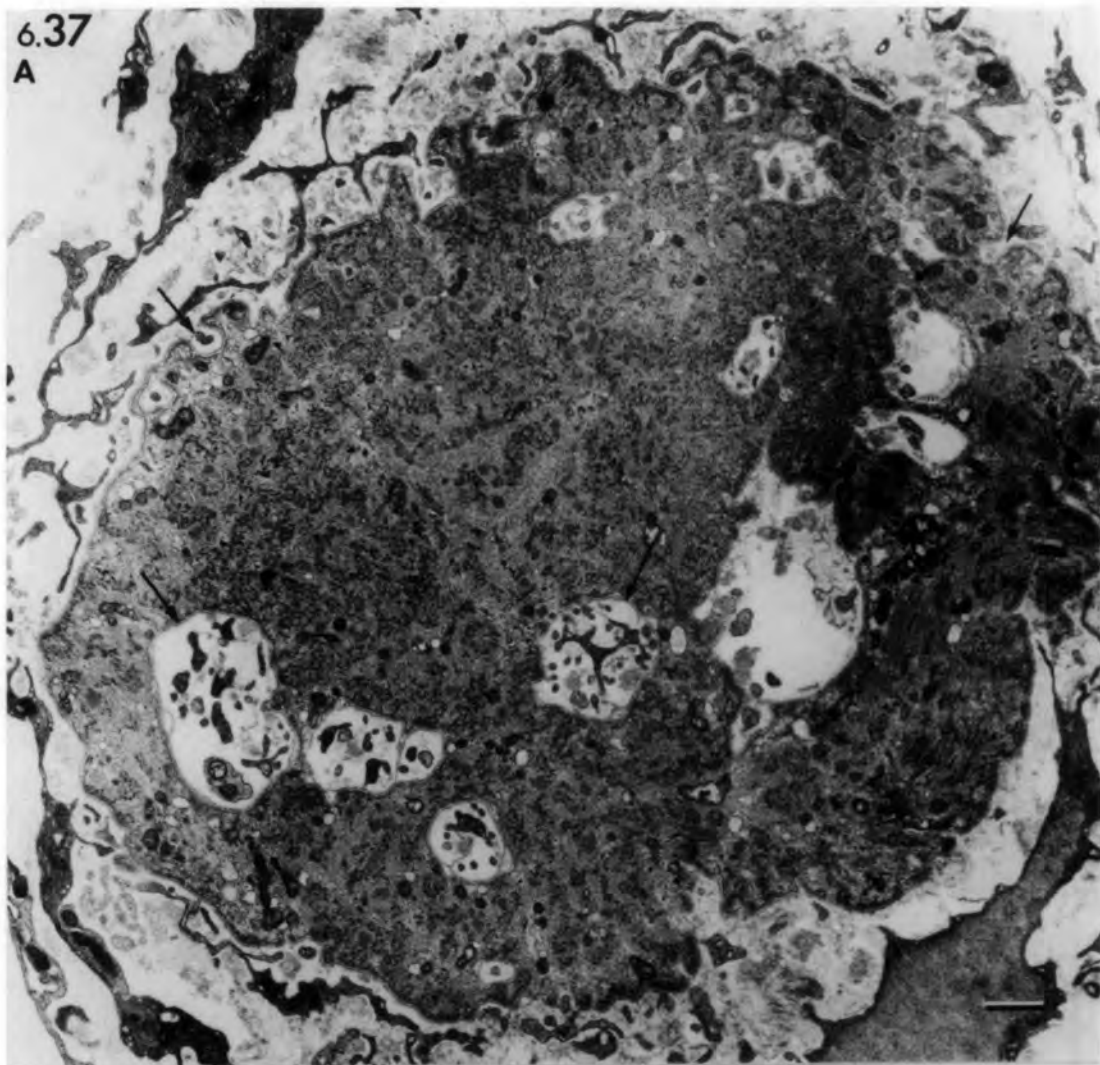


Fig. 7.1 Schematic diagrams of transverse sections of the equatorial region of muscle spindles from rat soleus at varying periods following devascularization illustrating the effects of ischaemia.

- A. Normal spindle: the bag<sub>2</sub> fibre (b<sub>2</sub>) is thicker than the bag<sub>1</sub> fibre (b<sub>1</sub>) and contains more equatorial nuclei (n). Sensory nerve terminals (snt) are distributed to both bag and chain (c) fibres.
  
- B. 0-3 days: The sarcoplasm and sarcolemma of all intrafusal fibres have degenerated, and the debris is removed by phagocytes (ph). The preserved basal lamina tubes (bl) contain satellite cells (sat) and presumptive myoblasts (mb). Sensory nerve terminals and the spindle's nerve axons (ax) have degenerated. The capsule (cap) is packed with erythrocytes (er).
  
- C. 3-5 days: Regeneration proceeds more rapidly in the original bag fibres, which contain myotubes (mt) and myoblasts, than in the original chain fibres, which contain myoblasts only. Phagocytes are no longer seen in the intrafusal fibres.
  
- D. 5-21 days: The regenerated original intrafusal fibres have matured into muscle fibres with central nuclei, in the absence of sensory innervation. Bags and chains of nuclei are absent. Additional fibres are located within the axial bundle (one arrowed) and between the capsule layers (arrow). Capillaries (cpl) have increased in number.
  
- E. 21-28 days: Sensory nerve terminals (snt) of reinnervating myelinated axons (ax) are mostly distributed to the thin original chain fibres, which contain central nuclei. The thick regenerated fibres receive few terminals and lack equatorial nuclei (group 3 regenerated spindle: see Fig. 7.12).

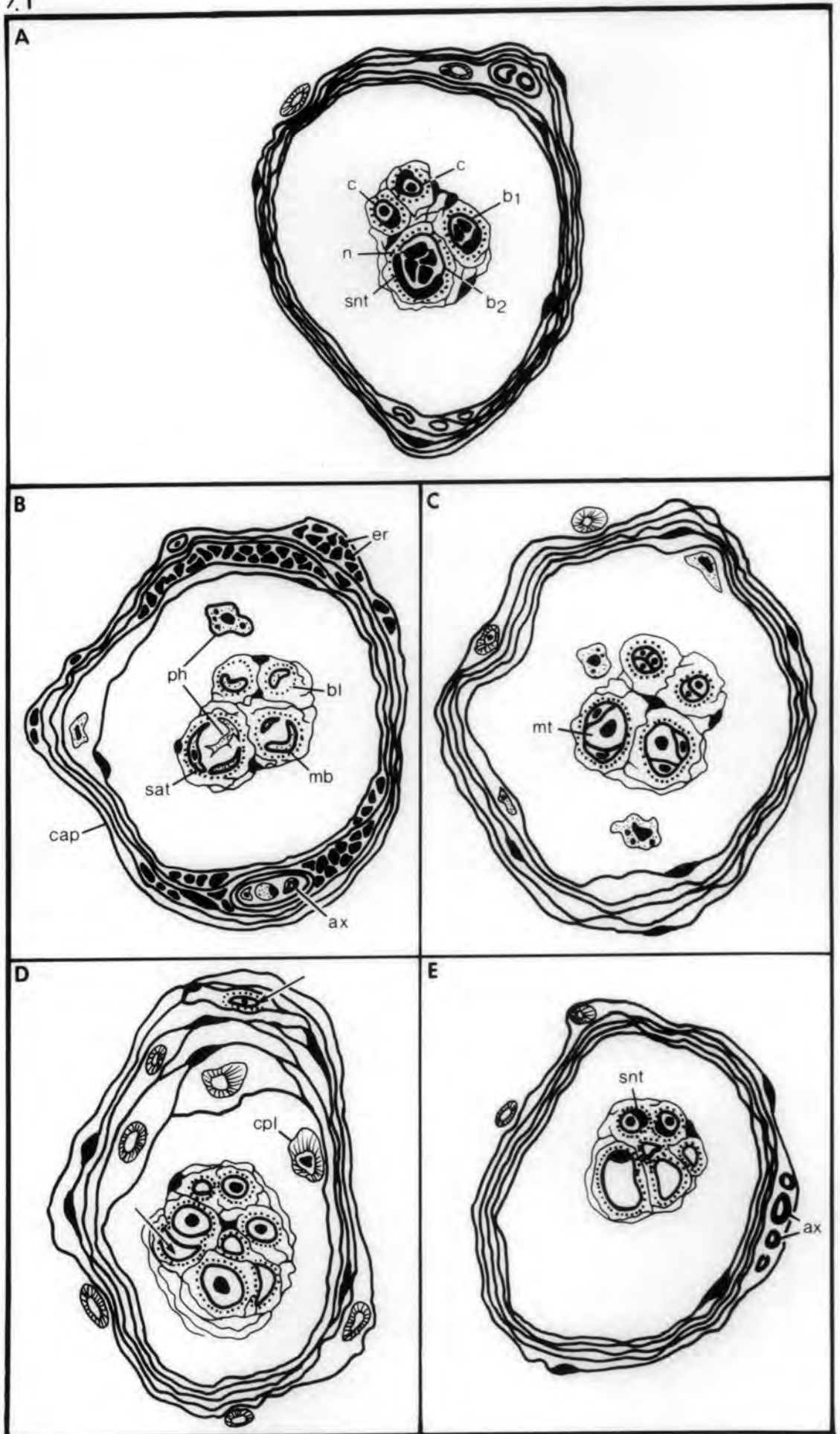


Fig. 7.2 Ischaemic muscle spindle

Transverse section through the equatorial region of a muscle spindle 30 minutes after devascularization. The spindle appears normal. Note the collapse of the inner layer of the capsule (arrow).  
1 $\mu$ m section stained with toluidine blue.

bar = 10 $\mu$ m

7.2

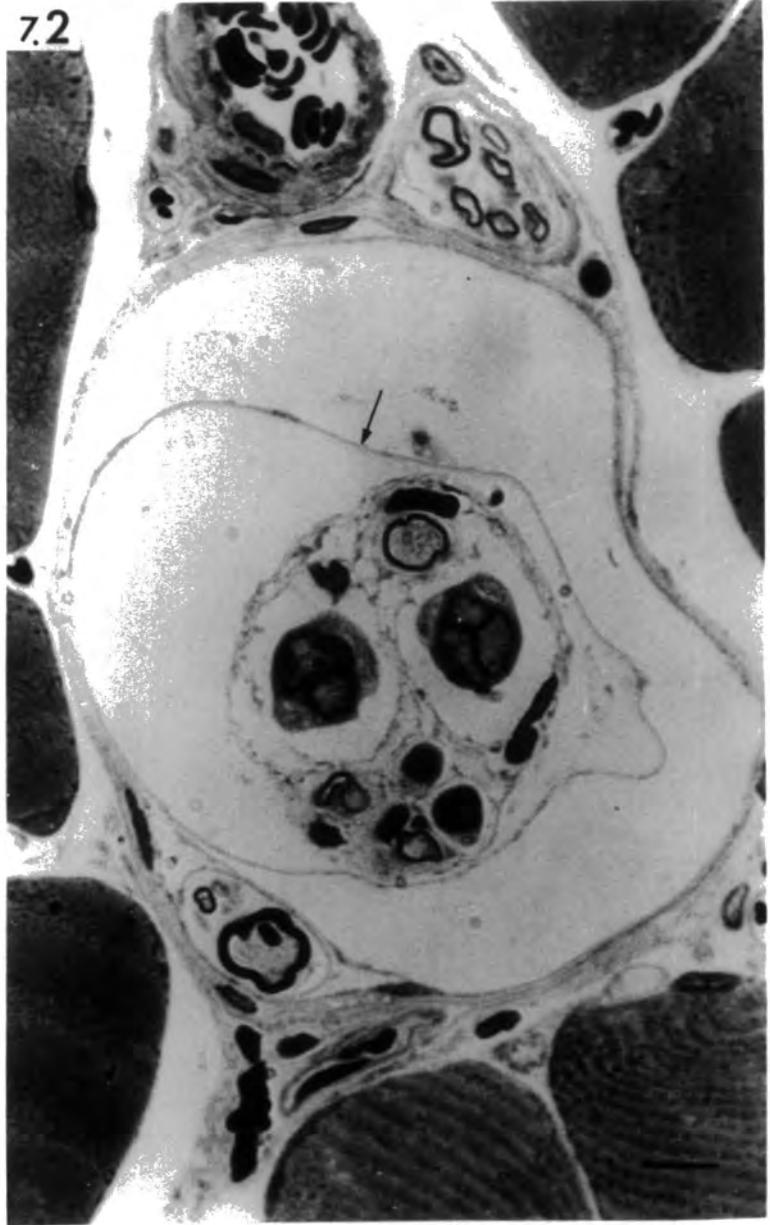


Fig. 7.3 Ischaemic muscle spindle

Transverse section through the equator of a muscle spindle 3 hours after devascularization. The intrafusal fibres have degenerated and only their basal-lamina tubes (arrows) are left.

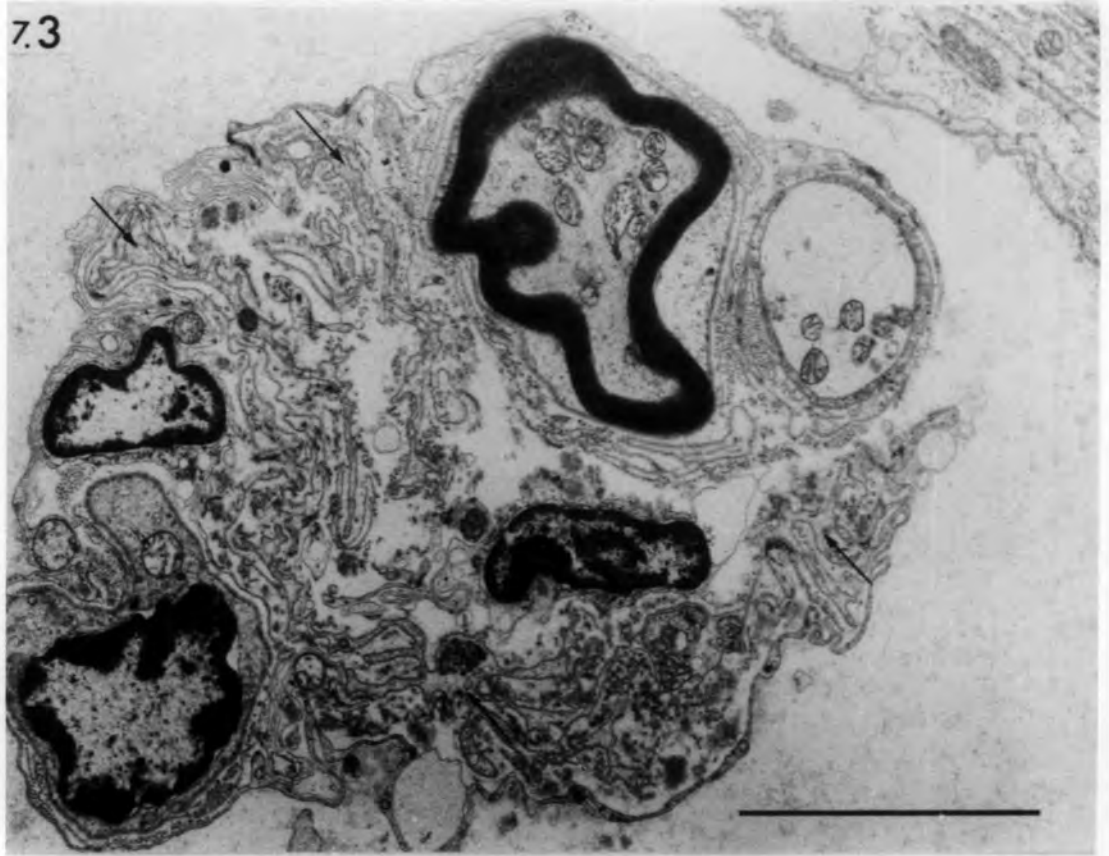
Fig. 7.4 Ischaemic muscle spindle

Transverse section through the juxta-equatorial region of a muscle spindle 6 hours after devascularization.

Hyaline degeneration is evident in the two thick (bag) fibres, while the thin (chain) fibres are less affected.

bars = 5 $\mu$ m

7.3



7.4

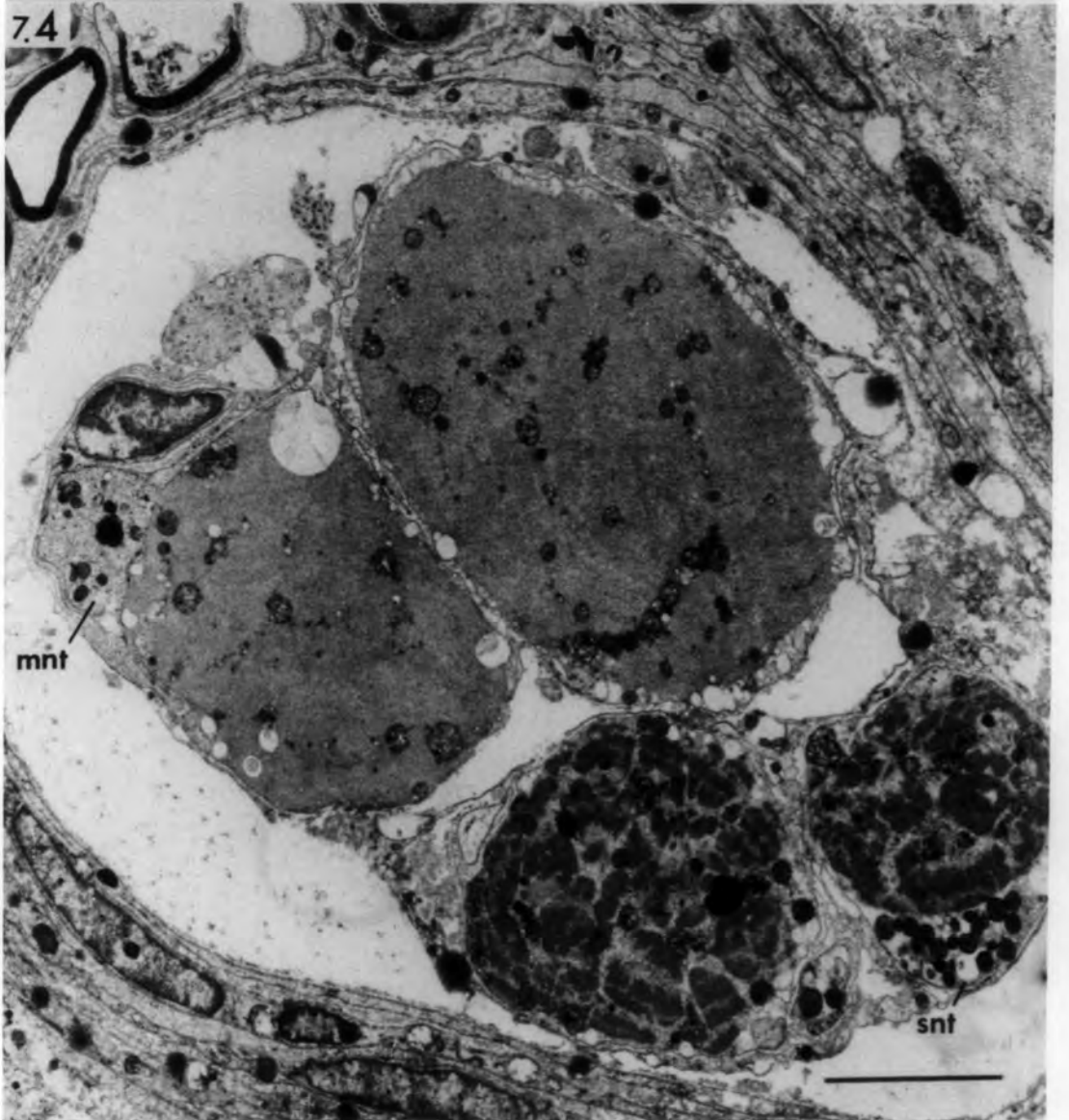

Fig. 7.5 Ischaemic muscle spindle

Transverse section through the equator  
of a muscle spindle 2 days after  
devascularization. Note the faintly-  
stained degenerating intrafusal fibres  
within the periaxial space and the  
capsule packed with erythrocytes (arrows).  
1µm section stained with Toluidine blue.

bar = 10µm

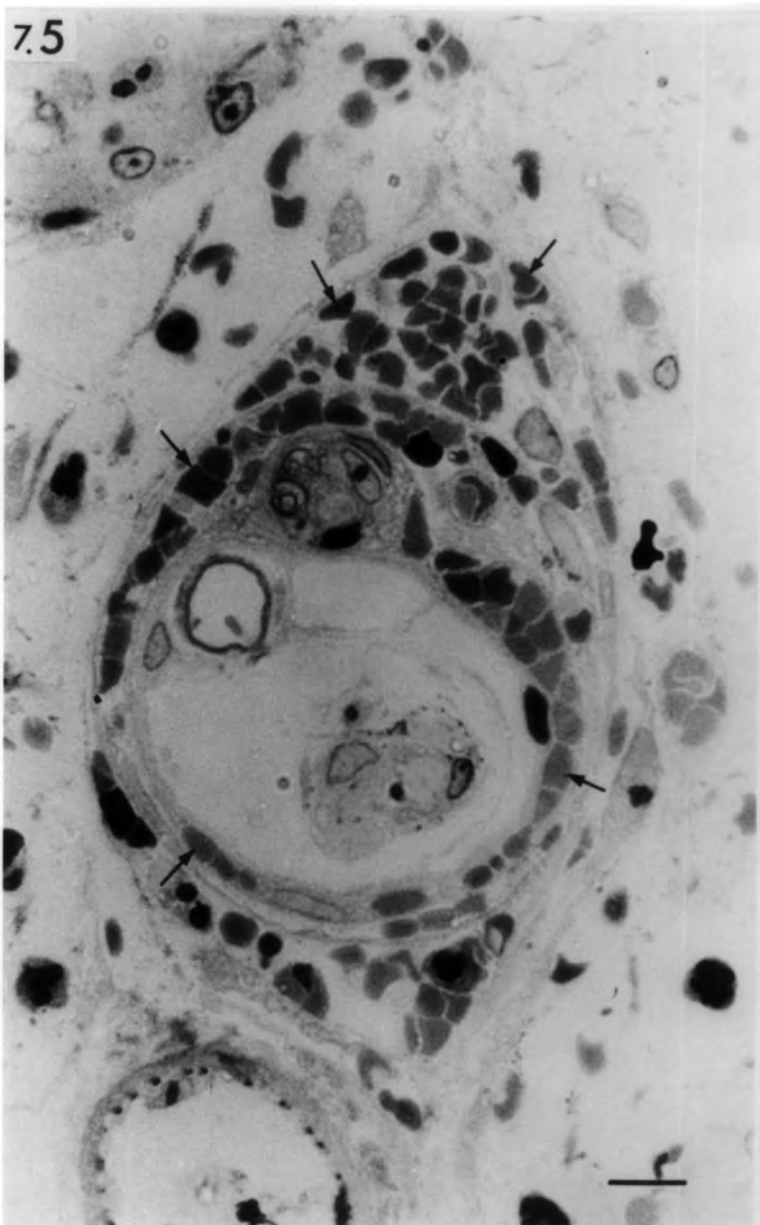


Fig. 7.6 Ischaemic muscle spindle, 2 days after  
devascularization.

- A. Transverse section through the equator: degeneration is more advanced in the thick fibres (F<sub>1</sub>, F<sub>2</sub>) than in the thin fibres (F<sub>3</sub>, F<sub>4</sub>). Remnants of equatorial nuclei (n) can be seen. Two presumptive myoblasts (mb) are present in F<sub>2</sub>. Note the activated Schwann cell (Sc) enclosing a degenerating nerve axon (ax) in which the myelin layers are collapsed and the axoplasm is changed to a honeycomb structure. Arrows point to undifferentiated cells. L; Lipid droplet.
- B. Transverse section through the intracapsular polar region of the same spindle. All of the intrafusal fibres exhibit hyaline degeneration. Macrophages (mac) and granular leucocytes (lc) have invaded the axial bundle. Note the preserved basal lamina of all four intrafusal fibres. Fibrin bundles (f) are present around the capsule.

bars = 5µm

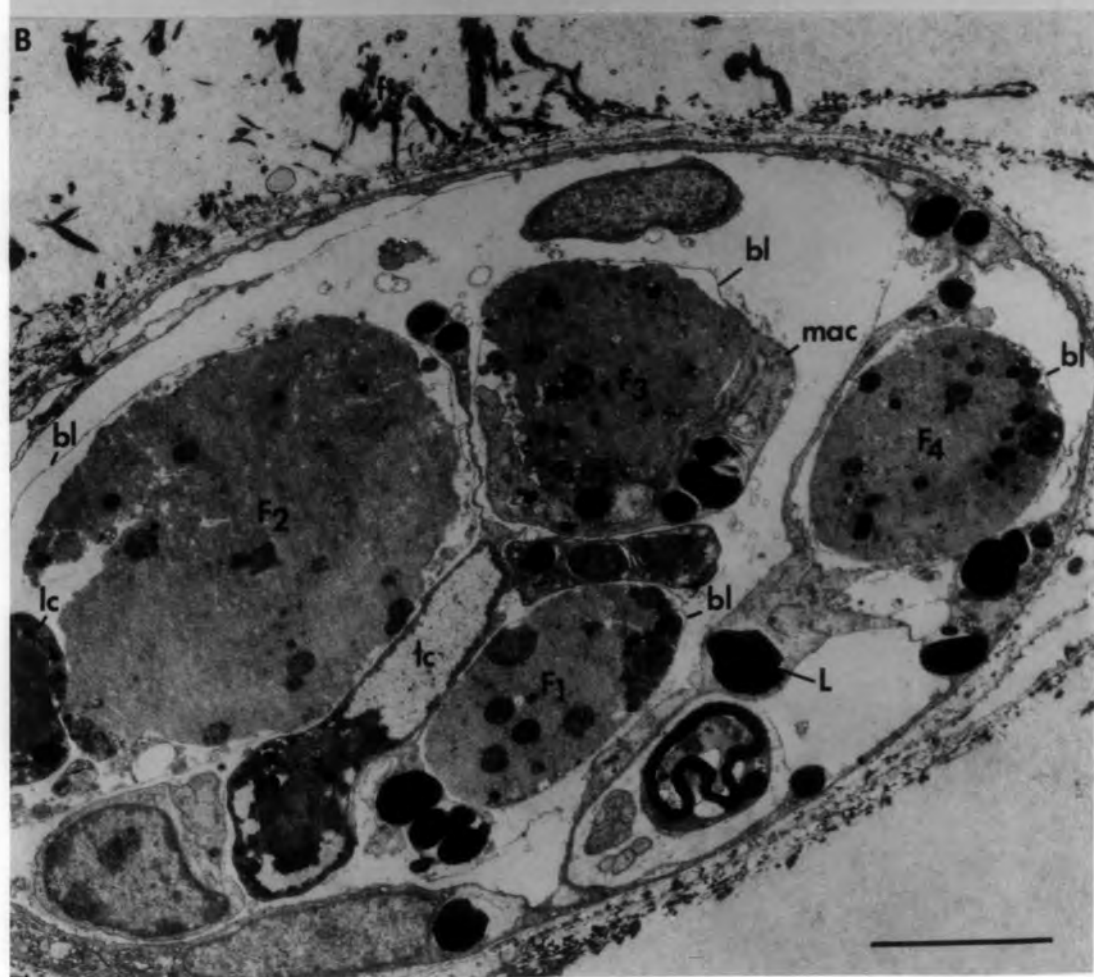
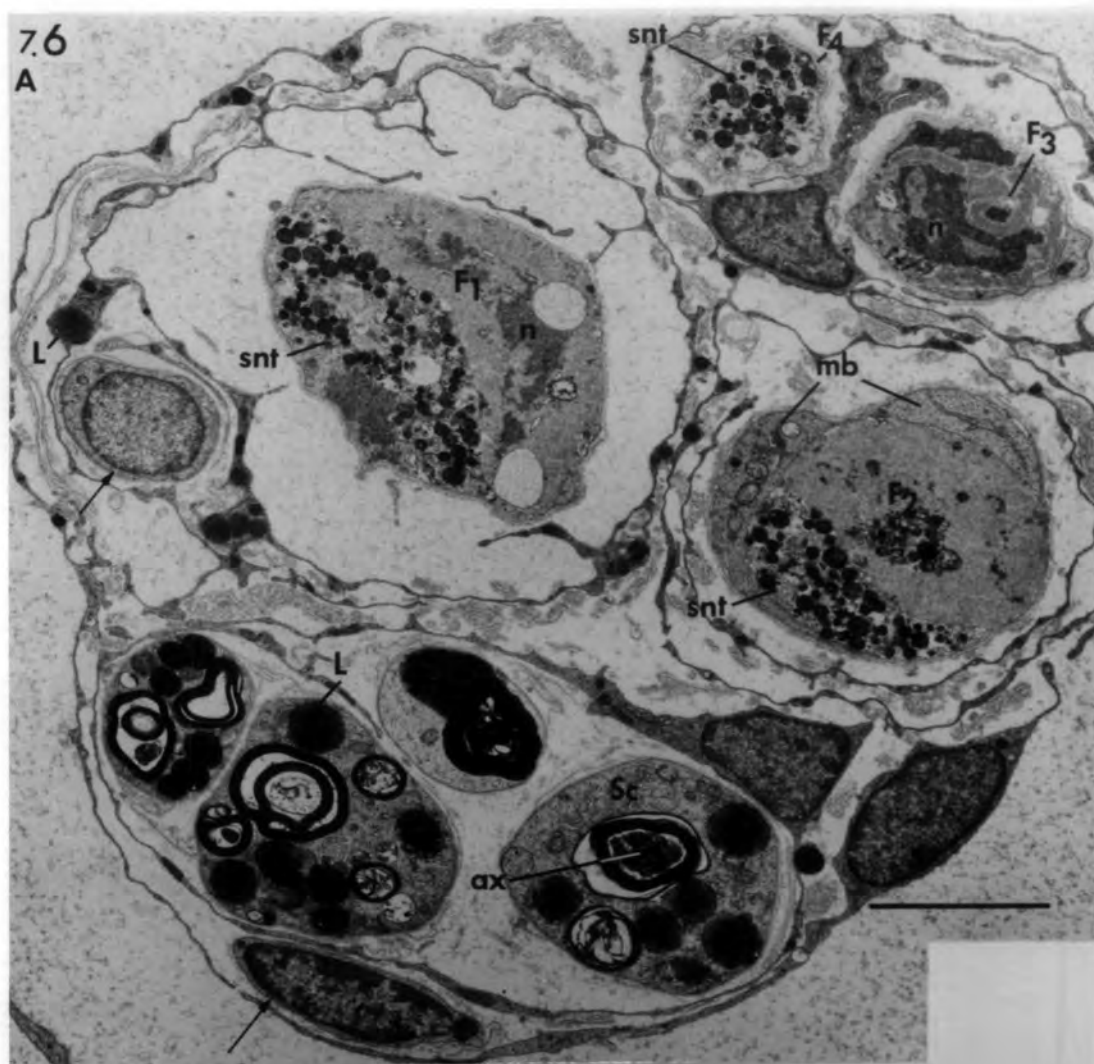
Fig. 7.7 Ischaemic muscle spindle, 3 days after  
devascularization.

Intrafusal fibres show signs of degeneration  
and regeneration.

A. Transverse section through the equator:

hyaline sarcoplasm and macrophages are  
present in three intrafusal fibres  
(F<sub>1</sub>, F<sub>3</sub> & F<sub>4</sub>) and well-developed  
myoblasts may be seen in two fibres  
(F<sub>1</sub> & F<sub>2</sub>). Note the absence of sensory  
nerve terminals.

B. Transverse section through the intra-

capsular polar region of the same spindle:  
hyaline sarcoplasm is absent from all  
fibres.

bars = 5µm

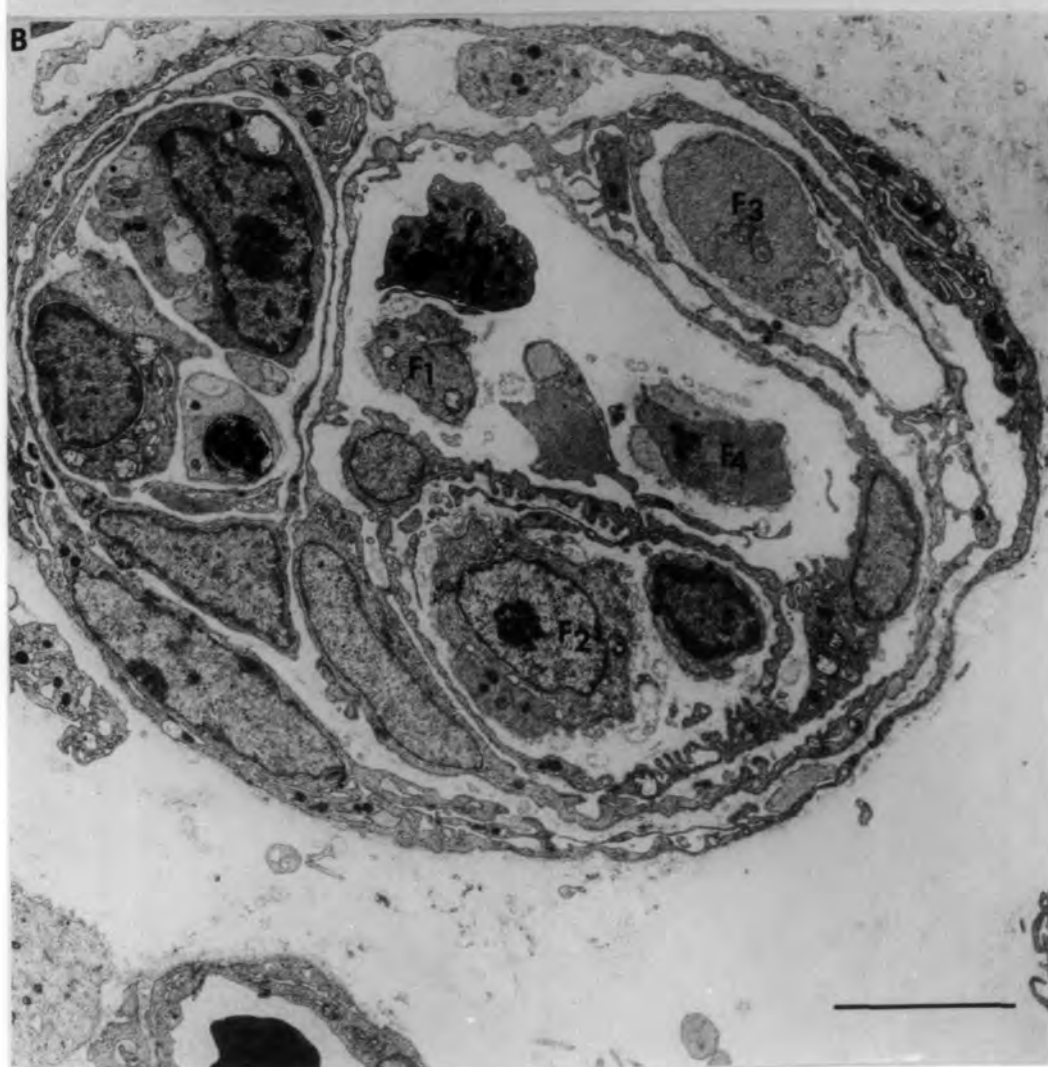
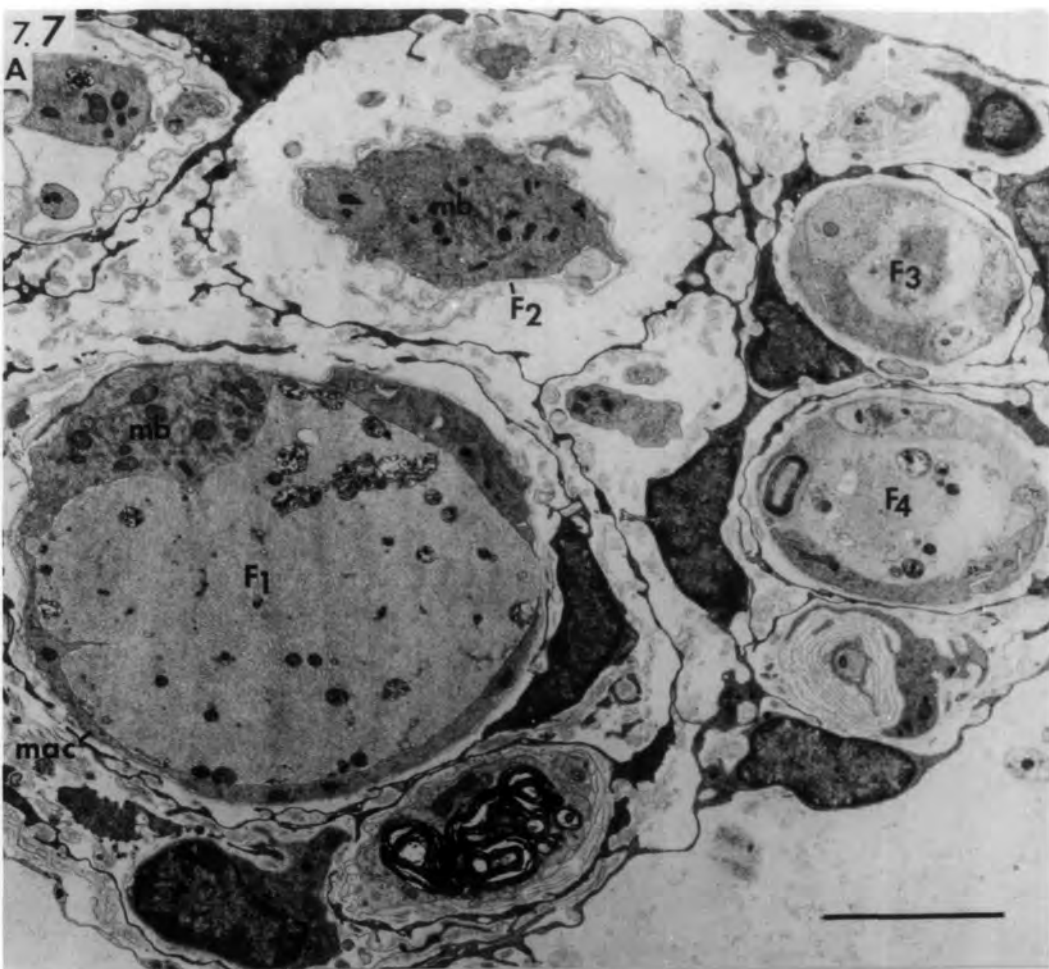


Fig. 7.8 Ischaemic muscle spindle, 5 days after  
devascularization.

Light and electron micrographs of transverse sections through the polar region of the same spindle: intrafusal fibres are at different stages of regeneration. F<sub>1</sub> and F<sub>2</sub> are well-formed myotubes with central nuclei and dense nucleoli, whilst F<sub>3</sub> and F<sub>4</sub> consist of a bundle of nascent myotubes and myoblasts. Note the capsule thickening as a result of activation of capsule cells (cap).

A. 1 $\mu$ m section stained with Toluidine blue.

bar = 10 $\mu$ m

B. bar = 5 $\mu$ m

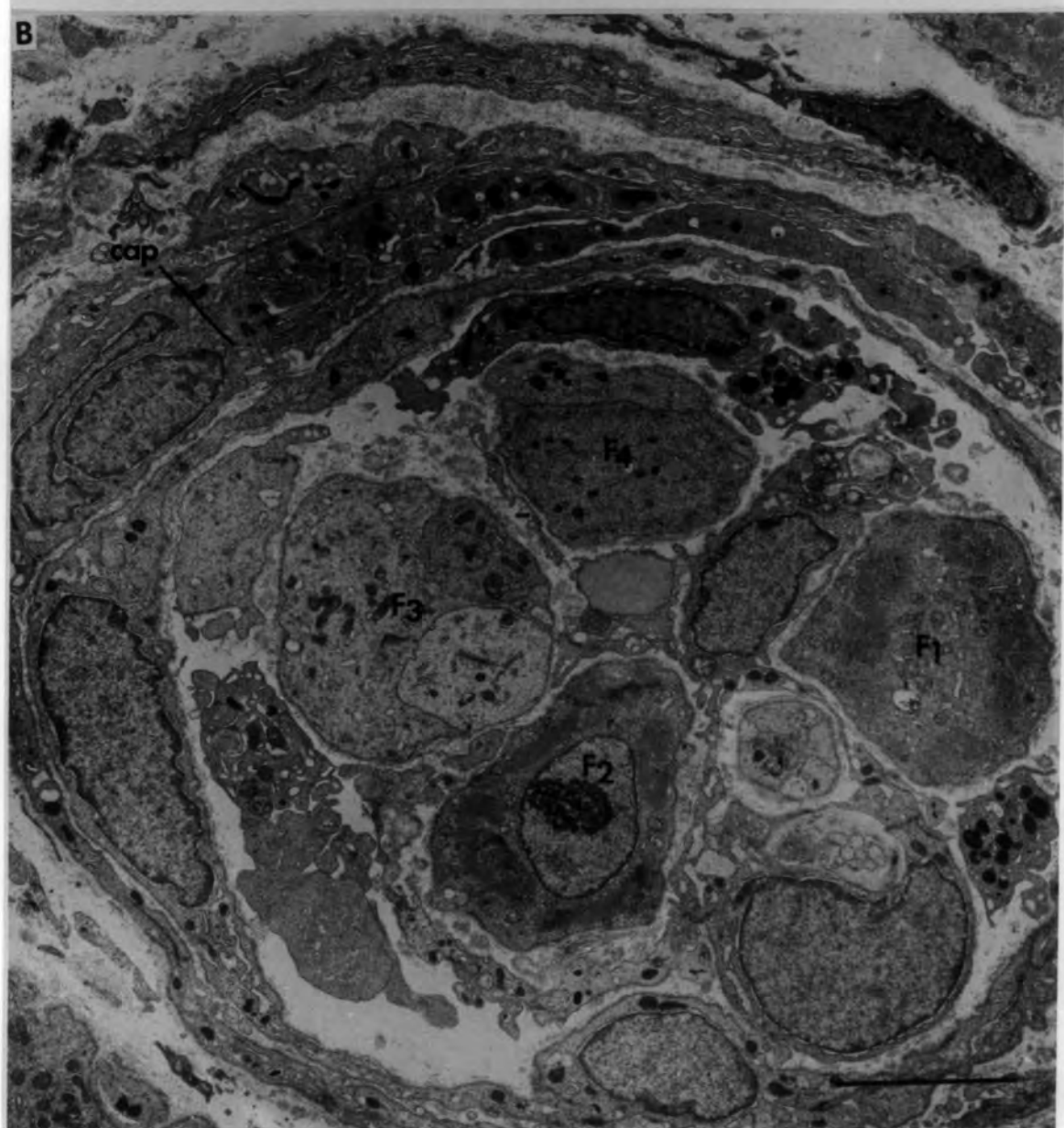
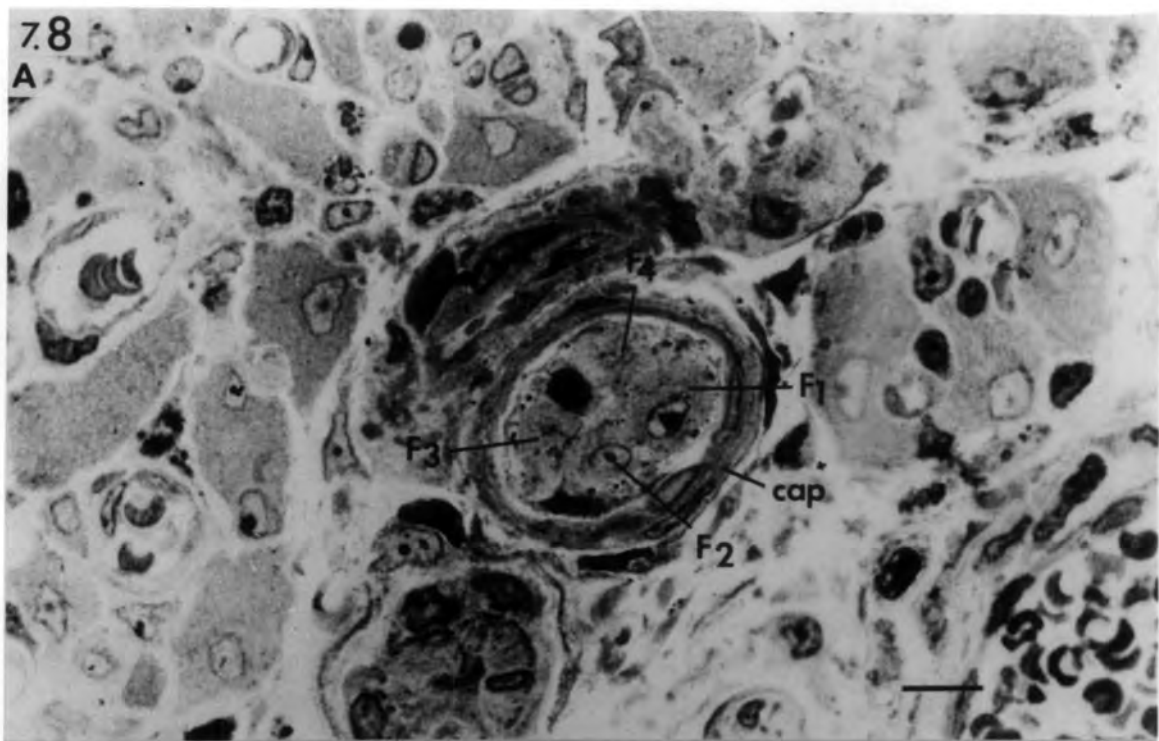


Fig. 7.9 Ischaemic muscle spindle, 14 days after  
devascularization

Light and electron micrographs of transverse sections through the equator of the same spindle: the axial bundle consists of four intrafusal fibres of similar diameters all at an advanced stage of regeneration comparable to that of neighbouring extrafusal muscle fibres (emf). Asterisks mark an additional fibre between the capsule layers.

A. 1µm section stained with Toluidine blue.

bars = 10µm

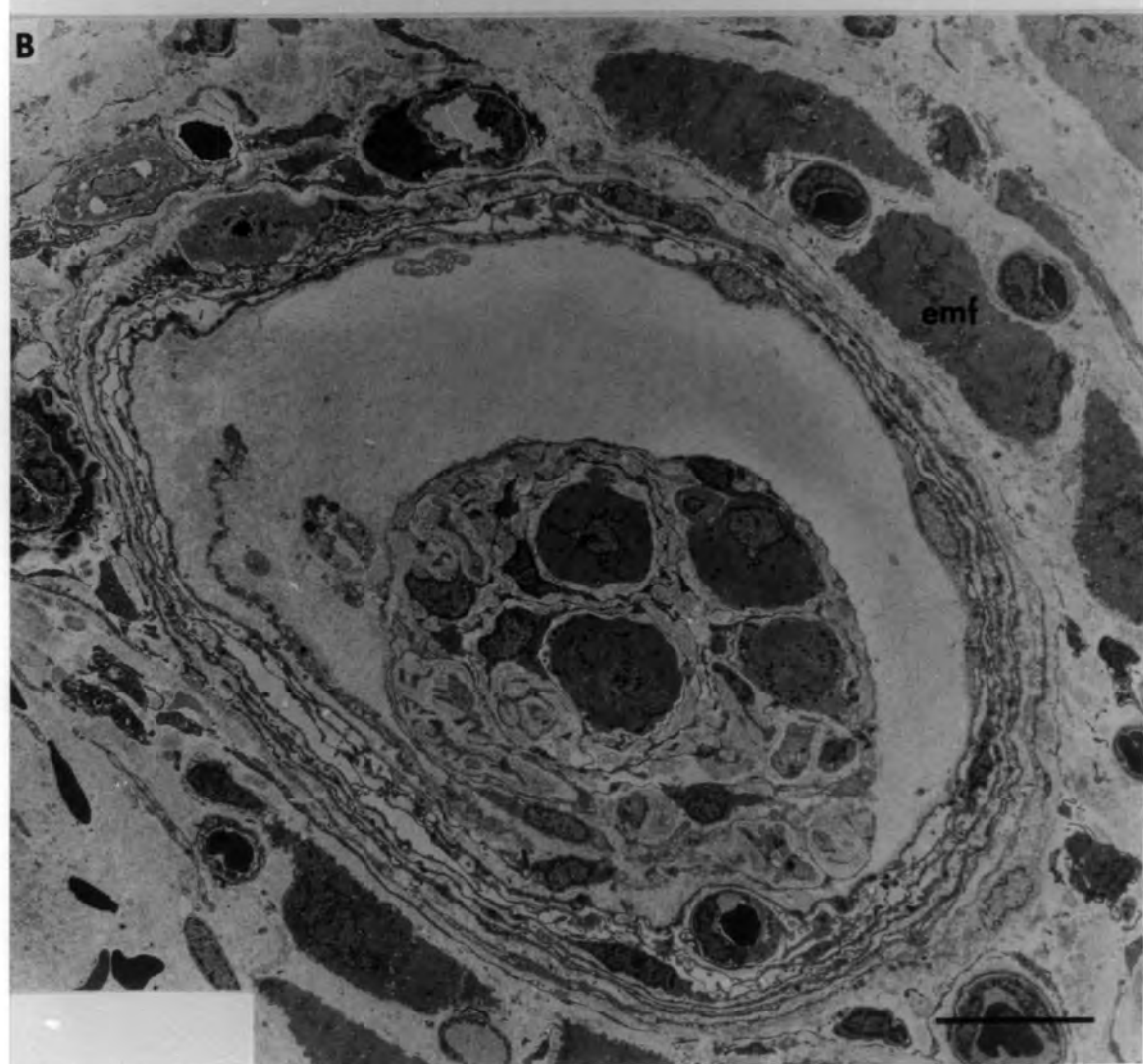
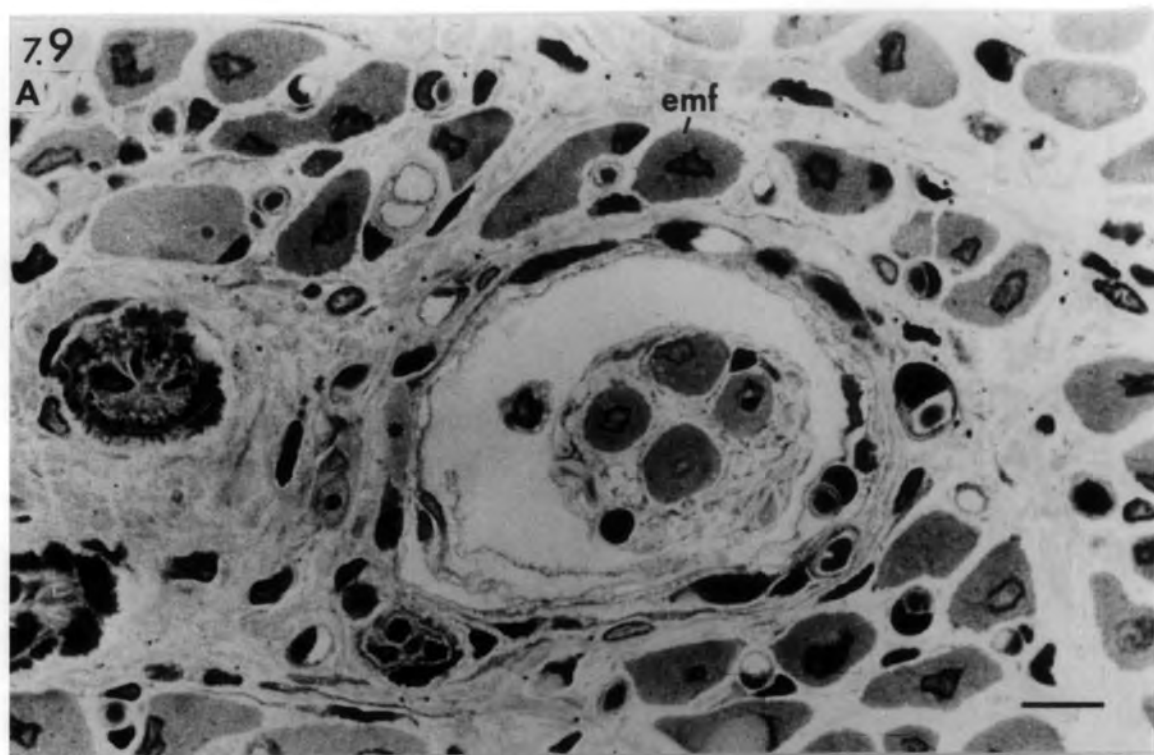


Fig. 7.10 Ischaemic muscle spindle, 14 days after  
devascularization.

Transverse section through the juxta-equatorial (A) and polar (B) regions of the spindle shown in Fig. 7.9A and B. Note the additional fibres (asterisks) within the axial bundle and the capsule. Unlike the original intrafusal fibres ( $F_1$ ,  $F_2$ ,  $F_3$  &  $F_4$ ), the additional fibres are short and do not extend the length of the capsule.

bars =  $5\mu\text{m}$

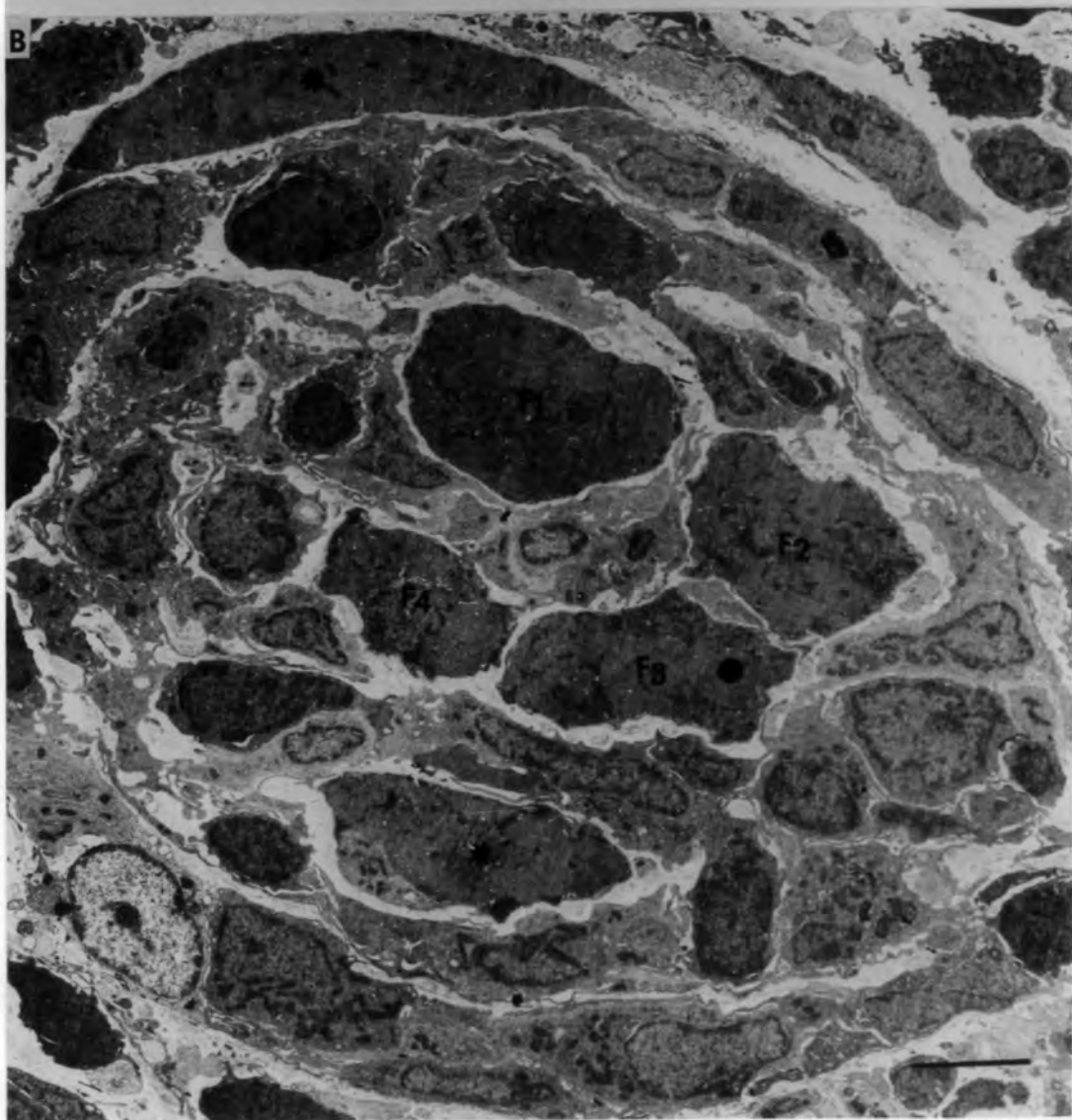
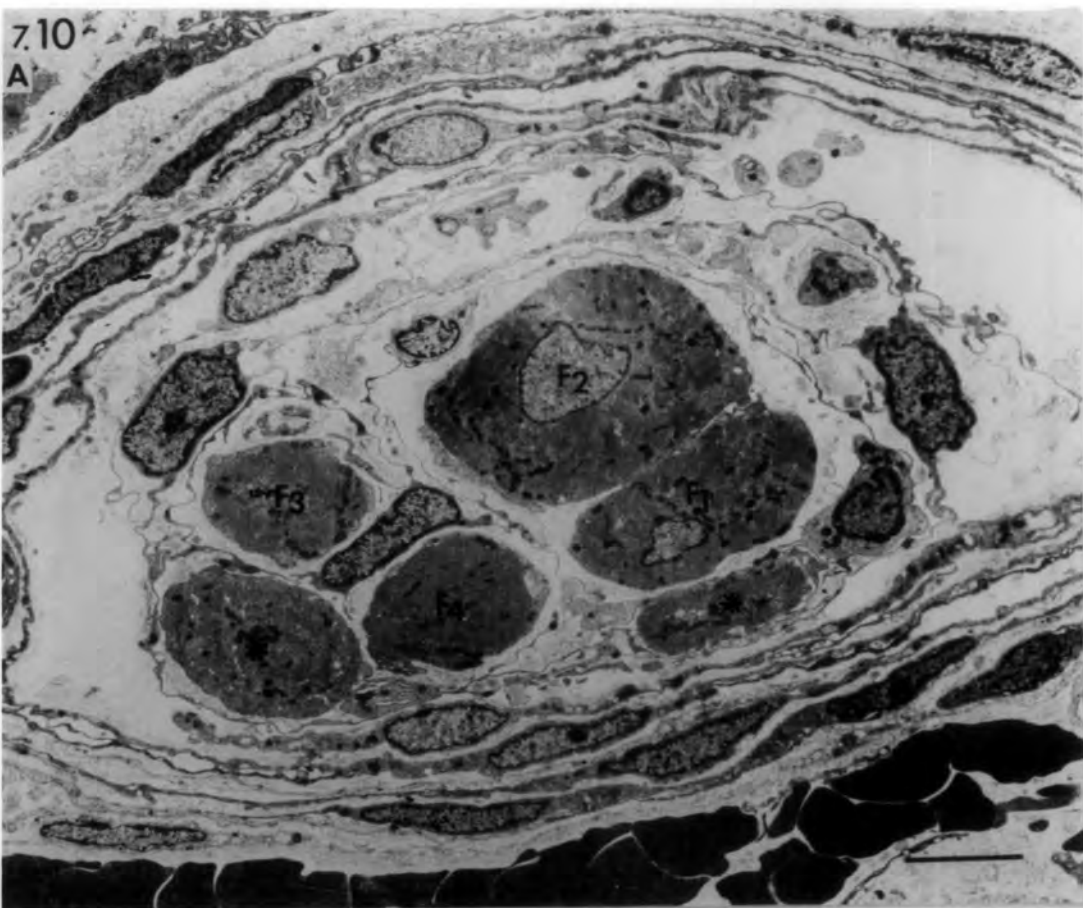


Fig. 7.11 Ischaemic muscle spindle, 21 days  
after devascularization.

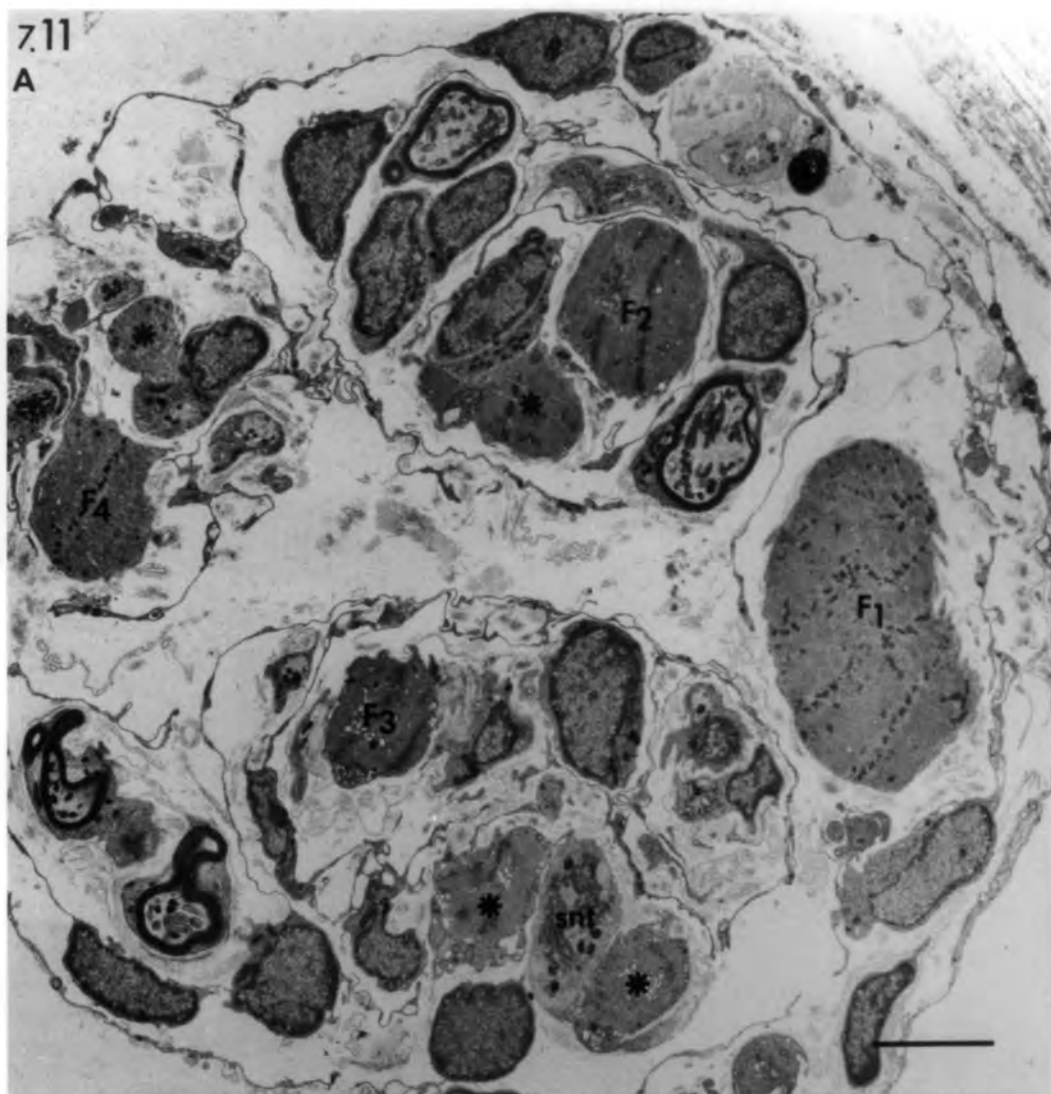
A. Transverse section through the equator: the intrafusal fibres ( $F_1$ ,  $F_2$ ,  $F_3$  &  $F_4$ ) are irregular in shape and are difficult to distinguish from additional fibres (asterisks). Note the sensory nerve terminal (snt) shared between two additional fibres.

B. Transverse section through the intracapsular polar region of the same spindle:  $F_1$  and  $F_2$  fibres show signs of atrophy, and lack any kind of innervation. Note the absence of additional fibres.

bars = 5 $\mu$ m

7.11

A



B

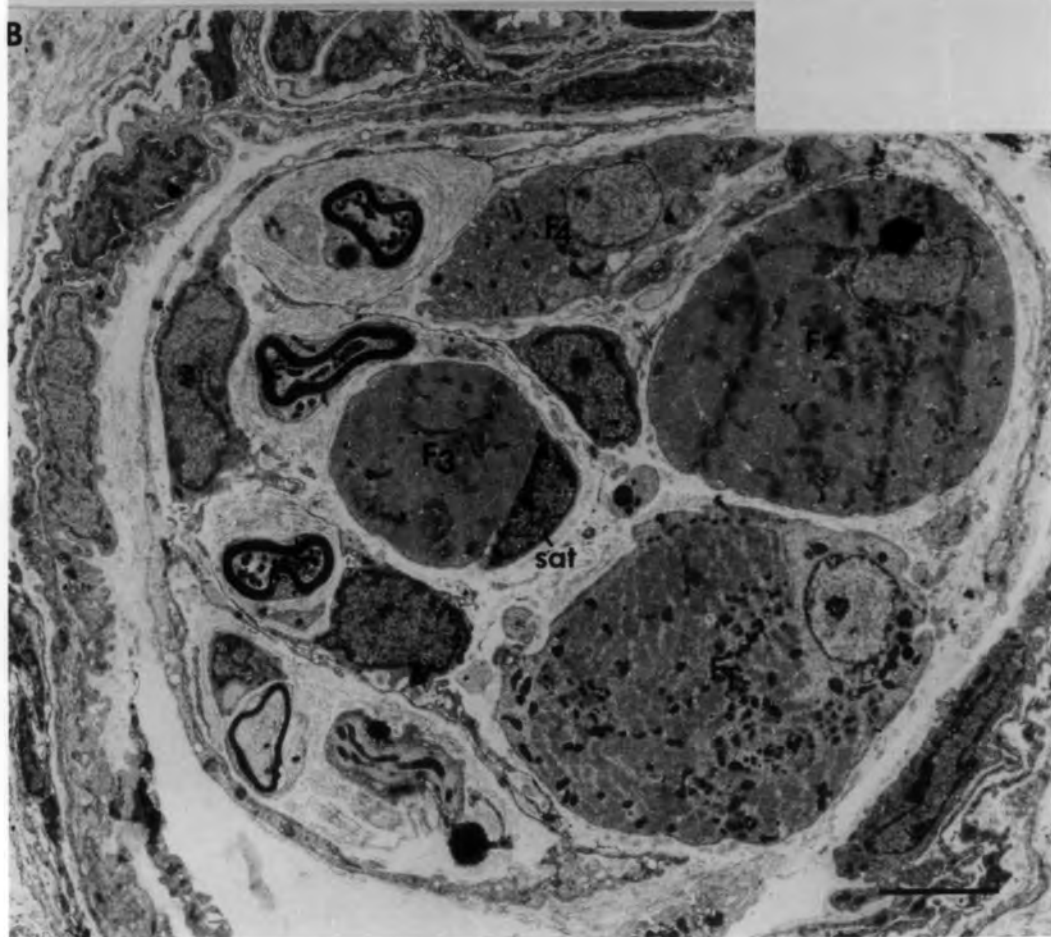

Fig. 7.12 Schematic diagrams of transverse sections of the equatorial regions of the four groups of regenerated ischaemic muscle spindles.

- A. Group 1: Fully-restored spindle with the characteristic features of a normal spindle. Sensory nerve terminals (snt) are distributed to all intrafusal fibres, which have the ultrastructure of bag<sub>2</sub>, bag<sub>1</sub> and chain fibres.
  
- B. Group 2: Sensory nerve terminals are distributed to all intrafusal fibres. The regenerated chain fibres have normal equatorial nucleation. The regenerated "bag" fibres have reduced bags of nuclei.
  
- C. Group 3: Sensory nerve terminals are mostly confined to the thin fibres which have abnormal chains of nuclei. The thick "bag" fibres lack equatorial nucleation.
  
- D. Sub-group 4A: Sensory nerve terminals are absent from all intrafusal fibres of this sub-group, which are reinnervated exclusively by motor axons. Note the highly-reduced periaxial space.
  
- E. Sub-group 4B: Sensory and motor nerve terminals are absent from all intrafusal fibres of this sub-group, although numerous axons (ax) are present.

Arrows point to additional fibres.

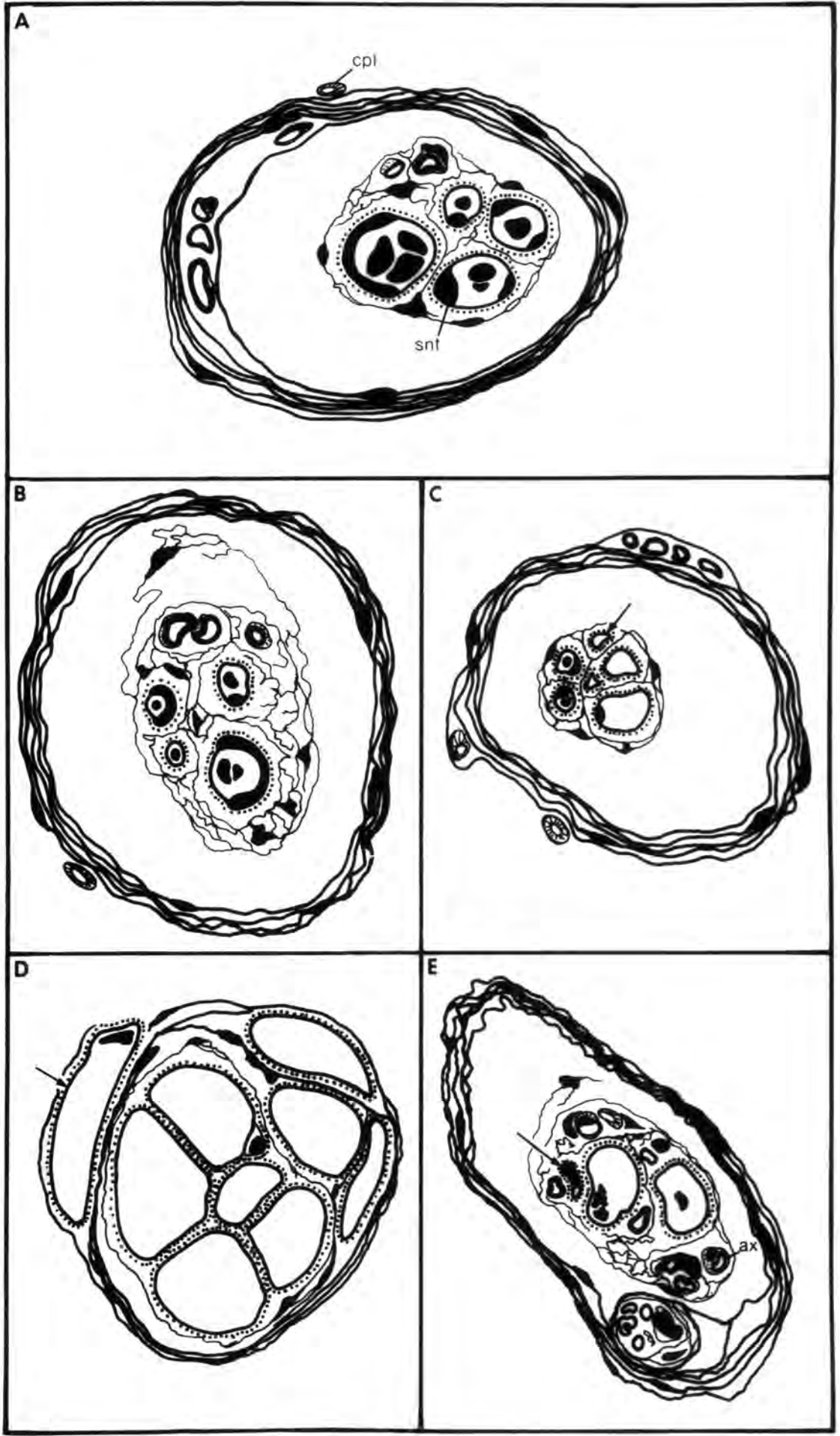


Fig. 7.13 Ischaemic muscle spindle, 28 days after  
devascularization.

An example of a group 1 regenerated  
spindle.

- A. Transverse section through the  
equatorial region showing fully-  
differentiated bag<sub>1</sub>, bag<sub>2</sub> and chain  
fibres, and extensive sensory  
innervation.
  
- B. Transverse section through the  
intracapsular polar region of the  
same spindle showing the normal  
M-line conditions in bag and chain  
fibres.

bars = 5 $\mu$ m

7.13  
A

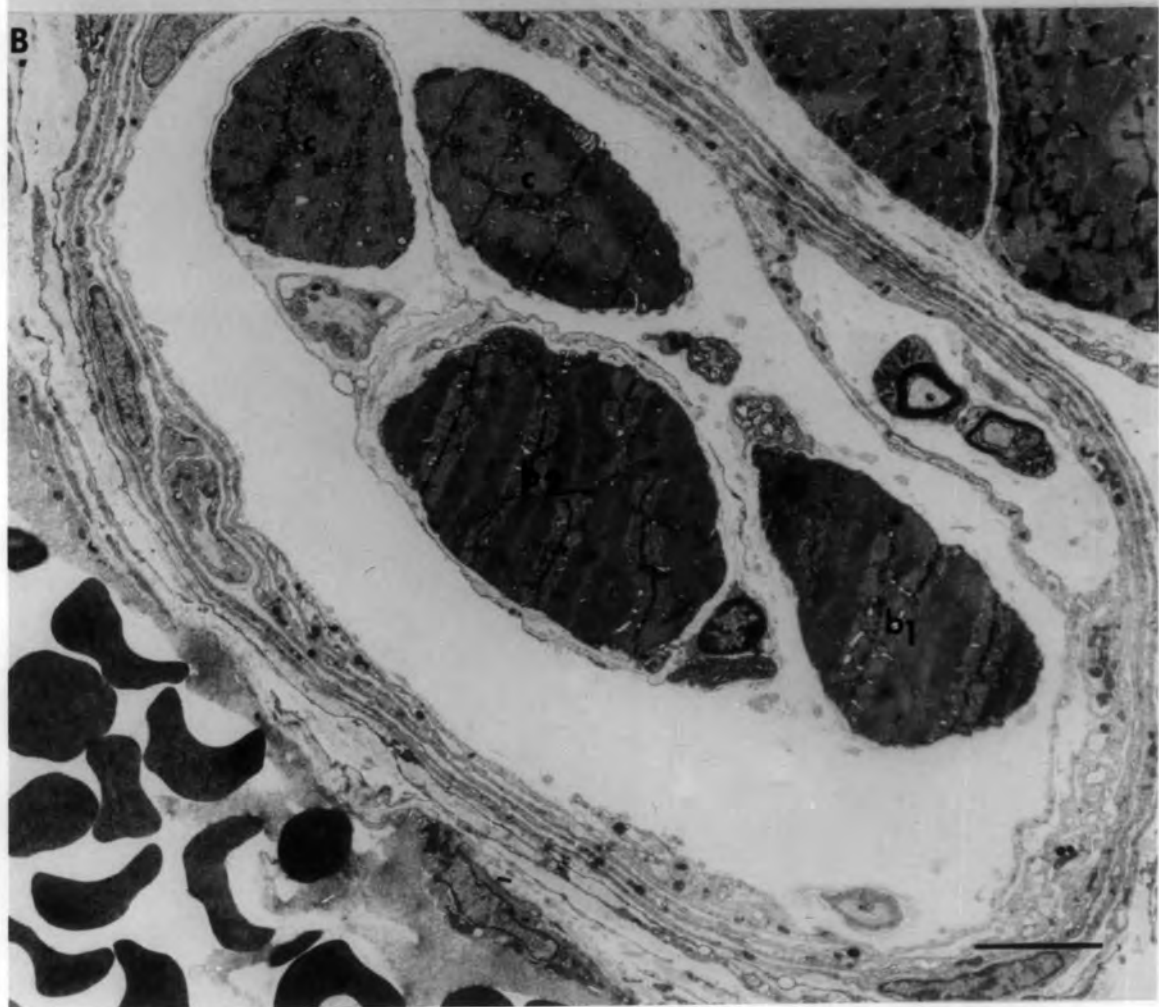
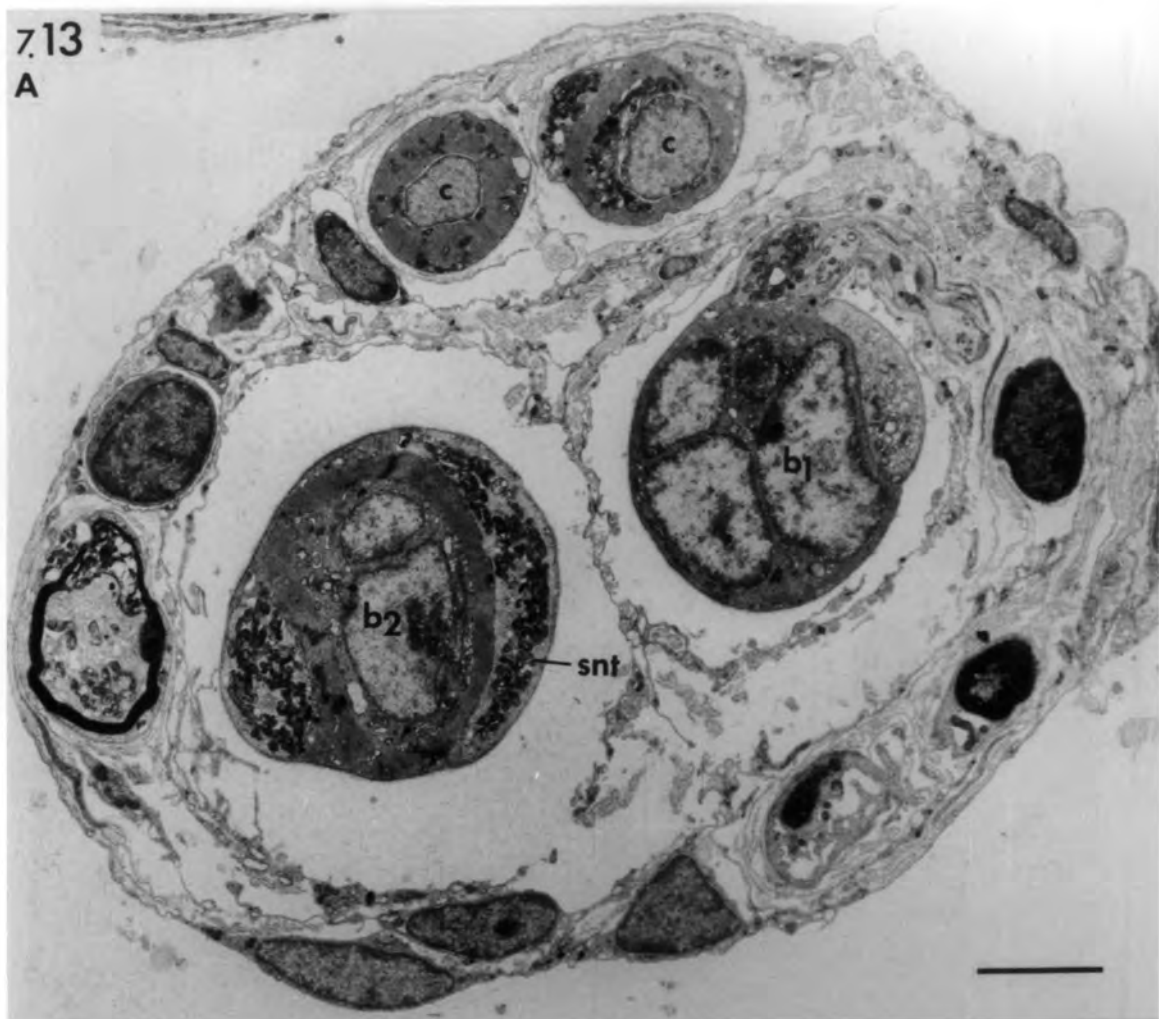


Fig. 7.14 Ischaemic muscle spindle, 56 days after  
devascularization.

An example of a group 2 regenerated spindle.

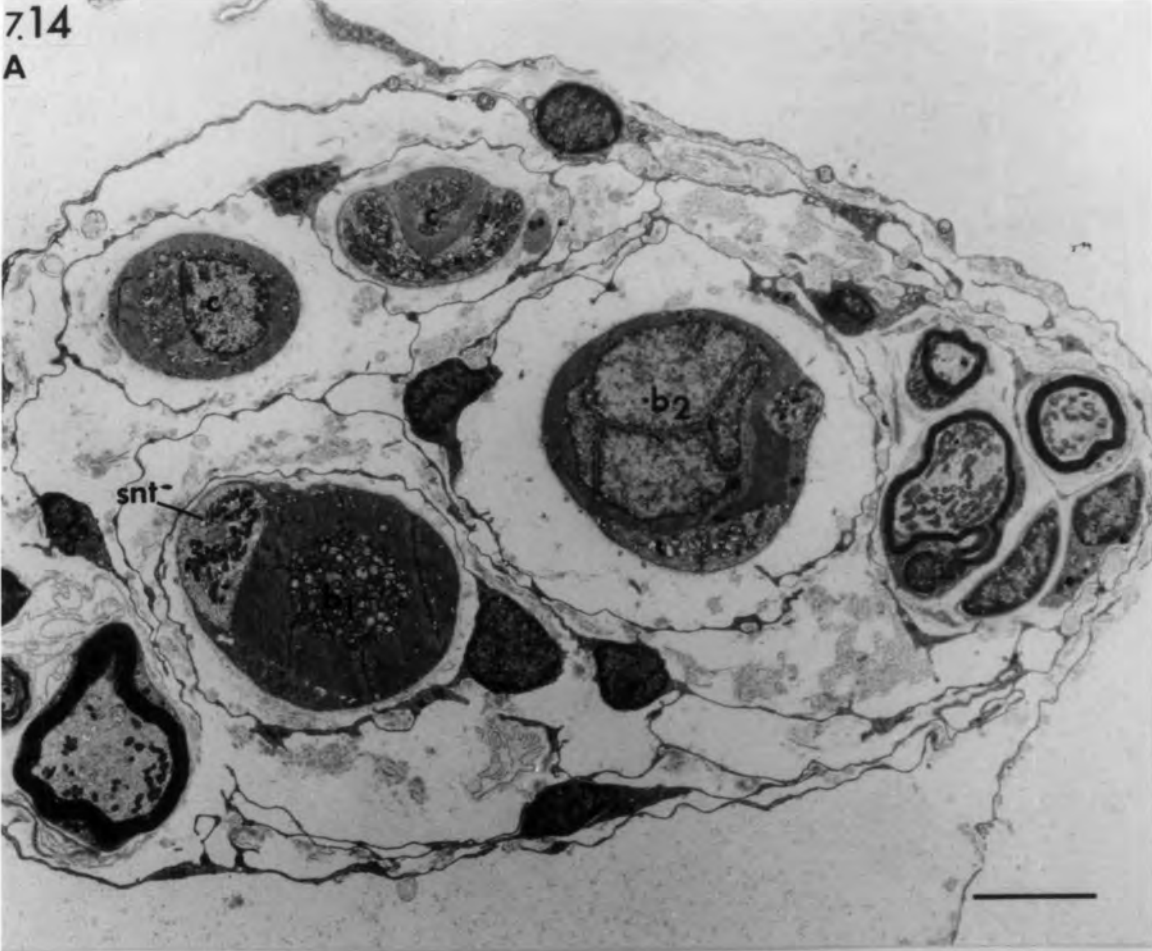A. Transverse section through the equatorial region showing sensory terminals on chain and bag fibres. Serial sectioning of the equatorial region showed the chain fibres to be fully-differentiated whilst the bag fibres are deficient in their equatorial nucleation.

B. Transverse section through the intracapsular polar region of the same spindle showing the normal M-line condition in bag and chain fibres. Note the motor nerve terminal (mnt) on the chain fibre.

bars = 5 $\mu$ m

7.14

A



B

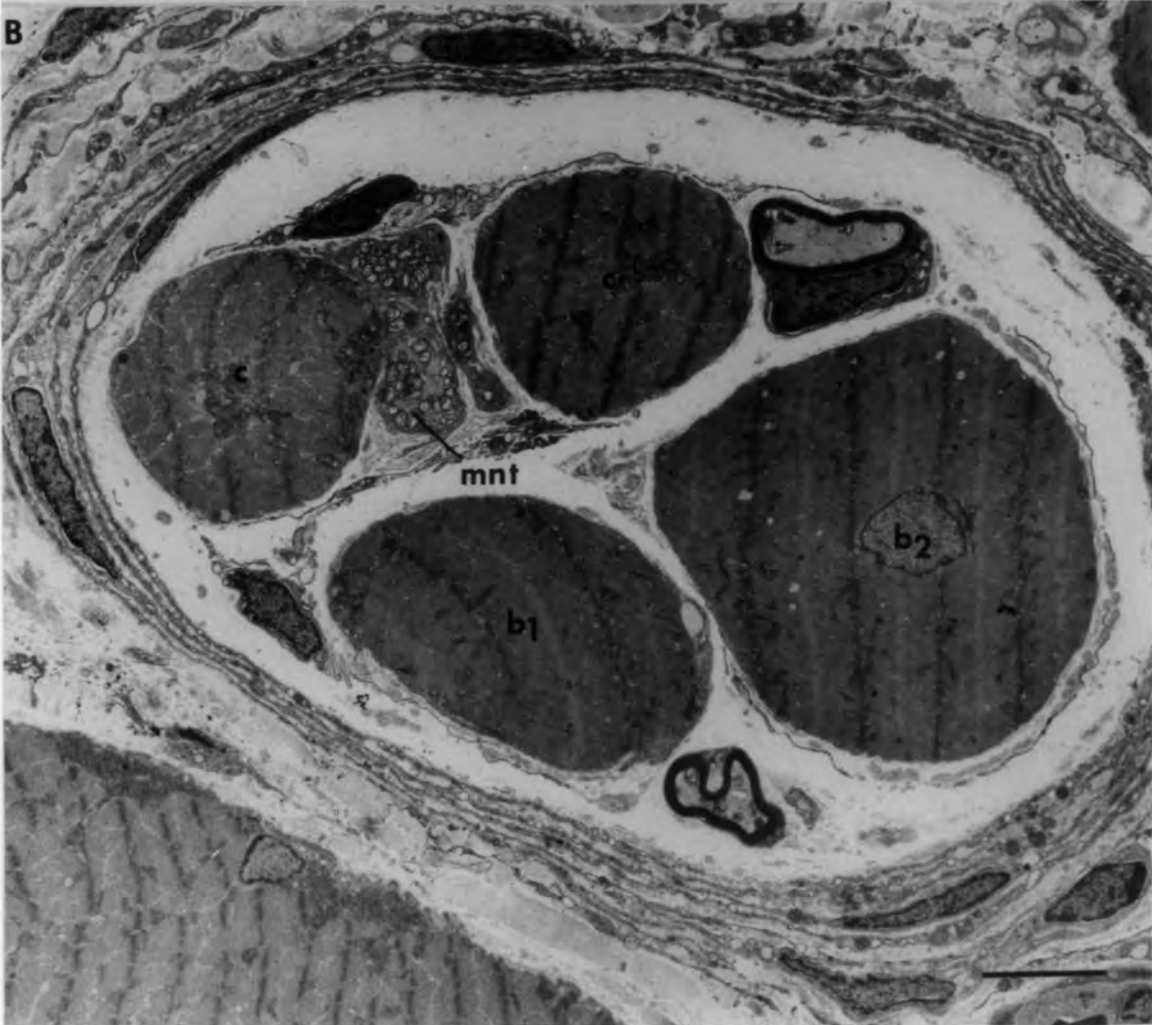

Fig. 7.15 Ischaemic muscle spindle, 56 days after  
devascularization.

An example of a group 3 regenerated  
spindle.

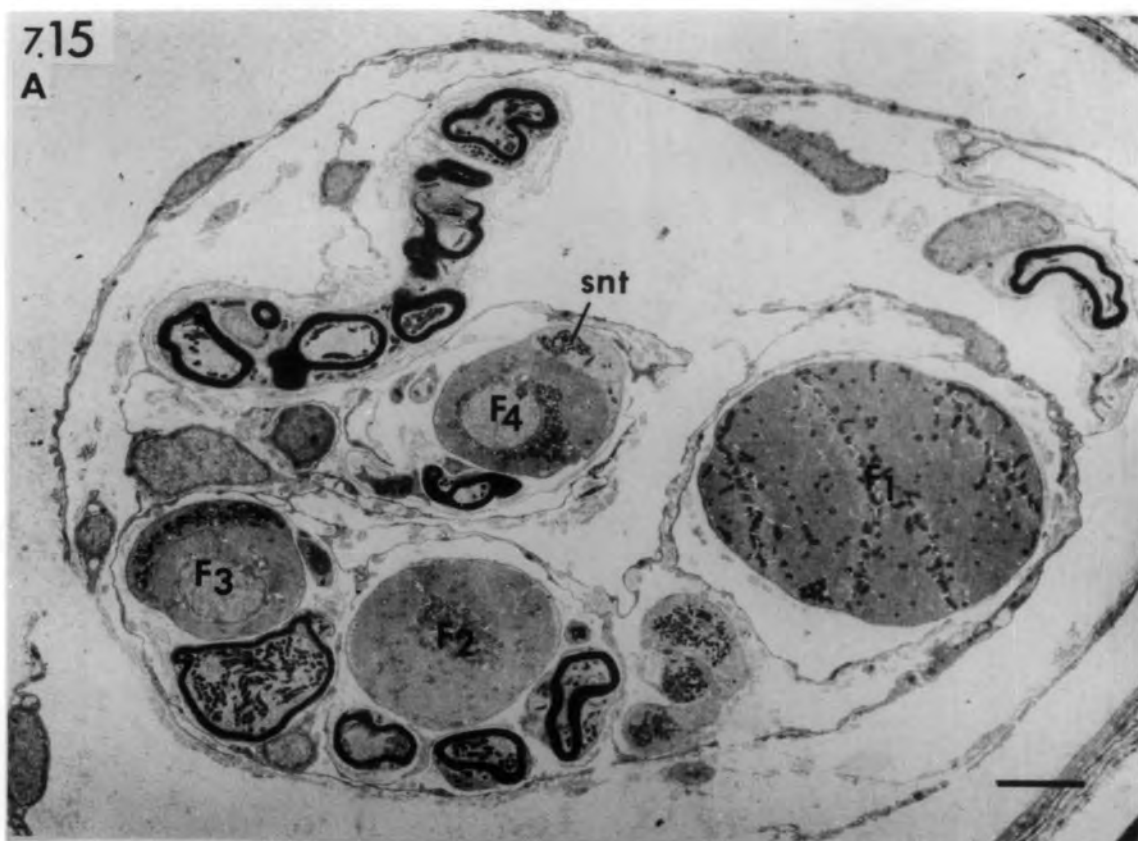A. Transverse section through the  
equatorial region showing sensory  
terminals on the thin fibres ( $F_3$  &  $F_4$ )  
only. Serial sectioning of the  
equatorial region showed that the  
sensory nerve terminals (snt) are  
confined to the thin fibres which have  
poorly-developed nuclear chains, and  
that the thick fibres ( $F_1$  &  $F_2$ ) lack  
any organized equatorial nucleation.

B. Transverse section through the  
intracapsular polar region of the same  
spindle.

bars =  $5\mu\text{m}$

7.15

A



B

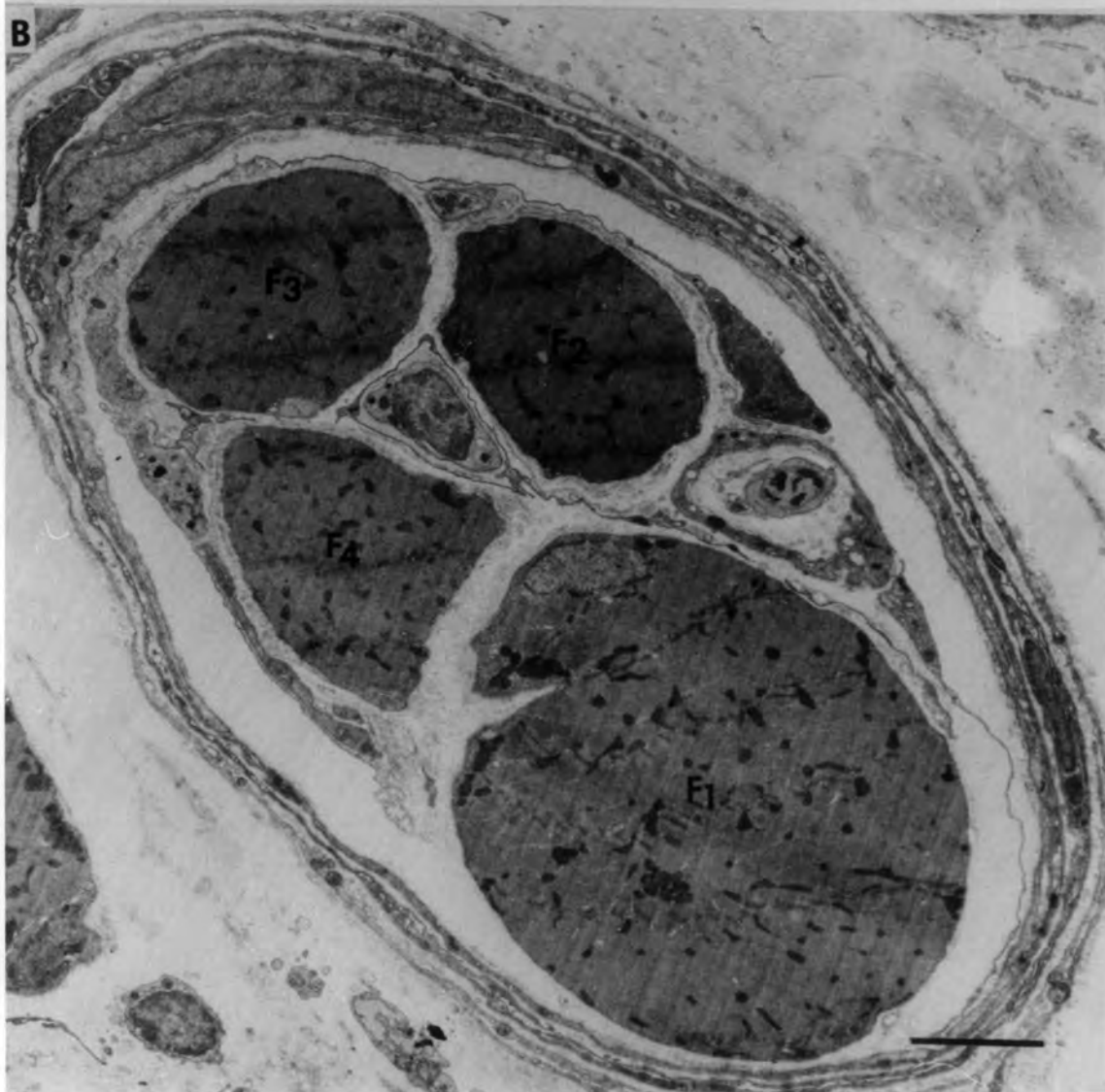

Fig. 7.16 Ischaemic muscle spindle, 182 days after  
devascularization.

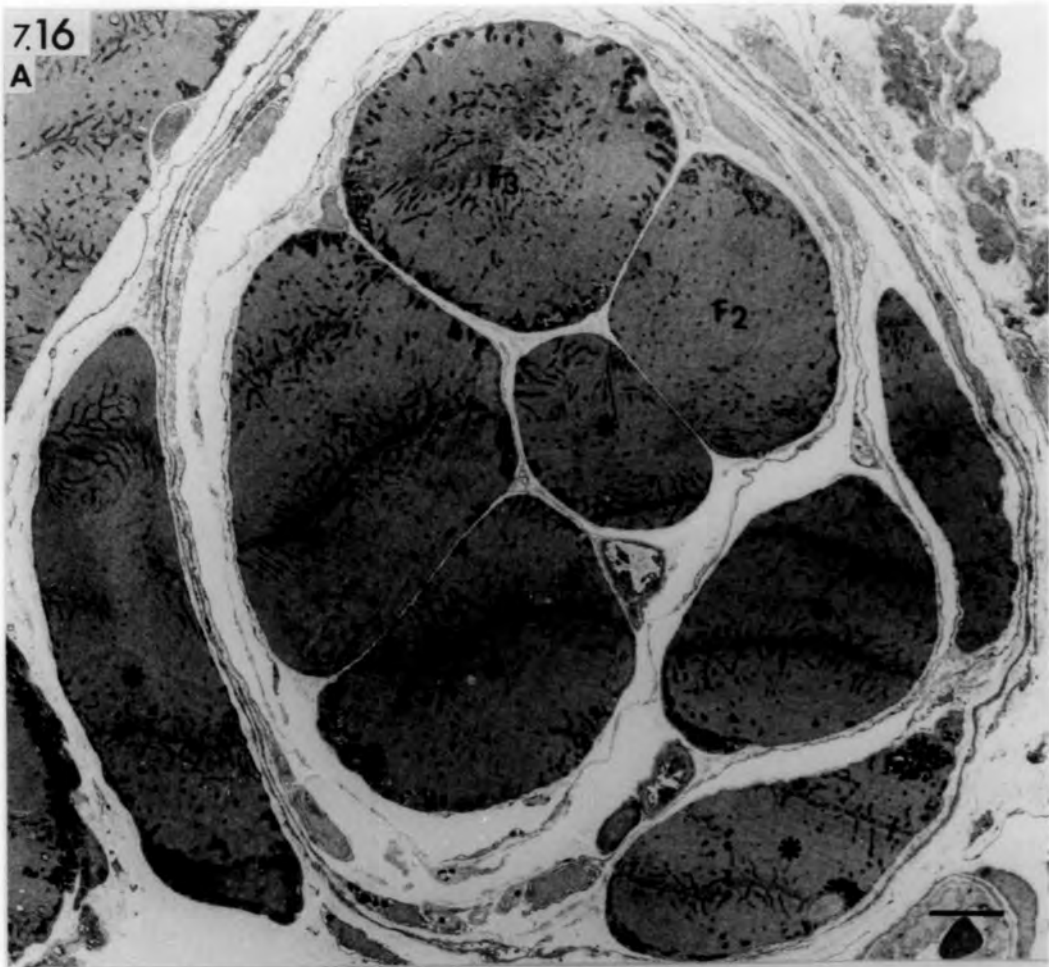
An example of a group 4 (subgroup A)  
regenerated spindle.

- A. Transverse section through the  
"equator". Note that the regenerated  
fibres ( $F_1$ ,  $F_2$  &  $F_3$ ) are thicker than  
normal and lack sensory terminals and  
equatorial nucleation. The periaxial  
space is reduced.
- B. Transverse section through the intracapsular  
polar region of the same spindle showing the  
large diameter of the regenerated fibres and  
the tight enclosing capsule. The intrafusal  
fibres of this subgroup have abnormal motor  
endings (not shown). Asterisks in both  
micrographs indicate additional fibres.

bars = 5 $\mu$ m

7.16

A



B

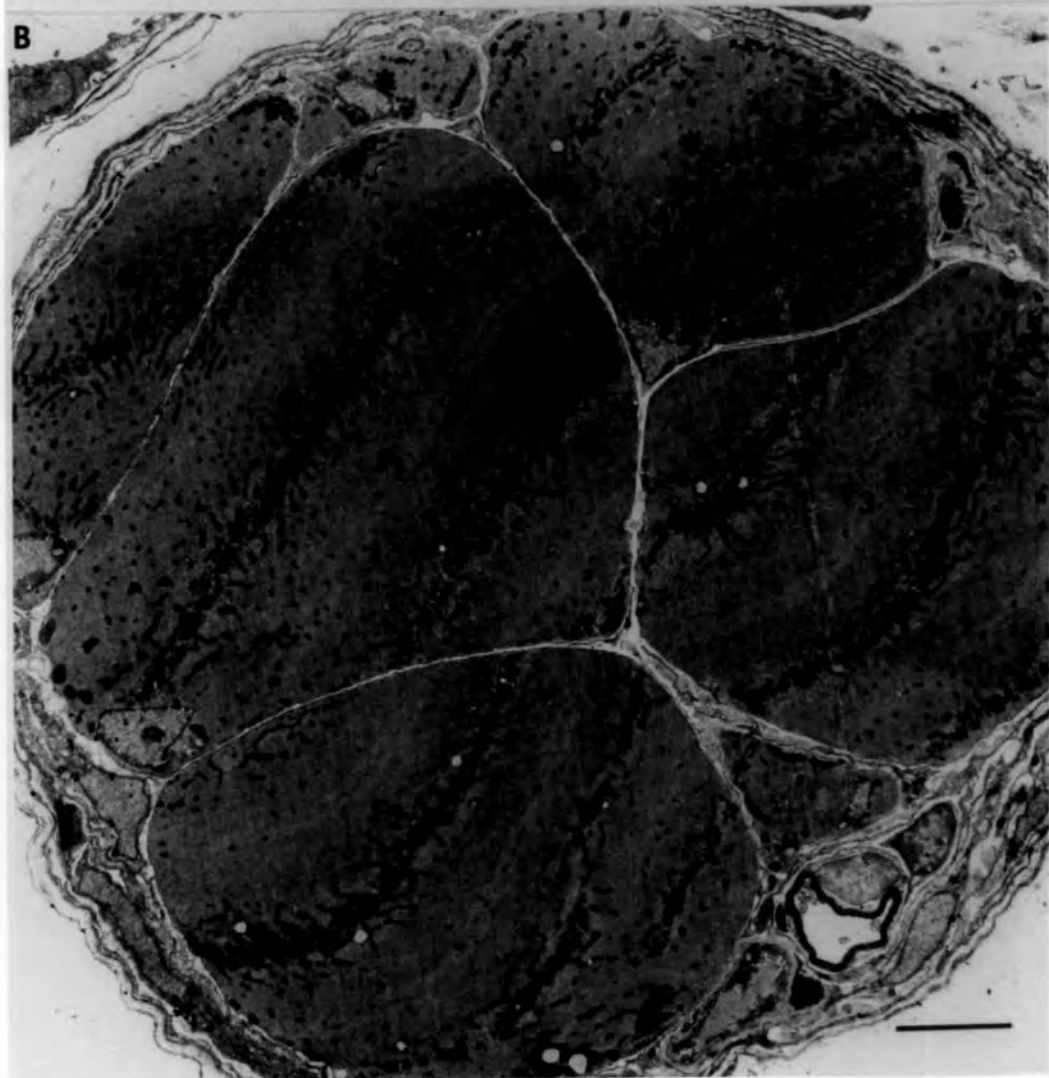

Fig. 7.17 Ischaemic muscle spindle, 56 days after  
devascularization.

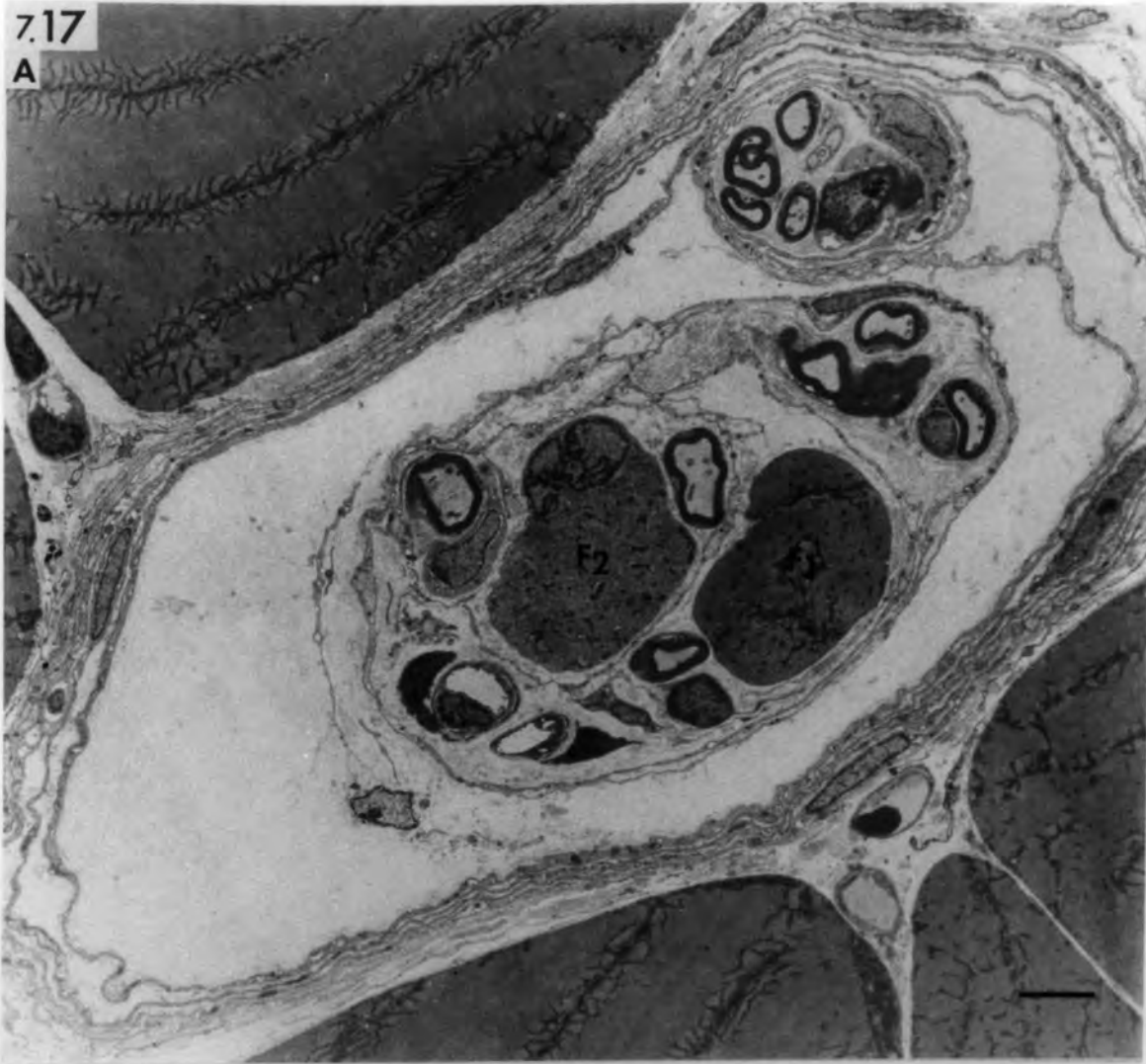An example of a group 4 (subgroup B)  
regenerated spindle.

- A. Transverse section through the equatorial region showing only two regenerated fibres ( $F_1$  &  $F_2$ ) that lack sensory terminals and equatorial nucleation. Signs of atrophy are seen in  $F_2$ . Note the flattened capsule and the reduced periaxial space.
- B. Transverse section through the intracapsular polar region of the same spindle. Asterisk indicates an additional fibre. The regenerated fibres of this subgroup lack any kind of nerve endings although many axons are present.

bars = 5 $\mu$ m

7.17

A



B

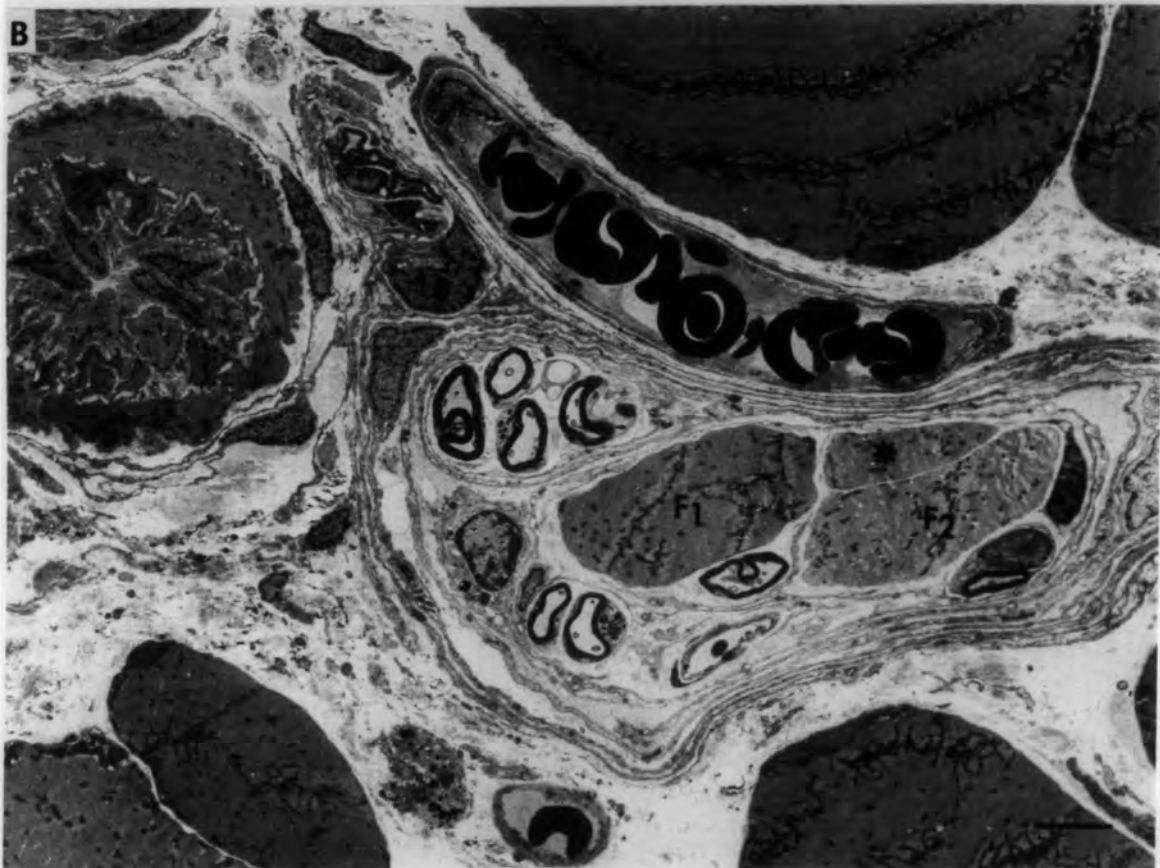

Fig. 8.1 Ischaemic muscle spindle 3 hours after  
devascularization

A. Longitudinal section of the intracapsular polar region showing early changes in the bag<sub>2</sub> and chain fibres whilst the bag<sub>1</sub> fibre appears normal. Note absence of Z-line (arrows) in the bag<sub>2</sub> fibre and the altered mitochondria (mit), pyknotic nucleus (n), and disorganized myofibrils in the chain fibre.

bar = 5µm

B. High power of a chain fibre showing altered mitochondria (mit), dilated sarcoplasmic system (sr) and disorganized myofibrils. Note the preserved M-line and absence of Z-line. Arrow heads point to sarcoplasmic elements that contain granular material.

bar = 1µm


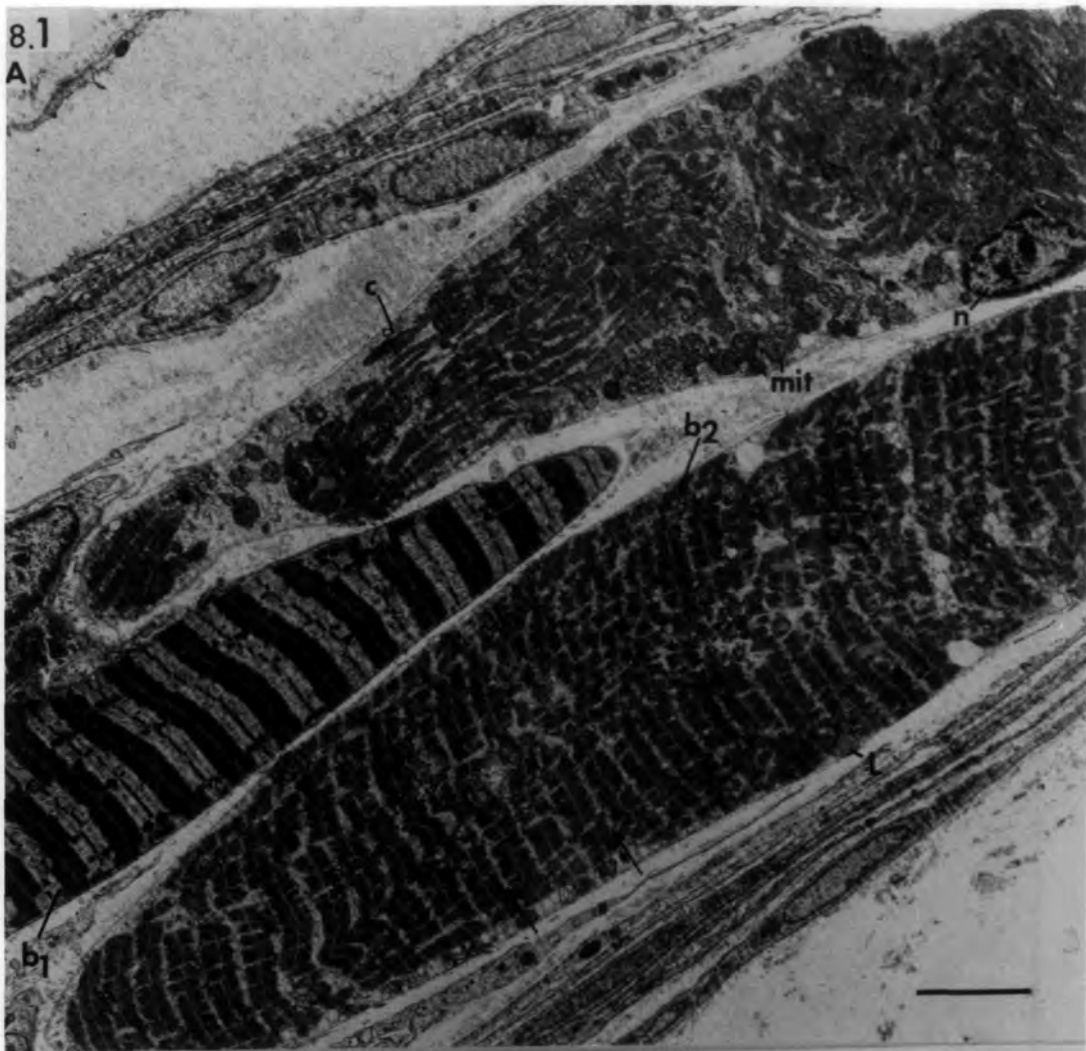


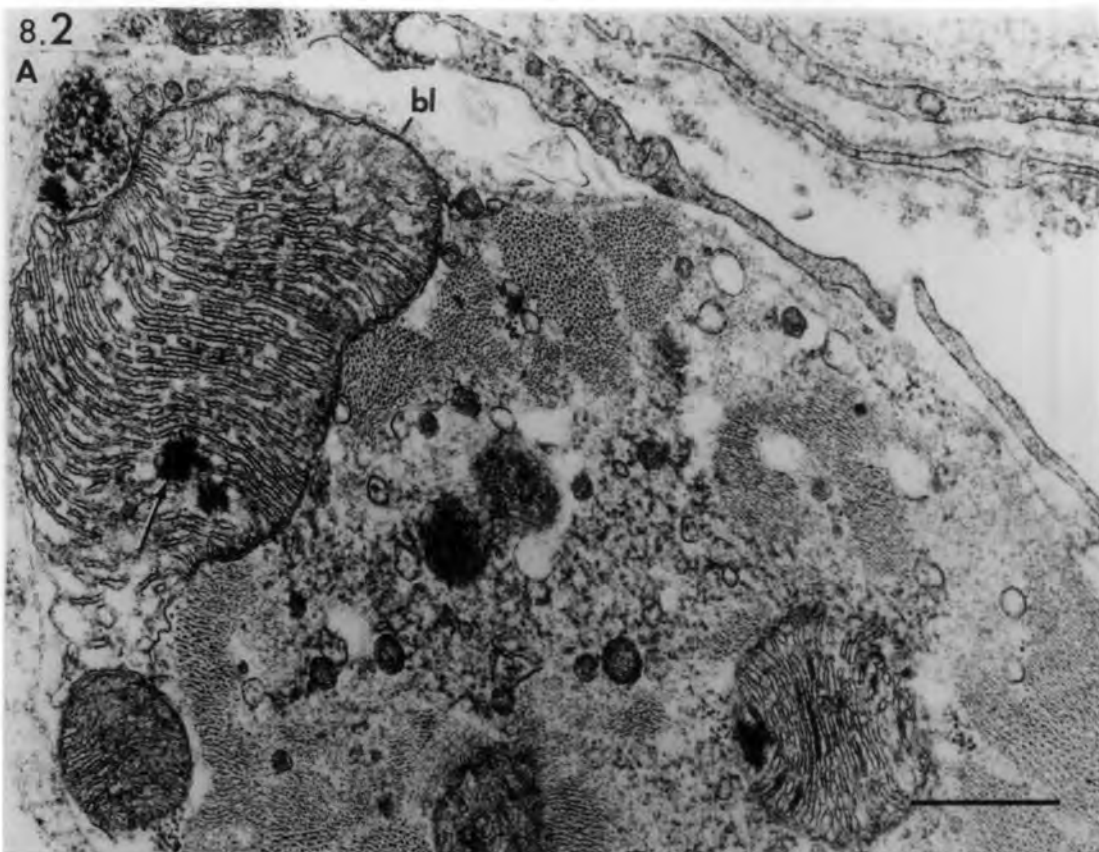
Fig. 8.2 Ischaemic muscle spindles 6 hours after  
devascularization

Transverse section of degenerating intrafusal fibres showing various mitochondrial changes; giant and enlarged mitochondria with tubular, vesicular and granular contents. Rod-like structures may be seen between the tubular cristae and between the outer mitochondrial membranes. Arrows point to osmiophilic bodies. The sarcotubular system is changed to vesicles of varying sizes which may contain granular material (arrow heads). Note the preserved basal lamina (bl) and absence of underlying sarcolemma.

bars = 1 $\mu$ m

8.2

A



B

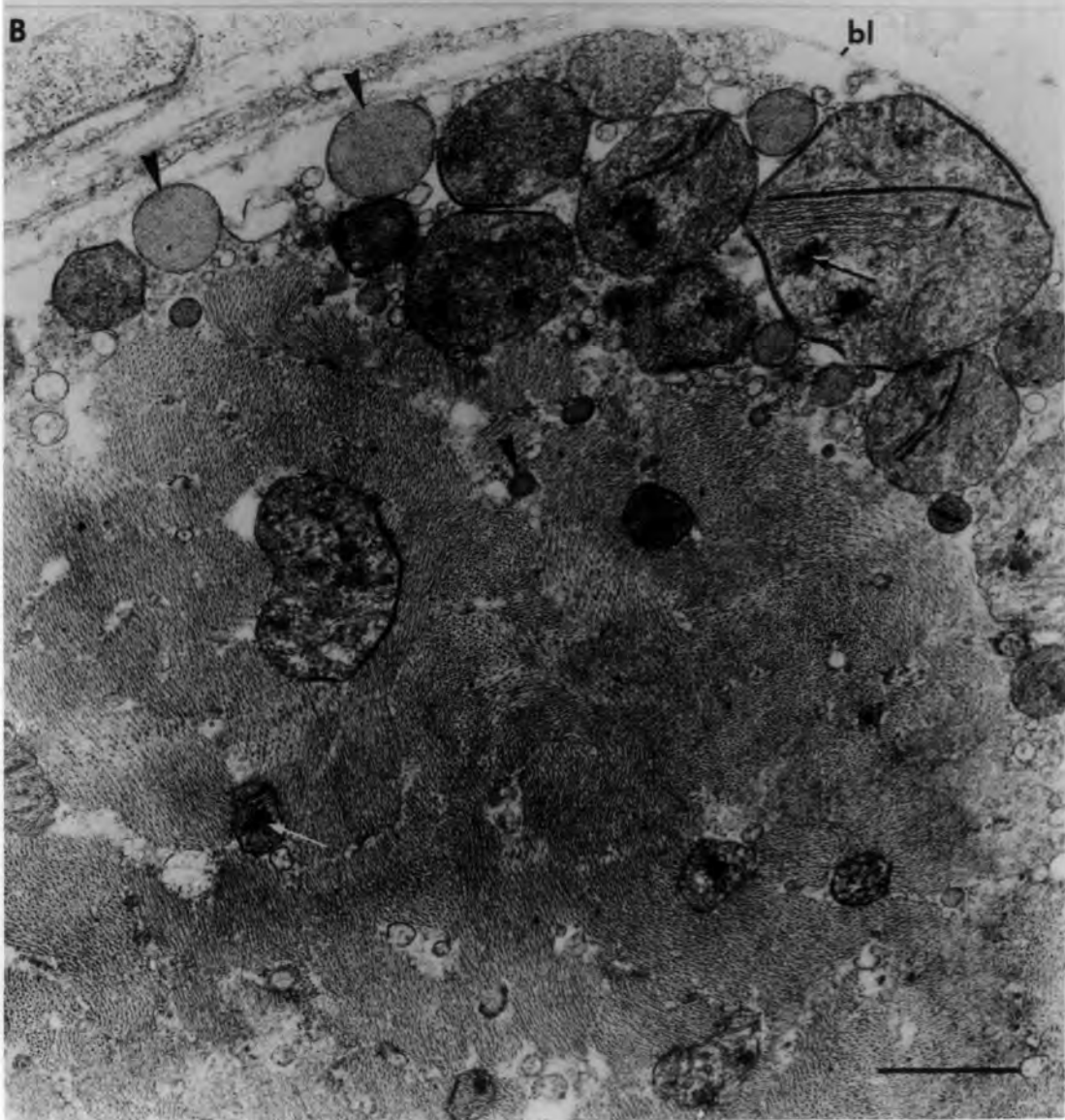


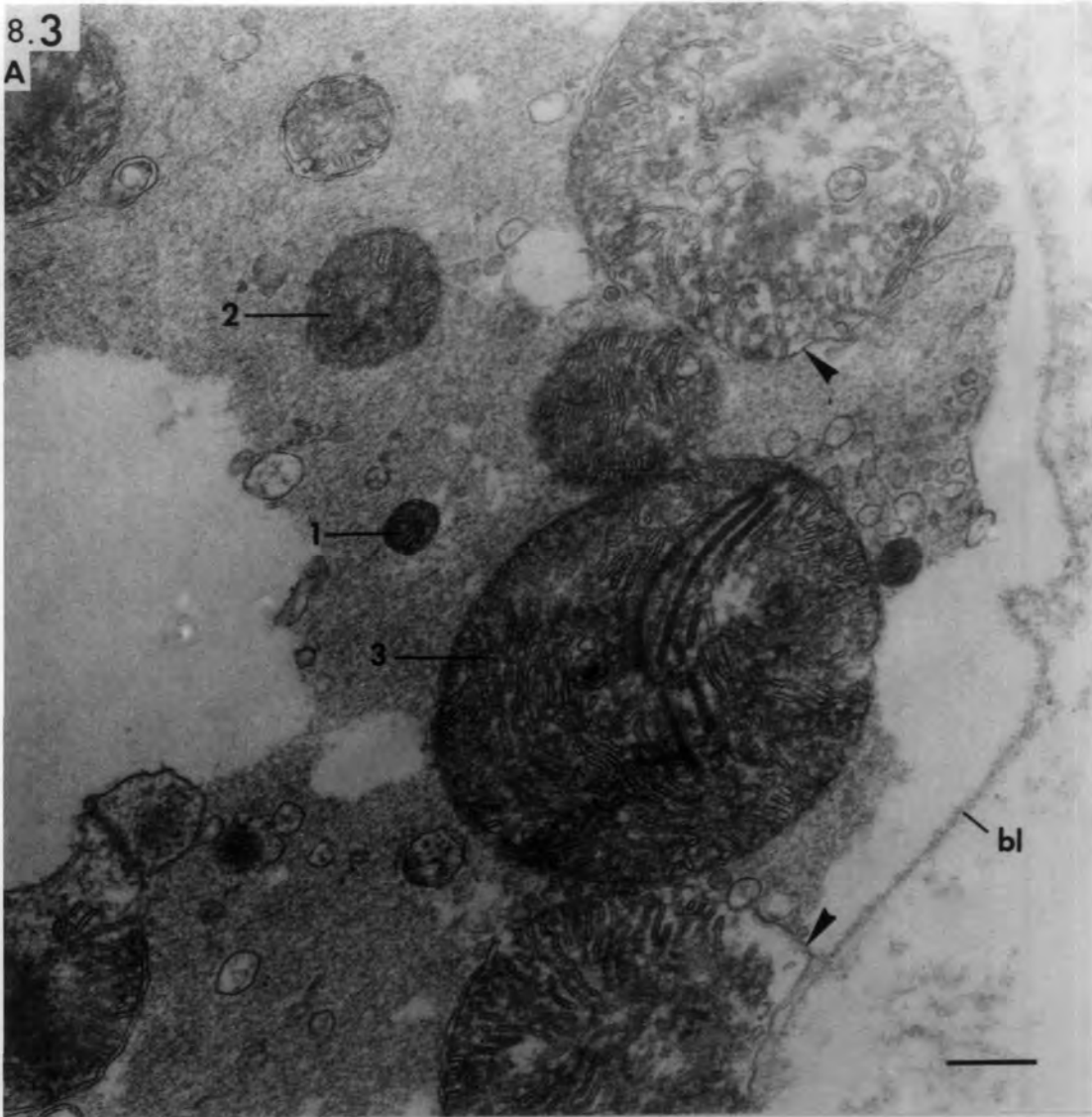
Fig. 8.3 Ischaemic muscle spindle 2 days after  
devascularization

Transverse section of degenerating intrafusal fibres showing size difference in mitochondria; (1)-normal, (2)-enlarged, and (3)-giant. The giant mitochondria in particular contain tubular (in A) and/or vesicular cristae (in B). Note the outer mitochondrial membrane is absent in places (arrow heads).

bars = 1 $\mu$ m

8.3

A



B

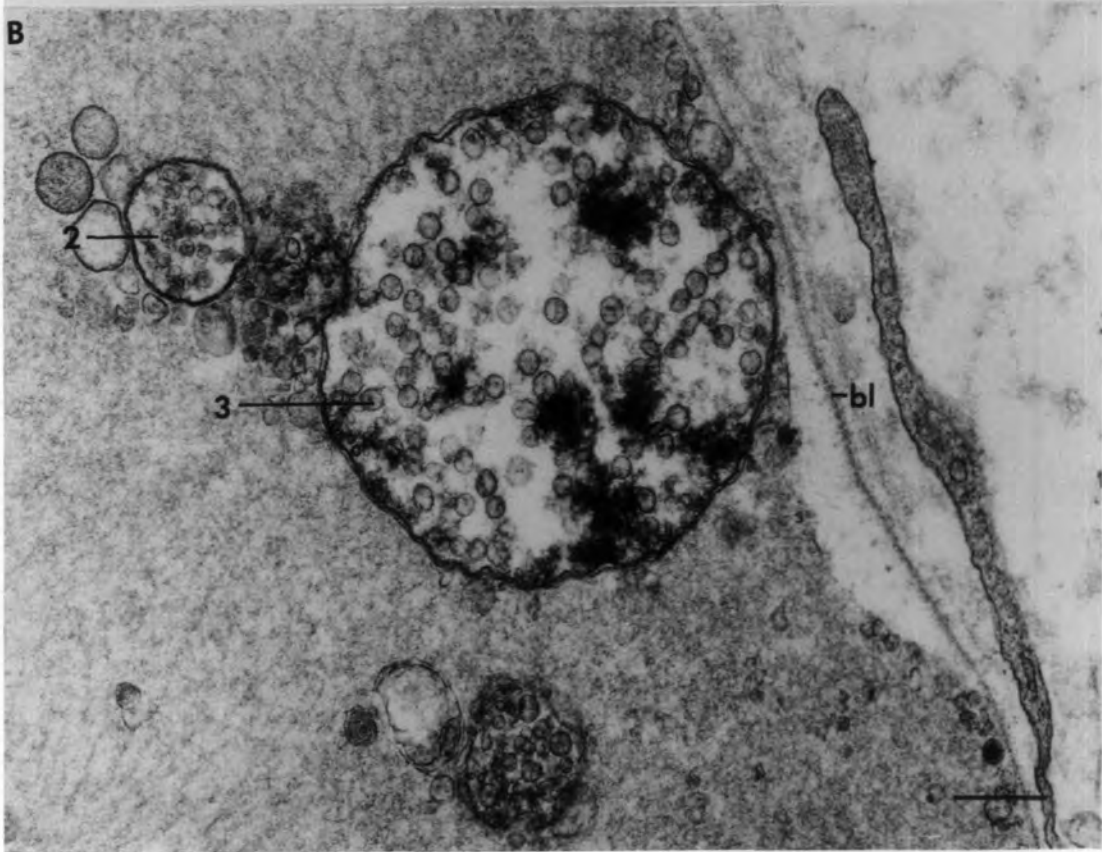


Fig. 8.4 Ischaemic muscle spindle 3 hours after  
devascularization

A. Transverse section at juxta-equatorial region of a spindle containing only two degenerating intrafusal fibres. Other fibres have already degenerated together with their basal laminae. A remnant of a basal-lamina tube (bl) is shown in this section.

ax: degenerating axon.

bar = 5 $\mu$ m

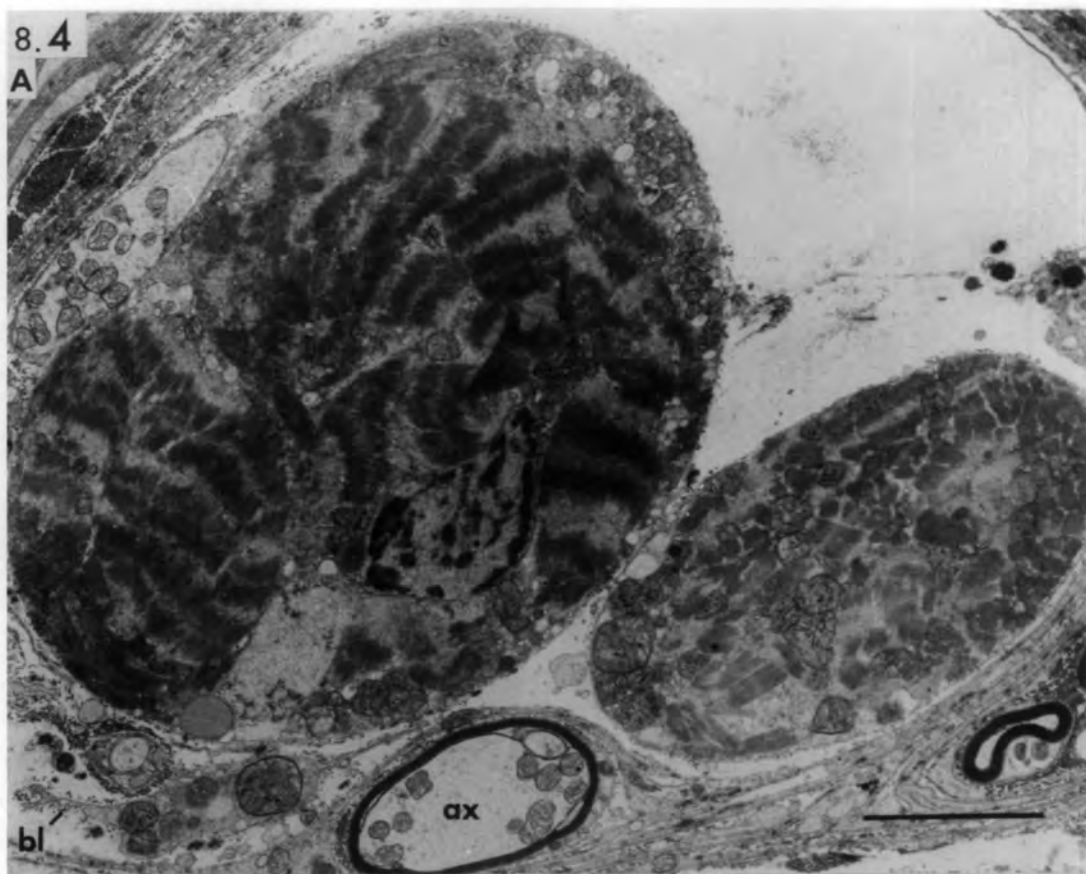B. Higher power to show mitochondrial, sarcoplasmic and myofibrillar changes.

Note the preserved capsule (cap).

bar = 1 $\mu$ m

8.4

A



B

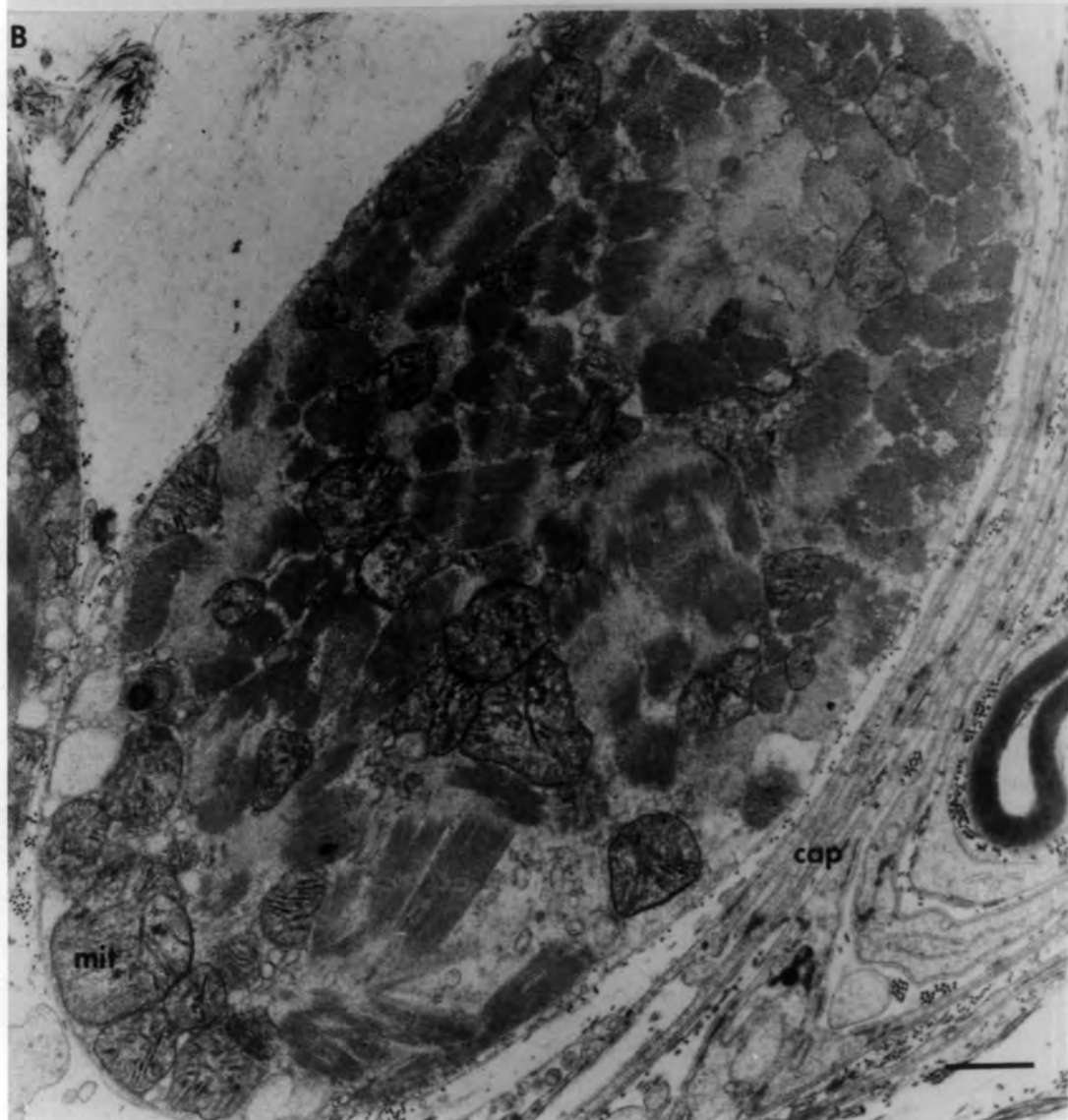

Fig. 8.5 Ischaemic muscle spindle 3 hours after devascularization.

Longitudinal section of two intrafusal fibres. Note the preserved sarcolemma in the left fibre (arrow) and the sarcolemma fragments (arrow) in the right fibre.

v: dilated subsarcolemmal vesicle.

Fig. 8.6 Ischaemic muscle spindle 6 hours after devascularization.

Transverse section of an intrafusal fibre undergoing hyaline degeneration. Its basal lamina is preserved (bl) whilst the sarcolemma (arrow) is reduced to an occasional strand.

Fig. 8.7 Ischaemic muscle spindle 3 hours after devascularization.

Transverse section of an intrafusal fibre showing early nuclear changes. The space between the outer and inner nuclear membrane is enlarged. The chromatin is condensed at the periphery.

Fig. 8.8 Ischaemic muscle spindle 12 hours after devascularization.

Transverse section of an intrafusal fibre showing a pyknotic nucleus in which the nuclear membrane is changed to tubules and vesicles, and the chromatin is condensed.

bars = 0.5 $\mu$ m

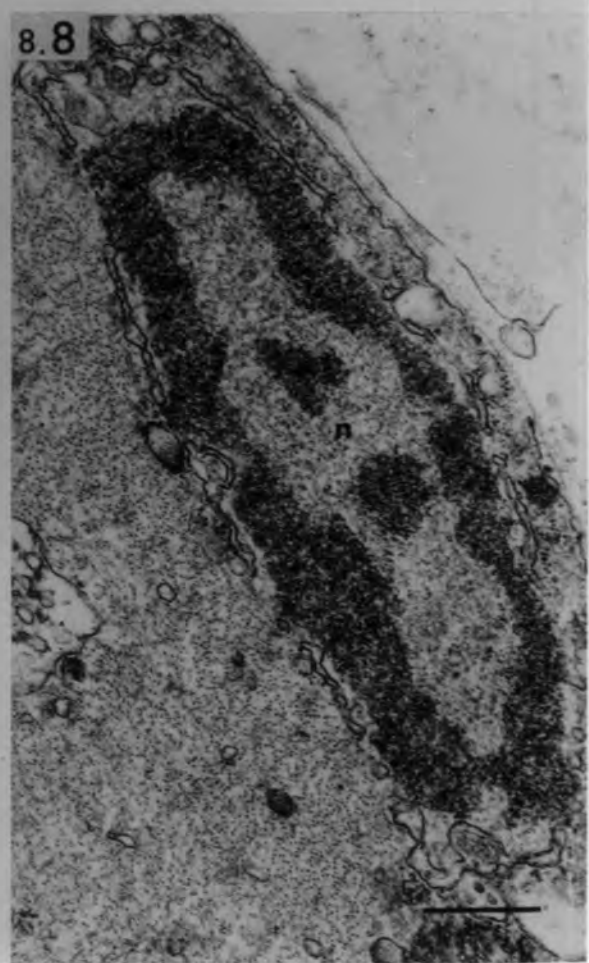
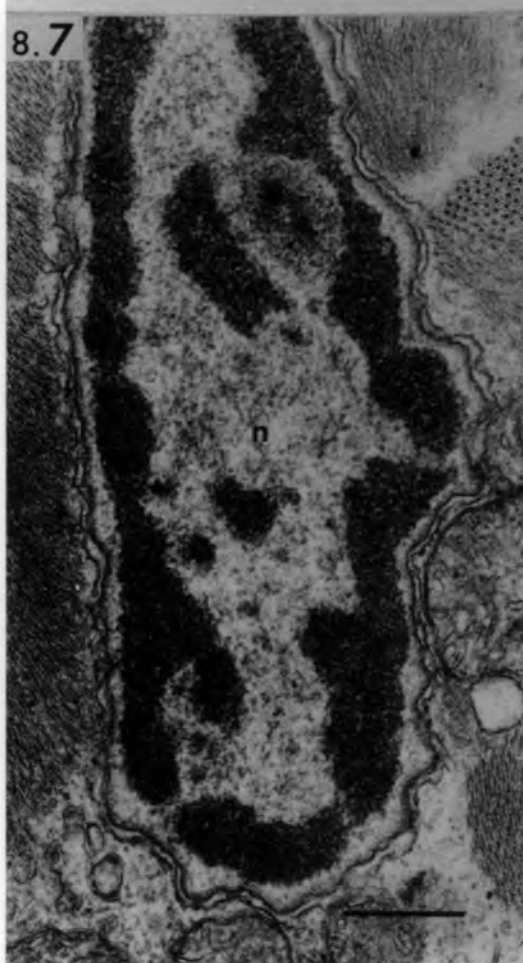
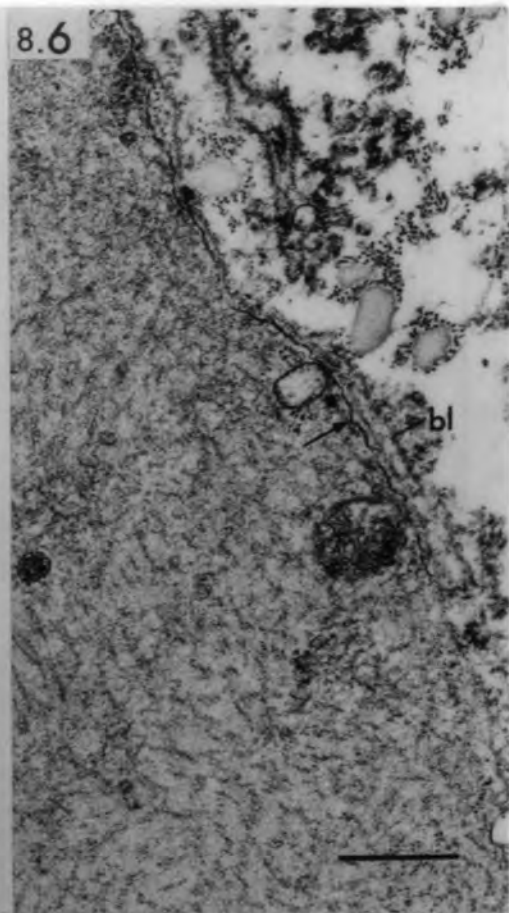
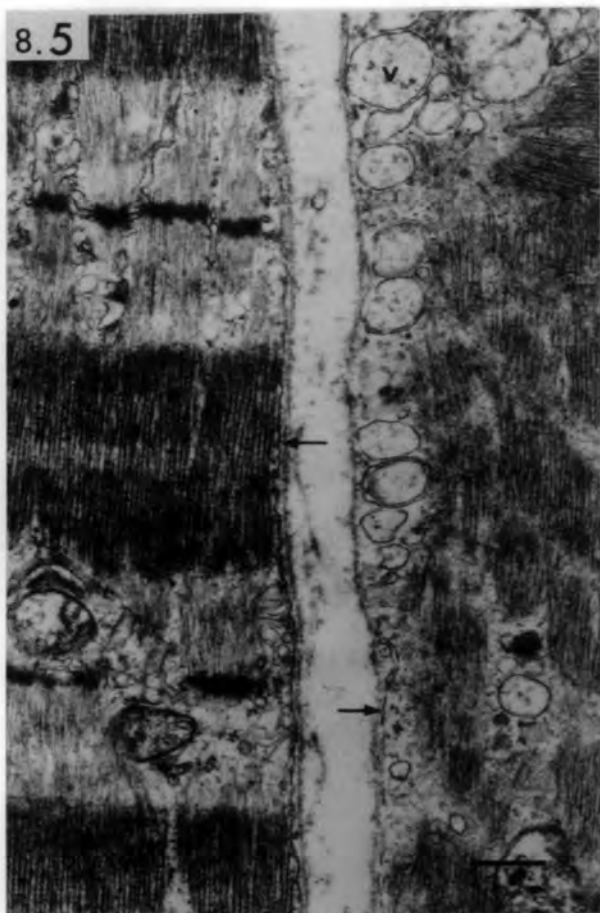


Fig. 8.9 Ischaemic muscle spindle 12 hours after devascularization.

Transverse section of the equatorial region of a bag fibre undergoing hyaline degeneration. Remnants of pyknotic equatorial nuclei (n) are present. The basal lamina is preserved while only fragments of underlying sarcolemma (arrow heads) are present. Dense mitochondria and autophagic vacuoles (asterisk) are present in the sensory terminal (snt). The axolemma is also fragmented. At the junction between the nerve and muscle cells, both the axolemma and sarcolemma may be absent (arrows).

Fig. 8.10 Ischaemic muscle spindle 12 hours after devascularization.

Transverse section of the equatorial region of a severely-affected bag fibre in which only the sarcolemma (arrow heads) is still intact as well as the basal-lamina tube.

The nuclear-bag fibres in Figs. 8.9 & 8.10 are from the same spindle.

bars = 1µm

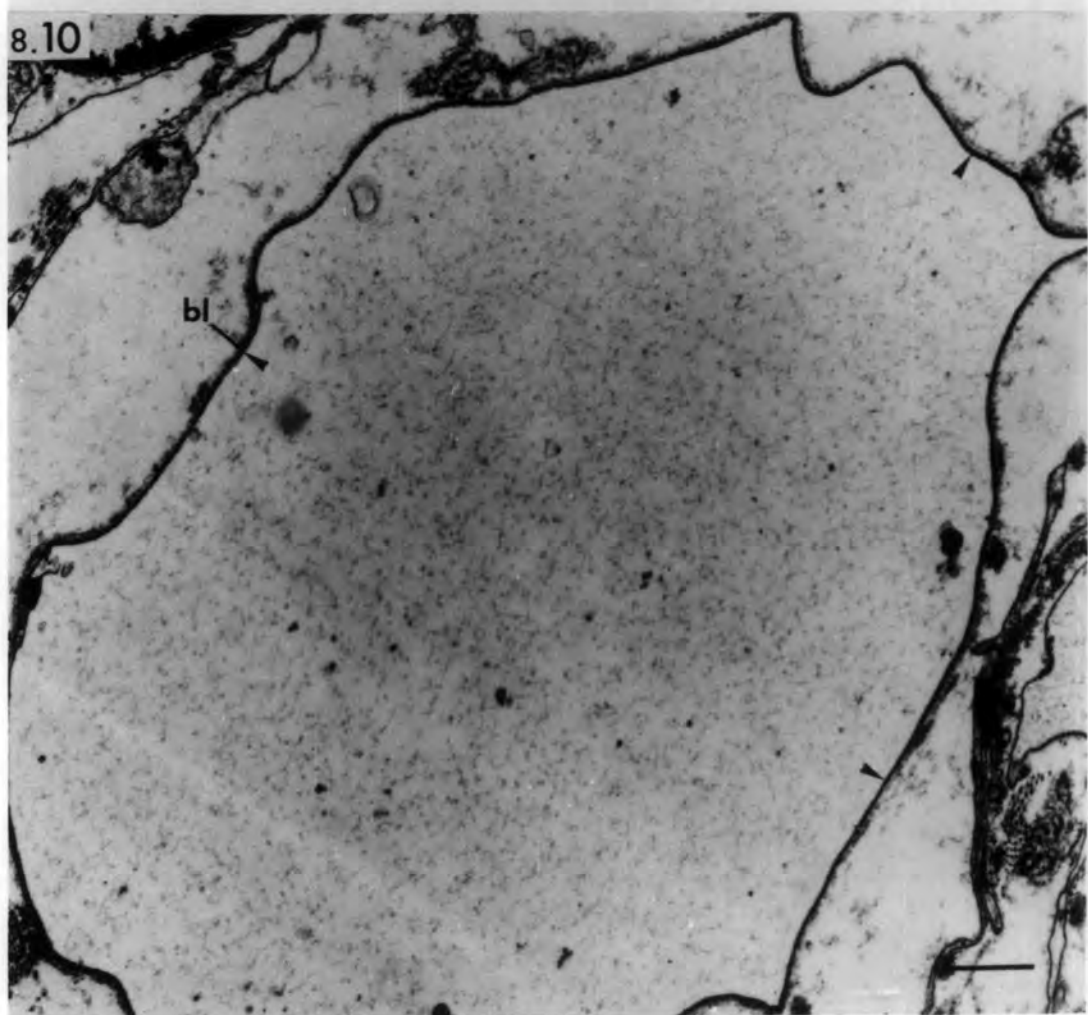
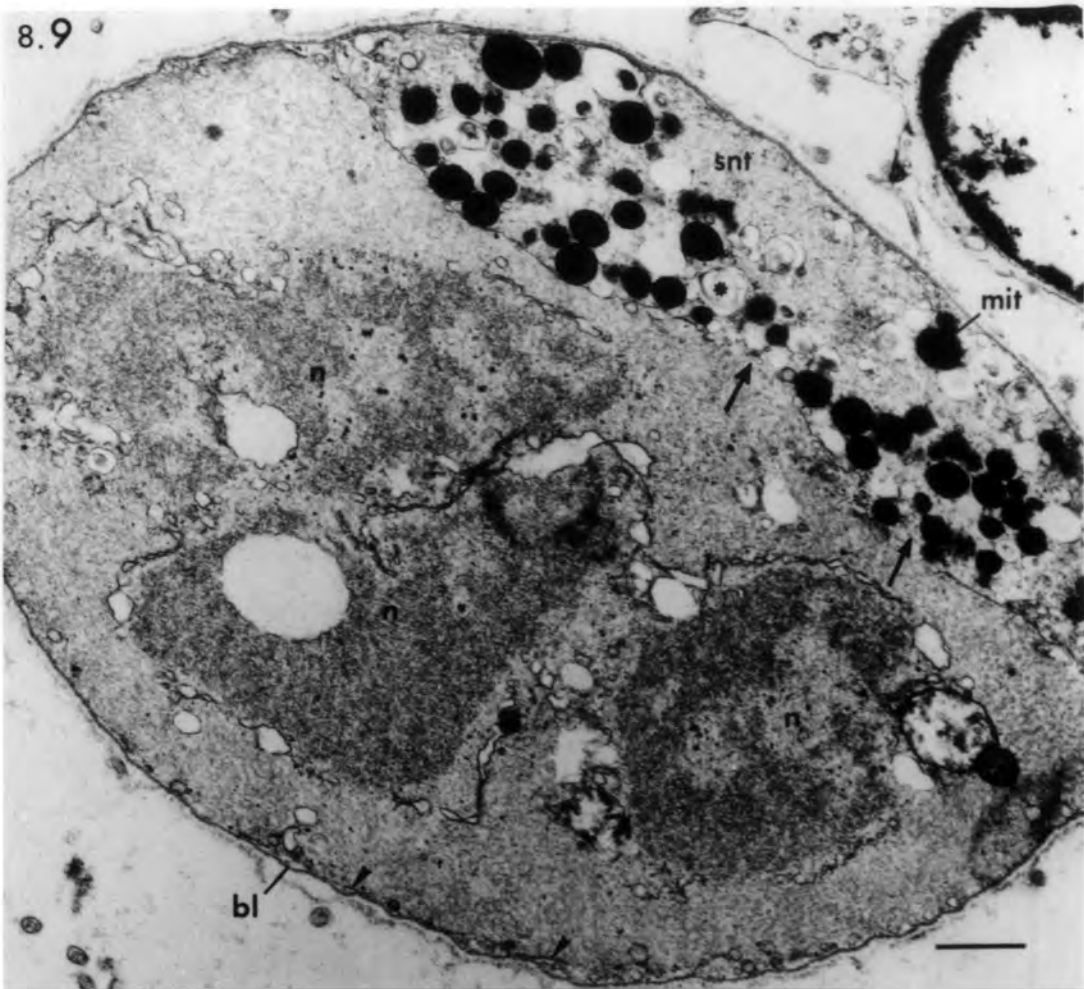


Fig. 8.11 Ischaemic muscle spindle 1 day after devascularization.

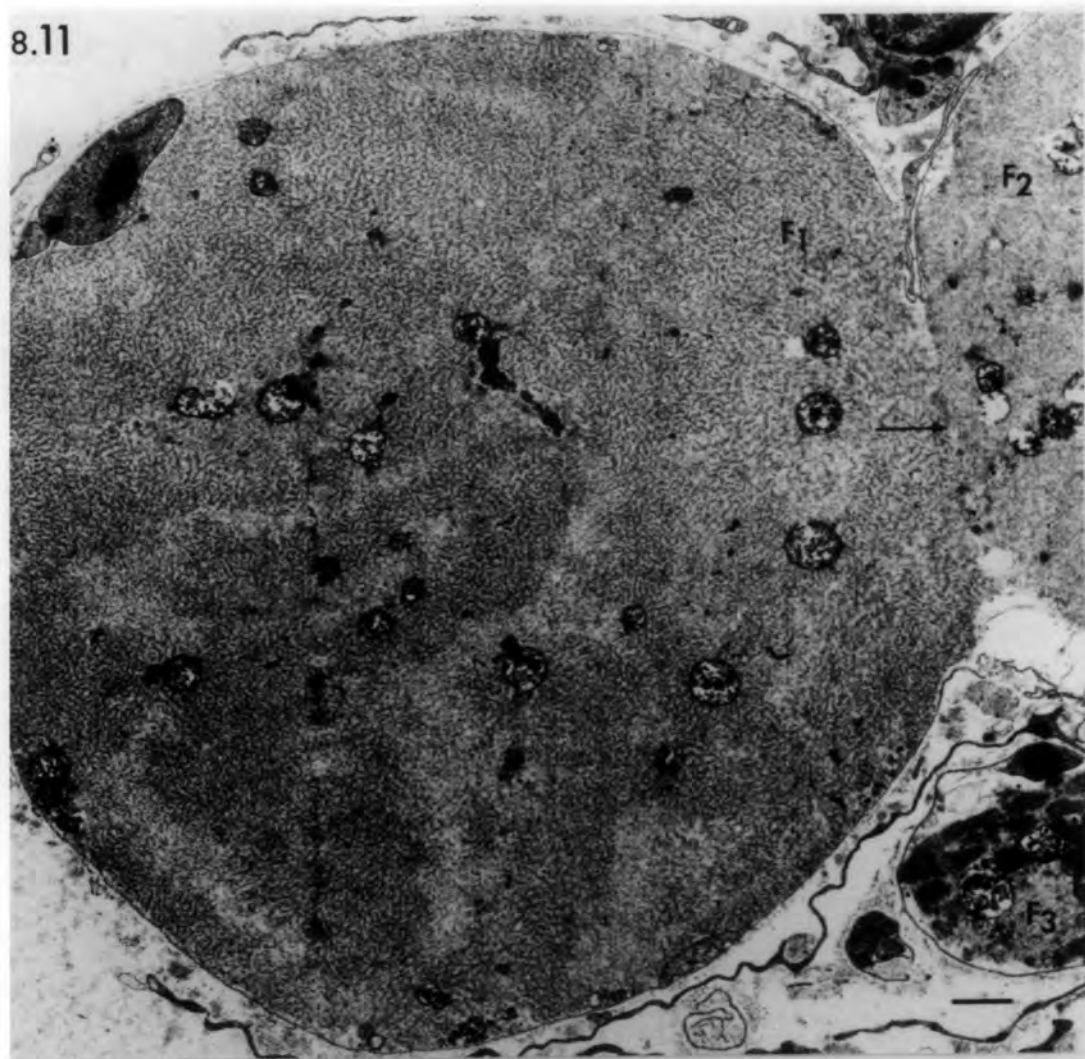
Transverse section of the equatorial region showing two closely-apposed bag fibres ( $F_1$  &  $F_2$ ) undergoing hyaline degeneration. Their sarcoplasm is mixed (arrow), where the interposing sarcolemma is absent. A less-affected chain fibre ( $F_3$ ) is also present.

Fig. 8.12 Ischeamic muscle spindle 1 day after devascularization.

Transverse section of a hyalinized intra-fusal fibre in which the original architecture of the myofilaments may still be recognized (**Z**).

bars =  $1\mu\text{m}$

8.11



8.12

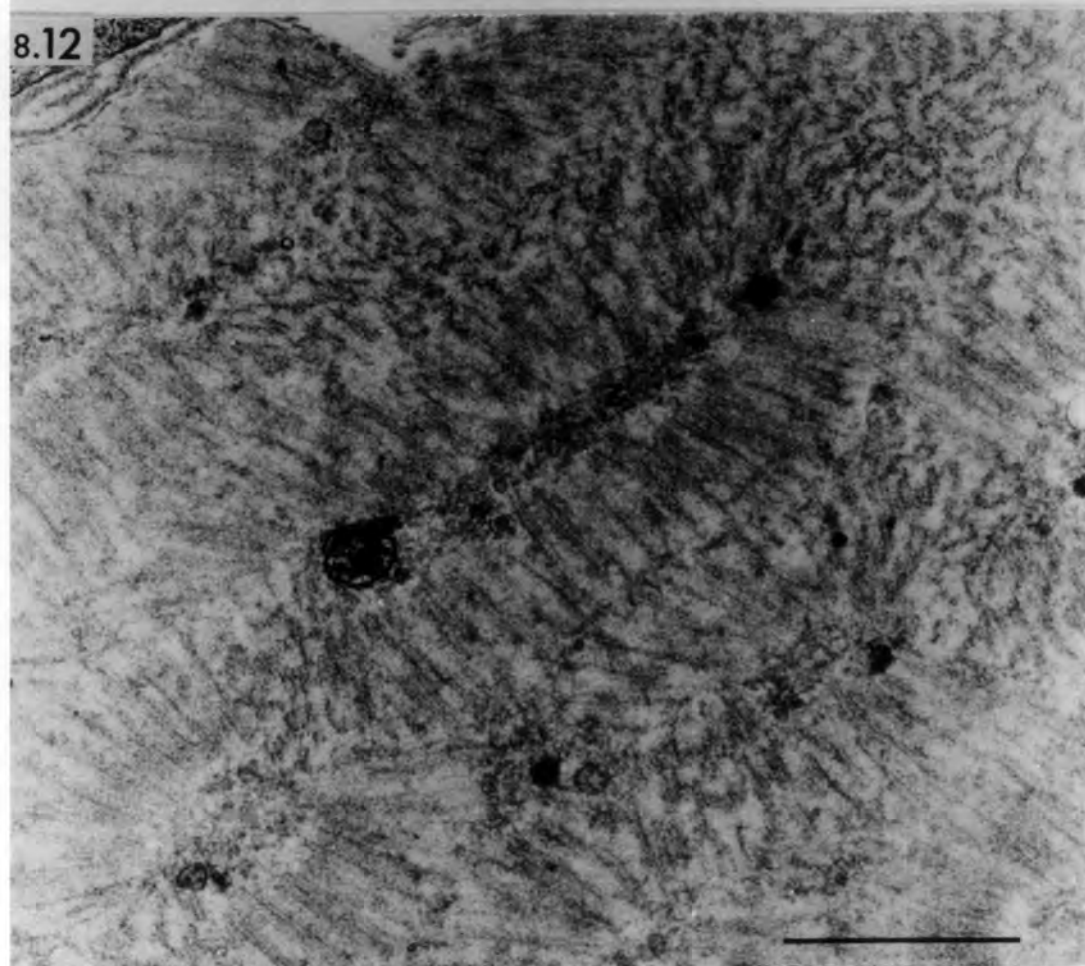


Fig. 8.13 Ischaemic muscle spindle 2 days after  
devascularization.

Transverse section of the equatorial region showing a less-affected chain fibre. An invading macrophage (mac) encloses the fibre, pushing the sensory terminal toward the centre. Arrow points to a strand of sarcolemma.

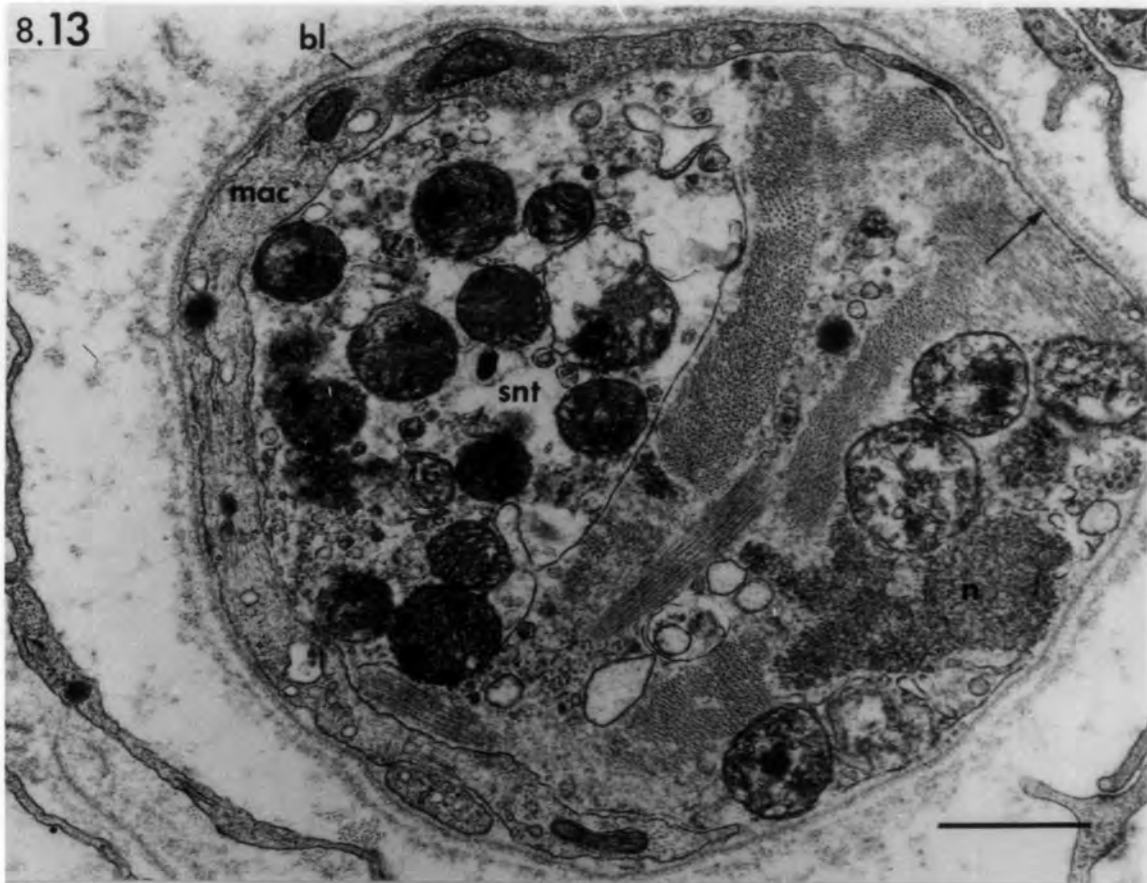
bar = 1 $\mu$ m

Fig. 8.14 Ischaemic muscle spindle 1 day after  
devascularization.

Transverse section of the extracapsular polar region of bag<sub>1</sub> and bag<sub>2</sub> fibres. Myofilaments may still be recognized in the bag<sub>1</sub> fibre.

bar = 4 $\mu$ m

8.13



8.14

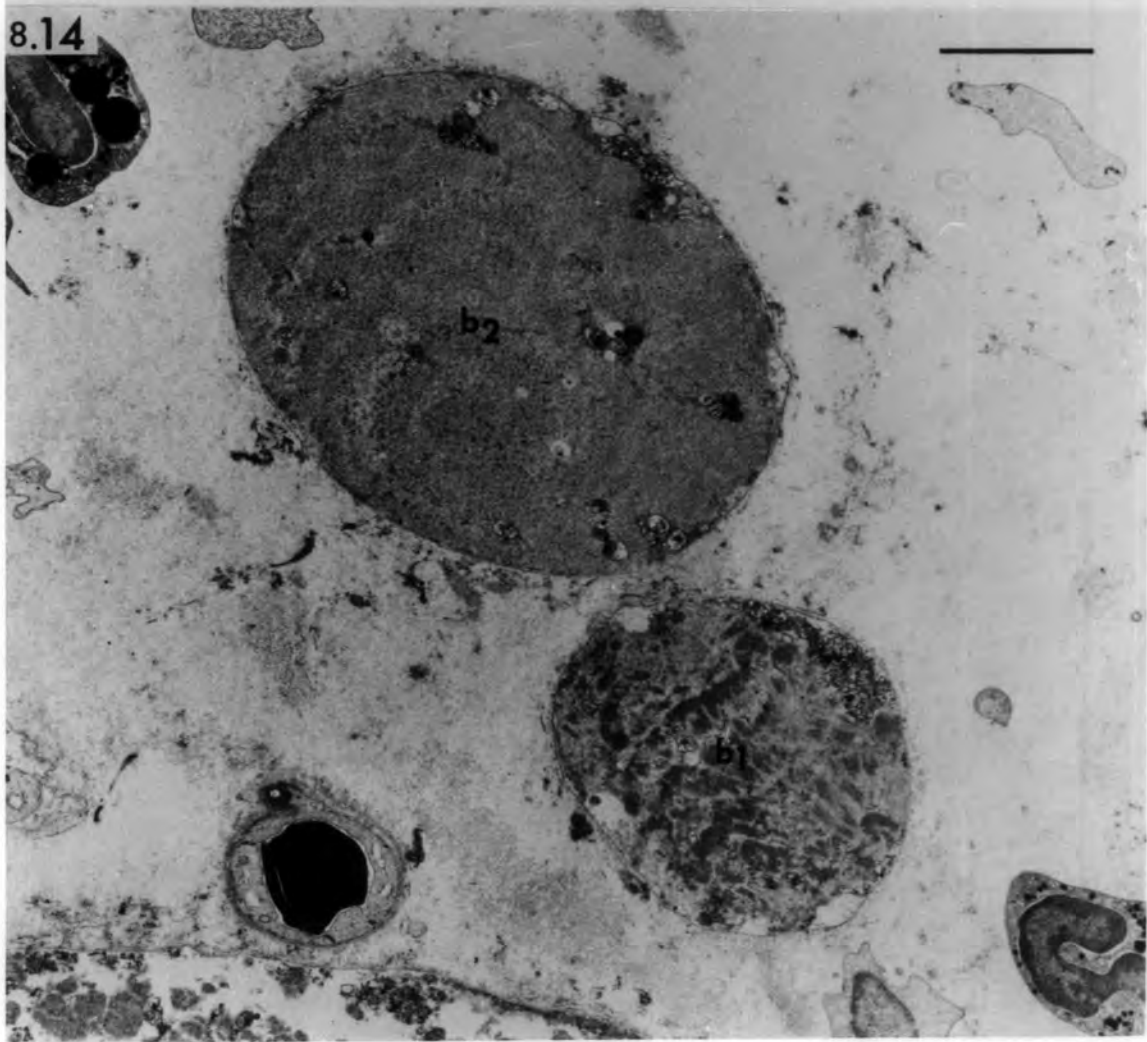


Fig. 8.15 Ischaemic muscle spindle 2 days after devascularization.

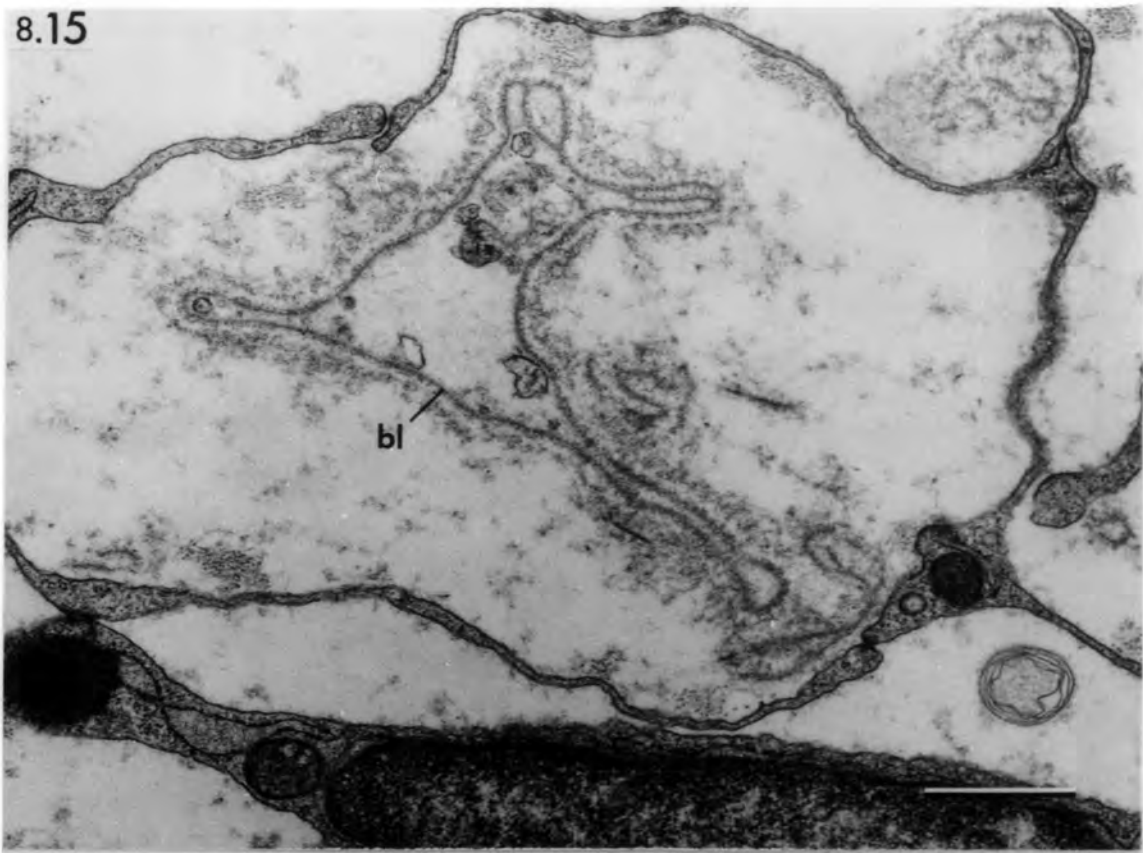
Transverse section of the equatorial region showing an empty, folded tube of basal lamina of a degenerated intrafusal fibre.

Fig. 8.16 Ischaemic muscle spindle 2 days after devascularization.

Transverse section of the equatorial region showing a basal-lamina tube containing remnants of a degenerating intrafusal fibre. A degenerating axon is engulfed by Schwann cells.

bars = 1 $\mu$ m

8.15



8.16

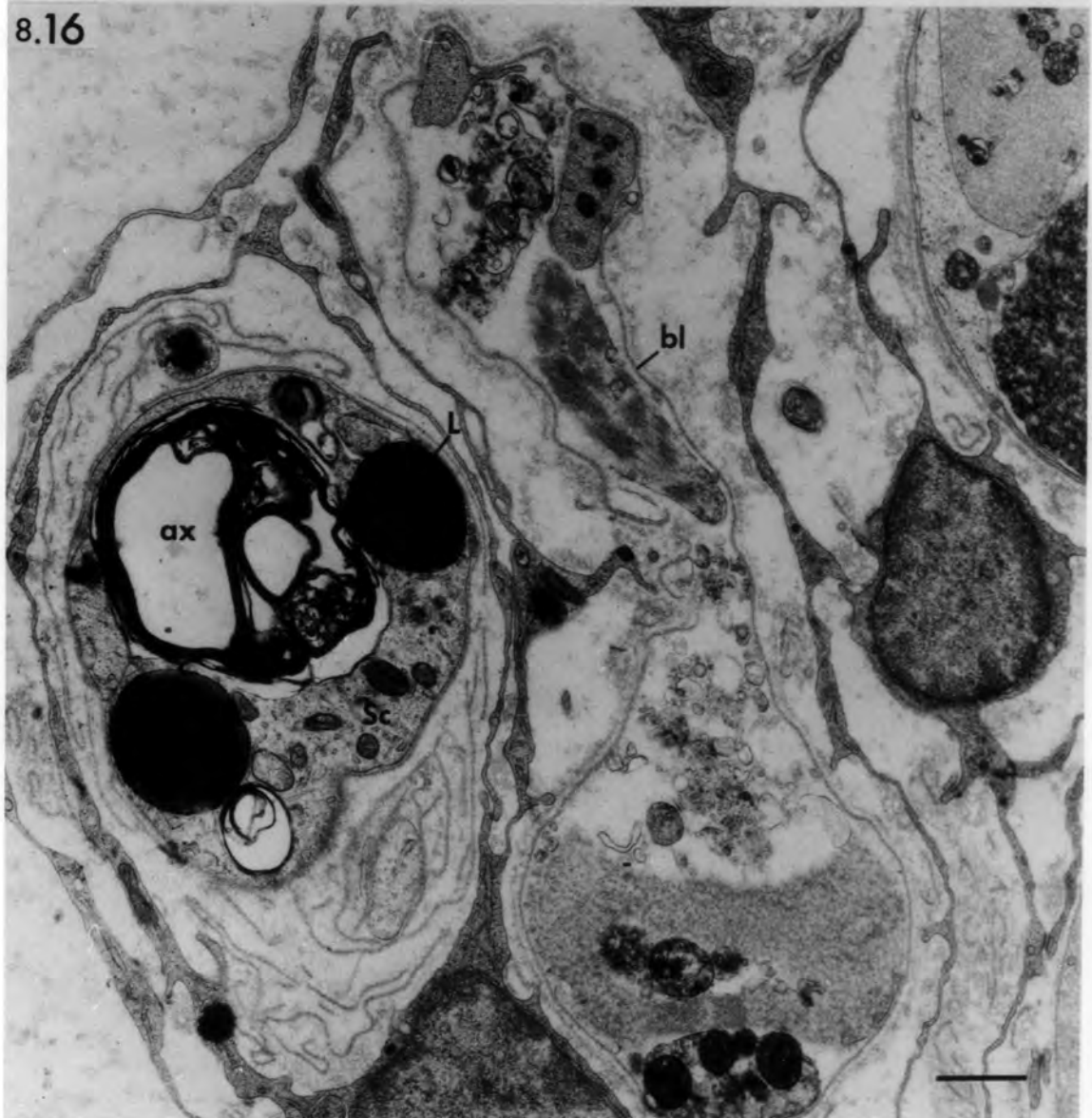


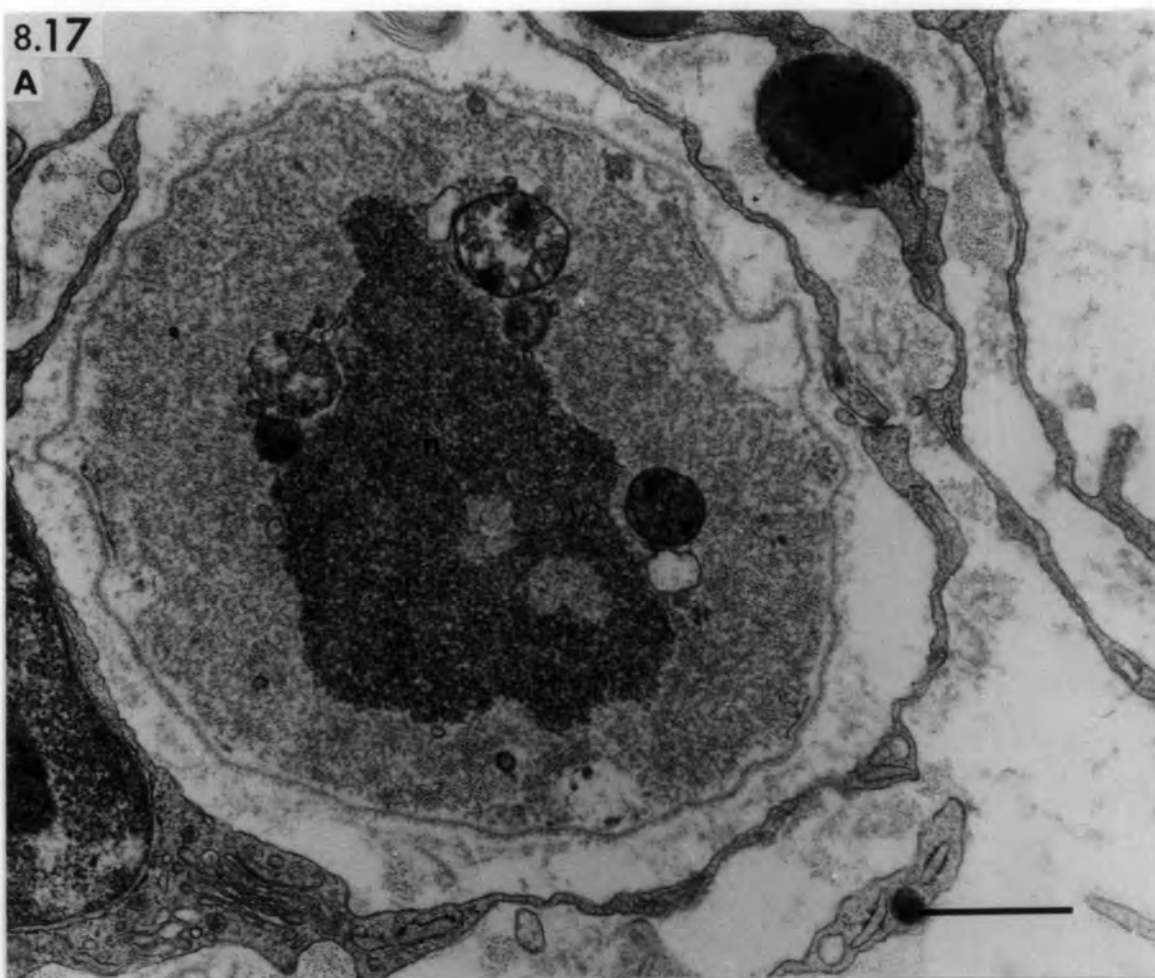
Fig. 8.17 Ischaemic muscle spindle 2 days after  
devascularization.

Transverse section of the equatorial region of degenerating chain (A) and bag (B) fibres. Remnants of the equatorial nuclei (n) are present in both fibres. The chromatin is changed to a dense granular substance and the nuclear membranes are either absent (as in A) or reduced to tubules, vesicles or vacuoles (arrows).

bar = 1µm

8.17

A



B

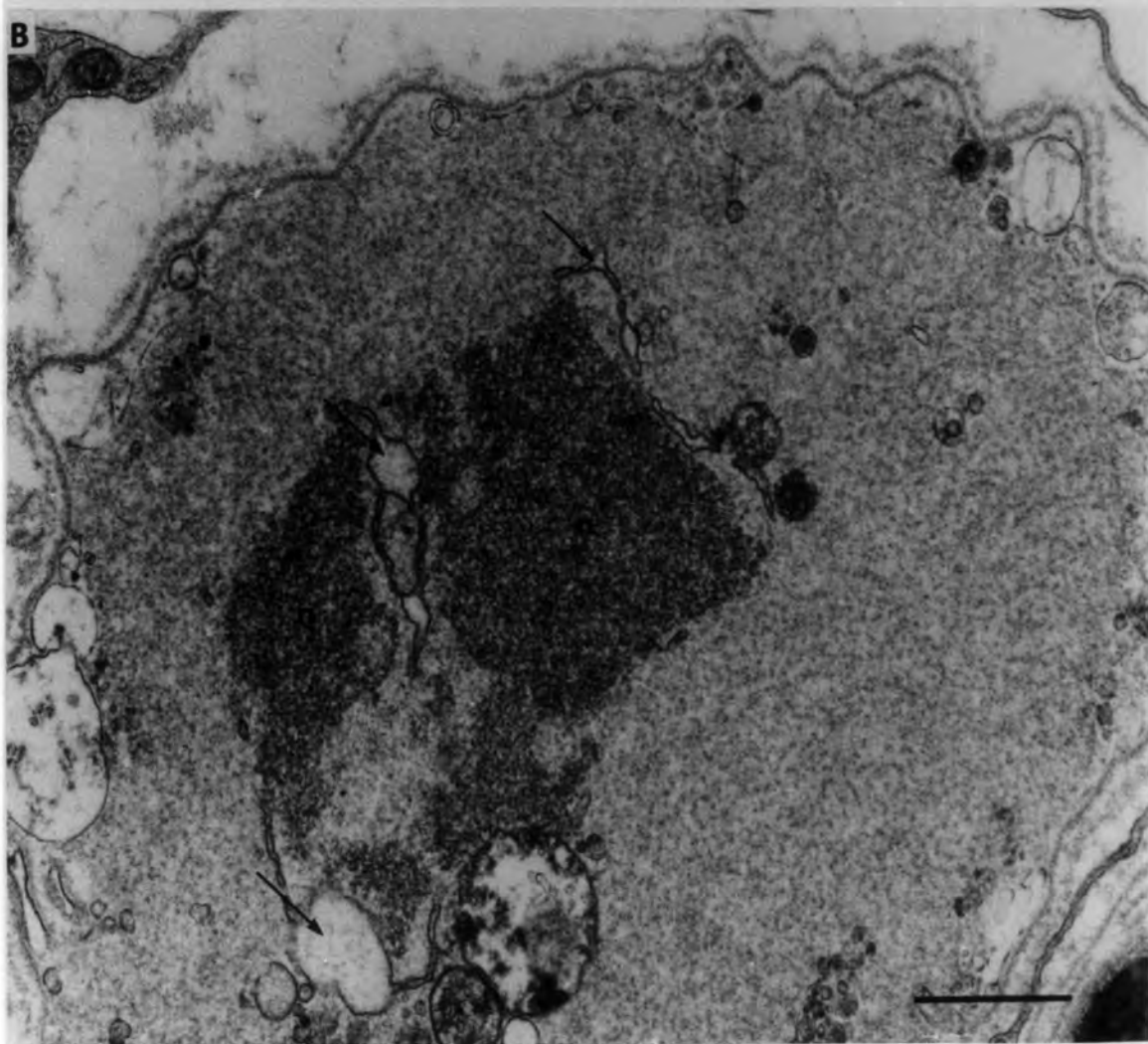


Fig. 8.18 Ischaemic muscle spindle 2 days after  
devascularization.

Transverse section of the equatorial region of a degenerating intrafusal fibre. The hyaline sarcoplasm is enclosed by preserved basal lamina and contains degenerating mitochondria (mit). Remnants of a sensory nerve terminal are present (snt). Arrow heads point to vesicles and vacuoles of sarcoplasmic origin. Arrows point to sarcolemmal fragments.

Fig. 8.19 Ischaemic muscle spindle 2 days after  
devascularization.

Transverse section of extracapsular polar region of a hyalinized intrafusal fibre. Bundles of fibrin threads (f) are attached to the external surface of the basal lamina.

bars = 1 $\mu$ m

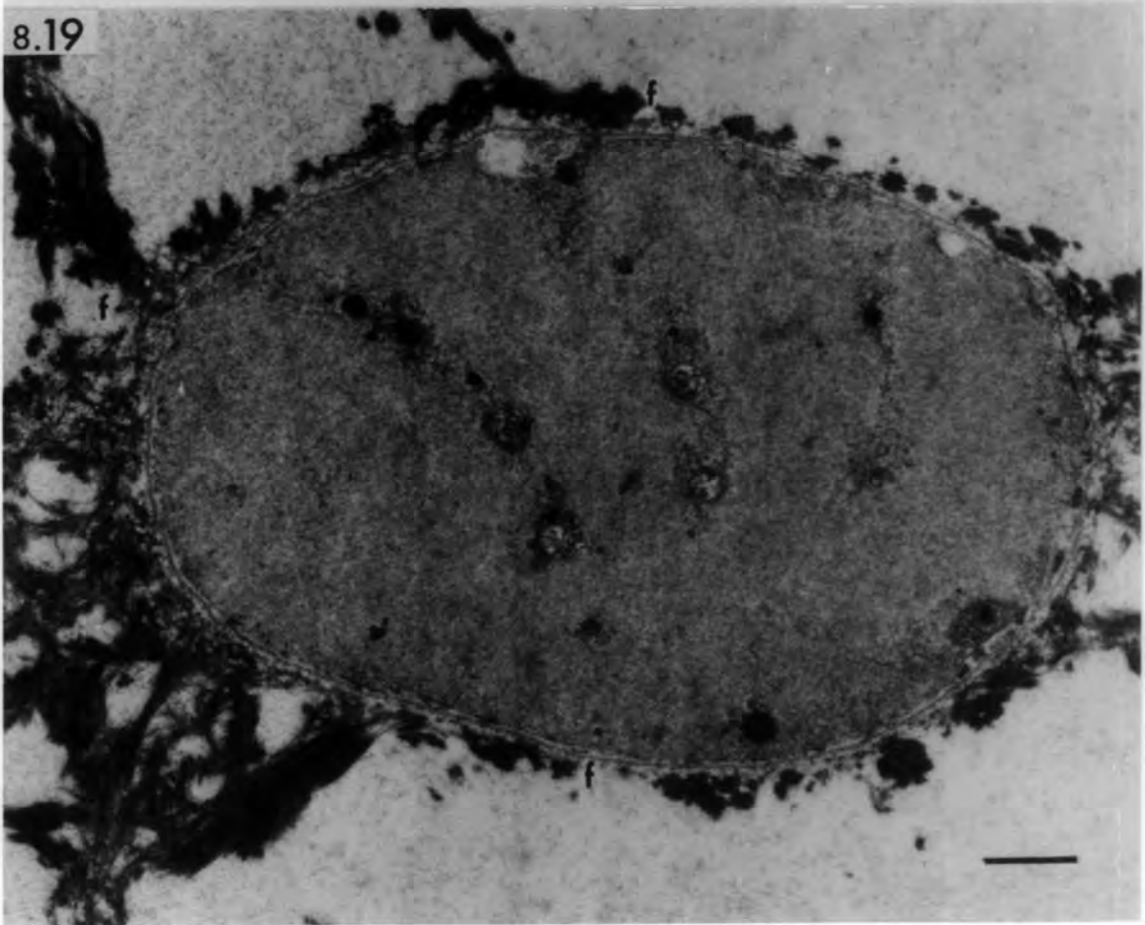
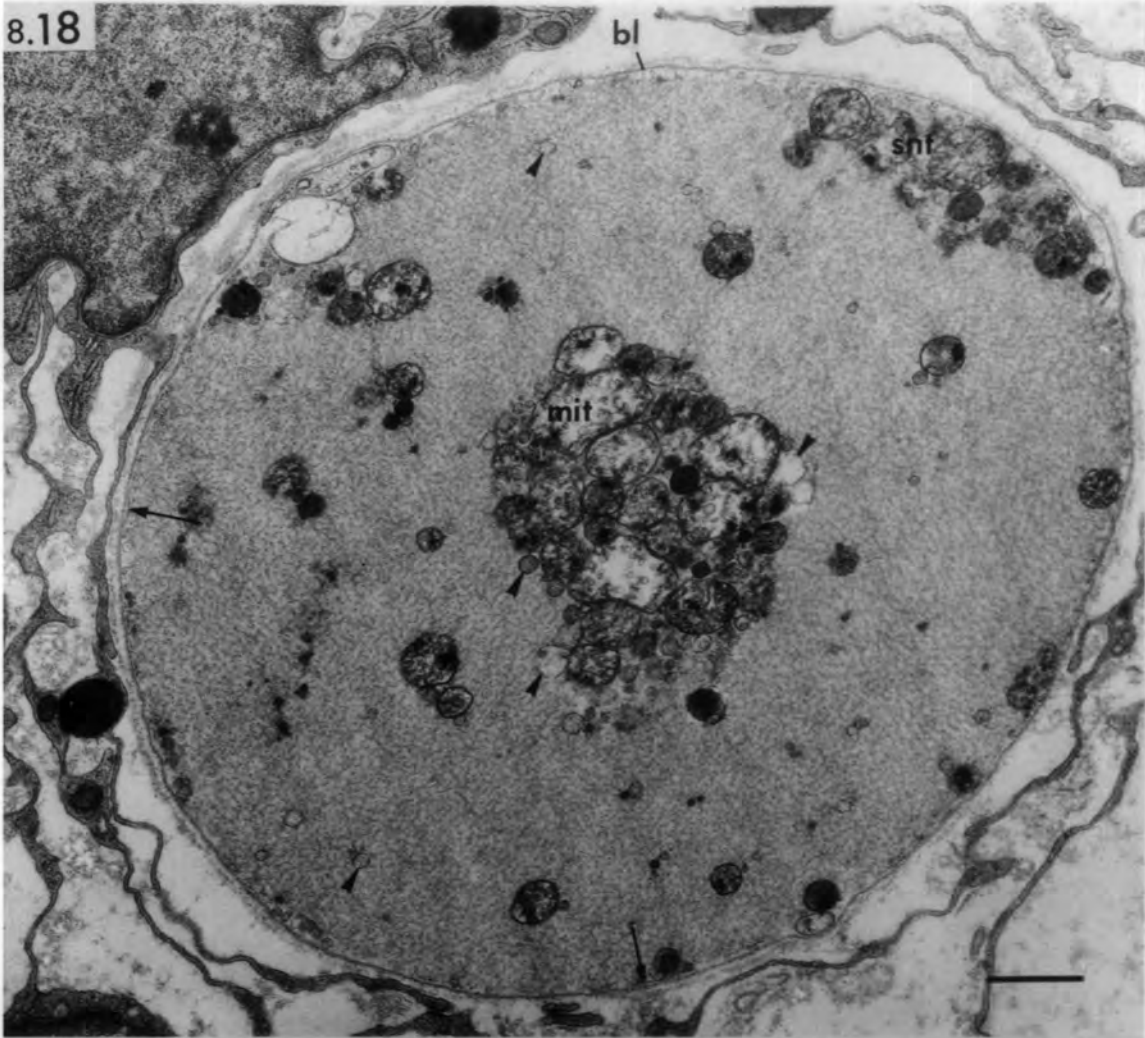


Fig. 8.20 Ischaemic muscle spindle 3 days after  
devascularization.

Transverse section of the equator region showing degenerating intrafusal fibres invaded by phagocytes. Activated satellite cells (sat) are present at the periphery.

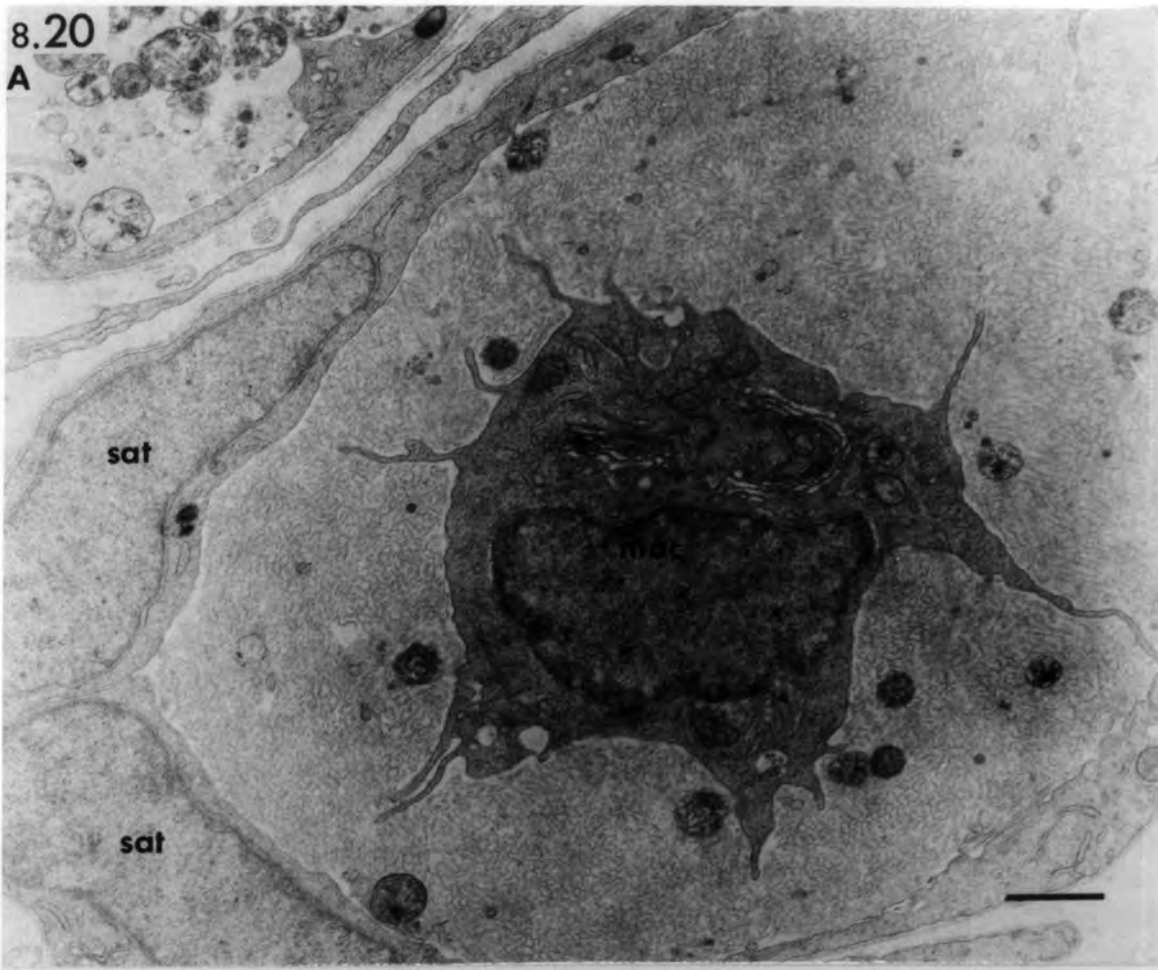
In A, a macrophage (mac) engulfs the  
hyaline sarcoplasm.

In B, a leucocyte (lc) has invaded the  
fibre.

bar = 1µm

8.20

A



B

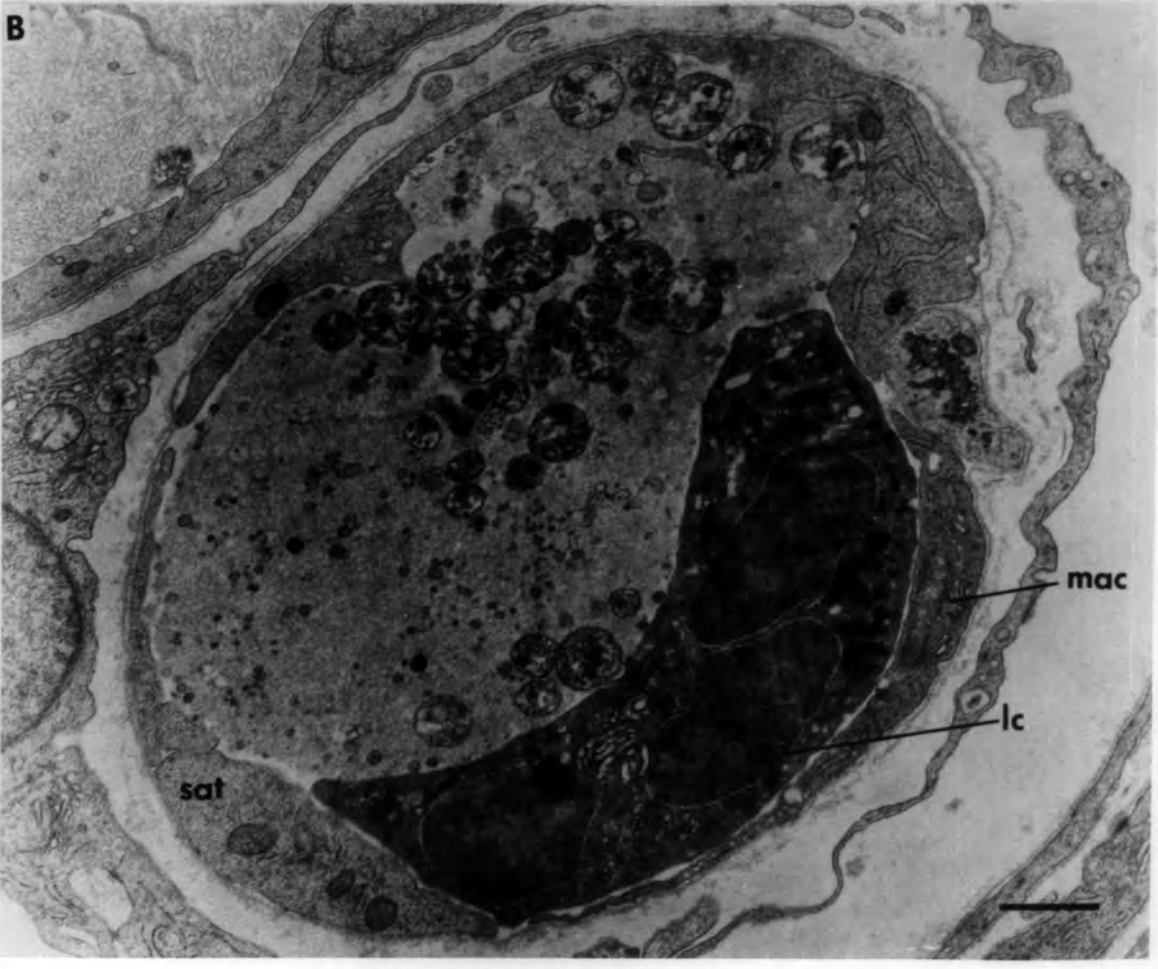


Fig. 8.21 Transverse sections of normal and ischaemic intrafusal fibres illustrating changes in satellite cells.

- A. Normal satellite cell with high nucleocytoplasmic ratio. Note the paucity of organelles in the cytoplasm.
- B. Ischaemic intrafusal fibre 12 hours after devascularization. Note the dense nucleus of the satellite cell.
- C. Ischaemic intrafusal fibre 12 hours after devascularization. Note the relative increase in the cytoplasm of the satellite cell and the lipid droplet (L).
- D. Ischaemic intrafusal fibre 2 days after devascularization. The satellite cell is activated; its abundant cytoplasm contains numerous ribosomes (arrow head) and an extensive Golgi apparatus (arrow). The nucleus is of normal appearance and contains two nucleoli.

bars = 1 $\mu$ m

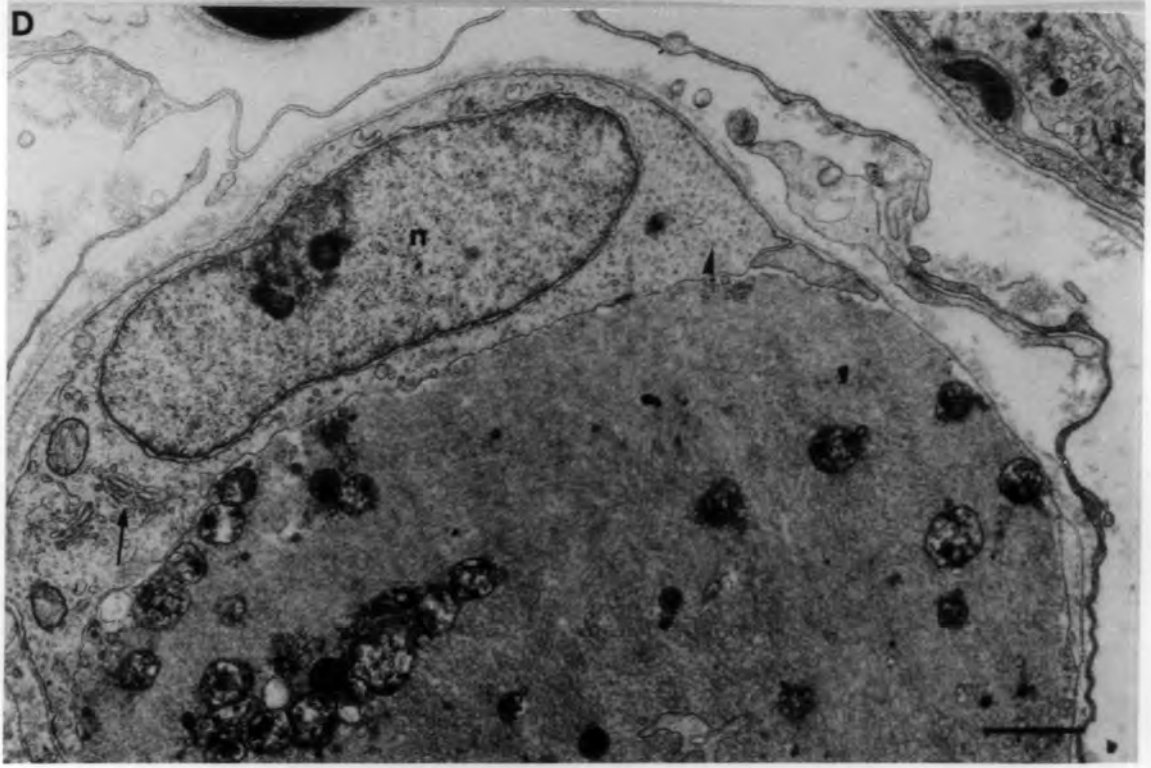
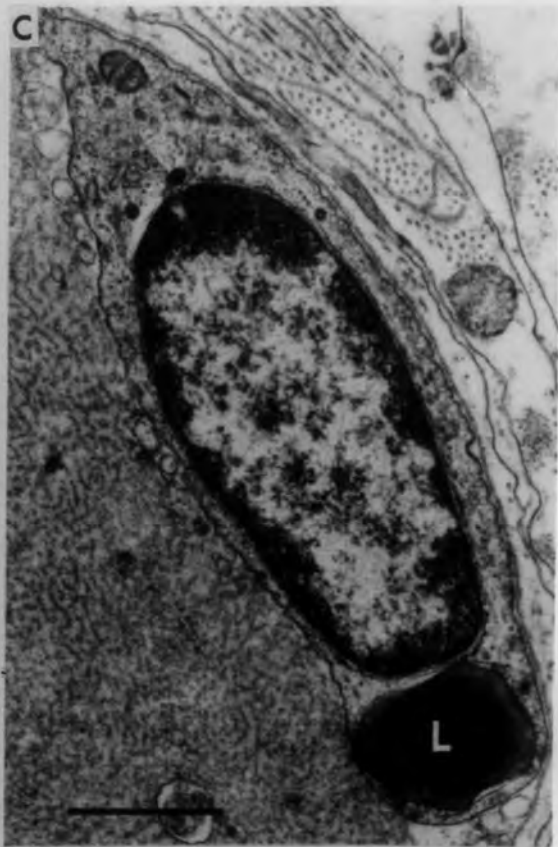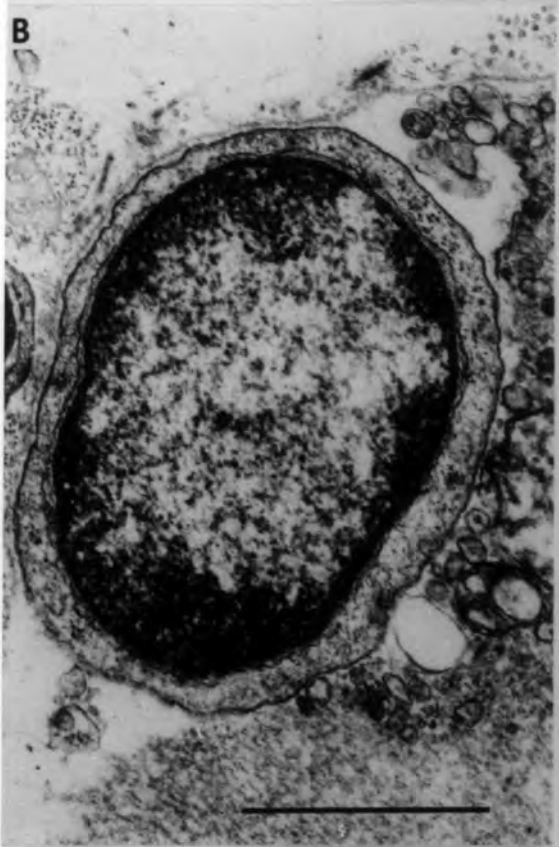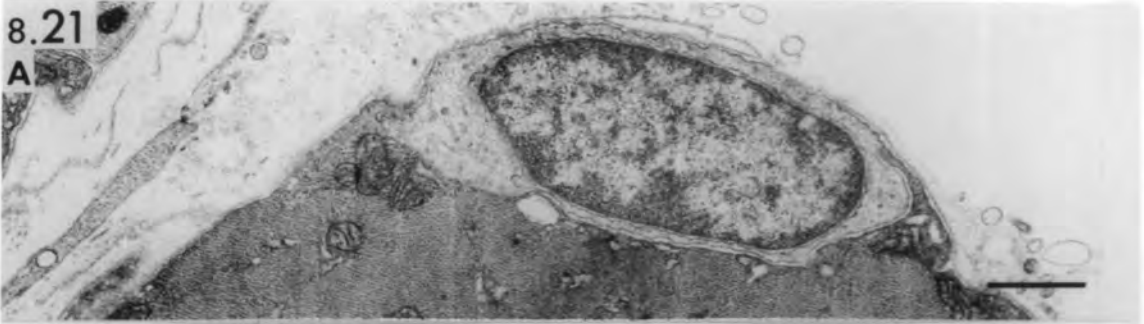


Fig. 8.22 Ischaemic muscle spindle 3 hours after  
devascularization.

Transverse section of the equatorial region of a chain fibre showing two degenerating sensory terminals which contain swollen mitochondria. The cristae are normal and the mitochondria disrupted. The axolemma (arrows) is fragmented.

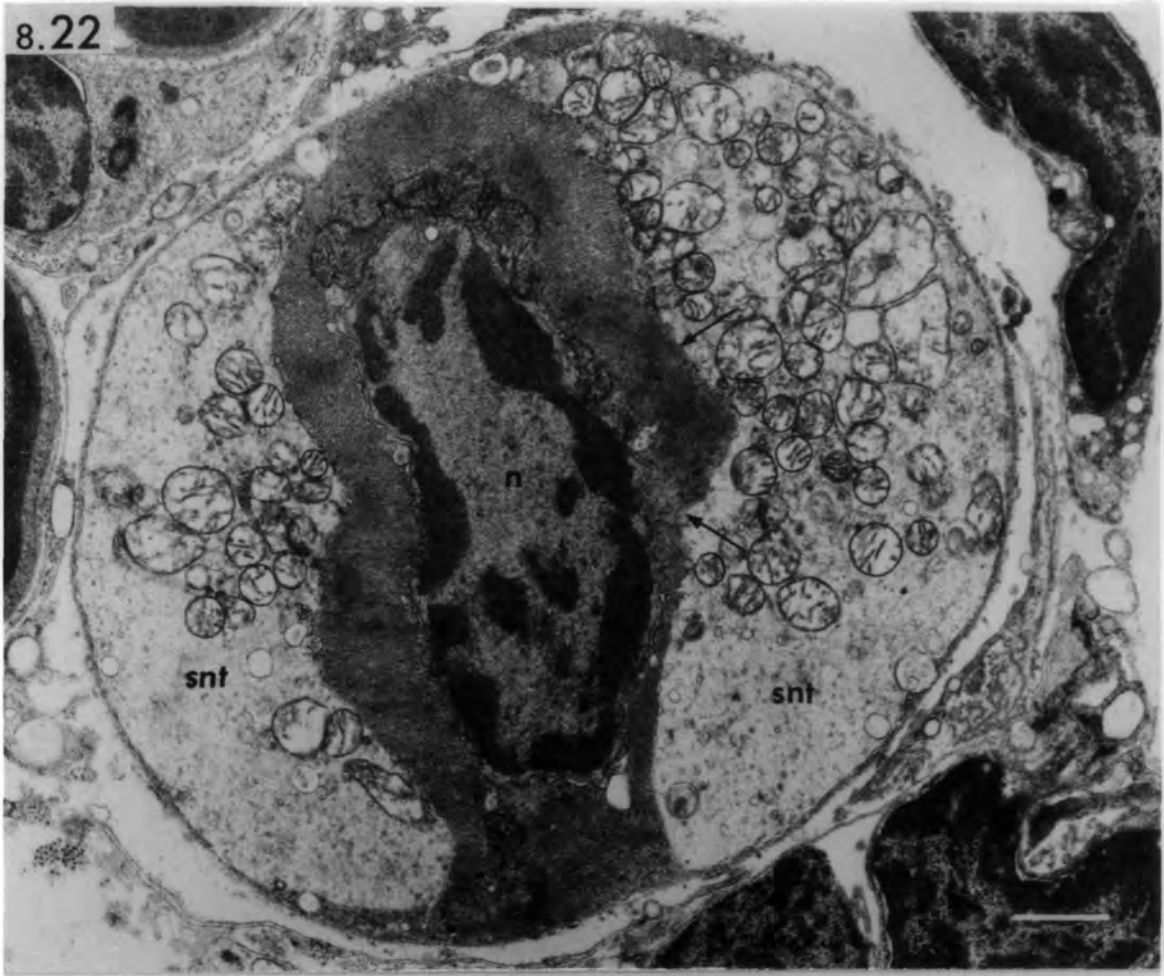
Fig. 8.23 Ischaemic muscle spindle 6 hours after  
devascularization.

Transverse section of the equatorial region of an intrafusal fibre showing a degenerating sensory nerve terminal which contains dense and swollen mitochondria with tubular, vesicular and granular contents. The axolemma is absent in places (arrows) at the neuromuscular junction. Arrow head points to a dense osmiophilic body.

Asterisk: autophagic vacuole.

bars = 1 $\mu$ m

8.22



8.23

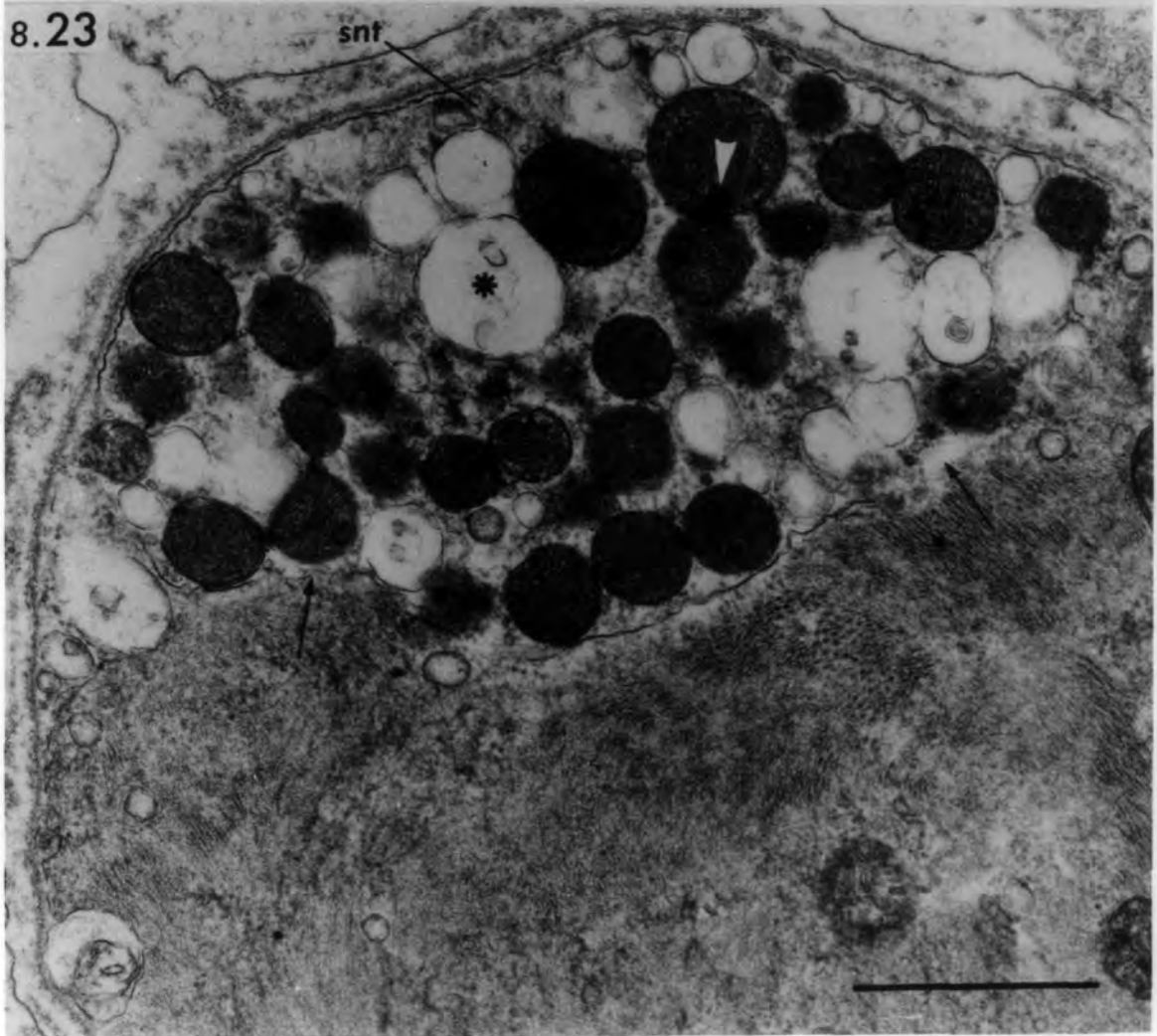


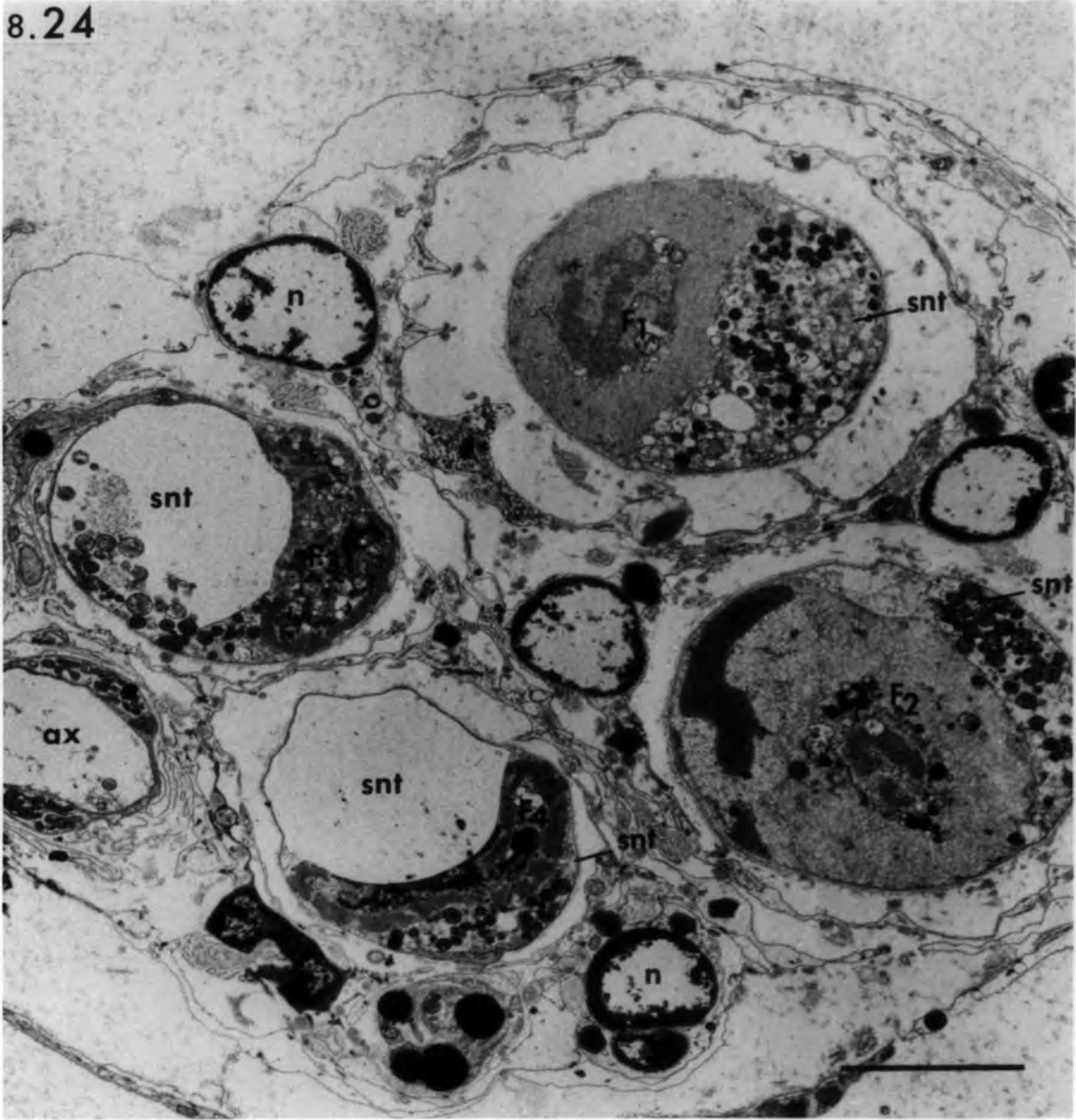
Fig. 8.24 Ischaemic muscle spindle 12 hours after  
devascularization.

Transverse section of the equatorial region showing different changes in the sensory nerve terminals. The chain fibres ( $F_3$  &  $F_4$ ) are less affected than the bag fibres ( $F_1$  &  $F_2$ ), but their sensory terminals are more severely affected than those of the bag fibres. Note the pyknotic nuclei (n) of the axial-sheath cells.

Ax: degenerated preterminal axon.

bar = 5 $\mu$ m

8.24



Figs. 8.25-8.27 Transverse sections of ischaemic intrafusal fibres showing different degenerative changes in motor nerve terminals.

8.25 Six hours after devascularization:

a motor nerve terminal contains swollen mitochondria with tubular, vesicular and granular contents.

The outer mitochondrial membranes may have disintegrated (arrow).

Arrow heads point to multilamellated structures.

Asterisk: autophagic vacuole.

8.26 Twelve hours after devascularization:

a normal motor nerve terminal engulfed by Schwann-cell processes.

Note the absence of basal lamina from the neuromuscular junction.

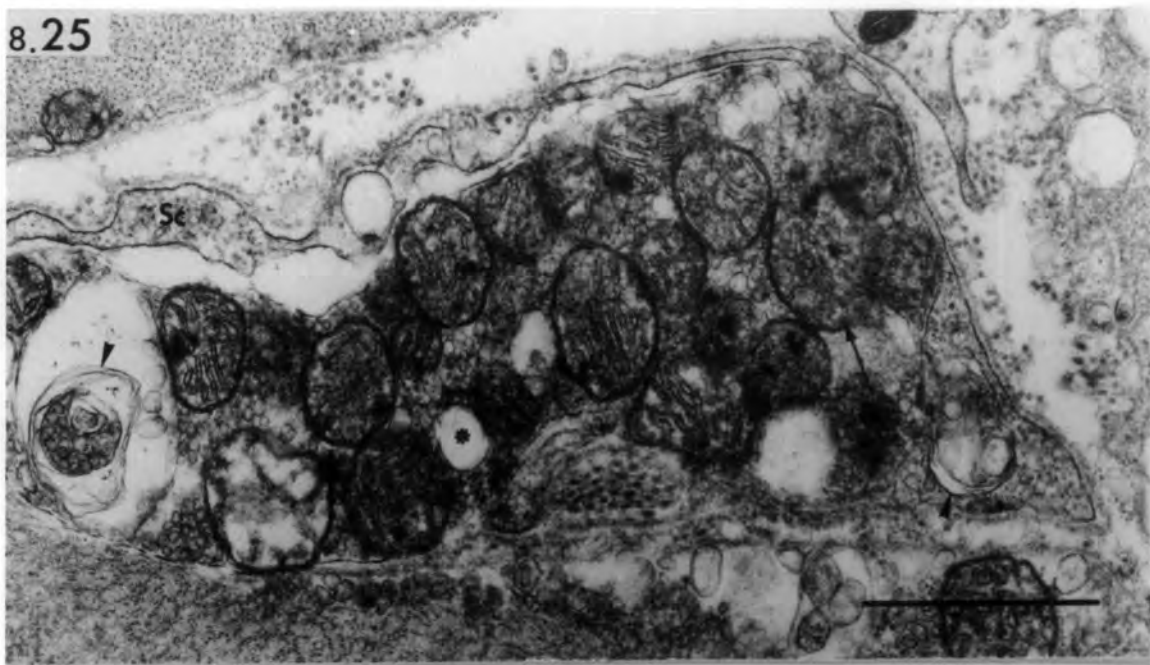
n: degenerated sole-plate nucleus.

Asterisks: probable degenerating nerve terminals.

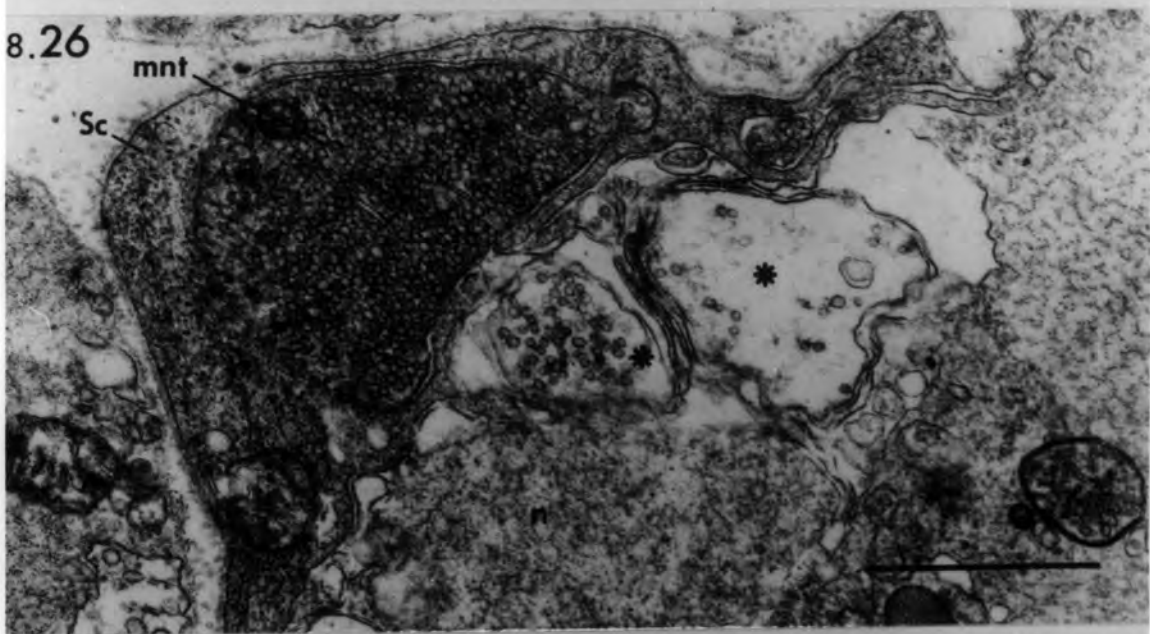
8.27 One day after devascularization:

degenerating motor nerve terminals (mnt) and preterminal axons (ax) are encircled by Schwann-cell processes that contain lipid droplets. Note the axons are more affected than the terminals. Arrow heads point to dense osmiophilic bodies in mitochondria.

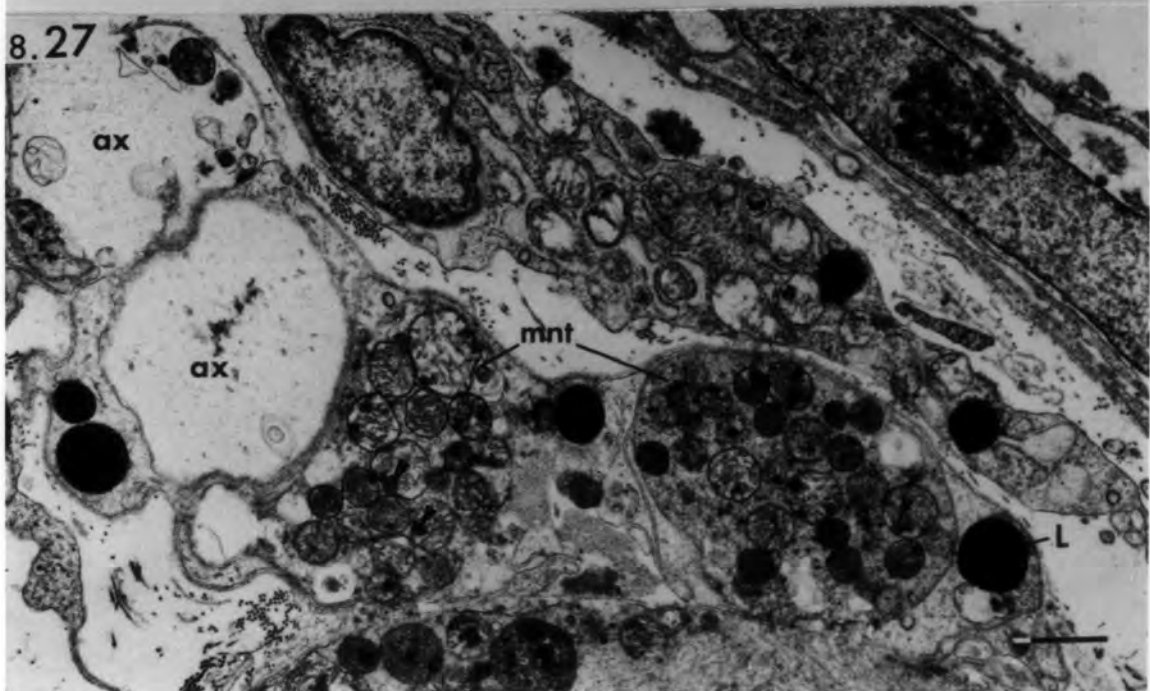
8.25



8.26



8.27



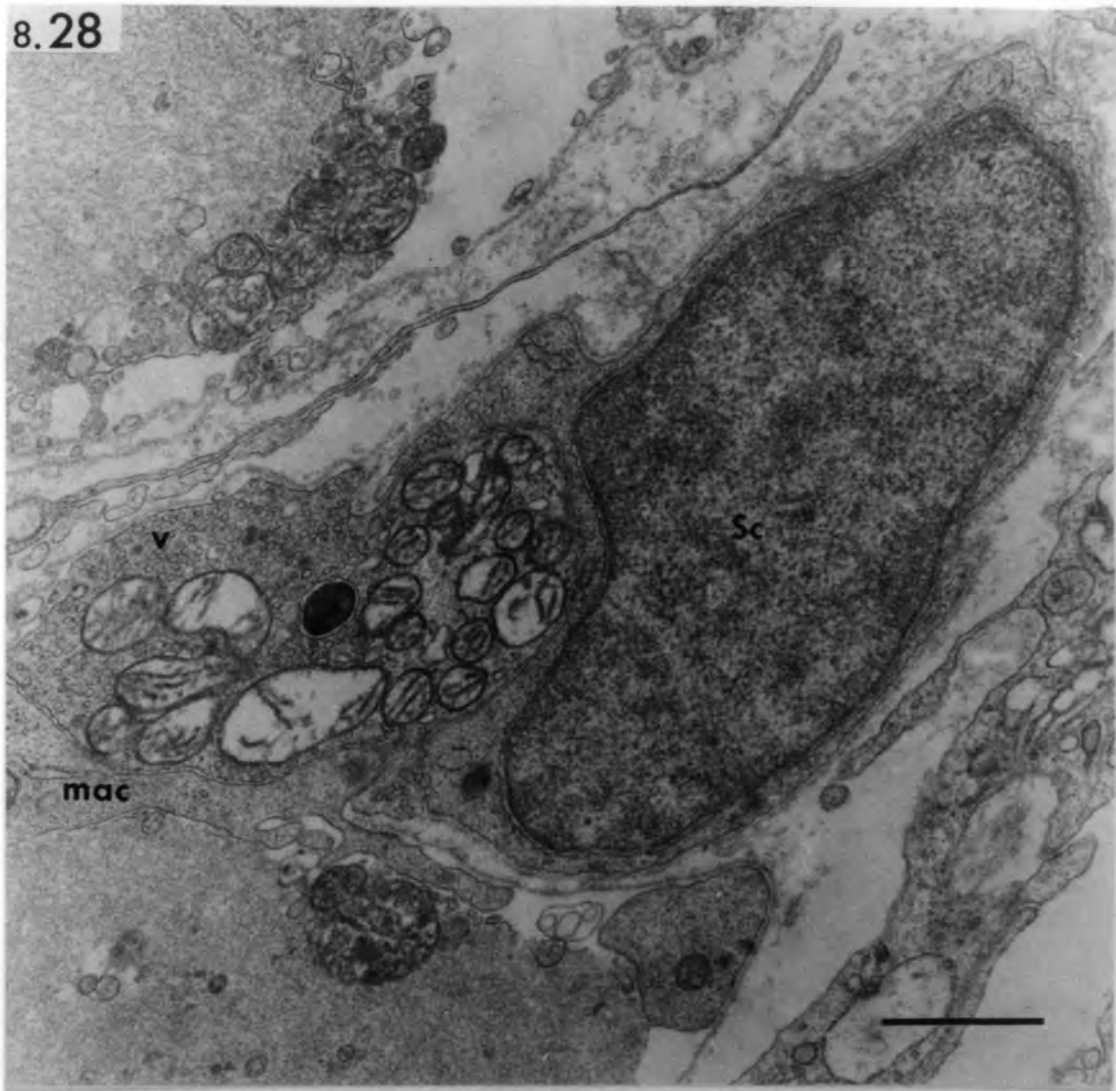
Figs. 8.28, 8.29 Transverse sections of ischaemic  
intrafusal fibres showing different  
degenerative changes in motor nerve  
terminals 2 days after devascularization.

8.28 A less-affected motor nerve terminal contains normal vesicles (v) and swollen mitochondria with disrupted cristae. A macrophage is present at the neuromuscular junction where the basal lamina is absent.

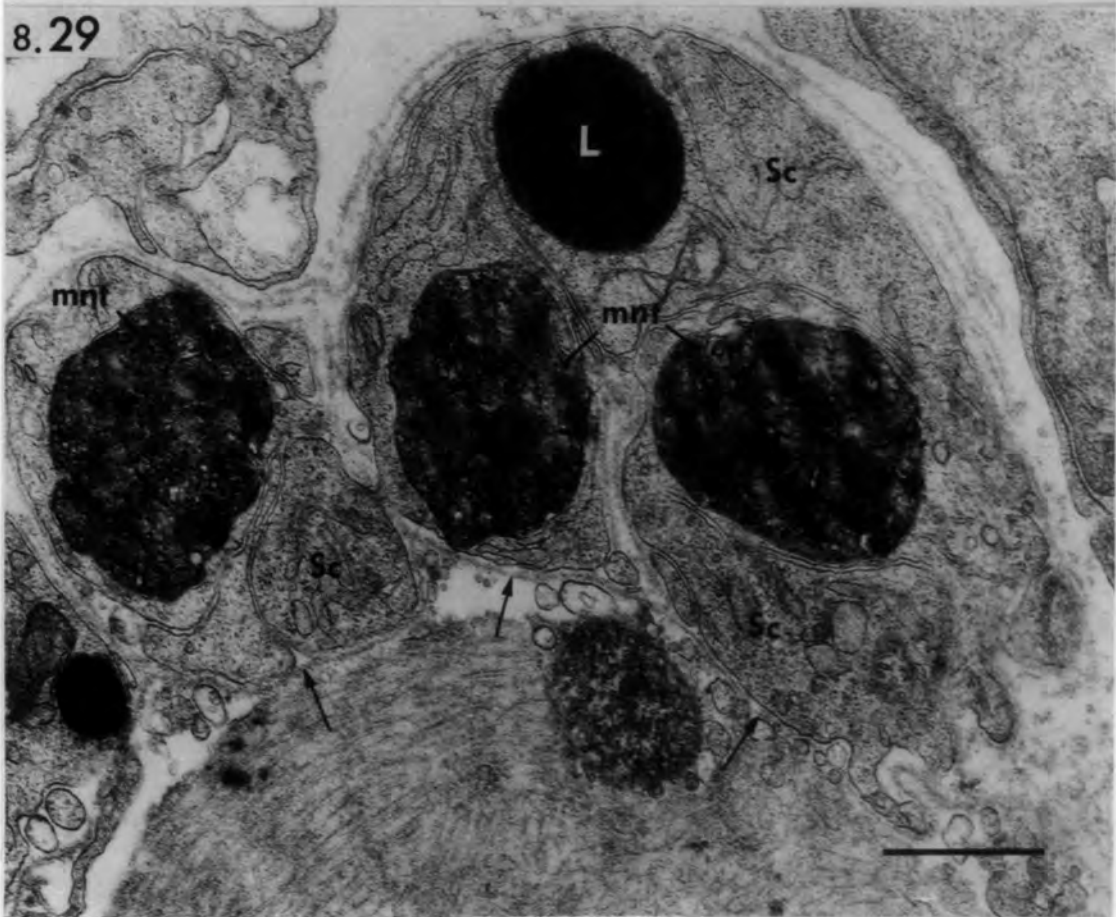8.29 Three severely-affected motor nerve terminals which resemble honeycomb structures. Condensed vesicles and mitochondria may be recognized in these structures. The terminals are completely encircled by Schwann cells. Note the persisting basal lamina (arrows) at the neuromuscular junction.

bars = 1 $\mu$ m

8.28



8.29



Figs. 8.30, 8.31 Transverse sections of ischaemic-  
spindle nerve trunks.

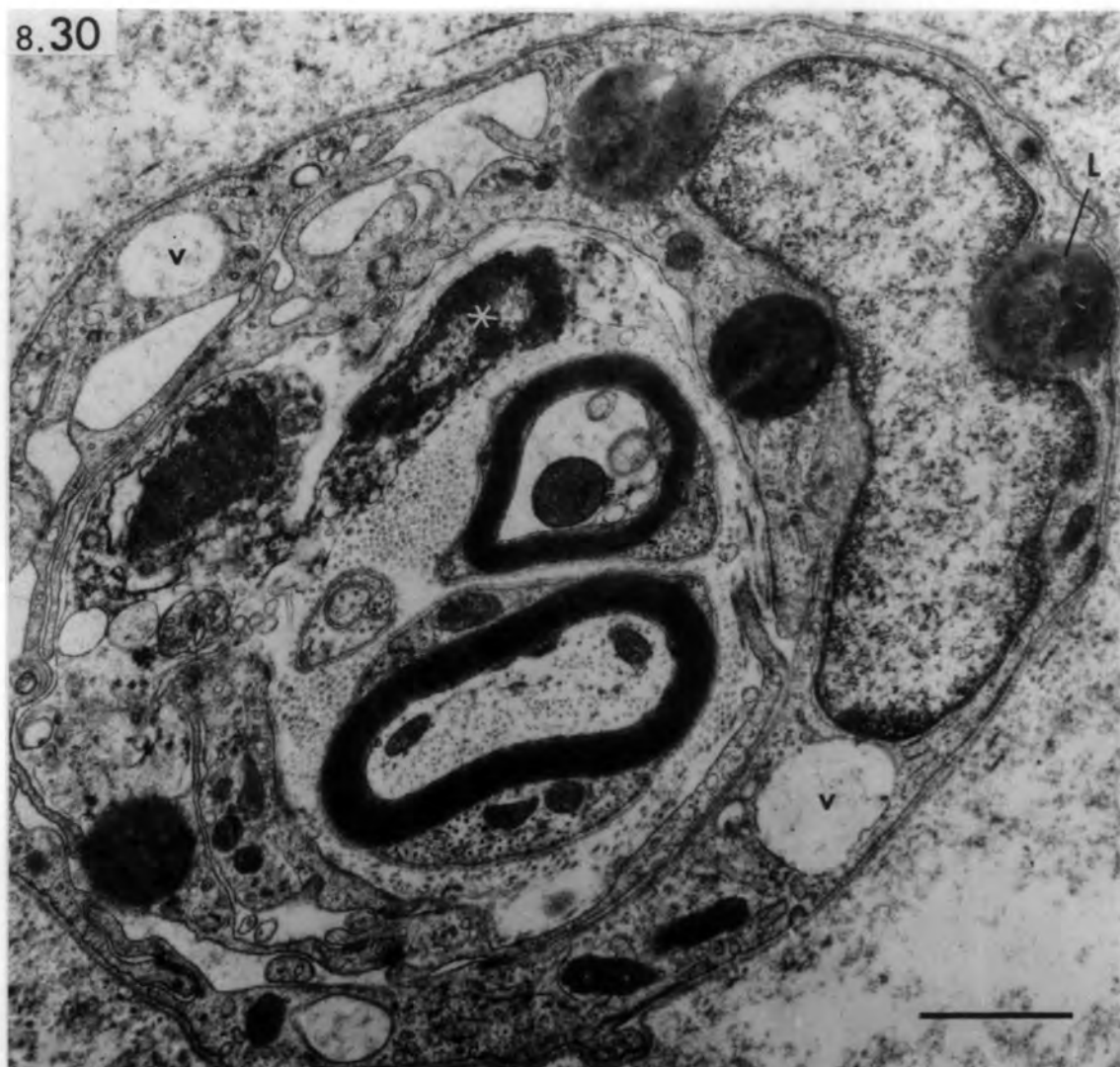8.30 Twelve hours after devascularization: activated perineurial cell contains lipid droplets (L) and vacuoles (v). The nerve trunk contains two degenerating endoneurial cells (asterisk) and two myelinated axons.

bar = 1 $\mu$ m

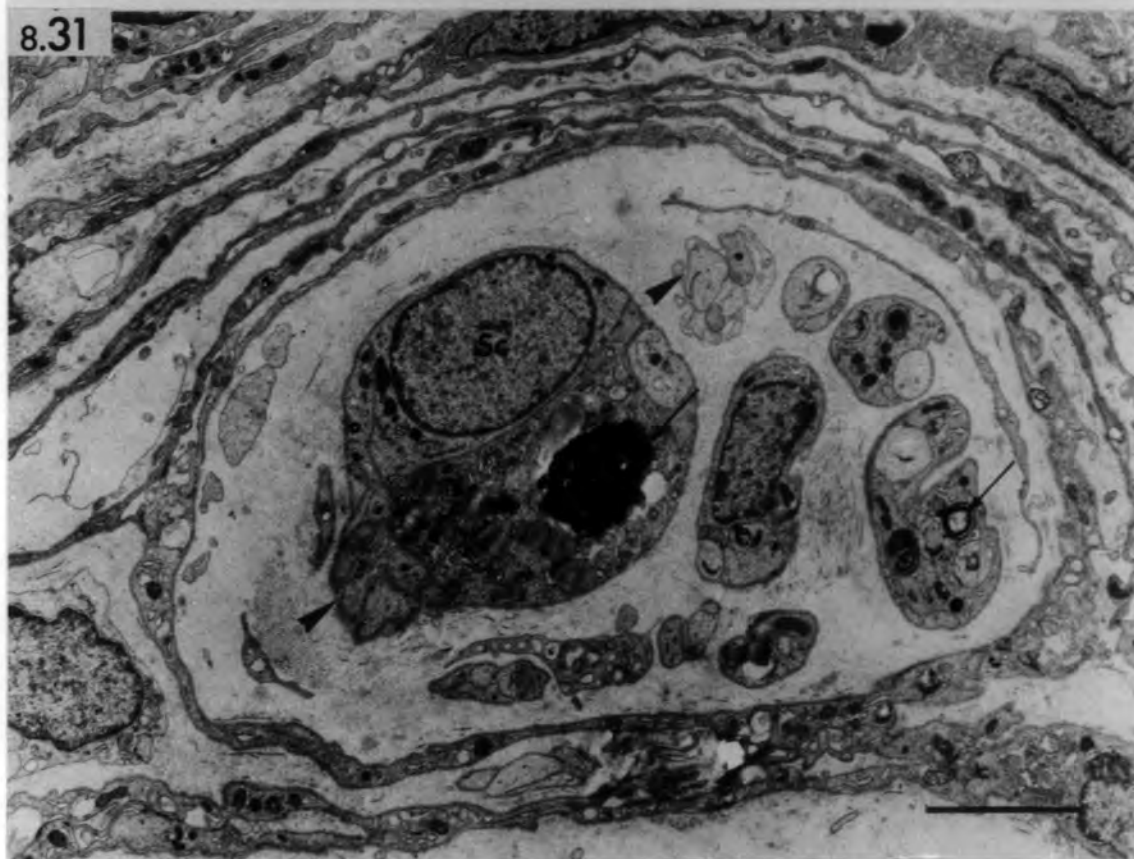8.31 Five days after devascularization: the spindle nerve trunk contains Schwann cells and their processes in the form of bands of Büngner (arrow heads). The Schwann cell contains dense material (arrow), which is probably myelin debris.

bar = 4 $\mu$ m

8.30



8.31



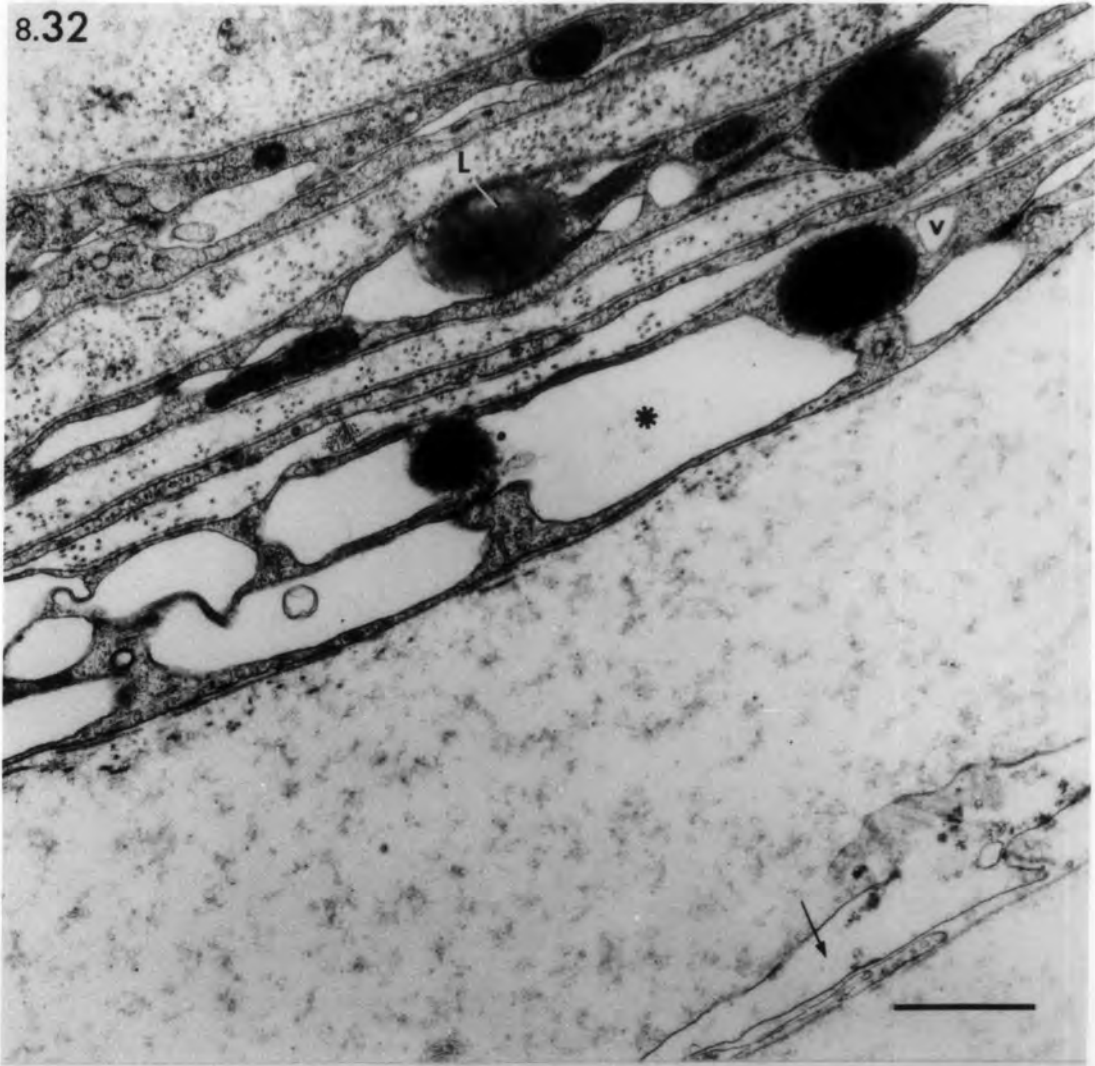
Figs. 8.32, 8.33 Ischaemic muscle spindle 12 hours  
after devascularization.

8.32 Transverse section of the spindle capsule showing lipid droplets (L) and vacuoles (v) in capsule cells. The channels between adjacent layers are enlarged (asterisk). Arrow points to an axial-sheath cell.

8.33 Transverse section of the axial sheath. The cytoplasm (asterisks) and, to a less extent, the nuclei of the axial-sheath cells appear bleached. Vacuoles (v), degenerating mitochondria, lipid droplets and dilated endoplasmic reticulum are present in the cytoplasm. Arrow points to a degenerating Schwann cell.

bars = 1 $\mu$ m

8.32



8.33

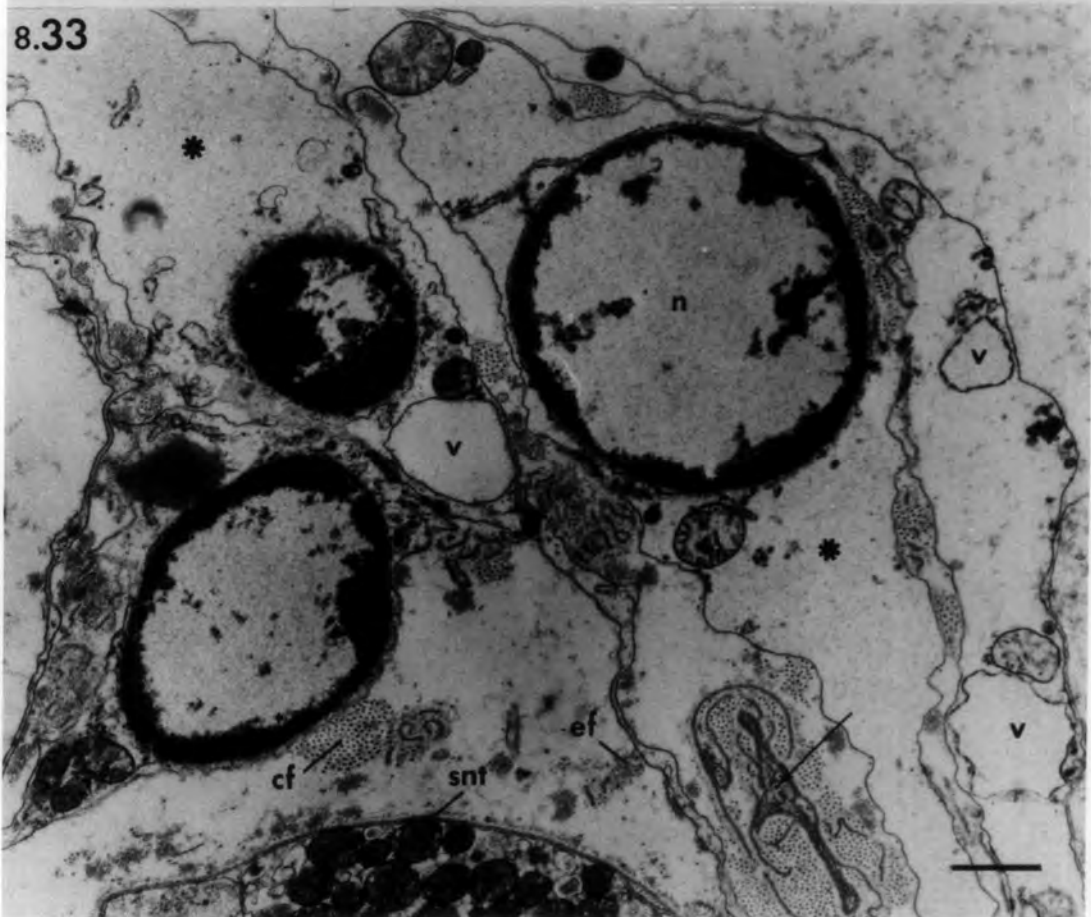


Fig. 8.34 Ischaemic muscle spindle 12 hours after  
devascularization.

Transverse section through the periaxial  
space showing flocculent material,  
contained in vacuole-like structures.

bar = 5 $\mu$ m

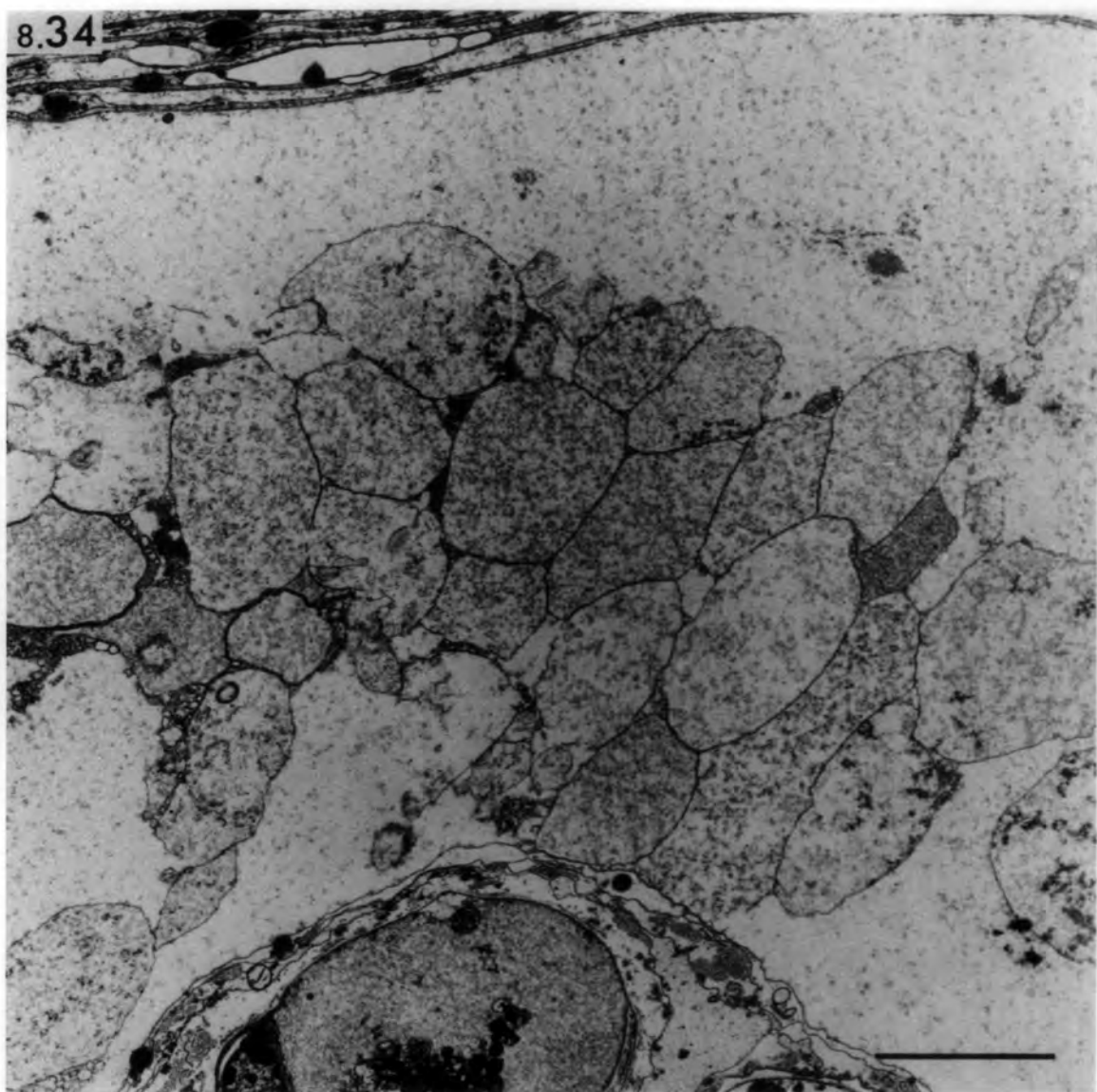


Fig. 8.35 Ischaemic muscle spindle 2 days after  
devascularization.

A. Transverse section of the intra-  
capsular polar region showing inflammation  
and haemorrhage around the spindle  
and phagocytic invasion of an  
intrafusal fibre.

bar = 5 $\mu$ m

B. Higher power to show a macrophage  
invading the degenerating fibre  
through a break (between arrows) in  
the basal lamina.

bar = 1 $\mu$ m



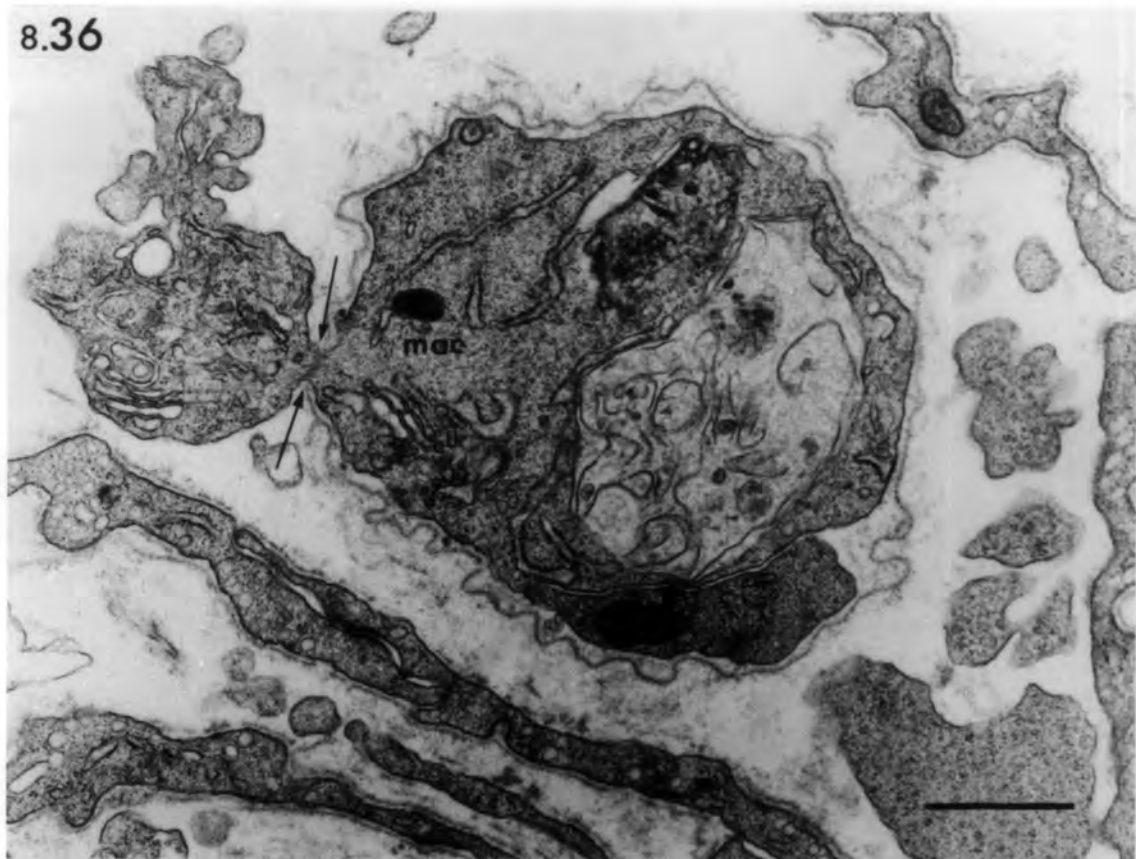
Figs. 8.36, 8.37 Ischaemic muscle spindle 3 days  
after devascularization.

8.36 Transverse section of the equatorial region showing a basal-lamina tube of a degenerated intrafusal fibre. A macrophage process is protruding through a break (between arrows) in the basal lamina, presumably caught in transit moving towards the periaxial space.

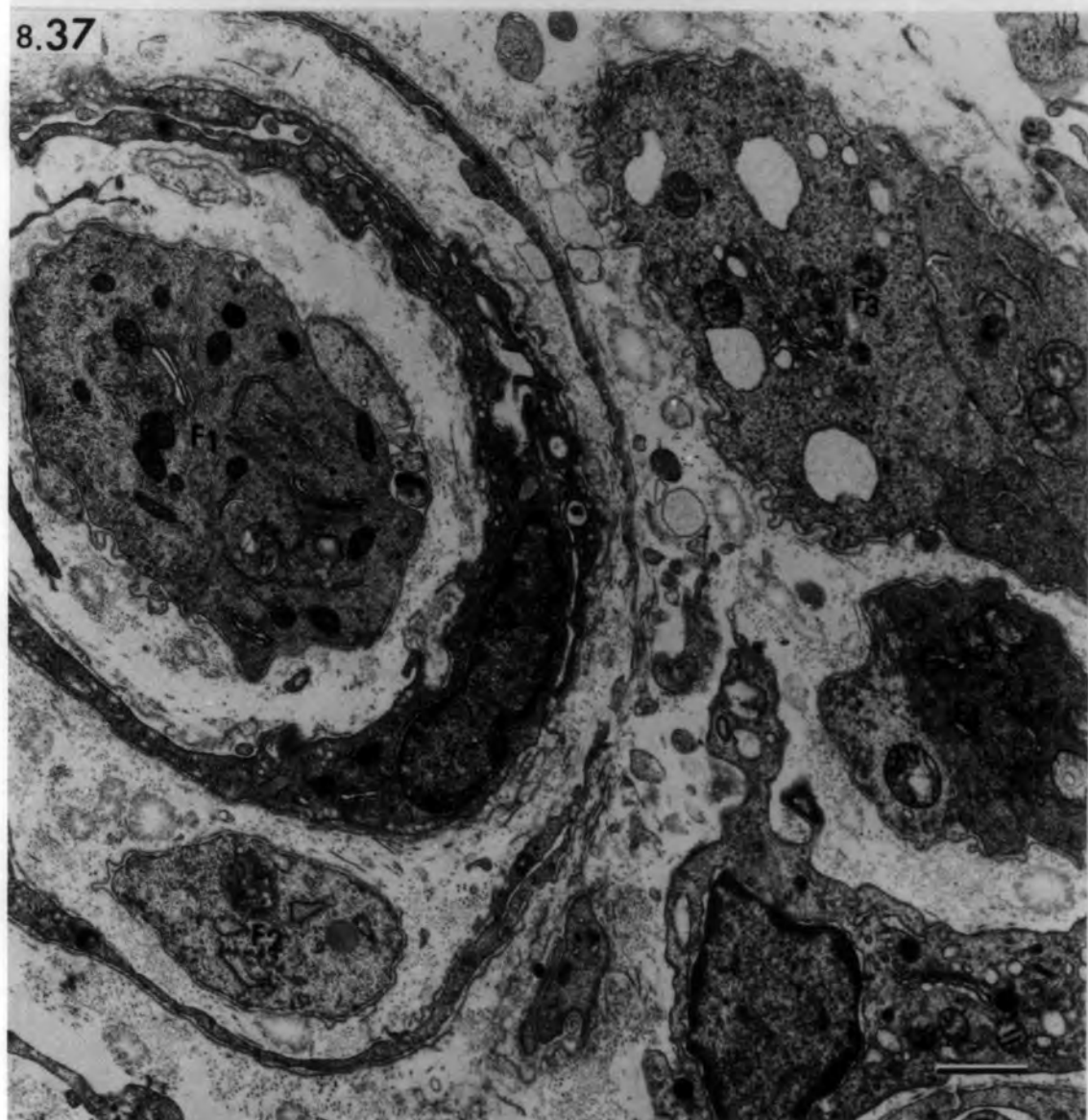
8.37 Transverse section through capsule termination showing four regenerating intrafusal fibres ( $F_1$ - $F_4$ ). The folded tubes of basal lamina contain myoblasts and nascent myotubes in addition to macrophages.

bars =  $1\mu\text{m}$

8.36



8.37



Figs. 8.38, 8.39 Ischaemic muscle spindles 5 days  
after devascularization.

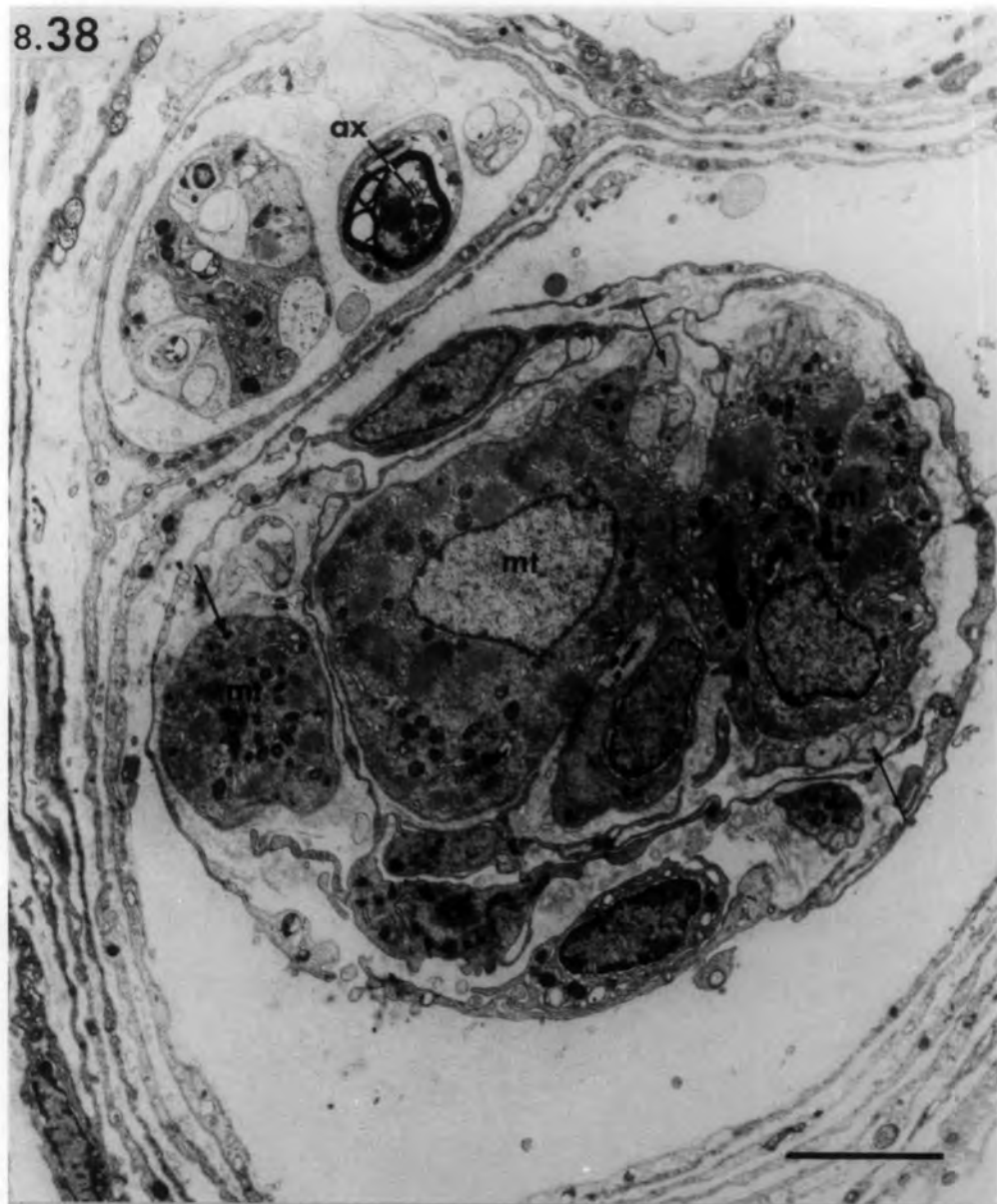8.38 Transverse section of the equatorial region showing regenerating intrafusal fibres. Two thick closely-apposed fibres consist of well-formed myotubes (mt) with central nuclei. A thin fibre (on the left) is similarly composed. Note the presence of bands of Büngner (arrows) beneath the basal lamina of the regenerating fibres.  
ax: degenerating nerve axon.

bar = 4µm

8.39 Transverse section of intracapsular polar region of a regenerating thin fibre which contains a nascent myotube (mt) and two myoblasts (mb) enclosed by a basal-lamina tube.

bar = 1µm

8.38



8.39

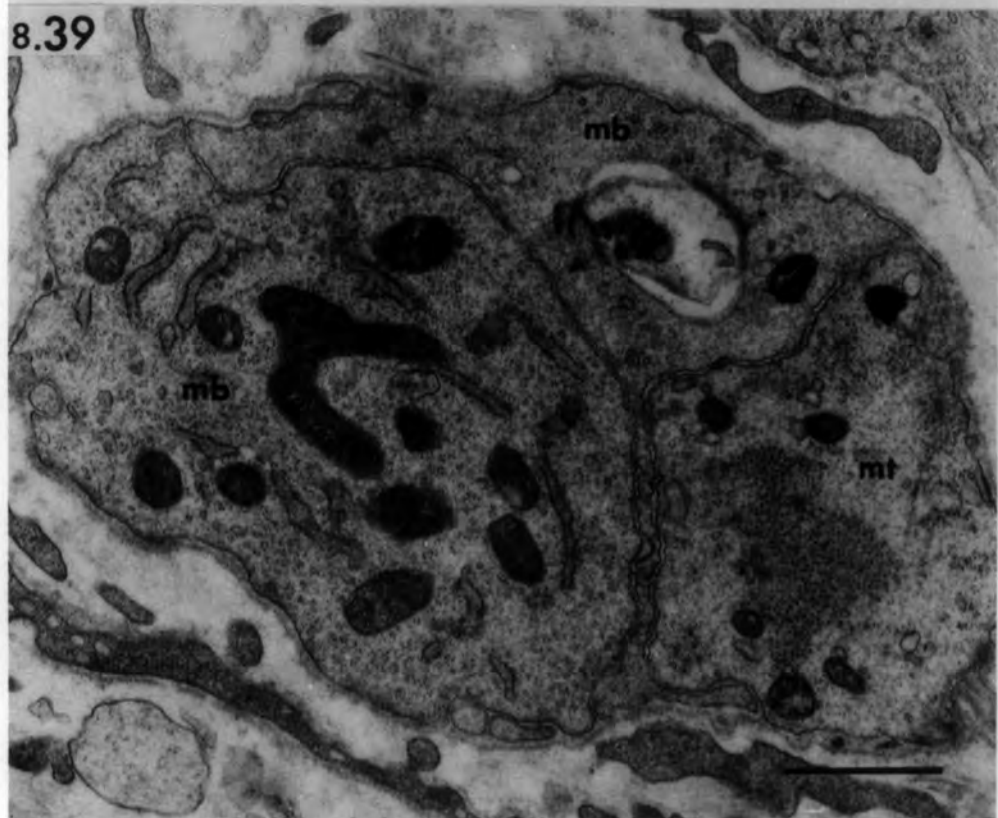


Fig: 8.40 Ischaemic muscle spindle 6 days after  
devascularization.

A. Oblique section of the equatorial region showing four intrafusal fibres at the same regenerative stage. Note the central nuclei (n) and myofibril assembly.

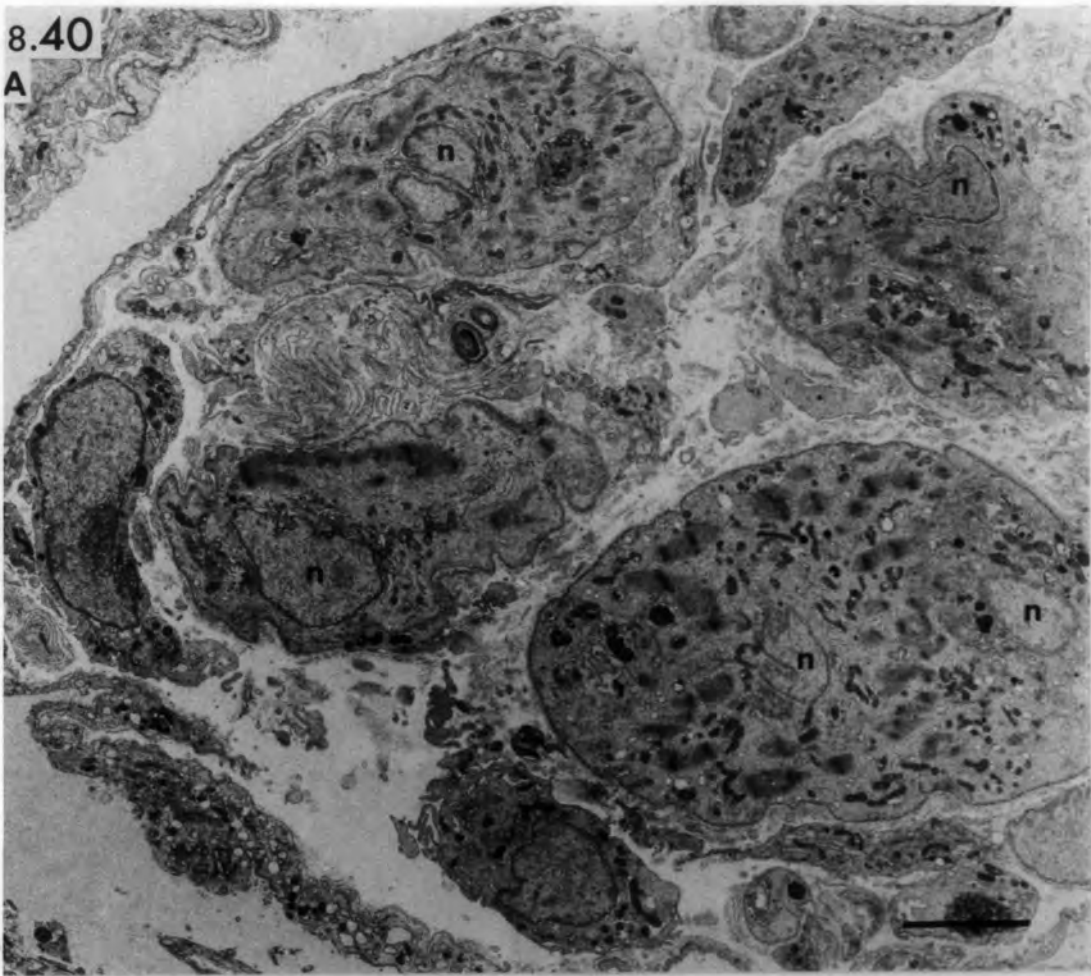
bar = 5µm

B. Higher power to show newly-formed Z- and M-lines. Golgi bodies, mitochondria and sarcoplasmic reticulum are present mainly around the nucleus. Note the broken basal lamina (between arrows) and cellular processes extending into the periaxial space.

bar = 1µm

8.40

A



B

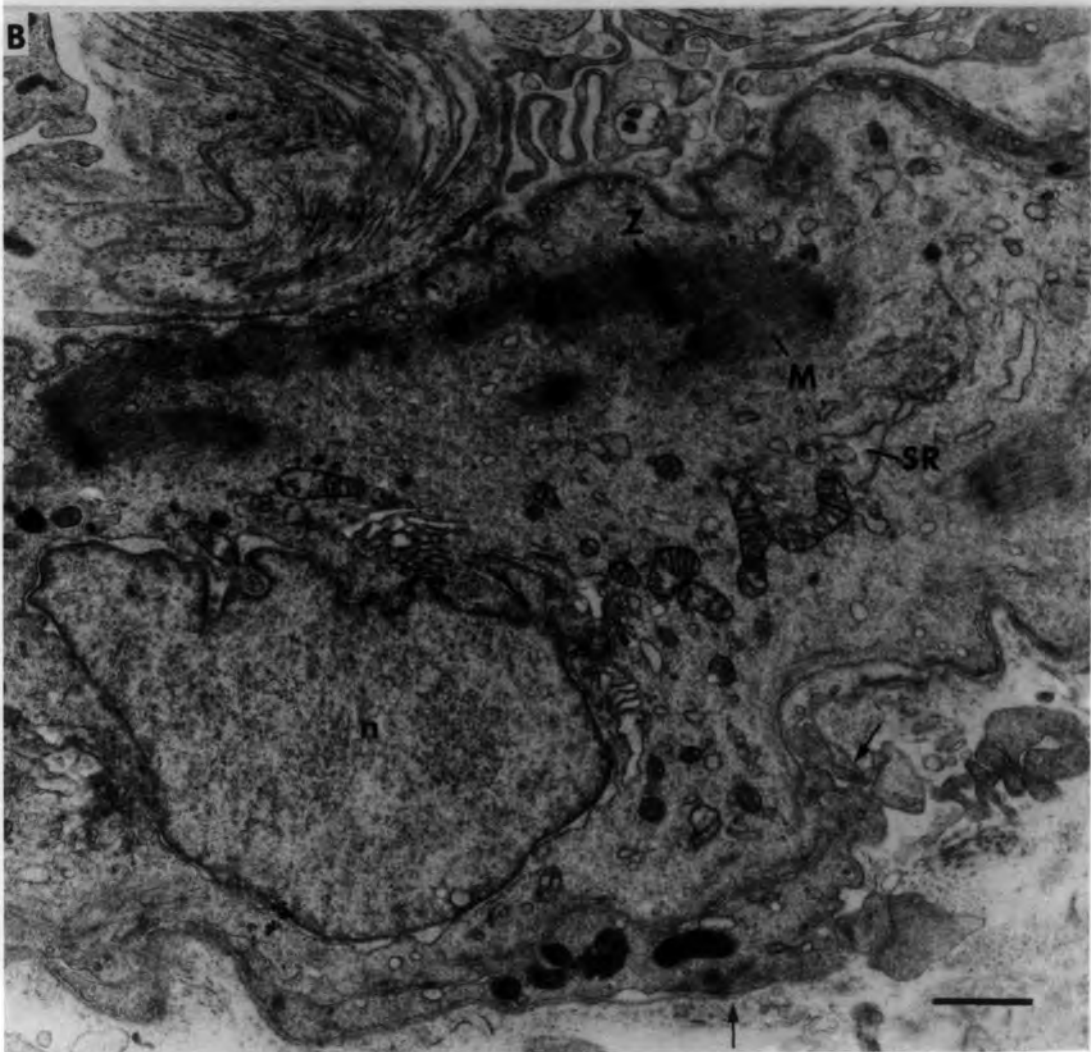

Fig. 8.41 Ischaemic muscle spindle 6 days after  
devascularization.

A. Transverse section of intracapsular polar region showing four intrafusal fibres of similar diameters but at different stages of regeneration.

F<sub>1</sub> and F<sub>2</sub> consist of well-developed myotubes while F<sub>3</sub> and F<sub>4</sub> consist of nascent myotubes and myoblasts.

bar = 5µm

B. Higher power to show the above differences in intrafusal-fibre regeneration. Note the abundant sarcoplasmic reticulum and the small mitochondria in F<sub>3</sub>. Arrows point to newly-formed myofilaments at the myotube periphery.

bar = 1µm

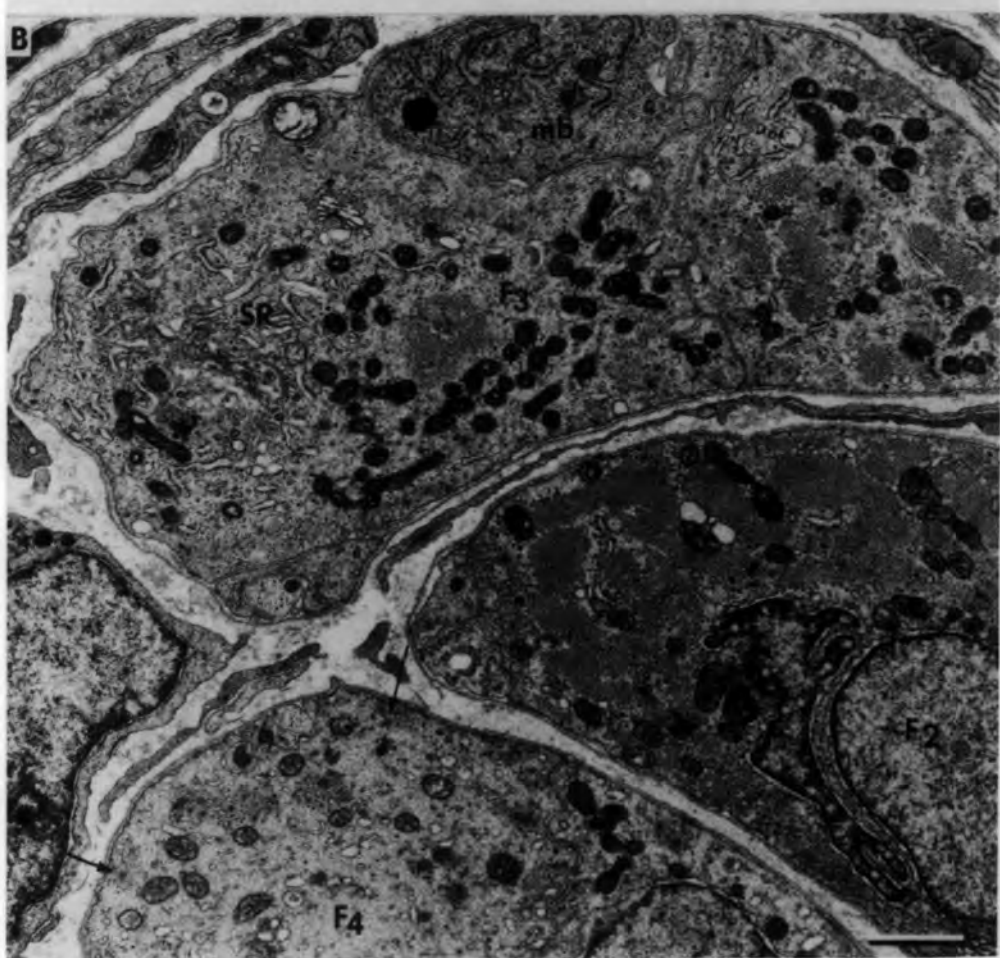
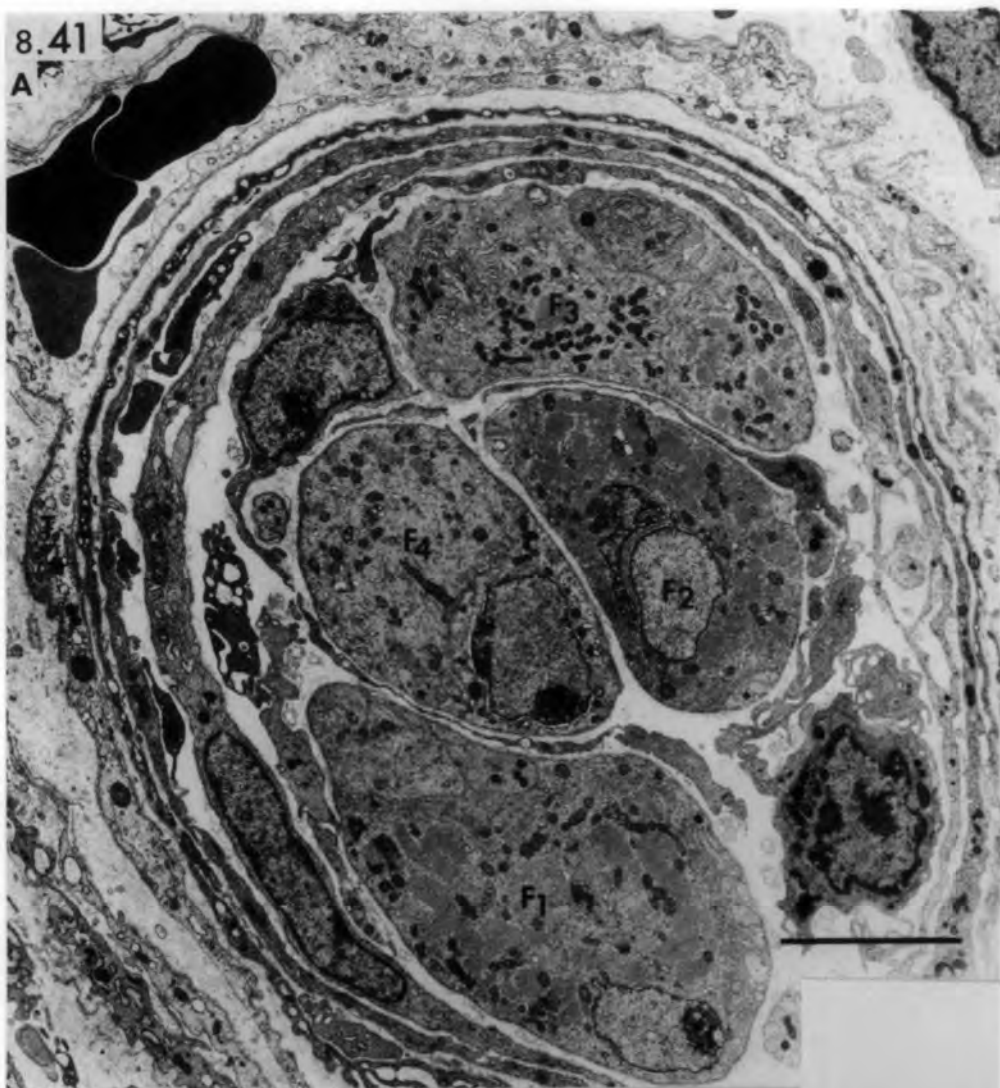

Fig. 8.42 Ischaemic muscle spindle 14 days after  
devascularization.

Transverse section of juxta-equatorial region showing four mature muscle fibres all with distinct M-lines. The three thick fibres (F<sub>1</sub>, F<sub>2</sub>, F<sub>3</sub>) are closely-apposed and share a common basal lamina. Note the similarity in size and distribution of the mitochondria in all fibres.

bar = 5µm

8.42

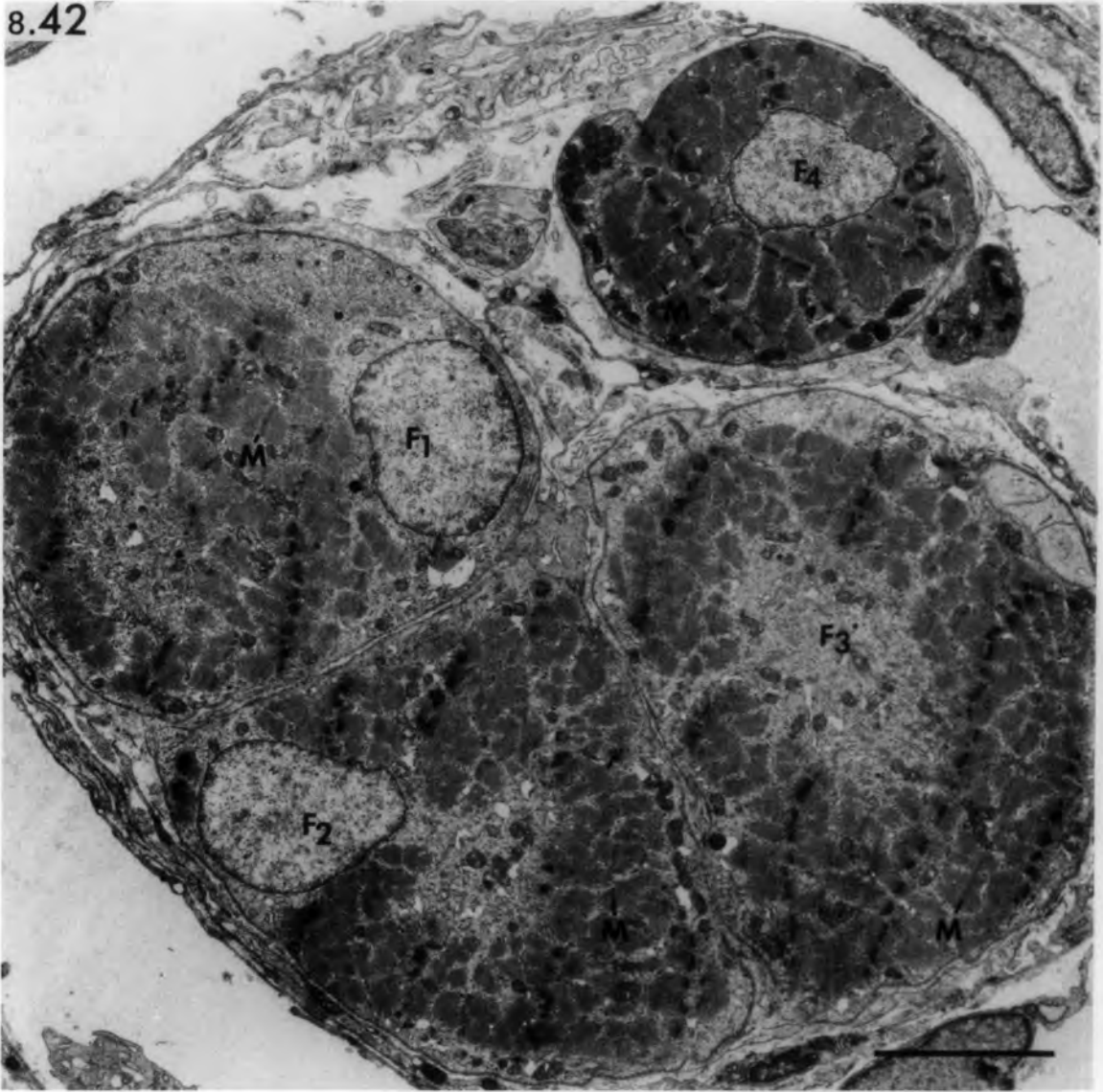
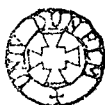

Fig. 8.43 Ischaemic muscle spindle 14 days after  
devascularization.

Transverse sections of the same spindle as that shown in Fig. 8.42. The sections in the latter figure, and in A and B, were cut at approximately 20 $\mu$ m intervals in sequence towards the pole. The closely-apposed F<sub>1</sub> and F<sub>2</sub> fibres in Fig. 8.42 are completely fused in A and separated in B. Arrow (in A) points to undifferentiated cell. Note the presence of capillary (cpl) and free erythrocytes (arrow heads) in the periaxial space.

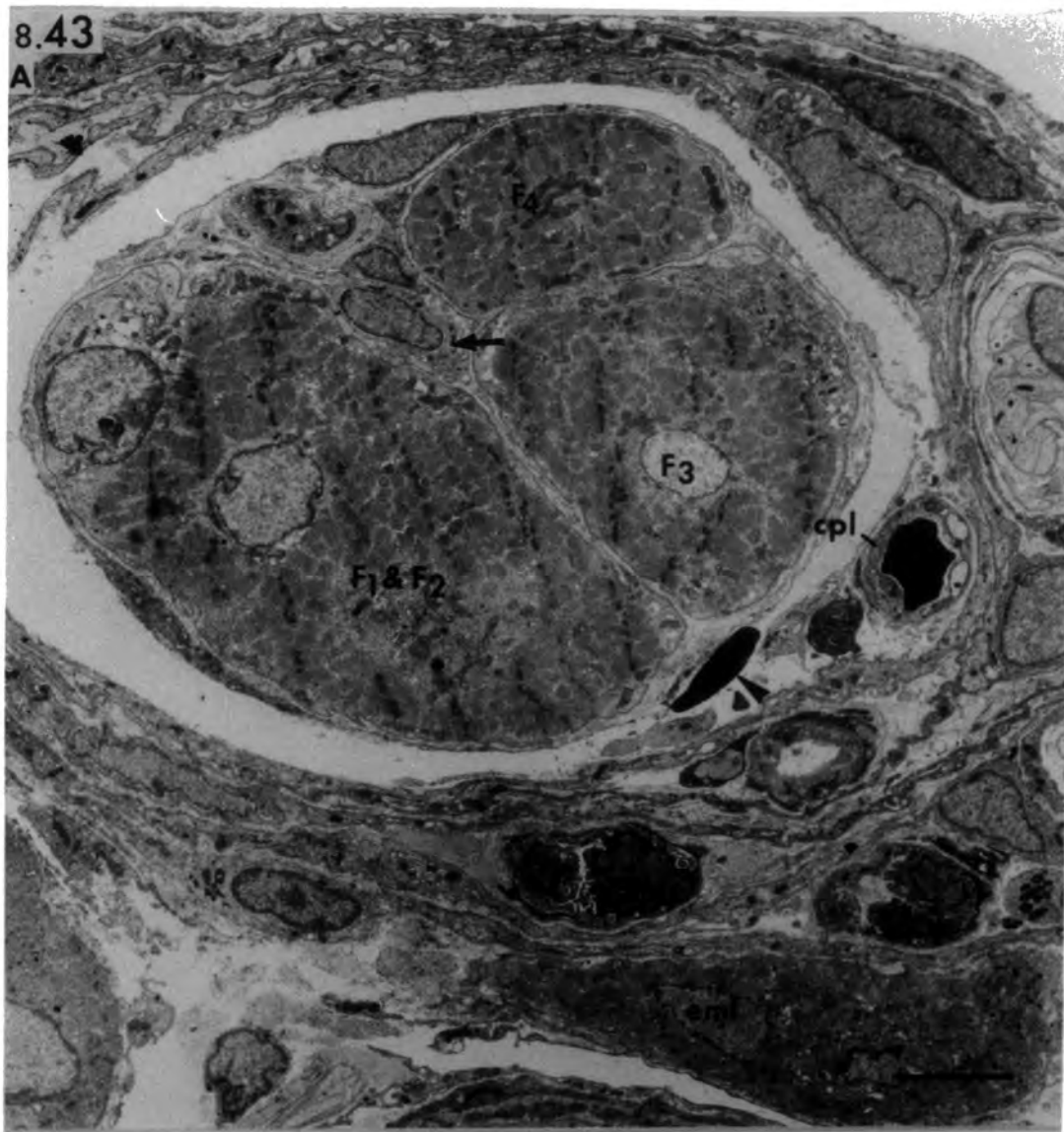emf: small extrafusal muscle fibre associated with the capsule.

bar = 5 $\mu$ m



8.43

A



B

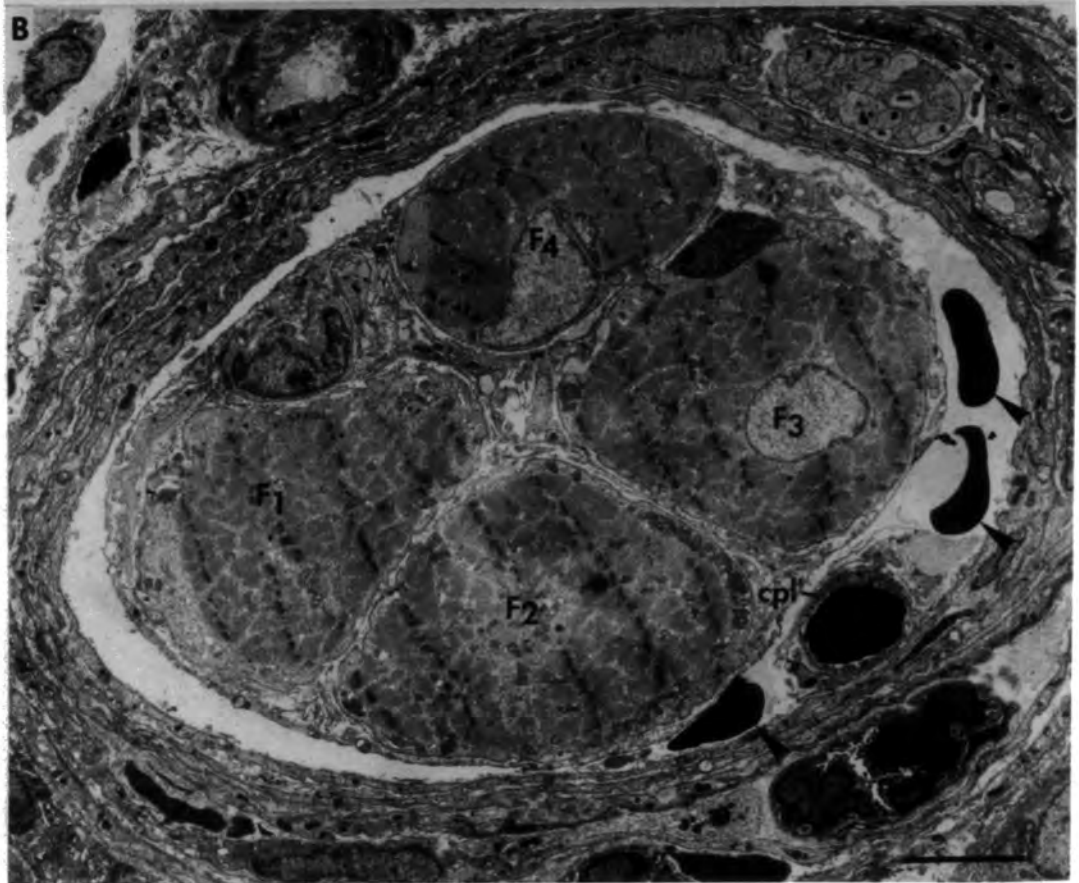


Fig. 8.44 Ischaemic muscle spindle 21 days after  
devascularization.

Transverse sections of the equatorial region showing combinations of original and additional muscle fibres.

- A. A common basal lamina (bl) encloses an original fibre ( $F_1$ ) and an additional fibre (asterisk) together with two other cells (probably migrated satellite cells) each with its own basal lamina.
- B. A common basal lamina encloses an original fibre ( $F_1$ ) and three additional fibres (asterisks) together with a migrated satellite cell (sat). The cluster is invaded by a myelinated axon through a break in the common basal lamina. Arrows (in A & B) point to processes of axial-sheath cells included within the clusters.

bars = 2 $\mu$ m



Fig. 8.45 Ischaemic muscle spindle 21 days after  
devascularization.

Longitudinal section of the juxta-equatorial region showing a motor nerve terminal reinnervating an intrafusal fibre. Note the distinct M-line (M) in both muscle fibres and the abundant sarcotubular system in the lower fibre.

Arrow heads point to myelin figures in the nerve and muscle cells.

bar = 1 $\mu$ m

8.45

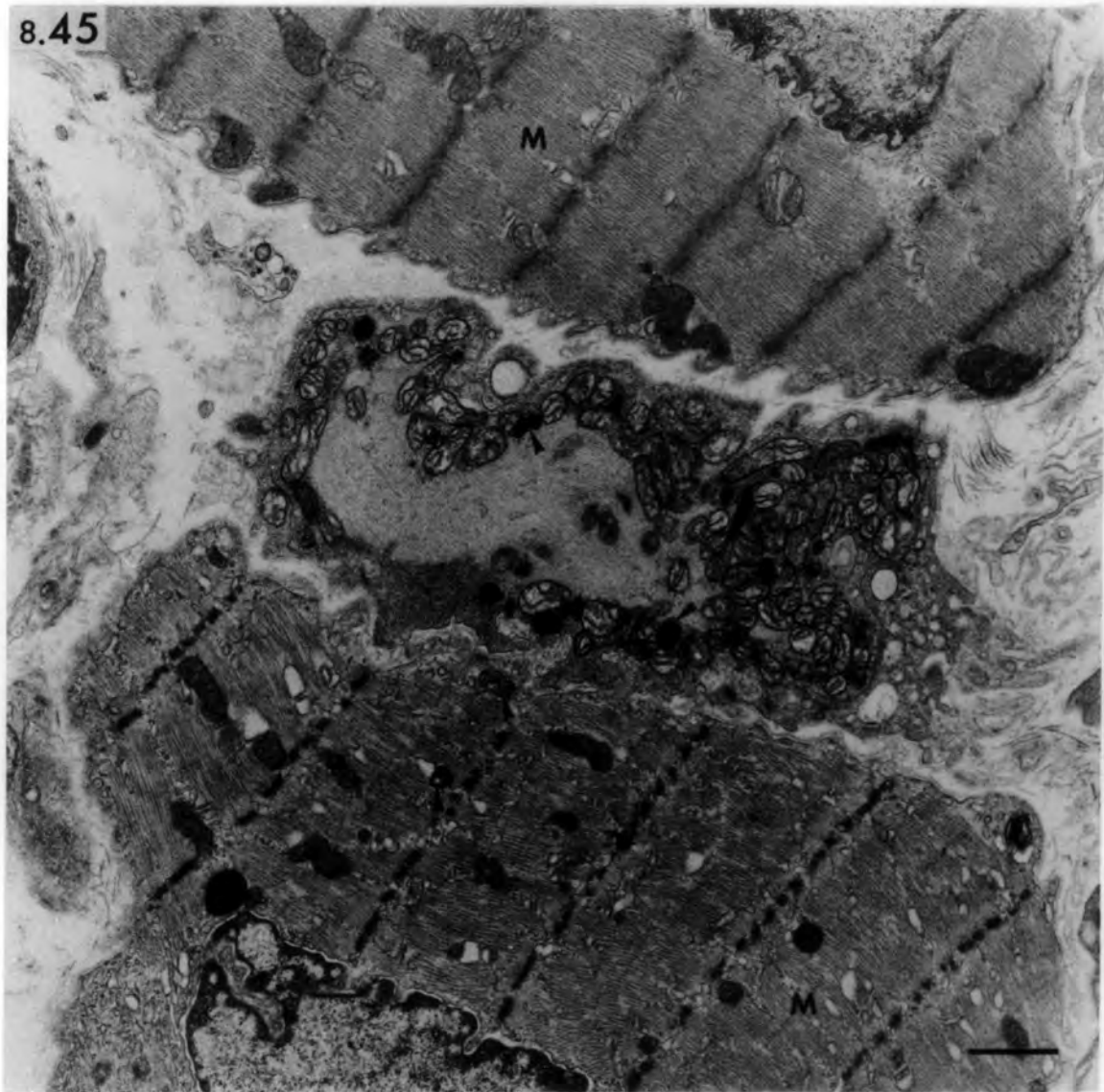


Fig. 8.46 Ischaemic muscle spindle 28 days after  
devascularization.

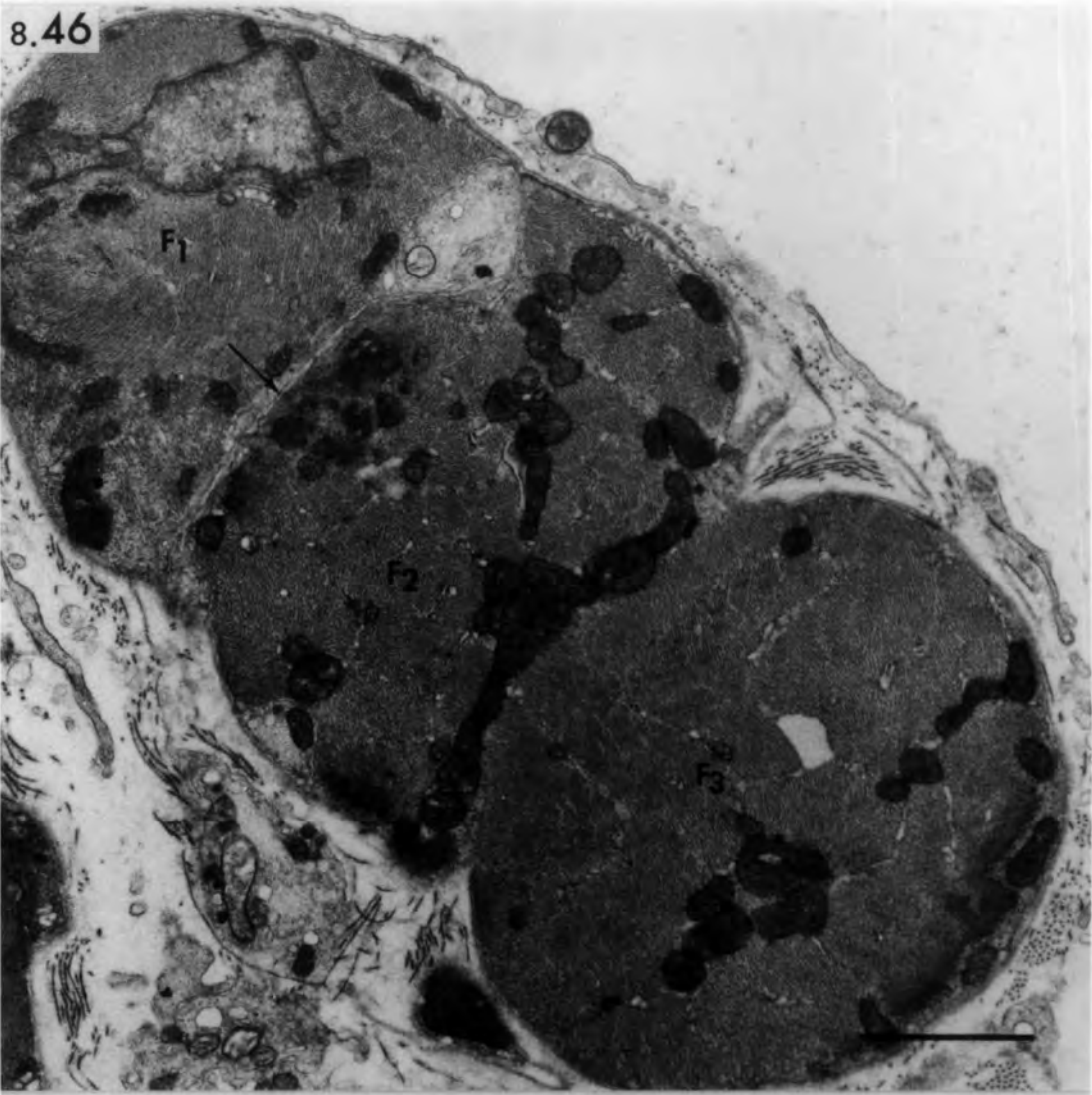
Transverse section of the equatorial region showing three muscle fibres enclosed by a common basal lamina.  $F_1$  and  $F_2$  are separated by a narrow cleft (arrow) without interposed basal lamina.  $F_2$  and  $F_3$  are fused and a strand of mitochondria marks the site of the fusion.

Fig. 8.47 Ischaemic muscle spindle 42 days after  
devascularization.

Transverse section of the equatorial region showing muscle fragments appearing as one muscle fibre that had split longitudinally. More probably they arose from separated or incompletely fused myotubes during regeneration.

bars =  $2\mu\text{m}$

8.46



8.47

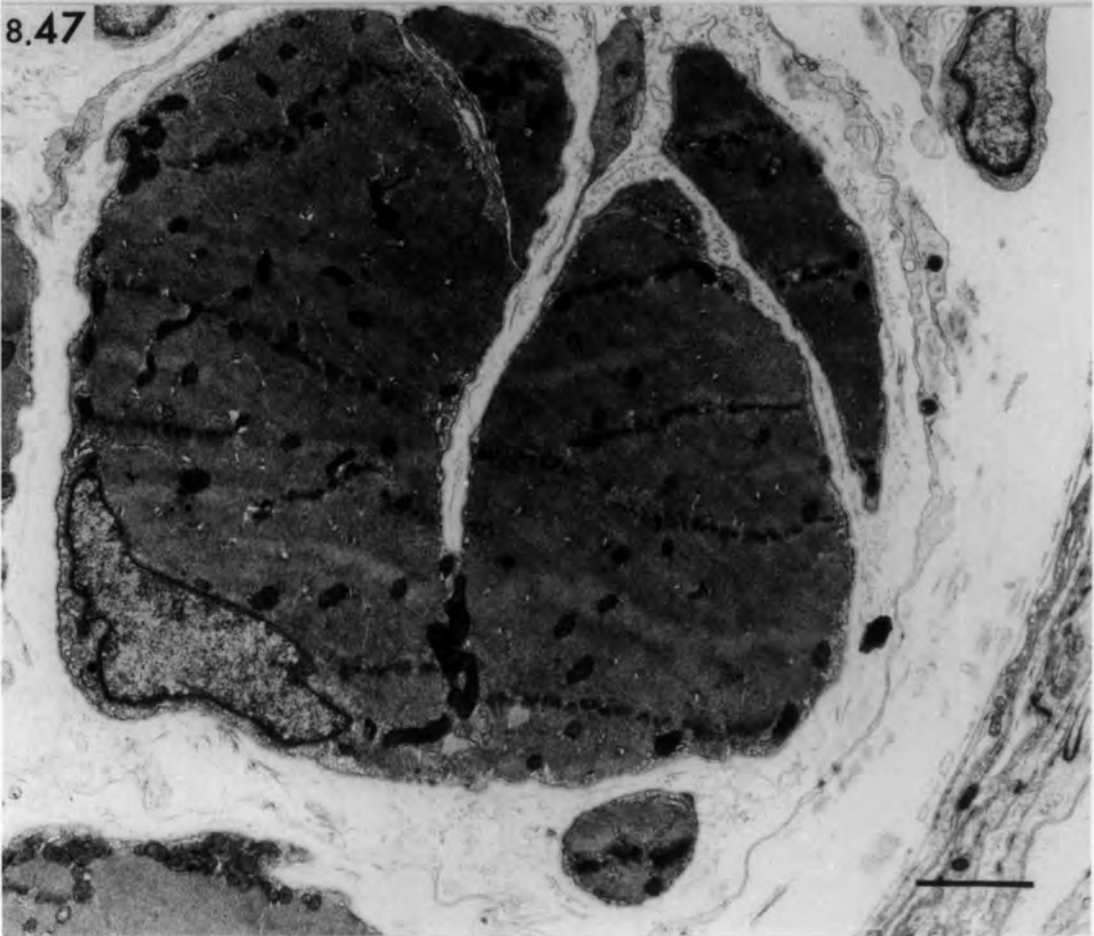


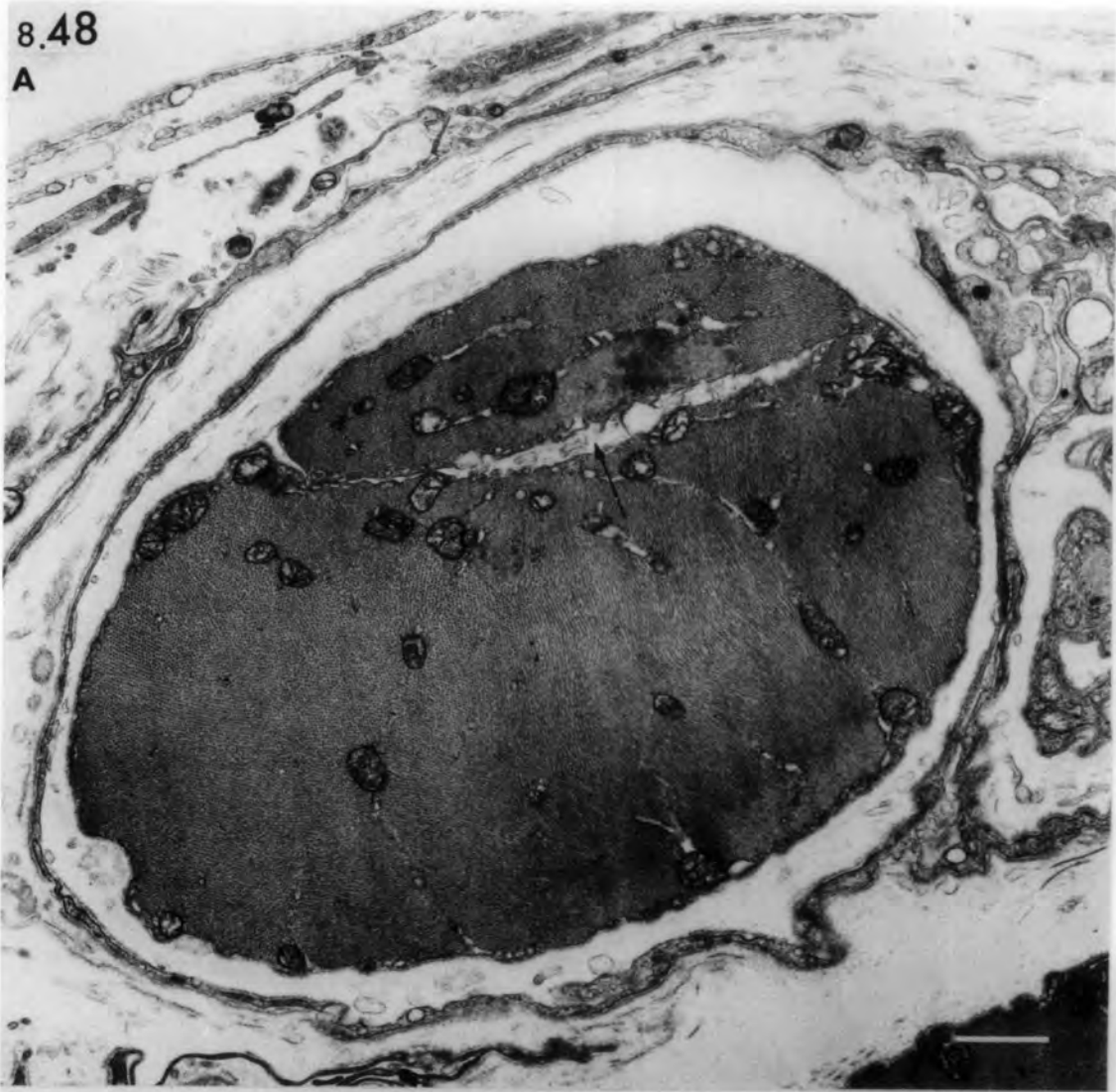Fig. 8.48 Ischaemic muscle spindle 42 days (A) and 182 days (B) after devascularization.

- A. Transverse section of intracapsular polar region showing incompletely split or fused intrafusal fibre. The cleft (arrow) lacks basal lamina and contains membranous structures.
- B. Transverse section of the equatorial region showing a fragmented intrafusal fibre. Note the basal lamina (arrows) in the cleft and around the muscle-cell processes. Arrow head points to a ring of basal lamina.

bars = 2 $\mu$ m

8.48

A



B

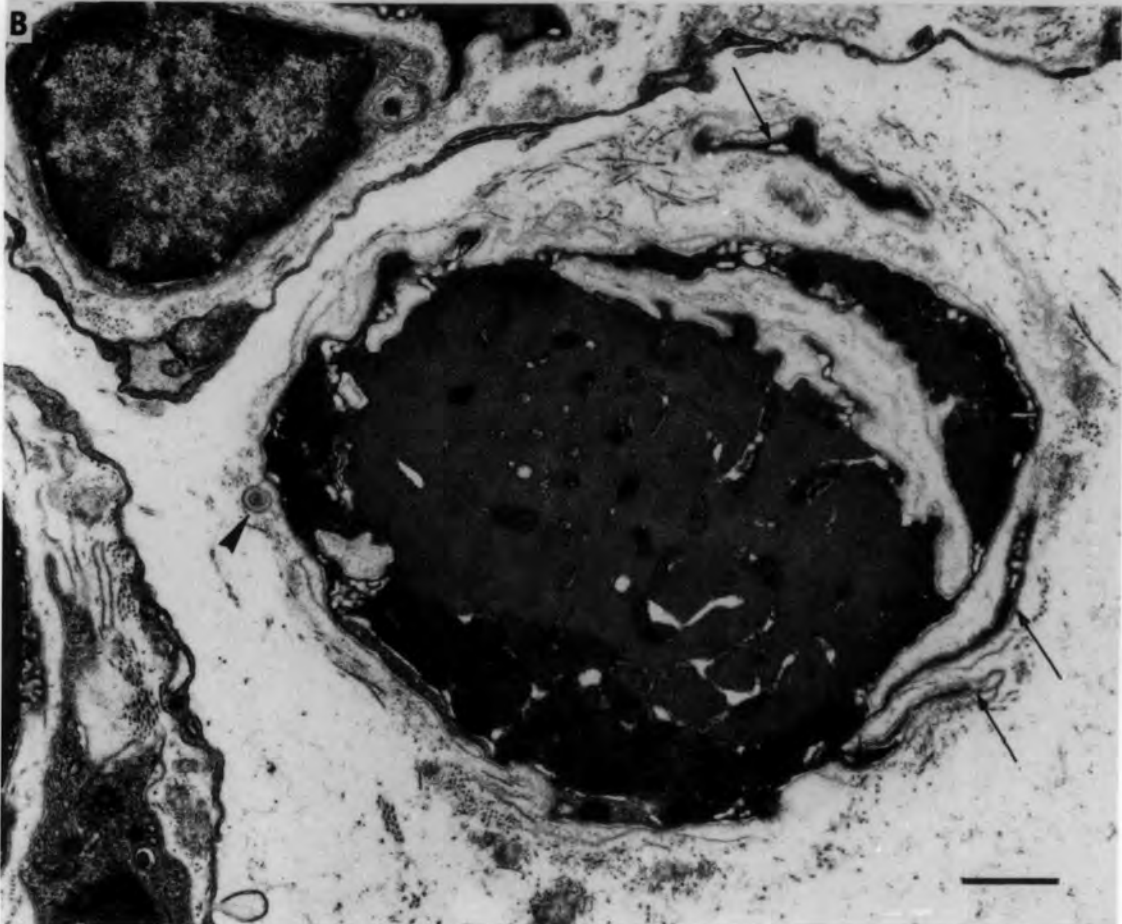


Fig. 8.49 Ischaemic muscle spindles

Transverse sections showing additional muscle fibres associated with the capsule.

- A. Additional muscle fibre with its own basal lamina (14 days after devascularization).
- B. Additional muscle fibre sharing a basal lamina (arrow) with a capsule cell (14 days after devascularization).
- C. Fragmented additional muscle fibre enclosed by capsule layers.

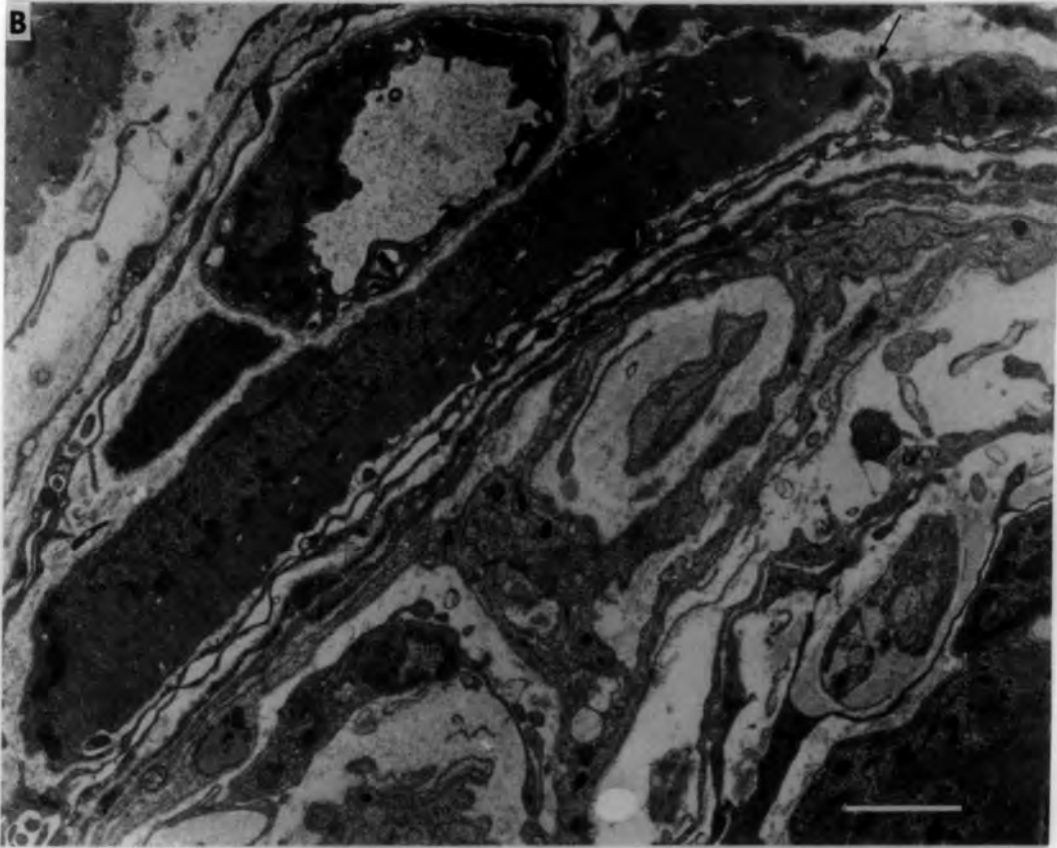
bars = 2 $\mu$ m

8.49

A



B



C

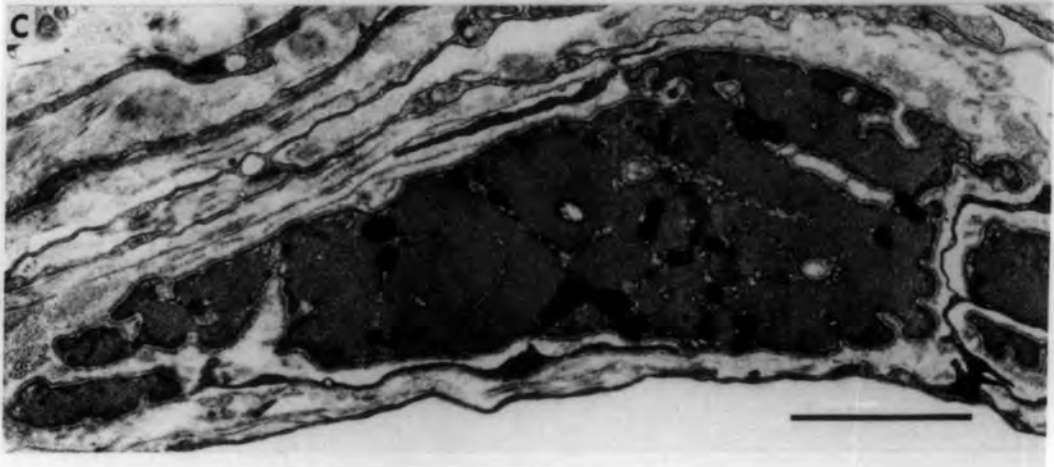


Fig. 8.50 Ischaemic muscle spindles

Transverse sections showing additional muscle fibres in the periaxial space and associated with the axial sheath.

A. Additional fibre in the periaxial space (21 days after devascularization).

B. Additional fibre within the axial sheath and attached to a probable satellite cell both sharing an incomplete common basal lamina (21 days after devascularization).

Asterisk indicates another small additional fibre.

C. Degenerating additional fibre encircled by processes of axial-sheath cells (182 days after devascularization).

bars = 1µm

8.50

A

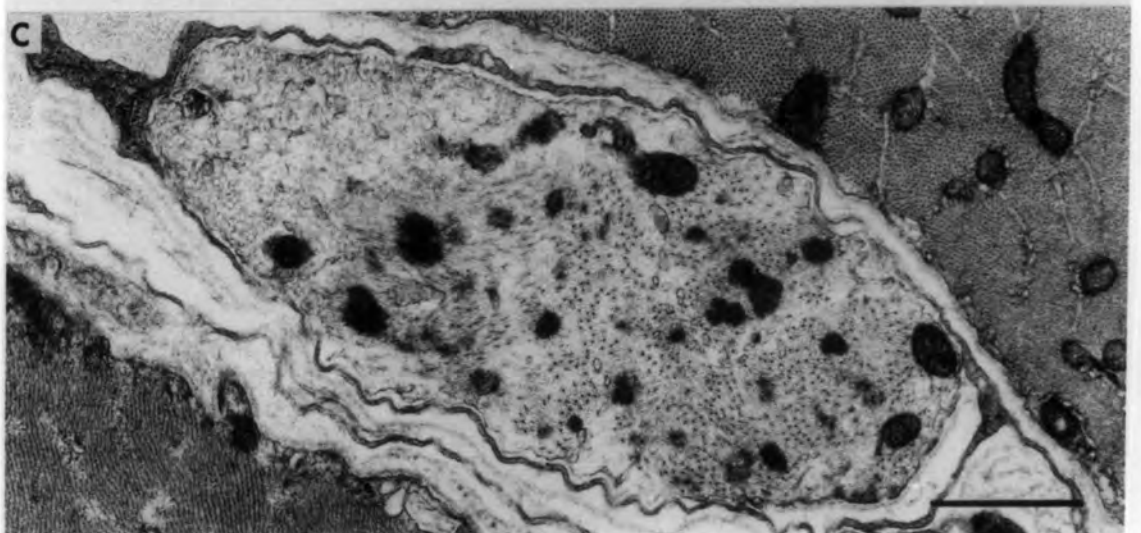
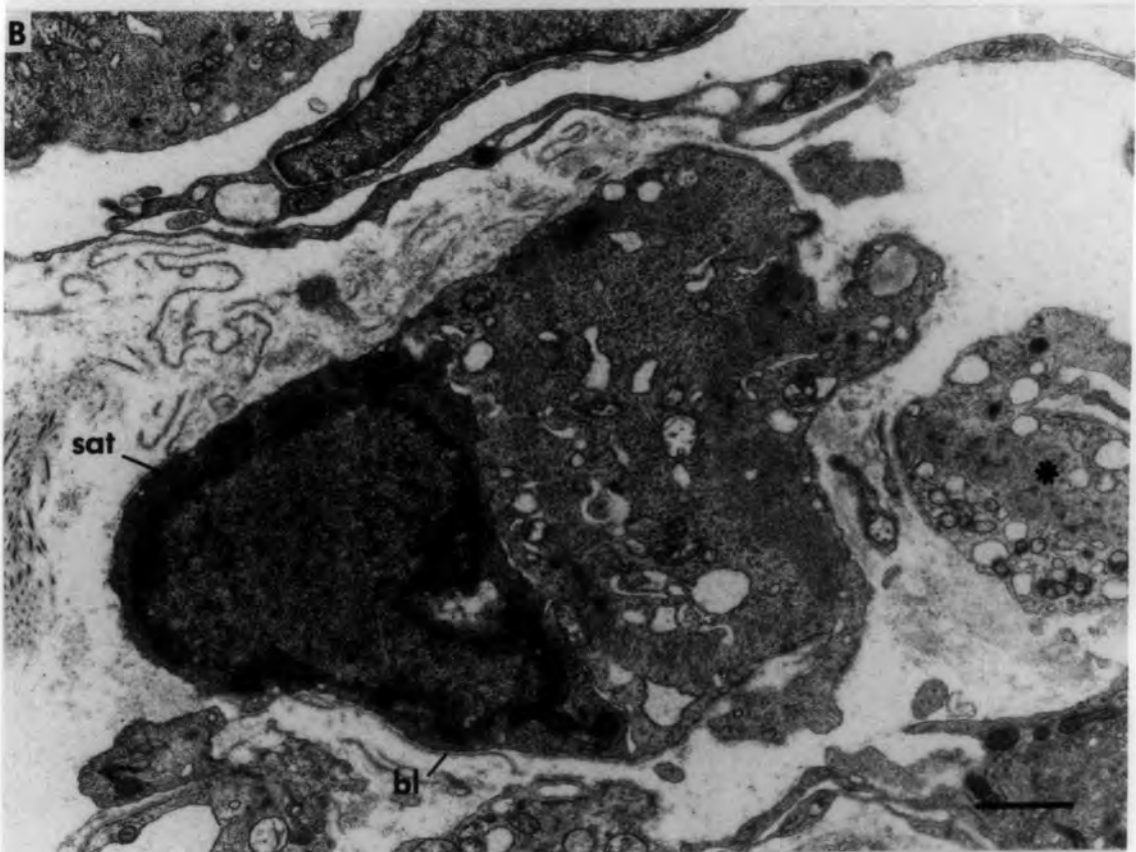
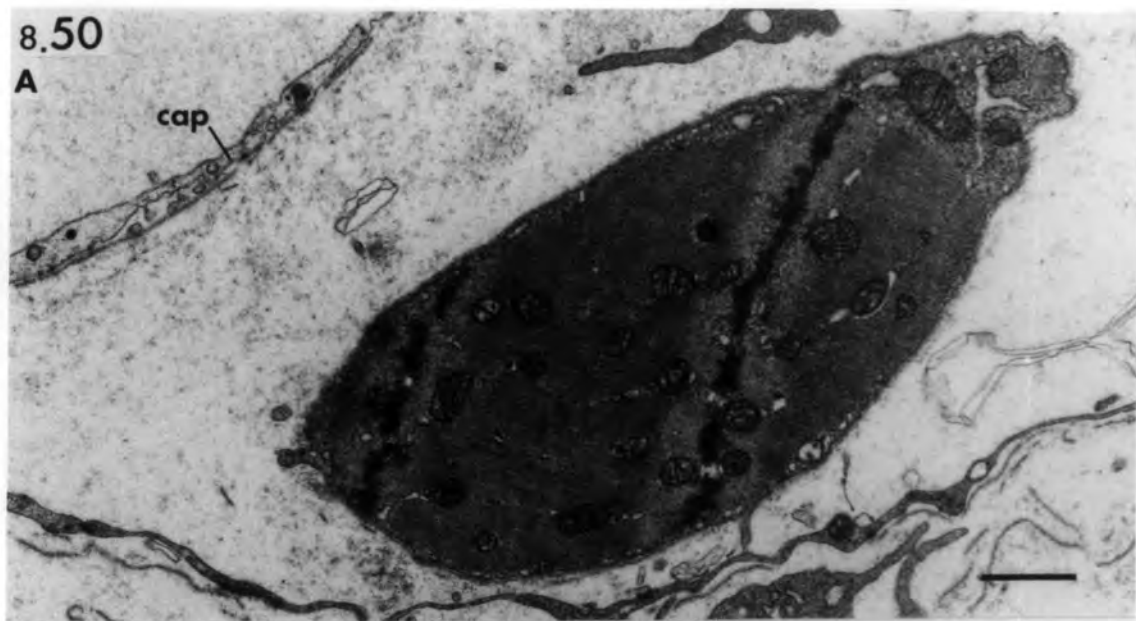


Fig. 8.51 Ischaemic muscle spindle 28 days after  
devascularization.

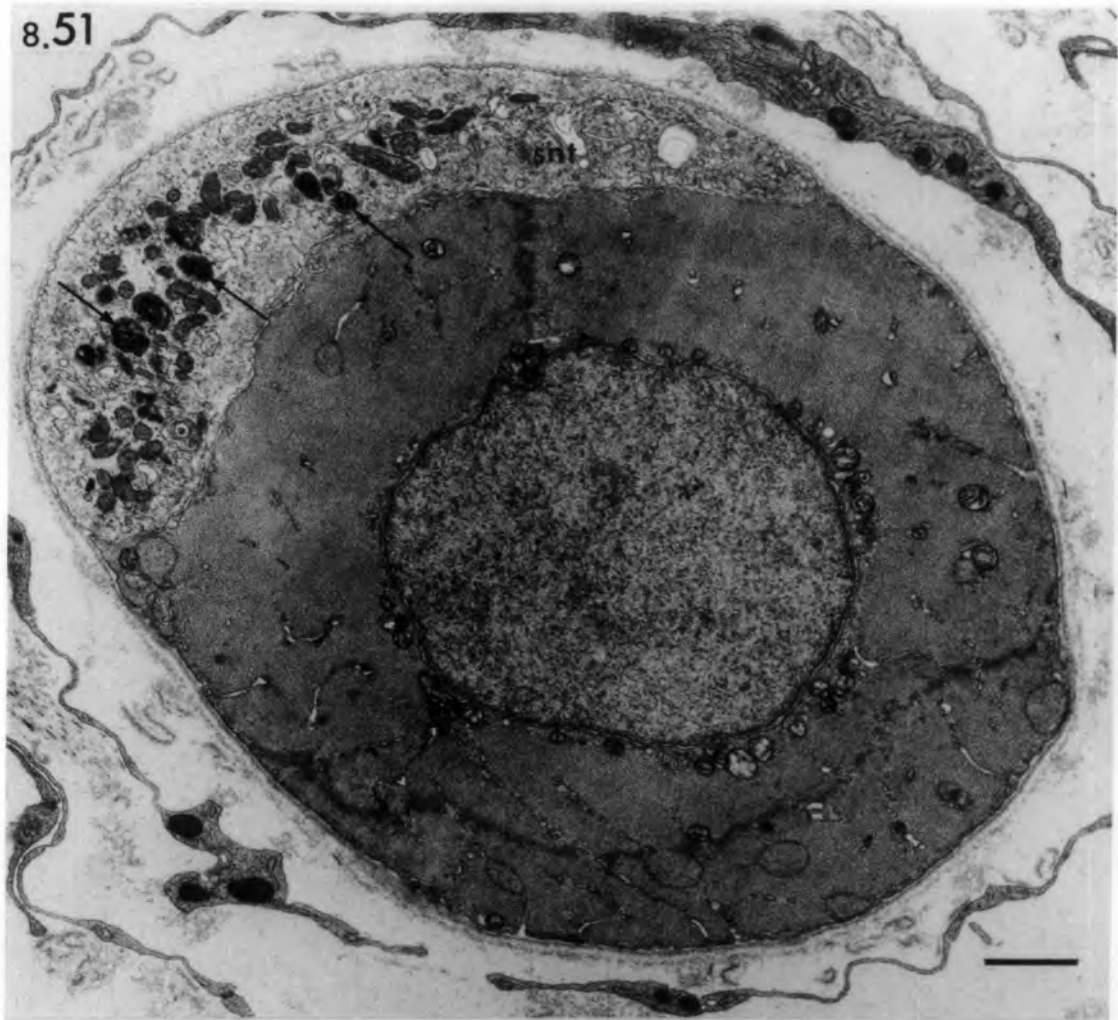
Transverse section of the equatorial region showing a regenerated sensory terminal of normal appearance. Several myelin figures (arrows) are present.

Fig. 8.52 Ischaemic muscle spindle 56 days after  
devascularization.

Transverse section of intrafusal fibre in the juxta-equatorial region showing regenerated motor nerve terminal and shallow postjunctional folds (arrow head) in a sole-plate with nucleus. Arrow points to a multilamellated structure.  
v: synaptic vesicles.

bars = 1µm

8.51



8.52

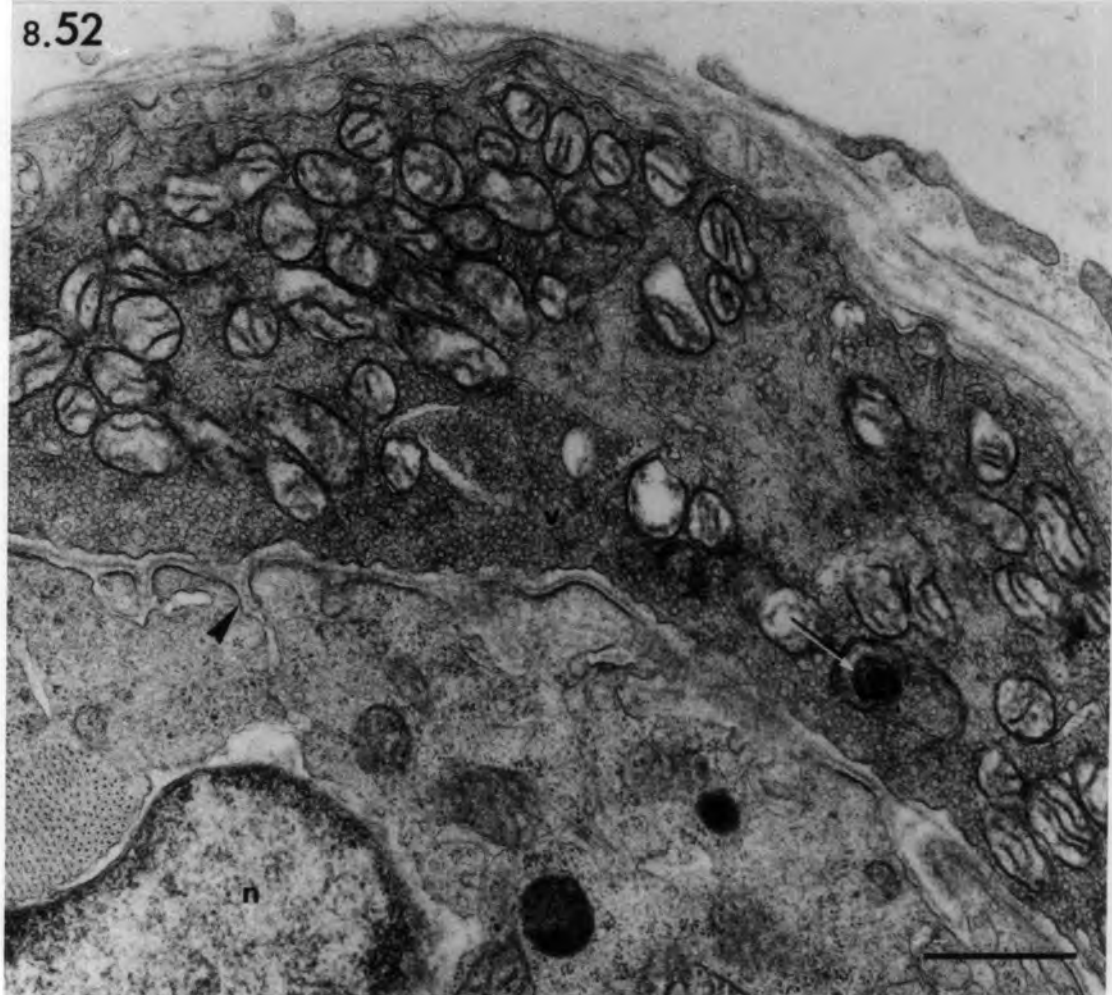


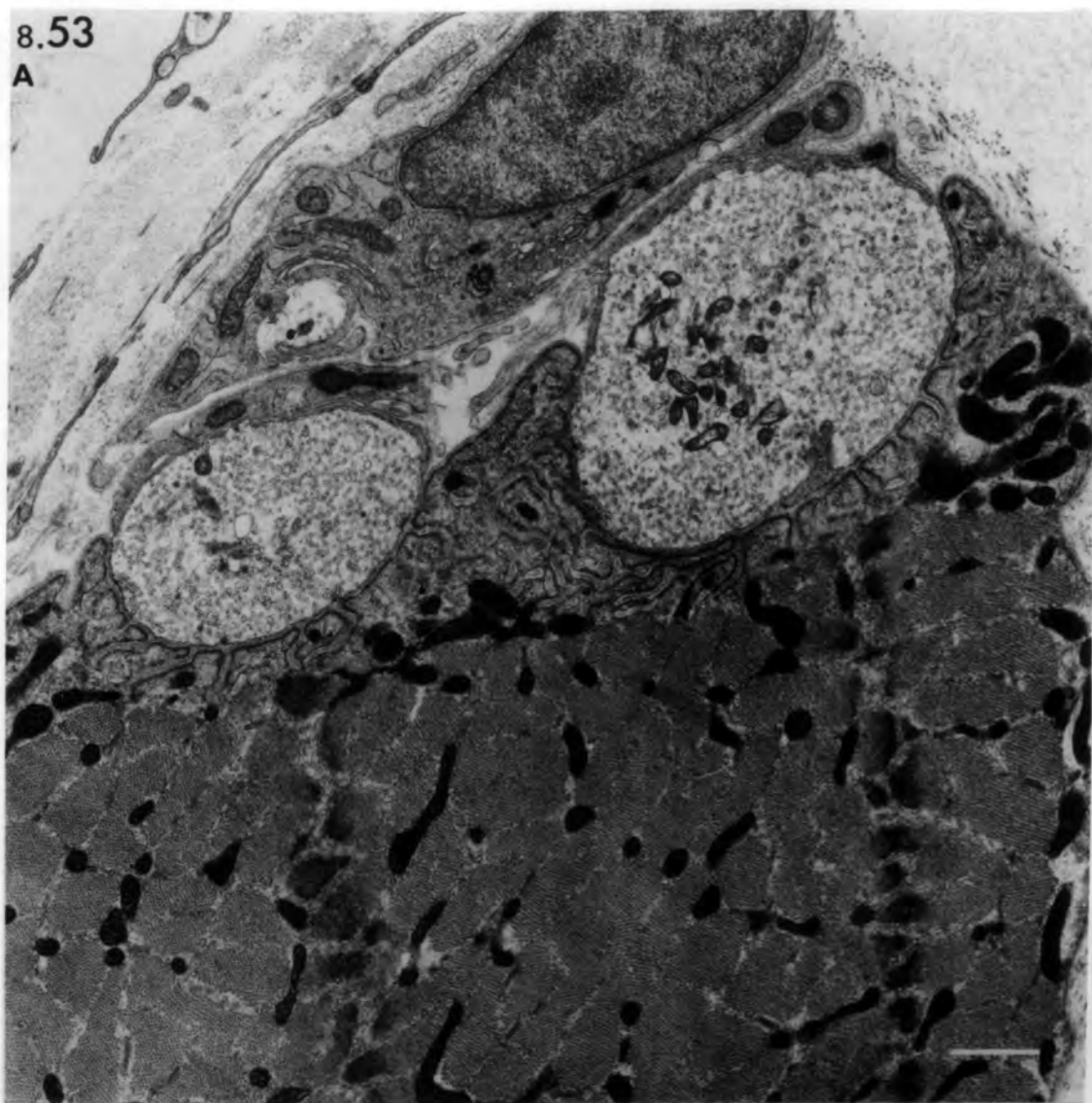
Fig. 8.53 Ischaemic muscle spindles showing abnormal  
motor nerve terminals

- A. Transverse section of an intrafusal fibre in the extracapsular polar region 42 days after devascularization. The abnormal motor end-plate, with well-developed branched post-junctional folds (arrow head), resembles extrafusal motor endings (compare with Fig. 6.31).
- B. Longitudinal section of an intrafusal fibre in the intracapsular polar region 56 days after devascularization. Note the degenerated motor nerve terminal engulfed by a Schwann cell lying close to the fibre. The dense material (arrows) resembles the honeycomb structures shown in Fig. 8.29.

bars = 1 $\mu$ m

8.53

A



B

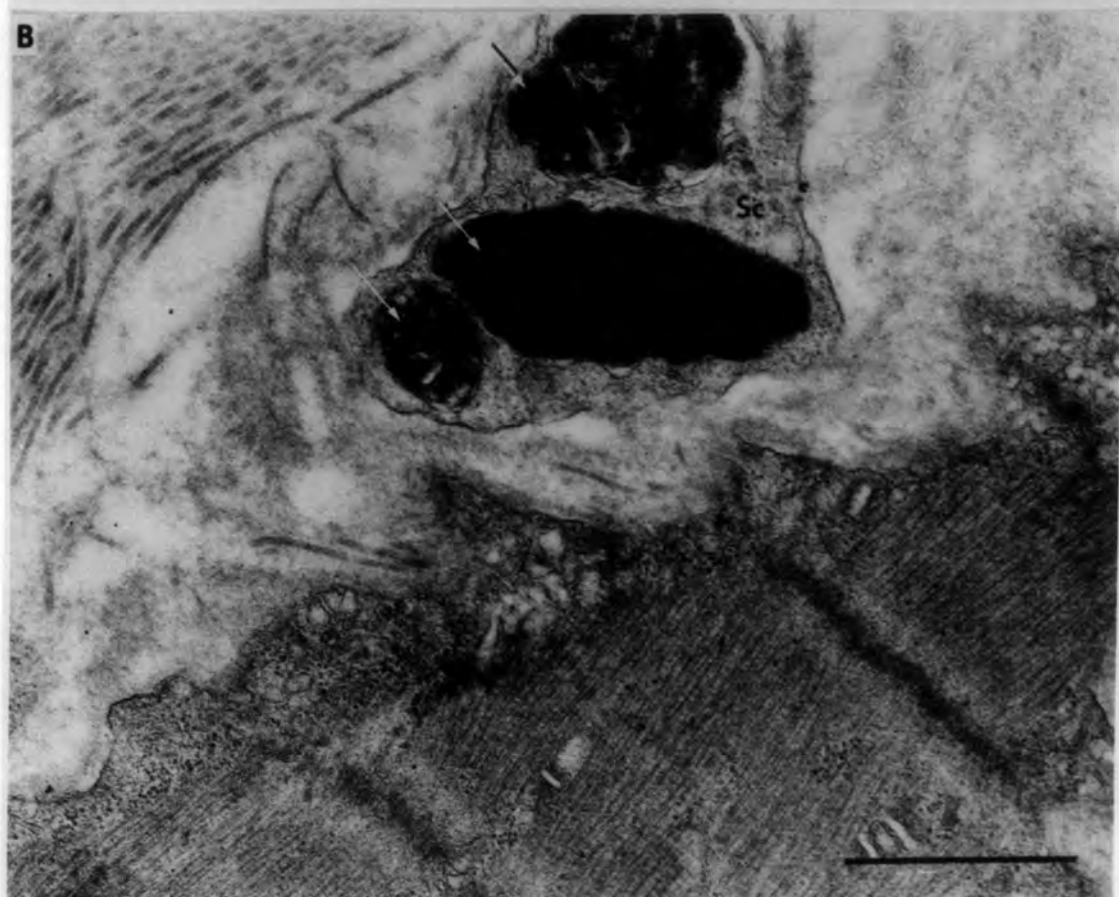


Fig. 8.54 Ischaemic muscle spindles

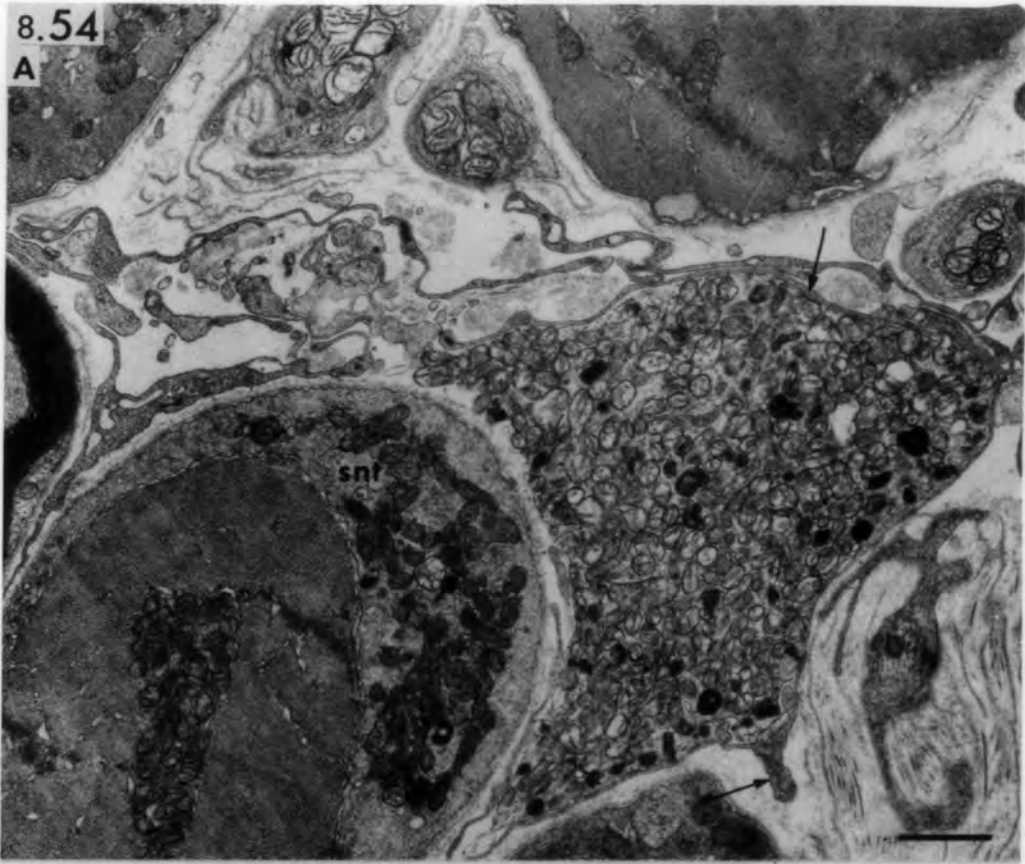
Transverse sections of the equatorial region showing free nerve terminals.

- A. Free terminal located between the intrafusal fibres and incompletely surrounded by axial-sheath cell processes (arrows). (56 days after devascularization.)
  
- B. Free terminals in the periaxial space and enclosed by Schwann-cell processes (Sc). (182 days after devascularization.)
  
- C. Free terminal in the periaxial space that lacks enclosing Schwann-cell processes (182 days after devascularization). Arrow points to axial-sheath cell process.

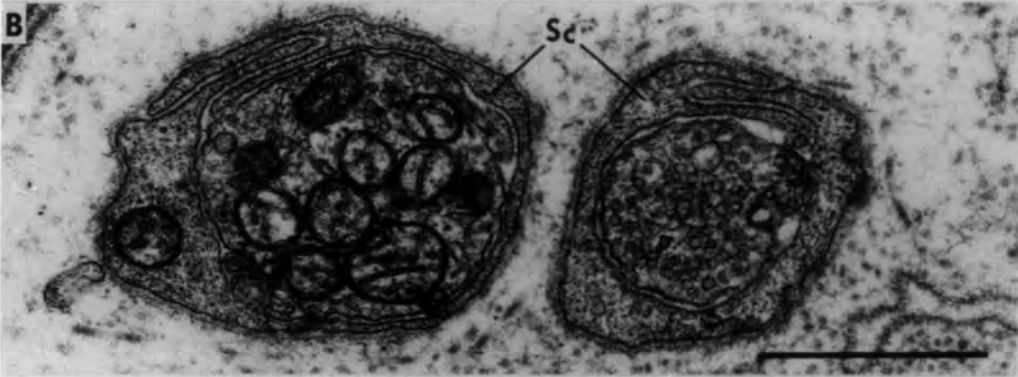
bars = 1µm

8.54

A



B



C

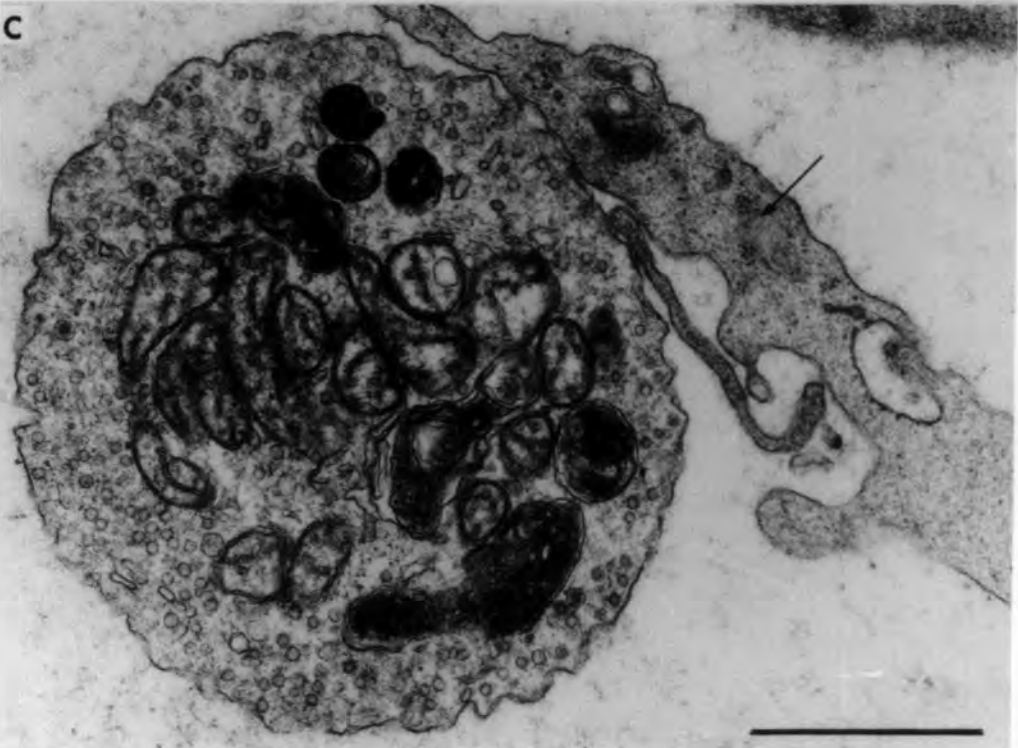


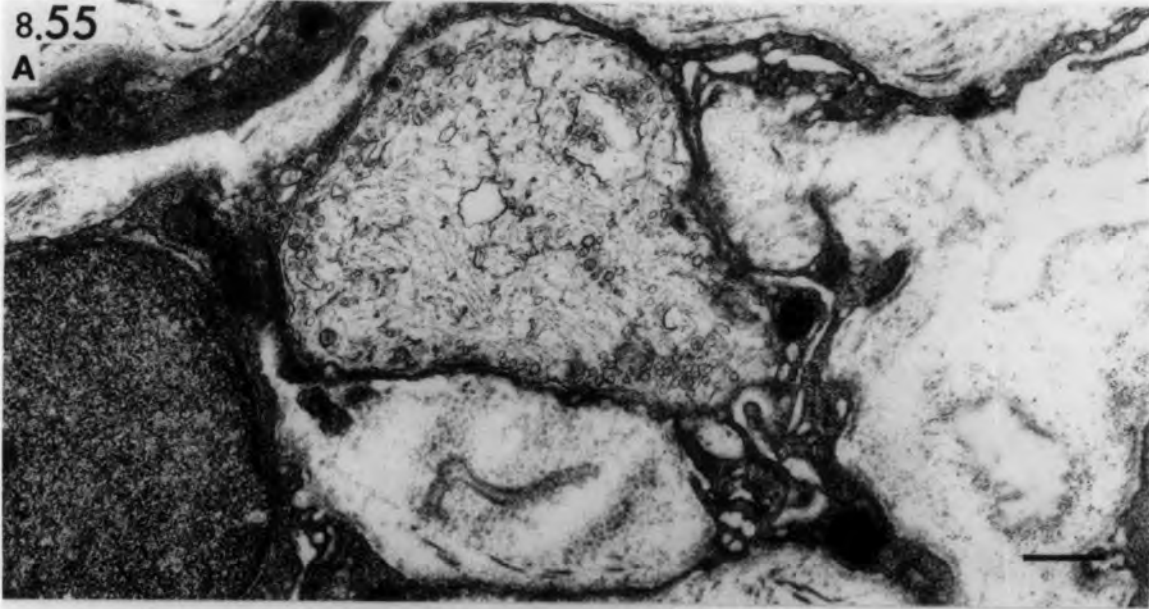Fig. 8.55 Ischaemic muscle spindle 182 days after  
devascularization.

Transverse sections of intracapsular polar  
region showing free nerve terminals between  
capsule layers.

A & B bars = 0.5 $\mu$ m

8.55

A



B

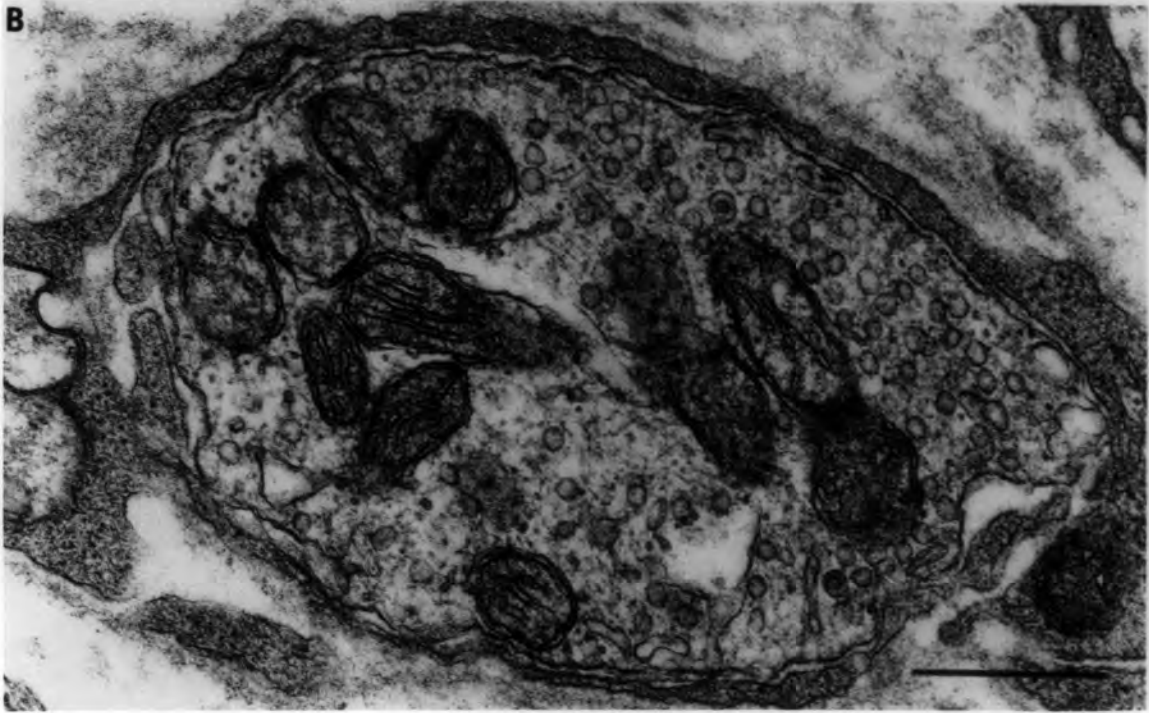


Fig. 8.56 Ischaemic muscle spindles

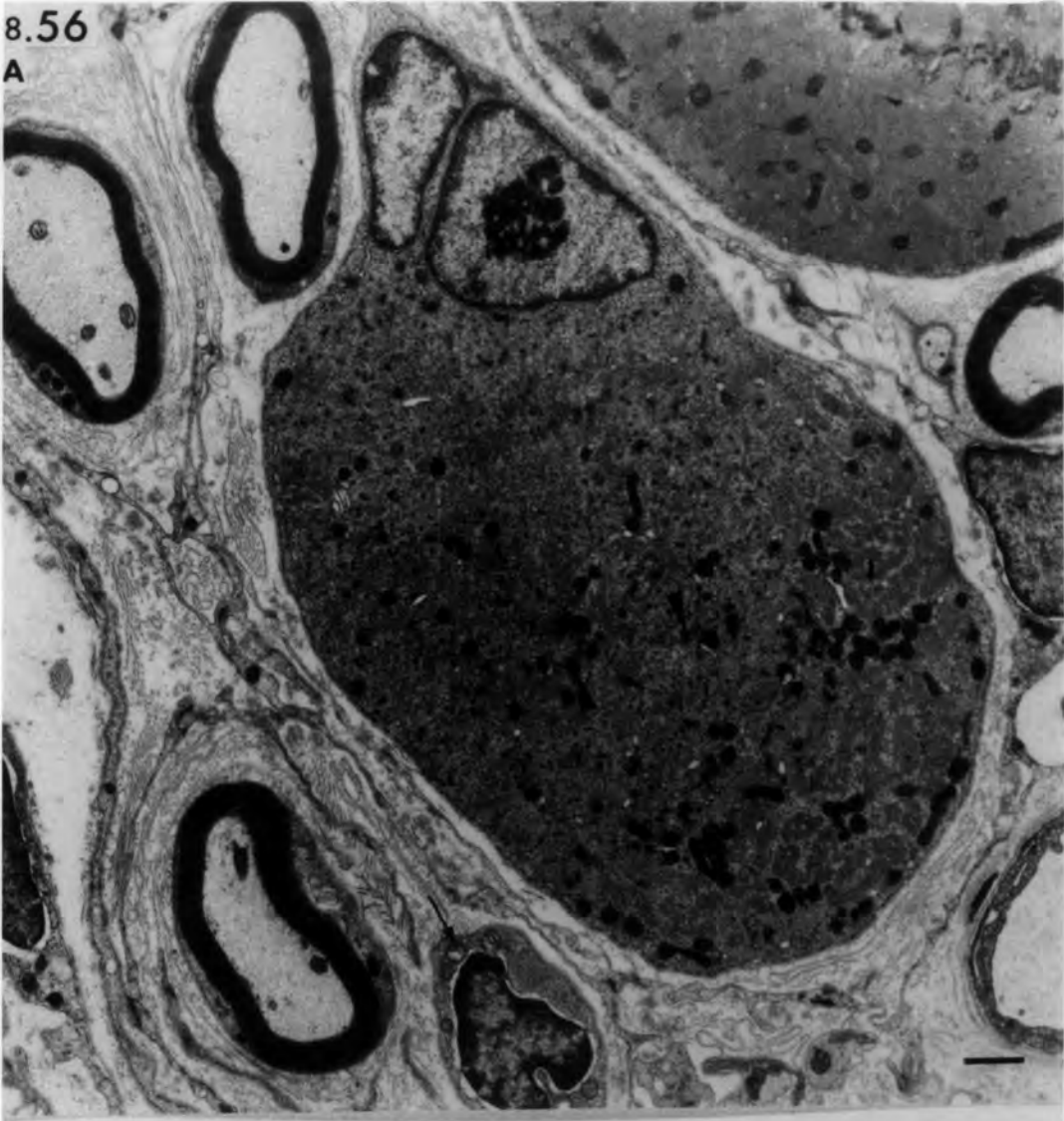
Intrafusal fibres exhibiting denervation atrophy.

- A. Transverse section of the equatorial region of an intrafusal fibre from a group 4B spindle. Note the dense granules (arrow heads) produced by the disintegration of the Z-lines. Compare with the intrafusal fibre shown in Fig. 9.21B. Arrow points to small atrophied muscle fibre. Part of a normal intrafusal fibre is seen in the top right hand corner. (56 days after devascularization.)
- B. Transverse section of the intracapsular region of an intrafusal fibre from a group 4A spindle. Note the helical complex (hc), tubular masses (asterisks), myelin figures (arrow.) and proliferated sarcotubular system (SR). Arrow head points to a ring of basal lamina. (182 days after devascularization.)

bars = 1µm

8.56

A



B

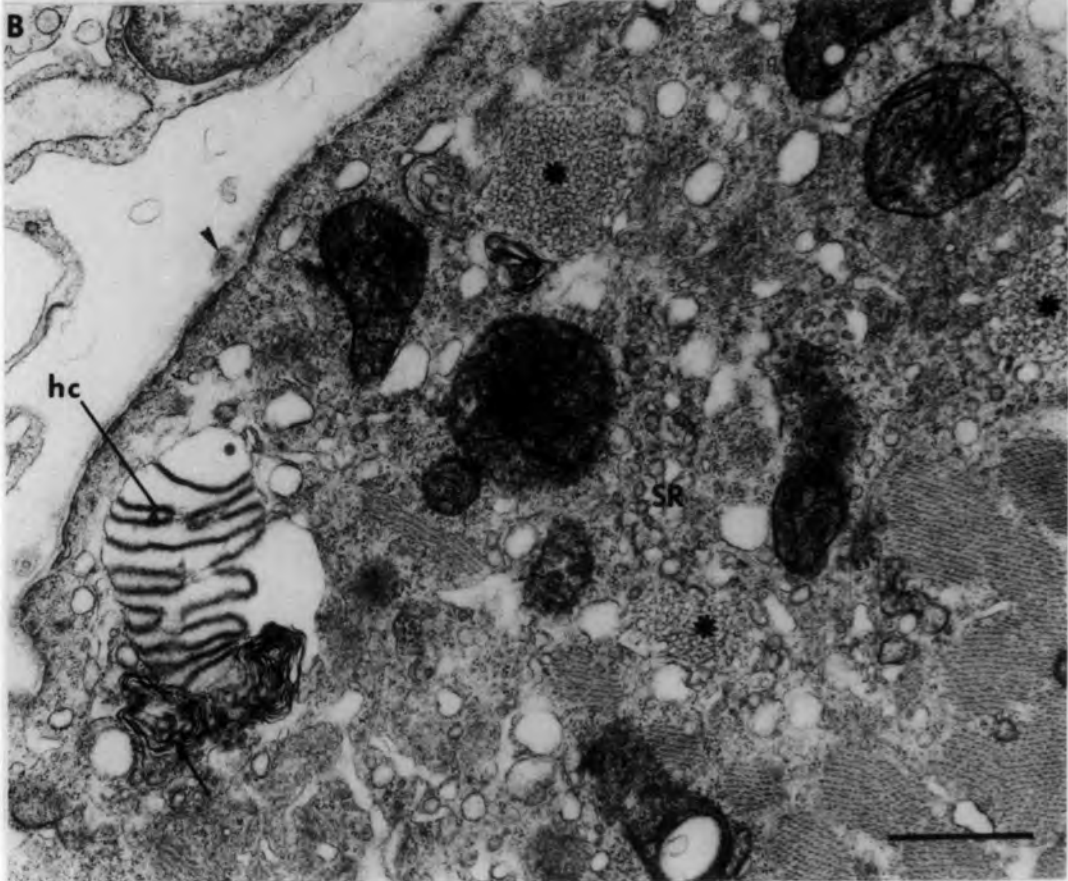


Fig. 8.57 Ischaemic muscle spindle 56 days after  
devascularization.

Longitudinal sections of the intracapsular polar region of intrafusal fibres from a group 4B spindle.

- A. Low power to show the capsule (cap) crowded with collagen and elastic fibrils, a blood vessel (arrow), myelinated axons (ax) and thin muscle fibres.

bar = 10 $\mu$ m

- B. High power showing the normal structure of the intrafusal fibre and abundance of collagen (cf) and elastic fibrils (ef).

bar = 1 $\mu$ m

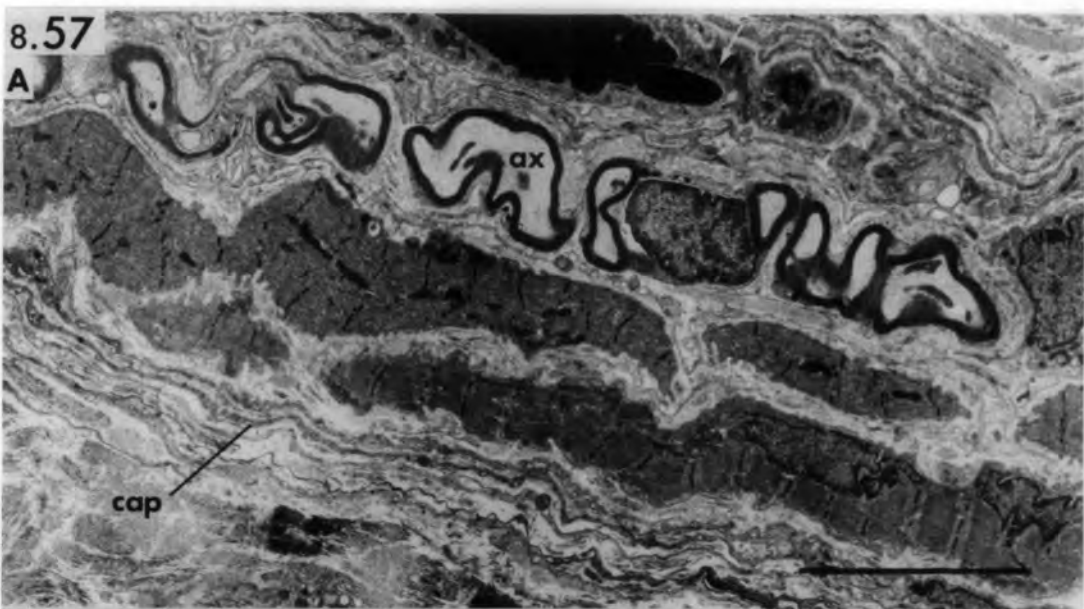
- C. High power of another intrafusal fibre undergoing denervation atrophy. Note the paucity of myofilaments and the extensive concentric membranes with dense granules (asterisks).

Compare with Fig. 9.24.

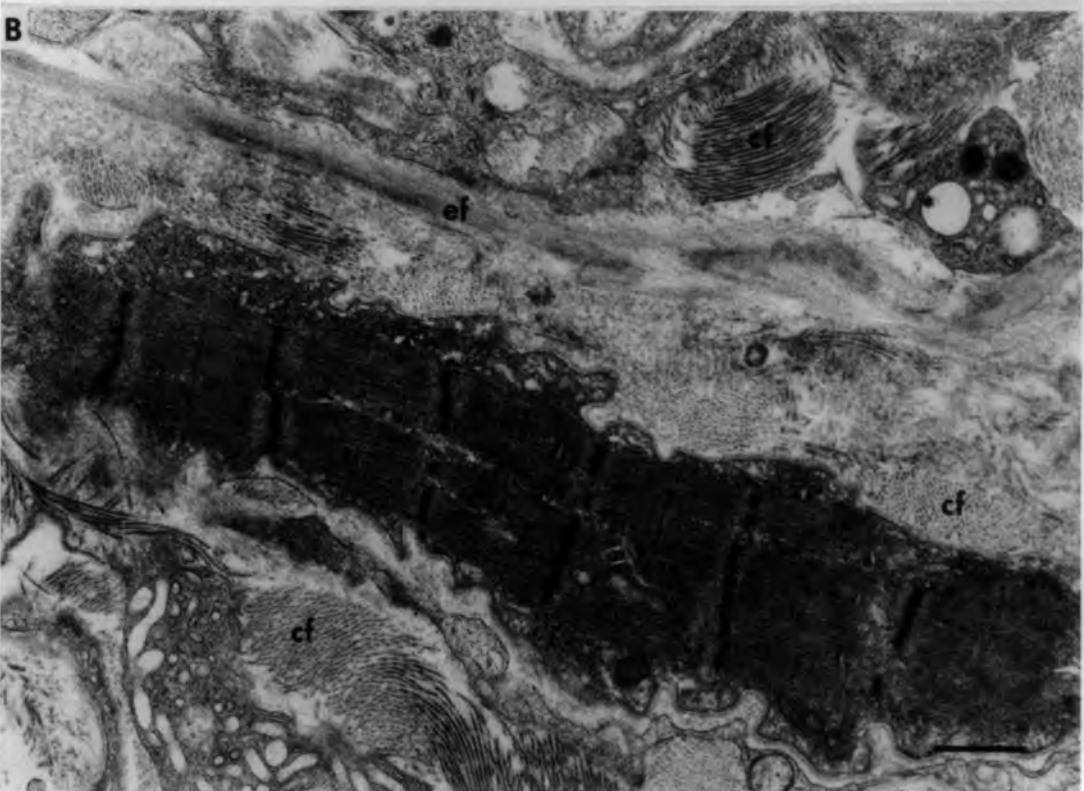
bar = 1 $\mu$ m

8.57

A



B



C

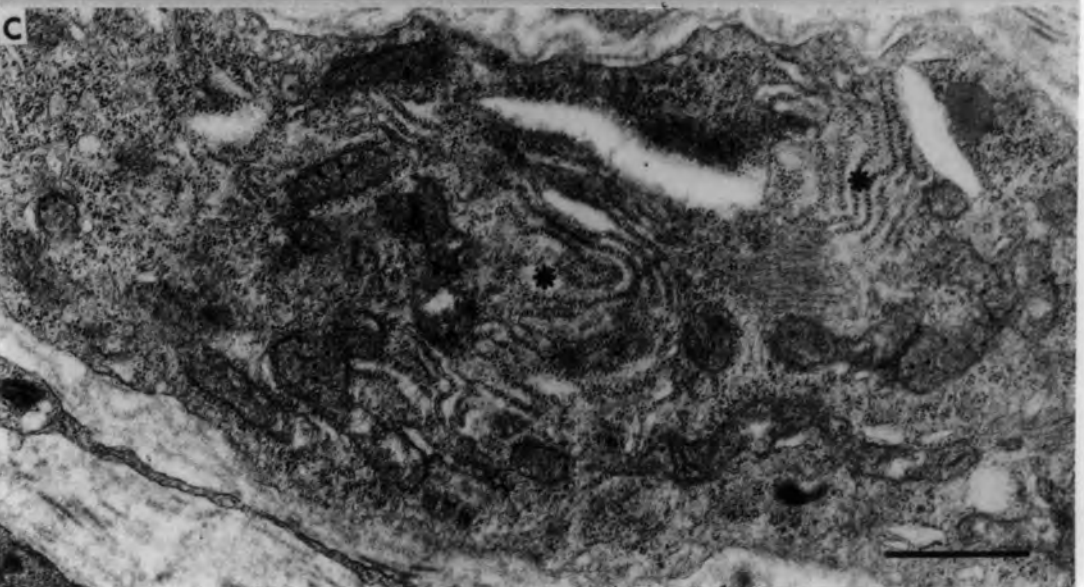

Fig. 9.1 Schematic diagram illustrating the effects of the various experimental lesions on intrafusal muscle fibres.


Intrafusal muscle fibres in series Isch, Isch/Dn and Isch/Rn/Dn (see methods for description of experimental procedures) degenerate in the first five days after revascularization.

Although presumptive myoblasts are present beneath the basal lamina as early as day 2, the recognisable process of muscle-fibre regeneration begins at about day 3 and is complete by day 21.

In the two series Isch and Isch/Rn/Dn, motor and sensory reinnervation begins at day 21 and induces the further differentiation of intrafusal muscle fibres. If the nerve supply is left intact at the time of devascularization (series Isch) no further differentiation is seen after day 28 and the intrafusal muscle fibres vary with respect to their equatorial nucleation (see Fig. 7.12). If however the muscle is denervated at day 28 (series Isch/Rn/Dn) the intrafusal muscle fibres undergo a slow process of atrophy.

In the series Isch/Dn, the muscle is permanently denervated at the time of devascularization. The intrafusal muscle fibres fail to differentiate and from day 21 begin to show signs of atrophy.

The intrafusal muscle fibres of permanently denervated muscle (series Dn) begin a slow process of atrophy probably from the time of interruption of the nerve supply and certainly after 21 days.



Muscle-fibre degeneration



Muscle-fibre regeneration



Muscle-fibre differentiation



Muscle-fibre atrophy



Experimental ischaemia



Experimental denervation

Beginning of motor and  
sensory reinnervation

Basal lamina



Fig. 9.2 Denervated muscle: transverse section of soleus muscle, 364 days after denervation.

Note the extensive atrophy of the extrafusal fibres compared with the almost normal intrafusal fibres (right), and the overall reduction in diameter of the extrafusal fibres, that vary in the degree of atrophy. Note also the increase in number and density of their nuclei. A few fibres are of normal structure (asterisk), while many others are severely atrophied (arrow heads). Arrow points to a degenerated nerve trunk.

bar = 10 $\mu$ m

9.2

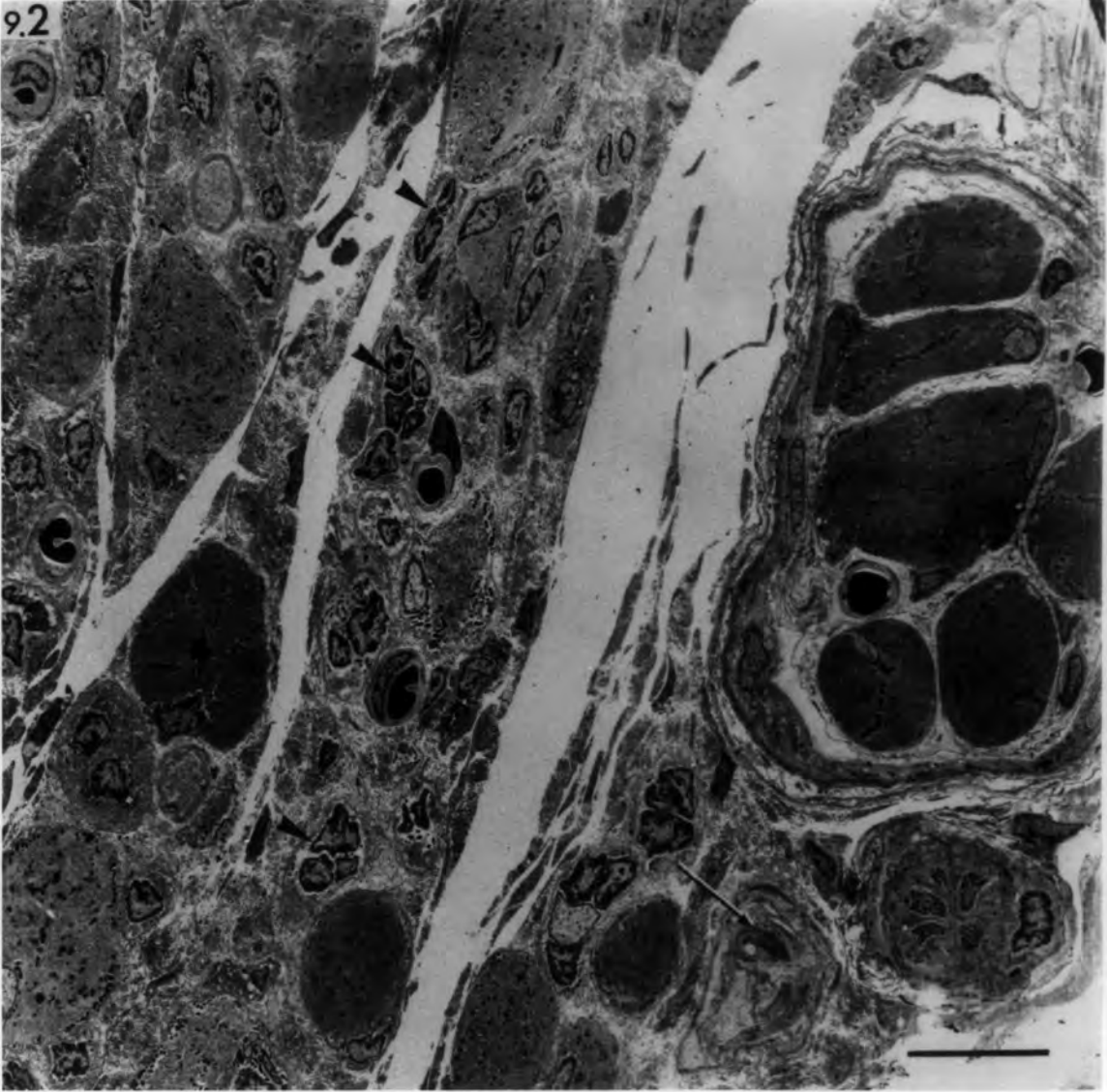


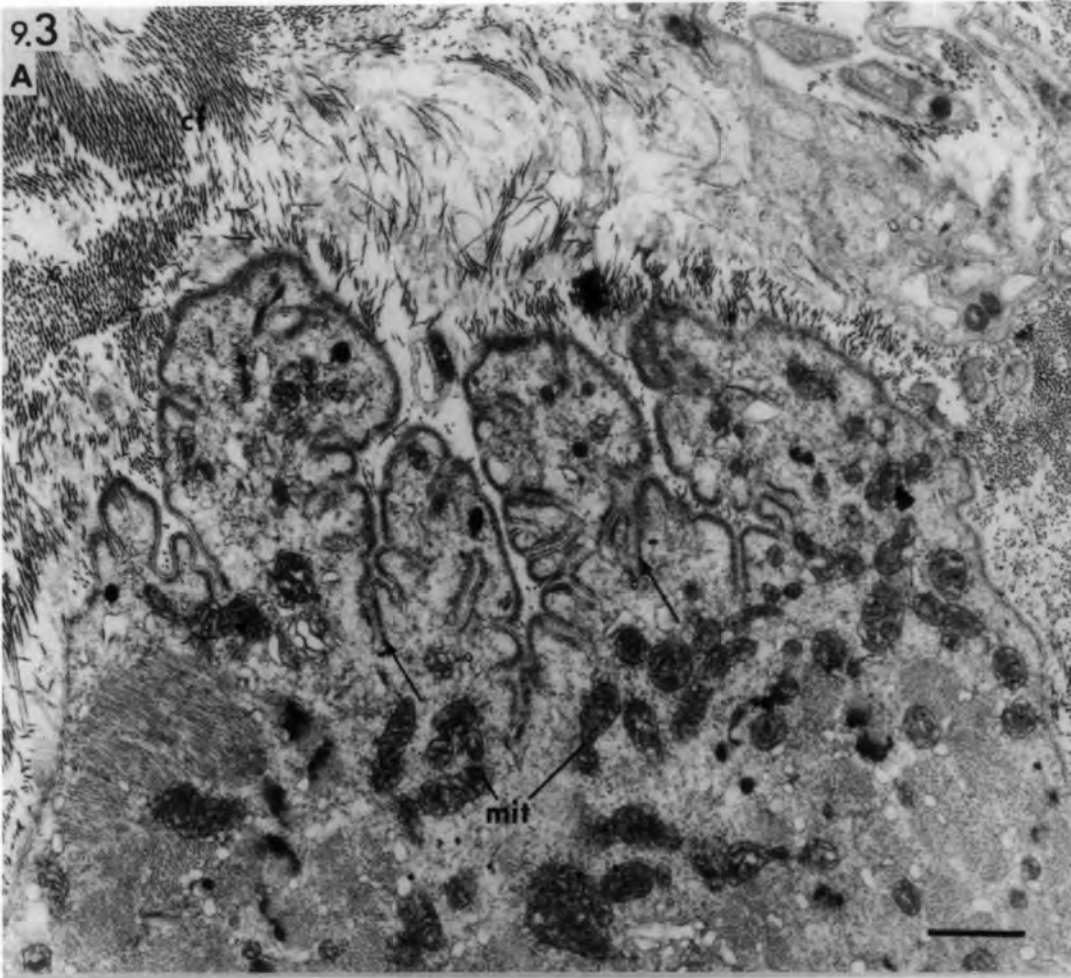Fig. 9.3 Denervated muscle, 156 days (A) and 364  
days (B) after denervation.

Transverse sections of extrafusal fibres showing persisting subneural apparatus of former motor end-plates. Note the preserved post-junctional folds (arrows) and sole-plate nuclei (n) and mitochondria (mit). The pre-synaptic site is occupied by collagen fibrils (cf) and remnants of degenerated Schwann cells may be present (Sc in B).

bar = 1µm

9.3

A



B

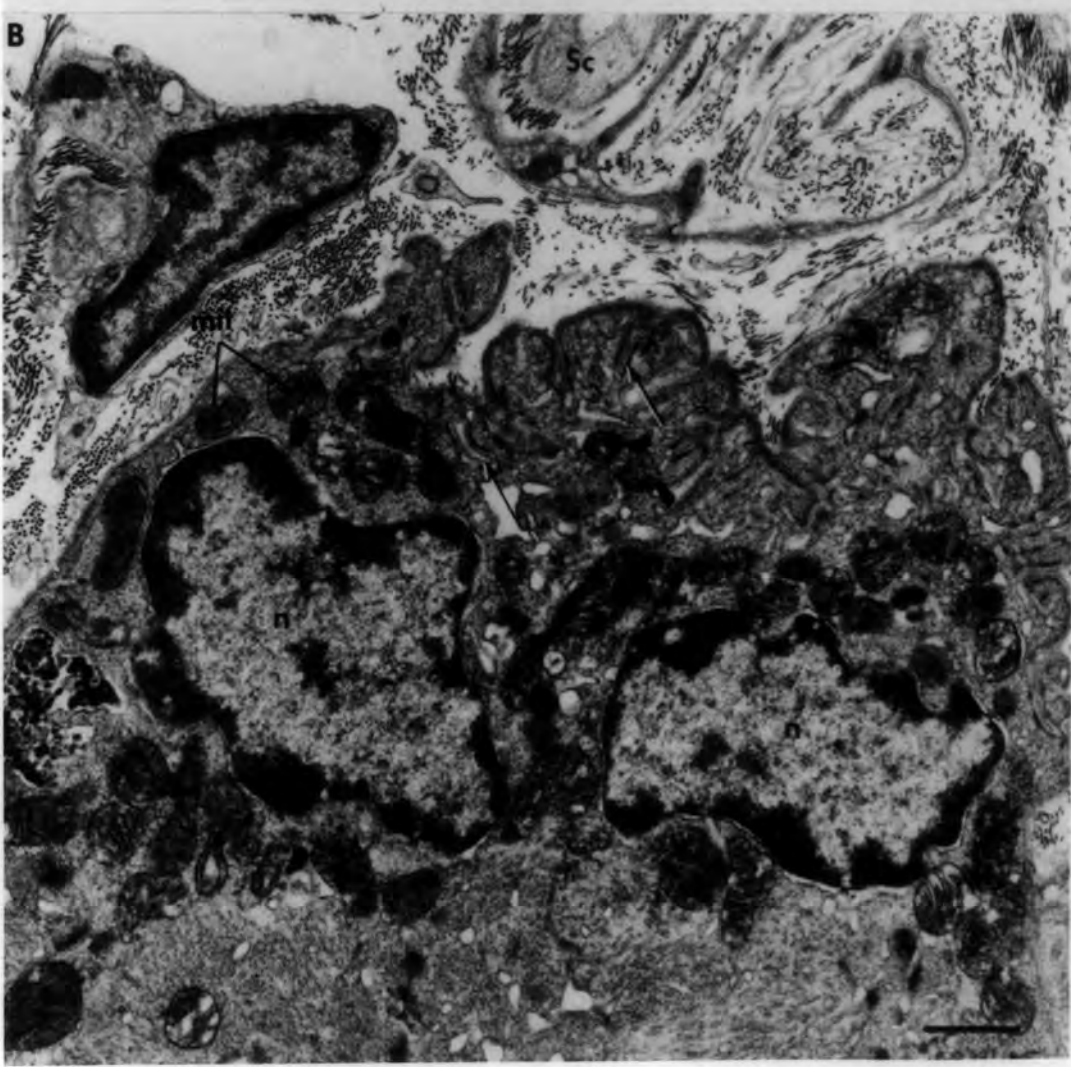


Fig. 9.4 Denervated muscle

Transverse section of extrafusal fibres, 156 days after denervation. Note the disorganized myofibrils, disintegration and streaming of Z-line (arrow heads), indented nuclei (n), helical complex (hc) in the severely-atrophied fibre and sarcolemmal invaginations (arrow). Note the irregular contour of the large fibre, the projection containing a nucleus (n) around a capillary (cpl), and the increased amount of collagen fibrils (cf) in the interstitial space.

bar = 10 $\mu$ m

Fig. 9.5 Denervated muscle

Transverse section of extrafusal fibres 364 days after denervation. In fibre F<sub>1</sub>, myofibrils are absent from the periphery and around the dense nucleus (n) whilst persisting myofibrils are surrounded by dense sarcotubular elements (arrow). In fibre F<sub>2</sub> only a few myofilaments are left around the dense nucleus. Fibre F<sub>3</sub> is severely-atrophied containing large helical complex (hc).

bar = 1 $\mu$ m

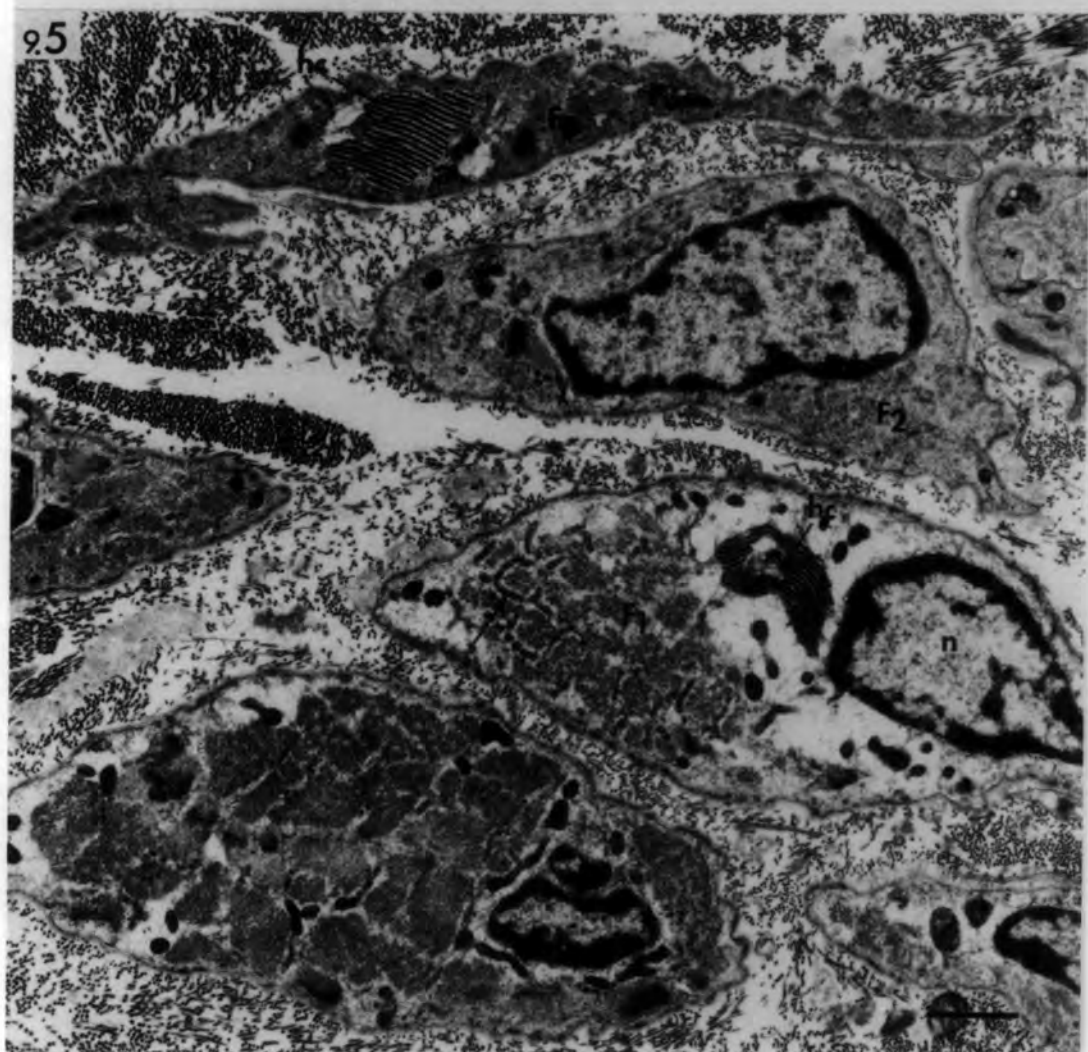
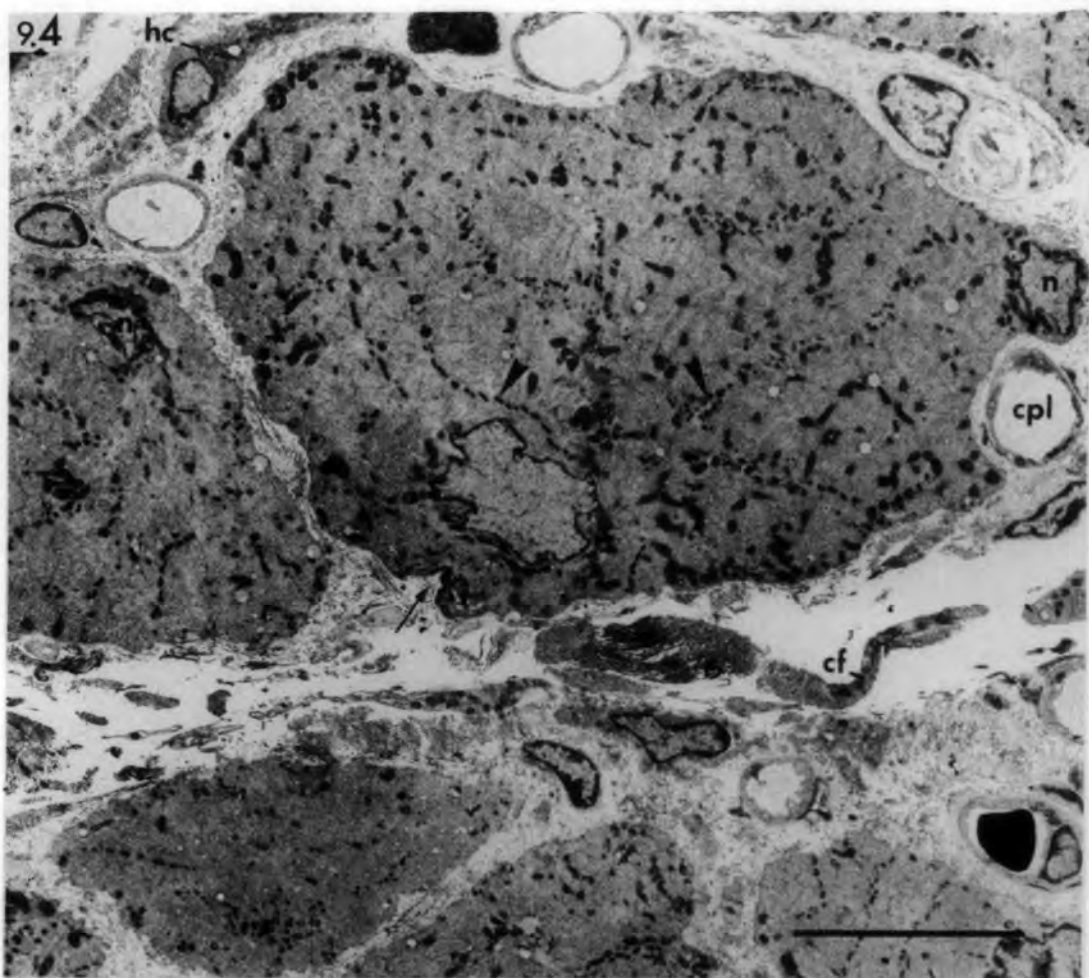


Fig. 9.6 Denervated muscle

Transverse section of atrophied extrafusal fibres 364 days after denervation. The peripheral myofibrils are disorganized but their filaments retain a longitudinal orientation, whereas the central zone consists of transversely orientated myofibrils that show Z-line streaming (Z). Asterisk: small severely atrophied fibre.

bar = 2 $\mu$ m

Fig. 9.7 Denervated muscle

Transverse section of atrophied extrafusal fibre 156 days after denervation. The orientation of the myofilaments is contrary to that shown in Fig. 9.6. The peripheral myofibrils are transversely orientated whilst the central myofilaments are longitudinally orientated. The large vacuole in the centre is formed by deep sarcolemmal invagination and contains debris. hc: helical complex.

bar = 2 $\mu$ m

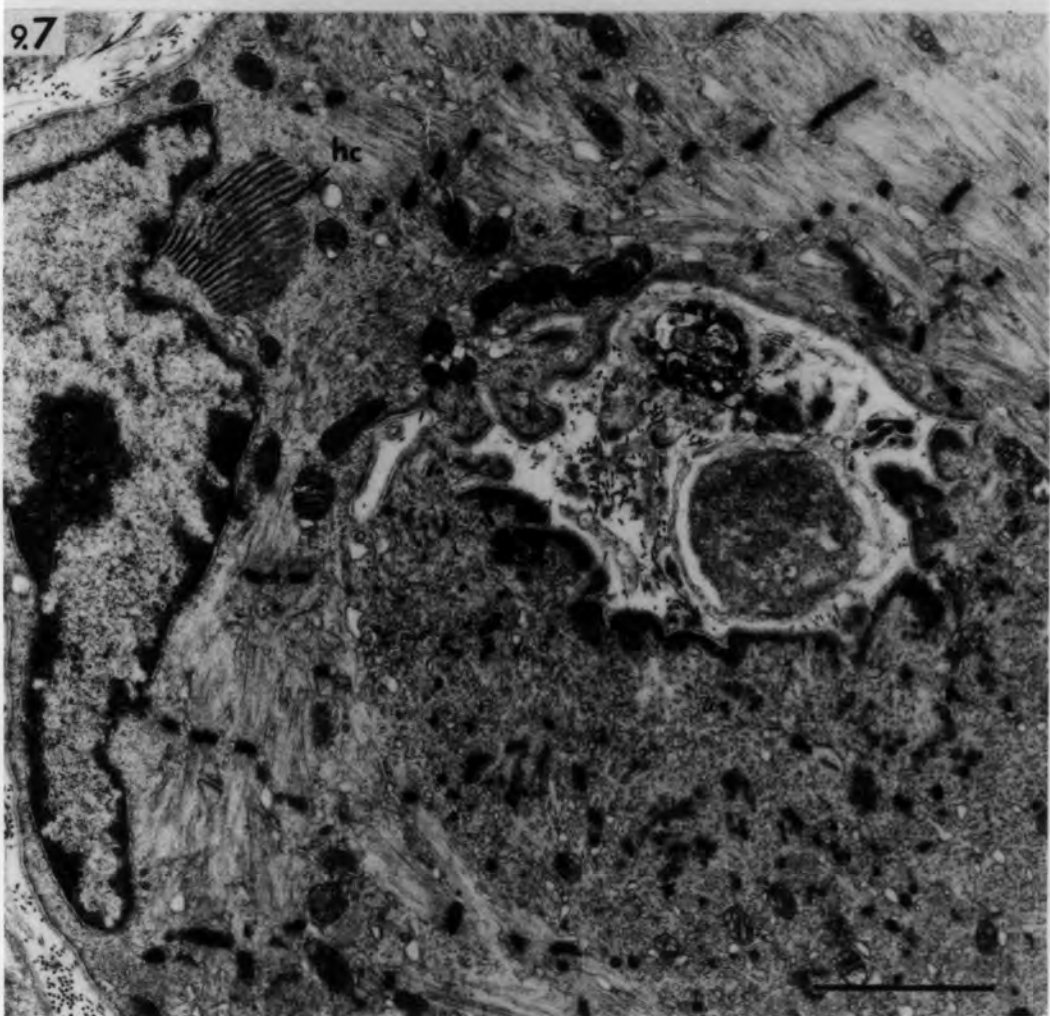
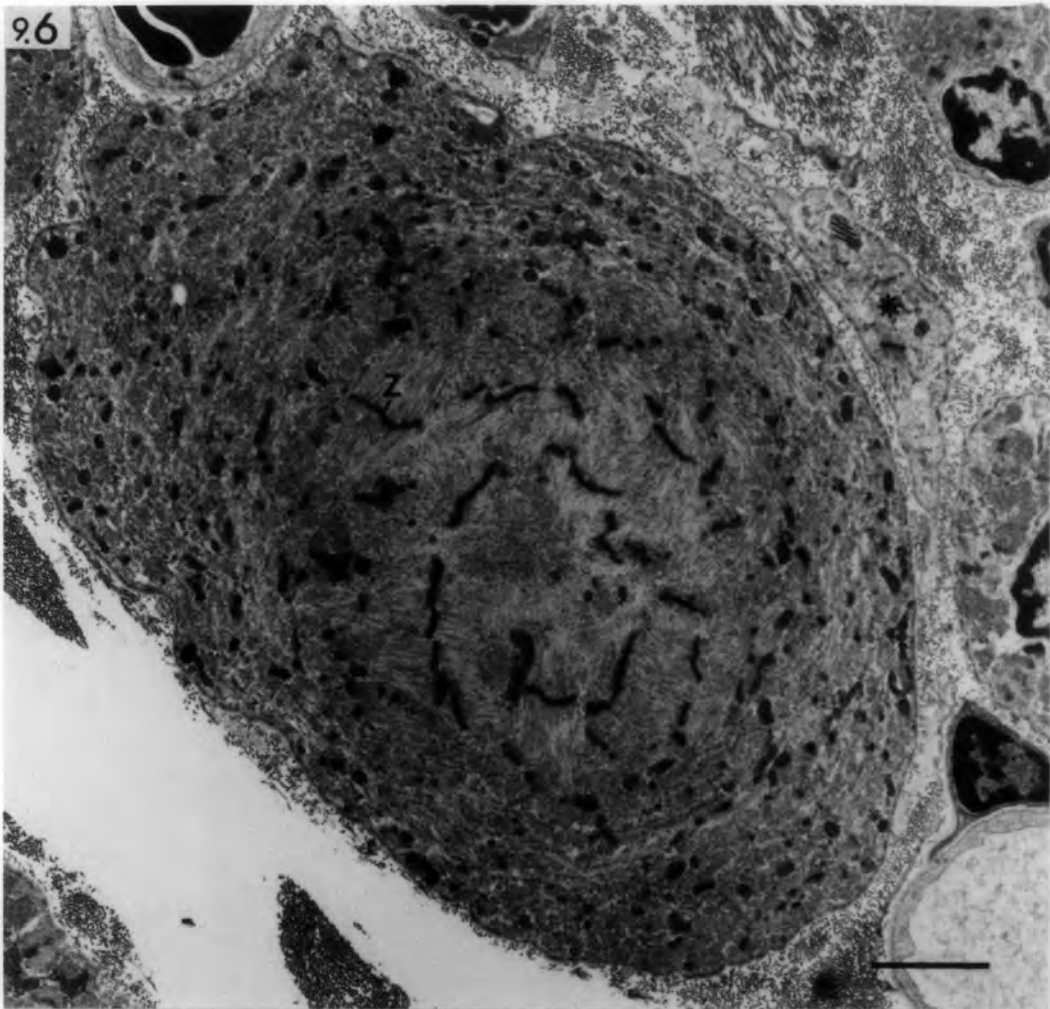


Fig. 9.8 Denervated muscle

Transverse section of extrafusal fibre  
364 days after denervation showing indented  
nucleus with projections (arrow).

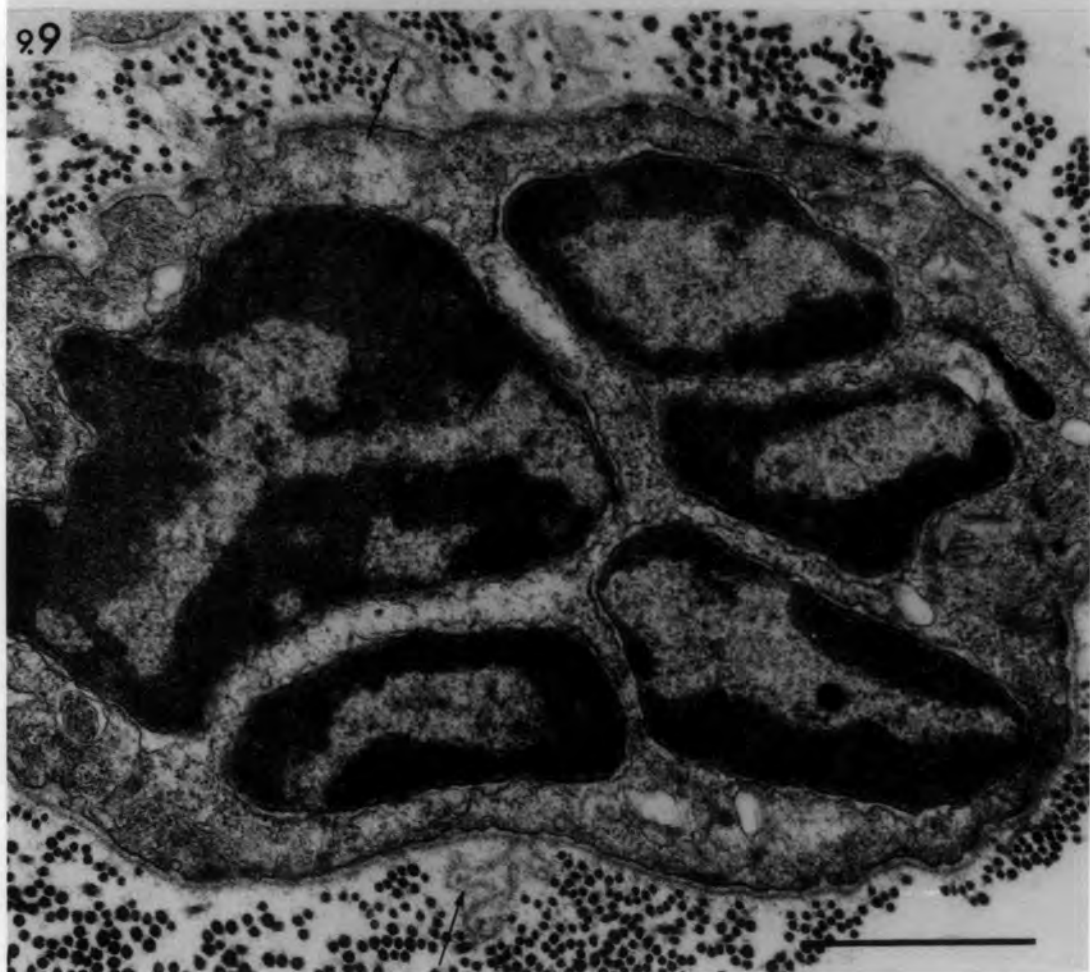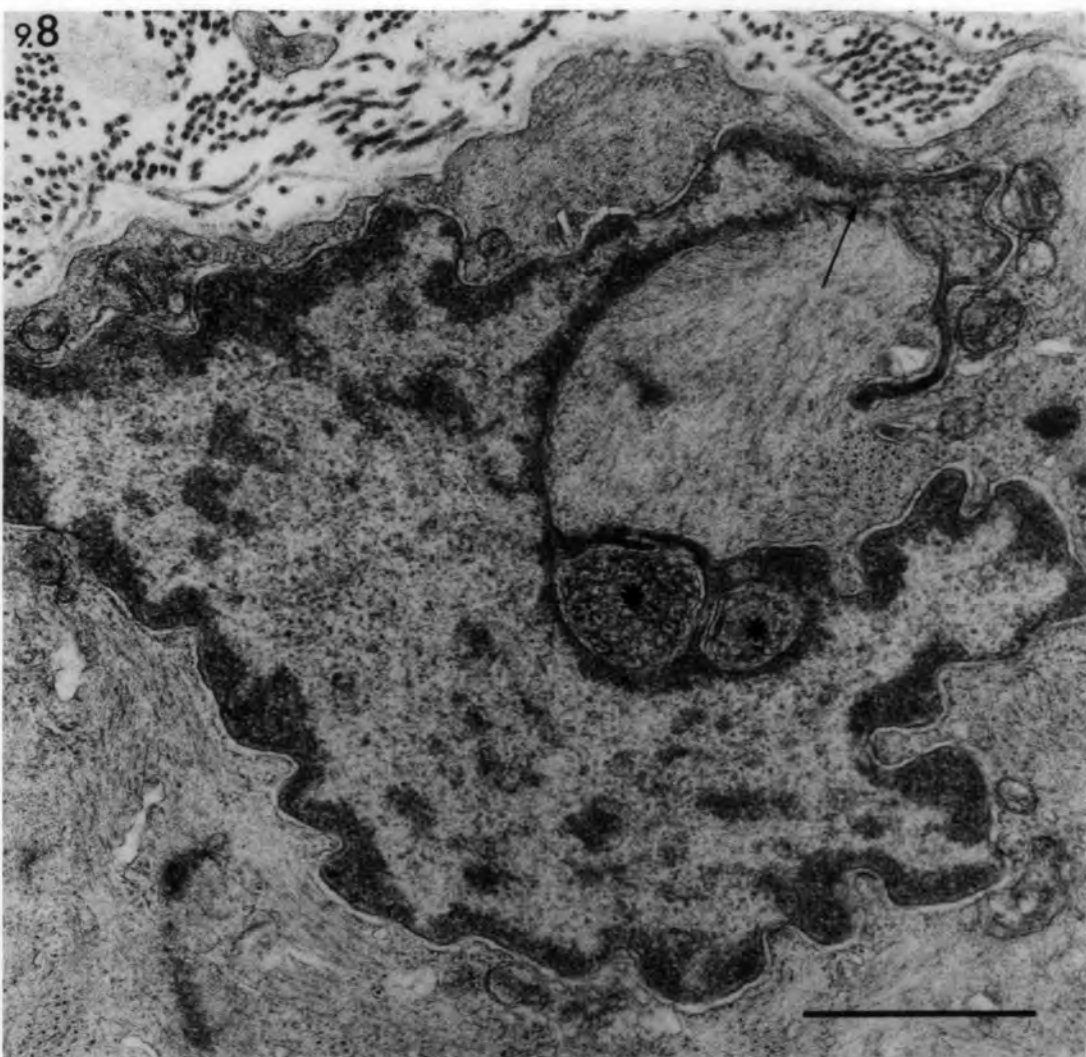
Asterisks: necrotic debris engulfed by the  
nucleus.

bar = 1µm

Fig. 9.9 Denervated muscle

Transverse section of severely atrophied  
extrafusal fibre 364 days after denervation.  
Note the dense nuclei and the high nucleo-  
cytoplasmic ratio. Arrows point to redundant  
basal lamina.

bar = 1µm



Figs. 9.10-9.12 Denervated muscle: transverse sections  
of extrafusal muscle fibres, 364 days  
after denervation.

9.10 A & B Atypical junctions (arrows in Fig. A., detailed structure in Fig. B) between sarcoplasmic reticulum (dark) and T-tubules. Note the parallel membranous structure (arrow head in Fig. A) which probably represents an early stage in the development of the helical complexes (see Fig. 9.13).

A: bar = 0.25 $\mu$ m

B: bar = 0.1 $\mu$ m

9.11 Sarcolemmal projection (arrow) and redundant basal lamina (bl).

bar = 0.5 $\mu$ m

9.12 Sarcolemmal invagination (arrow).

bar = 0.5 $\mu$ m

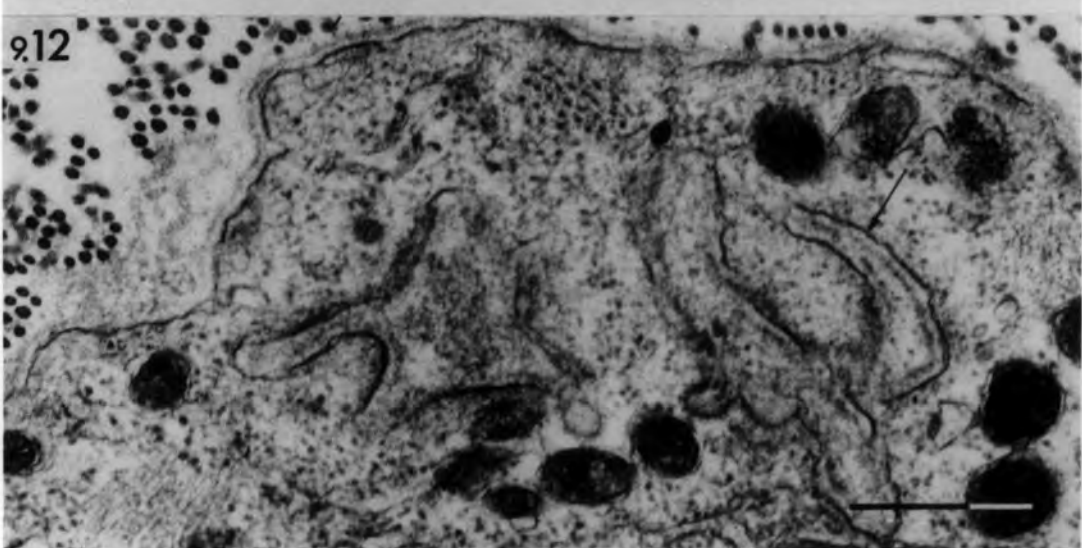
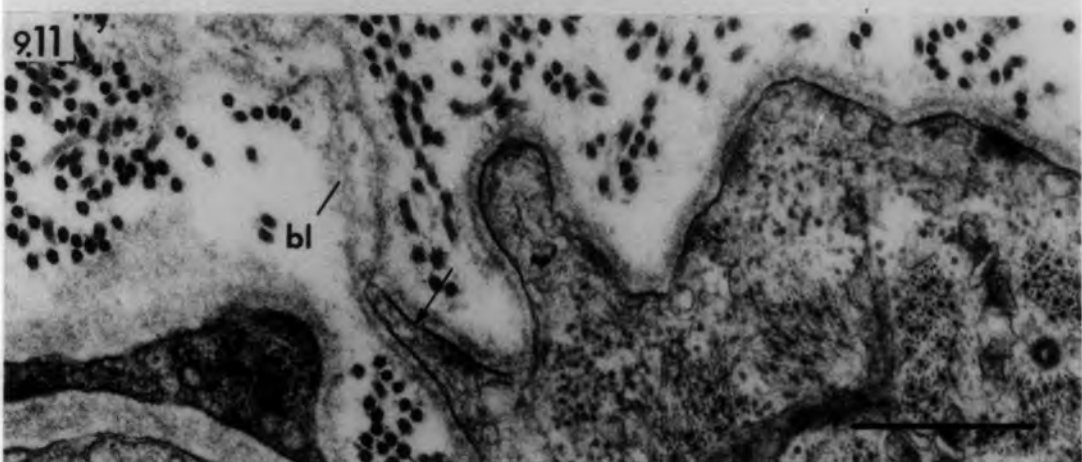
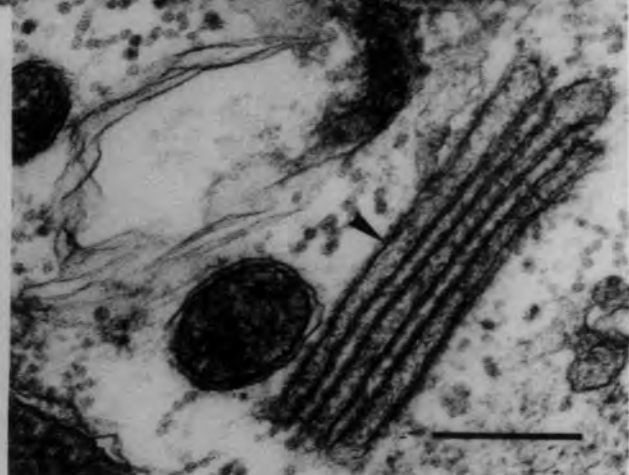
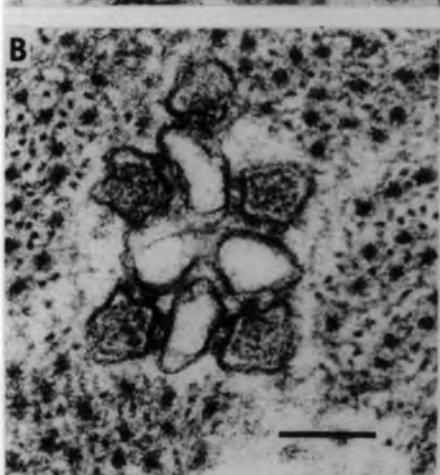
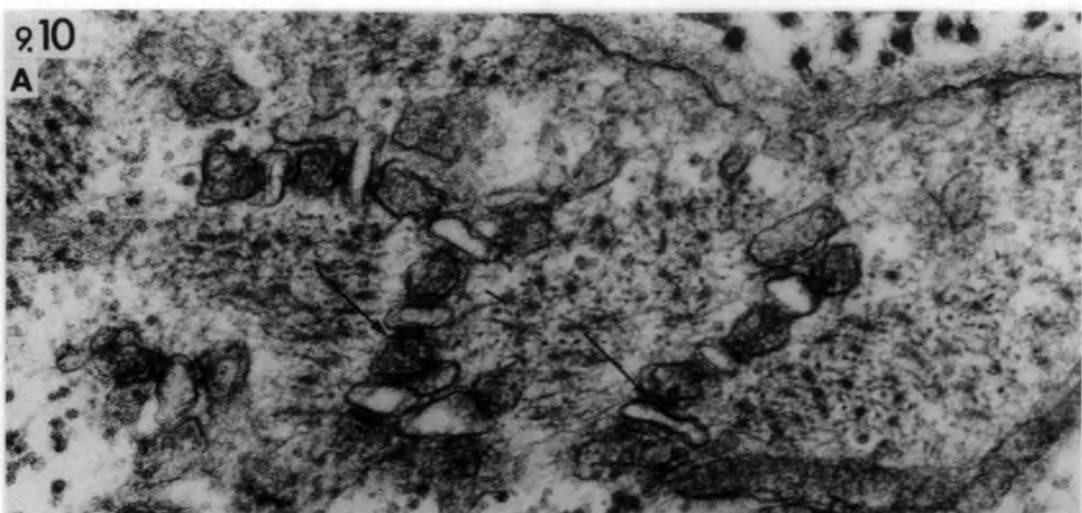


Fig. 9.13 Denervated muscle

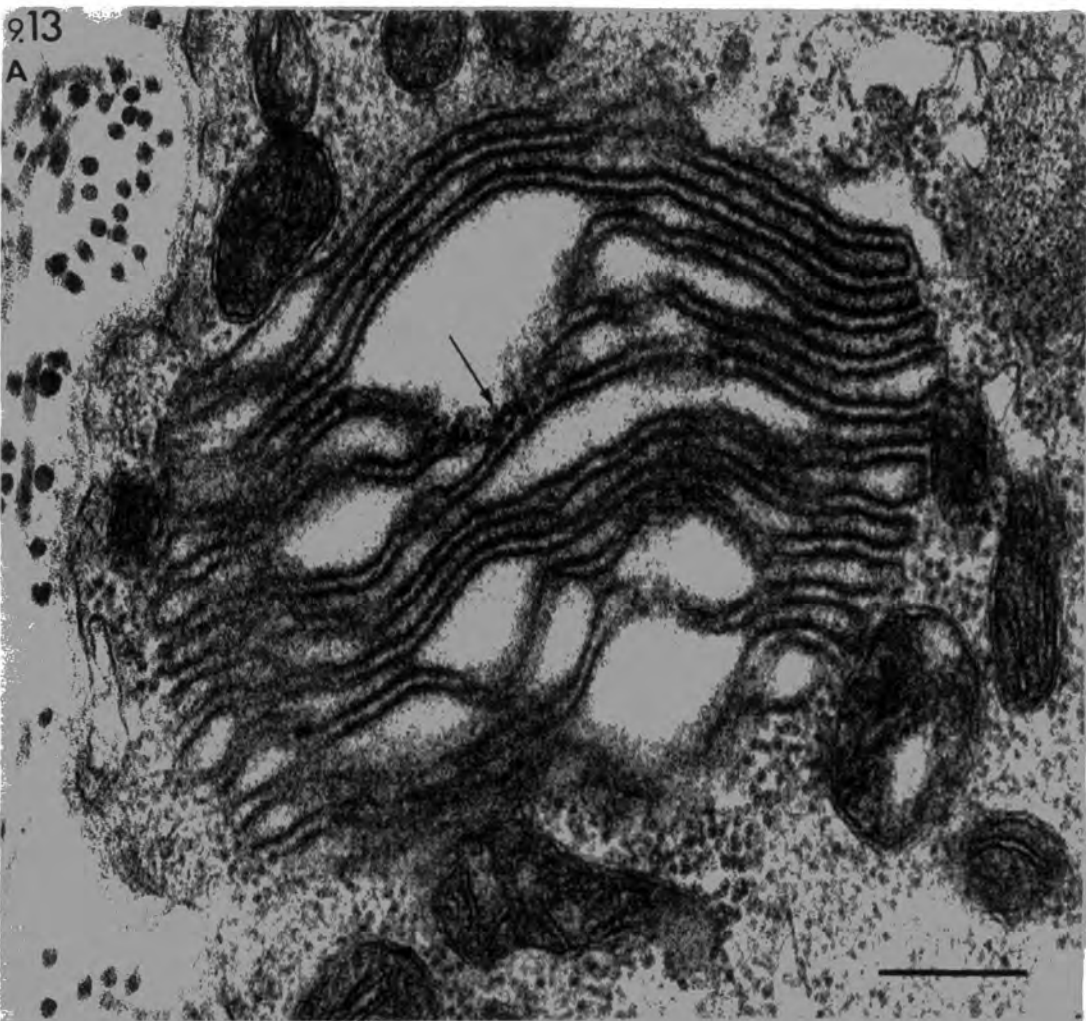
Transverse section of extrafusal muscle fibres 364 days after denervation.

Helical complexes at different stages of development (as suggested by Miledi & Slater, 1969).

- A. Early stage: simple membrane sacs with dense granular material between some membranes (arrows).
  
- B. Late stage: well-formed complex with periodically arranged densities (arrow heads) between parallel membranes.

bars = 0.25 $\mu$ m

A



B

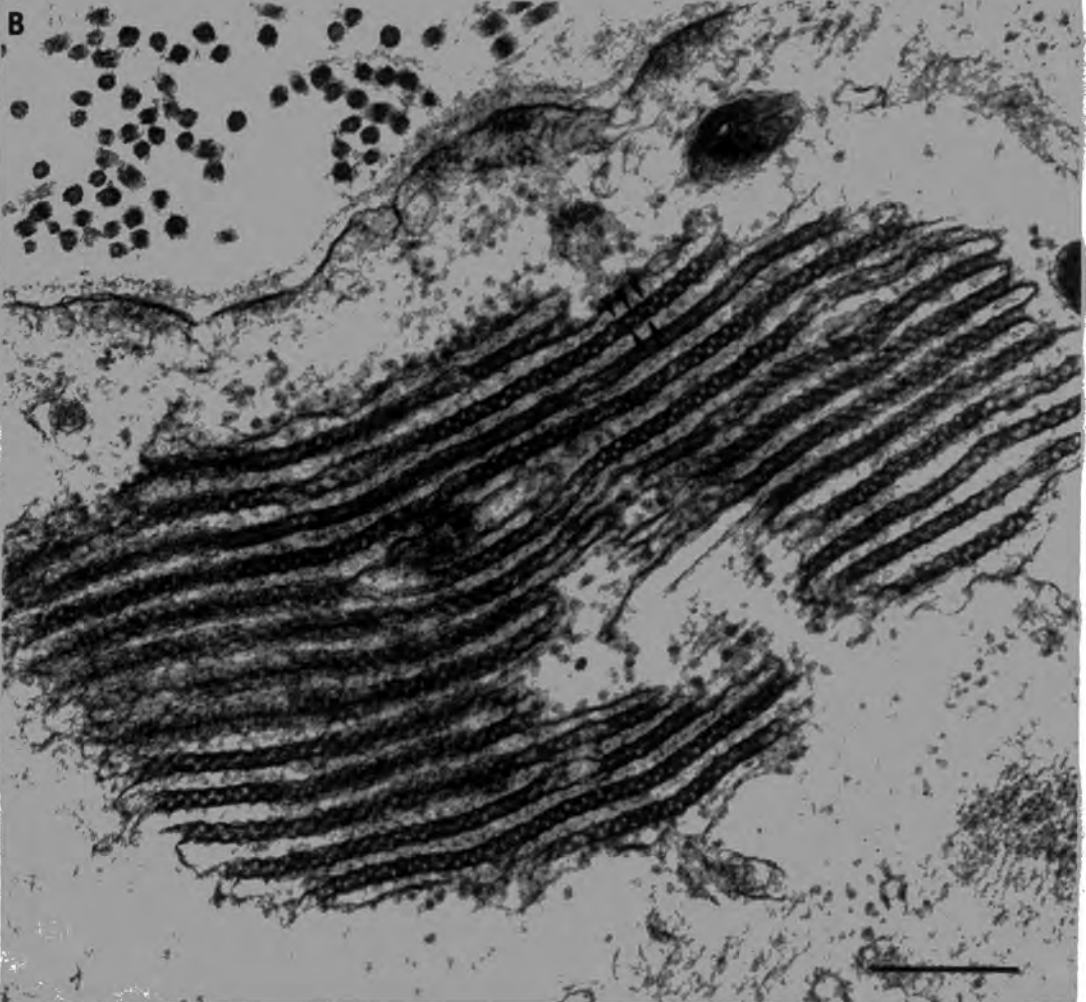

Fig. 9.14 Denervated muscle

Transverse section of extrafusal muscle fibre 364 days after denervation. Note the oval mass of dense granular material (arrow) surrounded by a translucent zone.

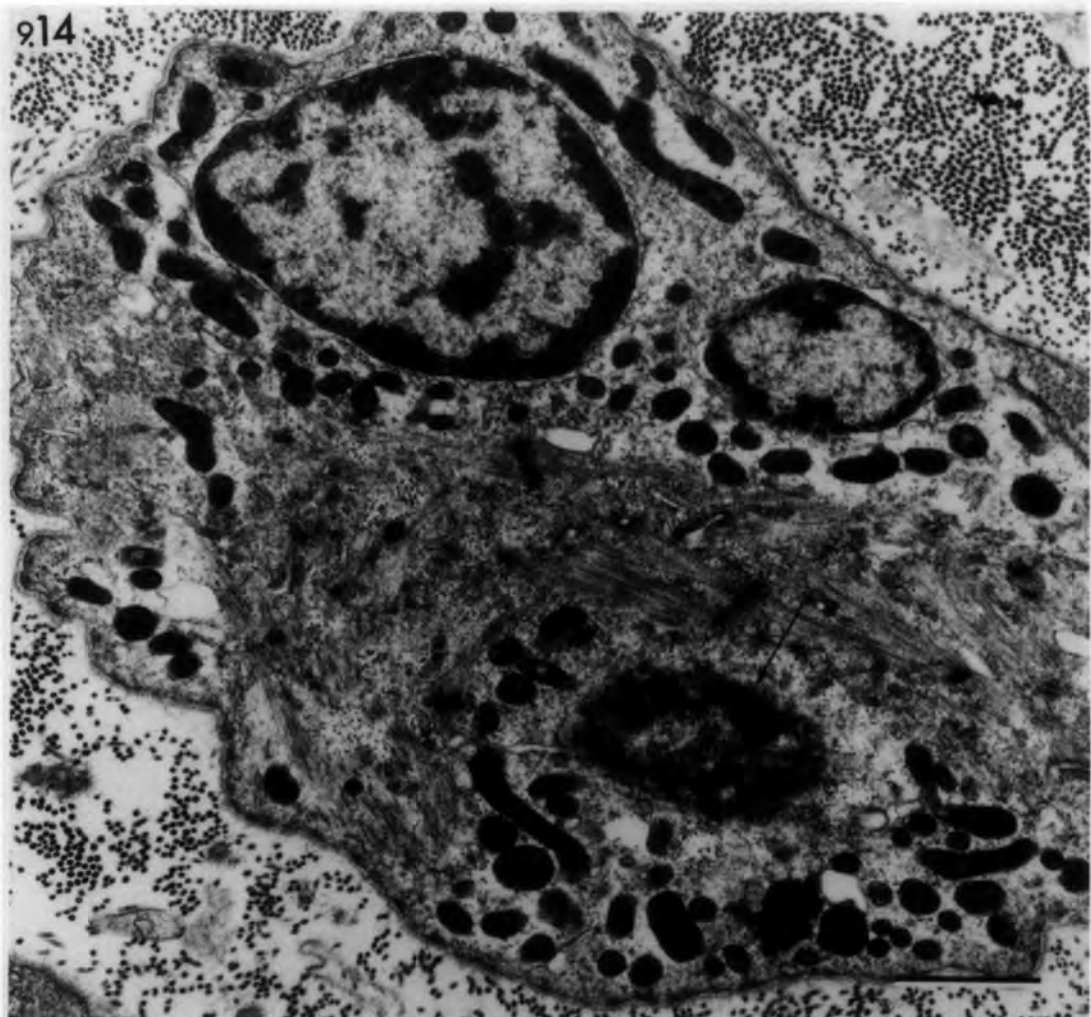
bar = 1 $\mu$ m

Fig. 9.15 Denervated muscle

Transverse section of extrafusal muscle fibre 364 days after denervation. Note the difference between the satellite-cell nucleus and the pyknotic myonucleus (n).

bar = 1 $\mu$ m

914



915

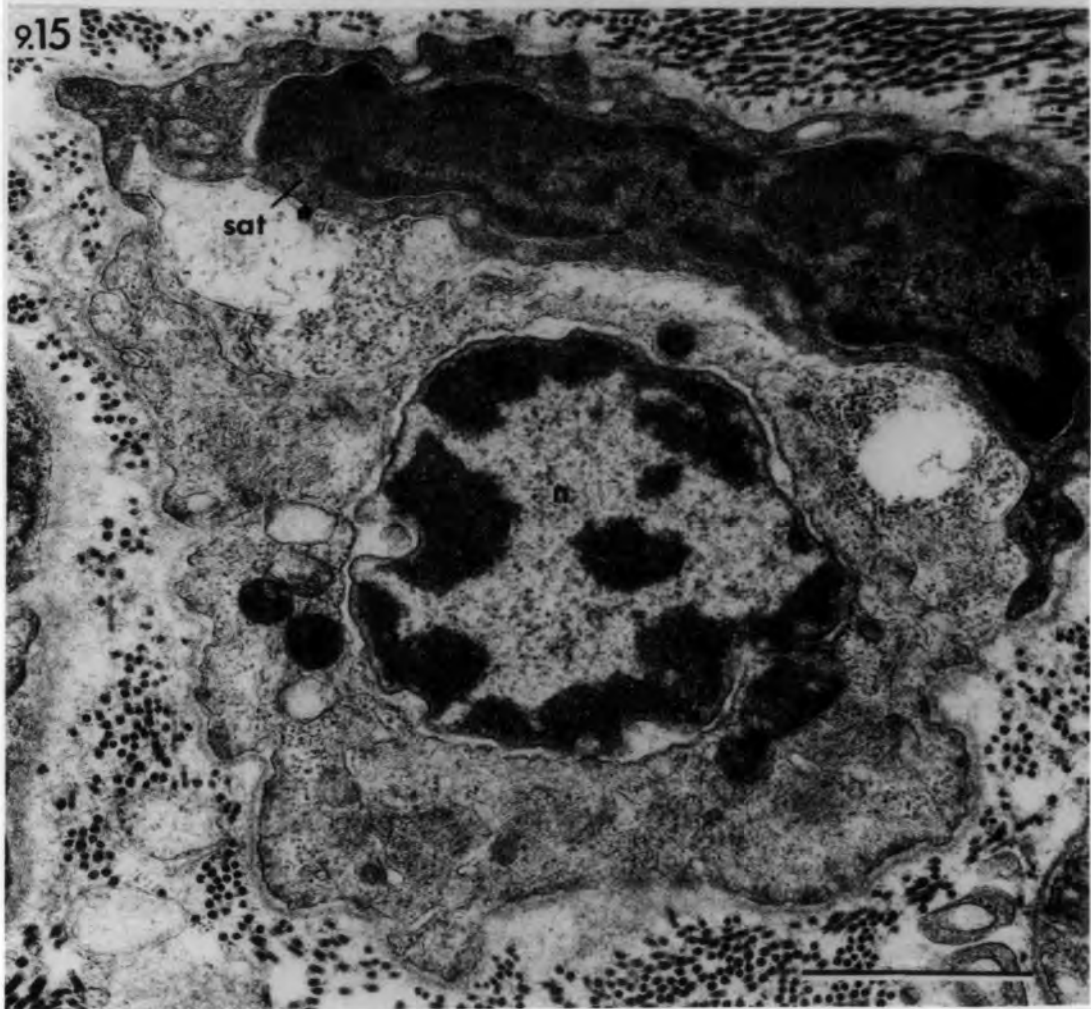


Fig. 9.16 Denervated muscle spindles: 21 days

Transverse section of the equatorial region of a bag fibre showing remnants of a degenerated sensory nerve terminal (snt). Note the presence of an equatorial nucleus (n).

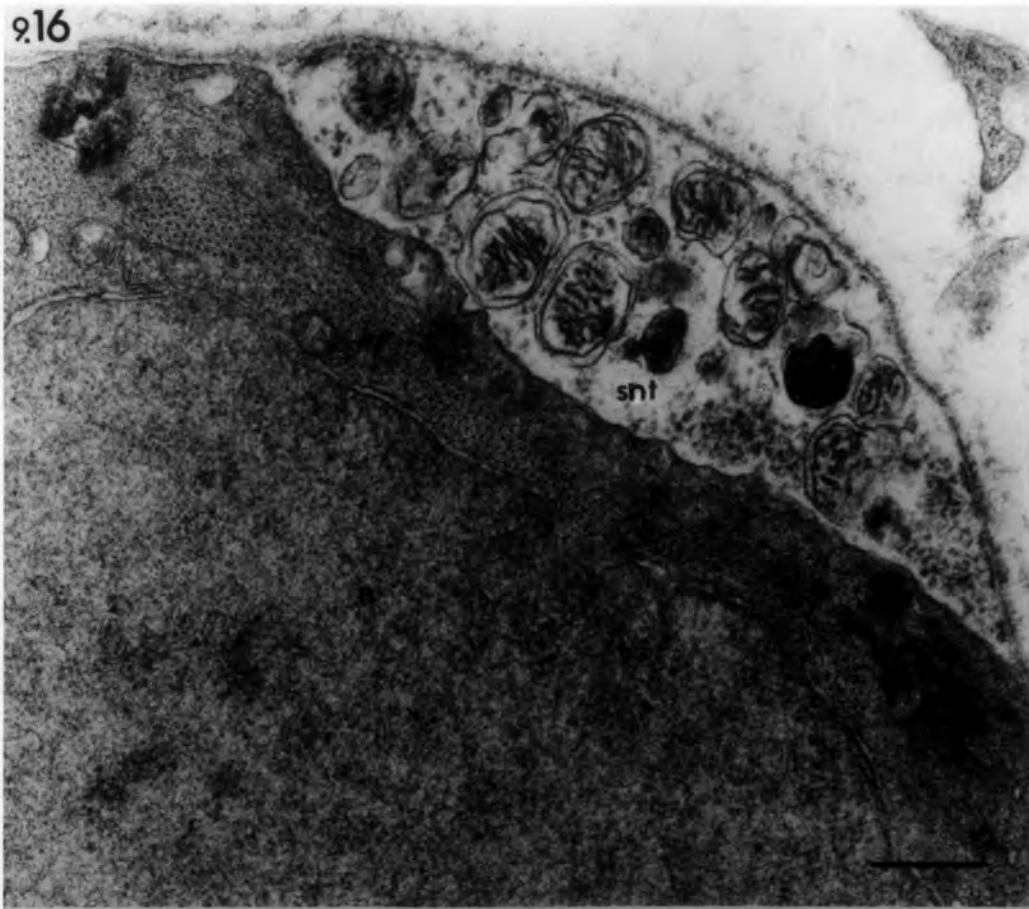
bar = 1 $\mu$ m

Fig. 9.17 Denervated muscle spindle: 21 days

Transverse section of the intracapsular polar region of a bag fibre showing a degenerated motor nerve terminal. A Schwann cell (Sc) occupies the pre-synaptic region. The subneural apparatus appears normal. Arrow points to a post-junctional fold.

bar = 1 $\mu$ m

9.16



9.17

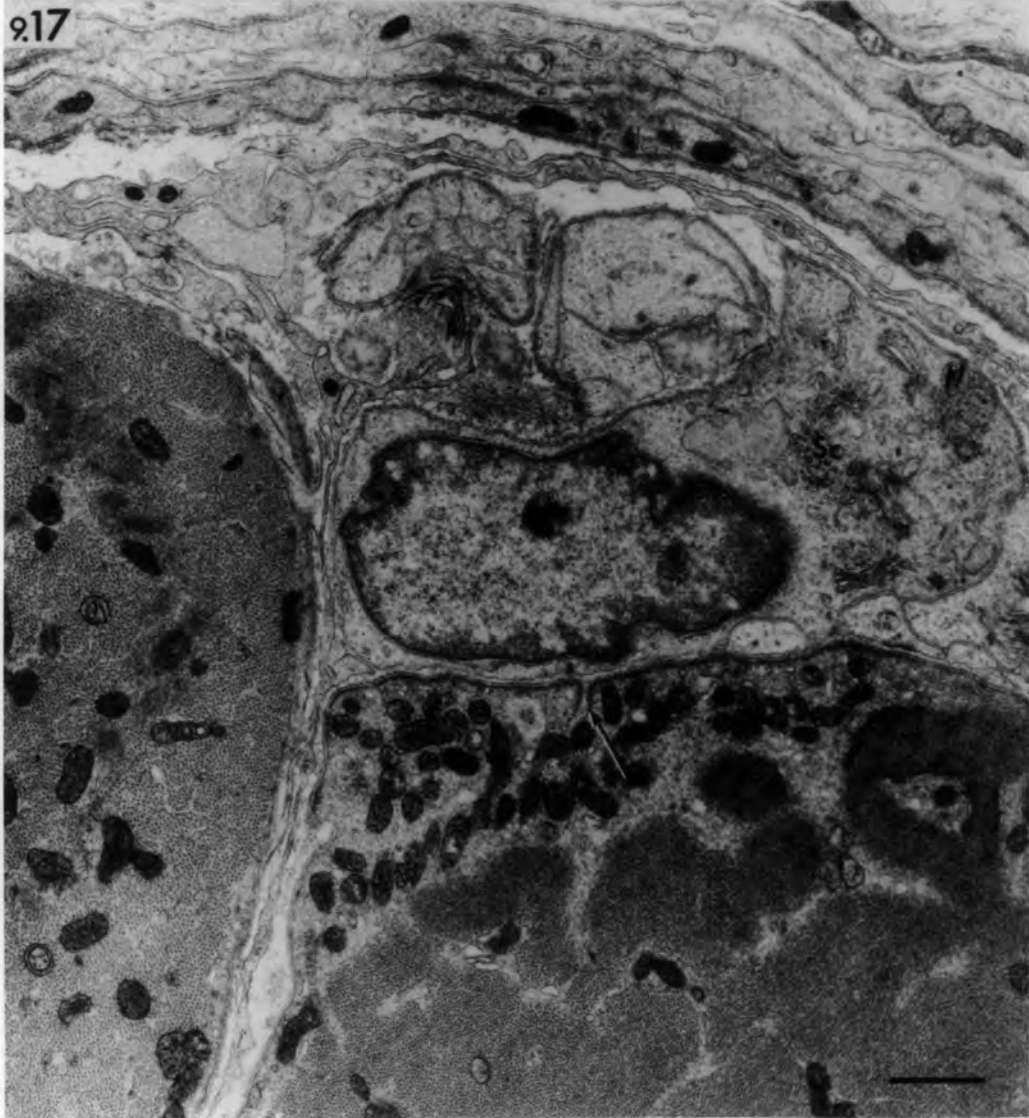

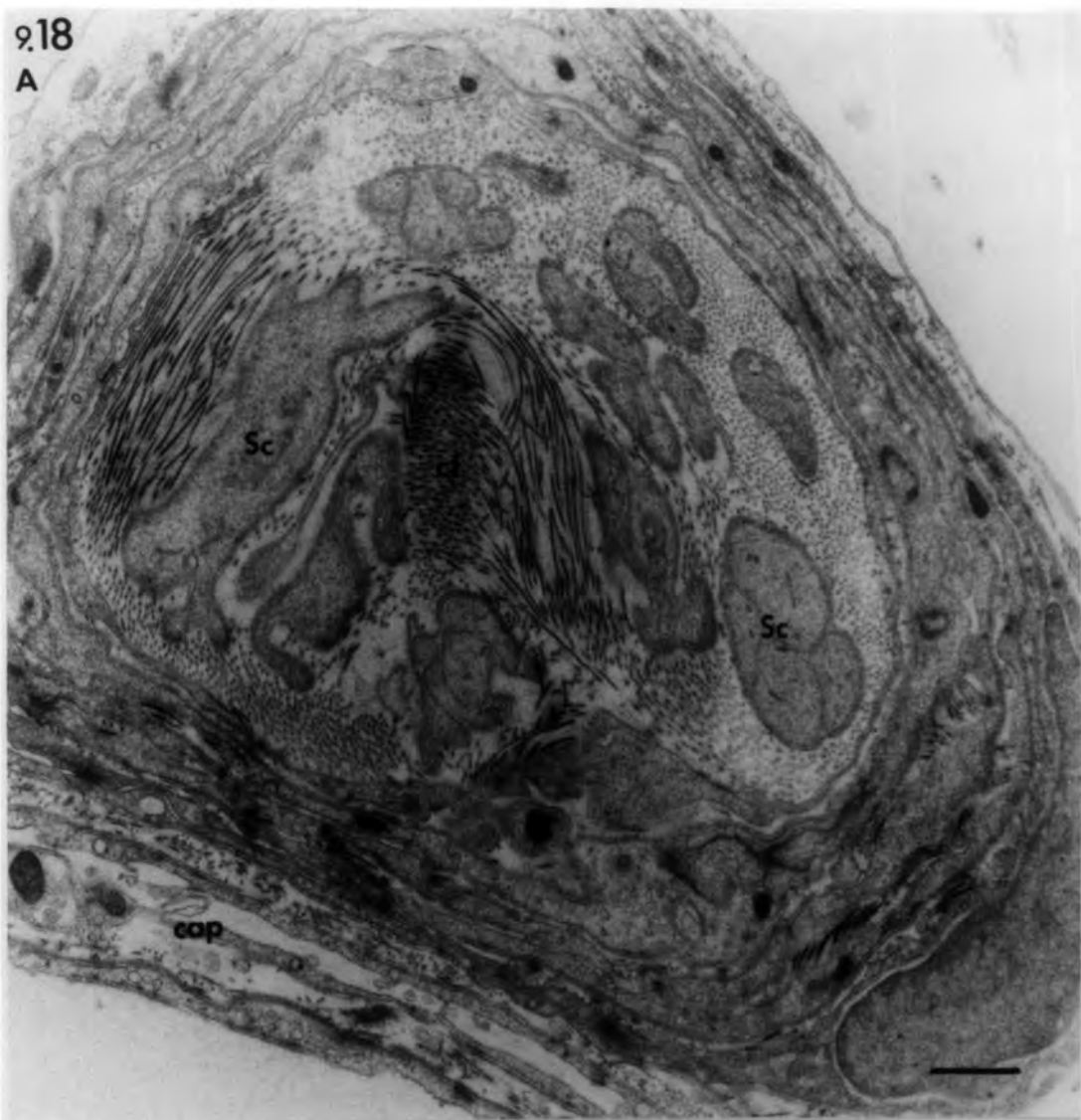
Fig. 9.18 Denervated muscle spindle: 21 days

- A. Transverse section of a spindle nerve trunk close to the nerve entry. Note absence of nerve axons and the presence of Schwann-cell processes (Sc) and collagen fibrils (cf).  
cap: spindle capsule.
- B. Transverse section of a spindle nerve trunk further away from nerve entry than in Fig. 9.18. The dense material (arrow) is encircled by Schwann-cell processes and resembles the honeycomb structure of degenerated axons. Note the small extrafusal muscle fibre to the left.

bars = 1 $\mu$ m

9.18

A



B

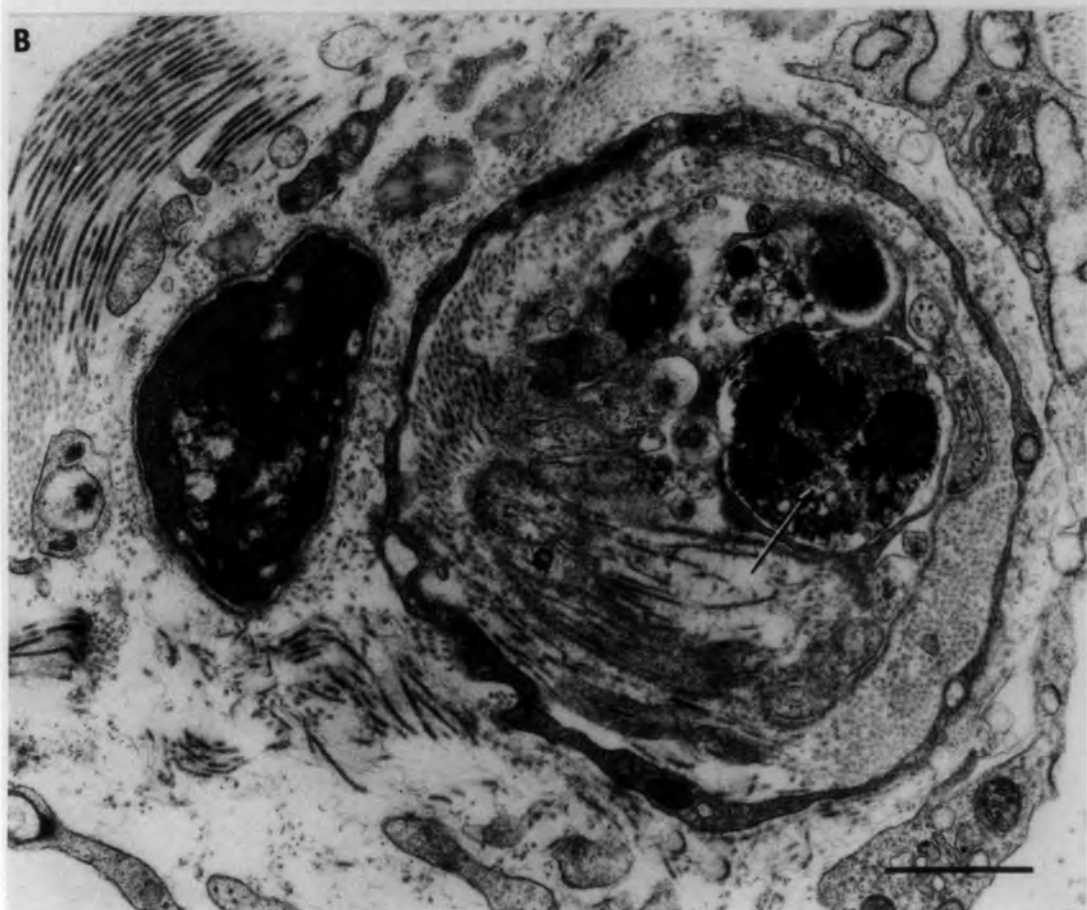

Fig. 9.19 Denervated muscle spindle: 21 days

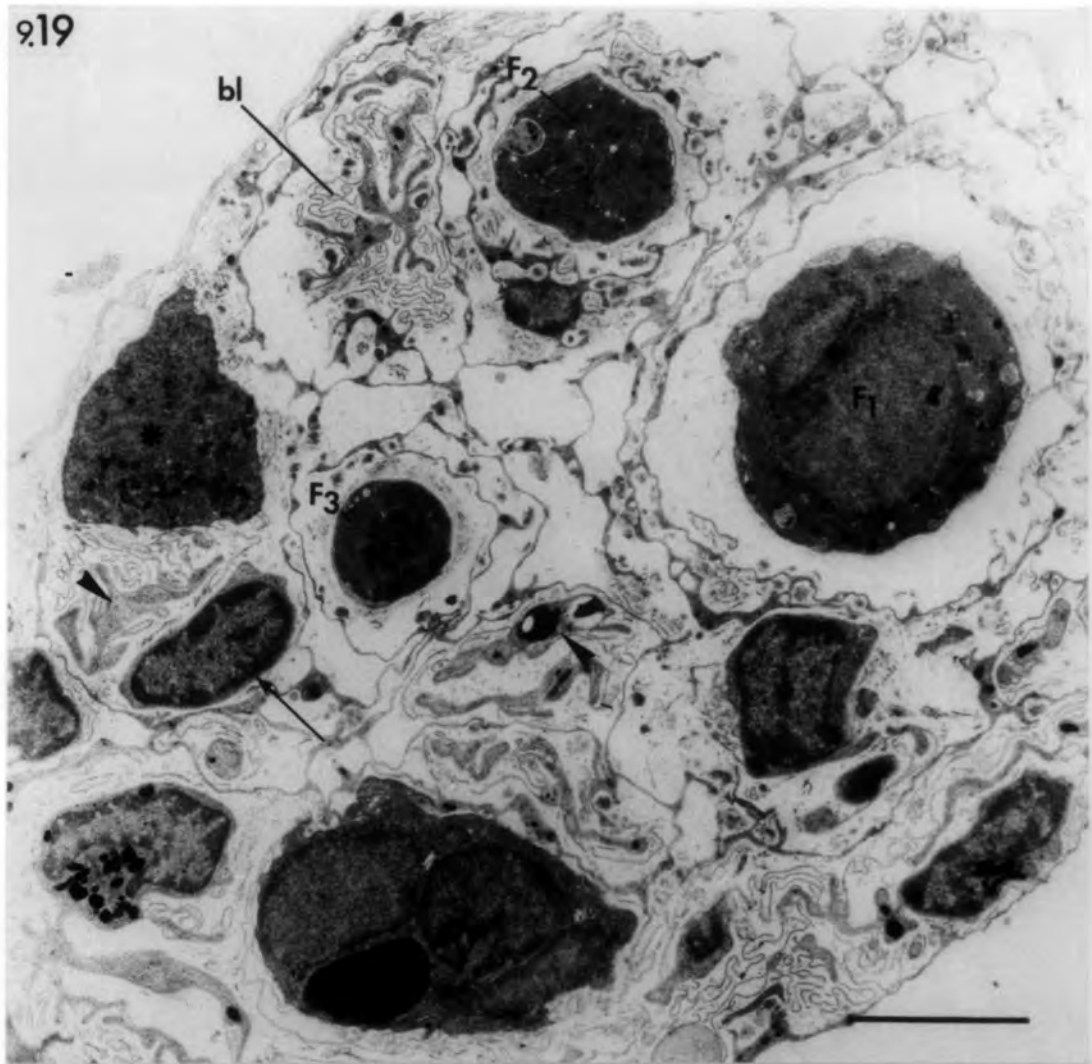
Transverse section of the equatorial region shows three atrophied intrafusal fibres ( $F_1$ ,  $F_2$  &  $F_3$ ) and an additional fibre (asterisk). Note absence of equatorial nuclei in  $F_2$  and  $F_3$ . The axial sheath contains remnants of degenerated Schwann cells (arrow heads) and extensive basal-lamina profiles (bl). Arrow points to an undifferentiated cell.

Fig. 9.20 Denervated muscle spindle: 56 days

Transverse section of the equatorial region shows four intrafusal fibres ( $F_1$ - $F_4$ ) that lack the characteristic equatorial nucleation. Note the disrupted axial sheath (arrow) and the presence of a capillary (cpl).

bars = 5 $\mu$ m

9.19



9.20

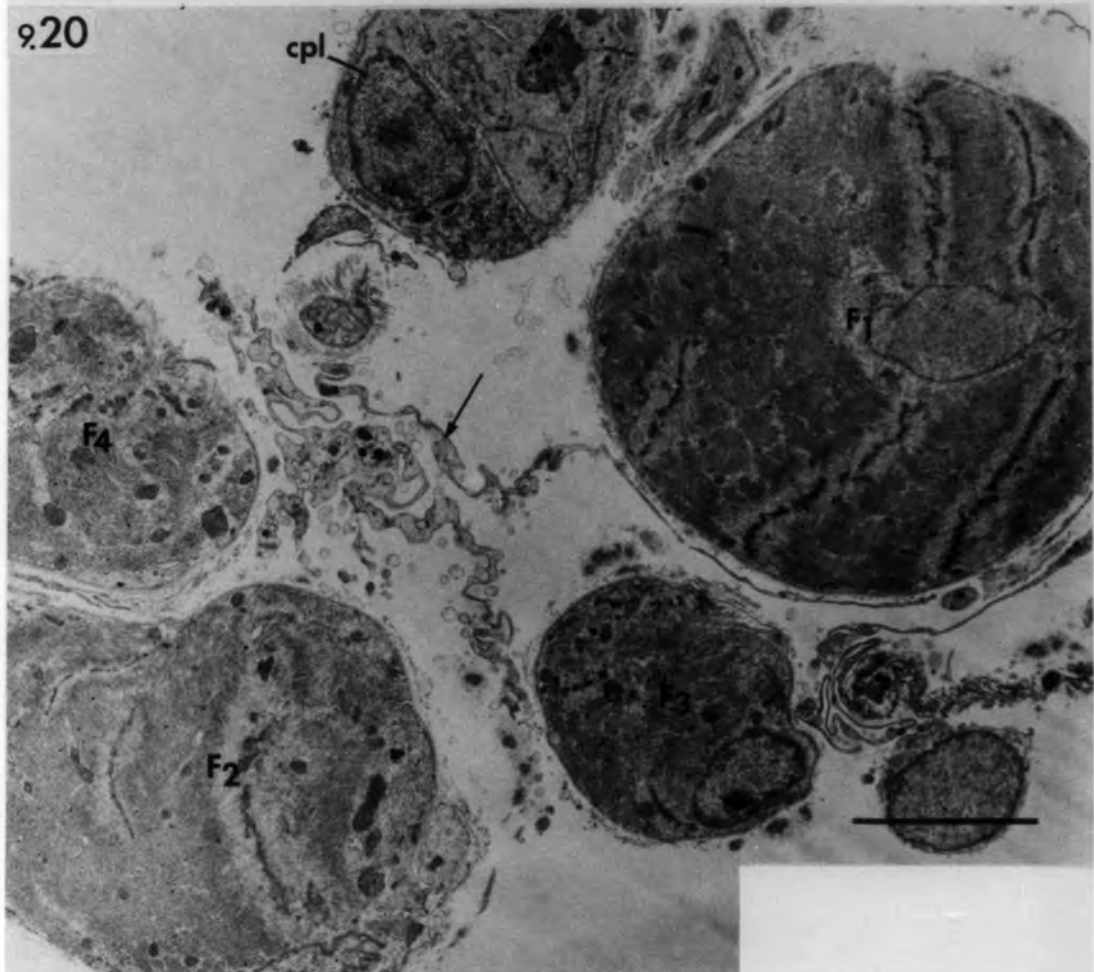


Fig. 9.21 Denervated muscle spindle: 21 days

Transverse section of the equatorial region of a bag<sub>1</sub> fibre. Note the reduction in size of the nuclear bag and the presence of a distinct M-line (M) in the myofibrils. Arrow points to an axial-sheath cell.

bar = 1µm

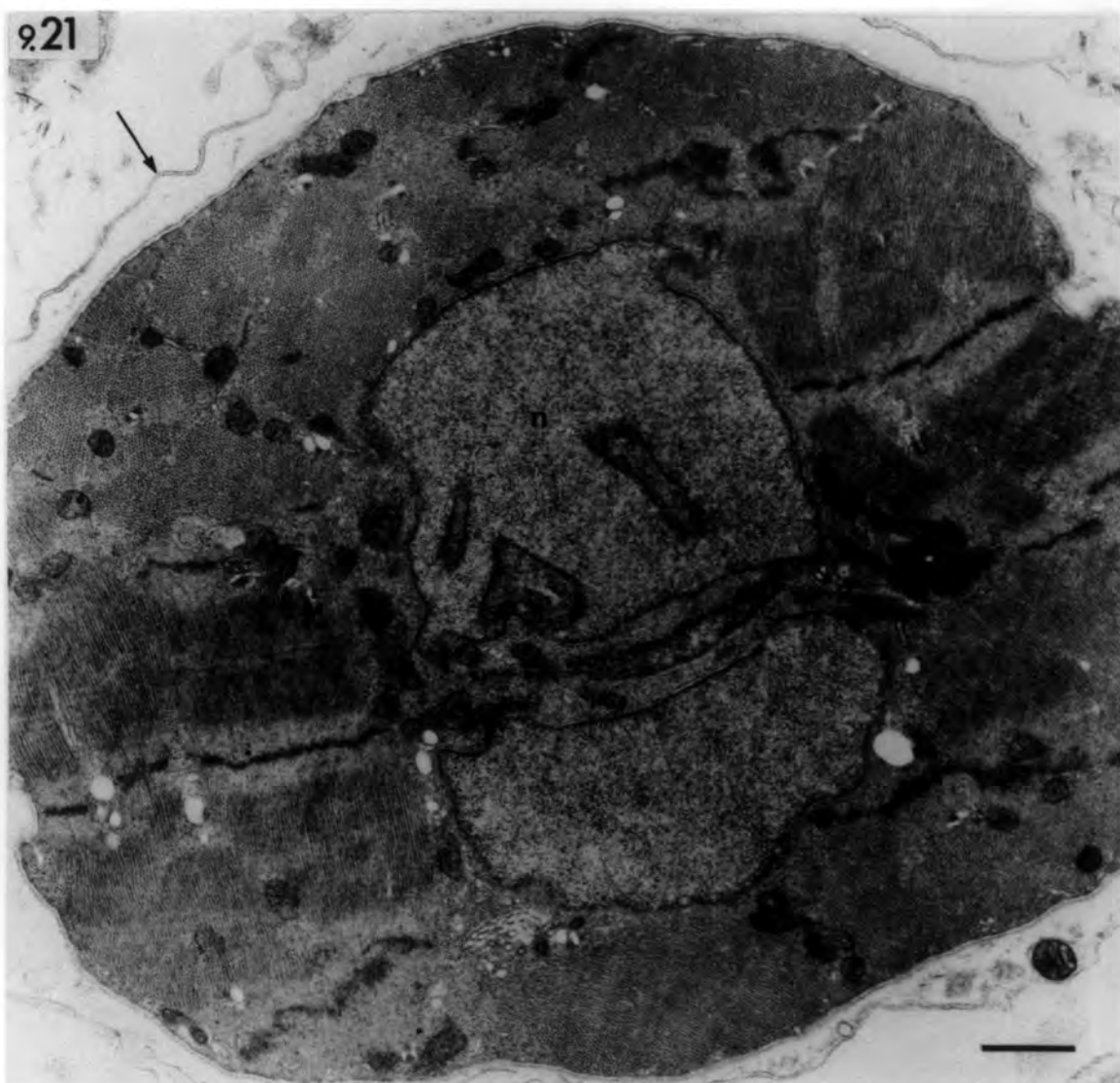


Fig. 9.22 Denervated muscle spindle: 364 days

A. Transverse section of the equatorial region shows four intrafusal muscle fibres ( $F_1$ - $F_4$ ) that appear well-preserved compared with extrafusal muscle fibres (emf). The intrafusal fibres lack equatorial nuclei and are packed with myofibrils. Note their irregular shape, the focal atrophy in  $F_1$  and the fragmented and projected nucleus (n) in  $F_3$ . The two additional fibres (asterisks) appear to be formed by splitting of  $F_2$  and  $F_3$ . A cell is present between  $F_2$  and its additional fibre. Note the abnormal capillaries (cpl) in the reduced periaxial space.

cap: collapsed capsule.

bar = 10 $\mu$ m

B. Higher power of  $F_1$  to show the focal atrophy (compare with Fig. 6.37). Arrow points to a deep sarcolemmal invagination. Arrow heads point to Z-line fragments. Note the double basal lamina (bl) in places around the muscle fibre and the collagen fibrils in between.

bar = 2.5 $\mu$ m

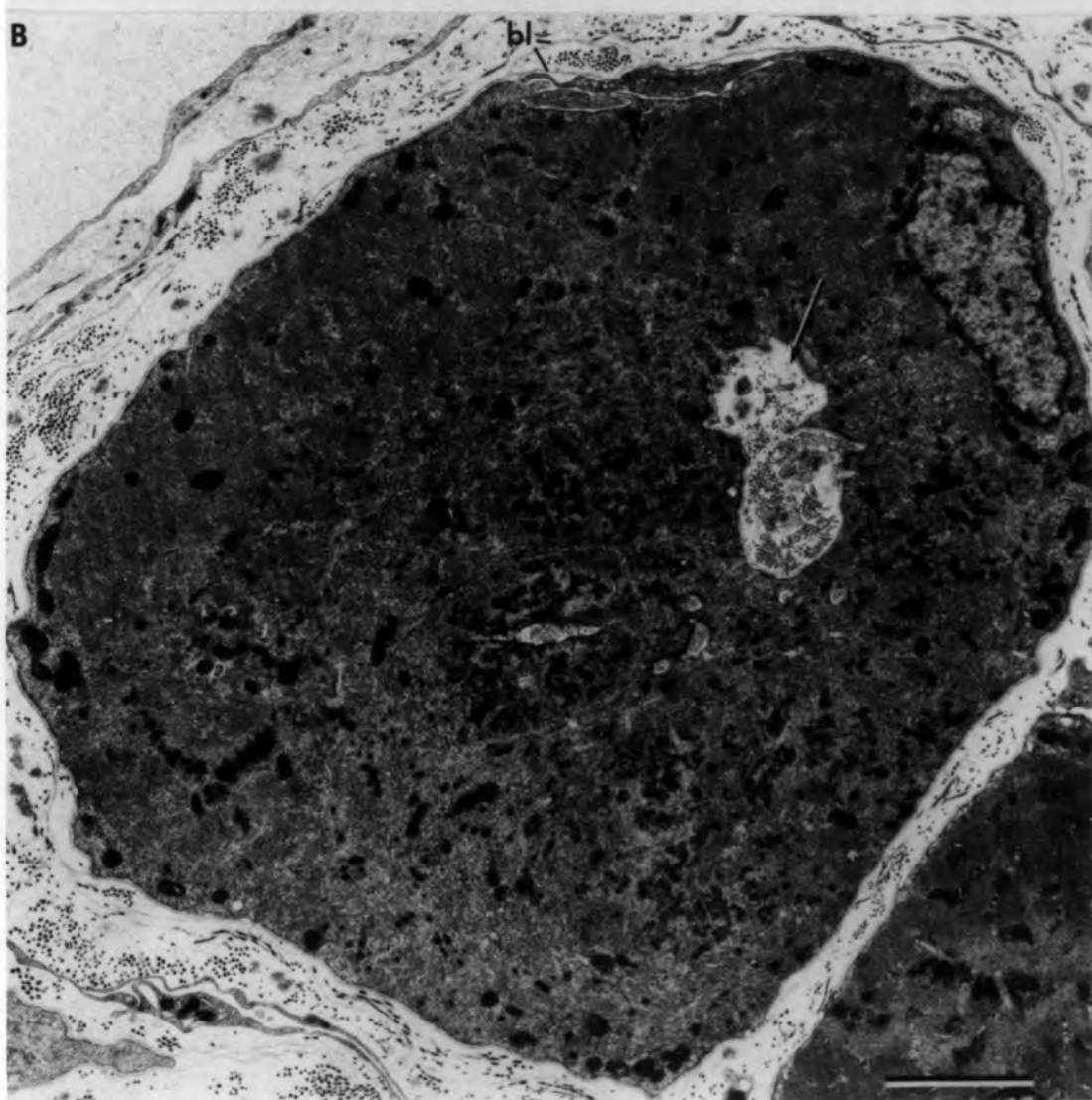
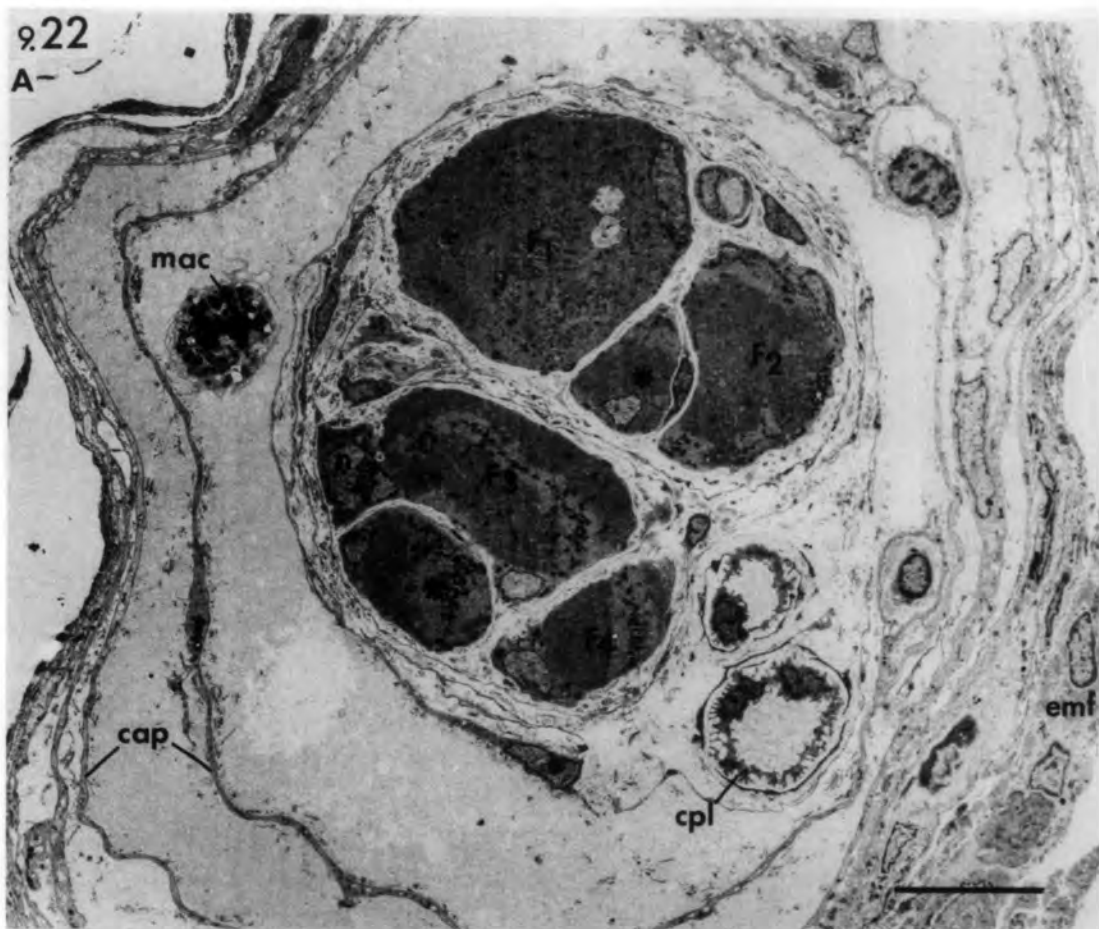


Fig. 9.23 Denervated muscle spindle: 364 days

Transverse sections of the intracapsular polar region of an intrafusal fibre showing Z-line streaming (arrow).

bar = 1 $\mu$ m

Fig. 9.24 Denervated muscle spindle: 21 days

Transverse section of the intracapsular polar region of an intrafusal fibre showing focal atrophy. Large amounts of ribosomes occupy the atrophied zone (right) in which rough endoplasmic tubules, degenerated mitochondria, Golgi apparatus, irregular concentric membranes (arrow) and membrane-bound structures (arrow head) are embedded.

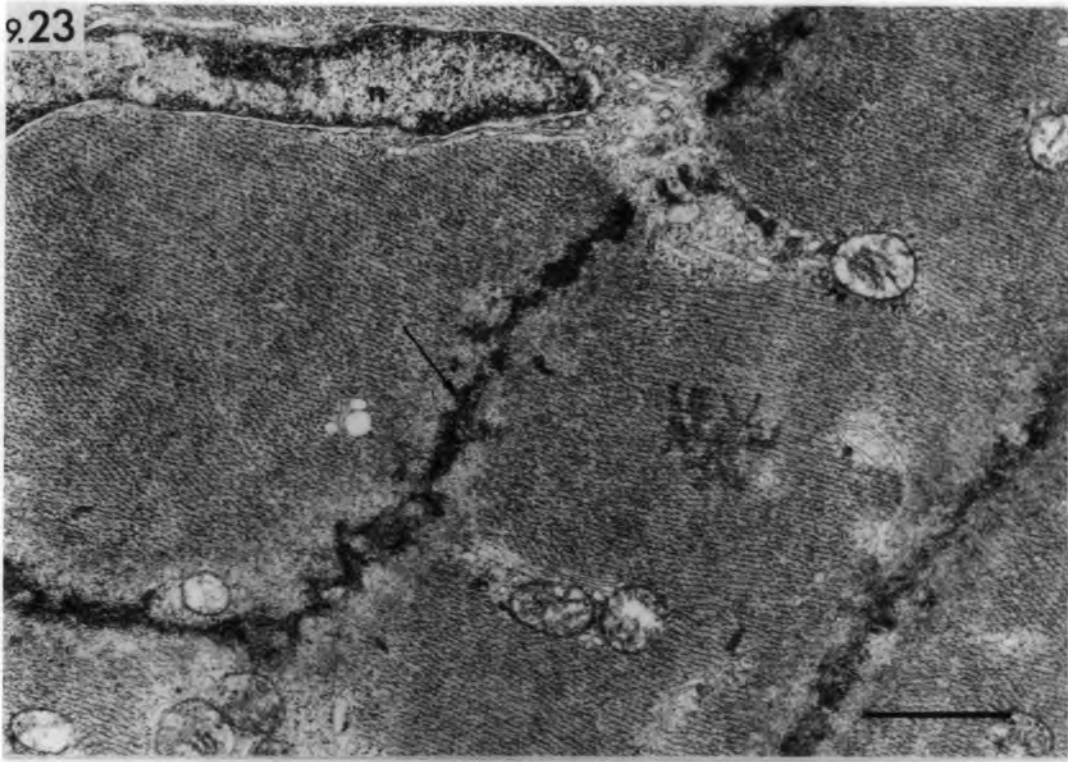
bar = 1 $\mu$ m

Fig. 9.25 Denervated muscle spindle: 21 days

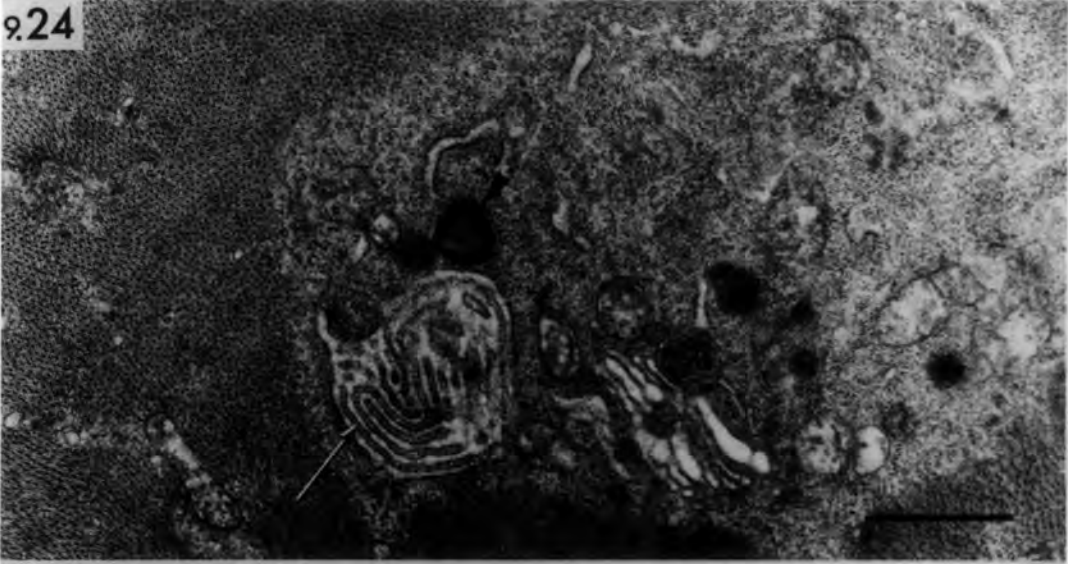Transverse section of the intracapsular polar region of an intrafusal fibre containing concentric membranes. Note the resemblance between the granules inside the concentric membranes (arrow heads) and ribosomes (arrows).

bar = 1 $\mu$ m

9.23



9.24



9.25

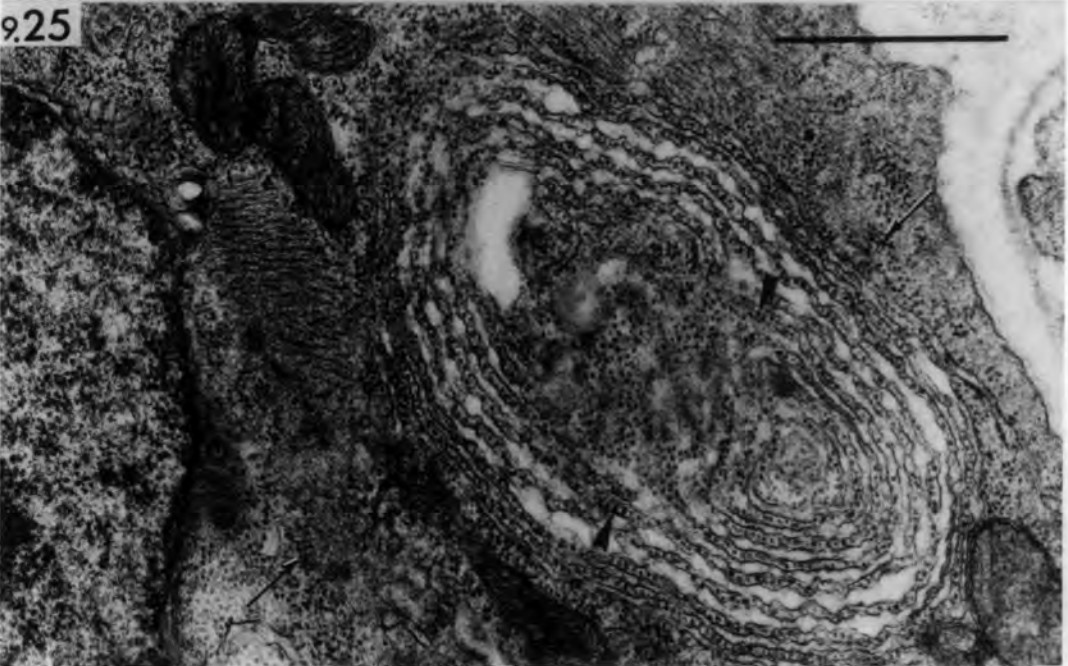


Fig. 9.26 Denervated muscle: nuclear changes

A. Transverse section of an extrafusal muscle fibre (14 days after devascularization and denervation: series Isch/Dn) showing a fragmented subsarcolemmal nucleus and whorls of densely-packed membranes (asterisk).

bar = 1 $\mu$ m

B. Transverse section of the intracapsular polar region of an intrafusal fibre (56 days after denervation) showing a nucleus with several processes engulfing the sarcoplasm.

bar = 0.5 $\mu$ m

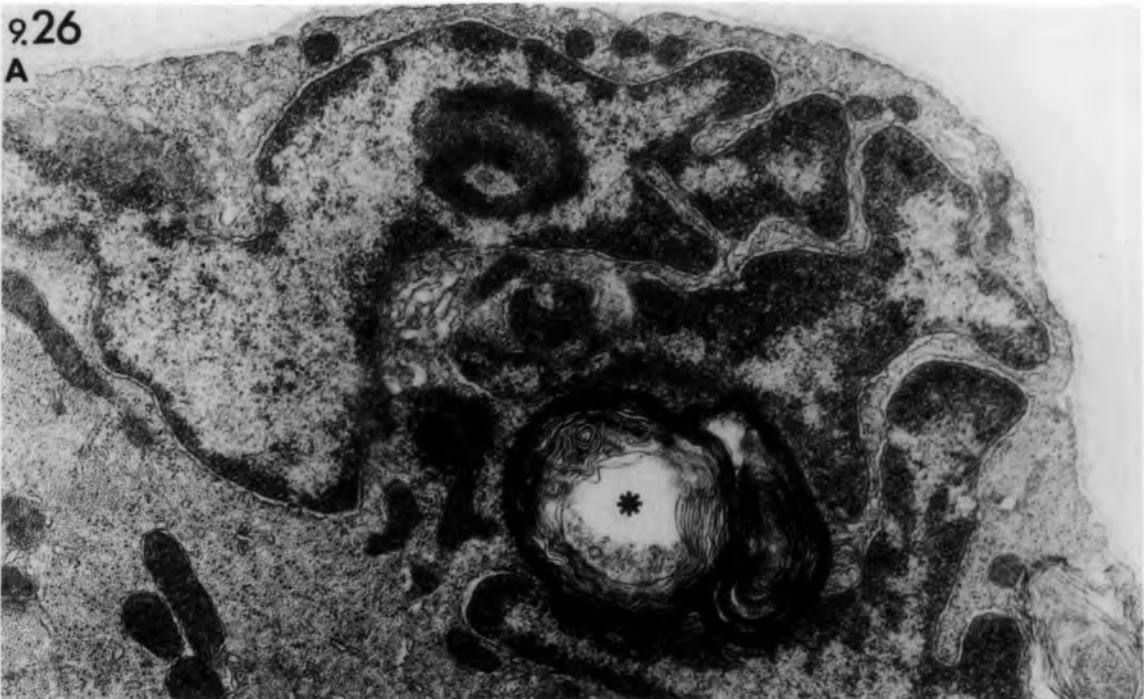Fig.9.27 Denervated muscle spindle: 21 days

Transverse section of the equatorial region (high power of Fig. 9.19) of a bag fibre showing various stages of sarcolemmal invagination. It begins with the depression of the sarcolemma (arrow head) and fusion of its lips to form a vacuole (arrow) containing necrotic debris.

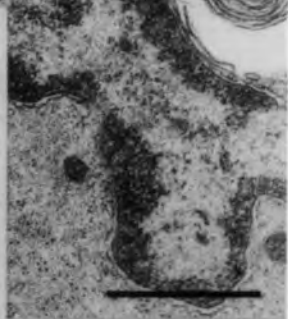
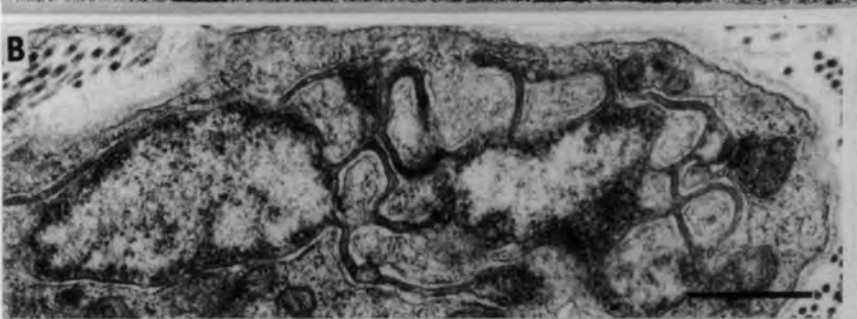
bar = 1 $\mu$ m

9.26

A



B



9.27

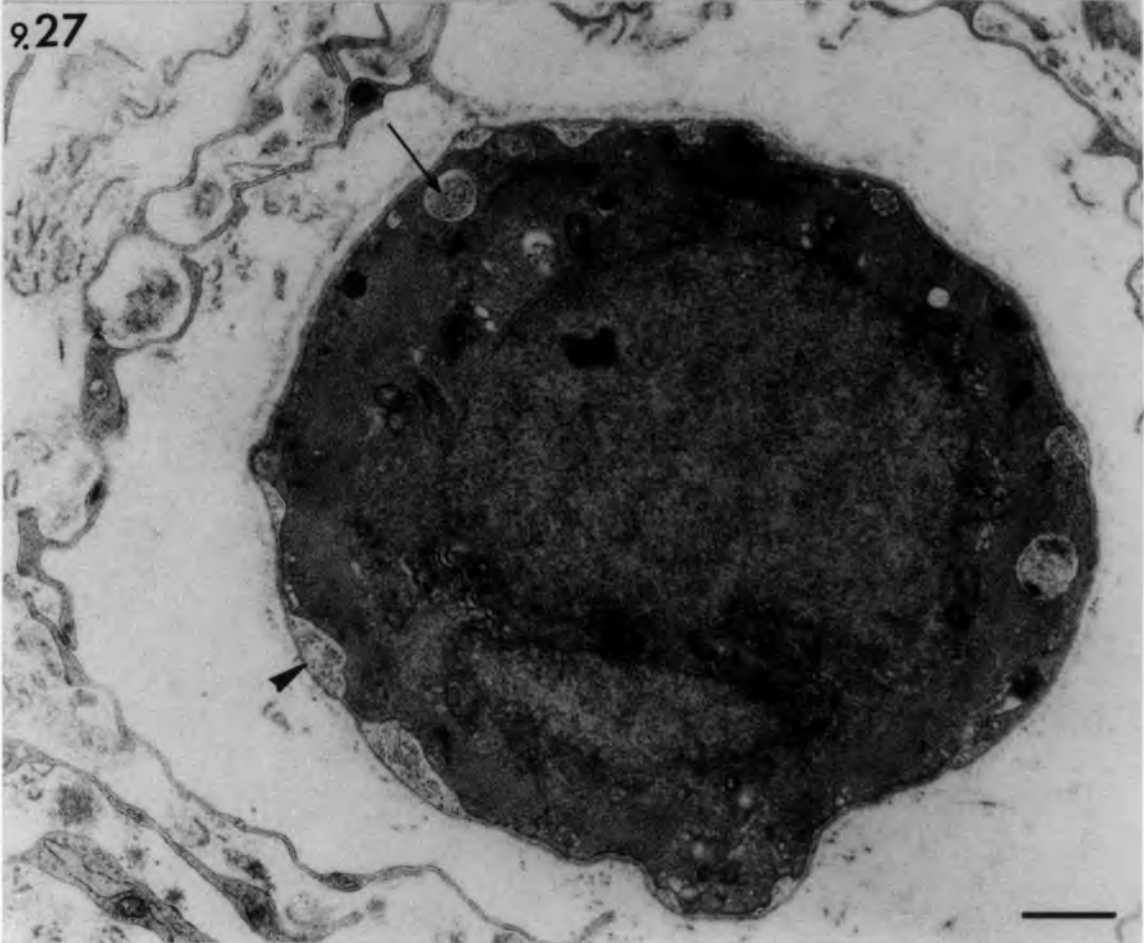


Fig. 9.28 Denervated muscle spindle; A: 21 days,

B: 56 days.

A. Transverse section of the equatorial region (high power of Fig. 9.19) to show an additional fibre (asterisk) and an undifferentiated cell (arrow).

B. Transverse section of the juxta-equatorial region: an additional fibre (asterisk) shows signs of atrophy. Note the vesicles (v) accumulated at the periphery.

bars = 1 $\mu$ m

9.28  
A

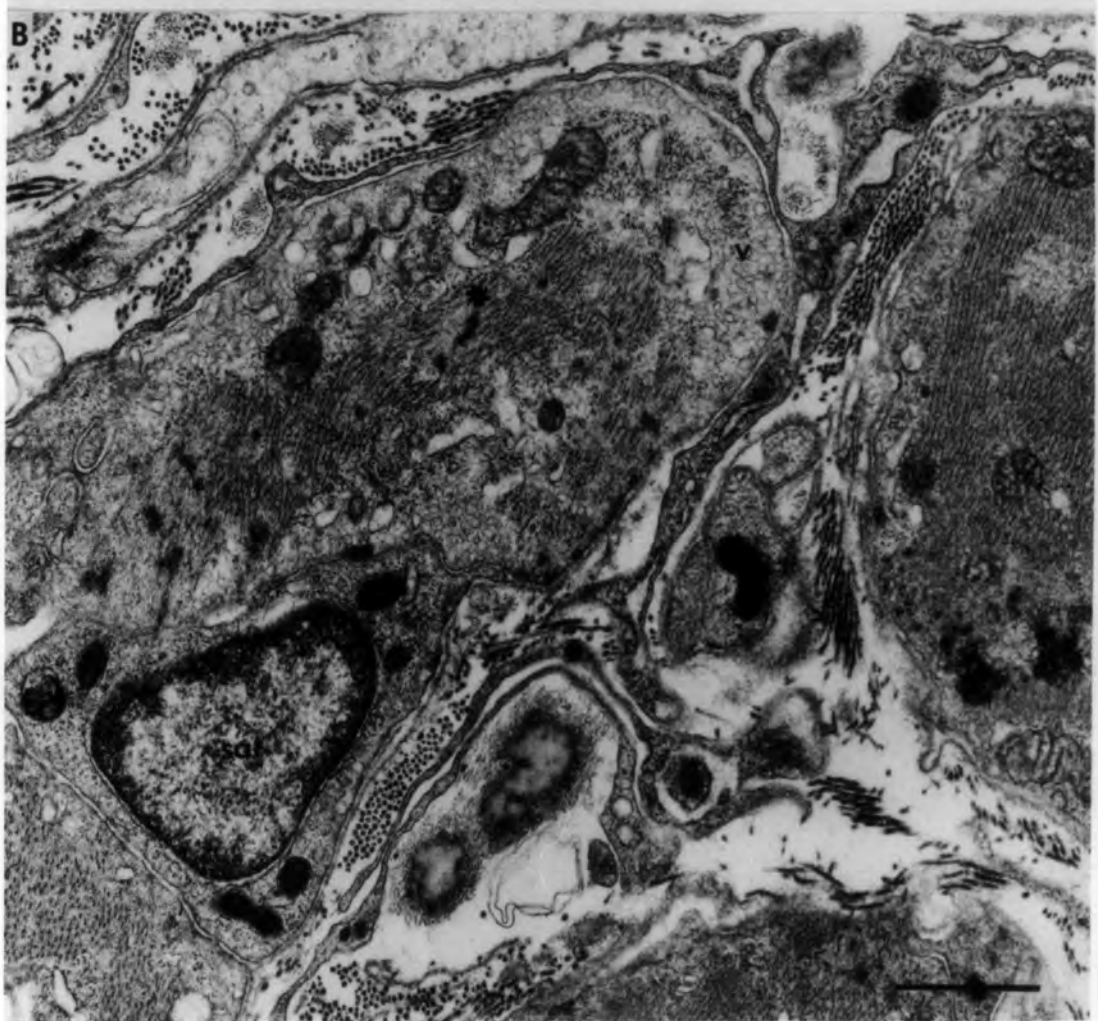
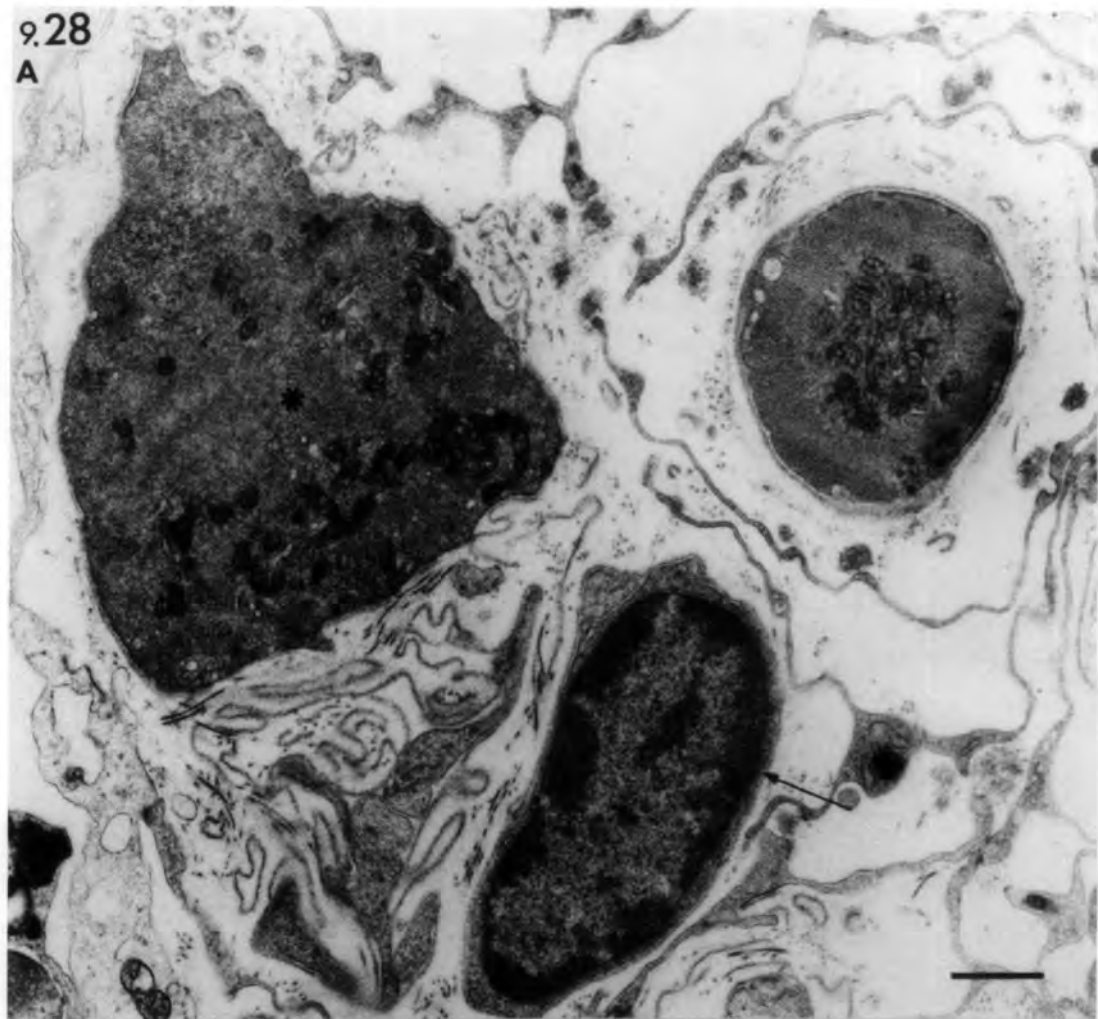


Fig. 9.29 Ischaemic and denervated muscle (Isch/Dn):

5 days.

Longitudinal section of a regenerating extrafusal fibre composed of a well-formed myotube with a central chain of nuclei.

bar = 2 $\mu$ m

Fig. 9.30 Ischaemic and denervated muscle (Isch/Dn):

8 days.

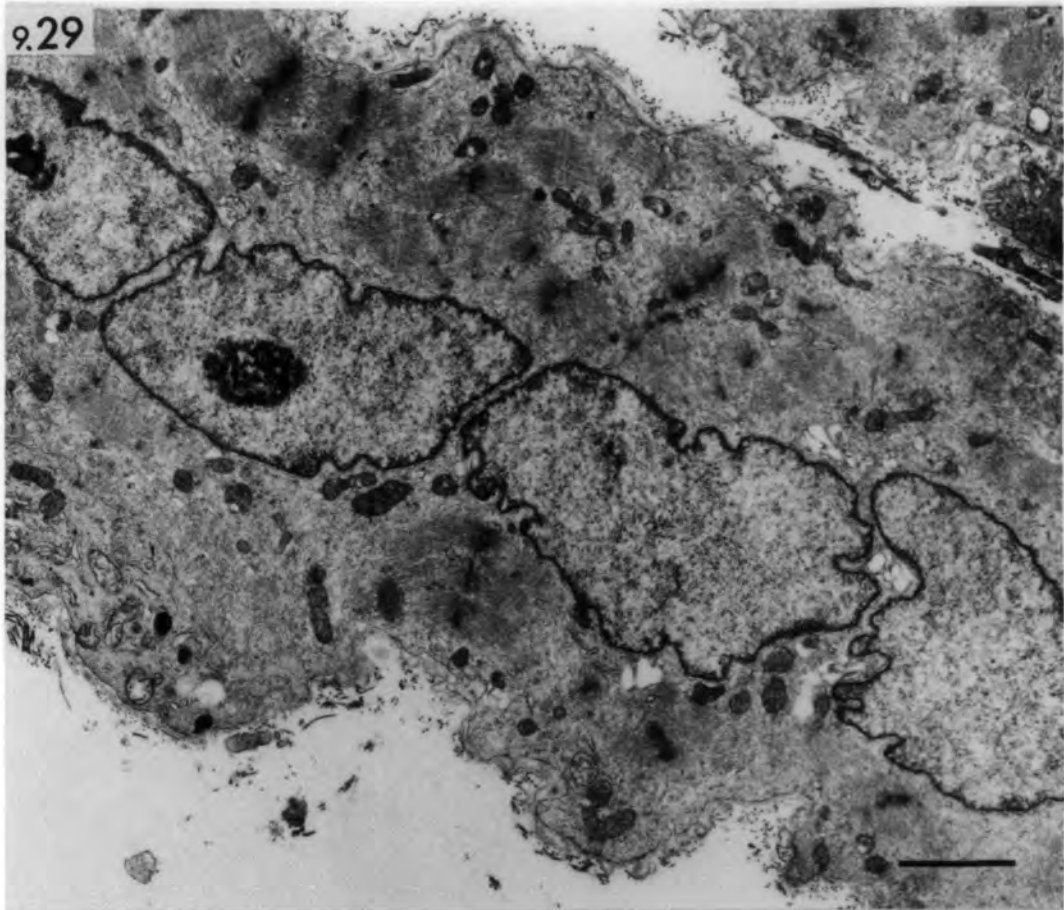
Transverse section of extrafusal fibres and a muscle spindle. Both intrafusal and extrafusal fibres are composed of mature muscle fibres, comparable with those at day-14 stage in series Isch (Fig. 6.27). Note that the satellite cells project over the muscle-fibre (arrow heads).

Arrow points to an undifferentiated cell.

bl: folded basal lamina.

bar = 10 $\mu$ m

9.29



9.30

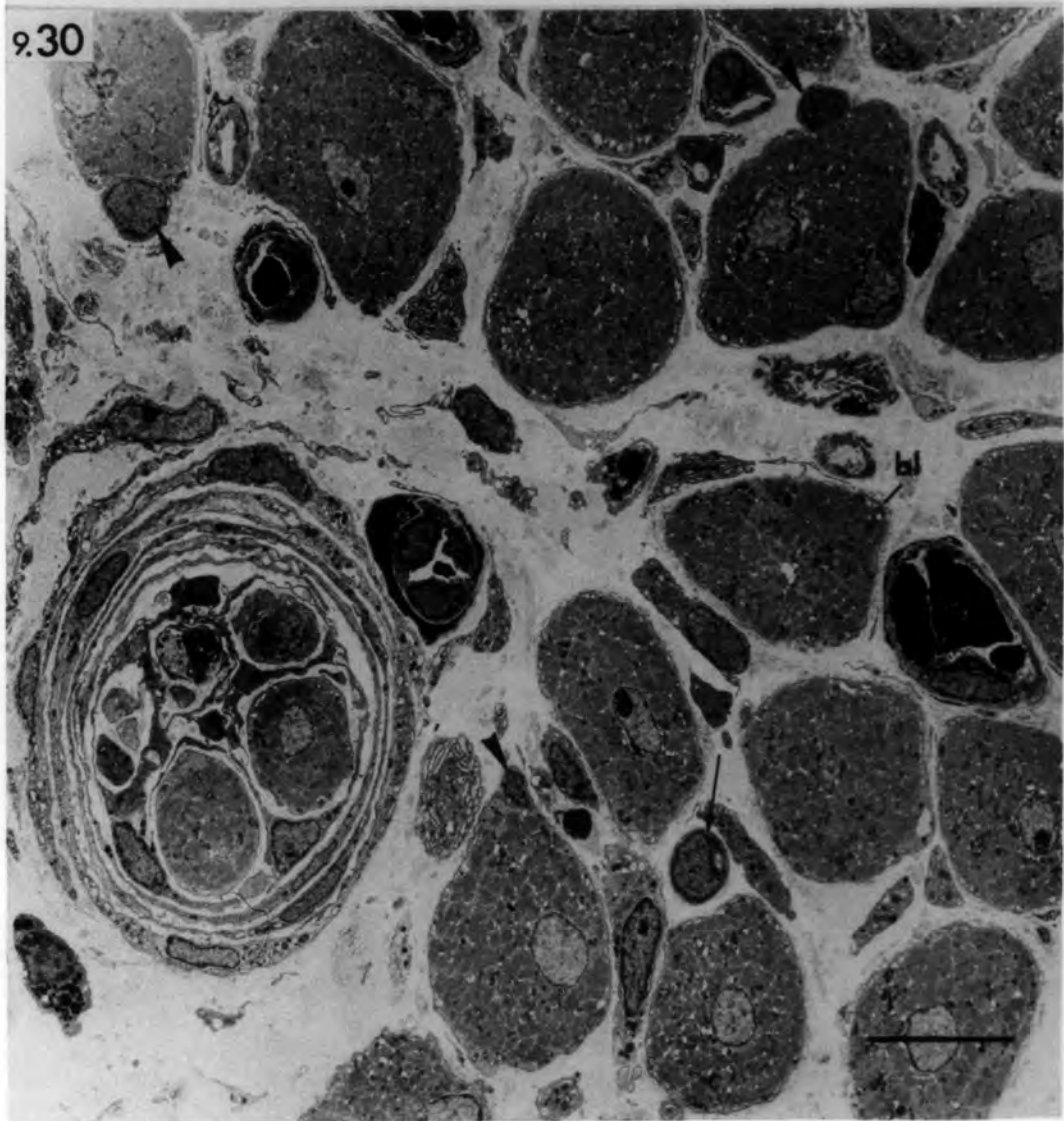


Fig. 9.31 Ischaemic and denervated muscle (Isch/Dn):

A: 8 days, B: 21 days.

Transverse sections of extrafusal fibres  
showing regenerating sole-plates.

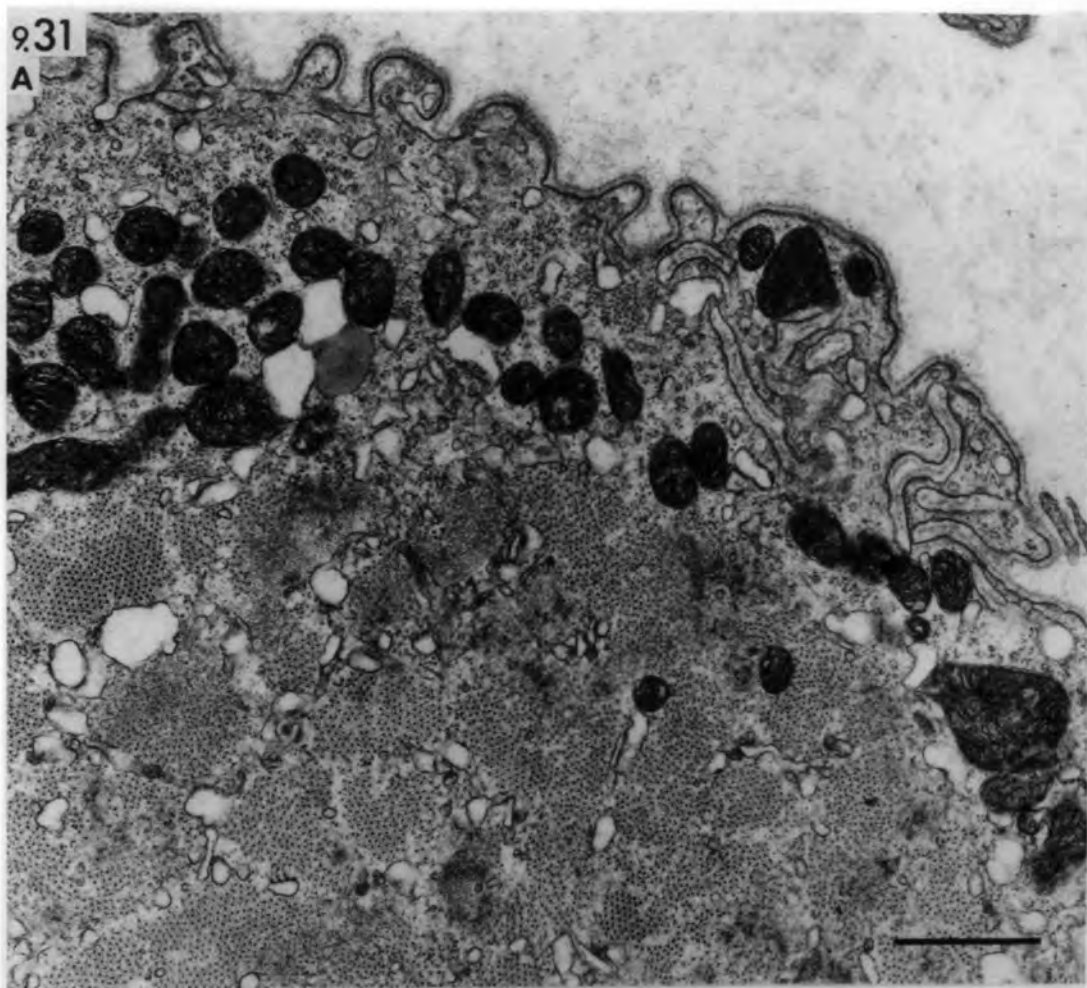
A. Note absence of collagen fibrils from  
the pre-synaptic site.

B. Note the presence of collagen fibrils  
(cf) at the pre-synaptic site and the  
indented nuclei (n) of the sole-plate.

bars = 1 $\mu$ m

931

A



B

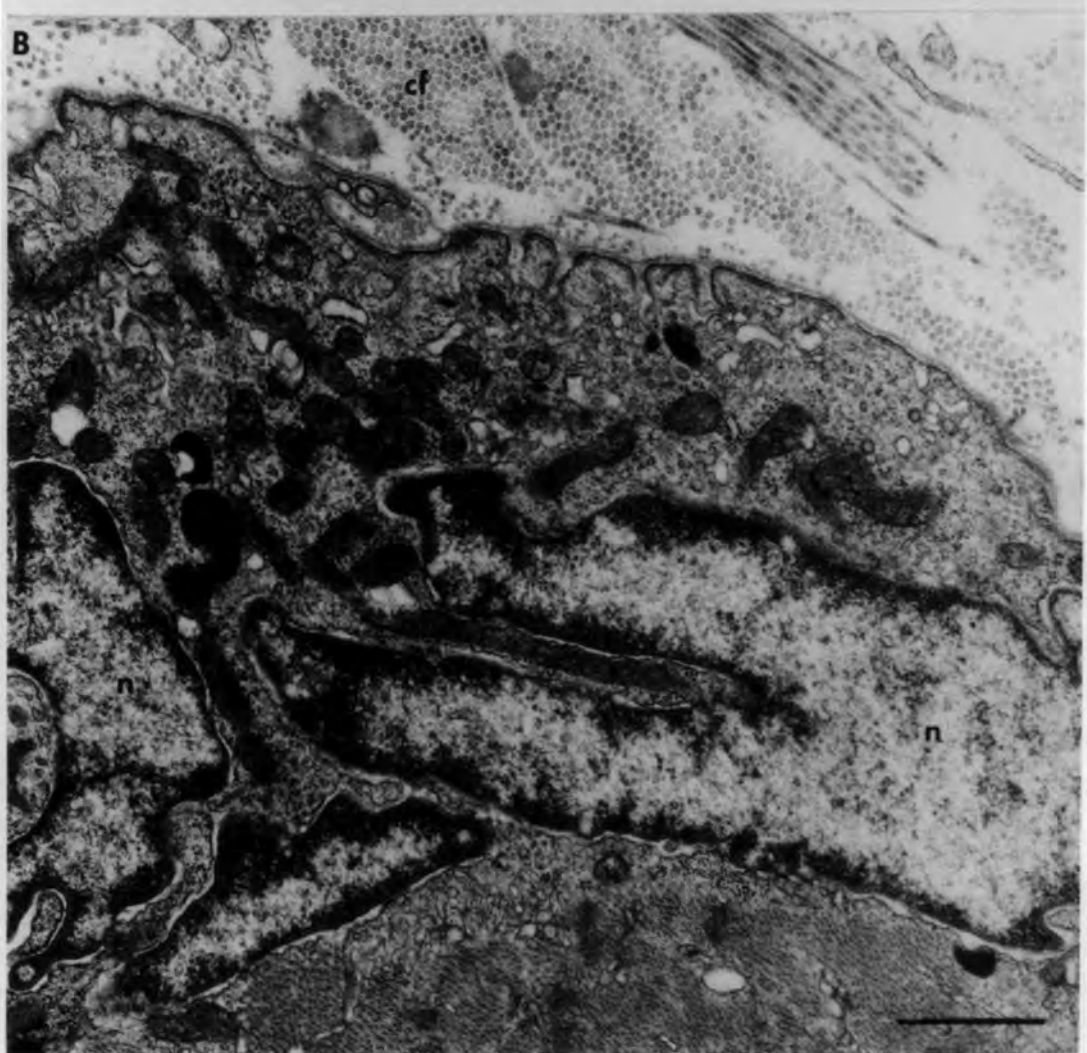

Fig. 9.32 Ischaemic and denervated muscle (Isch/Dn):

A: 21 days, B: 56 days.

Transverse sections of intramuscular nerve trunks.

A. Large amounts of collagen fibrils (cf) and degenerating Schwann cells (Sc) occupy the lumen of the nerve trunk.

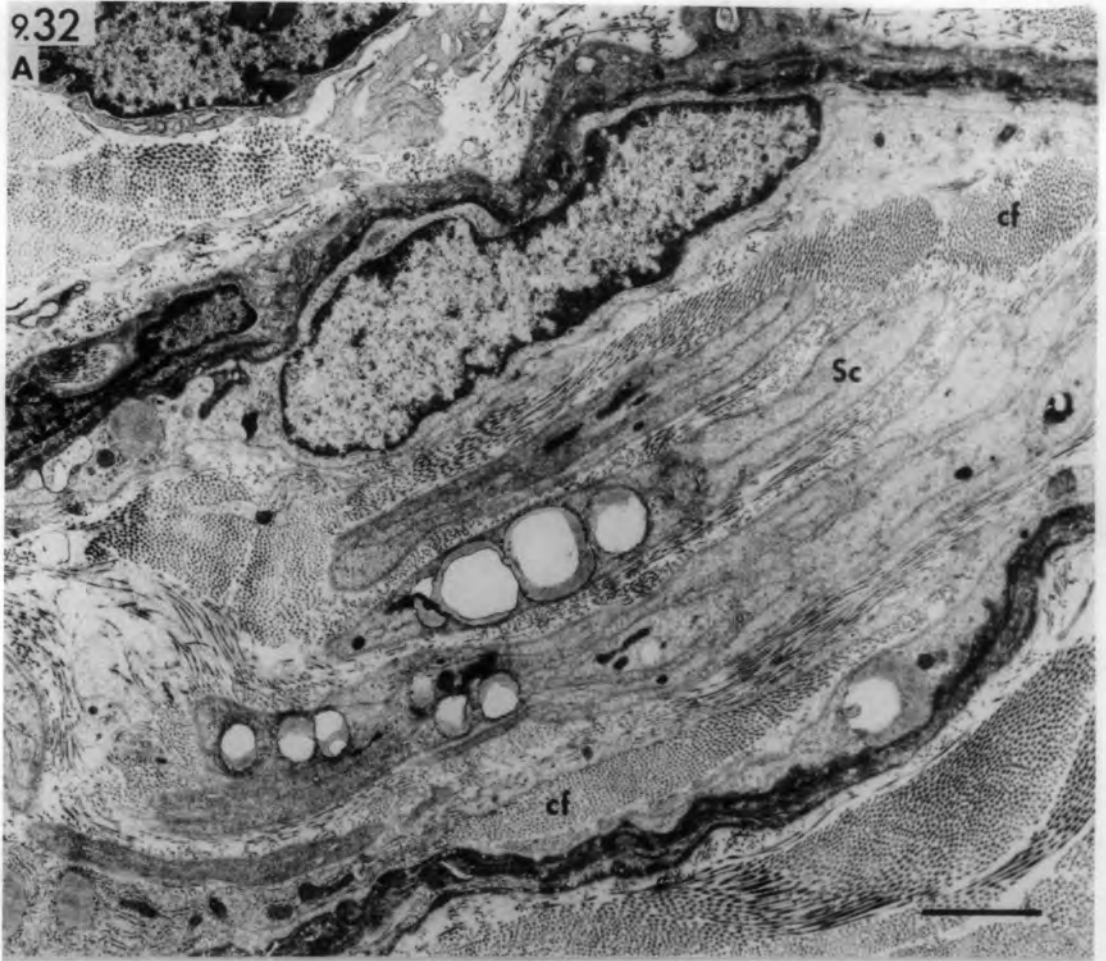bar = 2 $\mu$ m

B. The nerve trunk (asterisk) is empty and collapsed. Note the lipid droplets and Z-line streaming (Z) in the extrafusal fibres. Arrow points to a satellite cell apparently leaving an extrafusal fibre.

bar = 5 $\mu$ m

9.32

A



B

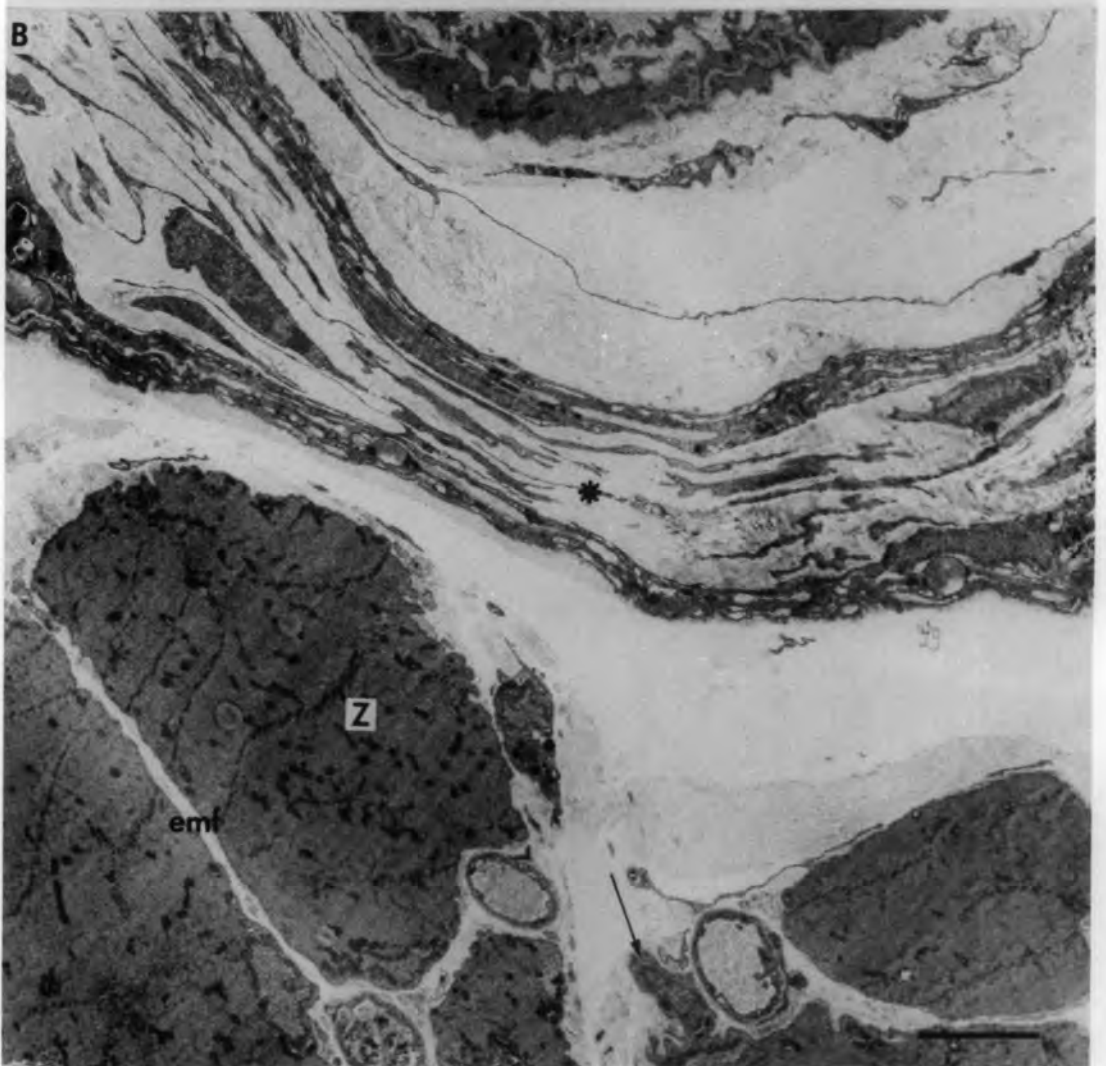

Fig. 9.33 Ischaemic and denervated muscle spindle

(Isch/Dn): 5 days.

Transverse section of the equatorial region shows thick ( $F_1$  &  $F_2$ ) and thin fibres ( $F_3$  &  $F_4$ ). The thick fibres are at a more advanced stage of regeneration than the thin fibres. Several undifferentiated cells (asterisks) resemble the myoblast (mb) in  $F_1$ . Note the extensive basal-lamina profiles and the collagen and elastic fibrils within the axial bundle.

bar = 5 $\mu$ m

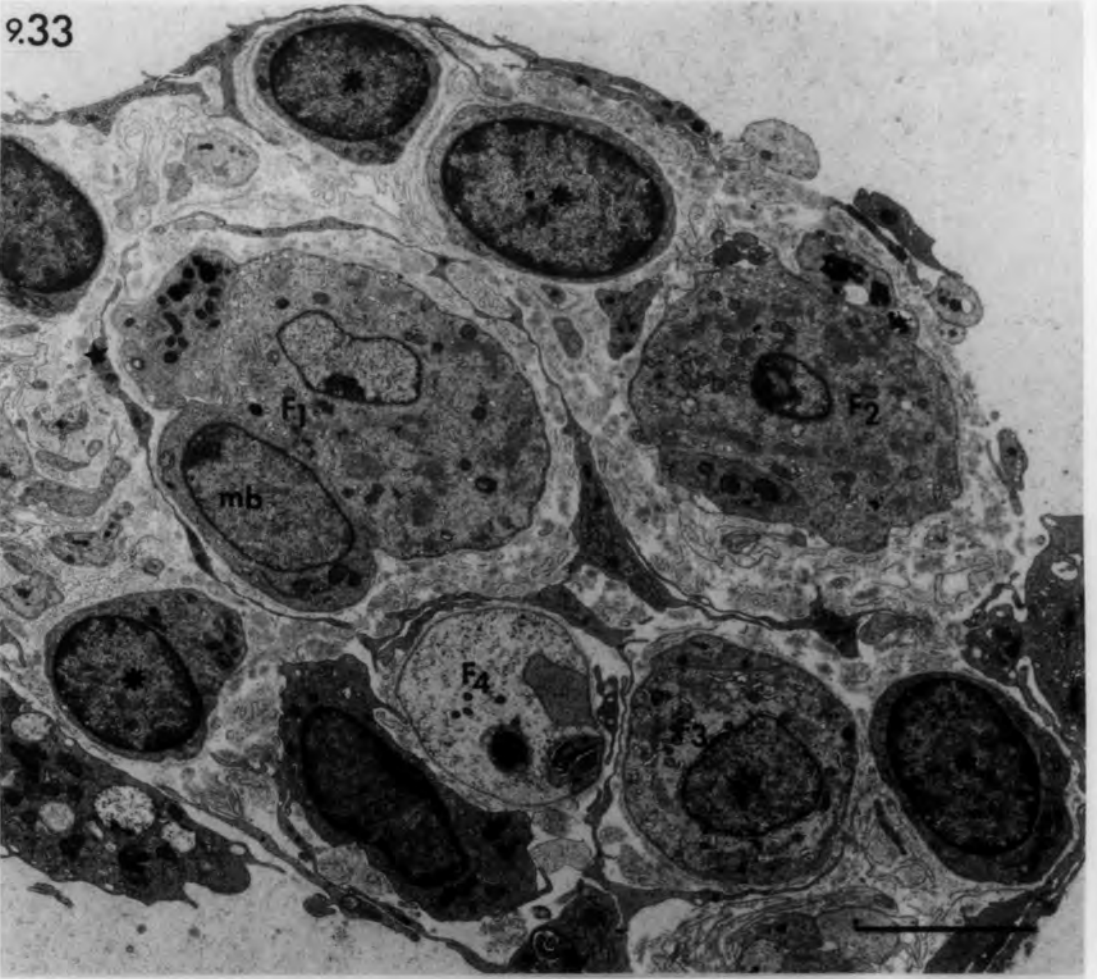Fig. 9.34 Ischaemic and denervated muscle spindle

(Isch/Dn): 8 days.

Transverse section of the equatorial region shows six mature muscle fibres. It was difficult to identify the original intrafusal fibres with certainty because serial sections of the spindle showed a complicated association between the muscle fibres. However,  $F_1$ ,  $F_2$  &  $F_3$  at least are regenerated original intrafusal fibres. The other fibres (asterisks) were probably formed by myotube detachment or by maturation of undifferentiated cells.

bar = 5 $\mu$ m

9.33



9.34

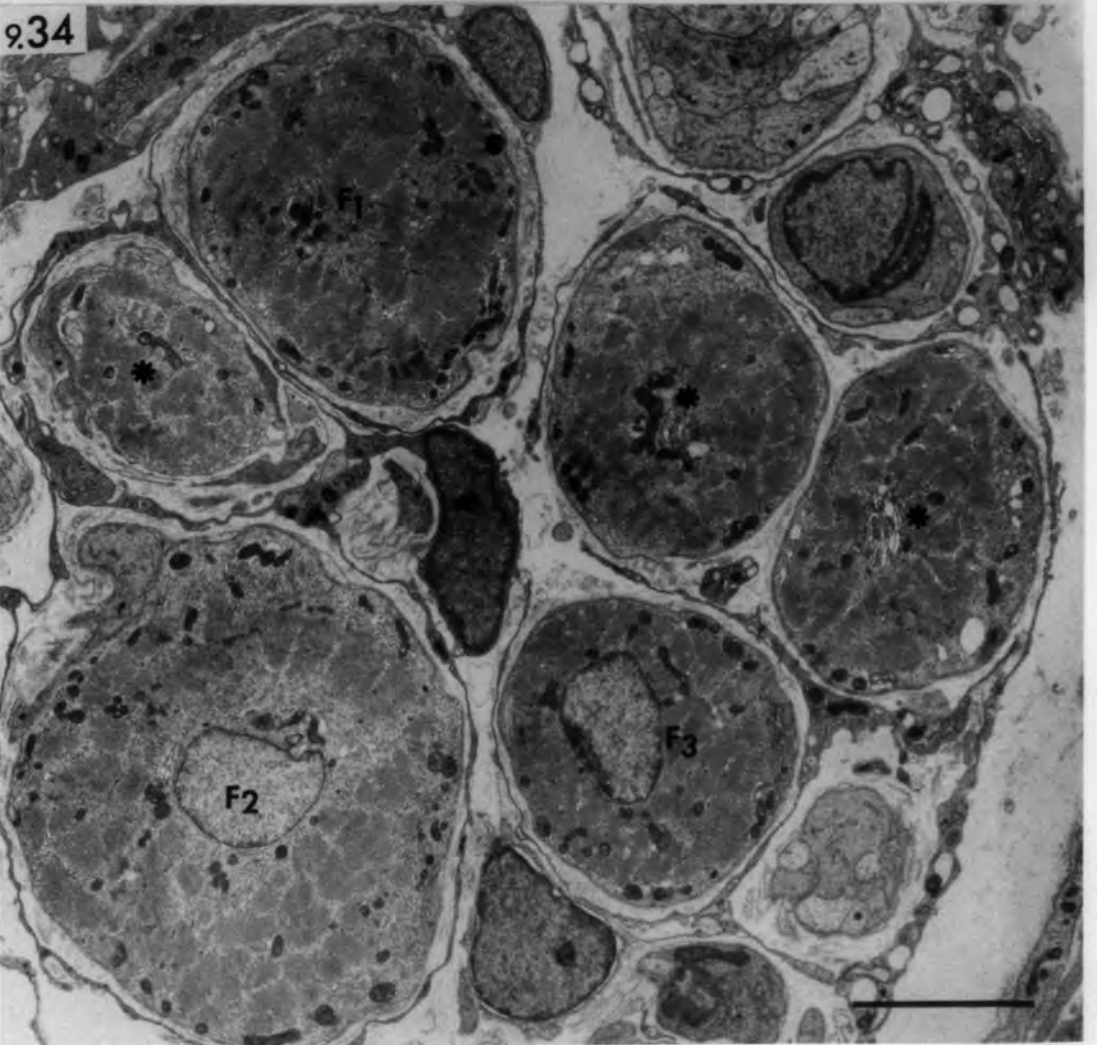


Fig. 9.35 Ischaemic and denervated muscle spindle  
(Isch/Dn), A: 28 days, B & C: 8 days.

Transverse sections of intrafusal fibres  
showing lateral extensions.

- A. Equatorial region: lateral extensions  
(arrows) between intrafusal fibres. Note  
the atrophied fibre (F) and the satellite  
cell (sat) dissociating from it.

bar = 5 $\mu$ m

- B. Intracapsular polar region: lateral  
extension (arrow) between an intrafusal  
fibre and capsule cell.

bar = 1 $\mu$ m

- C. Equatorial region: lateral extension  
(arrow) between an intrafusal fibre and  
axial-sheath cell.

bar = 1 $\mu$ m

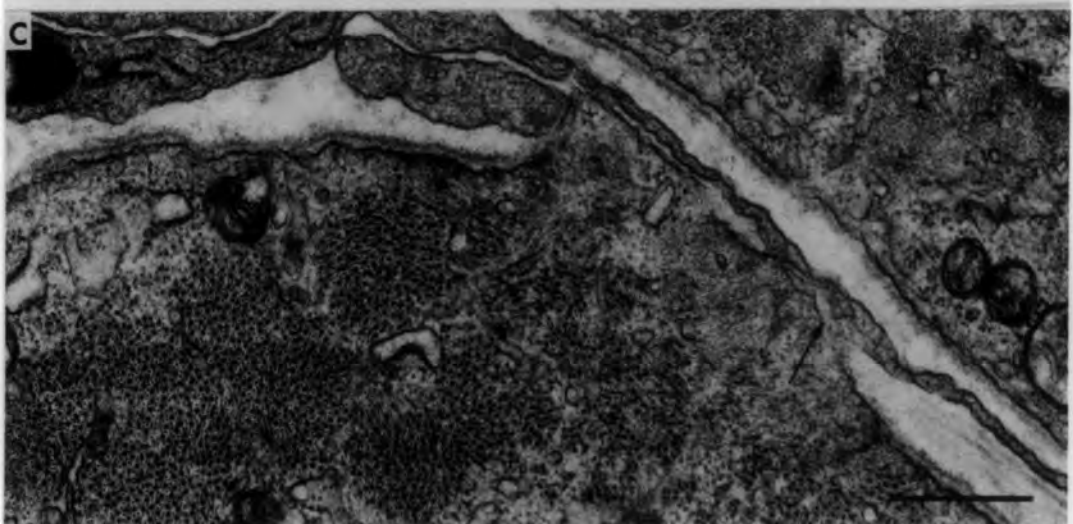
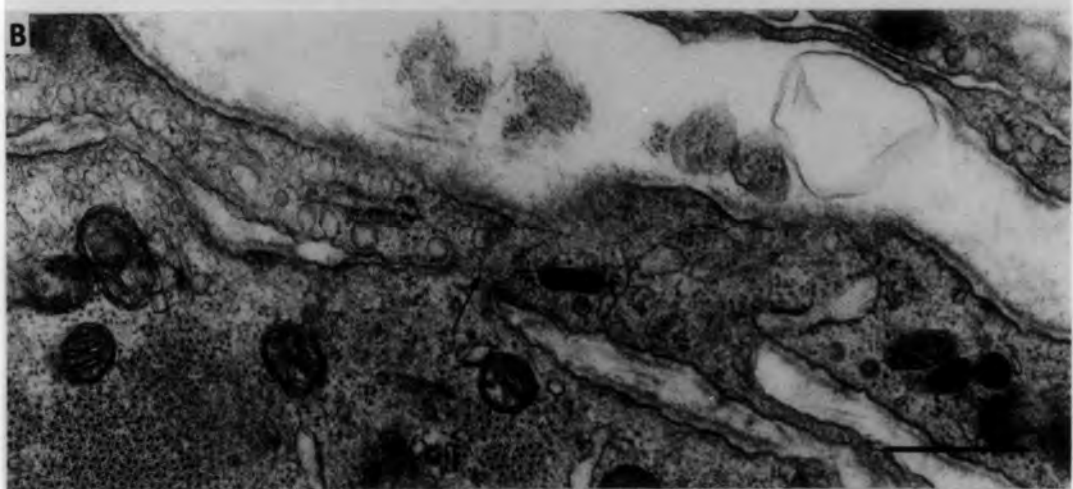
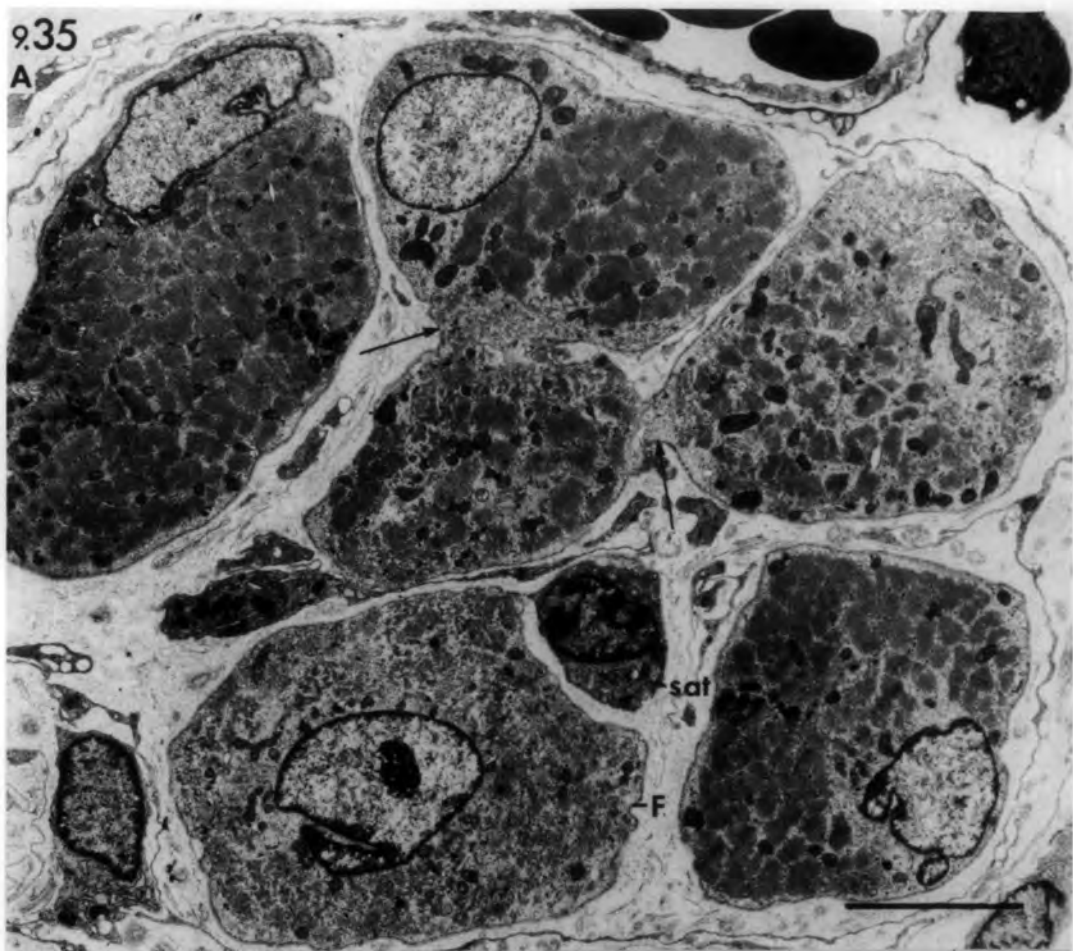


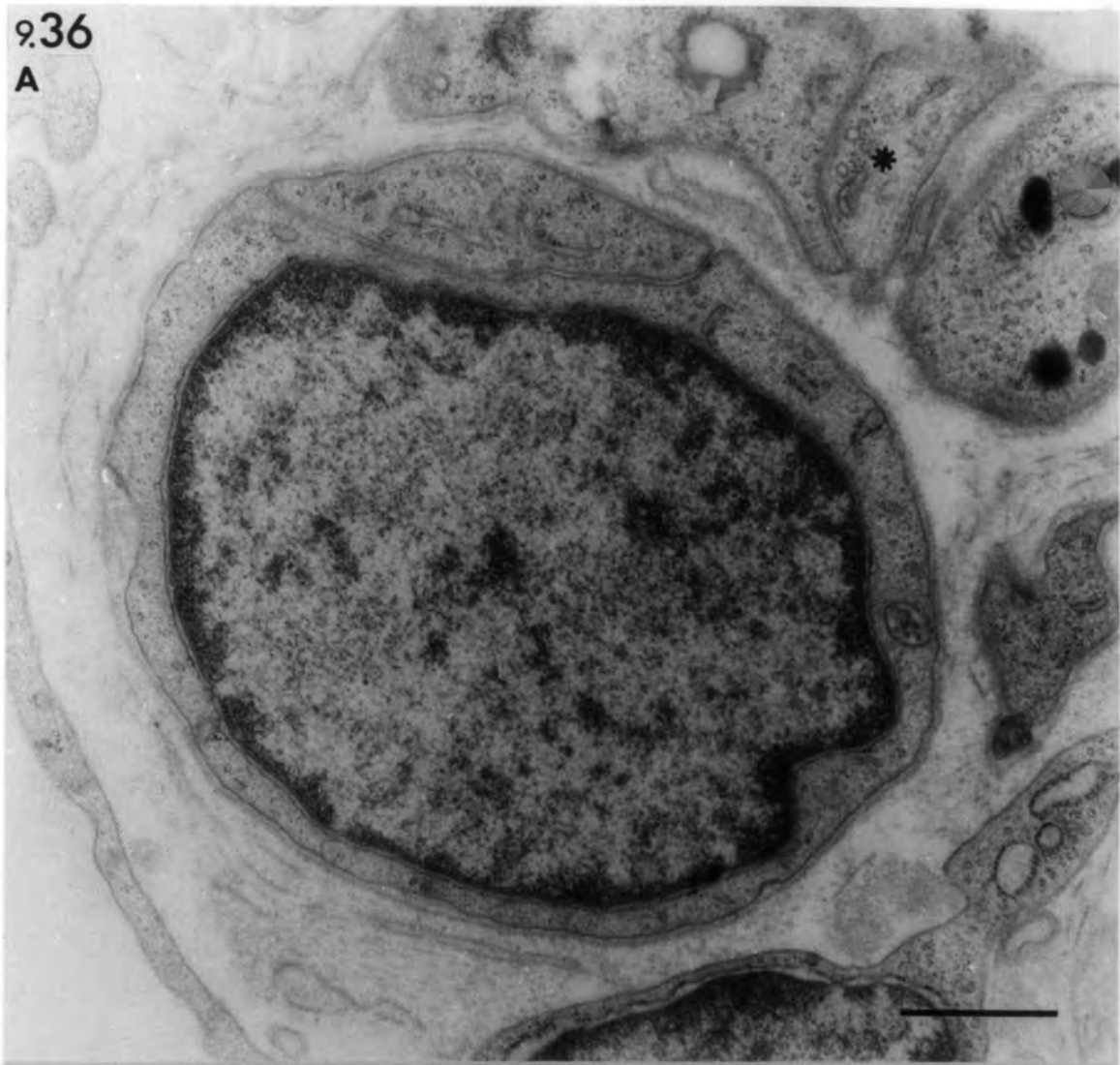
Fig. 9.36 Transverse sections of the equatorial region of muscle spindles showing undifferentiated cells.

- A. Undifferentiated cell resembling a Schwann cell (from a 21 day denervated spindle). Compare the cell with the nearby bands of Büngner (asterisk).
  
- B. Undifferentiated cell resembling a myoblast (from a 5 days-ischaemic and denervated spindle).

bars = 1µm

9.36

A



B

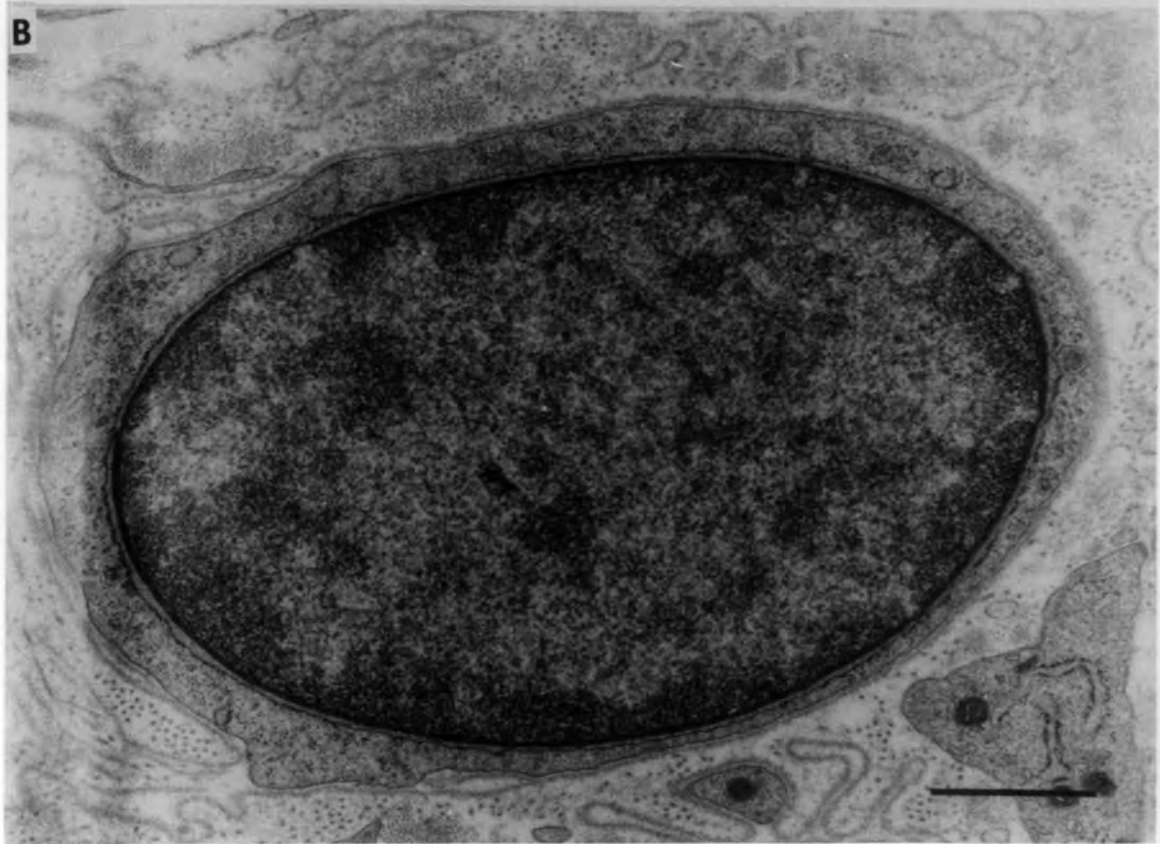


Fig. 9.37 Ischaemic and denervated spindle (Isch/Dn)

A: 21 days, B: 8 days.

- A. Transverse section of the equatorial region showing a poorly-developed additional fibre located in the periaxial space. Note the absence of basal lamina.

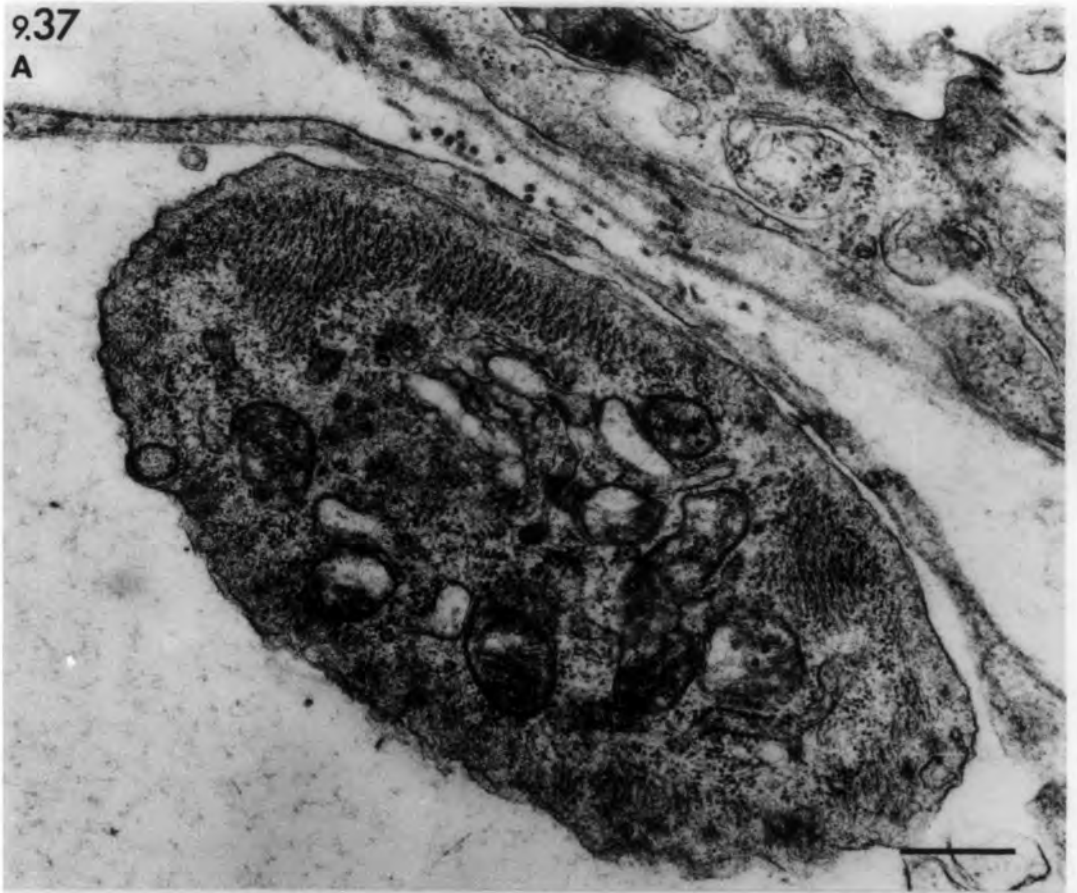
bar = 0.5 $\mu$ m

- B. Transverse section of the intracapsular polar region showing an additional fibre (asterisk) closely-associated with capsule cells. Note the well-developed intrafusal fibres (F<sub>1</sub>-F<sub>3</sub>).

bar = 2 $\mu$ m

9.37

A



B

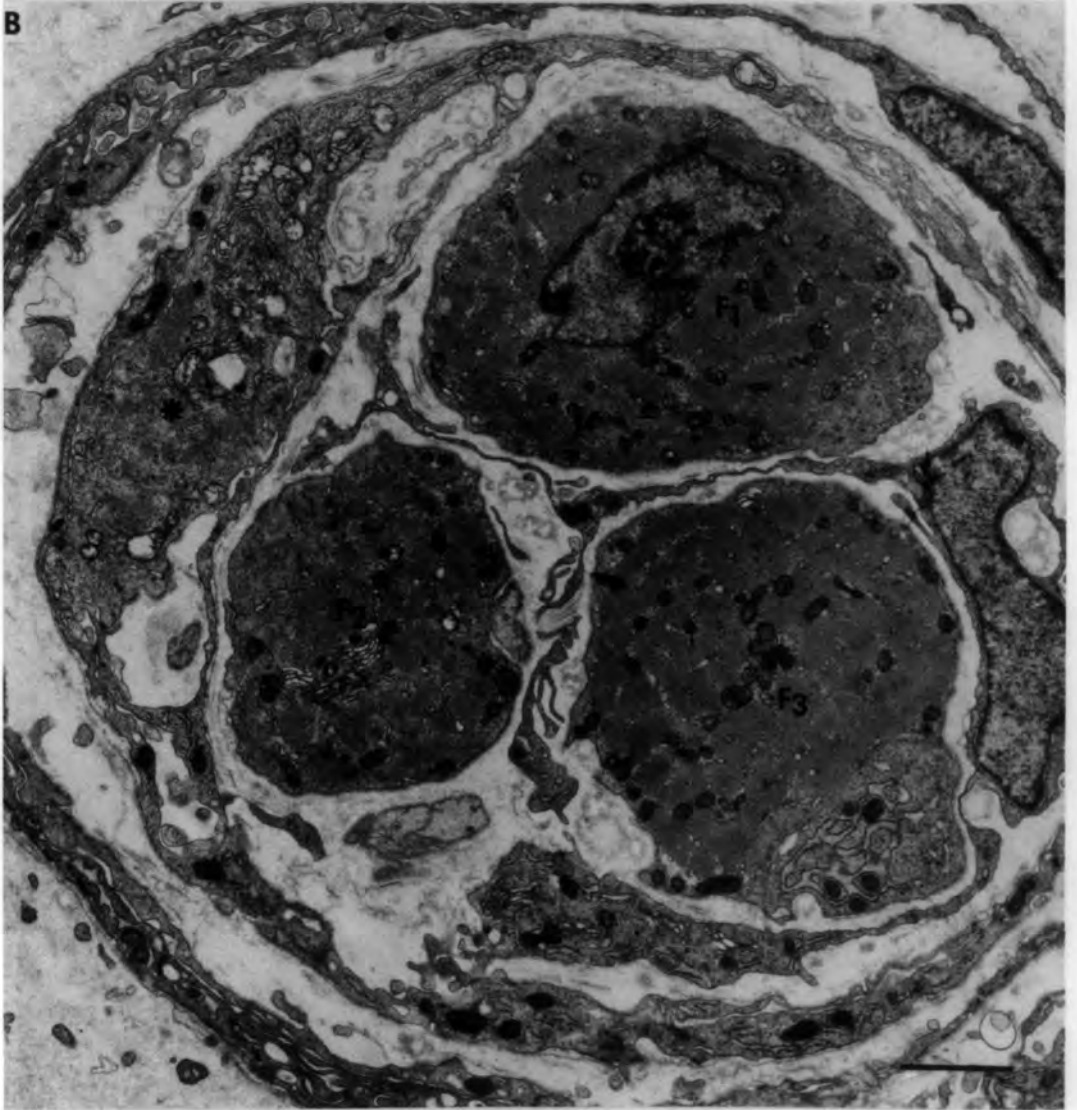

Fig. 9.38 Additional muscle fibres

A. Transverse section of the intracapsular polar region of a muscle spindle (21 days Isch/Dn). A common basal lamina (arrows) encloses an original intrafusal fibre ( $F_1$ ), a satellite cell (sat) and two additional fibres (asterisks). This combination probably formed by the detachment of muscle cells during regeneration. Note the detached satellite cell close to fibre  $F_2$ .

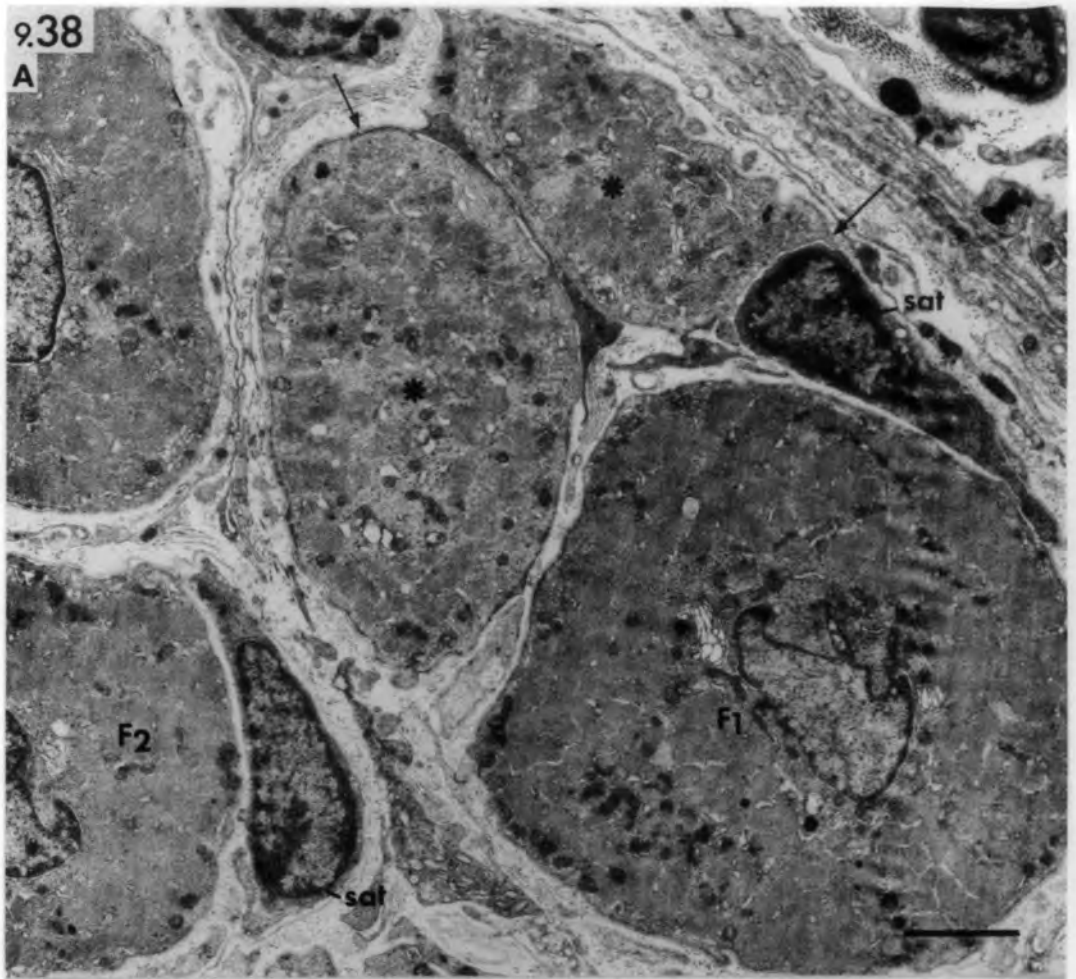
bar =  $2\mu\text{m}$

B. Longitudinal section of the intracapsular polar region of an ischaemic muscle spindle 56 days after devascularization. An atrophied additional fibre (asterisk) is incompletely fused with an original intrafusal fibre (F). A cellular process (arrow) is present in the separating cleft.

bar =  $0.5\mu\text{m}$

9.38

A



B



Fig. 9.39 Ischaemic and denervated muscle spindle

(Isch/Dn): 8 days.

Transverse sections of the equatorial region  
showing bands of Büngner,

A. enclosed by basal lamina

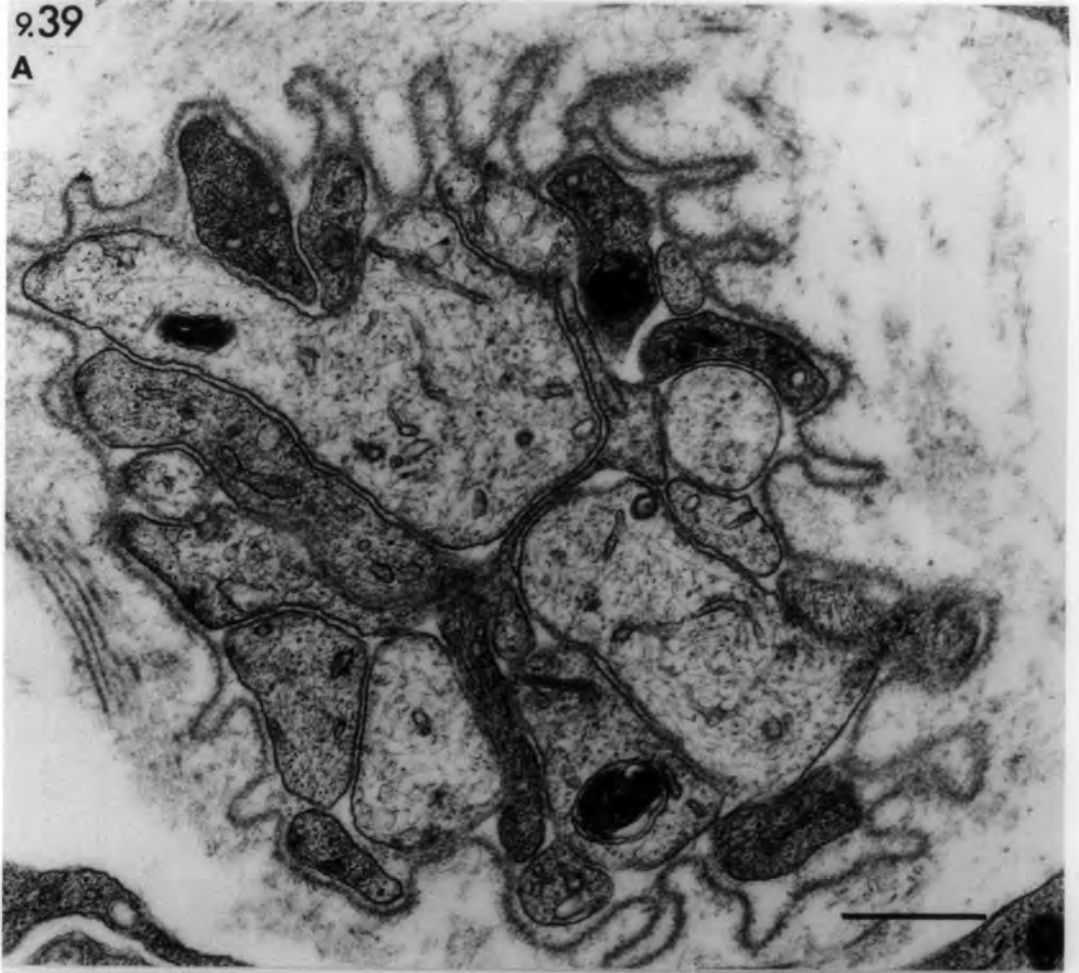
B. (arrow heads) located beneath the basal  
lamina of regenerating myotubes (mt).

Note the axial-sheath process (arrow)  
invading through a break in the basal lamina  
(bl).

bars = 1 $\mu$ m

9.39

A



B

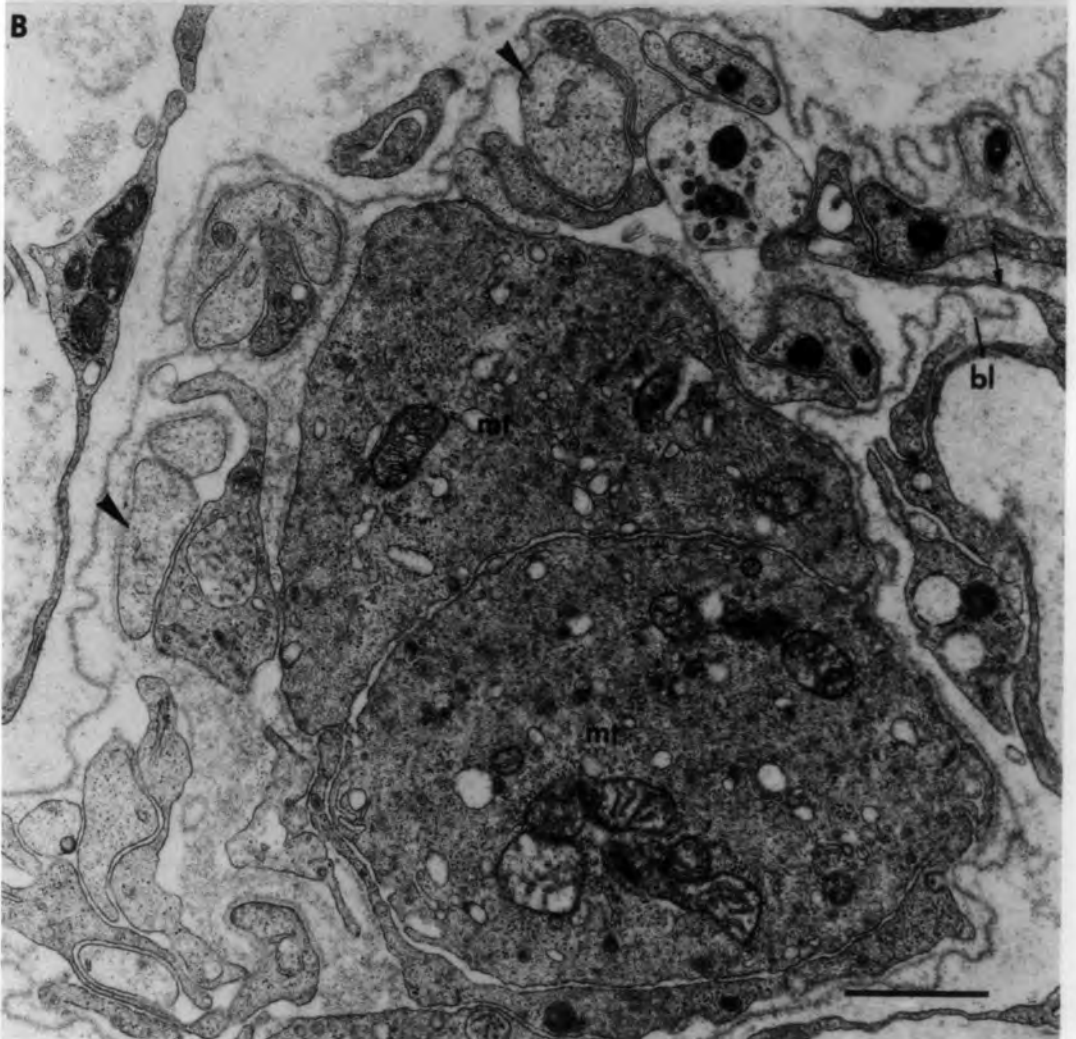


Fig. 9.40 Ischaemic and denervated muscle spindle

(Isch/Dn): 56 days.

Transverse section of the equatorial region showing four intrafusal fibres ( $F_1$ - $F_4$ ) and two very thin additional fibres (asterisks).

$F_1$  and  $F_2$  probably represent the original bag<sub>1</sub> and bag<sub>2</sub> fibres, whilst  $F_3$  and  $F_4$  represent two original chain fibres. Note the distinct M-line in  $F_1$ .

bar = 5 $\mu$ m

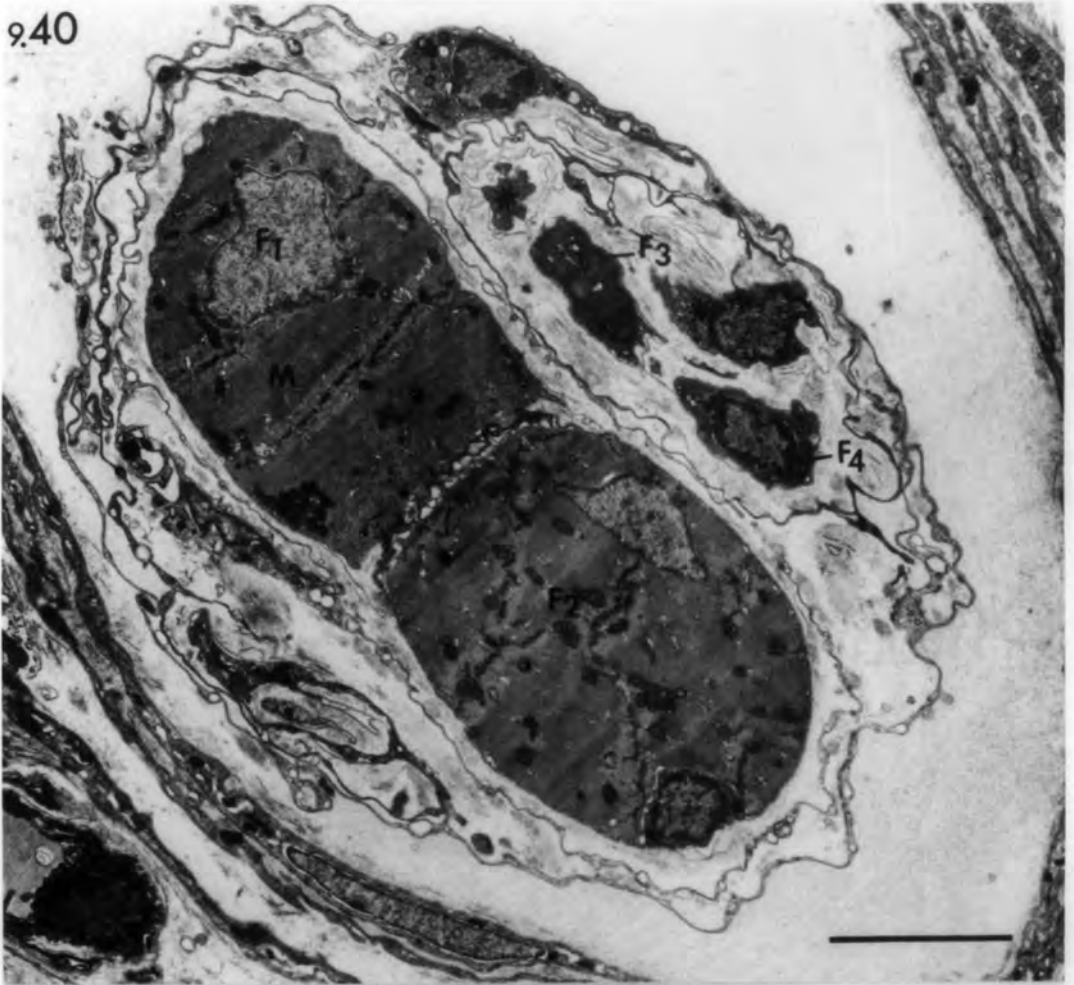
Fig. 9.41 Denervated muscle: 156 days

Transverse section of extrafusal fibres shows a satellite cell raised from the surface of an extrafusal fibre (emf). Compare with the separated satellite cell in Fig. 9.38A.

hc: helical complex.

bar = 0.5 $\mu$ m

9.40



9.41

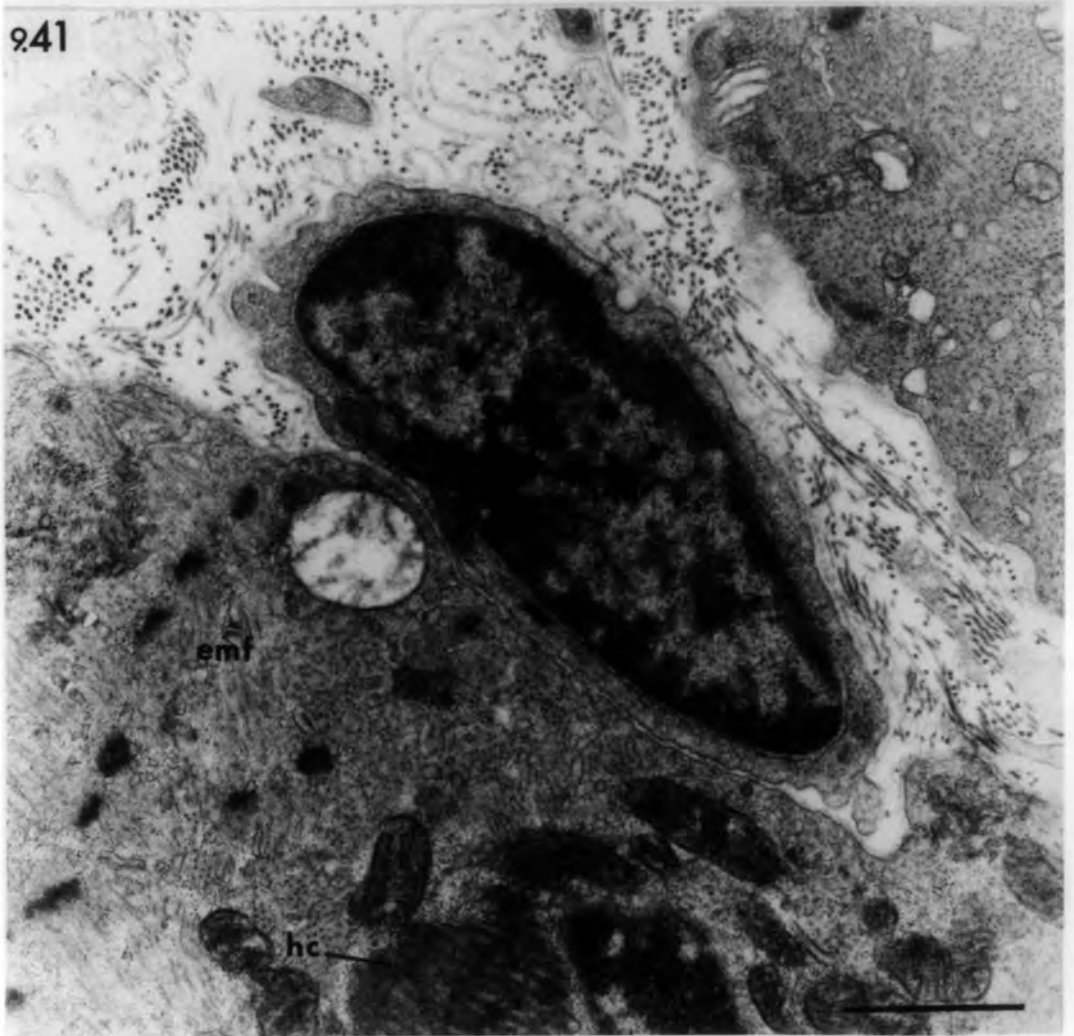


Fig. 9.42 Ischaemic and denervated muscle (Isch/Rn/Dn)

A: 14 days, B: 28 days.

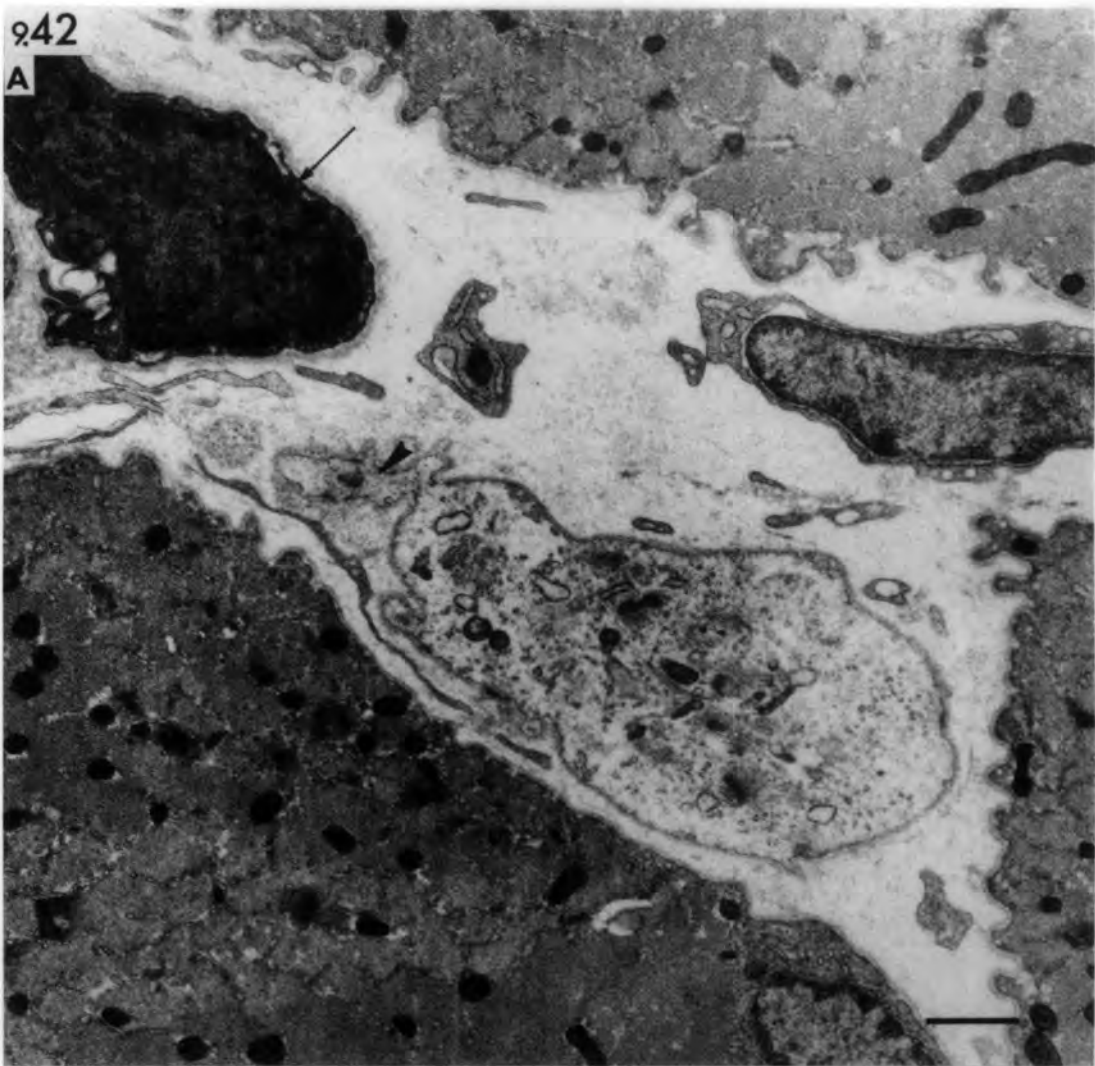
Transverse sections showing small muscle cells  
in the interstitial space.

- A. A poorly-developed myotube. Note the sarcolemmal projection (arrow head). An undifferentiated cell (arrow) resembles a satellite cell.
- B. Two muscle fragments that have a similar structure to the nearby large extrafusal fibre (emf).

bars = 1 $\mu$ m

942

A



B

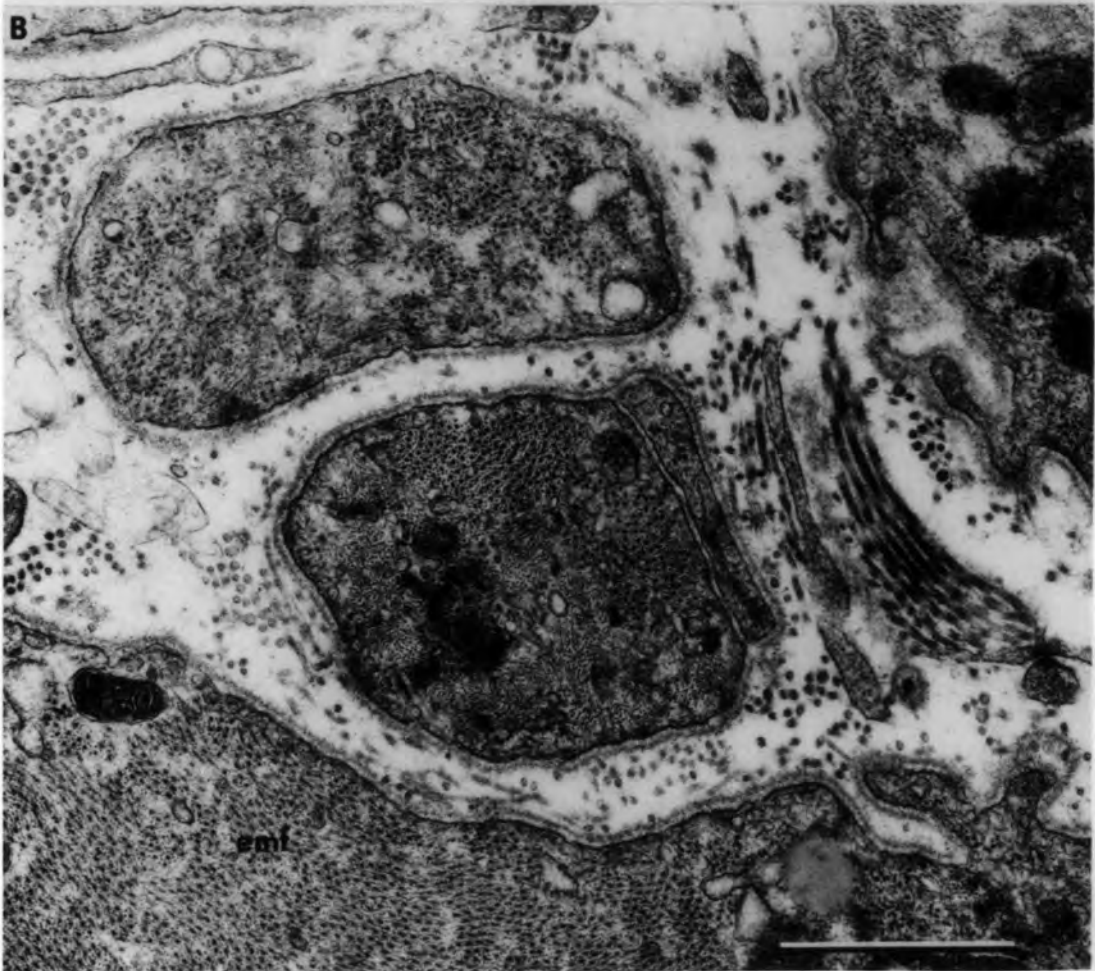


Fig. 9.43 Transverse sections of extrafusal muscle fibres showing modified basal lamina.

A. Denervated muscle (56 days): a compact thread of double basal lamina (arrows) surrounding three muscle cells.

bar = 5 $\mu$ m

B. Higher power of part of Fig. A to show details of the compact basal lamina. Note the small granules at the centre of the basal-lamina rings (arrow heads). Arrow points to an attachment between the compact basal lamina and that of the sarcolemmal projection.

bar = 0.5 $\mu$ m

C. Ischaemic and denervated muscle (8 days Isch/Dn). The old basal lamina (bl) encloses granules (arrow head).

bar = 0.5 $\mu$ m

943

A

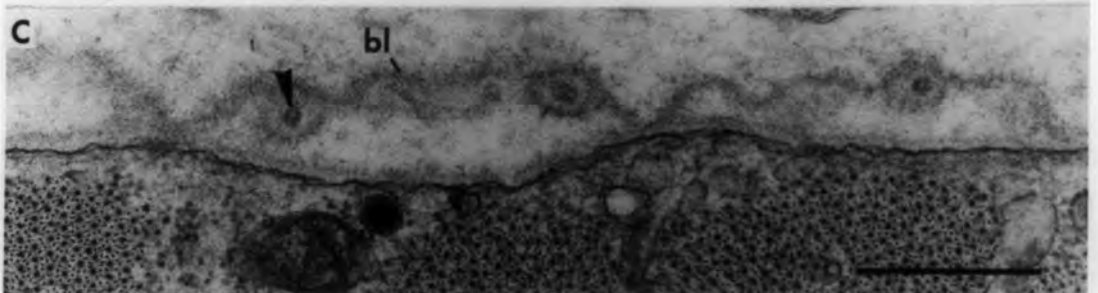
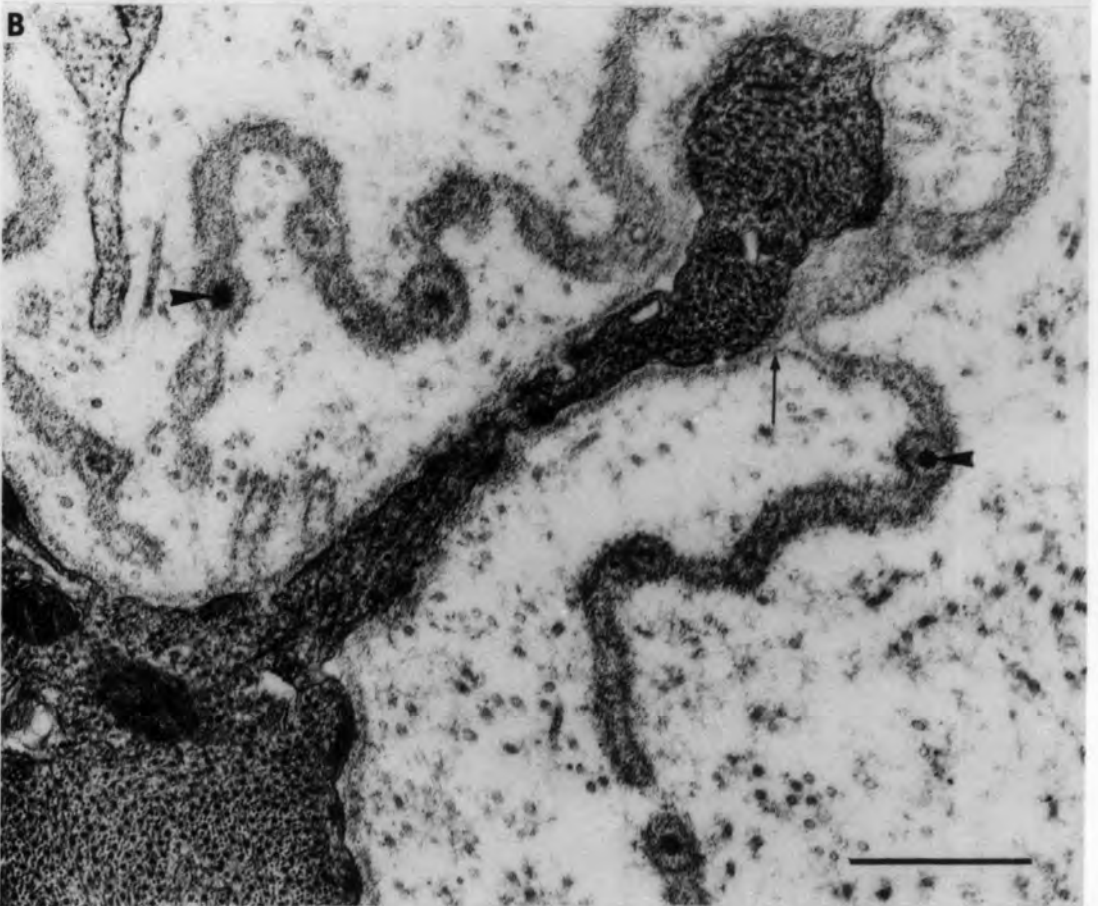
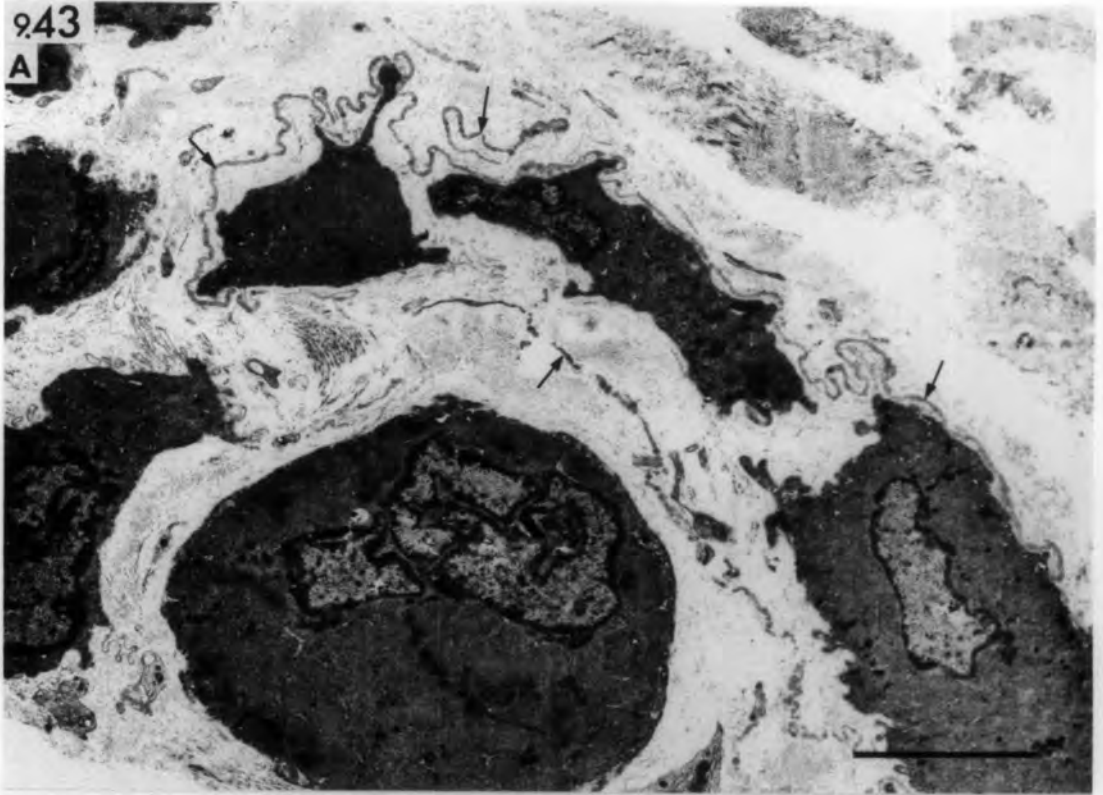


Fig. 9.44. Ischaemic and denervated muscle spindle

(Isch/Rn/Dn): 56 days

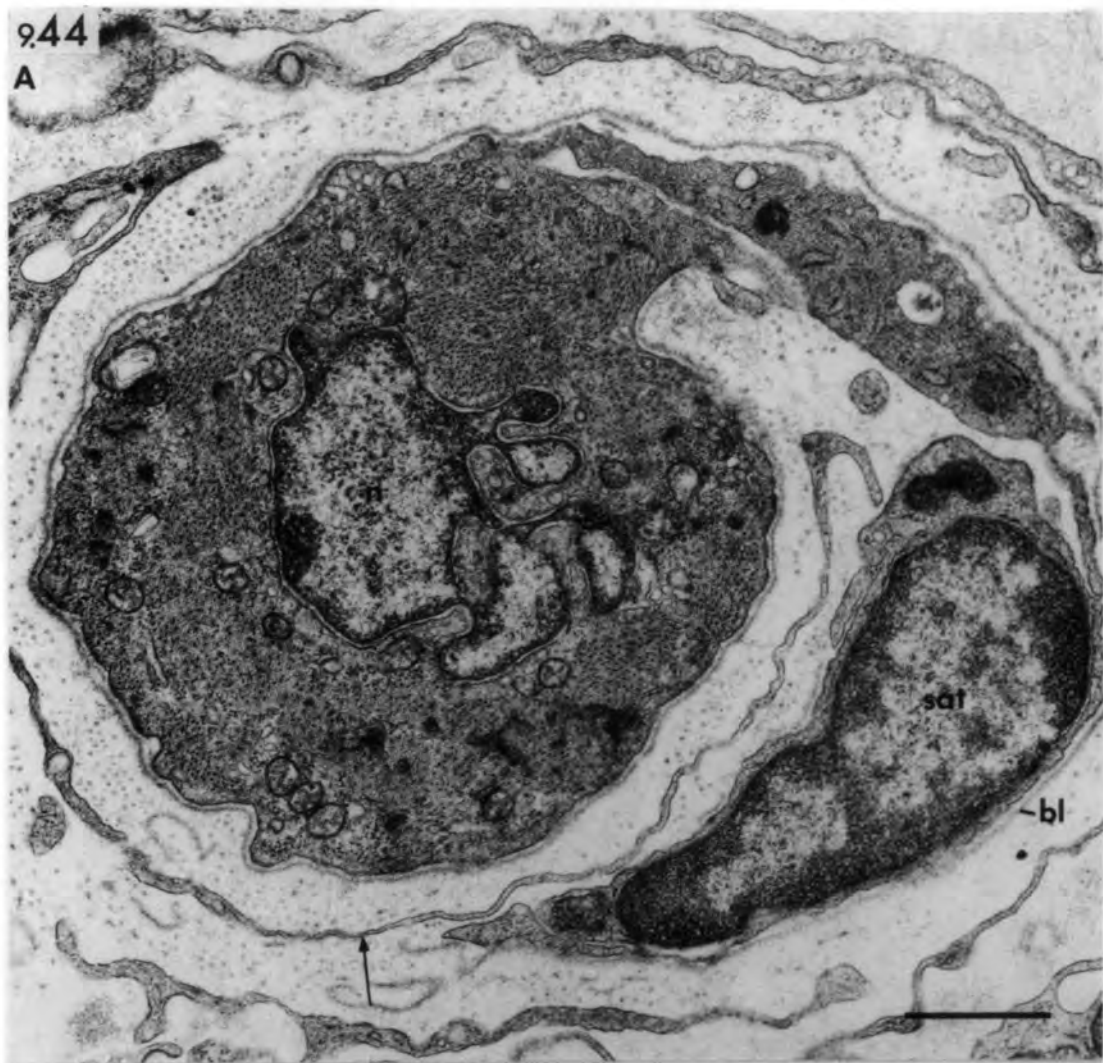
Transverse section of the equatorial region showing possible satellite-cell migration from intrafusal muscle fibres.

- A. A satellite cell (sat) completely separated from the muscle fibre and only partially enclosed by a broken old basal lamina (bl). Arrow points to invading process of an axial-sheath cell. Note abnormally-shaped nucleus (n) in the centre of the muscle fibre.
- B. A satellite cell loosely-attached to an intrafusal fibre and enclosed by its basal lamina.

bars = 1µm

9.44

A



B

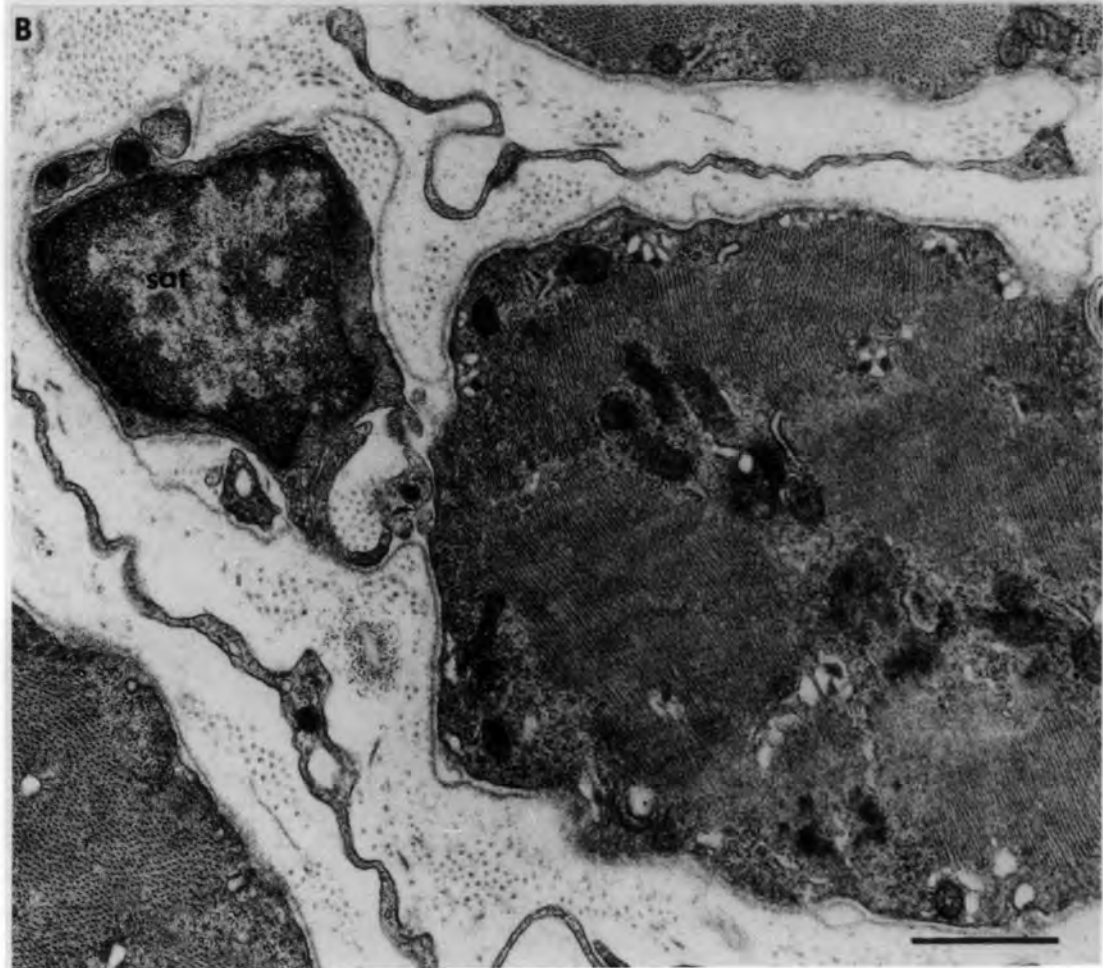


Fig. 9.45 Ischaemic and denervated muscle spindle

(Isch/Rn/Dn): 56 days.

Transverse section of the equatorial region shows four intrafusal fibres ( $F_1$ - $F_4$ ) and two additional fibres (asterisks). Serial sections of the spindle showed the additional fibre associated with  $F_1$  to be relatively long. Observations from other sections and the presence of the interposed satellite cell in this section suggest that the additional fibre formed by splitting of fibre  $F_1$ . The additional fibre associated with  $F_3$  is shorter and probably formed by myotube detachment during regeneration. Note the presence of a capillary (cpl), fibrin threads (f), and numerous erythrocytes.

bar = 10 $\mu$ m

9.45

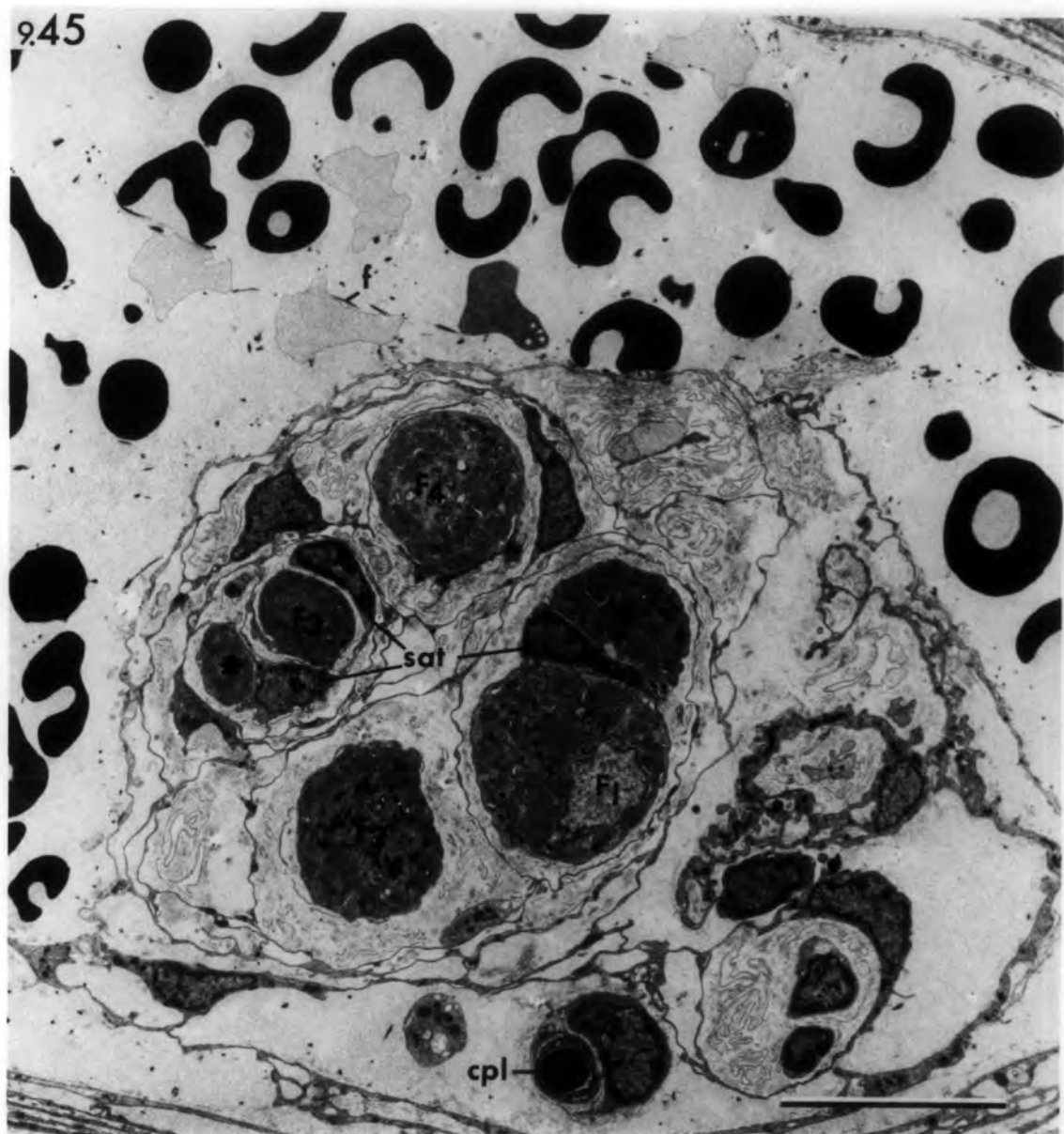

Fig. 10.1 Schematic diagram illustrating the proposed zonal distribution of the four groups of regenerated ischaemic spindles.

Differences in the innervation and equatorial nucleation of regenerated intrafusal muscle fibres in individual spindles, and between the various groups of regenerated spindles, suggest that the differentiation of the equatorial region is dependent on the degree of maturity of the regenerating intrafusal fibres at the time of sensory reinnervation.

The progressive nature of revascularization from the periphery (p) to the centre (c) of the muscle results in a gradient of regeneration in the same direction. At any one time during regeneration, the intrafusal fibres of spindles located in the central core of the muscle would be less mature than those located peripherally.

The reinnervating Ia afferent would induce the full differentiation of the immature intrafusal fibres of the central-core spindles (Group 1). In contrast to this, the Ia afferent would be unable to establish terminals on the mature intrafusal fibres of the peripheral spindles (Group 4). The intrafusal fibres of subgroup 4A are thicker than normal, and are reinnervated exclusively by motor axons. Those of subgroup 4B are thinner than normal and lack any kind of innervation.

The degree of restoration of spindles located in between is related to their distance from the muscle centre. In those spindles located close to the centre (Group 2), the incomplete differentiation of the "bag" fibres may be related to their advanced maturity compared with the "chain" fibres of the same spindles. In spindles located more peripherally (Group 3), all of the intrafusal fibres are more mature than those of Group 2 spindles at the time of the reinnervation so that sensory nerve terminals are established exclusively on the thinner original "chain" fibres.

The broken lines approximately delineate the zonal areas. The largest zone is the intermediate region in which Group 3 spindles are located. Muscle spindles were not seen in the thin peripheral zone.



