

## Durham E-Theses

---

*A clinical and archaeological study of Schmorl's  
Nodes: using clinical data to understand the past*

Janet Mary McNaught

### How to cite:

---

McNaught, Janet Mary (2006) A clinical and archaeological study of Schmorl's Nodes: using clinical data to understand the past. Doctoral thesis, Durham University.

### Use policy

---

The full-text may be used and/or reproduced, and given to third parties in any format or medium, without prior permission or charge, for personal research or study, educational, or not-for-profit purposes provided that:

- a full bibliographic reference is made to the original source
- a <https://etheses.durham.ac.uk/id/eprint/2689/> is made to the metadata record in Durham E-Theses
- the full-text is not changed in any way

The full-text must not be sold in any format or medium without the formal permission of the copyright holders.

Please consult the [full Durham E-Theses policy](#) for further details.

# **A Clinical and Archaeological Study of Schmorl's Nodes:**

Using clinical data to understand the past

**Janet Mary McNaught**

PhD Thesis


2006

The copyright of this thesis rests with the author or the university to which it was submitted. No quotation from it, or information derived from it may be published without the prior written consent of the author or university, and any information derived from it should be acknowledged.

Department of Archaeology

University of Durham

VOLUME 1 (Chapters 1 – 5)



11 JUN 2007

## **DECLARATION**

No part of this material has been previously submitted in part or as a whole for a degree in this university or any other university. This thesis is the result of my own work.

## **COPYRIGHT**

The copyright of this thesis rests with the author. No quotation from it should be published in any format, including electronic, and the internet without the author's prior written consent. All information derived from this thesis must be acknowledged appropriately.



## **Abstract**

This study of Schmorl's nodes in British populations past and present attempts to reach a better understanding of the origins and aetiology of Schmorl's nodes and their impact upon the vertebral column in relation to age, sex, pre-existing skeletal lower limb asymmetry, and work patterns. Georg Schmorl has been accepted as the leading authority on the nodes he named. Eighty years later modern diagnostic radiographic imaging and macroscopic studies are used to reach informed answers to the questions of prevalence, relationship to other degenerative joint diseases of the spine, and the possibility of Schmorl's node recognition by clinicians when presented with specific pain location. The clinical samples studied were from Pinderfields Hospital, Wakefield, and the Royal Hospital for Sick Children, Edinburgh. The archaeological samples studied were from Captain's Cabin, Dunbar, The Hirsell, Coldstream and Whithorn Priory, Galloway, all in Scotland, and St. Andrew, Fishergate, York, and Tanners Row, Pontefract in England, and dated to between the 6<sup>th</sup> and 16<sup>th</sup> centuries AD. The archaeological samples were from military and monastic settlements in urban and rural contexts. Congenital disorders and acute trauma affecting the spine, and alterations to the normal primary and secondary vertebral curves were studied in an attempt to prove or disprove a relationship to Schmorl's nodes. Macroscopic study of the vertebral columns from the archaeological samples, and radiographs of the clinical samples, were analysed, along with clinical case histories and known background information of the demography, settlement type and, the geographic and topographic locations for each sample. No weak area was found in the vertebral end plate. Positive proof for symptomatic Schmorl's nodes was found in the clinical samples. The greatest numbers of Schmorl's nodes were not formed in the first two decades of life, but in the third and fourth decades. Scheuermann's disease may be indirectly attributable to subadult Schmorl's nodes. However, Schmorl's nodes may or may not precede scoliosis. Males and females of similar ages from the same settlements did not produce similar frequencies, nor were similar patterns observed between samples. Further studies using larger and better-preserved samples, with good contextual evidence may help to provide clearer positive or, negative evidence for work related Schmorl's nodes.

## **Acknowledgements**

Completion of this thesis is in no small part due to the many people whom I have met along the way, who willingly discussed, advised, and listened, as Schmorl and his nodes were studied in libraries, museum archives, and departments of radiography. I would like to thank the following people and departments, starting with Robert Bovaird McNaught, whose understanding and belief in me has never wavered during the production of this thesis, and whose cartographic skills are manifest in the maps within the pages of this work. My thanks to Charlotte Roberts, my supervisor, who has shown me that self-belief, a sound knowledge of my field of research, and a willingness to look beyond the obvious were required to succeed, while still having time to listen and discuss the lighter moments of life. Thanks to Andrew Jones and Don Brothwell for encouraging me to take my interest in Schmorl's nodes forward and to Steve Dockrill for introducing me to Charlotte Roberts. Thanks to Alison Sheridan and Jacqueline Moran who showed me the distant stores of the Royal National Museum of Scotland. Thanks for the unforgettable time in Aberdeen to Clare Lamb and Ian Stewart in the Marischal School of Anatomy for providing workspace beside the mort-safes and crocodile. Thanks to all of the following: Mary McLeod and Noel Fojut (Historic Scotland); Ian Roberts, Rob McNaught and Jane Richardson (West Yorkshire Archaeology Services); Christine McDonnell, Annie Jowett, Bev Shaw and Christine Kyriacou (York Archaeological Trust); Alison Scott (RHSC); Edward Duval and Donald Salter (Edinburgh University School of Medicine); Rosemary Cramp and Sue Anderson for use of unpublished material from the Hirsell, Coldstream; Nicola Winter and Mark Wigglesworth (photography); Dianne Llewellyn, Karen Hill, Emily Harker and Adam Smith (Pinderfields Hospital Library), and Matt Williams (Pinderfields Hospital, Radiation Physics and Medical Research). Last but not least to all of the radiography staff at Pinderfields Hospital, especially Jonathan Siddall, Carol Spink, Shirley Stephens, Neil Roberts and Gary Holdsworth.

Thank you to the Rosemary Cramp Trust, John Wheelwright Trust and to Agfa-Gaevert, who each funded parts of this research.

# CONTENTS

<b>CHAPTER I: Introduction</b>	<b>32</b>
1.1 What are Schmorl's nodes?	32
1.2 Hypotheses, aims, and objectives	34
1.3 Christian Geörg Schmorl, the man, and the pathologist	39
1.3.1 Christian Geörg Schmorl: his work on Schmorl's nodes and his main findings	41
1.3.2 Methods used by Schmorl	44
(i) Dissection	44
(ii) Radiography	47
(iii) Christian Geörg Schmorl and Junghanns and the development of Schmorl's nodes	48
(iv) The main findings from Schmorl's research	53
1.4 Research on Schmorl's nodes since Schmorl	58
1.4.1 Research without direct reference to Schmorl	58
1.4.2 The use of magnetic resonance imaging	60
1.4.3 Scheuermann's disease and Schmorl's nodes	60
1.5 Schmorl's nodes in clinical practice today	61
1.6 Schmorl's nodes in biological anthropology	62
<b>CHAPTER 2: THE VERTEBRAL COLUMN: Structures and Development</b>	<b>65</b>
2.1 Introduction	65
2.2 Development of the vertebral column	68
2.2.1 Embryonic development: The first nine weeks	68
(i) Week 1	68
(ii) Week 2	69
(iii) Week 3	70
(iv) Weeks 4 and 5	70

(v)	Weeks 6 and 7	71
(vi)	Week 8	72
(v)	Week 9	72
2.2.2	Foetal development: week 10 to birth	72
2.2.3	Neonatal vertebral column	74
2.2.4	Ossification and fusion of the vertebral elements	75
(i)	The neural arch	75
(ii)	Union between the neural arch and centrum	76
(iii)	End plate union	77
(iv)	Secondary centres of ossification	77
<b>2.3</b>	<b>Anatomy of the adult vertebral column</b>	<b>78</b>
2.3.1	Cervical vertebrae	78
(i)	The first cervical vertebra	79
(ii)	The second cervical vertebra	79
(iii)	The seventh cervical vertebra	80
2.3.2	Thoracic vertebrae	81
(i)	The first thoracic vertebra	82
(ii)	The ninth thoracic vertebra	82
(iii)	The tenth thoracic vertebra	82
(iv)	the eleventh thoracic vertebra	82
(v)	The twelfth thoracic vertebra	82
2.3.3	Lumbar vertebrae	82
2.3.4	Sacrum	83
(i)	The sacral promontory	84
(ii)	The spinous tubercles	84
(iii)	The sacral hiatus	85
2.3.5	Coccyx	85
2.3.6	Primary and secondary curves	85
(i)	Primary curve	86
(ii)	Secondary curves	86

(iii)	Curvature in the elderly	87
2.3.7	Intervertebral discs	87
(i)	Nucleus pulposus	89
(ii)	Annulus Fibrosus	89
(iii)	End plates	90
(iv)	Intervertebral disc nutrition	92
<b>2.4</b>	<b>Physiology of the adult vertebral column</b>	<b>92</b>
2.4.1	Myology of the thoracic and lumbar vertebrae	92
(i)	The multifidus muscle	93
(ii)	The erector spinae muscle	95
(a)	The spinalis	95
(b)	The iliocostalis	96
(c)	The longissimus	96
(iii)	The interspinales muscle	97
(iv)	The quadratus lumborum	97
(v)	The psoas major muscle	98
2.4.2	Ligaments	99
(i)	Anterior longitudinal ligament	99
(ii)	Posterior longitudinal ligament	100
(iii)	Supraspinous ligament	101
(iv)	Interspinous ligament	102
(v)	Ligamentum flavum	102
(vi)	Sharpeys fibres	103
2.4.3	Tendons	103
2.4.4	Nerve and blood supply	104
(i)	The nerve roots	104
(ii)	The blood vessels of the vertebral column	106
(a)	The arterial supply	106
(b)	The venous drainage	107

<b>CHAPTER 3: THE VERTEBRAL COLUMN: its disorders, diseases, and associated conditions</b>	110
<b>3.1 Introduction</b>	110
<b>3.2 Degenerative joint disease of the spine</b>	110
3.2.1 Osteophyte formation	112
3.2.2 Articular surface pitting	112
3.2.3 Alterations of joint contours	113
3.2.4 Reduction of joint space	113
3.2.5 Eburnation and subchondral cysts	114
<b>3.3 Ankylosing spondylitis</b>	114
<b>3.4 Diffuse idiopathic skeletal hyperostosis</b>	116
<b>3.5 Osteopenia and Osteoporosis</b>	118
3.5.1 Osteopenia	118
3.5.2 Osteoporosis	119
<b>3.6 Scheuermann's kyphosis</b>	120
3.6.1 Juvenile osteochondritis	122
3.6.2 Adult osteochondritis	123
<b>3.7 Alterations to the primary and secondary curves</b>	125
3.7.1 Loss of curves of the spine	125
3.7.2 Retrolisthesis	126
3.7.3 Scoliosis	128
(i) Congenital scoliosis	129
3.7.4 Kyphosis	130
<b>3.8 Talipes Equinovarus</b>	130
<b>3.9 Irregular endplates</b>	132
<b>3.10 Loss of disc height</b>	133
<b>3.11 Posterior neural arch defect</b>	134
3.11.1 Spondylolysis	135
3.11.2 Spondylolisthesis	135
3.11.3 Spina Bifida	136

(i)	Spina bifida occulta	137
(ii)	Spina bifida cystica	138
<b>3.12</b>	<b>Associated conditions</b>	<b>139</b>
3.12.1	Asymmetry of leg length	139
 <b>CHAPTER 4: Material and Methods I: Clinical</b>		<b>142</b>
<b>4.1</b>	<b>Introduction</b>	<b>142</b>
4.1.1	The relevance of clinical data	143
4.1.2	The choices of clinical samples	143
<b>4.2</b>	<b>Clinical samples: selection criteria</b>	<b>144</b>
4.2.1	Ethical considerations	145
4.2.2	Data selection	147
4.2.3	Protocols	148
4.2.4	The X-Ray card and the relevance to this research	149
<b>4.3</b>	<b>Pinderfields and Clayton Hospitals: location and environment</b>	<b>151</b>
4.3.1	Pinderfields and Clayton Hospitals: Group I	153
4.3.2	Materials	153
4.3.3	Methods	154
<b>4.4</b>	<b>Pinderfields and Clayton Hospitals: Group II</b>	<b>158</b>
<b>4.5</b>	<b>Royal Hospital for Sick Children: Group III</b>	<b>160</b>
4.5.1	Background information	160
4.5.2	Materials	161
4.5.3	Hypotheses requiring clinical paediatric material	161
4.5.4	Methods	162
<b>4.6</b>	<b>Comparisons between Hospital locations</b>	<b>163</b>
4.6.1	Wakefield and Edinburgh	163

4.6.2	Rural and urban areas	164
<b>CHAPTER 5: Materials and Methods 2: Archaeological</b>		<b>165</b>
<b>5.1</b>	<b>Materials</b>	<b>165</b>
5.1.1	Introduction	165
5.1.2	Captain's Cabin, Castle Park, Dunbar, East Lothian	171
5.1.3	The Hirsell, Coldstream, Berwickshire	176
5.1.4	Whithorn Priory, Whithorn, Galloway	180
5.1.5	St. Andrew, Fishergate, York	185
5.1.6	Tanners Row, Pontefract, West Yorkshire	189
<b>5.2</b>	<b>Methods</b>	<b>193</b>
5.2.1	Adapting clinical methods to archaeological coring	193
5.2.2	Macroscopic recording	194
(i)	Age and sex determination	194
(ii)	Recording of vertebrae: vertebrae present and Schmorl's nodes	196
(iii)	Recording of diseases and disorders	199
(a)	Recognition of diseases and disorders of the spine in archaeological materials	200
(iv)	Relevant information	205
(v)	Diagrammatic recording	206
5.2.3	Radiographic imaging	206
<b>5.3</b>	<b>Analysis of data</b>	<b>209</b>
<b>CHAPTER 6: Results: clinical and archaeological</b>		<b>215</b>
<b>6.1</b>	<b>Introduction</b>	<b>215</b>
6.1.1	Schmorl's nodes (clinical and archaeological)	216
6.1.2	Superior and inferior vertebral end plate frequency of Schmorl's nodes	218
<b>6.2</b>	<b>Vertebral end plate weakness frequency: subadult</b>	<b>219</b>
6.2.1	Clinical data	219

(i)	Pinderfields Hospital	219
(ii)	Royal Hospital for Sick Children	220
6.2.2	Archaeological samples	221
<b>6.3</b>	<b>Schmorl's nodes: symptomatic or asymptomatic?</b>	<b>223</b>
6.3.1	Clinical data	223
(i)	Pinderfields Hospital	223
(ii)	Royal Hospital for Sick Children	224
6.3.3	Archaeological samples	228
(i)	Captain's Cabin, Dunbar	228
(ii)	The Hirsell, Coldstream	229
(iii)	Whithorn Priory, Galloway	230
(iv)	St. Andrews, Fishergate, York	232
(v)	Tanners Row, Pontefract	234
<b>6.4</b>	<b>Schmorl's nodes and their relationship to age</b>	<b>234</b>
6.4.1	Clinical and archaeological data	234
(i)	Pinderfields Hospital 1994-5 and the Royal Hospital for Sick Children I	234
(ii)	Pinderfields Hospital 1995 and the Royal Hospital for Sick Children II	236
6.4.2	Archaeological data	236
(i)	Captain's Cabin	236
(ii)	The Hirsell	237
(iii)	Whithorn Priory	237
(iv)	Fishergate	238
(v)	Tanners Row	238
6.4.3	Comparisons of Schmorl's nodes for defined age ranges: clinical and archaeological	238
(i)	Prenatal to ten years of age	238
(ii)	Eleven to twenty years of age	239
(a)	Clinical data	239
(b)	Archaeological data	240
(iii)	Twenty-one to twenty-five years of age	241

(a)	Clinical data	241
(b)	Archaeological data	242
(iv)	Twenty-six to thirty-five years of age	242
(a)	Clinical data	242
(b)	Archaeological data	243
(v)	Thirty-six to forty-five years of age	244
(a)	Clinical data	244
(b)	Archaeological data	244
(vi)	Over forty-five years of age	245
(a)	Clinical data	245
(b)	Archaeological data	246
<b>6.5</b>	<b>Altered dynamics of the vertebral column</b>	<b>247</b>
6.5.1	Clinical data	247
(i)	Pinderfields Hospital	247
(ii)	Royal Hospital for Sick Children	249
6.5.2	Archaeological data	250
(i)	Captain's Cabin	250
(ii)	The Hirsell	250
(iii)	Whithorn Priory	251
(iv)	Fishergate	251
<b>6.6</b>	<b>Schmorl's nodes and their relationship to sex</b>	<b>252</b>
6.6.1	Clinical data	252
6.6.2	Archaeological sample	254
(i)	Captain's Cabin	254
(ii)	The Hirsell	254
(iii)	Whithorn Priory	255
(iv)	St. Andrew, Fishergate	255
(v)	Tanners Row	256
<b>6.7</b>	<b>The origins of Schmorl's nodes (Clinical data)</b>	<b>257</b>
6.7.1	Schmorl's nodes: subadults	257

6.7.2	Schmorl's nodes: adults	258
6.8	Schmorl's nodes and their association with irregularities of the pelvis and lower limbs (clinical data)	261
<b>CHAPTER 7: Discussion</b>		266
7.1	Schmorl's nodes frequency	267
(i)	Clinical samples	268
(ii)	Archaeological sample	269
7.2	Vertebral end plate weakness and the formation of Schmorl's nodes: subadult	274
7.2.1	Subadult end plate weakness: Clinical sample	276
7.2.2	Subadult end plate weakness: archaeological samples	276
7.2.3	Irregular vertebral end plates	277
7.2.4	Beneath the end plates: immature clinical samples	279
7.3	Are Schmorl's nodes: symptomatic or asymptomatic?	284
7.4	Schmorl's nodes and their relationship to age	287
7.4.1	The first two decades	287
(i)	Clinical subadults	287
(ii)	Archaeological samples	288
7.4.2	Individuals from 21 to 25 years of age	288
(i)	Clinical data	289
(ii)	Archaeological data	290
7.4.3	Individuals from 26 to 35 years of age	291
(i)	Clinical data	291
(ii)	Archaeological data	291
(a)	Captain's Cabin, Dunbar	291
(b)	The Hirsell, Coldstream	294
(c)	Whithorn Priory, Galloway	295
(d)	St. Andrew, Fishergate	295
(e)	Tanners Row, Pontefract	296

7.4.4	Individuals from 36 to 45 years of age	297
(i)	Clinical data	297
(ii)	Archaeological samples	298
(a)	Captain's Cabin, Dunbar	298
(b)	The Hirsell, Coldstream	298
(c)	Whithorn Priory, Galloway	299
(d)	St. Andrew, Fishergate	299
(e)	Tanners Row, Pontefract	300
7.4.5	Individuals over 45 years of age	300
(i)	Clinical data	300
(ii)	Archaeological data	301
(a)	Captain's Cabin, Dunbar	301
(b)	The Hirsell, Coldstream	302
(c)	Whithorn Priory, Coldstream	302
(d)	St. Andrew, Fishergate	303
(e)	Tanners Row, Pontefract	304
<b>7.5</b>	<b>Altered dynamics of the vertebral column</b>	<b>304</b>
7.5.1	Clinical data	305
(i)	Pinderfields Hospital samples	305
(ii)	Royal Hospital for Sick Children	306
7.5.2	Archaeological data	307
<b>7.6</b>	<b>Schmorl's nodes and their relationship to sex</b>	<b>308</b>
(i)	Clinical data	309
(ii)	Archaeological data	310
(a)	Captain's Cabin, Dunbar	310
(b)	The Hirsell, Coldstream	312
(c)	Whithorn Priory, Galloway	313
(d)	St. Andrew, Fishergate	314
(e)	Tanners Row, Pontefract	315
<b>7.7</b>	<b>The origins of Schmorl's nodes</b>	<b>315</b>

7.7.1	End plate disruption by Schmorl's nodes	316
7.7.2	Superior and inferior end plate incidences for Schmorl's nodes	316
(i)	Tunnelling Schmorl's nodes	318
(ii)	Rough Schmorl's nodes	319
(iii)	Smooth Schmorl's nodes	321
<b>7.8</b>	<b>Schmorl's nodes and their association with irregularities of the pelvis and lower limbs</b>	<b>321</b>
7.8.1	Clinical irregularities of the pelvis and lower limbs	322
<b>7.9</b>	<b>Summary of the results</b>	<b>324</b>

## **CHAPTER 8: Conclusions** 326

### **8.1** A summary of the hypotheses and findings 326

#### 8.1.1 Comparison of pooled clinical data and pooled archaeological data 329

##### 8.1.1.1 Vertebral end plates affected by Schmorl's nodes 329

##### 8.1.1.2 Almost all Schmorl's nodes occur within the first two decades of life 330

##### 8.1.1.3 The distribution of Schmorl's nodes remains constant through time

for males and females of similar age at death, in different

archaeologically derived populations and clinical groups of

corresponding ages 330

### **8.2** Limitations to the research 331

### **8.3** The advantages of a clinical and archaeological study 334

### **8.4** Possible directions for future vertebral column studies 335

## **BIBLIOGRAPHY** 338

## **LIST OF FIGURES**

### 1.1 Schmorl's node on the inferior end plate of a lumbar vertebra 32

1.2	Motor segment at rest (without uneven compression or movement) and with uneven lateral pressure causing the fractured fragment of the end plate to raise rupturing the nucleus Pulposus	33
1.3	Roentgenogram (paper image) showing Schmorl's vertical plates and end plates of a nine year old child	50
1.4a	Twenty three year old spine	51
1.4b	Six year old spine	51
1.5	Anterior superior sequestration with necrosis	52
1.6	A sagittal section of intervertebral disc showing possible directions taken by extruded material from the nucleus pulposus	56
2.1	Sagittal view of the vertebral column showing the primary and secondary curves, and the number of vertebrae in each curve	66
2.2	The range of movements within the vertebral column	67
2.3	The three primordial growth layers	70
2.4	Somite formation has begun	71
2.5	Somite formation showing the position of nerves and vessels	72
2.6	Eight month old foetus showing vertebral bodies and unfused elements	73
2.7	Lateral neonatal spine radiograph showing equal height of discs and vertebrae	74
2.8	Radiograph of a three-month-old baby showing posterior spinal processes prior to union	76
2.9	Constituent parts of a 1-2 year old vertebra	76
2.10	Anatomically correct position of the peg of the axis and the interior anterior ring of atlas	78
2.11	Superior view of the atlas	79
2.12	Anterior view of the axis	79
2.13	Lateral thoracic vertebra	81
2.14	Lateral lumbar vertebra	83
2.15	Adult pelvis	84
2.16	Lateral view of sacrum and coccyx	85

2.17	Primary embryonic curve	86
2.18	Intervertebral disc articulating with vertebrae	88
2.19	Intervertebral disc showing alternating layers of the annulus fibrosus	90
2.20	Erector spinae showing tendons and fascicle divisions	95
2.21	Psoas major (PM) and quadratus lumborum (QL) showing their points of attachment to the vertebral column. The PM attaching antero-laterally to the vertebral margins, transverse processes and intervertebral discs. The QL attaching to the twelfth rib (D), iliac crest (A), transverse processes (C) and iliolumbar ligament (B)	98
2.22	Sagittal section of the lumbar spine showing the ligaments	100
2.23	A posterior section of the vertebral column showing the nerve roots of the autonomic and motor nerves emanating from the intervertebral foraminae	105
2.24	Lumbar vertebra showing the arterial drainage of the spine	107
2.25	Sagittal section of the venous system of the vertebral column	108
3.1	Osteoarthritic cervical vertebra	111
3.2	Vertebrae showing osteophytosis and wedging	113
3.3	Subchondral bone cysts in a femoral head	114
3.4	Diffuse idiopathic skeletal hyperostosis	117
3.5	Vertebral collapse from underlying trabecular destruction	119
3.6	Typical surface markings in vertebral collapse	119
3.7	Paediatric spine with active juvenile osteochondritis with sclerosis and anterior Schmorl's nodes with cortical regeneration	123
3.8	Lateral lumbar spine showing sclerosis, irregular end plates, and retracted anterior end plates	124
3.9	Lateral lumbar spine showing loss of lordosis and active Schmorl's nodes with sclerotic margins	126
3.10	Lateral cervical spine showing retrolisthesis	127
3.11	Scoliosis with spinal rotation	128
3.12	Bifid centrum	129

3.13	Bi-lateral talipes equinovarus	131
3.14	Irregular end plates with sclerosis and Schmorl's nodes	133
3.15	Spondylolysis of the fifth lumbar vertebra at the left pars interarticularis	134
3.16	Classification of spondylolisthesis	136
3.17	Spina bifida occulta	137
3.18	Spina bifida cystica	138
3.19a	Scoliosis due to asymmetry of leg length	140
3.19b	Resolved scoliosis by placing 6 mm block under the foot of the shorter leg	140
4.6	Map showing location of Edinburgh (Royal Hospital for Sick Children) and Wakefield (Pinderfields and Clayton Hospitals)	152
5.1	Map showing the location of Captain's Cabin, Dunbar; the Hirsell, Coldstream; Whithorn Priory, Whithorn; Fishergate, York and Tanners Row, Pontefract	166
5.2	Map showing location of Captain's Cabin, Dunbar, East Lothian, Scotland	171
5.3	Captain's Cabin, Dunbar, burial plan for groups 1 and 2	172
5.4	Captain's Cabin, Dunbar, burial plan for groups 3 and 4	173
5.5	Map showing the location of the Hirsell, Coldstream, Berwickshire	177
5.6	The Hirsell cemetery, Coldstream	180
5.7	Map showing the location of Whithorn and the Isle of Whithorn, Galloway	181
5.8	Stage 5, phase one of the Whithorn burial groups	183
5.9	Map showing the location of the city of York	186
5.10	Cemetery plan of St. Andrew, Fishergate	188
5.11	Map showing location of Pontefract	189
5.12	Tanners Row Anglo-Saxon cemetery, with sub-adults shaded in blue	190
5.13	Example of a skeletal data collection grid	197
5.14	Example of the adapted skeletal materials collection grid	197
5.15	Schmorl's node causing posterior vertebral body fracturing	199

5.16	Thoracic vertebrae showing sclerosis and osteochondritis/spondylosis	201
5.17	Bi-lateral spondylolysis of the fifth lumbar vertebra	202
5.18	Example of a clinical disorder and disease collection grid	203
5.19	Example of a skeletal materials disorder and disease collection grid	203
5.20	Inferior end plate <i>rough</i> Schmorl's node (Whithorn Priory skeleton No. 539)	204
5.21	Smooth Schmorl's node (The Hirsel, skeleton No. 12)	205
5.22	An example of how the archaeological samples were radiographed	207
6.1	The viability of the archaeological samples: the percentages show the individuals with and without thoracic and lumbar vertebral columns	215
6.2	The percentages of individuals affected with at least one Schmorl's node for each clinical and archaeological sample	217
6.3	Numbers and percentages for superior, inferior and contiguous vertebral end plate intrusions by Schmorl's nodes	218
6.4	The Royal Hospital for Sick Children: disorders and diseases associated with individuals with Schmorl's nodes	225
6.5	Numbers and percentages for individuals with irregular end plates where Schmorl's nodes had been diagnosed in the clinical samples	226
6.6	The numbers and percentages of individuals with reduced intervertebral disc height where Schmorl's nodes have been diagnosed in the clinical samples	227
6.7	Age ranges in which Schmorl's nodes were first reported within the 1994-5 Pinderfields Hospital and RHSC I sample and the 1995 Pinderfields Hospital and RHSC II sample	235
6.8	Numbers and percentages by age groups for all individuals found positive for Schmorl's nodes in the Captain's Cabin, Dunbar, the Hirsel, Coldstream, Whithorn Priory, Galloway and the Tanners Row, Pontefract samples	239

6.9	Diagram of thoracic vertebrae showing a healed subchondral Schmorl's node, a rough (active) Schmorl's node, and a re-herniation of a healed, subadult, subchondral Schmorl's node	260
7.1	Immature lumbar spine showing vertebral end plate avulsion, separation, sclerosis, irregular end plates, and Schmorl's nodes forming and formed beneath the vertebral end plates	281
7.2	A Shetland crofter from the Lerwick Parish, knitting as she carries home her Kishie full of peats. Note the woman's posture as she walks from the Shetland Museum Picture Archive, photographer: Wilson, G. W. (1885)]	293
7.3	Late stage septic arthritis with complete destruction of the left femoral epiphysis (McCarthy <i>et al</i> , 2004).	323

## LIST OF TABLES

5.1	Gives the number of skeletons excavated at the Captain's cabin site, and the number of skeletons studied	175
5.2	The number of sub-adult vertebral columns studied from the Captain's Cabin sample by age group	175
5.3	The number of adult vertebral columns studied from the Captain's Cabin sample by age group	175
5.4	Gives the number of skeletons excavated at the Hirsell site, and the number of skeletons studied	178
5.5	The number of sub-adult vertebral columns studied from the Hirsell sample by age group	179
5.6	The number of adult vertebral columns studied from the Hirsell sample by age group	179
5.7	The number of subadult vertebral columns studied from the Whithorn sample by age group	183
5.8	The number of adult vertebral columns studied from the Whithorn sample by age group	184

5.9	Gives the number of skeletons excavated from the Fishergate site, and the number of skeletons studied	187
5.10	The number of subadult vertebral columns studied from the Fishergate sample by age group	187
5.11	The number of adult vertebral columns studied from the Fishergate sample by age group	187
5.12	The number of skeletons excavated from the Tanners Row site, and the number of skeletons studied	191
5.13	The number of sub-adult vertebral columns studied from the Tanners Row sample	192
5.14	The number of adult vertebral columns studied from the Tanners Row sample	192
5.15	The Medieval archaeological cemetery populations, their Ordnance Survey positions, the centuries they encompass, and the types of settlement	193
<b>Appendix 1: Permissions given to allow clinical research to be undertaken</b>		374
	<i>Dr. I. G. Burnside, Consultant Clinical Psychologist</i>	374
	<i>Jonathan Siddall, Radiology Services Manager</i>	375
	<i>Jane Shewan, Head of Research and Effectiveness</i>	376
	<i>Alison Scott, Lecturer, Queen Margaret University, Edinburgh</i>	377
<b>Appendix 2: Data sheets for clinical and archaeological recording</b>		378
	The x-ray request card used to gather patient data for all clinical patients used in this research	378
	The data collection sheet for the recording of all clinical and archaeological vertebrae and the positions of Schmorl's nodes	379
	The data collection sheet for the recording of all disorders and	

diseases for the clinical and archaeological samples	380
The data collection sheet for all other information which might be of relevance when analysing the results from each of the clinical and archaeological samples	381
5.21 Diagrammatic collection sheet for macroscopic data	382
5.22 Diagrammatic collection sheet for macroscopic data	382

**Appendix 3:** Tables showing percentages and numbers of individuals within samples

6.1 The number of vertebral columns studied in each clinical sample, and the number and percentages found positive for Schmorl's nodes	383
6.2 Numbers and percentages for Schmorl's nodes using the complete vertebral columns within each archaeological sample as the complete sample	383
6.3 The frequency of vertebral end plate intrusions associated with Schmorl's nodes for superior, inferior and contiguous end plates	384
6.4 The number of complete vertebral columns in each age group examined for possible notochord weakness (weakened area within the vertebral end plates)	384
6.5 The viability of the subadult archaeological materials studied for possible vertebral end plate weakness caused by incomplete notochord regression	385
6.6 Numbers and percentages of subadults found to have centrally placed Schmorl's nodes which might be indicative of vertebral end plate weakness caused by incomplete notochord regression	385
6.7 Numbers and percentages of individuals with Schmorl's nodes by age for the 1994-5 Pinderfields Hospital and RHSC I sample	386
6.8 Numbers and percentages of individuals with Schmorl's nodes by age for the 1995 Pinderfields Hospital and RHSC II samples	386
6.9 Numbers and percentages for individuals with Schmorl's nodes	

	at death for all the archaeological samples	386
6.10	Numbers and percentages of the three most prevalent disorders found in each of the clinical samples where Schmorl's nodes were present	387
6.11	Numbers and percentages of the three most prevalent disorders found in each of the archaeological samples where no Schmorl's nodes were observed	387
6.12	Scoliotic shift in relation to the affected lower limb in subadults with Schmorl's nodes and other associated disorders and diseases (RHSC)	388
6.13a	Male, female and subadult numbers and percentages of disorders and diseases for the individuals found positive for Schmorl's nodes in the 1994-5 Pinderfields Hospital sample, the 1995 Pinderfields Hospital sample, the RHSC sample, the Captain's Cabin, Dunbar sample and the Hirsell, Coldstream sample. Blank = no evidence of disorder in that population group or, no subadults present affected by Schmorl's nodes	389
6.13b	Male, female and subadult numbers and percentages of disorders and diseases for the individuals found positive for Schmorl's nodes the Whithorn Priory, Galloway sample, the St. Andrew, Fishergate sample and the Tanners Row sample. Blank = no evidence of disorder in that population group or, no subadults present affected by Schmorl's nodes	390
<b>Appendix 4:</b> Figures showing male, female, subadult and unsexed distributions of Schmorl's nodes		391
6.10	Numbers, percentages and levels of Schmorl's nodes for males, females and subadults in the 1994-5 Pinderfields Hospital sample	391
6.11	Numbers, percentages and levels of Schmorl's nodes for males, females and subadults in the 1995 Pinderfields Hospital sample	391

6.12	Numbers, percentages and levels of Schmorl's nodes for subadult males, and females in the RHSC sample	392
6.13	Numbers, percentages and levels of Schmorl's nodes for males and females in the Captain's Cabin, Dunbar sample	392
6.14	Numbers, percentages and levels of Schmorl's nodes for males and females in the Hirsal, Coldstream sample	3393
6.15	Numbers, percentages and levels of Schmorl's nodes for males, females subadults and unsexed adults in the Whithorn Priory, Galloway sample	393
6.16	Numbers, percentages and levels of Schmorl's nodes for males, females and unsexed adults in the St. Andrew, Fishergate sample	394
6.17	Numbers, percentages and levels of Schmorl's nodes for males and females and in the Tanners Row, Pontefract sample	394

**Appendix 5:** Figures showing superior and inferior Schmorl's nodes in clinical and archaeological samples of different age groups 395

6.18	Numbers, percentages and levels of vertebral end plate intrusions for Schmorl's nodes at different levels in the 1994-5 Pinderfields Hospital sample aged 11 to 20	395
6.19	Numbers, percentages and levels of vertebral end plate intrusions for Schmorl's nodes at different levels in the 1994-5 Pinderfields Hospital sample aged 21 to 25	395
6.20	Numbers, percentages and levels of vertebral end plate intrusions for Schmorl's nodes at different levels in the 1994-5 Pinderfields Hospital sample aged 26 to 35	396
6.21	Numbers, percentages and levels of vertebral end plate intrusions for Schmorl's nodes at different levels in the 1994-5 Pinderfields Hospital sample aged 36 to 45	396
6.22	Numbers, percentages and levels of vertebral end plate intrusions for Schmorl's nodes at different levels in the 1994-5 Pinderfields	

	Hospital sample aged >45	397
6.23	Numbers, percentages and levels of vertebral end plate intrusions for Schmorl's nodes at different levels in the 1995 Pinderfields Hospital sample aged 11 to 20	397
6.24	Numbers, percentages and levels of vertebral end plate intrusions for Schmorl's nodes at different levels in the 1995 Pinderfields Hospital sample aged 21 to 25	398
6.25	Numbers, percentages and levels of vertebral end plate intrusions for Schmorl's nodes at different levels in the 1995 Pinderfields Hospital sample aged 26 to 35	398
6.26	Numbers, percentages and levels of vertebral end plate intrusions for Schmorl's nodes at different levels in the 1995 Pinderfields Hospital sample aged 36 to 45	399
6.27	Numbers, percentages and levels of vertebral end plate intrusions for Schmorl's nodes at different levels in the 1995 Pinderfields Hospital sample aged >45	399
6.28	Numbers, percentages and levels of vertebral end plate intrusions for Schmorl's nodes at different levels in the RHSC sample aged 6 to 10	400
6.29	Numbers, percentages and levels of vertebral end plate intrusions for Schmorl's nodes at different levels in the RHSC sample aged 11 to 16	400
6.30	Numbers, percentages and levels of vertebral end plate intrusions for Schmorl's nodes at different levels in the Captain's Cabin, Dunbar sample aged 26 to 35	401
6.31	Numbers, percentages and levels of vertebral end plate intrusions for Schmorl's nodes at different levels in the Captain's Cabin, Dunbar sample aged 36 to 45	401
6.32	Numbers, percentages and levels of vertebral end plate intrusions for Schmorl's nodes at different levels in the Captain's Cabin, Dunbar sample aged >45	402
6.33	Numbers, percentages and levels of vertebral end plate intrusions for	

	Schmorl's nodes at different levels in the Hirsal, Coldstream sample aged 26 to 35	402
6.34	Numbers, percentages and levels of vertebral end plate intrusions for Schmorl's nodes at different levels in the Hirsal, Coldstream sample aged 36 to 45	403
6.35	Numbers, percentages and levels of vertebral end plate intrusions for Schmorl's nodes at different levels in the Hirsal, Coldstream sample aged >45	403
6.36	Numbers, percentages and levels of vertebral end plate intrusions for Schmorl's nodes at different levels in the Whithorn Priory sample aged 11 to 20	404
6.37	Numbers, percentages and levels of vertebral end plate intrusions for Schmorl's nodes at different levels in the Whithorn Priory sample aged 26 to 35	404
6.38	Numbers, percentages and levels of vertebral end plate intrusions for Schmorl's nodes at different levels in the Whithorn Priory sample aged 36 to 45	405
6.39	Numbers, percentages and levels of vertebral end plate intrusions for Schmorl's nodes at different levels in the Whithorn Priory sample aged >45	405
6.40	Numbers, percentages and levels of vertebral end plate intrusions for Schmorl's nodes at different levels in the St. Andrew, Fishergate sample aged 26 to 35	406
6.41	Numbers, percentages and levels of vertebral end plate intrusions for Schmorl's nodes at different levels in the St. Andrew, Fishergate sample aged 36 to 45	406
6.42	Numbers, percentages and levels of vertebral end plate intrusions for Schmorl's nodes at different levels in the St. Andrew, Fishergate sample aged >45	407
6.43	Numbers, percentages and levels of vertebral end plate intrusions for	

	Schmorl's nodes at different levels in the Tanners Row, Pontefract sample aged 26 to 35	407
6.44	Numbers, percentages and levels of vertebral end plate intrusions for Schmorl's nodes at different levels in the Tanners Row, Pontefract sample aged >45	408
	<b>Appendix 6:</b> Demographic data, for both clinical and archaeological samples	409
6.14a	Male data for Schmorl's nodes in the 1994-5 Pinderfields Hospital sample showing the levels and surfaces affected: superior (S) being the superior end plate of the vertebral body and inferior (I) being the inferior end plate of the vertebral body	409
6.14b	Female data for Schmorl's nodes in the 1994-5 Pinderfields Hospital sample showing the levels and surfaces affected: superior (S) being the superior end plate of the vertebral body and inferior (I) being the inferior end plate of the vertebral body	410
6.15	Male and female data for Schmorl's nodes in the 1995 Pinderfields Hospital sample showing the levels and surfaces affected: superior (S) being the superior end plate of the vertebral body and inferior (I) being the inferior end plate of the vertebral body	411
6.16	Male and female data for Schmorl's nodes in the RHSC sample showing the levels and surfaces affected: superior (S) being the superior end plate of the vertebral body and inferior (I) being the inferior end plate of the vertebral body	412
6.17	Data for Schmorl's nodes in the Captain's Cabin, Dunbar sample showing the levels and surfaces affected: superior (S) being the superior end plate of the vertebral body and inferior (I) being the inferior end plate of the vertebral body. Vertebra present (P), vertebra absent (A), and vertebra present and fractured (P#)	413
6.18a	Data for Schmorl's nodes in the Hirsell, Coldstream sample showing the levels and surfaces affected, superior (S) being the	

- superior end plate of the vertebral body and inferior (I) being the inferior end plate of the vertebral body. Vertebra present (P), vertebra absent (A), vertebra present and fractured (P#), and spina bifida occulta (SBO) 414
- 6.18b Data for Schmorl's nodes in the Hirsell, Coldstream sample showing the levels and surfaces affected: superior (S) being the superior end plate of the vertebral body and inferior (I) being the inferior end plate of the vertebral body. Vertebra present (P), vertebra absent (A), vertebra present and fractured (P#), and spina bifida occulta (SBO) 415
- 6.19 Data for Schmorl's nodes in the Whithorn Priory, Galloway sample showing the levels and surfaces affected: superior (S) being the superior end plate of the vertebral body and inferior (I) being the inferior end plate of the vertebral body. Vertebra present (P), vertebra absent (A), and vertebra present and fractured (P#) 416
- 6.20a Data for Schmorl's nodes in the St. Andrew, Fishergate sample showing the levels and surfaces affected: superior (S) being the superior end plate of the vertebral body and inferior (I) being the inferior end plate of the vertebral body. Vertebra present (P), vertebra absent (A), and vertebra present and fractured (P#) 417
- 6.20b Data for Schmorl's nodes in the St. Andrew, Fishergate sample showing the levels and surfaces affected: superior (S) being the superior end plate of the vertebral body and inferior (I) being the inferior end plate of the vertebral body. Vertebra present (P), vertebra absent (A), and vertebra present and fractured (P) 418
- 6.20c Data for Schmorl's nodes in the St. Andrew, Fishergate sample showing the levels and surfaces affected: superior (S) being the superior end plate of the vertebral body and inferior (I) being the inferior end plate of the vertebral body. Vertebra present (P), vertebra absent (A), and vertebra present and fractured (P#) 419

- 6.20d Data for Schmorl's nodes in the St. Andrew, Fishergate sample showing the levels and surfaces affected: superior (S) being the superior end plate of the vertebral body and inferior (I) being the inferior end plate of the vertebral body. Vertebra present (P), vertebra absent (A), and vertebra present and fractured (P#) 420
- 6.20e Data for Schmorl's nodes in the St. Andrew, Fishergate sample showing the levels and surfaces affected: superior (S) being the superior end plate of the vertebral body and inferior (I) being the inferior end plate of the vertebral body. Vertebra present (P), vertebra absent (A), vertebra present and fractured (P#), and spina bifida occulta (SBO) 421
- 6.21 Data for Schmorl's nodes in the Tanners Row, Pontefract sample showing the levels and surfaces affected: superior (S) being the superior end plate of the vertebral body and inferior (I) being the inferior end plate of the vertebral body. Vertebra present (P), vertebra absent (A), and vertebra present and fractured (P#) 422
- Appendix 7: associated disorders and diseases (clinical and archaeological) 423**
- 6.22a Disorders and diseases associated with Schmorl's nodes occurrences for the males of the 1994-5 Pinderfields Hospital sample. Schmorl's nodes were recorded by type and position; types were recorded as rough (R) or smooth (S), and positions were recorded as anterior (A), central (C), or posterior (P). 423
- 6.22b Disorders and diseases associated with Schmorl's nodes occurrences for the females of the 1994-5 Pinderfields Hospital sample. Schmorl's nodes were recorded by type and position; types were recorded as rough (R) or smooth (S), and positions were recorded as anterior (A), central (C), or posterior (P). 424
- 6.23 Disorders and diseases associated with Schmorl's nodes occurrences

- for the males and females of the 1995 Pinderfields Hospital sample.  
Schmorl's nodes were recorded by type and position; types were recorded as rough (R) or smooth (S), and positions were recorded as anterior (A), central (C), or posterior (P). 425
- 6.24 Disorders and diseases associated with Schmorl's nodes occurrences for the males and females of the RHSC sample. Schmorl's nodes were recorded by type and position; types were recorded as rough (R) or smooth (S), and positions were recorded as anterior (A), central (C), or posterior (P). 426
- 6.25 Disorders and diseases associated with Schmorl's nodes occurrences for the individuals of the Captain's Cabin sample. Schmorl's nodes were recorded by type and position; types were recorded as rough (R), smooth (S), grape (G), or tunnelling (T), and positions were recorded as anterior (A), central (C), or posterior (P). 427
- 6.26a Disorders and diseases associated with Schmorl's nodes occurrences for the individuals of the Hirsell, Coldstream sample. Schmorl's nodes were recorded by type and position; types were recorded as rough (R) or smooth (S), and positions were recorded as anterior (A), central (C), or posterior (P). 428
- 6.26b Disorders and diseases associated with Schmorl's nodes occurrences for the individuals of the Hirsell, Coldstream sample. Schmorl's nodes were recorded by type and position; types were recorded as rough (R) or smooth (S), and positions were recorded as anterior (A), central (C), or posterior (P). 429
- 6.27 Disorders and diseases associated with Schmorl's nodes occurrences for the individuals of the Whithorn, Galloway sample. Schmorl's nodes were recorded by type and position; types were recorded as rough (R) or smooth (S), and positions were recorded as anterior (A), central (C), or posterior (P). 430
- 6.28a Disorders and diseases associated with Schmorl's nodes occurrences

- for the males of the St. Andrew, Fishergate sample. Schmorl's nodes were recorded by type and position; types were recorded as rough (R) or smooth (S), and positions were recorded as anterior (A), or posterior (P). 431
- 6.28b Disorders and diseases associated with Schmorl's nodes occurrences for the males of the St. Andrew, Fishergate sample. Schmorl's nodes were recorded by type and position; types were recorded as rough (R), smooth (S), or tunnelling (T), and positions were recorded as anterior (A), central (C), or posterior (P). 432
- 6.28c Disorders and diseases associated with Schmorl's nodes occurrences for the males of the St. Andrew, Fishergate sample. Schmorl's nodes were recorded by type and position; types were recorded as rough (R), smooth (S), or tunnelling (T), and positions were recorded as anterior (A), central (C), or posterior (P). 433
- 6.28d Disorders and diseases associated with Schmorl's nodes occurrences for the males of the St. Andrew, Fishergate sample. Schmorl's nodes were recorded by type and position; types were recorded as rough (R), smooth (S), or tunnelling (T), and positions were recorded as anterior (A), central (C), or posterior (P). 434
- 6.28e Disorders and diseases associated with Schmorl's nodes occurrences for the males of the St. Andrew, Fishergate sample. Schmorl's nodes were recorded by type and position; types were recorded as rough (R), or smooth (S), and positions were recorded as central (C), or posterior (P). 435
- 6.29 Disorders and diseases associated with Schmorl's nodes occurrences for the males of the Tanners Row, Pontefract sample. Schmorl's nodes were recorded by type and position; types were recorded as rough (R), smooth (S), or grape (G), and positions were recorded as, central (C), or posterior (P). 436

<b>Appendix 8: Other relevant information</b>	<b>437</b>
6.30a Other relevant information for the males of the 1994-5 Pinderfields Hospital sample	437
6.30b Other relevant information for the females of the 1994-5 Pinderfields Hospital sample	438
6.31 Other relevant information for the individuals of the 1995 Pinderfields Hospital sample	439
6.32 Other relevant information for the individuals of the RHSC sample	440
6.33 Other relevant information for the individuals of the Captain's Cabin, Dunbar Sample	441
6.34a Other relevant information for the individuals of the Hirsell, Coldstream sample	442
6.34b Other relevant information for the individuals of the Hirsell, Coldstream sample	443
6.35 Other relevant information for the individuals of the Whithorn Priory sample	444
6.36a Other relevant information for the individuals of the St Andrew, Fishergate sample	445
6.36b Other relevant information for the individuals of the St Andrew, Fishergate sample	446
6.36c Other relevant information for the individuals of the St Andrew, Fishergate sample	447
6.36d Other relevant information for the individuals of the St Andrew, Fishergate sample	448
6.36e Other relevant information for the individuals of the St Andrew, Fishergate sample	449
6.37 Other relevant information for the individuals of the Tanners Row, Pontefract sample	450

## CHAPTER 1: Introduction

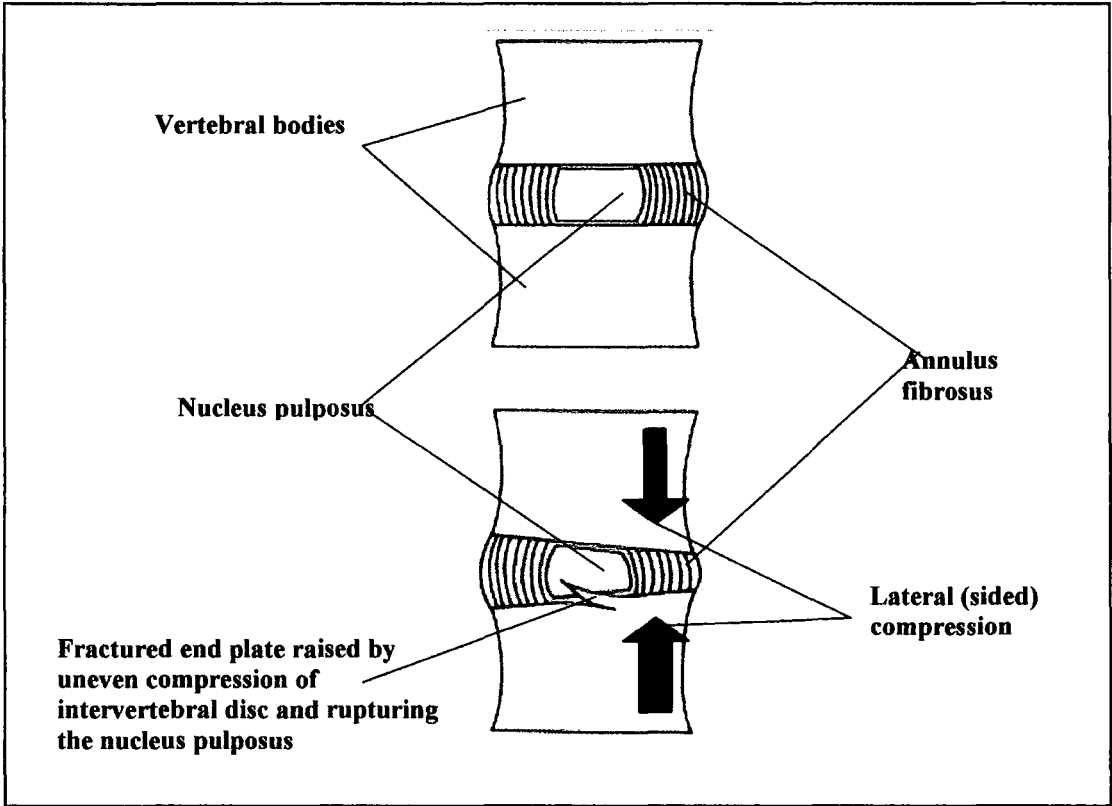
### 1.1 What are Schmorl's nodes?



**Figure 1.1 Schmorl's node on the inferior end plate of a lumbar vertebra (Hirsal skeleton No. 337)**

Schmorl's nodes (Fig. 1.1) are lesions of the vertebral bodies caused by the invasion of the nucleus pulposus of the intervertebral discs through the vertebral end plates of the bodies of the vertebrae (Renfrew, 2003: 237). Furthermore, when posterior intrusion of the vertebral end plate occurs, bone can be fractured and displaced posteriorly into the neural canal, causing damage to the spinal cord at the level of the intrusion (Schmorl and Junghanns, 1971: 180). First named and brought to the attention of the medical world in Stuttgart in 1927 by Christian Georg Schmorl, the aetiology of Schmorl's nodes still remains uncertain. The rupturing of the nucleus pulposus within the annulus fibrosus is understood to be caused by several different types of compression. The first consists of falling from a height and landing either on the feet or on the base of the spine, causing sudden massive compression of the intervertebral discs, followed by lessening repercussive compressions (Wagner *et al.*, 2000). The initial compression ruptures the nucleus pulposus and further compressions force the nucleus pulposus to

fracture weakened end plates and destroy trabecular structures immediately below the end plates (Schmorl and Junghanns, 1971: 4). Torsion and compression placed simultaneously on the vertebral column, with or without added weight, can also cause traumatic rupturing of the nucleus pulposus and Schmorl's nodes. Repetitive unequal compression of the vertebral column (Fig. 1.2), as observed in field athletics and gymnastic disciplines, may also cause rupture of the nucleus pulposus, and Schmorl's nodes (Walters *et al.*, 1991).



**Figure 1.2 Motor segment at rest (without compression or movement); and with uneven lateral pressure the fractured fragment raises the end plate and ruptures the nucleus pulposus (by R. B. McNaught, 2005)**

Schmorl's nodes are known to form where disease causes a disruption to the end plates, underlying trabeculae, and the vascular plexus (Jarvik and Deyo, 2002). Subchondral bone loss immediately below the end plate caused by osteolysis caused by, for example,

metastases, multiple myeloma, osteoporosis or osteomyelitis, leads to thinning of the cortical bone, resulting in fracturing of the end plates (Kakitsubata *et al.*, 2002). It is as if the nucleus pulposus feels required to fill the space provided by the disruption to the vertebral body; the possible reason is unnatural sharp pressure upon the nucleus pulposus by the sharp fractured edges of the disrupted vertebral end plate (Fig. 1.2) during repeated compressions (Wagner *et al.*, 2000; Vinson and Major, 2003). Rupturing of the annulus fibrosus of the nucleus pulposus then allows the contents to redistribute within the damaged area of the spongiosa (McInerney *et al.*, 2000).

## 1.2 Hypotheses, aims and objectives

This study aims to test several hypotheses about Schmorl's nodes using both clinical data, and archaeologically derived skeletal remains. The ultimate objective is to try to clarify some of Schmorl's findings, and to eliminate others, in an attempt to come closer to defining an aetiology for Schmorl's nodes.

Schmorl's nodes are deliberately named after a person, and a node is a nodule or soft tissue swelling or growth (Steadman, 2000). In dissection, the term "node" is correct as the visualised material of the ruptured nucleus pulposus forms a hernia within the cancellous bone of the vertebral body. However, it should be noted that to use "node" as a descriptive term in osteoarchaeology when only the imprint of the herniated pulposus remains may be incorrect, as the vertebral body contains only the imprint or negative image left by the soft tissue infiltration of the ruptured nucleus pulposus.

The following hypotheses will be tested:

1. The point of regression of the notochord is the weakest point within the end plate of the vertebra, making it the most likely point of herniation of the nucleus pulposus,

and the formation of Schmorl's nodes.

This first hypothesis (does a weak spot exist within the end plates of the vertebral bodies and centra left by the notochord) needs to be assessed as it is regularly given as a reason for intrusion of the extruded nucleus pulposus through the vertebral end plates into the subchondral bone of the vertebral bodies. Prescher (1998: 187) states that "In most cases Schmorl's nodes are established in the centre of the vertebral body, since in that region the cartilage end plate is thin because of the earlier passage of the chorda dorsalis". This statement, regularly used as an introduction to research concerning Schmorl's nodes (Begg 1954; Chandraraj *et al.*, 1998), is historically accepted as medically proven<sup>8</sup> but may have no foundation in fact. If this hypothesis is disproved then the fundamental belief that the notochord's regression is the primary cause of Schmorl's nodes must be treated with extreme caution, or discarded. Furthermore<sup>9</sup> we will better appreciate what really caused Schmorl's nodes in our ancestors.

## 2. Schmorl's nodes: symptomatic or asymptomatic?

The proof of presence or absence of pain in association with Schmorl's nodes may help us to understand the impact of Schmorl's nodes upon the vertebral column, and the reasons why doctors never request radiographic imaging for back pain citing Schmorl's nodes as a possible cause. It may also help us understand the impact of Schmorl's nodes on the lives of past people. Clinical opinions vary as to the presence or absence of pain and, if present, its impact on a patient's life. Pain charts are a regular tool used to draw a pain map of the areas affected and the differing levels of that pain. If acute localised pain is found to be a direct reaction to the moment of intrusion of the nucleus pulposus through the end plate, and chronic pain a long term after effect, Schmorl's nodes would

be given proper recognition, rather than treated as an incidental finding to be noted and then ignored.

3. Almost all Schmorl's nodes occur within the first two decades of life.

If subadults do have a vertebral end plate weakness, it may not be a weakened area within the end plate but, in the areas of incomplete fusion at the anterior superior and inferior vertebral body margins. Disruption to the vertebral end plates and subchondral bone during the growth phase might be expected to leave some visible bony marker which can be seen macroscopically. The end plates do not fuse with the vertebral bodies until skeletal growth within the vertebral column is complete (Scheuer and Black, 2004), making the subadult spine structurally less robust than the adult vertebral spine when resisting disruption by the intervertebral disc. Macroscopic studies might show undulation with or without retraction along the anterior superior and/or inferior vertebral margin without any visible signs of Schmorl's nodes, making accurate recording almost impossible in the subadult spine.

4. Schmorl's nodes, when not central formed within the vertebral bodies, cause instability to the dynamics of the vertebral column.

Alterations to the normal shape of the vertebral body may be a result of Schmorl's nodes where their intrusion causes peripheral damage, for example the anterior Schmorl's nodes found in conjunction with kyphosis caused by Scheuermann's disease (Scheuermann, 1920). Conversely, kyphosis, scoliosis and asymmetry of the pelvis and lower limbs, may cause Schmorl's nodes (Steinberg *et al.*, 2003). Osteophyte formation and in both clinical and archaeological data will be recorded and any correlation

between their positions, the position of Schmorl's nodes (He and Xinghua, 2005), and any resulting alteration to the natural curves of the vertebral column.

5. Different work patterns cause Schmorl's nodes at varying levels in the thoracic and lumbar spine.

The aetiology of Schmorl's nodes is unknown (Peng *et al.*, 2003), but if repetitive work is a possible cause, different populations, both past and present may present varying patterns of Schmorl's nodes. For example, "apprentice spine" (Goldsmith, 2001) is a term coined to describe permanent deformity of the thoracic spine in children who worked in a bent position for long periods of time before child labour laws were introduced (Tann, 1981) this condition may have been associated with Schmorl's nodes. The archaeological skeletal samples chosen for this study are from varying geographical locations, with different settlements and work patterns. Alterations to the axial skeleton, caused by repetitive work, may show differing rates, and locations, for Schmorl's nodes, when the samples are compared. A consideration of clinical data may help us to understand what activities may lead to Schmorl's nodes in the past.

6. The distribution of Schmorl's nodes remains constant through time for males and females of similar age at death, in different archaeologically derived populations, and clinical groups of corresponding ages.

Frequency, a predominance of Schmorl's nodes in males, both clinical (Schmorl and Junghanns, 1927: 164; Hilton *et al.*, 1976; McFadden and Taylor, 1989), and archaeological (Jakob, 2004 and Saluja *et al.*, 1986) is seen. If work patterns are a factor in aetiology, then it may be assumed that where women are not just homemakers and

mothers, but fully integrated into a rural or industrial work force, the stresses and strains on their vertebral columns will replicate those of their male counterparts. In the 21<sup>st</sup> century women expect to be treated as equals, not only in clerical and administrative jobs, but in predominantly male employment areas such as engineering and construction, this change of culture may show for the first time equal or greater frequencies of Schmorl's nodes in the female clinical groups (Smith and Mustard, 2004).

7. The different appearances of Schmorl's nodes have different origins and underlying causes.

The aetiology of varying types of Schmorl's nodes may be elusive because each type is not found in association with a specific disorder or disease. Our knowledge of the development of Schmorl's nodes is limited because of the clinical belief that they are incidental findings where back pain investigations are undertaken, and are therefore not considered as a possible cause of the acute pain suffered by the patient. Traumatic Schmorl's nodes, and Schmorl's nodes found where bone weakening diseases and metabolic disorders are present, may be found to have differing aetiologies.

8. The underlying pathologies, deformities, and irregularities of the pelvis and alterations of the leg length cause disruption to the dynamics of the vertebral column and Schmorl's nodes.

This hypothesis could only be tested within the clinical samples as the majority of archaeological samples had incomplete pelvic and lower limb bones.

### 1.3 Christian Geörg Schmorl, the man, and the pathologist.

Born in the Kingdom of Saxony, Georg Christian Schmorl by his ninth birthday in 1869, found himself living in the State of Saxony, soon to become part of the Weimar Republic (German Embassy, 2005). Son of a noble family he entered the Princely School in Meissen aged fourteen years, and graduated aged twenty years. Mathematics was his first choice on entering university, but after one year at the University of Frauberg, he switched studies to the Medical School of the University of Leipzig. Schmorl graduated as a doctor of medicine in 1887, qualifying in the same period as a modern doctor. Schmorl was to join a profession where doctors had been demoted to tradesmen, lowering their status, and at the same time removing all restrictions on practices within the trade; the North German Confederation implemented this change of status. He undertook further education and research in the young country of Germany, communicating only in his mother tongue of Saxon, augmented by classical Greek and Latin. During the post war period when Schmorl began his research on the structures and stresses affecting the intervertebral disc, doctors were not only divided into separate disciplinary groups, they were also being restricted, or progressed, within medicine dependent upon their political affiliations (Cocks, 2002). Unlike his modern counterparts, he immediately took up a post as a trainee pathologist, and continued to work within the same discipline, and Institute, in Dresden for the whole of his life, (Junghanns, 1983).

Study of the vertebral column was his third, and final field of research, having first studied and published papers on neural eclampsia of women suffering pre-eclampsia (Hanson, 2000). Schmorl's next research area was neonatal jaundice and its effect upon the cerebellum, for which he autopsied 280 neonatal cadavers. In 1928, Schmorl turned his attention to the vertebral column as a dynamic whole, and specifically to the

intervertebral discs, which until that time were ignored in the context of possible pain, and disruption, when considering restricted movement and acute pain (Vernon-Roberts, 1994).

Seeing an extremely high incidence of rickets in soldiers returning from the First World War was the explanation given to students for his sudden change of direction in research within the autopsy room. This condition manifests itself in permanently altered primary and secondary curves caused by scoliotic shift on becoming a chronic condition. A collection of over 10,000 vertebral columns was accumulated for dissection and examination, from the whole of Germany over five years. Today this method of collecting material for autopsy would not be possible, due to strict ethical guidelines set down by the German government, and the need for a pre-death agreement between the donor and the recipients. In the period between the two world wars, guidance on ethics came from within the medical profession, which was self-governing. The populace of Germany, and several other European countries, did not object to friendless people who died in hospital, or prisoners who died in prison, becoming the subject of dissection, as long as they had a proper religious service, and the state paid for the interment after dissection (Wikipedia, 2005). The autopsy room must have been similar to a modern factory production line, with between fifteen to twenty junior colleagues dissecting spines simultaneously. Schmorl conducted the minutiae of each dissection to provide correctly prepared specimens for his research, at the same time teaching pathology to those junior doctors. Within the spinal collection of the Stadt Krankenhaus Dresden-Friedrichstadt, every known spinal disease and disorder is represented, with space number "1" reserved for Schmorl's own vertebral column. His friend and successor, Professor Giepel, placed the macerated vertebral column of Schmorl in the space he had reserved.

Before focussing on intervertebral disc structures, disorders, and diseases, Schmorl undertook a study of the serrated edges of the superior and inferior cortical borders of subadult vertebrae, his results showed incomplete fusion of the vertebral end plates and not sequestration by tuberculosis. Misdiagnosis of the rough edged growth areas of the juvenile vertebra, as “serration of tuberculosis sequestera”, given when reporting roentgenograms ceased, and normal findings in the juvenile vertebrae, where growth was incomplete, became the reasoned diagnosis (Esteve, 1994).

Prior to the work of Schmorl, the loss of disc height visible on roentgenograms was ignored as an ‘invisible space’, or as Junghanns (1983: 332) said, “for the diagnostic x-ray this space was empty, without meaning” and, therefore an unlikely source of pain. Schmorl associated loss of disc height with intrusions and extrusions of intervertebral disc material, which was confirmed by his research of the disc and its predisposition to structural damage due to repetitive torsion and compression, or impact injury.

Schmorl’s co-author and professor of Medicine at the same Institute, Herbert Junghanns, outlived him by thirty-four years, continuing to research until 1968 and helping to translate their book of ‘The Spine in Health and Disease’, first published in English in 1971. Septicaemia caused the premature death of Christian Georg Schmorl in 1932, caused by a scalpel which slipped and cut his own finger during the dissection of a vertebral column.

### 1.3.1 Christian Geörg Schmorl: his work on Schmorl’s nodes and his main findings

The original focus of Schmorl’s research was cadaveric dissection of the vertebral column, initially, to study the painful condition of rickets which he had regularly diagnosed in soldiers returning from the First World War. Rickets or osteomalacia is

now scientifically proven to be caused by a deficiency in vitamin D which is found in oily fish, and is produced in the skin by the action of the sunlight's ultraviolet rays (Levis *et al.*, 2005). Lowered levels of vitamin D reduce the intestine's ability to absorb phosphates and calcium, without which demineralization of the skeleton occurs (Meyer, 2004). The diet of the soldier was mainly vegetables and porridge, corned beef and hard biscuits, the whole accompanied by strong tea or water (Holmes, 2005) which did nothing to provide the body with sufficient levels of vitamin D. However, most of vitamin D is produced in the skin. The change of focus to research of the intervertebral disc is neither explained nor discussed within the writings of Schmorl or Junghanns. Schmorl's research of the intervertebral disc may have been brought about by his visualization of turgidity and structural disintegration of the intervertebral disc, due to reduced nutrient infiltration caused by lack of vitamin D in the diet (Lewis, 2005). Vitamins had been given the name 'vitamine' by Casmir Funk, a Polish biochemist (Carpenter, 2004), who proposed that 'vital-amines' were missing from the diet of people suffering from scurvy and polineuropathy (Thomas, 1998). Schmorl's methods of recording anatomy and physiology through dissection included visual recording and photography as the principle recording mediums. In 1930, one of Schmorl's pathology students, namely Herbert Junghanns (Junghanns, 1983: 7), suggested the use of roentgen imaging as a second method of investigation. Acting immediately upon this suggestion, provision for roentgenography allowed researchers to visualise cadavers by means of x-rays before dissection commenced. Now Schmorl was able employed two mediums which could be used to diagnose injury, and disease, firstly time honoured anatomical dissection and secondly (the new) radiography/ roentgenography.

This new recording medium was discovered in 1895 by a fellow German from Wuerzburg, Wilhelm Roentgen (Bowers, 1970: 3), and named *x-rays*, the X

representing the as yet undiscovered source of this amazing invisible ray. Röntgen discovered the *x-ray*, as an accidental bi-product of the bombardment of electrical particles from a cathode onto the surface of an anode within a sealed, gas filled tube (Thomas, 2001). The ability of these invisible rays to pass without interruption through everything except bone and metal brought great excitement to scientists, as well as physicians and surgeons; before that time, non-invasive investigations were not available to diagnose injury and disease.

Herbert Junghanns, co-author of the *Human Spine in Health and Disease* remains a shadowy figure, always named along with Schmorl, but rarely quoted as an authority on the dynamics of the spine in his own right. Junghanns was researching the function, and interaction, of the intervertebral discs and vertebrae, with the main emphasis of his work on the spinal cord and nerve roots (Edelmann, 2004). This work was carried out at the university hospital in Freiburg with no communication with Schmorl; only after the First World War did Junghanns move to the Dresden Institute. This move was at the suggestion of a Professor Aschoff, who took up a position at the Freiburg Institute, a position originally offered to Schmorl. Aschoff visited Junghanns, told him of Schmorl's research, and suggested that a move to Dresden could only be beneficial to his own research. Employed as a student pathologist, Junghanns arrived at the beginning of Schmorl's work on the invisible space or the soft tissue structures of the disc (Junghanns, 1983). In the 1950's, the term 'Junghanns segment' was given to two contiguous vertebrae and the intervening intervertebral disc. Junghanns researched changes to vertebral structures and their functions where paralysis was caused by injury, fracture or disintegration of the annulus fibrosus, causing pressure on the nerve roots and/or spinal cord (*ibid*, 1983). Professor Grashey, who was editor of a magazine, 'Progress in X-Rays', suggested co-authorship of the book, known in English as, 'The

Human Spine in Health and Disease'. Schmorl had submitted several articles to Grashey for publication. Grashey had also attended many lectures on the structures and stresses of the spine, where the lectures were accompanied by roentgenograms of the various diseases under discussion. Subsequently, Grashey approached Schmorl about the possibility of one book to carry all the known information of the spine, using roentgenogram images, and photographs of dissected vertebral columns as visual aids, wherever possible. Schmorl replied that he was too old to carry out such a work but, with the help of a senior physician, it might be possible. Grashey proposed Junghanns as a suitable person, being the introducer of radiography to Schmorl's work, and a long established researcher into the segmentation of the spine (*Ibid*, 1983). Schmorl died in 1932, only months after the first edition of his international acclaimed book *Die Gesunde und Kranke Wirbelsäule im Röntgenbilde* and prior to the book's updating and translation for use throughout the world.

### 1.3.2 Methods used by Schmorl

The methods employed as discussed previously were dissection and radiography. In the first instance, dissection with copious notes, anatomical drawings and photography were used to record the work undertaken in the dissection room. In later years, radiography was introduced into this research and, for the first time, Schmorl, with Junghanns help, could visualise the bones. This new medium allowed bones to be studied in the living before making surgical decisions, and in the deceased before autopsy. The intervertebral disc was to remain the "invisible space" for many decades to come, the exception being when a contrast agent containing traces of iodine was introduced into the disc tissues (Barrington, 2005).

#### (i) Dissection



Cadaver preservations and historic dissections are not comparable to methods used today where preservation of the cadaver is carried out as close to death as is possible and micro-tools are now used (*pers comm.*, Dr. E. Duval, Professor of Anatomy, Edinburgh University Medical School, 09/05/2005). Bodies studied in anatomical dissection at the end of the 19<sup>th</sup> and at the beginning of the 20<sup>th</sup> century are unlikely to have been preserved or mummified because of the high costs this would have incurred. In an age where the telephone and the internal combustion engine had little place, the length of time that corpses awaited collection is unclear. The statement of Henderson (1987, 43-54), that, “the exposed corpse, however, is more open to changes in the environment (such as humidity and temperature) and is more susceptible to attack”, suggests possible early decomposition before any autopsy was undertaken. Herbert Junghanns writes of the collection of foetuses, stillbirths, deceased children and women from the local women’s hospital, as well as autopsies of the dead from his own Institute (hospital). How long these cadavers waited for dissection is an unknown quantity; there may have been a considerable time lapse before dissection occurred. Shutting down of the vital organs, starving the tissues of oxygen, and delay in processing these cadavers, would all have lead to degeneration of the soft tissues used by Schmorl in his research of the intervertebral disc (Freemont *et al.*, 2001). The invention of large refrigeration plants of the type we use today for the storage of dead bodies did not exist so, other than stone-floored rooms without heating or windows, where constant coolness or humidity could not be applied, there was no way of preserving the bodies. Bone deteriorates if not dry therefore, if it remained attached to the macerated soft tissue structures the environment would not be ideal (Mant, 1987; Rintoul and Smith, 1973). The results from Schmorl’s research may have been skewed by deterioration of bone and tissue structures. Mant (1987) and Rintoul and Smith (1973), discuss the deterioration of bone which remains attached to the macerated soft tissues where the environment is not

controlled by temperature, enabling bodily fluids to react with the bony structures.

The number of bodies dissected by Schmorl was 10,000. This is the only figure recorded, and data on the numbers of males and females, the number of subadults, or aborted fetuses, are not given. The Anatomy Act of 1832 did not apply to Germany, and the European attitude to the fate of the soul was not given much weight, where the poor and dispossessed were concerned (Bhanji, 1995). In all probability the dissection of untreated cadavers was undertaken as soon as possible after acquisition with any tissues to be used for slides being frozen before slicing to allow thin sections to be made (*pers comm.*, Iain Stewart, Marischal School of Anatomy, 09/05/2005). If Junghanns (1983) was correct in his estimation of the number of cadavers collected and dissected over a five year period, it would necessitate a minimum of five dissections per day, every day of each year.

No finely milled steel tools or carbon fibre blades for dissection were available, instead a large band saw, described as large enough and robust enough to be employed in a large sawmill was used (Junghanns, 1983). The atlas and odontoid peg were chiselled free of the foramen magnum, the innominates were sawn through to leave the complete sacrum, and then Schmorl sagittally sectioned the full vertebral column using the band saw. Carrying out this work must have been laborious and extremely time consuming. Vertebral end plates may well have suffered damage, due to bad preservation or by soaking in a preservative, making possible diagnosis of anatomical structures inaccurate. Schmorl and Junghanns (1971: 10) state that, "Within the circumference of the vertebral rim, the perforated vertebral plates are covered by the cartilaginous plate. The latter has been destroyed by maceration of the specimen".

(ii) Radiography

Diagnostic radiography in the modern world has become a routine tool in the diagnosis and treatment of injury and disease, free at the point of delivery in Britain and almost expected as a right by all patients attending hospital (Paxton and Heaney, 1997). Modern Radiation Physics Protection Boards not only expect good practice, they also examine all aspects of radiation dosage and set stringent guidelines for use that are non-negotiable within all disciplines (Anon. 1, 2003). Comparison of the tools and equipment available to the modern clinician, and those Schmorl used leave question marks as to the validity of his understanding of the vertebral and intervertebral structures. Modern stainless steel tools edged with carbon can be designed and milled to much finer specifications, allowing smoother cuts and finer slices during autopsy (Anon. 2, 2006).

The introduction of radiography into Schmorl's research methods, allowed imaging of each vertebral column in the antero-posterior, and lateral positions before dissection took place. Whether the images were compared to the sagittally sectioned vertebral columns is not recorded, so no information regarding possible damage during dissection is available. A paper, or positive image, is as good as the technician and his/her understanding of what was required in the production of a radiograph. An aesthetically pleasing image to the eye might not be a good diagnostic image for the physician. A modern negative radiographic image can be manipulated by increasing and decreasing the emitted light used to read the imposed image. Using the very latest computed radiology (CR) system the negative image can also be manipulated, the image reversed to a positive image, or an area of special interest can be magnified to give a clearer view of the minutiae allowing the smallest of lesions to be identified (Eastman Kodak, 2003).

(iii) Christian Geörg Schmorl and Junghanns and the development of Schmorl's Nodes

Schmorl writes, “not only are there omissions, but various false concepts of the nature of certain diseases, and the changes which may occur in trauma and disease which have been perpetuated by uncritical transference from one text to the next”. This is particularly true with regard to those spinal diseases in which the developmental processes, involving the area between the disc and the vertebral body, are so important (Schmorl and Junghanns, 1971: 2).


The above statement is contained within the second page, of the first chapter, of the *Human Spine in Health and Disease*. It highlights the problems in research on Schmorl's nodes encountered in the current study. The reported findings of the research carried out by Christian Georg Schmorl on the structure and diseases of the vertebral column and specifically Schmorl's nodes appear contradictory when separate entries are compared, with the expectation of each supporting the other. A few of the written statements are:

1. Schmorl associates the cartilaginous plate (Fig. 1.3) with the disc (*ibid*: 12).
2. The cartilaginous plate is fixed to the vertebral end plate by a layer of calcium. The calcium layer acts as a nutrient filter, allowing nutrient infiltration to the intervertebral disc through the lacunae of the cartilaginous end plate (*ibid*: 15).
3. Disc tissue becomes embedded between the cartilaginous end plates and the bony plates of the vertebrae and then, by rupturing the end plates, lodges in the inner parts of the vertebrae (*ibid*: 167).

4. Describing a macerated vertebra, the superior and inferior surfaces are described as consisting of rough bone, best described as vertebral plates.
5. The nucleus pulposus is located on this strengthened area which, thus may be called a stress bearing plate (*ibid*: 6).

The structure and strength of the end plate is at the centre of all the hypotheses to be tested in the current study, as it is the action and reaction of the nucleus pulposus with the end plate, and the end plate's inherent strengths or weaknesses in health, and sickness, which are the focus. It is therefore necessary to have a clear understanding of the results of Schmorl's own research of Schmorl's nodes.

When dealing with the development of the vertebral column with reference to the vertebral bodies and intervertebral discs, the following is noted. "As the beginnings of ossification occur, the chorda dorsalis becomes encroached upon, while in the area of the disc analage it becomes ballooned (intervertebral chorda swelling). Finally, within the vertebral border, the chorda disappears completely; but in the nucleus pulposus, some chorda cells remain" (Schmorl and Junghanns, 1971: 2). This statement by Schmorl and Junghanns (1971: 2) which is supported by Begg (1954: 184) and Leibner and Floman (1998: 227) is of significant importance regarding the integrity and strength of the end plates. At no point does Schmorl refer to a remnant of the notochord within the vertebral body's superior and inferior cortical surfaces; it is said that congenital or acquired pathological changes can cause fissures to appear in the superior and inferior end plates of the vertebral body. Schmorl (1971: 6) also states, "The nucleus pulposus is located on the strengthened area of the end plate which thus may be called a *stress-bearing plate*", once again confirming a strong end plate (Fig. 1.3).



**Figure 1.3** Roentgenogram (paper image) showing Schmorl's vertical plates, and end plates, of a nine-year-old child (from Schmorl and Junghanns, 1971: 9)

Intervertebral disc height reduction may be a significant indicator of the presence of Schmorl's nodes, or conversely of little significance when modern radiographic imaging is used. Two macerated specimens (Fig. 1.4a and 1.4b) are said by Schmorl (1971: 7-9) to demonstrate the alteration of the height of the intervertebral disc space during, and on completion of, the growth phase. Looking at the photograph of a twenty-three year-old woman (Fig. 1.4a), the vertebral end plates have fully developed and united with the vertebral bodies; this is labelled as presenting diminished intervertebral disc height. Looking at Figure 1.4a, there do not appear to any intervertebral discs present; an empty space between the two lower vertebral bodies is visible, with the remaining vertebrae sitting directly upon each other, bone to bone. This six year-old spine shows clearly the remains of intervertebral discs (Fig. 1.4b) sitting between the vertebral bodies. Schmorl (1971: 7-11) relates loss of disc height at the level of Schmorl's nodes to loss of the

pulposus of the nucleus because of its intrusion into the vertebral body in a healthy spine as demonstrated but, the images (Fig. 1.4a and 1.4b) do not appear to demonstrate Schmorl's nodes. When Schmorl's nodes are formed, the nucleus pulposus ruptures and forces its contents through the end plate of the vertebra leaving the annulus fibrosus of the intervertebral disc as a cushion of reduced height (Clark and Letts, 2001), and not completely absent as shown (Fig. 1.4a).

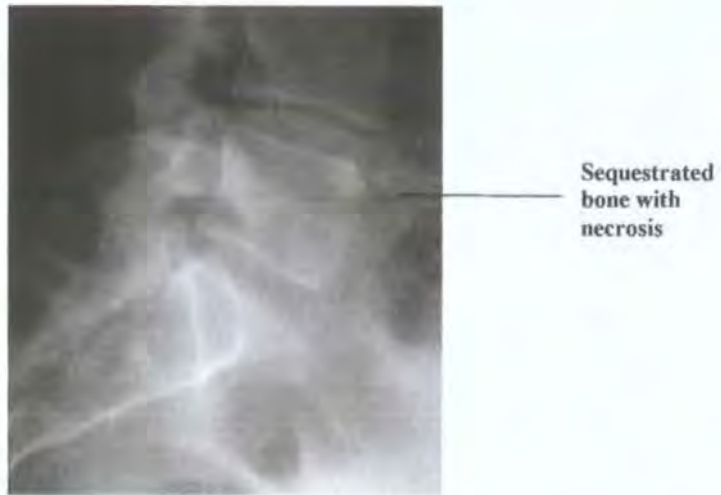

Figure 1.4a Twenty three year old spine

Figure 1.4b Six year old spine

(from Schmorl and Junghanns, 1971: 7-9)

Reasoning suggests that if Schmorl used a band saw to sagittally section the vertebral columns, he may have caused damage to the plates at the point of sectioning and, by vibration, further across the necrosed end plates. Vibration, leading to fracturing of the end plates, cortex, and trabeculae, would allow displacement of any ruptured nucleus pulposus into the damaged vertebral body.



**Figure 1.5 Anterior superior sequestration with necrosis  
(from Royal Hospital for Sick Children teaching archive)**

The separation of wedge shaped pieces of bone (sequestration) (Fig. 1.5) is said to be an almost exclusive occurrence in the superior-anterior rim, where the pulposus of the ruptured nucleus finds a weak crevice, or fissure, caused by daily repeated stress to the area (Begg, 1954). Only rarely are these oblique fractures or sequestrations seen on the inferior-anterior rim and cartilaginous plate (Schmorl and Junghanns, 1971: 16). Once the pulposus of the ruptured nucleus has fractured, the cartilaginous and the osseous end plate of the vertebra, they are infiltrated by the pulposus of the nucleus which enters the vertebral body, forming a Schmorl's node (*ibid*: 159).

Another statement made by Schmorl (1971: 161) is that "when intervertebral discs rupture under extreme tensile pressure they produce a decrease in the expansive pressure of the intervertebral disc. This decrease in expansive pressure is said to create a 'hump-like' raised area of excessive osseous tissue in the opposing side of the adjacent vertebral body". The type of trauma involved is described as producing extreme compression. Calcifications of the edges of the Schmorl's node through time are recorded with the disc material being reabsorbed or calcifying. Posterior and anterior

Schmorl's nodes are described, with anterior Schmorl's nodes causing Scheuermann's disease, a type of juvenile idiopathic kyphosis, or kyphosis dorsalis juvenilis (Scheuermann, 1920; Schmorl, 1930). Posterior herniation is described as putting pressure upon the spinal cord, and nerves of the appendicular skeleton, appropriate to the levels of intrusion. No mention is made of the fractured fragments of cortical bone pushed into the spinal cord space by posterior Schmorl's nodes. No person under thirty years of age was found by Schmorl to have posterior herniation; these extrusions of the nucleus pulposus and fragments of the annulus fibrosus rested between the posterior vertebral body and the longitudinal ligament, with the greatest incidence within the lower thoracic and lumbar vertebrae (*ibid*: 172).

Schmorl did not study the living before dissecting them in death, leaving us without notes relevant to signs and symptoms, which might lead us to the conclusion that, in life, localized spinal pain existed where Schmorl's nodes were discovered during dissection. Clinical evidence will be considered in the current study where acute or chronic pain was a precursor to the diagnosis of Schmorl's nodes, or conversely a complete lack of pain. A greater number of males were found positive for Schmorl's nodes in Schmorl's research but no relevant data is given.

#### (iv) The main findings from Schmorl's research

- How rates of foetal ossification of the vertebral components vary

Spondylolysis and spondylolisthesis can be caused by the inherent problem of differing ossification rate, between the somites (vertebral bodies) and the vertebral arches (posterior neural cord spaces) during the foetal growth period. The vertebral bodies

form from the pairs of somites which, in the final stage of transition into vertebral bodies/centra, go through a period of endochondral ossification caused by the in-growth of blood vessels. The laminae and pedicles of the vertebral arches have a period of perichondral growth, making their pre-ossified construction different to that of the vertebral bodies with which they will eventually unite, and ossify to form the adult vertebrae of the spinal column (Schmorl and Junghanns, 1971: 3).

- The development of the notochord's final stages

The notochord is formed from the endoderm as a primitive streak, from which the vertebral column forms. In the areas of the somites or vertebral bodies, the notochord regresses, and at the same time forms the intervertebral swelling which becomes the primordial nucleus pulposus (*ibid.*: 3 and 17). Healthy vertebrae have no weak spots within their endplates (*ibid.*: 158)

- The process of development of the vertebral rim (end plates)

These bony rims, or annular plates, unite with the superior and inferior surfaces of the vertebral bodies, but are not truly bony epiphyses as they have no growth areas facing the intervertebral discs (*ibid.*: 11-12).

- The structure of the spongiosa

The spongiosa of the vertebrae is made up of vertical and horizontal bony plates (Fig. 1.5) with a thicker bony plate parallel to both the superior and inferior end plates (*ibid.*: 12-13).

- The height of the intervertebral disc

The disc space had previously been known as a 'cleft', giving the impression of an empty space; this so-called empty space is the area between two vertebrae, where the intervertebral disc sits. The intervertebral disc height is a measurement of the height of the disc tissue acting as a cushion between the apposing vertebral bodies (*ibid*: 14). By comparing radiographic images, and dissected vertebral columns, through all stages of growth, a pattern of reducing disc height emerged. Adult intervertebral discs take up approximately one third of the height of the adult vertebral column, whereas the intervertebral discs of a neonatal vertebral column are equal in height to the centra of vertebrae (*ibid*: 14).

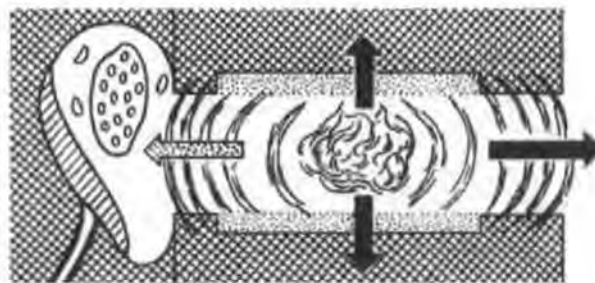
- How the intervertebral discs age and degenerate

The alteration of intervertebral disc height to vertebral body height as an ageing process, and as a radiographic indicator of possible discogenic disorder, were considered by Schmorl to be due to changed structural composition, by both ageing processes and continuous wear and tear. In ageing, the tissues of the body, and specifically the intervertebral discs, become less elastic and more friable, as their abilities to introduce nutrients by filtration decreases, and the nucleus pulposus becomes more turgid, and less able to alter its shape under pressure (*ibid*: 141).

- The process of development of osteochondrosis vertebralis (intervertebral osteochondrosis)

Intervertebral osteochondrosis on roentgenograms is seen as clear loss of vertical disc

height, often accompanied by radio-lucency in the area corresponding to the nucleus pulposus. Aging of the disc shows desiccation of the annulus fibrosus and tearing and fraying, along the leaves of the annulus fibrosus. In contrast, the nucleus pulposus, much reduced in height, has lost its elasticity, becoming an almost static component within the vertebral column. The loss of nutrient filtration is given as the main factor for this dynamic change of the intervertebral disc (*ibid.*: 139-140). This type of intervertebral osteochondrosis is contained within the intervertebral disc space with no impingement on the surrounding nerve roots, ligaments, or tendons. Secondary intervertebral osteochondrosis is the chronic condition involving an extrusion of material from the nucleus pulposus, annulus fibrosus, or both, posteriorly, anteriorly, laterally, superiorly, or inferiorly (Fig. 1.6). This displacement of intervertebral disc material may cause pressure upon the anterior, or posterior, longitudinal ligament, producing acute pain or loss of feeling at the levels of involvement (loss of neural signalling). The reduced vertical height, combined with the turgid intervertebral disc can reduce ligament strength, allowing the superior vertebra to slip forward on the inferior vertebra, causing spondylolisthesis.



**Figure 1.6 A sagittal section of intervertebral disc showing possible directions taken by extruded material from the nucleus pulposus (from Schmorl and Junghanns, 1971)**

Superior and inferior prolapse of the nucleus pulposus through the vertebral body end plates produces *Schmorl's nodes*. Schmorl made one further observation of intervertebral osteochondrosis in its severest form, that the end plates of the

vertebral bodies had cartilaginous nodes superimposed upon them at irregular intervals, with subchondral changes to the trabeculae leaving well define spaces just beneath the cortical bone (*ibid*: 145-146).

- The process of development of Schmorl's nodes

Schmorl's nodes are extrusions of the nucleus pulposus of the intervertebral disc through the end plates of the superior and inferior vertebral body end plates, causing disruption to the subchondral bone beneath. Schmorl describes them thus: "At first, through the resorption of small, fine trabeculae, a small cavity is created into which more and more of the disc tissue is pressed. Gradually, the continued and repeated pressure stimuli produce reactive changes in the surrounding osseous trabeculae which at first produce a cartilaginous, and later osseous, casing, in the surrounding of the prolapsed disc tissue. The osseous casing halts the enlargement of the disc prolapse" (Schmorl and Junghanns, 1971: 165). Further progression is halted, and pressure changes are arrested, as soon as the nucleus pulposus loses its elastic expansive pressure. This is in part possible because of a decrease in the water content of the disc, ageing processes, and general wear and tear; it is also partly the result of local formation of cartilaginous nodes with associated loss of tissue and fluid. With the formation of larger Schmorl's nodes, these changes become regular and unavoidable sequelae (*ibid*: 159). Two causes of Schmorl's nodes are given, the first by wear and tear, and the second by trauma. The first type of Schmorl's node is a fracturing of the end plate, caused by repeated bending and twisting, with or without added weight; the end plate, having a weak spot, allows intrusion of the material of the nucleus pulposus. The second type is said to be caused by one sudden injury, and is known to produce single or multiple Schmorl's nodes (*ibid*: 166). Schmorl does not provide evidence of the end

plates affected by Schmorl's nodes, nor the levels or numbers when describing his findings.

#### 1.4 Research in Schmorl's nodes since Schmorl

In 1971, the translation from German to English of *the Human Spine in Health and Disease* allowed more British researchers, in a wider range of disciplines, to read and understand the work that Schmorl and Junghanns had carried out in the 1920s and 1930s.

##### 1.4.1 Research without direct reference to Schmorl

Many orthopaedic and neurological surgeons, and specialists in pain management, have researched the vertebral lesion known as a Schmorl's node. However, some of those researchers carried out their work without reference to the work of Schmorl, or Schmorl and Junghanns. Peng *et al.*, (2003: 880), discuss the 'Pathogenesis of Schmorl's Nodes', stating within their introduction that, "Schmorl's nodes have been widely assumed to be the herniation of the nucleus pulposus through the cartilaginous end plate into the vertebral body". At no point is Schmorl's work discussed neither is he cited within the bibliography. Siberstein *et al.*, (1999: 27) used magnetic resonance imaging in their research into the aetiology of Schmorl's nodes, and the interaction between the nucleus pulposus and the vertebral end plates; again no direct reference to the work of Schmorl is found. However, in the introduction, the following statement is made, "a Schmorl's node is a focal herniation of the nucleus pulposus into the adjoining vertebral end plate, most are thought to arise from trauma following compressive loading". A third example (Riepert *et al.*, 1995: 126-127) is a forensic study that used computed tomography to identify a murder victim whose torso had been recovered from a river. This particular case used the presence and position of a previously diagnosed Schmorl's node within

the fourth lumbar vertebra, and clubbing of the lateral process of the same vertebra, as a means of identification by comparing ante-mortem radiographs. At no point do Riepert *et al.*, (1995) give a definition of a Schmorl's node, or quote from Schmorl's work to understand the reasoning behind the victim's positive identification. Altered positioning of the spine and focal angulations in the radiographic process can give varying results when computed tomography is executed; this alone could alter the resulting images yet at no point is the degree of accuracy of the CT mentioned. All these authors provide a description of Schmorl's nodes without reference to Schmorl and Junghanns (1971) book *The Human Spine in Health and Disease*.

Nevertheless researchers have written many short papers about Schmorl's nodes, with almost all accepting without question the statements of Schmorl (Schmorl and Junghanns, 1971: 158) that, with reference to Schmorl's nodes,

- “The protrusion of disc tissue into the adjacent vertebral body is only possible when there are gaps in the cartilaginous plates” (Chandraraj *et al.*, 1998: 71; Hannson and Roos, 1983: 266).
- “An area of special interest is the region of the nucleus pulposus for here the previous chorda dorsalis extended through the spine and in many cases left an indentation” (Leibner and Floman, 1998: 225).

Researchers who have produced papers on Schmorl's nodes and who have not cited the work of Schmorl and Junghanns include Begg (1954), Seymour *et al* (1998), Frymoyer *et al.* (1984), Marchiori *et al.* (1994); each has quoted one or both of the above statements, leading to the conclusion that these statements are taught and retained as fact.

#### 1.4.2 The Use of Magnetic Resonance Imaging

As early as 1994, Hamanashi *et al.* were undertaking studies of Schmorl's nodes using magnetic resonance imaging to assess the incidence of Schmorl's nodes found using this method of investigation compared to plain film imaging. Research has continued using MRI to try to discover a link between Schmorl's nodes and degenerative disc disease, where pain experience points to localised acute or chronic pain. Pffirman and Resnick (2001), and Benneker *et al.* (2005) have used varying signs on MRIs, with and without gadolinium (intravenous contrast agent), in an attempt to show clear correlation between Schmorl's nodes, degenerative disc disease and pain experience without complete success. Positively proved is the correlation of localised pain and Schmorl's nodes.

#### 1.4.3 Studies of Scheuermann's disease and Schmorl's nodes

Swischuk *et al.*, (1998), and Ali *et al.* (2000) using plain film radiography, and MRI, have further researched the possible correlation of Scheuermann's disease and anterior end plate erosion and the vertebral bowing of the anterior part of the superior and inferior borders of the cortex of the vertebral body. Schmorl wrote of the anterior Schmorl's node found in children in their early teenage years and the subsequent softening of the cancellous bone of the anterior vertebral body. This did not provide proof of a definite relationship between Schmorl's nodes and Scheuermann's disease. Taylor (2000) using dissected spinal material looked at Schmorl's nodes and changed vascularity in the area of the end plate of the vertebral body where Scheuermann's disease had been diagnosed. Again, a definite link between Schmorl's nodes and Scheuermann's disease could not be positively identified. Studying the original writings of Schmorl and Junghanns, alongside any other records of Schmorl's pathological studies of the vertebral column, may bring a better understanding of the methods he

used and his results and interpretations. Accepting as correct the previous interpretations of Schmorl's nodes cannot further our understanding of Schmorl's nodes, their origins or their sequelae. It may be reasonable to assume that, historically, medical students receiving their clinical expertise did so from their teachers in verbal and note form; this verbal transfer of knowledge led to incorrect interpretations and to well-held beliefs becoming fact. An example of the almost godlike status of professors of medicine, and their dismissive attitude to any person of lower rank questioning their knowledge, is the case of Ignaz Semmelweiss (junior doctor of obstetrics and gynaecology) which represents the attitudes of the time (Hurlbert, 1999).

### 1.5 Schmorl's nodes in clinical practice today

No patient presents for radiographic examination of the spine with a clinical history that includes a specific statement of pain caused by Schmorl's nodes. Patients requiring radiographic examinations of their thoracic and/or lumbar spines, and showing positive for Schmorl's nodes, are often suffering acute localised pain at the levels of vertebrae affected. A sneeze or cough while bending, or other sudden movement (Wagner *et al.*, 2000), can cause the sudden onset of pain with a very specific focus (Takashi and Takata, 1994), where no previous pain existed. If this pain diminishes and then disappears over several weeks, no further images will be taken. Until recently, physicians and surgeons have been inclined to dismiss Schmorl's nodes because they are asymptomatic (Pfirrmann and Resnick, 2001; Dr .A. McGowan, and Mr. Ghalli, October 1996, *pers. comm.*). This perception has changed over the last two years as MRI has become a regularly used tool in diagnosing back problems which cause persistent pain and loss of locomotive co-ordination (Renfrew, 2003: 129-150). When active Schmorl's nodes are observed during MRI, they are noted, and treatment normally reserved for discitis is prescribed; this treatment is an intravenous infusion of

antistaphylococcal antibiotics which are introduced over a three to five day period, during which time the pain should have diminished (McCarthy *et al.*, 2004). A bright, or white, signal is present where sclerotic, or reactive, bone is present at the levels of reported Schmorl's nodes (Tosi *et al.*, 1996).

“Schmorl's nodes, the result of previous intraosseous disc herniation, are a common incidental finding on plain radiographs, computed tomography, and magnetic resonance imaging” state Seymour *et al* (1998). This is a statement often made in clinical research papers. Several authors of papers who have made the preceding statement in their introductions to work on Schmorl's nodes include Hauger *et al*, (2001); and Takahashi and Takata (1994). However, these authors misuse the term “common” as no statistical evidence is produced to support their statements.

#### 1.6 Schmorl's nodes in biological anthropology

Many osteoarchaeologists report the presence of Schmorl's nodes in skeletal remains from archaeological sites. The method of recording this disorder, with few exceptions, reports the evidence of presence, the number of vertebrae involved, and percentages of males and females affected; the levels or surfaces of vertebrae affected are not usually provided (Anderson and Carter, 1994). This manner of reporting Schmorl's nodes arises from the incomplete nature of many of the skeletons excavated due to adverse burial conditions. For example, the skeletal report may indicate the number of skeletons found positive for Schmorl's nodes, but the sex of the individual skeletons affected, and the vertebral surfaces involved, do not appear within that report. As the vertebral column is a complex jointed structure, it may be reasonable to assume that looking at each individual vertebra, without considering its relationship as part of the whole, does not give a true indication of its action and reaction, as part of that whole (Lunn *et al.*, 2003). This research is confined to skeletons with a complete compliment of thoracic and

lumbar vertebrae with and without Schmorl's nodes to allow comparison with clinical data.

In osteological work Schmorl's, or cartilaginous, nodes have been categorised as "spinal joint disease" (King, 2000: 14), which is correct as to location but not in definition as two recent studies have proved (Tellwright, 1998; Fan, 2004). Schmorl's nodes and osteoarthritis may be present within the same vertebral column but correlation between the two is impossible to determine. The vertebral column can show signs of early degeneration within the second and third decades of life but a skeleton of 40 to 50 years of age may show no bony alterations or degeneration i.e. people age at different rates within the vertebral column.

The Tarbat Old Church, Portmahomack skeletal report (King, 2000) indicates another method of presenting data. It gives the percentage of vertebrae found positive for Schmorl's nodes by the individual vertebrae examined, thus eliminating the possibility of assessing the frequency of vertebral columns affected. Any possible link between the spinal joint diseases of Schmorl's nodes, osteoarthritis, and degenerative disc disease (spondylosis) cannot be estimated, as the individual vertebral columns affected are unknown. 37 or 38 skeletons were recovered from a burial pit in Yorkshire, England, the site of the battle of Towton (AD 1461), Eighty percent of vertebral columns macroscopically examined were recorded as containing Schmorl's nodes. The numbers of superior or inferior end plates involved were displayed graphically (Boylston *et al.*, 2000); these results go further to help identify the levels of insult but do not allow estimation of the number of vertebrae involved per skeleton or to look at possible relationships between osteoarthritis, spondylosis, and Schmorl's nodes. Each skeletal report varies in the way results are presented; this may be due to the space allowed

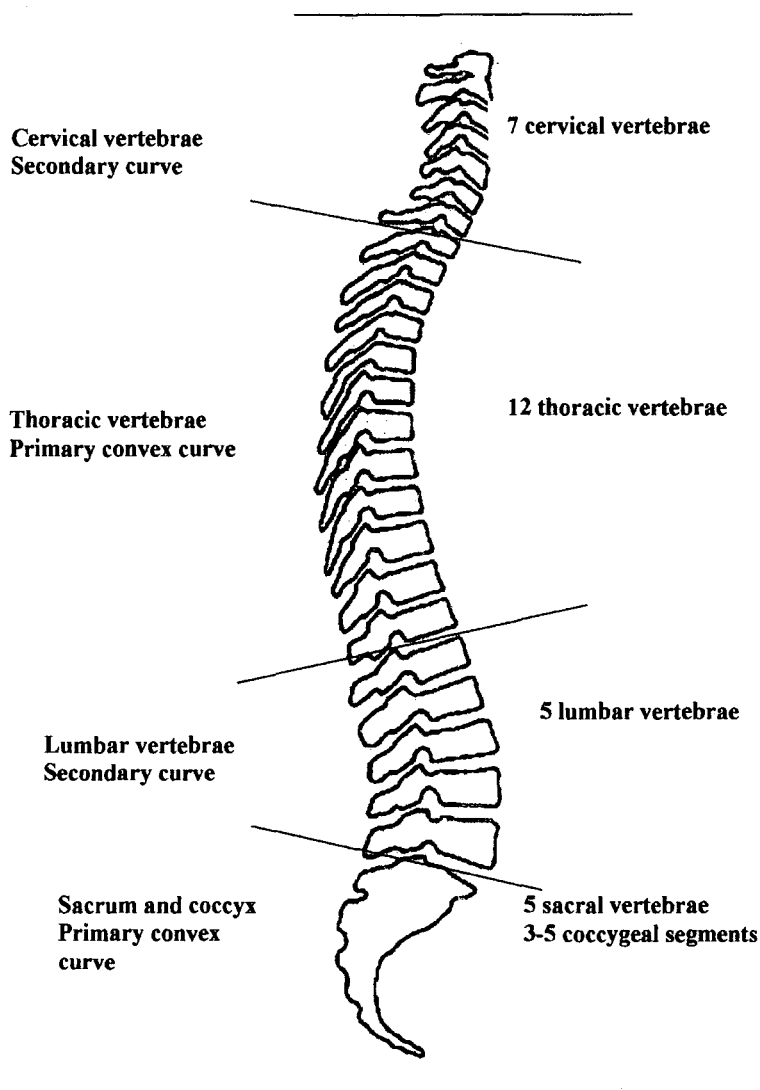
within the publication, the author's own preferred presentation, or the specialist interest of the author. Many archaeologists/osteoaarchaeologists introduce their reports on Schmorl's nodes by describing the depressions in the end plates of the vertebrae and attributing them to physical stress, and bending and twisting when lifting and moving heavy objects (Anderson, 1994: Cardy, 1997 and Coughlan and Holst, 2000 ).

## **Chapter 2: THE VERTEBRAL COLUMN: Structures and Development**

### **2.1 Introduction**

To test each of the hypotheses in this study requires an understanding of the anatomy and physiology of the integral parts of the vertebral column. The vertebrae, and the intervertebral discs, are a series of segmental units (Junghanns, 1990) which have no intrinsic strengths or stability without the support and strength of the longitudinal muscles, the ligaments, and the Sharpeys fibres (Unwin and Jones, 1975: 75).

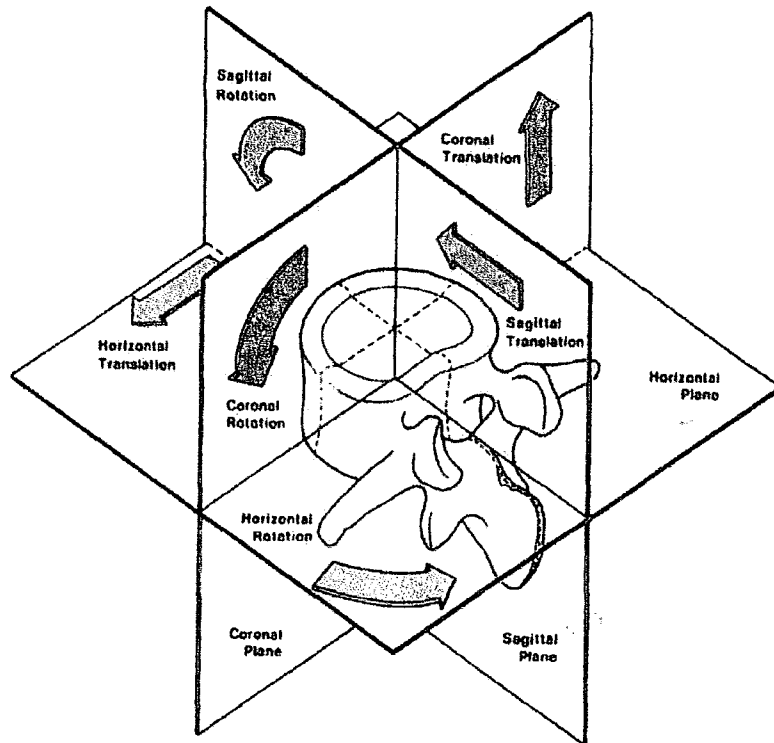
The cost of adapting to an upright posture (Merbs, 1996) is the exaggeration of the natural curves of the vertebral column and an increased risk of disruption to the intervertebral discs, and degeneration of the spine. Primary and secondary curves of the vertebral column relate directly to specific groups of vertebrae, the cervical and lumbar spine curving concavely (secondary curves), the primary convex curves being retained in thoracic, sacral and coccygeal areas, when viewed from the antero-posterior position in the sagittal plane (Fig. 2.1). When the vertebral column supports extra weight during bending and twisting movements (Seidler et al., 2003), or during extremes of flexion or extension of the natural curves, the risk of intervertebral disc disruption is greatly increased (Panjabi, 1998). From the moment of conception, the development of the vertebral column follows a pre-ordained pattern within which, each new embryo carries the risk of developing congenital disorders, somite failures, or drug induced abnormalities (Schier, 2004). Each component of the vertebral column has both strengths and weaknesses which in the healthy spine are of no significance. When acute pain and reduced patterns of movement are the outcomes of disruption in any part of the vertebral column then a clear understanding of anatomical structures is required if accurate diagnosis is to be made (Young et al., 1997).



**Figure 2.1 Sagittal view of the vertebral column showing the primary and secondary curves, and the number of vertebrae which form each curve**

The vertebral column is classified into five distinct sections (Fig. 2.1), comprising the seven cervical vertebrae, the twelve thoracic vertebrae, the five lumbar vertebrae, the five sacral segments and 3-5 coccygeal vertebrae. They contain and protect the spinal cord's autonomic and motor nerve roots and meninges without interruption, unless disruption of the vertebral column occurs at any part (Gunn, 2002). This complex structure allows minimal autonomic movements to permit re-centering of the body's gravity, and much more complex motor movements of twisting, extending and flexing (Fig. 2.2) (individual and interactive movements) as required. Intervertebral discs

connect and cushion the vertebrae, altering their dynamics as required to give the greatest functional stability possible to every movement of the vertebral column (Palastanga *et al.*, 1998; Schmorl and Junghanns, 1971).



**Figure 2.2** The range of movements within the vertebral column (from Bogduk, 2003: 69).

It is within the embryonic and foetal phases of growth that many of the structural faults of the vertebrae are currently understood to occur (Moore and Persaud, 2003: 350-2). Of relevance are radiologists and paediatricians who seek constantly to make medical staff aware that children cannot be treated as small adults (Renfrew, 2003: 39), and that these patients have their own growth problems, injuries and insults as well as disorders and diseases in their still growing and altering skeletal frames. Damage to any part of the yet incompletely developed growth areas of the paediatric vertebral column may lead to permanent disruption, and continuous complications, which may or may not be corrected by surgery or non-invasive treatments.

## 2.2 Development of the vertebral column

In understanding the complex anatomy and physiology of the human vertebral column, and its many reasons for failure, both major and minor, it is necessary to study the embryonic evolution of the soft tissue and osseous structures of the vertebral column. Profound and decisive influences are at work during the embryonic stages of evolution (Schmorl and Junghanns 1971: 2-3). Both formation and malformation of soft tissue and osseous structures are irrevocably influenced by the notochord during the prenatal phases (Moore and Persaud, 2003: 348-352). The notochord is string-like in appearance, sitting dorsally and traversing the abdominal and thoracic segments of the embryo, terminating within the cranial space where it is not yet distinguishable from the brain tissues. The notochord carries nutrition and nerve bundles, egressing during the early embryonic period and regressing during the later growth period.

### 2.2.1 Embryonic development: The first nine weeks.

Post fertilisation of the oocyte by the sperm, and before subdivision has occurred, a unique genetic fingerprint of an, as yet, not totally formed foetus containing half of its chromosomes from each parent is present. During the first nine weeks of embryonic growth, the rate of growth is rapid with tissues becoming distinguishable as separate primitive organs and structures (Moore and Persaud, 2003: 348-352). The embryonic cycle takes nine weeks to complete before the foetal period, or second and third stages of gestation, take place. Regardless of hereditary and genetic composition, every embryo follows the same evolutionary pattern from conception to birth.

#### (i) Week 1

Fusion of the bi-parental chromosomal material has already determined whether the embryo is male or female. At the same time paternal and maternal strings of chromosomes give a new genetic fingerprint to this, as yet, not totally formed human.

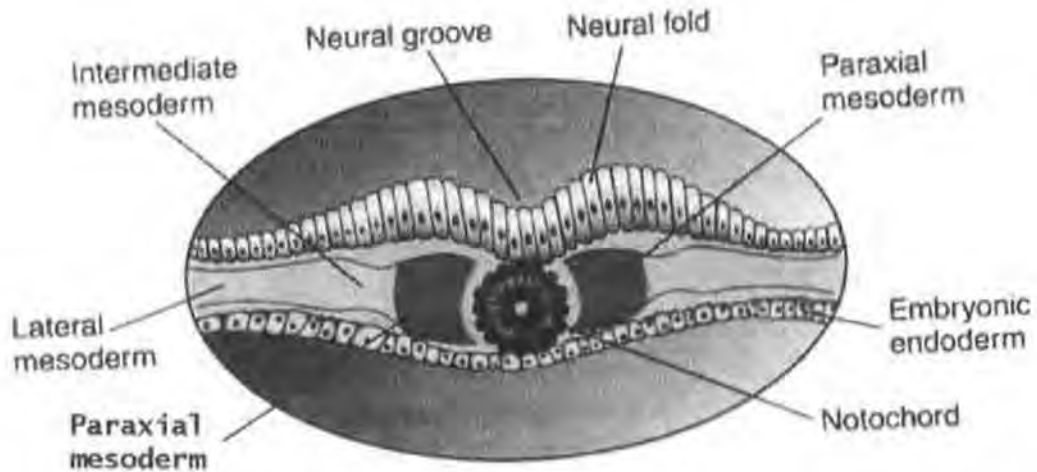
(ii) Week 2

The germ or primordial growth forms three distinct layers (Fig. 2.3):

- The ectoderm or outer germ layer is in contact with the amniotic fluid surrounding the embryo and foetus during gestation (Moore and Persaud, 2003: 51). The ectoderm forms the dermis or layers of the skin and the nervous systems, both central and peripheral.
- The mesoderm forms the connective tissues, organ linings and blood related organs (Vernon-Roberts, 1994); it will also form muscle coating, bone marrow, the constituents of the blood and the reproductive organs (Browder and Iten, 1998: 1).
- The endoderm is the inner layer of the germ, forming the primitive soft tissue structures of the lungs, digestive system and endocrine glands (Drummond, 1998: 2365). The first recognisable structure to evolve is the notochord.

The notochord and neural plate appear within the embryo, with the notochord arising from the endoderm and the neural plate from the ectoderm (Moore and Persaud, 2003: 49-52). Synchronised growth of the neural plate and notochord occurs in the second week, after which the neural plate extends cranially beyond the notochord to form the beginnings of the oropharyngeal membrane. The oropharyngeal membrane is that part

of the digestive system connecting the mouth to the oesophagus below, and the posterior part of the mouth and nasal cavity above (Goodman, 2003).



**Figure 2.3 The three primordial growth layers (Moore and Presaud, 2003)**

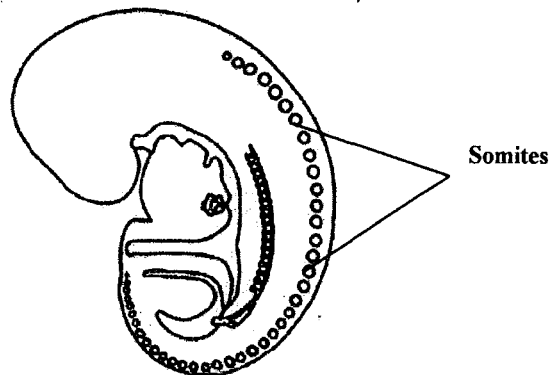
### (iii) Week 3

Central and peripheral nerves are represented in the primordial state by the neural plate, which sits dorsally to the notochord and forms from the ectoderm of the germ. During the third week of embryonic growth, the neural plate folds in on itself to form the neural groove, with flaring of the neural groove presenting cranially as the earliest representation of the meninges or covering layers of the hemispheres of the brain. Folding of the neural plate continues until the neural tube is formed; the neural tube is the rudimentary spinal cord (Scheuer and Black, 2004: 184).

### (iv) Weeks 4 and 5

Sclerotomes alter and evolve to produce the first recognisable elements of the vertebral column from within the mesoderm, sitting either side of the notochord and anteriorly to the neural tube. Somites are paired and matching groups of cells arising from the

mesoderm (Fig. 2.3); these paired somites attach themselves to the notochord commencing at the hindbrain and arising cranio-caudally over the fourth and fifth weeks of gestation (Scheuer and Black, 2004: 184). Segmentation and re-segmentation of the paired somites occurs until the centra/bodies of the vertebrae become recognisable as separate elements of the embryonic axial skeleton. Paired somites in their first embryonic form are separated from their neighbours by the paired intersegmental vessels, and divided into cranial and caudal sections by the paired segmental nerves (Moore and Persaud, 2003: 310-311).



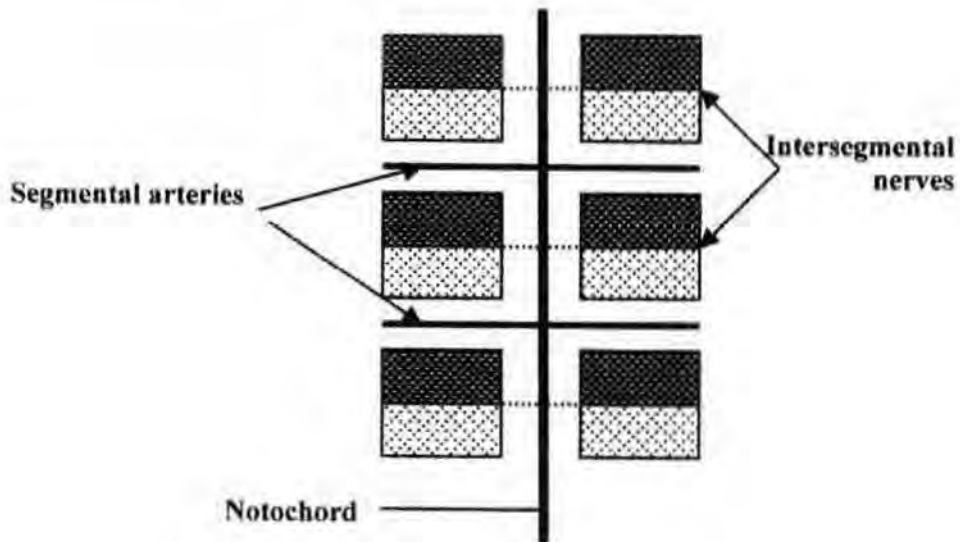
**Figure 2.4 Somite formation has begun (by R. B. McNaught 2003)**

The cranial half of each somite migrates, as does the caudal half of each adjacent somite, uniting to form the embryonic hemi centra. In this new development intersegmental vessels become segmental vessels and segmental nerves become intersegmental nerves (Fig. 2.5). This migration and evolution of the ectoderm and mesoderm from their primordial state form the first true elements of the vertebral column (Polin and Fox 1988: 2365).

(v) Weeks 6 and 7

Each of the centra sits anteriorly to the osseous ring, which in the neonate comprises of two symmetrical parts; each consists of a lateral pedicle connected to the posterior

process by a narrow osseous bridge which forms the bony protection around the spinal cord (Scheuer and Black, 2004: 189).



**Figure 2.5 Somite formations showing the position of nerves and vessels**

(vi) Week 8

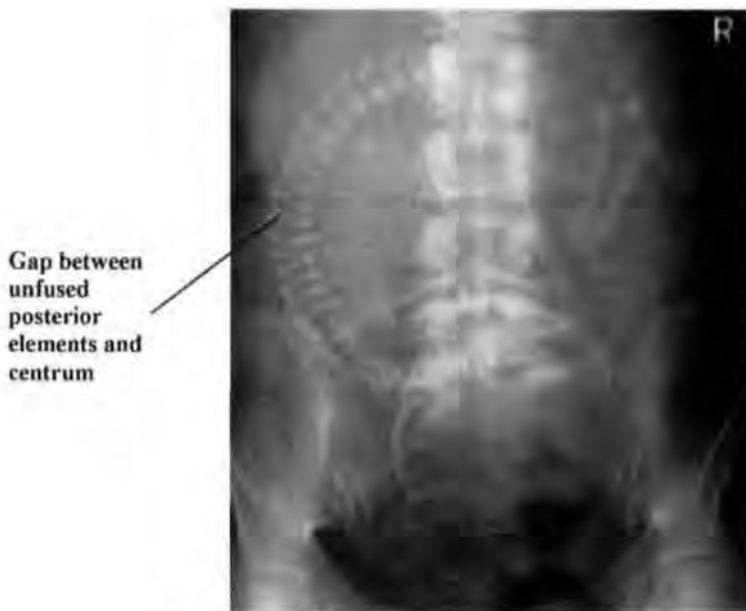Regression of the notochord from within the centra begins as the cartilaginous centra forms, with the remnants of the notochord swelling in the spaces between the centra forming the nucleus pulposus of the intervertebral discs (Wilson and Maden, 2005).

(vii) Week 9

Embryonic development is almost complete and the foetal period about to begin. As the intervertebral discs begin to form, the major organs evolve and the axial skeleton completes its prenatal structuring.

2.2.2 Foetal development: week 10 to birth

During the 10<sup>th</sup> to 12<sup>th</sup> week perichondral, ossification of the lamellae of the posterior neural arches commences (Scheuer and Black, 2004: 188). At twenty-six weeks, should the foetus be expelled from the uterus in spontaneous abortion, it can with great care survive independently of its host or mother (Moore and Persaud, 2003: 83). Twenty-six weeks is the point in foetal development when all organs are formed, but are not necessarily capable of self-function. One example are the lungs which, although fully formed, are still wet and need oxygen until the mucous membranes have dried sufficiently for the alveoli to function independently, causing spontaneous respiration.

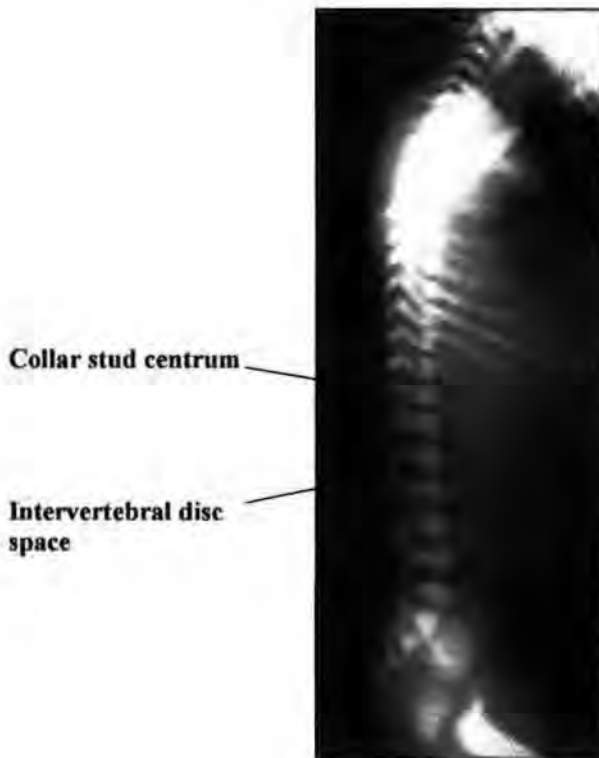


**Figure 2.6** Eight -month old foetus showing vertebral bodies and unfused posterior elements (Pinderfields Hospital teaching archive)

During the third month of embryonic life the primary centres of ossification occur. The primary centres of ossification appear as ‘knots’ along the notochord. Ossification commences at the level of the twelfth thoracic vertebra, continuing cranially and at the first lumbar vertebra, and continuing caudally until all thirty-three vertebrae are present (Schmorl and Junghanns, 1971: 3). Plain film radiographic imaging (Fig. 2.6) of the foetus during the eighth month shows the bodies of the vertebrae as clearly recognisable

radiolucent discs. Intervertebral discs form from the notochord and surrounding sclerotomes, the nucleus pulposus forming out of the notochord swellings between the centra, and the annulus fibrosus from the sclerotomes within the mesoderm (Herkowitz, *et. al.*, 1999: 11).

### 2.2.3 Neonatal vertebral column



**Figure 2.7 Lateral neonatal spine radiograph showing almost equal height of intervertebral discs and vertebrae (from the Pinderfields Hospital teaching archive)**

At birth, the vertebrae are separated by intervertebral discs each taking up equal space within the vertebral column and sharing epiphyses or growth plates (Fig. 2.7). The end plates are closely bound to the intervertebral discs by many Sharpeys fibres (Prescher, 1998: 3). Each vertebral body has a distinct waisted appearance in a lateral radiographic image, which can be likened to a “collar stud” in size and shape (Fig. 2.7). The “waists”

of the vertebral bodies are caused by the vascular channels passing horizontally at the levels of fusion of the paired somites. These remain visible until complete ossification has taken place (Schmorl and Junghanns, 1971: 4), although remnant holes are occasionally seen in adult vertebrae.

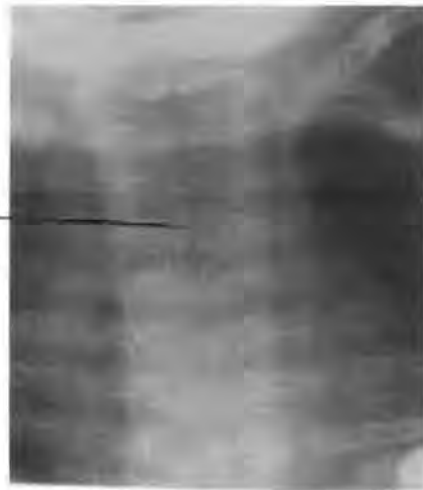#### 2.2.4 Ossification and fusion of the vertebral elements

In a normal neonate, all elements of the adult vertebrae are represented in either bone or cartilage. The transition from cartilage to bone produces the single bony structure of each vertebra. Fusion of the integral parts of the vertebrae commences between one and two years of age with the hemi-spinous processes being the first to unite. Last to form and unite are the mamillary processes; these appear at approximately the seventeenth year of growth and fuse by the nineteenth year.

##### (i) The neural arch

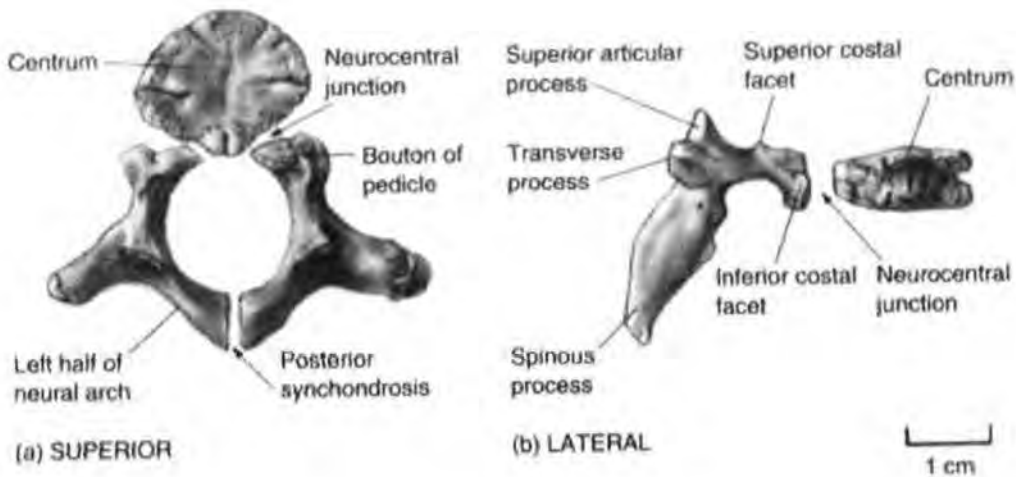
The two halves of the neural arch (Fig. 2.8) commence fusion at the lower border of the posterior spinous processes, and complete fusion occurs when the upper borders have calcified as one posterior spinous process. The process follows the same sequence as the early cartilaginous formation of the centra along the notochord, beginning at the lower thoracic and upper lumbar region, and continuing cranially and caudally until ossification has taken place along the whole vertebral column. The only exception is the fifth sacral segment, which remains unfused and forms the sacral hiatus (Gunn, 2002: 163).

Black line is the space between the bifurcated spinous processes



**Figure 2.8 Radiograph of a three-month-old baby showing posterior spinal processes prior to union (from Pinderfields Hospital teaching archive)**

(ii) Union between the neural arch and centrum



**Figure 2.9 Constituent parts of a 1-2 year old vertebra (from Scheuer and Black, 2004)**

Fusion of the lateral pedicles to the centrum is indirect with the anterior 'bouton' (a small button like growth) growth of the pedicle forming the union. It is with the 'bouton' that the posterior rib ends articulate and not the centrum or vertebral body (Fig. 2.9). This union begins during the second year of life and is complete by the fifth to sixth year of life. The process of fusion starts at the superior borders of the centrum and boutons and ends at the inferior borders of the boutons (Scheuer and Black, 2004: 194).

The thoracic vertebrae are the last to unite, forming miniature versions of the adult vertebrae excepting for the mamillary processes which appear much later in the final growth period.

(iii) End plate union

Union between the epiphyseal end plates and the vertebral body begins at 17 years of age and is complete by 18 years of age. This fusion takes place only when vertical and horizontal growth of the vertebral body is complete (Lusted and Keats, 1972: 512-517).

(iv) Secondary centres of ossification

There are a total of nine mamillary processes in a vertebra which include the epiphyseal rings of the vertebral bodies. The other secondary centres are situated at the superior and inferior edges of the lateral pedicles and at the posterior edge of the spinous process. This group of secondary centres appear at 12 to 16 years of age and commence fusion at 19 years, with all fusion completed by the 25<sup>th</sup> year (Scheuer and Black, 2004).

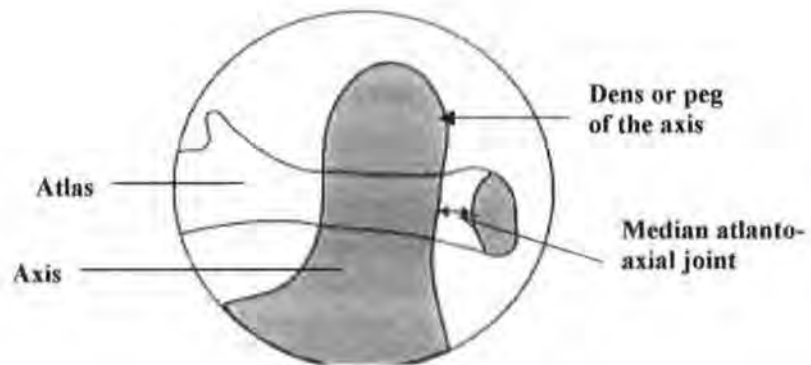
At the moment of birth the neonate is seen to be the perfect product of heterosexual union, without a visible flaw. Using the latest design in baby transport, the pushchair with a sloping back, allows the infant to rest with the spine curved and fully weight bearing, the head only supported by a soft surround. However, if vertebral and intervertebral disc compression occurs before complete ossification has occurred this may be the precursor of spinal problems in the present and future. Throughout life, constant usage of our joints causes wear and tear and, with ageing, degenerative and destructive changes takes place. It is not always those who have undertaken manual labour who show the greatest joint alterations, so genetic factors may have a role to play

(Richard *et al.*, 2005). Alterations to bones, joints and soft tissues by diseases and disorders impact upon our ability to have a full and active lifestyle (Kop *et al.*, 2005).

### 2.3 Anatomy of the adult vertebral column

Each of the vertebrae have similar characteristics (Gunn, 2002: 145-146), the body or centra, lateral pedicles, posterior process or spine, superior and inferior articular processes and the pars interarticularis; each group of vertebrae also have individual structural and functional differences. The body consists of a core of cancellous bone overlaid on all surfaces by a layer of cortical bone, with the body having an increasing depth and transverse diameter as the vertebral sequence is observed cranio-caudally.

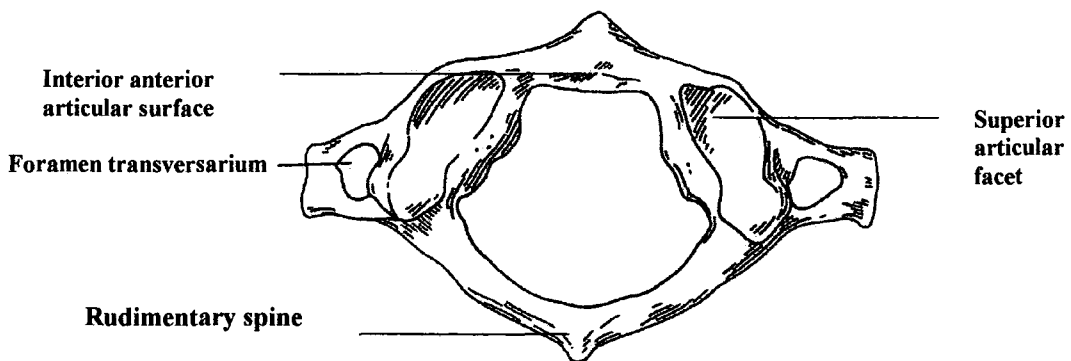
#### 2.3.1 Cervical vertebrae



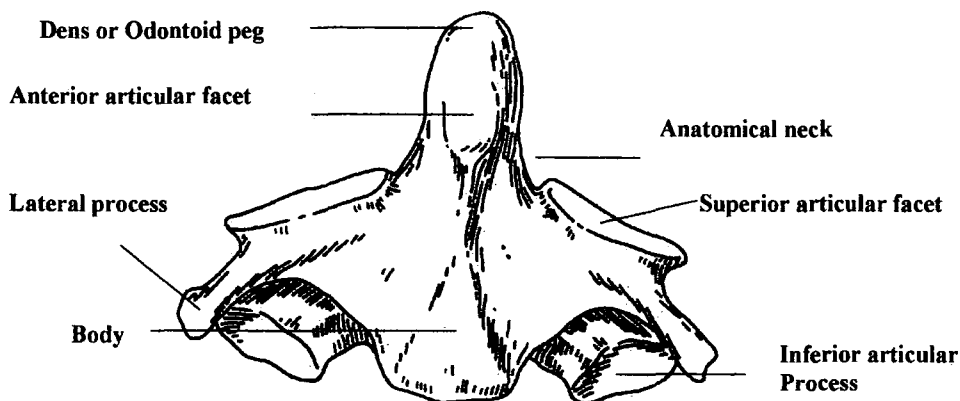
**Figure 2.10 Anatomically correct position of the peg of the axis and the interior anterior ring of atlas (from Raby, 2001)**

There are seven cervical vertebrae, which are commonly referred to as the “neck”. The cervical vertebrae have three vertebral variants:

(i).The first cervical vertebra (Fig. 2.11), or ‘atlas’ has no body and comprises two lateral masses united by the anterior and posterior arches and forming a bony ring (Gunn, 2002: 150-152). Both the superior and inferior articular processes are part of the lateral masses, with the superior articular facets forming the occipito-atlas articulations. Anteriorly and interiorly sits the articulation to which the dens of the axis is attached by the transverse ligament (Fig. 2.10).



**Figure 2.11 Superior view of the atlas (by R. B. McNaught, 2005)**



**Figure 2.12 Anterior view of the axis (by R. B. McNaught, 2005)**

(ii). The second cervical vertebra, or ‘axis’, consists of a body, two lateral pedicles and a posterior spinous process; bony bridges or laminae unite the lateral pedicles and

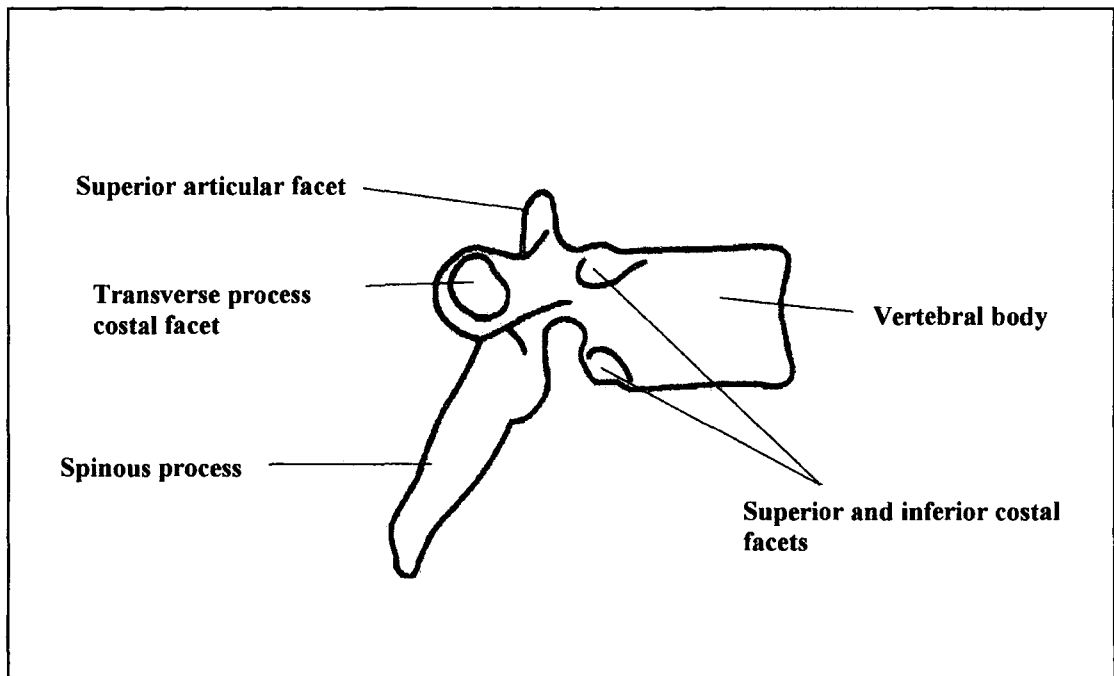
spinous process. Sitting on the superior surface of the second vertebral body is the odontoid process or peg (Fig. 2.12) with the anterior surface articulating with the inferior anterior surface of the atlas and acting as the body of the atlas (Raby, 2001). This anterior joint is known as the median atlanto-axial joint (Fig. 2.10) and is the most significant joint within the vertebral column; trauma here can disrupt the spinal cord, causing death (Berman *et.al.*, 2001: 1070-1079; Scheuer and Black, 2002: 202).

(iii). The seventh cervical vertebra is similar in shape to the 3<sup>rd</sup> to 6<sup>th</sup> cervical vertebrae except for the posterior spinous process which is much longer and not bifid. Landmarks on the body surface are useful anatomical markers in clinical examination and the posterior spinous process of this vertebra makes a clear skin or surface marker (Palastanga *et al.*, 1998: 592-593). The transverse foramina are often absent in this vertebra and, when present, do not contain the vertebral arteries. Occasionally the lateral processes continue to grow and become cervical ribs.

Cervical vertebrae three to six inclusive have all elements in common: an oval body, lateral pedicles, a pair of laminae and a posterior spine. The vertebral body is waisted in the vertical dimension. Each lateral pedicle projects backwards and upwards from the postero-lateral aspect of the body. Each of the laminae projects backwards in an arc to form half of the posterior ring; these laminae unite and terminate in a bifid posterior process. Medial to the lateral pedicles are the transverse foraminae, which contain and protect the vertebral arteries; enclosed and protected by the laminae in the space known as the posterior neural arch is the spinal cord.

### 2.3.2 Thoracic vertebrae

The normal number of vertebrae in the thoracic spine is twelve; these twelve vertebrae form the primary concave (anterior) curve (Fig. 2.1). Together with the ribs, sternum, clavicles and scapulae, the thoracic spine forms a protective bony cage, which encloses the heart, lungs, trachea and oesophagus. Each of the thoracic vertebrae has a heart shaped body with each vertebra increasing in diameter and depth when examined cranio-caudally.



**Figure 2.13 Lateral view of a thoracic vertebra (R. B. McNaught 200**

Anatomically the presence of costal articular facets distinguishes these vertebrae from the cervical and lumbar vertebrae. Each lateral pedicle carries a shallow costovertebral facet for articulation with the ribs; these lateral pedicles become shorter the further caudally they sit in the thoracic spine. Variation in the posterior spinous processes is marked with the upper spinous processes being narrow, long, protruding and almost horizontal, with the third to tenth having the same profile and angling inferiorly (Fig. 2.13), and the eleventh and twelfth being shorter, greater in depth and more representative of the lumbar spinous processes (Schmorl and Junghanns, 1971: 586-92).

Occasionally there is a thirteenth thoracic or sixth lumbar vertebra. Several thoracic vertebrae have individual anatomical differences:

(i) The 1<sup>st</sup> thoracic vertebra has complete superior costal facets articulating with the first pair of ribs, and semicircular inferior facets at their caudal edge articulating with the upper edges of the second pair of ribs (Fig. 2.13).

(ii) The 9<sup>th</sup> thoracic vertebra may have no inferior articular facets present.

(iii) The 10<sup>th</sup> thoracic vertebra occasionally articulates alone with the 10<sup>th</sup> ribs; the costal articular facets are oval and the lower facets are absent.

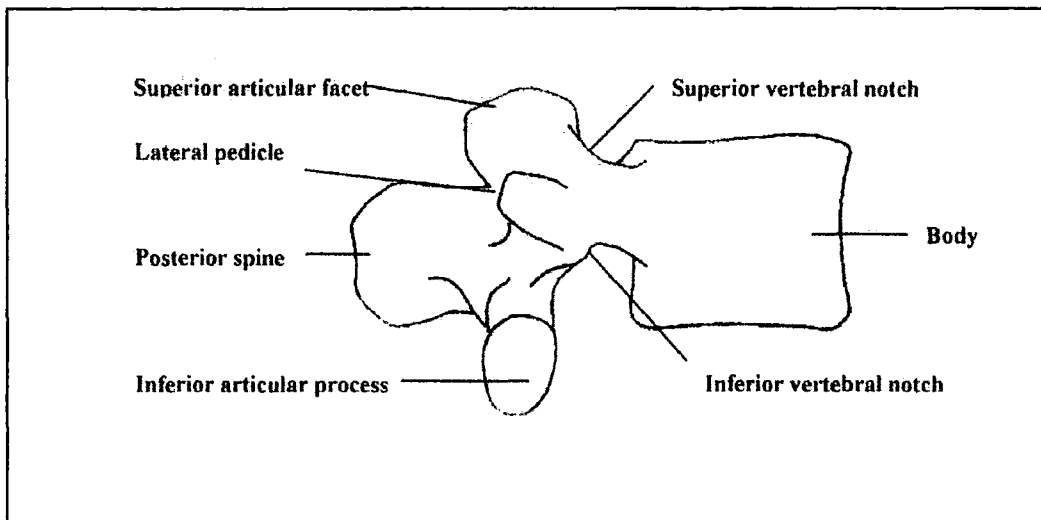
(iv) The eleventh thoracic vertebra has complete articular facets and no lower articular facets. The small lateral pedicles do not have the small costovertebral joints which are present in the other thoracic vertebrae.

(v) The 12<sup>th</sup> vertebra articulates with the twelfth ribs, the articular process sitting lower down the body and no caudal costal articular facets being present. The lateral pedicles are small and have no costovertebral facet.

### 2.3.3 Lumbar vertebrae

Usually five in number, this group of vertebrae form the lumbar curve which is markedly concave posteriorly (Fig. 2.1) when viewed in the sagittal plane. A sixth lumbar vertebra is occasionally present; this may be a genetic variation and does not appear to be related to the height of the full-grown adult as would be expected (Papagelopoulos *et al.*, 1998). The vertebral bodies each gain in depth and diameter the

further down the lumbar region they are situated. All spinous processes are square in the vertical plane and sit horizontally (Fig. 2.14) that is without upward or downward angulations (Bogduk, 1997: 4-5). Only one lumbar vertebra varies from the group; the fifth lumbar vertebra is the largest vertebra in the vertebral column being not only deeper and wider but also greater in depth. in its anterior aspect. It forms a wedge shape when viewed in the sagittal plane.

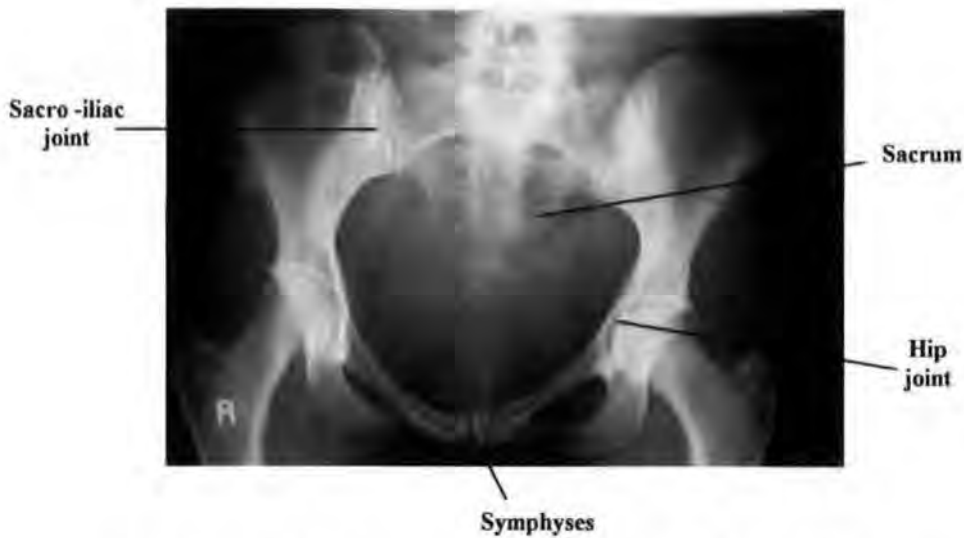


**Figure 2.14 Lateral view of a lumbar vertebra (R. B. McNaught 2000)**

#### 2.3.4 Sacrum

The sacrum articulates with the right and left innominate bones at their auricular surfaces and forms the posterior section of the pelvic girdle (Fig. 2.15). This flat bone is formed from the fusion of the five sacral vertebrae of the vertebral column. Triangular in shape, its widest part lies superiorly and its narrowest part lies inferiorly, it forms part of the second primary curve (Gunn, 2002: 161-3). On the lateral aspects of the sacrum are the kidney shaped auricular facets (Fig. 2.16), which articulate with the ilia of the innominate

bones, forming the sacro-iliac joints (Fig. 2.15).



**Figure 2.15 Adult pelvis (from the Pinderfields Hospital teaching archive)**

The superior aspect of the first sacral segment articulates with the fifth lumbar vertebra, and the fifth sacral vertebra articulates with the first coccygeal vertebra, forming the sacro-coccygeal joint. In the adult sacrum, fusion of the spinous processes of the vertebrae, on the dorsal convex surface, form the central sacral crest (Fig. 2.16). Complete fusion of the lateral pedicles leaves no surface bony markings but appears as a smooth surface on the anterior concave surface of the sacrum. Between the pelvic sacral foraminae, which carry the paired sacral nerves, are the bony ridges where fusion of the vertebral bodies has occurred. Posteriorly the sacral foraminae carry the dorsal sacral nerves (Bogduk, 1997: 163-4). Observations of three further irregularities of the sacrum are as follows:

- (i.) The sacral promontory (Fig. 2.16) of the first sacral vertebral body projects out into the pelvic cavity.

(ii.) Three or four spinous tubercles sit proud of the medial sacral crest (Fig. 2.16).

(iii.) The laminae of the fifth sacral segment fail to unite, forming the sacral hiatus (Fig. 2.16).

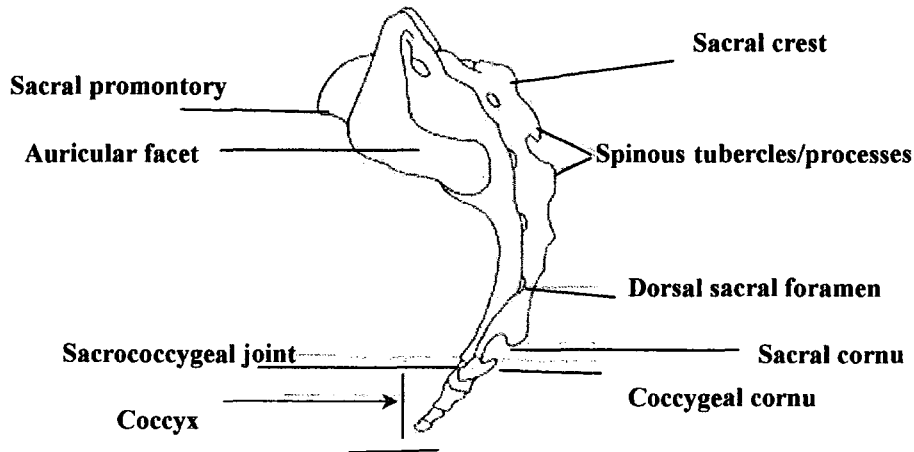


Figure 2.16 Lateral view of sacrum and coccyx

### 2.3.5 Coccyx

The inferior part of the spinal column is the coccyx (Fig 2.16), consisting of three to five vertebrae, each of which are formed by a body and two rudimentary transverse processes. These vertebrae partially or completely fuse forming the inferior part of one of the second primary curves. Curving upwards and turning anteriorly, the coccygeal cornua articulates with the inferior articular processes of the fifth sacral vertebra. In childbirth, these vertebrae can dislocate posteriorly to allow the foetal head to pass through the pelvic outlet into the birth canal.

### 2.3.6 Primary and secondary vertebral curves

Alternating curves of the adult spine in the sagittal plane (Fig. 2.1) help to retain a well-balanced vertical position. Using only small segmental alterations, the centre of gravity

within the vertebral column continuously changes during locomotion (Palastanga *et al.*, 1998: 583-4). The cervical vertebrae form a concave posterior curve, as do the lumbar vertebrae; the thoracic vertebrae form a convex posterior curve, as do the sacral segments. Viewed from the anterior aspect the vertebral column lies in a vertical line with no lateral deviation unless disruption has occurred at any part.

(i) Primary curve

The 'primary curve' is present within the developing foetus; viewing the vertebral column in sagittal section (Fig. 2.17), the cervical, thoracic, lumbar and sacral vertebrae form one continuous anterior concave curve (Scheuer & Black, 2004: 217). The thoracic anterior concave curve is retained throughout life, becoming less pronounced as the ribs, sternum and vertebrae mature and as the infant first learns to sit and then to walk. The anteriorly convex 'cervical curve' begins to form at an advanced stage of foetal development, maturing around eight weeks post partum. This is the point in natal development when the baby becomes capable of supporting and lifting its own head. This 'secondary curve' develops post-natally.

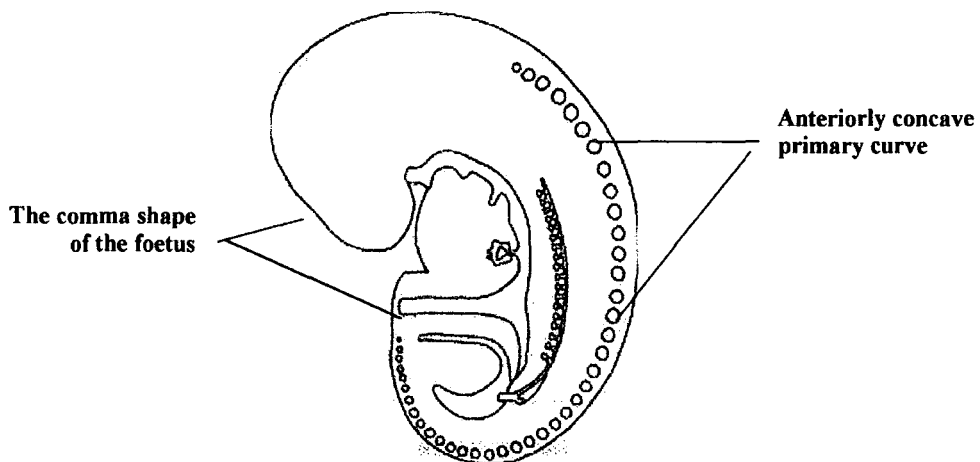


Figure 2.17 Primary embryonic curve (by R. B. McNaught, 2003)

## (ii) Secondary Curves

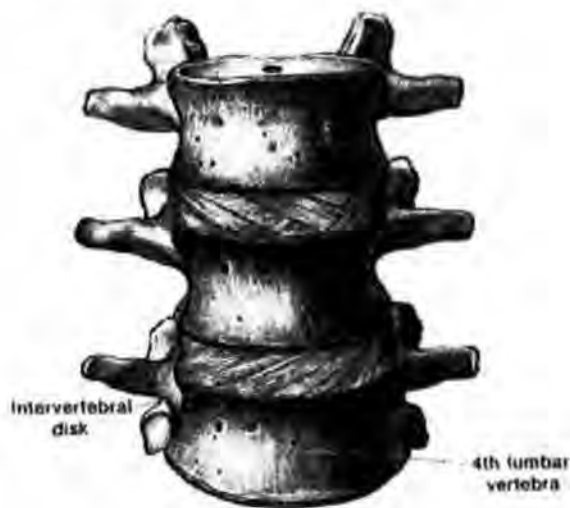The cervical spine's anteriorly convex curve is already formed at birth and is soon accompanied by the formation of the anterior convex lumbar curve. Locomotion in the bipedal child alters the vertebral column's curvature once more, as the infant strives to gain an upright stance and, initially, an unstable gait, which soon moves onto a more mature and even stride pattern. The thorax and abdomen no longer sit within the centre of gravity in this new upright position, causing the lumbar vertebrae to form an anterior convex curve to bring the torso and pelvis back within the centre of gravity (Palastanga et al., 1998: 584). The 'lumbar curve' is the second secondary curvature to form (Fig. 2.1) and is the last alteration to the primary spinal curvature. As an analogy, tall narrow buildings require downward stresses or weights to counter balance the vertical thrust of that building (usually finials) and the vertebral column has the same downward or opposing pressure placed upon it by the cranium (*ibid*, 1998: 583).

## (iii) Curvature in the elderly

One final alteration to the curvature of the vertebral column is in the elderly where the vertebral column returns to a gentler variation of the foetal anterior concave curve. This alteration in the healthy ageing adult is caused by loss of intervertebral disc height and the greater friability of the spinal discs. Fluid uptake and retention decreases the cushioning effect of the intervertebral disc but does not alter the structure of the vertebrae within the vertebral column (*ibid*, 1998: 584-5). Loss of height can be even greater if osteoporosis is an additional factor of the ageing process (Woolf & Dixon, 1998).

### 2.3.7 Intervertebral Discs

The discs originate from the remnants of the notochord during the embryonic evolution of the vertebral column, forming cushions between the vertebrae (Scheuer and Black, 2004: 186). Exceptions are the atlas and axis of the cervical spine and the coccygeal segments, which are without discs at their joints; the only separation of these vertebrae is with hyaline cartilage on the articulating surfaces of these synovial pivotal joints (Gunn, 2002: 150-151). The intervertebral discs take up one fourth of the total height of the vertebral column in the healthy adult. These intervertebral discs articulate with the vertebral bodies (Fig. 2.18) to allow rocking and twisting movements to occur where only slippage would be possible were the vertebrae alone articulating (Bridwell, 2004: 1-3). It is only when multiple vertebral bodies and discs articulate that a wide range of movement is possible; one disc working in isolation between two vertebral bodies produces only limited movement.



**Figure 2.18 Intervertebral discs articulating with vertebrae (Montgomery, 1980)**

Load bearing is the greatest stress placed upon the intervertebral disc, and the discs are thinnest in the cervical area and thickest in the lumbar area as the load of the spinal column increases cranio-caudally. Intervertebral discs vary in their anterior and posterior heights depending on the curvature of the spine within the area where they are

situated, thoracic intervertebral discs being narrowest anteriorly and widest posteriorly in the vertical plane (Palastanga et al., 2002: 447-449). A disc consists of two distinct components which provide elasticity, strength, cushioning and an ability to change profile without damage, except in exceptional circumstances.

(i) Nucleus pulposus

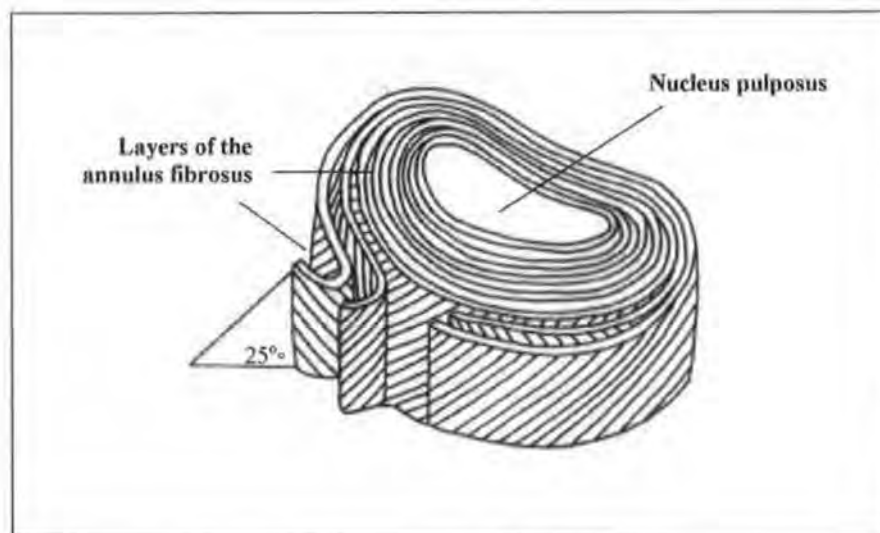
Demonstrated diagrammatically as a sphere, the nucleus pulposus sits centrally within the leaves/layers of the annulus fibrosus and is the more fluid component of the disc. It readily alters its shape within its own space, and as a fluid the nucleus pulposus cannot be compressed. The fluid within the annulus is of a flowing solid similar to toothpaste (Bogduk, 1997: 17) and not a flowing liquid. In discography, which is the visualization of the structure of the disc by the introduction of radiolucent contrast, the nucleus pulposus shows no absolute boundaries but more of a merging of its outer layer with the inner bands of the annulus fibrosus (Palastanga et. al., 1998: 636-637).

The contents of the nucleus pulposus in the healthy spine consist of approximately 80% water and proteoglycans, and a few collagen fibres. The hydrophilic nature of the proteoglycans allows the uptake of large amounts of water, and collagen gives the flowing consistency to the nucleus pulposus (Bogduk, 1997: 14-15). In later life it is the degeneration of the proteoglycans that reduces the uptake of water and makes the disc friable, reducing its mobility and load bearing capabilities.

(ii) Annulus fibrosus

The annulus fibrosus is a series of sheets or lamellae consisting of collagen fibres laid down in parallel rows (Adams et al., 2000). Each of the lamellae has its collagen fibres set at an oblique angle of approximately 65 degrees to the vertical, with each sheet

angling in the opposing direction (Fig. 2.19). These lamellae or leaves are found in dissection to be incomplete and so have weak points within them. No two lamellae are weakened or disrupted at the same point and thus the annulus fibrosus has overall strength and tenacity; this gives great resistance in twisting motions. Furthermore, the opposing angulations of the collagen fibres within each lamella resist twisting to the opposite sides, making disruption to the intervertebral disc harder to achieve.



**Figure 2.19 Intervertebral disc showing multiple layers of the annulus fibrosus  
(By R. B. McNaught, 2005)**

### (iii) End plates

The end plates of both surfaces of vertebral bodies consist of two types of cartilage (Bogduk, 2003: 14-6):

- Fibro cartilage facing the intervertebral disc
- Hyaline cartilage facing the vertebral body

Hundreds of Sharpeys fibres, or bundles of collagenous fibres attaching the intervertebral discs to the end plates, give the appearance of 'ownership' (Palastanga,

1998: 636). The close relationship of intervertebral discs, and vertebral bodies, separated only by the vertebral body endplates, acting as the stress resisting plates of the vertebral bodies, and anchors for the intervertebral discs, causes confusion as to their true anatomical relationships. The end plates of the vertebral bodies act as epiphyses during the period of vertical growth and, when imaged by radiography during adulthood, fusion appears to have taken place. Schmorl and Junghanns confirm this 'ownership' of end plate (ibid: 7) where they say that, "At the surface of the vertebral body, a layer of hyaline cartilage is found embedded between the vertebral body and the intervertebral disc, firmly united with the latter (cartilaginous plate of the disc)".

Another view by John Caffey (1945: 780-781) states that, "Each intervertebral disc contains three components: the paired cartilaginous articular plates, the fibrous ring or the annulus fibrosus, and the nucleus pulposus. In the growing spine, the paired cartilaginous articular plates are merely central superficial portions of the underlying cartilaginous mass of the vertebral body and are directly contiguous with them. In the adult spine the articular plate is composed of ordinary hyaline cartilage and lies between the end-surface of the bony vertebral body and the annulus fibrosus".

'Ownership' of the end plates is a controversial subject amongst clinicians; physiotherapists (Palastanga et al, 1998: 636) are sure that the end plates are part of the intervertebral disc while radiologists (Hauger et al, 2001; Ring and Wenger, 1994) see them as part of the vertebral body. An anatomist, who regularly dissects vertebral columns, will not commit herself to an absolute ownership of the end plate (pers comm., Dr. C. Lamb, Department of Anatomy, University of Aberdeen, 2004). A forensic anthropologist specialising in the identification and ageing of immature skeletal and soft tissue remains identifies the end plates of the vertebral column as belonging to the

vertebral body, being the unossified epiphyses of the vertebral bodies which grow vertically and transversely mimicking the diaphyses of long bones (pers. comm., Professor S. Black, 2005).

#### (iv) Intervertebral disc nutrition

Considerations of the mechanisms that provide nutrition to the intervertebral discs give a better understanding of the degeneration of the ageing intervertebral discs. No direct arterial supply or venous drainage occurs within the intervertebral discs, making them reliant upon filtration of nutrients from the vertebral bodies (Michael et al., 2002). The nutrients are supplied by diffusion through the end plates of the vertebral bodies by means of the capillary plexus, augmented by the anastomosed metaphyseal arteries of the annulus fibrosus. Each 'Junghanns segment' is a unit made up of two adjacent vertebrae, and the intervening intervertebral disc, with each movement of the vertebral column increasing or reducing pressure, on each of the segments. Movement with pressure on the 'Junghanns segment' allows the intervertebral disc to be squeezed, reducing water content and removing exhausted nutrients; altered movement reduces pressure and allows water and nutrients to infiltrate the nucleus pulposus and to a lesser degree the annulus fibrosus (Resnick, 2002: 1385-1386). The greater a person's activity, the greater the nutrient exchange between vertebrae and intervertebral discs, so as age and disease reduce spinal column mobility, reduction of nutrition with degeneration of the intervertebral disc begins (Miller et al., 1988).

## **2.4 Physiology of the adult vertebral column**

### **2.4.1 Myology of the thoracic and lumbar vertebrae**

Working in pairs, the muscles of the vertebral column stabilize movement within the vertebral column (Palastanga et al., 2002: 466-467). Extension or stretching of one of the paired muscles leads to contraction of its partner, thus rotation to the right causes contraction of the musculature on the vertebral column's right side, and relaxation/extension of the musculature on the left side. Muscle strength is dependent on the type of muscle and its internal structure:

- Sheet muscle covering large areas of the spine, rib cage and posterior viscera have good contraction properties of up to 50% of their length, but exert little power.
- Short thick muscles with an oblique arrangement of fibres exert great tensile strength with minimal contraction.
- Fine long muscles do not have great intrinsic strength, usually merging with the shorter thicker muscles.

The muscles of the vertebral column interact with each other, so that no individual muscle pairing has a single action and reaction unique to them.

(i) The multifidus muscle

The multifidus is a deep (medial) muscle sitting in the hollow between the posterior spinous processes and the lateral processes; this space is known as the "gutter". Acting as a segmental stabilizer during rotation of the thoracic vertebrae, it exerts pressure on the lumbar vertebrae, exaggerating lordosis (Bogduk, 2003: 105-108). Originating on the posterior surface of the sacrum the medial, middle and posterior layers of the

multifidus muscle engage with each vertebra of the spine from the fifth lumbar vertebra to the second cervical vertebra (axis). The multifidus laminar fibres arise on the inferior border of the posterior surface of the laminae, and insert into the mamillary processes of the lumbar vertebrae and the lateral processes of the thoracic vertebrae, two vertebrae below their origin. Posterior attachments of the multifidus laminar fibres extend to the level of the first dorsal foraminae of the posterior surface of the sacrum (Moseley et al., 2002). These laminar fibres are the shortest fascicles of the multifidus muscle. The larger fascicles of the lateral multifidus muscles arrange themselves into three layers:

- The medial group arising from the superior, posterior, iliac spine of the ilium
- The middle group from the superior, posterior, surface of the ilium immediately lateral to the sacro-iliac joint
- The dorsal group on the posterior border of the ilium, laterally and inferior to the sacro-iliac joint

Insertions of the fascicles follow a step-like progression towards the vertebral column's midline or spinous processes. The medial fascicles of the deep layer are inserted into the fifth lumbar vertebra, the middle fascicle insert into the fourth or third lumbar vertebra, and the posterior fascicles into the second or first lumbar vertebra; this is a bilateral progression with recurring insertions into the inferior postero-lateral surfaces of the spinous processes (Kavcic *et al.*, 2004). Viewed from the lateral position the multifidus muscles are at right angles to the longitudinal axis of each inferior vertebral spinous processes. Viewed posteriorly the fascicles form the hypotenuse of a triangle with the

vertebral column's spinous processes forming the vertical axis, and the base consisting of an imaginary line drawn between the inferior point of the multifidus groups and the spinous processes.

(ii) The erector spinae muscle

The erector spinae muscle is a dense, large, powerful, muscle which overlies the multifidus and has a wider, stronger base (Fig. 2.20). Attachments around the posterior elements of the pelvis give great strength to the lumbo-sacral junction. Arising from a wide, flat, strong, tendon which curves around the origin of the multifidus, the erector spinae divides into three parallel, strong, well defined bands, each of which subdivides into regional fascicles (Hjortskov et al., 2005):

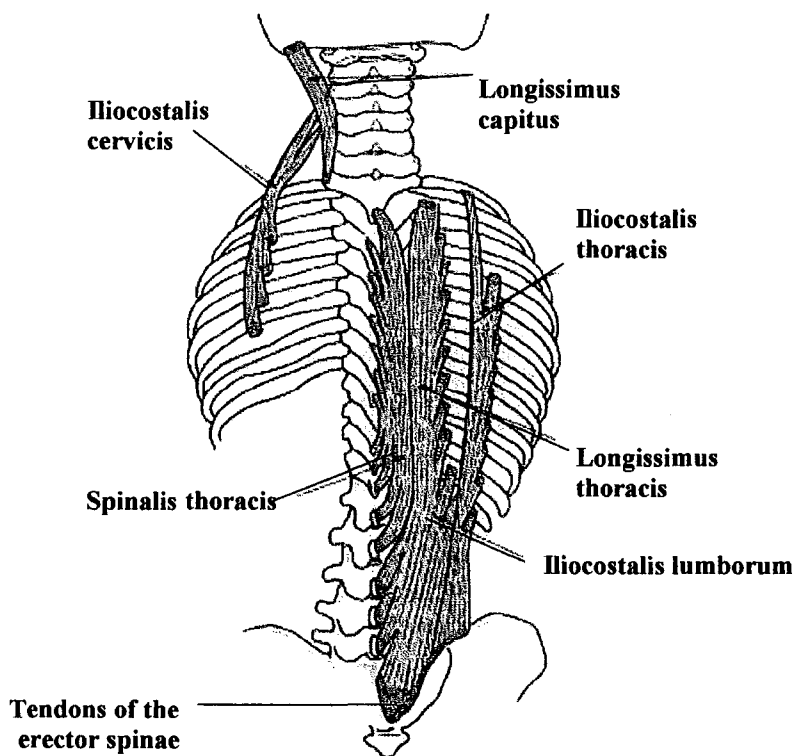


Figure 2.20 Erector spinae showing tendons and fascicle divisions (from Palastanga et al, 2002)

(a) The spinalis is the least effective of the erector spinae tri-partite structure, but as part of the whole, it helps to produce an effective, tensile, strength (McIntosh and Bogduk, 1987):

- The spinalis thoracis is the medial band stretching from the first thoracic vertebra to the twelfth thoracic vertebra, with insertions into the vertical axis of each of the spinous processes of the vertebrae.
- The spinalis cervicis is a weak muscle of the neck, interacting with and blending with other muscles of the cervical spine.
- The spinalis capitis blends and interacts with other muscles of the base of skull and cervical spine, in a weak musculature.

(b) The iliocostalis lumborum acts as a clearly defined lateral border of the erector spinae, interacting along its length with the ribs:

- The iliocostalis lumborum has insertion points along the inferior borders of the seventh to twelfth ribs. Each rib has six insertion points close to the rib's angle.
- The iliocostalis thoracis interacts with the first to sixth ribs, and the seventh cervical vertebra's transverse processes.
- The iliocostalis cervicis has insertion points on the posterior edge of the transverse processes of the fourth to seventh cervical vertebrae.

(c) The longissimus spans the length of the thoracic and lumbar portions of the vertebral column and contains the densest fascicles of the erector spinae

(Lee *et al.*, 2005). Each vertebra interacts with this column of the erector spinae:

- The longissimus thoracis does not, as its name suggests, only interact with the thoracic spine but also with the lumbar vertebrae (Kowalski *et al.*, 2005). The longissimus thoracis has insertion points on the posterior aspect of each of the lumbar vertebra's accessory facets of the transverse processes. Each thoracic vertebra and its articulating rib have one or two insertion points at the level of the costal facets.
- The longissimus cervicis arises from the lateral processes of the first to fifth thoracic vertebrae, and inserts into each of the transverse processes of the second to seventh cervical vertebra.
- The longissimus capitus arises from the transverse processes of the first to fifth cervical vertebrae, and inserts into the mastoid process.

(iii) The interspinales muscle

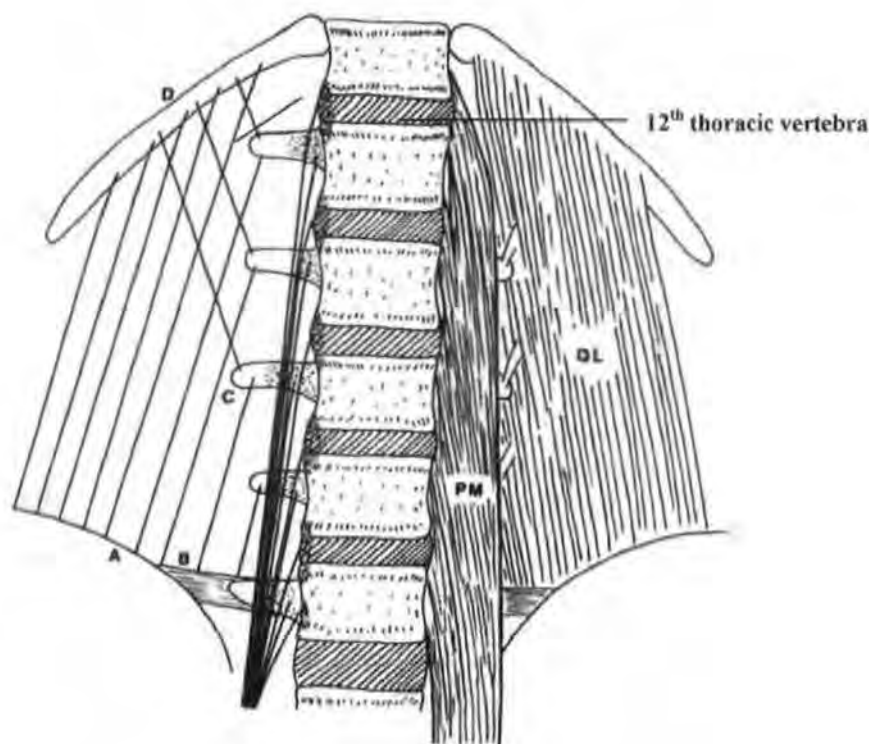
The fascicles of the interspinales span the spaces between the superior border of the inferior vertebra's spinous process and the inferior border of the superior vertebra's spinous process (Jorgensen, 1997). The interspinales sit laterally to the interspinous ligament and exert little tensile strength.

(iv) The quadratus lumborum muscle

The quadratus lumborum is a large flat muscle surrounding and supporting the organs of the abdomen posteriorly, and blending with the iliocostalis and longissimus, fascicles

off the erector spinae (Leetun et al., 2004). The common points of insertion into the ribs and lateral pedicles of the vertebrae (Fig. 2.21) allow the muscles to intertwine becoming a complex structure where clear muscular borders are lost (Daggfeldt et al., 2000). Stability of the lumbar spine in lateral extension is aided by the quadratus lumborum, therefore requiring its inclusion with the muscles of the vertebral column.

(v) Psoas major muscle



**Figure 2.21 Psoas major (PM) and quadratus lumborum (QL) showing their points of attachment to the vertebral column. The PM attaches antero-laterally to the vertebral margins, transverse processes and intervertebral discs. The QL attaches to the twelfth rib (D), iliac crest (A), transverse processes (C) and iliolumbar ligament (B). (From Bogduk, 2003)**

The psoas major muscle controls flexion of the hip with insertions antero-laterally to the vertebral bodies, intervertebral discs and the lateral pedicles of the lumbar vertebrae.

This muscle passes over the upper border of the pelvic ramus and inserts into the lesser trochanter of the femur. Acting in conjunction with the abdominal muscles, the psoas major is the muscle in control of the body's movement from a supine to sitting position. The psoas major exerts great pressure causing anterior compression upon the intervertebral discs when raising the legs or in achieving an upright position, and must be considered as a possible cause of disruption and pain to the lumbar vertebral analage (Juker et al., 1998).

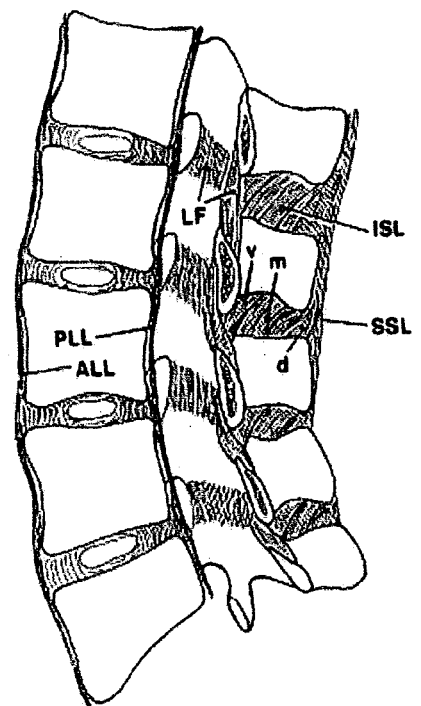
#### 2.4.2 Ligaments

Ligaments are collagen structures with a tensile strength, connecting bones and cartilage, encapsulating joints, and enclosing muscles, or interleaving muscle layer (Moseley et al., 2002). The ligaments of the thoracic and lumbar spine interact with the movements of the posterior and articular processes, controlling and limiting movement. The vertebral column is a stable structure when all the muscles, ligaments, Sharpeys fibres and intervertebral discs are intact. Sharpeys fibres are the fine filaments of connective tissue anchoring ligaments and soft tissue structures to cortical bone (Heylings, 1978). Rotation, flexion and extension of the vertebral column do not require great strength from the muscular and ligamentous structures when a person is not lifting or carrying an object of significant weight. Each motor segment as a unit of the whole column only moves slightly as part of each body movement (Palastanga et al., 1998: 660-661). The anterior and posterior longitudinal ligaments, along with the supraspinous and interspinous ligaments and several collagen bands presenting as membranes and not true ligaments, form the connections between the vertebrae and intervertebral discs of the spinal column (Hukins et al., 1990).

##### (i) Anterior longitudinal ligament

This ligament encloses the anterior parts of the vertebral bodies and intervertebral discs from the atlanto-occipital joint to the superior area of the sacrum. Almost triangular, the anterior longitudinal ligament has a single attachment to the anterior tubercle of the atlas, and widens as it moves caudally with a width across the anterior superior sacral region of approximately 25 mm (Panjabi et al., 1989). This ligament attaches itself to the superior and inferior anterior margins of the vertebral bodies, and is almost inseparable from the annulus fibrosus of the intervertebral discs (Fig. 2.22). The anterior longitudinal ligament reduces the anterior separation of the vertebrae, preventing excessive lordosis in the cervical and lumbar regions of the spinal column (Bogduk, 2002: 44-46). Anteriorly small bulges are present at the levels of the intervertebral discs between the superior and inferior anterior margins of the vertebral bodies, accentuated by the concavity of the vertebral bodies in their vertical axis (Palastanga et al., 2002).

- ALL anterior longitudinal ligament
- PLL posterior longitudinal ligament
- SSL supraspinous ligament
- ISL interspinous ligament
- v ventral part
- m middle part
- d dorsal part
- LF ligamentum flavum (viewed from within the vertebral canal)



**Figure 2.22** Sagittal section of the lumbar spine showing the ligaments (from Bogduk, 2002)

(ii) Posterior longitudinal ligament

The posterior longitudinal ligament consists of two dense layers of collagen fibres, with each layer having different lengths of fibres. The longer ligamentous fibres of the superficial layer cross several vertebral bodies at a time, merging with the annulus fibrosus of the posterior wall of the intervertebral disc, and embedding themselves into the vertebral bodies at their superior and inferior edges only (Fig. 2.22). This bony attachment comprises merged collagen fibres of both the superficial longitudinal ligament and the annulus fibrosus. The deep collagen fibres only pass from one posterior vertebral body wall to the next (Bylund *et al.*, 1987). This longitudinal ligament sits anteriorly within the vertebral foramen, anterior to the spinal cord and posterior to the vertebral bodies. Unlike the anterior longitudinal ligament, the posterior longitudinal ligament sits proud of the posterior part of the vertebral body to allow the basivertebral vein to exit the vertebral body's posterior aspect (Montgomery, 1980). Bulging of this ligament caused by extrusion of intervertebral disc material, bony fragments or vertebral dislocation impinges upon the posterior arch space but does not cause spinal cord compression unless spinal stenosis is present (Grieve, 1988).

### (iii) Supraspinous ligament

The spinous processes are covered and connected in the mid-line to the supraspinous ligament which consists of three layers of collagen. Just below the dermis lays the subcutaneous layer of collagen fibres; these fibres are long enough to cover up to four spinous processes at a time. Below the subcutaneous layer and intertwined with it is the middle layer of more robust tendon-like fibres (Palastanga *et al.*, 2002). The deep fibres of the supraspinous ligament arch anteriorly and caudally to attach to the superior borders of the inferior



spinous process acting as a tendon and having interaction with the multifidus muscle (Fig. 2.15). Unlike the anterior and posterior longitudinal ligaments, the supraspinous ligament does not contain the movement of the spinous processes; instead, it acts as a tendon and interacts with the deep muscle layers (Hytoshi *et al.*, 2003).

(iv) Interspinous ligament

This ligament has three separate layers (posterior, middle and ventral) with each layer being paired and replicating the pattern of its partner (Fig. 2.15). These fibres are recorded as having an almost vertical pattern when seen in dissection, while in radiographic imaging they run almost parallel to the long axis of the spinous processes along which they have their anchorage (Grieve, 1998). Clarification of the direction in which the interspinous ligaments lie is required if strengths and weaknesses of spinous processes are to be better understood. If vertical attachment between inferior and superior spinous processes is correct, restriction of separation of the spinous processes would be minimal. Horizontal positioning of the fibres, that is fibres running parallel to the long axis of the spinous processes, would be stronger than vertical attachments (Hytoshi *et al.*, 2003).

(v) Ligamentum flavum

The ligamentum flavum is a membranous structure running along the posterior interior part of the vertebral foraminae of the vertebral column, connecting the inferior border of each of the laminae of the vertebral foramen to the next (Fig. 2.15). There is a narrow gap in the mid-line, allowing nerves, veins and arteries to enter and leave the vertebral column (Bogduk, 2003: 46-48; Resnick, 2002:

1504). This ligament has a much greater elasticity than any other spinal ligament, allowing it to return to its normal position without folding after bending and/or rotation of the spinal column, this reduces the chances of the nerve roots being nipped or trapped.

#### (vi) Sharpeys fibres

Sharpeys fibres are the filament like fibres of ligament which attach the annulus fibrosus to the vertebral margins. Rupturing of the Sharpeys fibres by trauma, wear and tear or degeneration is believed to be the cause of enthesos formation, millimetres from the points of disruption. The rupturing of anterior Sharpeys fibres from the vertebral rim allows anterior and antero-lateral movement of the intervertebral disc material, placing pressure upon the anterior longitudinal ligament at its sites of anchorage to the superior and inferior vertebral body margins. These points of anchorage, when disrupted, are the instigators of reactive bone formation and enthesophytes (Resnick, 2002: 1397-1399).

#### 2.4.3 Tendons

Tendons are strong connecting tissues consisting of bundles of collagen fibres, but lacking the elasticity of the ligaments. The tendons, muscles and ligaments all form from the same genetic blueprint or osteogenic protein which also produces bone formation; these variations in structural composition are not clearly understood, but are known to produce strong actions, interactions and reactions with each other (Chang *et al.*, 1994). Tendons are both pliable and tough, allowing them to carry out their roll as transformers of strong muscular extension and contraction into smooth joint movement, with the ligaments containing that movement (Wolfman *et al.*, 1997). Muscles merge with tendons

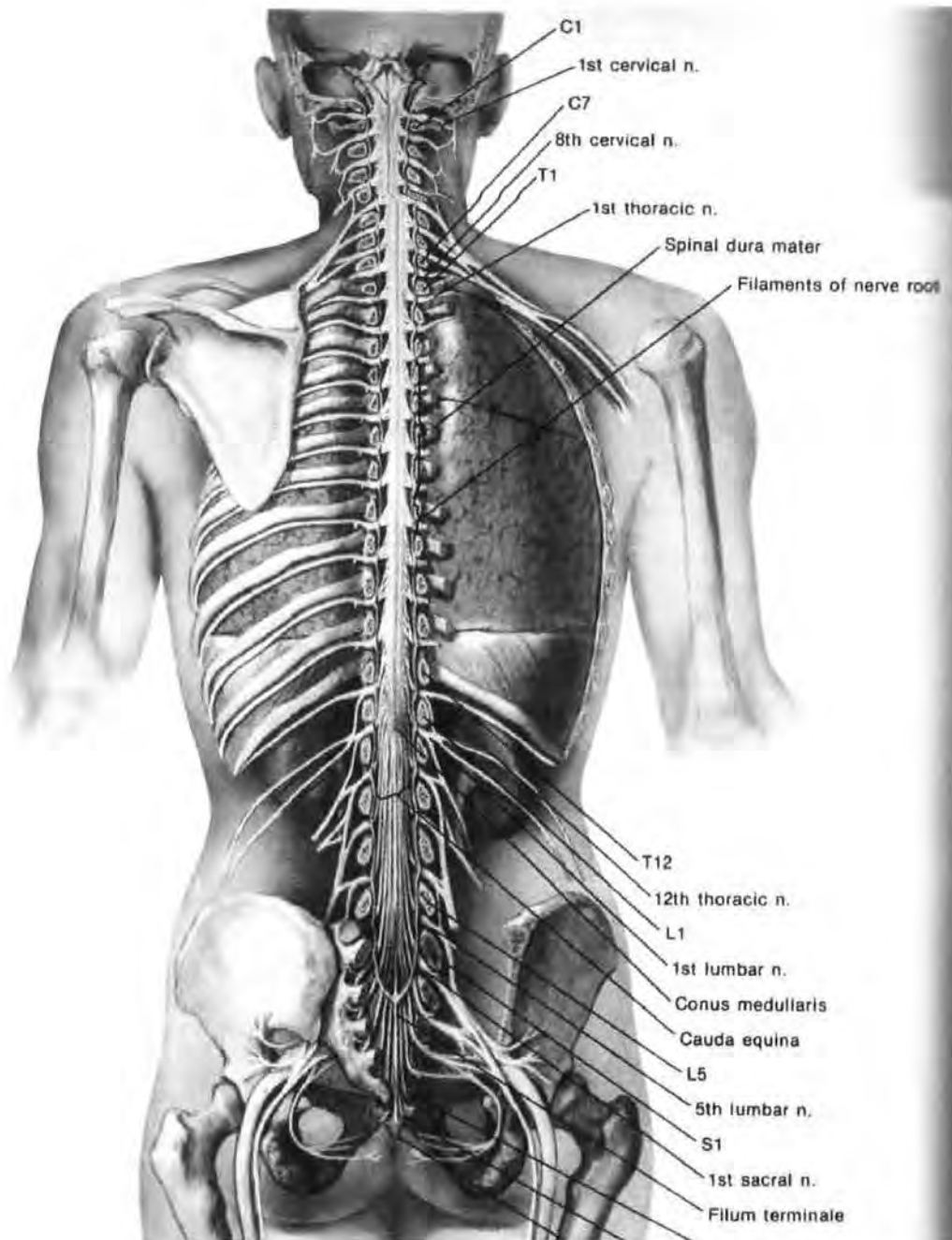
at their extremities, using the tendons to bind them to bone, close to each joint of the vertebral column. The areas of attachment are known as “insertion points”.

#### 2.4.4 Nerve and blood supply

Clinical radiography and archaeological samples when studied macroscopically look at the anatomy of the axial vertebral column, to discover whether there are associated disorders or diseases. Without an understanding of the nerve and blood supply to the vertebral column it is difficult to understand the impact of disruption to these systems when anatomical alterations are brought about by injury, disorder, or disease (Edenbichler *et al.*, 2001).

##### (i) The nerve roots

Each pair of nerve roots arise from the spinal cord and pass from within the posterior neural space through the gap provided by the superior and inferior vertebral notches. The superior articular and inferior articular facets sit anteriorly to the zygapophysial joints forming the vertebral notches. When all the vertebral zygapophysial joints are truly aligned and no stenosis of the spinal canal is present, root compression will not occur unless disruption of the annulus fibrosus and/or rupture of the nucleus pulposus place pressure upon the nerve root by lateral extrusion into the area of the intervertebral foramen (Lorenz, 1982). Spondylolisthesis of the fifth lumbar vertebra upon the first sacral segment causes compression within the intervertebral foramen as the inferior articular facet of the joint slides forward within the vertebral foramen, reducing the space and compressing the sciatic nerve (Shivonen and Partanen, 1990).



**Figure 2.23 A posterior section of the vertebral column showing the nerve roots of the autonomic and motor nerves emanating from the intervertebral foraminae (from Netter, 1986)**

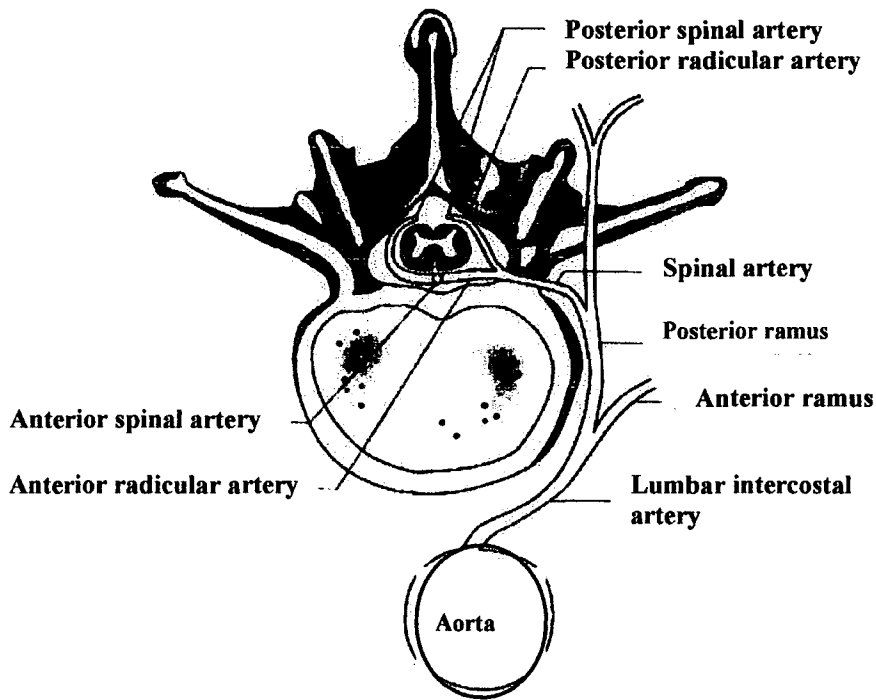
The somatic or motor nerves produce voluntary actions or movements such as grasping, bending, smiling and mastication. Autonomic nerves are the involuntary enervators, causing the heart to beat, the kidneys to excrete the diaphragm to raise and lower and every other internal organ to function (Bremner and Smith, 2006)

(ii) The blood vessels of the vertebral column

The blood supply to the vertebral column and its muscles, tendons and ligaments does not have any major vessels and receives its blood supply via radicular arteries arising from the posterior aspect of the aorta and the subclavian arteries. Venous drainage is a simple ring system fed by radices, the whole system being without valves until it passes out through the deep muscles of the vertebral column (Hempfung et al., 2005)

(a) The arterial supply

The main arteries of the vertebral column and spinal cord are the anterior and posterior spinal arteries. The anterior spinal artery and paired posterior spinal arteries are enclosed within the posterior vertebral space, close to the spinal cord. The anterior spinal artery runs the whole length of the vertebral column from the atlas of the cervical spine to the third coccygeal bone. Arterial plexuses and anastomoses carry the supply of oxygenated blood from the anterior spinal artery to the spinal cord, vertebrae and intervertebral discs (Fitzgibbon *et al.*, 1995). The first two thoracic vertebrae have their arterial drainage augmented by radicular arteries supplied by the subclavian arteries. Eight of the aortic medullary arteries supply the anterior spinal artery and the largest of these is called the Adamkiewicz. The mid thoracic area of the spine and spinal cord are supplied by collateral anastomoses which are liable to ischaemic attack should the aorta suffer damage, stenosis or aneurysm (Syed and Fiad, 2002). The posterior spinal arteries are paired vessels running the length of the posterior aspect of the spinal cord, but in certain areas, these are found to be almost non-existent, with little arterial flow being registered.



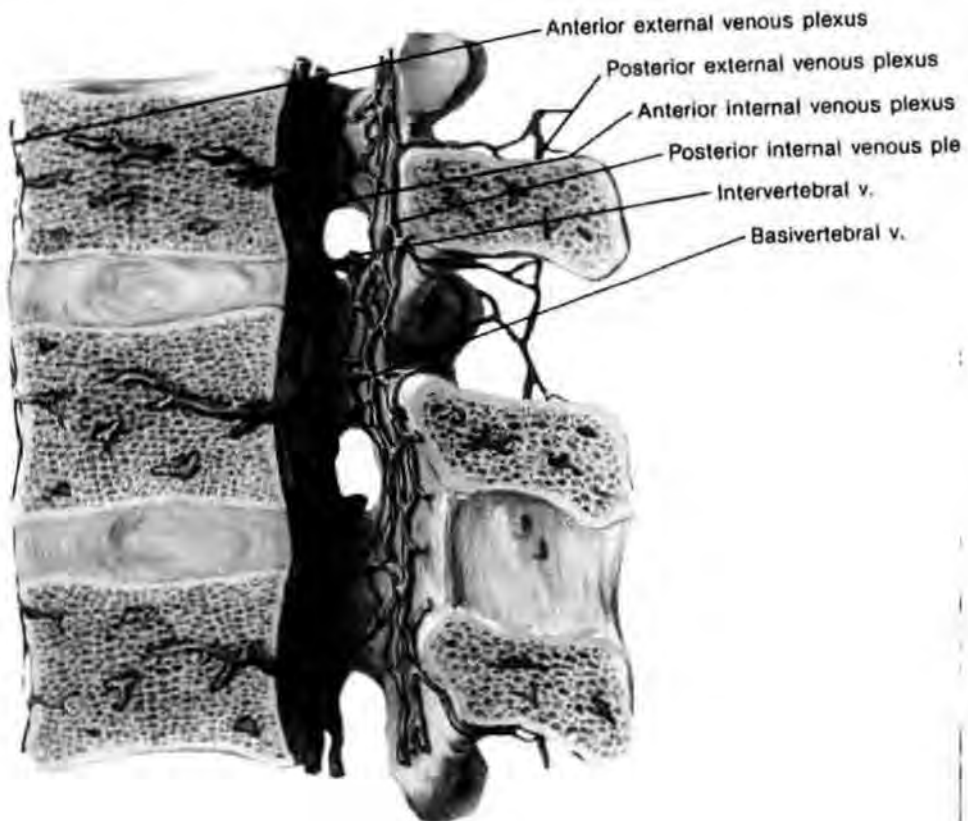
**Figure 2.24 Lumbar vertebra showing the arterial drainage of the spine (from Keyuri et al, 2004)**

Minute radicular arteries pass through the vertebral foraminae, supplying the nerve roots with oxygenated blood (Fig. 2.24). Pairs of arteries arise from the posterior aspect of the thoracic and lumbar aorta, passing through the psoas muscle to feed the musculature of the vertebral column (Suzuki *et al.*, 2003). These arteries then pass through the ligaments of the spine at the levels of the forming anastomoses to feed the vertebral bodies, zygapophysial joints, lateral pedicles and spinous processes (Fig. 2.24).

**(b) The venous drainage**

The venous drainage is unsupported by valves, as with arteries as the system consists of anastomoses and radicular veins which interact with each other at all levels. The lack of valves to contain and produce a uni-directional flow of deoxygenated blood allows occlusion to occur if the central spinal fluid alters its pressure (Popat *et al.*, 2004). Altered pressure can lead to loss of function in

the upper and/or lower limbs depending on the level of the occlusion; this usually consists of a temporary paralysis reverting when normal vascular pressure is being attained (Cheng *et al.*, 2004). Venous drainage from the vertebral bodies is by way of the basivertebral tributaries which enter the external vertebral plexus sitting anteriorly to the vertebral bodies; this vertebral plexus runs from the occiput to the third sacral vertebra. The basivertebral veins form single or double channels in the cancellous bone of the vertebral bodies with fine intervertebral tributaries, the whole emptying posteriorly into the posterior internal venous complex and anteriorly into the anterior external venous plexus (Netter, 1986: 66).



**Figure 2.25** Sagittal section of venous system of the vertebral column (from Netter, 1986: 66)

Drainage of the posterior spines, lateral pedicles and lamellae of the vertebral column is by way of anastomoses and radices which drain into the posterior

external venous plexus (Fig. 2.25). Intervertebral veins channel the de-oxygenated blood from the spinal cord through the internal and external venous plexuses, passing through the intervertebral foraminae, following the same route as the nerve roots and arterial vessels and entering the vertebral, intercostal, lumbar and sacral vertebral veins (Choi and Berenstein, 1988).

## **Chapter 3: THE VERTEBRAL COLUMN: its disorders and diseases, including associated conditions.**

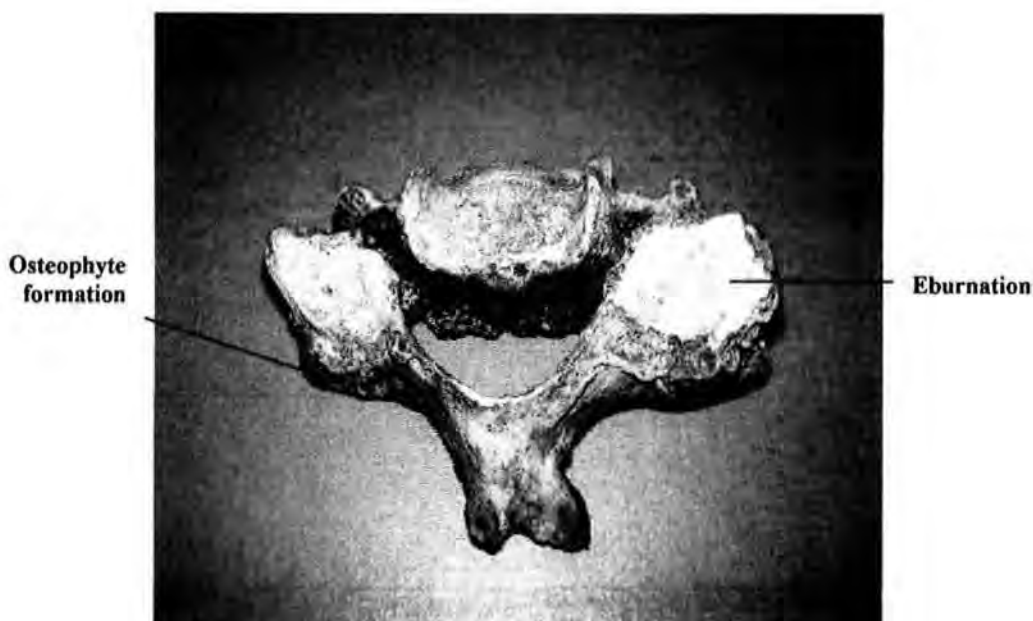### **3.1 Introduction**

The complex structures of the vertebral column have stresses and strains placed upon them during the foetal stages of gestation with every movement of limb or head. Throughout life, the almost incessant movement of the spine, even when the body appears to be at rest, causes wear and tear on a daily basis. Degenerative joint disease occurs with increasing age but can have an early onset where congenital abnormalities, trauma, and idiopathic disorders, both bony and muscular, including Schmorl's nodes, are present (Prescher, 1998). Dehydration of the intervertebral disc by reduced nutrient filtration causes shrinkage which reduces the cushioning effect it has between each vertebra, leading to osteochondrosis which, in turn, damages the end plates of the vertebra. In its final stages, not only does the nucleus pulposus become friable, but parts of the annulus fibrosus tear, allowing them to compress the nerve roots (Prescher, 1998). Schmorl's nodes may be the end result of alterations of the mechanics of the vertebral column as a result of diseases and disorders, and conditions found associated with them (Taylor, 2000). This chapter reviews these conditions and diseases, their relevance and Schmorl's nodes.

### **3.2 Degenerative joint disease of the spine**

Degenerative joint disease is associated with increasing age. Osteoarthritis is one of the most commonly reported joint diseases reported in the clinical data in this study, and this prevalence was reflected in the archaeological samples (Fig. 3.1). Osteoarthritis of the synovial joints of the vertebral column is easily detectable on radiographic images

as reduced joint space (impingement) always being reported when present in the clinical groups used for this research.



**Figure 3.1 Osteoarthritic cervical vertebra with eburnation  
(Fishergate skeleton No. 223)**

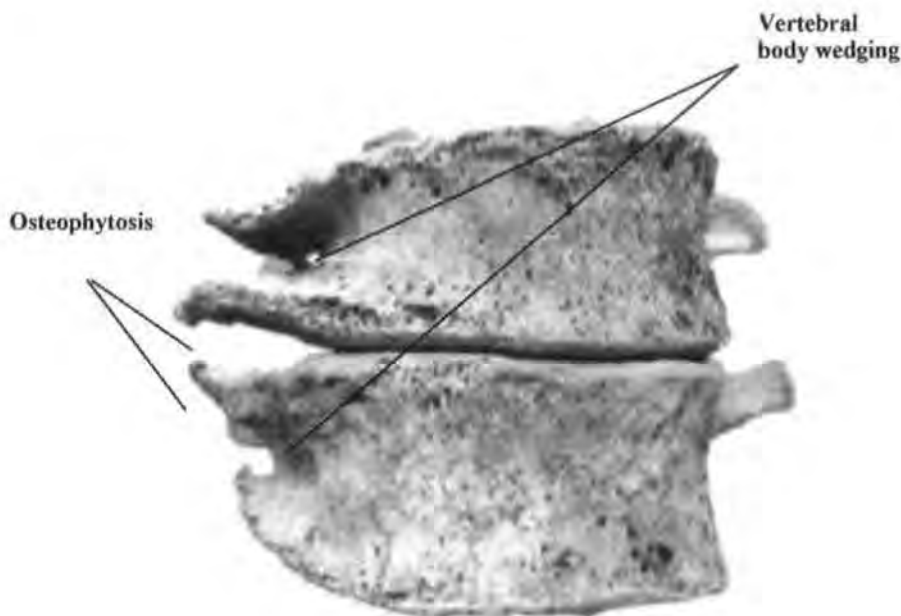
Common to this disease is the bone-to-bone contact created by the loss of the hyaline cartilaginous covering of the bones of the joint, potentially caused by increasing age, genetic predisposition and workload (Roberts and Manchester, 1995: 99). With increasing age, the function of synovial joints is compromised (Palastanga et al., 1998: 660). In clinical and archaeological diagnosis the following criteria are used;

- Osteophyte formation (clinical and archaeological)
- Articular surface pitting (clinical and archaeological)
- Alteration to joint contours (clinical and archaeological)
- Reduction of the joint space (clinical)
- Eburnation and subchondral cysts (clinical and archaeological)

3.2.1 Osteophyte formation is the body's attempt to regenerate the damaged cortical bone and strengthen the affected joint (Fig. 3.2), by forming bone (Rogers and Waldron, 1995: 8; Rogers *et al.*, 1997). In radiography, these osteophytes appear to act as osseous stabilizers, potentially reducing the range of movement (Roberts and Manchester, 1995: 101). Observation of osteophyte formation of the vertebral column shows that formation occurs around the annular epiphysis where the Sharpey's fibres of the annulus fibrosus have sheared from the end plates. Osteophyte formation commences in a horizontal plane (Rogers and Waldron, 1995: 21), and is known as "lipping" when reported in diagnostic radiography (Simon, 1975: 73). Vertical growth takes place to stabilize vertebrae in areas of the spinal column where wedging is found and where other structural disruption has taken place. This development of osteophytic bone (Fig. 3.2) can, in extreme cases, continue until fusion has occurred. Ankylosis means there is cessation of all movement within the affected joint (Roberts and Manchester, 2005: 140).

3.2.2 Articular surface pitting is caused by the small fractured parts of the degenerated surface acting as an erosive agent when caught within the joint. Each movement of the joint increases the damage to the cortical bone of the joint (Knüsel, 2000). Recent research suggests that the synovial fluid within the joint capsule can also become a bone destroyer, the bone surfaces becoming pitted, and the synovial fluid infiltrating the subchondral bone (Lubberts *et al.*, 2000). Synovial fluid is found to have a raised urea level in rheumatoid arthritis, but the connection to osteoarthritis remains tenuous (Hui, *et al.*, 1997; Agrawal *et al.*, 2004). Osteophyte formation is commonly found where articular surface pitting is present, and osteophytes may intrude into the spinal cord space and cause acute pain.

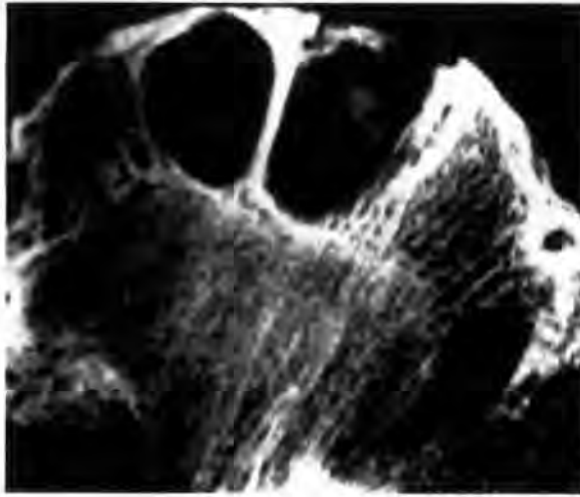3.2.3 Alterations of joint contours are directly related to the advancement of osteoarthritis, rheumatoid arthritis, and also gout; minimal wear and tear causes narrowing of the joint space and moderate changes show pitting and slight osteophyte formation (Fig. 3.1) of the bone at the joint's edges (Waldron, 2001). Osteoblastic bone formation and osteoclastic bone erosion, when minimal, are difficult to categorize, but must be noted when observed on the margins of joints showing eburnation and/or narrowing of the joint space (Rogers and Waldron, 1995). In the vertebral column osteoblast and osteoclast alterations around the vertebral body margins are believed to be caused by disruption of the bony margins by shearing of Sharpeys fibres, ligament, and tendon attachments (Benedetti *et al.*, 2000).



**Figure 3.2 Vertebrae showing osteophytosis and wedging (from Brickley *et al.*, 2005)**

3.2.4 Reduction of joint space (impingement) occurs when the natural space between the bony components of a joint are seen to be visibly reduced when radiographed for clinical classification of disease or disorder of a joint. This reduction of joint

space is caused by loss of the cartilaginous cushion within the joint (Simon, 1975: 70).



**Figure 3.3 Subchondral bone cysts in a femoral head (Pinderfields Hospital teaching archive)**

3.2.5 Eburnation and subchondral cysts (Fig. 3.3) occur when the degeneration of the joint has caused loss of cartilage and exposure of the bone. When synovial fluid is forced through the eburnated and porous cortex of the articular surfaces of osteoarthritic joint, subchondral bone-cysts are formed (Simon, 1975: 68); these cysts disrupt the trabecular pattern and cause weakness to the cancellous bone. This is clearly visible in archaeological samples using radiography. Reported in radiographic imaging as impingement or reduction of the joint space, this reduction of the joint space is accompanied by bright clear reactive cortical bone outlining the cysts on the radiographs (Resnick, 2002: 1269-1516).

### 3.3 Ankylosing spondylitis

This disease is an idiopathic inflammatory arthritis of the axial skeleton, which is associated genetically with the 6<sup>th</sup> chromosome, and biochemical studies place the HLA-B27 molecule of the 6th chromosome as present in blood in over 90% of all diagnosed cases (Vinson and Major, 2003). This disease is believed to be hereditary,

affecting a greater number of males than females, and being at its most active between the third and fourth decades of life. Human leukocyte antigens (HLA) are now placed within the immunosuppressive reactive groups, and these can cause self-destruction or over reaction of tissues (Marshall et al., 2004). Surface tissue protein reactions determine which, if any, immune responses are triggered when disease, disorder or neurological changes are recognised; occasionally incorrect neurological responses cause the body to attack its own immune system, the outcome being destructive rather than constructive reaction. The active and reactive degeneration of the discs and synovial joints in ankylosing spondylitis shows as bright white areas on radiographs when discitis is present. The disrupted nucleus pulposus forms Schmorl's nodes. Osseous erosions are visible where the Sharpeys fibres attaching to the annulus fibrosus of the intervertebral disc are detached, and enthesopathies form. The final and only outcome of untreated ankylosing spondylitis is ankylosis of the spine (Renfrew, 2003: 354; Resnick, 2002: 880).

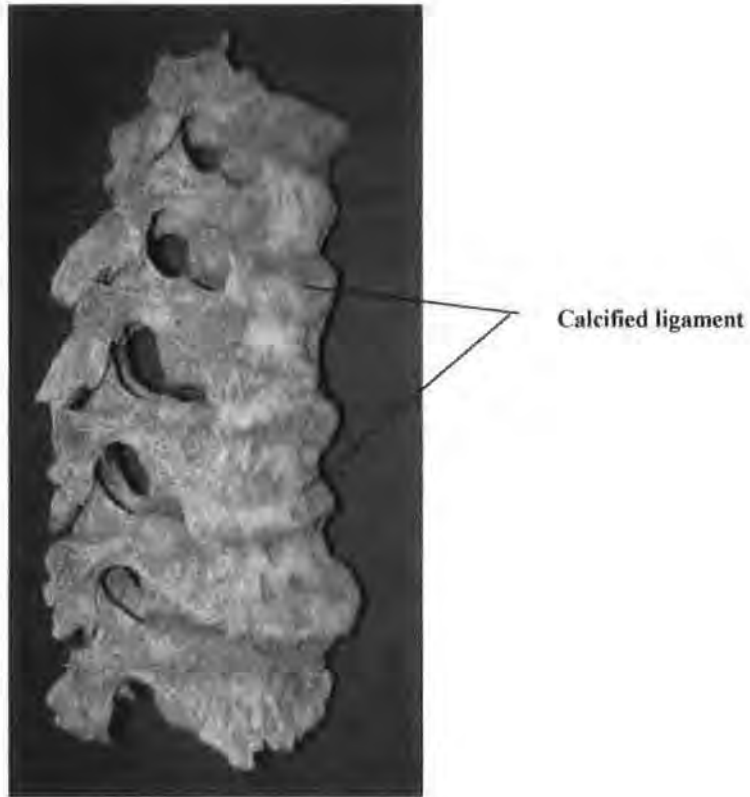
Complete fusion of the affected vertebrae where rupture and loss of the cushioning effect of the intervertebral disc has occurred, causing cortical bone loss, is not unusual. Subchondral bony cysts in the area of the apophyseal joints where ankylosis spondylitis is observed, indicate areas of weakened cancellous bone caused by the "leaking" synovial fluid. These lesions are clearly visible on radiographic images as the intervertebral discs and vertebrae show inflammatory reaction to this disease (Kurugoglu *et al.*, 2002). Ankylosis of the vertebral bodies occurs when the nucleus pulposus of the vertebral discs has ruptured and the annulus fibrosus has degenerated/disintegrated due to loss of nutrient and fluid uptake (Vinson and Major, 2003: 109). Sacral ankylosing spondylitis always involves the lateral segments of the sacrum but does not always involve the vertebral bodies, and can be mistakenly identified as

metastatic disease, tuberculosis or transdiscal stress fracture (Obradov *et al.*, 1998). Conventional plain film imaging produces a radiographic image which appears to show complete ankylosis across the joints of the sacral segments; the same sacrum screened using magnetic resonance imaging shows the lateral elements as fused and the vertebral bodies as separate elements with the exception of the annular ring, where disruption of the Sharpeys fibres has occurred (Renfrew, 2003: 354). Ankylosing spondylitis is a progressive disease with onset usually occurring in the sacral region and progressing upward through the lumbar and thoracic vertebrae in a step-like progression. Calcifications of the ligaments of the vertebral column do not have a right sided bias as is seen in diffuse idiopathic skeletal hyperostosis (Rogers and Waldron, 1995). Schmorl's nodes are observed in radiographs and MRI images where spondylosis is also observed, but at present no significance is placed on possible relationship in the clinical setting (Kurugoglu *et al.*, 2001).

### **3.4 Diffuse idiopathic skeletal hyperostosis (DISH)**

This condition can be easily identified in skeletal material (Rogers and Waldron, 1995) and it was also observed in the clinical groups in this research. Today, people suffering Type II diabetes who require insulin to stabilize their condition are found to produce unbound retinol, which affects the muscles of the eyes, the thoracic and lumbar spine (Fig. 3.4), and the pelvis (Waltuck, 2000). In the past the rich diet of the incumbents of monastic establishments is believed to be a major contributor to the high incidence of DISH found in skeletal material recovered from known monastic cemeteries (Rogers and Waldron, 2001). Diabetes is a condition associated with DISH but does not provide a specific aetiology for the disease. Diffuse idiopathic skeletal hyperostosis in the spine has the appearance of a glassy continuous covering of new bone over the right side of the bodies and pedicles of the thoracic and lumbar vertebrae involved. In diagnosing of

DISH, the clinician or osteologist would require a minimum of four contiguous vertebrae to be involved (Bassano, 2004).



**Figure 3.4 Diffuse idiopathic skeletal hyperostosis (Fishergate skeleton No. 172)**

The right side of the vertebral column becomes immobile as the paraspinal ligaments ossify along the right side of the dorso-lumbar spine. Aortic positioning along the left side of the vertebral column is thought to deter bone formation on this side, by its regular pulsation (Rogers & Waldron, 1995; 55). This condition of the soft tissues (Rogers, 2000: 171) involves the spinal column from mid-thoracic region to mid-lumbar region. The intervertebral discs are not normally reduced in height, but anteriorly the superior and inferior anterior margins of the vertebral bodies produce extra bone, which encapsulate the anterior annulus fibrosus causing a ridge within the calcified anterior longitudinal ligament. Bone formers are prone to this disease regardless of status, both past and present (Rogers *et al.*, 1997); the number of individuals affected is small, with

a greater prevalence in males. A genetic predisposition may be a factor in this disease, but as yet this is not absolutely proven (Havelka *et al.*, 2001). On the appendicular skeleton, enthesophytes can be found mainly on the calcaneum, the olecranon articulation of the radial head, the patella and the tibial tuberosity (Rogers *et al.*, 1997). Differentiation between early spinal osteophytosis, early ankylosing spondylitis, and the changes of spinal diffuse idiopathic skeletal hyperostosis is not always possible. Schmorl's nodes are observed where DISH is present in both clinical and archaeological samples.

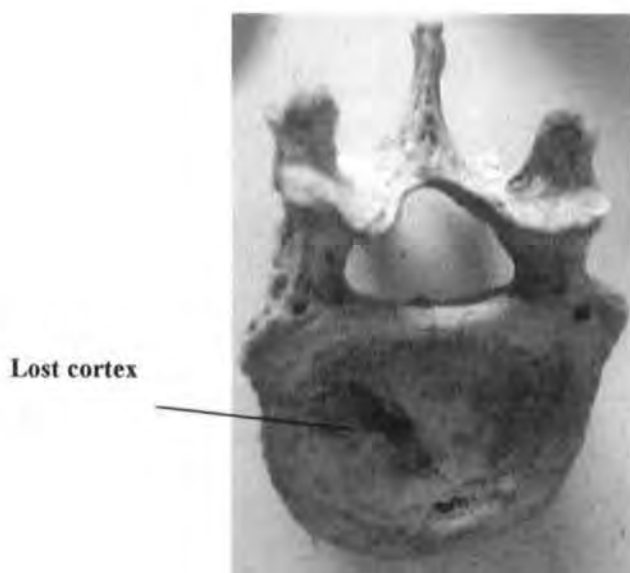
### **3.5 Osteopenia and Osteoporosis**

Mineral bone loss is observed in the skeleton where either of these disorders is present. Common to osteopenia and osteoporosis is the thinning of cortical bone and alteration to the structure of the trabeculae of the vertebral bodies (Hansson and Roos, 1983; Mays, 1998: 142-143); in healthy bone, the vertical trabeculae are braced at regular intervals by horizontal bars of trabeculae. In osteoporotic and osteopenic vertebrae, the horizontal bars of trabeculae are absent and many of the vertical structures are incomplete; when viewed on radiographic images the vertical lines of the trabeculae are clearly visible. This loss of structural form predisposes to wedging and collapse of the vertebrae following trauma/compression (Fig. 3.5) which, in the earliest stages, shows on the end plates as linear fractures (Fig. 3.6).

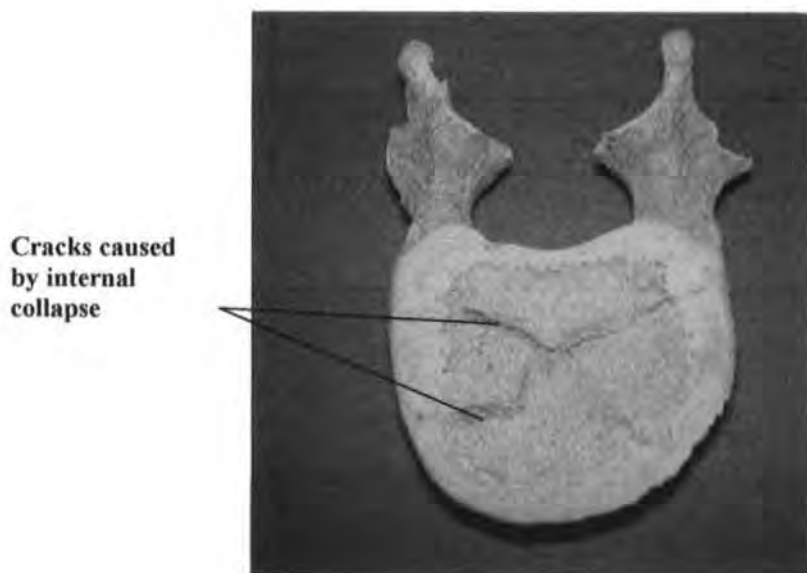
#### **3.5.1 Osteopenia**

Osteopenia is a descriptive indicator of decreased calcification or decreased bone density. This is diagnosed when vertebrae are less than normal weight and density when compared with similar vertebrae of a robust or healthy skeleton in clinical and archaeological samples. Loss of bone density has many different origins including

menopause, smoking, inactivity, hyperthyroidism osteogenesis imperfecta and lymphoma (Woolf and Dixon, 1998). In medical assessment, osteopenia is thought to be the precursor to osteoporosis and not a separate disease (Paterson *et al.*, 2001).



**Figure 3.5** Vertebral collapse from underlying trabecular destruction  
(Whithorn skeleton No. 323)



**Figure 3.6** Typical surface markings in vertebral collapse  
(Fishergate skeleton No. 144)

### 3.5.2 Osteoporosis

Osteoporosis is known to be a disease of bone caused by hormonal alteration,

malnutrition or mal-absorption of nutrients by the gut. It is most prevalent in the postmenopausal Caucasian female, but also presents within a proportion of males whose genetic predisposition and lifestyle cause metabolic and hormonal alterations (Brickley, 2000; Mays, 1998: 140-142). Reaching a diagnosis of osteoporosis requires radiography using a step wedge (radio-opaque metal strips of known density and equal thickness placed in step-like formation) for comparison, or dual energy x-ray absorption (DEXA) study (Casele *et al.*, 2006). Neither of these methods could be used because of constraints laid down by the curators of skeletal collections. Osteopenia and osteoporosis were reported within the clinical groups as a suspected, or as the known cause, of the patient's reduced vertebral density. In the archaeological samples any noticeable reduction in vertebral body density was noted but, without further analysis to prove bone mass reduction, these observations could not be included as evidence of osteoporosis.

### 3.6 Scheuermann's kyphosis

Holger Scheuermann first described this disorder in 1920 as 'osteochondritis deformans dorsi' and 'kyphosis dorsalis adolescentium', giving it recognition as a disorder found predominantly in children between the ages of 12 and 18 or the pubescent growth period (Scheuermann, 1920). Today the term 'Scheuermann's kyphosis' is still the preferred clinical name where anterior wedging of the thoracic and lumbar vertebrae produces an exaggerated thoracic curve, and an accentuated lumbar lordosis, with or without scoliosis (Ali *et al.*, 1999). The resulting exaggerated kyphosis must exceed 45° of curvature and involve a minimum of three consecutive vertebrae (Ali *et al.*, 2000).

This juvenile/sub-adult osteochondritic condition is observed on the cartilaginous surfaces of the epiphyses of the growing bone (Simon, 1975: 79), often present in the

thoracic spine, with Schmorl's nodes presenting anteriorly at the same levels (Renfrew, 2003: 73; Resnick, 2002: 3725). This inflammation shows as a roughened surface with 'bright echoes' on magnetic resonance imaging where the end plate no longer covers the anterior margins of the superior and inferior surfaces. The aetiology of this disorder remains unclear; trauma and severe physical stress have been cited as possible causes (Renfrew, 2003: 74-75; Resnick, 2002: 3727). Several vertebral and intervertebral alterations must be observed before Scheuermann's disease/kyphosis is given as the diagnosed condition:

- Reduced disc height with the nucleus pulposus intruding through the end plates causing disruption within the cancellous bone at the anterior borders (Fig. 3.7).
- Fracturing of the anterior portion of the epiphyseal rings by the force of the extruded nuclear material from the herniated nucleus pulposus of the intervertebral disc (Resnick, 2002: 3728). Sclerotic reactive bone and cartilage showing on plain film radiographic images and MRI as a bright white signal/image (Fig. 3.7) during the acute stage of osteochondritis (Adams *et al.*, 2000).
- Late in this disease the vertebral bodies involved become wedge shaped due to softening and desiccation of the anterior portion of the vertebral body (Simon, 1975: 74-82).
- A minimum of three consecutive vertebrae must be wedged anteriorly, forming an exaggerated primary curve of more than 45°, the normal thoracic curve being between 20° and 45° (Murray *et al.*, 1993).

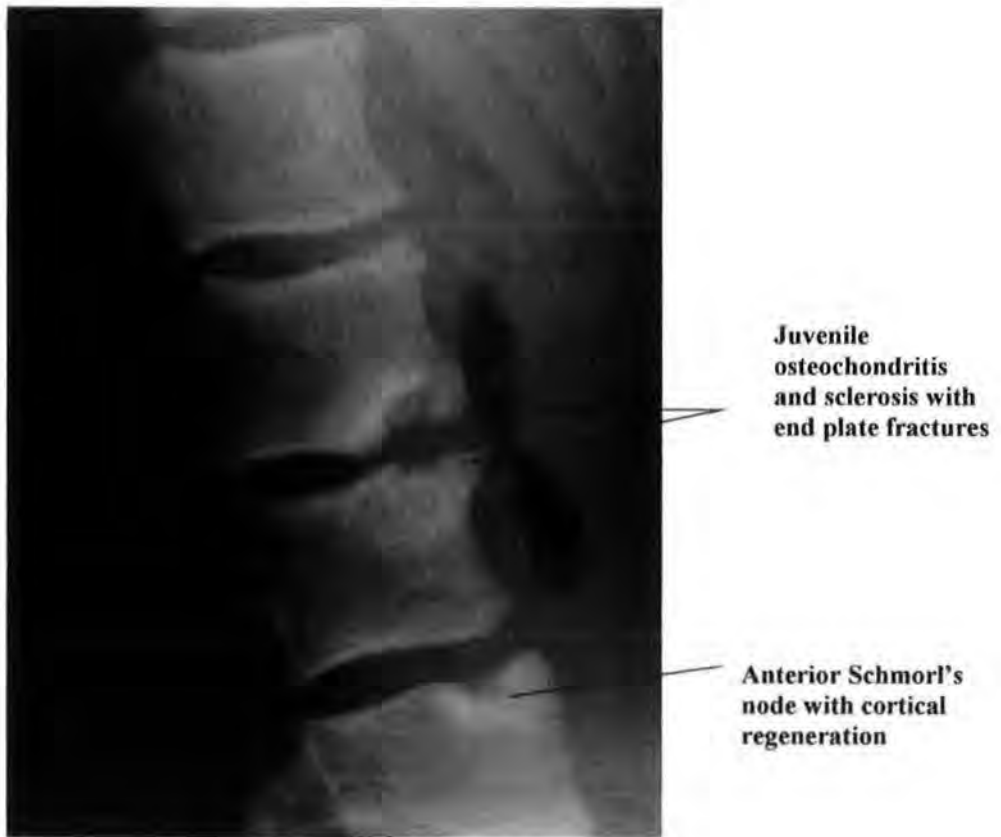
The necrotic separation and desiccation of cortical and subchondral bone caused by arterial occlusion is feature of Scheuermann's kyphosis, Perthes disease of the hip, and Osgood-Schlatter's disease of the tibial tuberosity (Roberts and Manchester, 2005: 121).

### 3.6.1 Juvenile osteochondritis

The initial response to occlusion of arteries supplying nutrition to the vertebral end plates and intervertebral discs is osteochondritis in the occluded affected area. Up to 8% of children are diagnosed with juvenile osteochondritis which may, or may not, progress to Scheuermann's kyphosis (Renfrew and Heithoff, 2003: 68-76). Juvenile osteochondritis (Fig. 3.7) may be seen incidentally during radiographic imaging of the chest before wedging of the vertebrae has occurred. This slight accentuation of the thoracic primary curve, accompanied by sclerotic end plates of the vertebral bodies is always reported to allow early referral to a paediatric spinal specialist for further examination (*pers comm.*, Suprio, 29/11/2005)

Parents of children will often not be aware of the disorder, and so may tend to ignore their child's complaint of back pain brought on by activities requiring lifting, bending, or asymmetrical sporting activities such as javelin throwing (Sathananthan and David, 1997). The highly sensitive parameters of MRI allow the radiologist to acquire images which show clearly any disruption of the anterior superior, and inferior borders, of the vertebral bodies, and intervertebral discs (Boden *et al.*, 1990). Osteochondritis, if diagnosed in its early stages can now be observed at regular intervals using ultrasound and MRI to check for possible progression to Scheuermann's kyphosis, or to its point of regression, and regeneration to healthy bone and cartilage (Kakitsubata *et al.*, 2005), thus removing the risk of cumulative doses of radiation to growing tissues and organs. Juvenile osteochondritis is used to describe the osteological and intervertebral disc

changes observed before and during the onset of Scheuermann's kyphosis in the clinical setting.

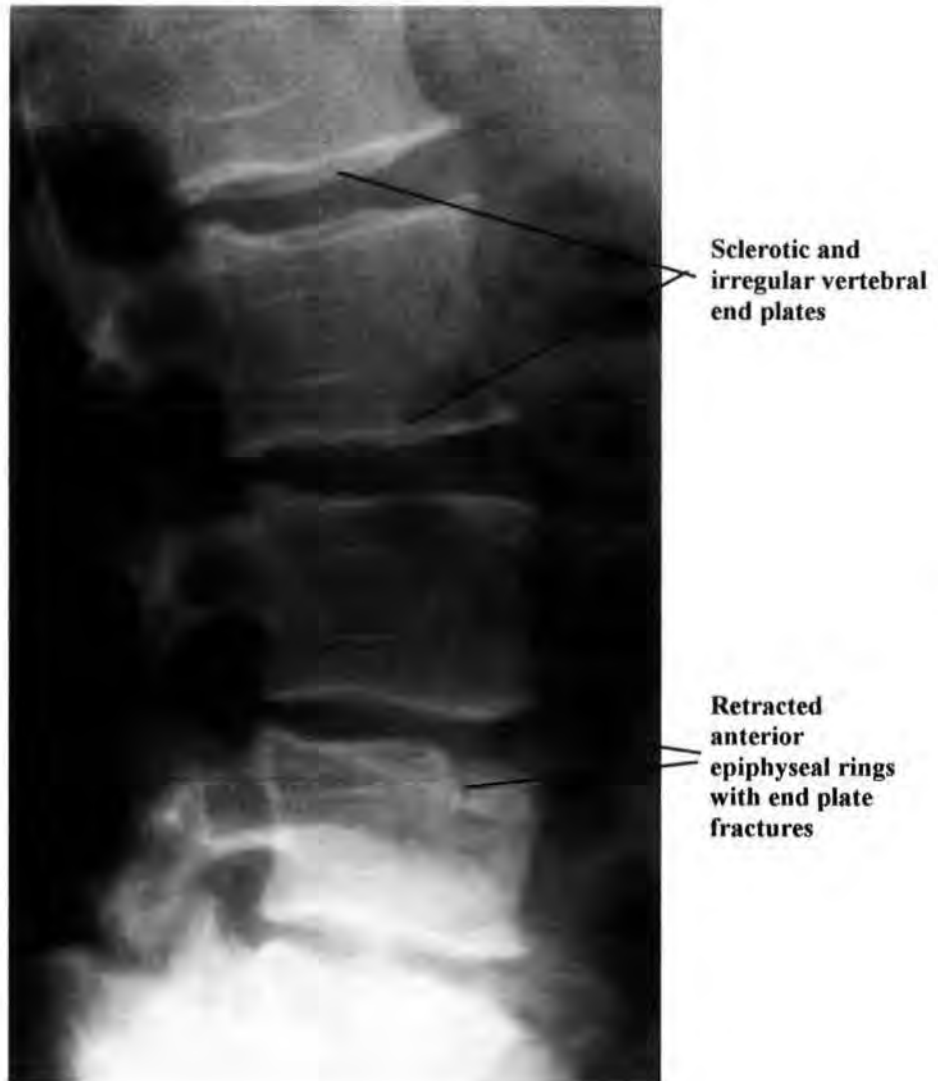


**Figure 3.7** Fourteen year old paediatric spine with active juvenile osteochondritis with sclerosis and anterior Schmorl's node with cortical regeneration (Pinderfields Hospital teaching archive)

### 3.6.2 Adult osteochondritis

Osteochondritis in the adult vertebral column involves the end plates, subchondral bone, and intervertebral discs; change is part of the natural ageing processes (Buckwalter *et al.*, 2003). The nucleus pulposus becomes much more turgid in the later decades of life as its ability to absorb water, and nutrients, decreases, reducing its ability to react as a shock absorber within the vertebral segment (Urban and Roberts, 2003). Disruption within the collagen fibres of the annulus fibrosus due to the same reduction of nutrient infiltration allows fissures to form within the lamellae causing reduced tensile strength during movement within the vertebral column (Resnick, 2002, 74: 3729). The ability the

cells of the annulus fibrosus to regenerate are lost and fragmentation begins releasing small pieces of the lamellae into the area of interaction between the vertebral end plate and the intervertebral disc (Urban *et al.*, 2004). The calcification of the end plates of the vertebral bodies at the end of the growth phase reduces the capability of the peripheral vessels to oxygenate and feed the subchondral bone of the vertebral bodies.



**Figure 3.8 Lateral lumbar spine showing sclerosis, irregular end plates, and retracted anterior epiphyseal rings with end plate fractures (Pinderfields Hospital teaching archive)**

The end plates of the vertebra appear sclerotic with their once smooth contours showing slightly roughened undulations when viewed on plain film radiography (Fig. 3.8) during the early stages of degeneration. MRI would have to be the imaging modality chosen if

the intervertebral disc changes were to be observed and recorded (Prescher, 1998; Beattie and Myers, 1998). Mild osteochondritis is the terminology used to describe early osteochondritic changes in the joints of the vertebral column when radiographic reporting is undertaken. The fragments of the degenerated annulus fibrosus erode the vertebral end plates; allowing the ruptured nucleus pulposus to infiltrate the end plates forming Schmorl's nodes when only minor trauma occurs.

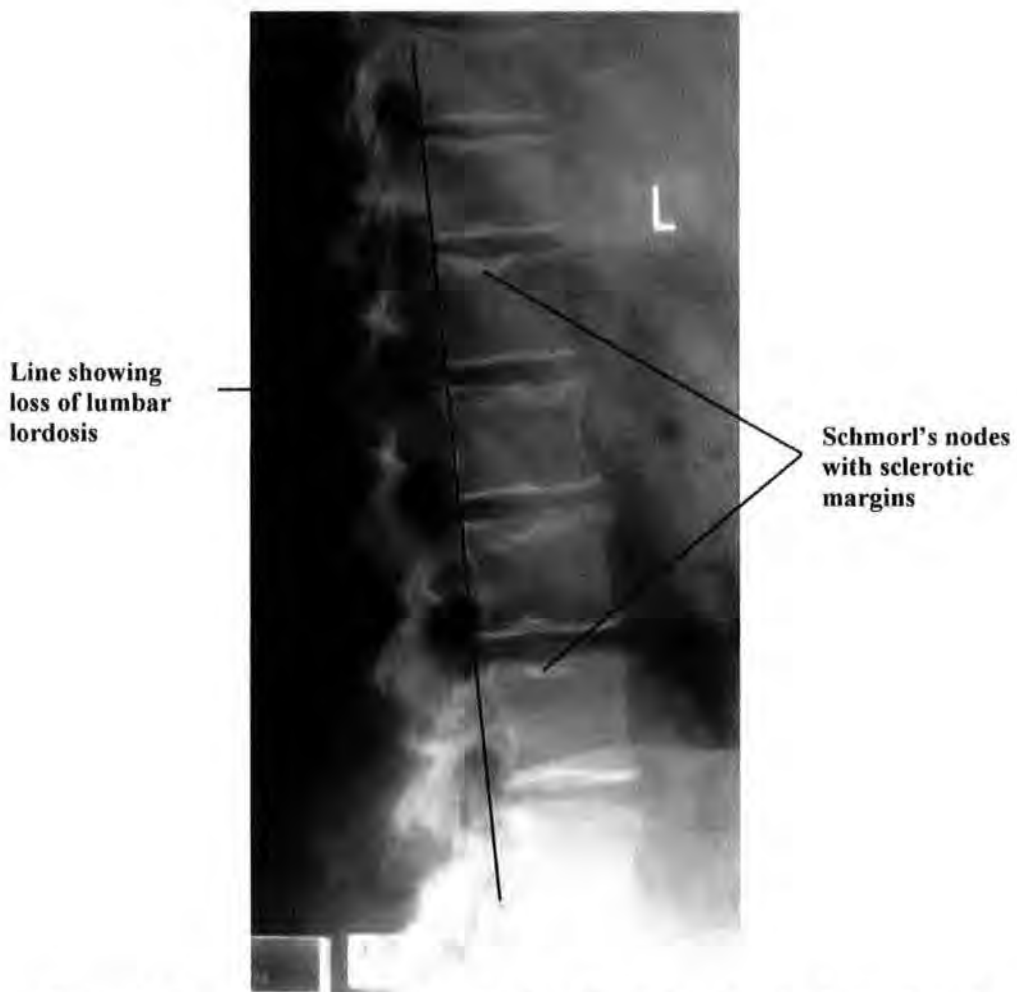### 3.7 Alterations to the primary and secondary curves of the spine

The primary source of information used for this section is from Resnick (2002) unless otherwise stated. From small muscular tears to major spinal trauma, alteration to spinal anatomy and physiology can cause temporary or permanent alterations to the natural curves of the human spine. The body's natural response to all disruptions of the vertebral column is to try to stabilize and realign the vertebrae to allow upright bi-pedal locomotion. An alteration to the normal primary and secondary curves alters the normal intervertebral disc compression, increasing the chances of disruption to the nucleus pulposus and thus the formation of Schmorl's nodes.

#### 3.7.1 Loss of curves of the spine

Loss of the natural curves of the spine (Fig. 3.9) can be due to injury or disruption to the soft tissues of the vertebral column; those tissues that lead to alteration of the curves are the anterior and posterior longitudinal ligaments, the multifidus muscle, the erector spinae, the interspinales, the quadratus lumborum, and the psoas muscle. Muscle spasm or contraction can occur for prolonged periods due to injury or abnormal exposure to reduced temperature and, although extremely painful, these muscles will usually return to their normal physiological position, with continued but reduced activity and longer than normal rest periods. Structural damage and disease will cause permanent alteration

to the dynamics of the spine with little or no prospect of the natural curve returning. If a complete vertebral column is present, loss of natural curvature is possible to diagnose in skeletal material where permanent alteration has left bony markers, and altered bony contours have been retained; in radiological images (Frymoyer *et. al.*, 1984: 1051), loss of the natural curve is often found where Schmorl's nodes are present. The Schmorl's nodes observed where the natural curve is absent are usually positioned centrally or posteriorly within the vertebral bodies (Fig. 3.9).

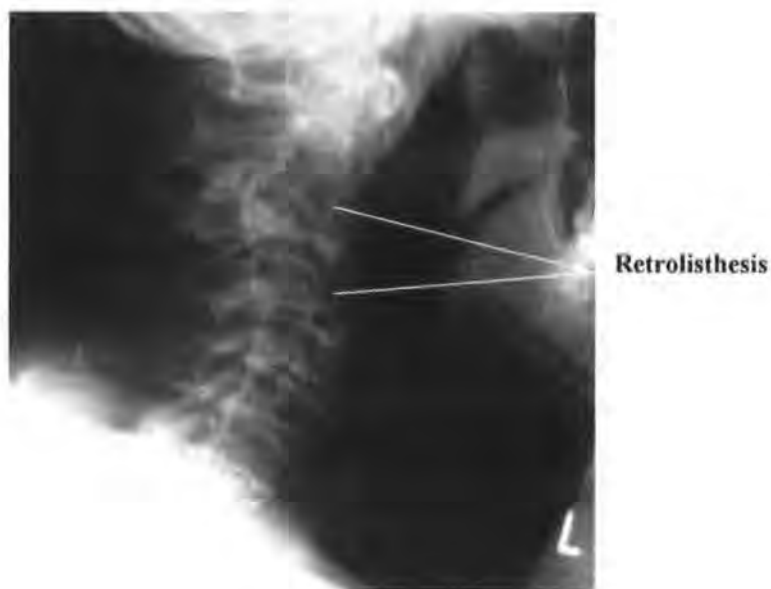


**Figure 3.9 Lateral lumbar spine showing loss of lordosis and active Schmorl's nodes with sclerotic margins (from Pinderfields Hospital, teaching archive).**

### 3.7.2 Retrolisthesis

Complete reversal of the spinal curve from convex to concave, or concave to convex, is very rare. In clinical radiography, it is occasionally viewed in lateral radiographs where

compression fractures of vertebral bodies and posterior or anterior slippage has occurred, with subluxation of the inferior and superior articular facets. Alternatively, anterior vertebral body fracture in the vertical plane, with anterior displacement, can result in the curve forming an “S” shape laterally, with the curve reversing at the level of the fracture (Fig. 3.10). The few vertebral column injuries with posterior subluxation or dislocation of vertebrae are usually caused by direct, high impact trauma which results in muscle and ligamentous disruption. This disruption can be so great, that the lateral pedicle tips and parts of the spinous processes are sheared off; as slippage of the unstable joints occurs the compression forces placed upon the intervertebral discs are so great that the integrity of the annulus fibrosus is lost, and the nucleus pulposus is herniated. This complex chain of events results in retrolisthesis as the muscles and ligaments try to stabilize the disrupted elements of the vertebral column (Ahmed *et al.*, 2005).



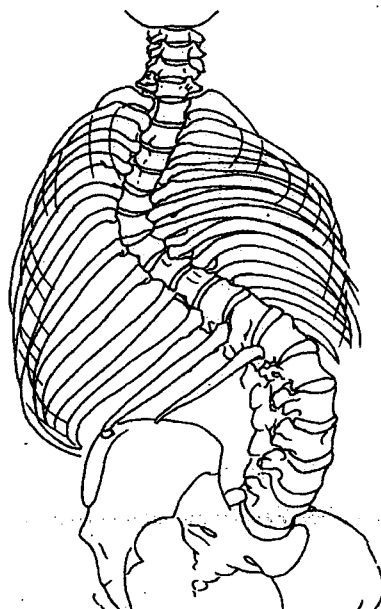
**Figure 3.10 Lateral cervical spine showing retrolisthesis  
(Pinderfields Hospital teaching collection)**

Osteoporotic collapse, spondylolysis, tuberculosis and metastatic disease can cause

retrolisthesis and neurological deficit at the level of the reversal of the primary or secondary curve (Resnick, 1985; Sharif, 1992). Congenital abnormalities such as hemivertebrae, block vertebrae or unequal growth of the elements of the posterior arch can result in scoliotic-kyphosis with retrolisthesis (Ozonoff, 2002). Paraspinal soft tissue masses such as infectious spondylitis, or intervertebral discs mimicking infectious spondylitis affecting several consecutive vertebral segments, can cause retrolisthesis (Renfrew, 2003: 259-280).

### 3.7.3 Scoliosis

This can be defined as rotational alteration to the dynamics of the vertebral column, with rotation of the vertebrae lessening cranially and caudally the further distant they are from the main point of insult (Fig. 3.11). The lateral curvature has not been found to have a left or right bias in studies undertaken by orthopaedic surgeons (Palastanga et al., 2002: 694). Both the thoracic and lumbar curves are prone to scoliosis with the thoracic spine being most commonly affected. Lumbar scoliosis (Fig. 3.19a) is linked to a loss of lordosis in those studies undertaken (Vialle et al., 2005).

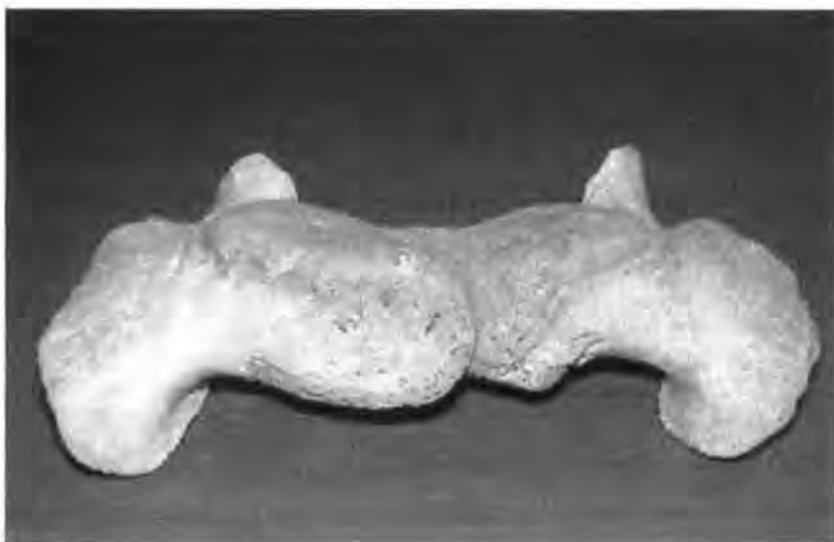

**Figure 3.11 Scoliosis with spinal rotation (from Palastanga *et al.*, 2002.)**

No further studies have been done to prove that early observation of loss of lordosis in the lumbar region is a marker of future scoliosis. This type of scoliosis is said to be idiopathic, as a cause cannot be readily ascertained, although many cases are found to be amongst young athletes and dancers where right and left sides are not exercised and used equally (D'Hemecourt *et al.*, 2002: 91) as in pole vaulting, javelin throwing and ballet dancing (Hellström *et al.*, 1990: 127-128).

(i) Congenital scoliosis

Congenital scoliosis can be caused by the failure of the somites to evolve and pair correctly (Fig. 3.12); the failed formation of an upper or lower somite will produce a vertebral body of unequal height when observed in antero-posterior position (Renfrew, 2003: 300). Posterior arch elements can fuse causing reduction of vertebral height on the side of fusion. These congenital abnormalities of the spine occur commonly in vertebral columns of children known to have Jarcho-Levin syndrome and Klippel-Feil deformity, and occasionally manifest in the normal child as a single anomalous occurrence (Winter and Lonstein, 1996).



**Figure 3.12 Bifid centrum (Hirsal skeleton No. 143)**

Muscular inequality and neurological signalling can also cause congenital scoliosis where the tension and torsion on the vertebral column is controlled by alterations to the neuron pathways; this causes uneven signals to reach left and right muscle groups. The muscles themselves, due to side preference when working and exercising, may also lead to uneven forces being exerted on the vertebral column on all or part of its length (Schmorl and Junghanns, 1971: 34-35).

#### 3.7.4 Kyphosis

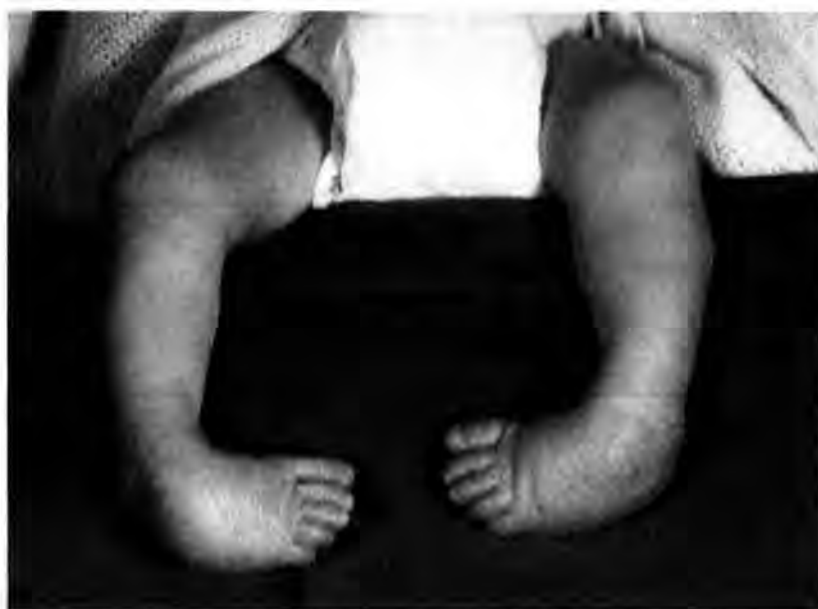This anterior concave curve can be the result of trauma, osteoporosis, tuberculosis, Marfan's disorder, and chondrodystrophy, all of which exaggerate the natural primary curve of the thoracic spine. Reporting of Schmorl's nodes presence where kyphosis is diagnosed in clinical radiology is a regular occurrence; in this case, they are situated anteriorly on the vertebral bodies within the margins of the end plates. The degree of primary concave curve must be more than 45° to be classified as kyphosis and often as the degree of curvature increases, scoliosis often accompanies this disorder (Ali, et al., 2000).

#### 3.8 Talipes Equinovarus

First discussed by Hippocrates (Hippocrates, 1849: 632), this disorder's aetiology still eludes today's physicians. Talipes is a condition which, if untreated, can become chronic and cause scoliosis in the thoraco-lumbar spine due to asymmetrical leg lengths (Alexander et al., 1999). Talipes equinovarus alters the normal anatomical position of the foot and ankle by the unequal strengths and lengths of the muscles and tendons supporting the bony structures (Fig. 3.13) (Roberts et al., 2004):

- The metatarsals, phalanges and calcaneum turn inwards.

- The foot points down, removing the angle between the ankle and foot anteriorly.
- The whole foot is rotated medially.



**Figure 3.13 Bilateral talipes equinovarus (Pinderfields Hospital teaching archive)**

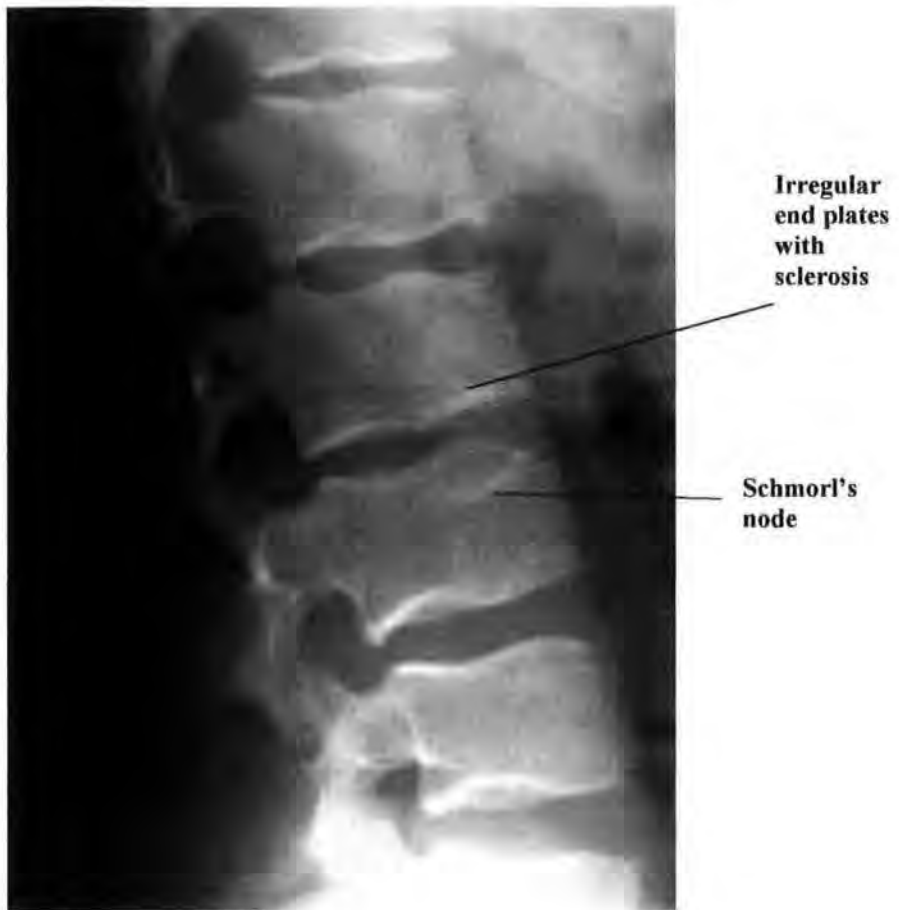
During the embryonic growth phase, the calcaneum and talus sit side by side until the longitudinal growth of the fibula pushes the calcaneum down, moving it into its recognised anatomical position below the talus (Scheuer and Black, 2004: 380). Any disruption to the normal growth pattern may result in cessation of calcaneal and talar evolution at nine weeks of embryonic growth, presenting as talipes equinovarus at birth (Kawashima and Uthoff, 1990). When the affected foot and ankle are compared radiographically during the neonatal period the calcaneum, talus and middle cuneiform are approximately 30% smaller than those of the unaffected side (Cummings et al., 2002). Congenital origins are suggested (Roberts and Manchester, 1995: 32), and in most cases, no other structural abnormalities are present (Farsetti et al., 1994). Recently an hereditary factor has been suggested as an osteological possibility, it having been noted that a close relative of an affected person in the preceding generation also has

'talipes equinovarus' (Resnick, 2002: 4561-4632). A dominant gene within certain cultural groups is one possible aetiology suggested by Chapman et al., (2000), after researching the medical history of those Maori families who have a sibling with talipes equinovarus. Another equally compelling proposal is that of a neurological origin as the deformity is caused by the uneven shortening and tightening of the musculature of the ankle and foot (Handelsman and Badalamente, 1981). Bilateral presentation is less common, with monozygotic twins occasionally presenting with the opposite limbs involved. Clinically, this condition can be surgically altered to allow normal growth to occur, but this procedure would not have been available in the past. If the abnormal gait is not corrected permanently, the continual uneven pressure on the spine may cause Schmorl's nodes.

### **3.9 Irregular endplate**

Sclerosis of the end plates of the vertebrae is the outcome of the body's immune system fighting an insult to any part of the sclera, it presents as a hardened non-pliable surface (Ring and Wenger, 1994). In the reactionary phase the sclera is bright white on radiographic images (Fig. 3.14) and is often visible around Schmorl's node lesions; irregular end plates are connected to active Schmorl's nodes.

When studying radiographic images of paediatric vertebral columns found positive for Schmorl's nodes, irregular end plates were always clearly visible (Fig. 3.14). Radiologists regularly reported this end plate condition when acute trauma to the vertebral column had recently taken place. The status of end plates was considered in the clinical data, but excluded from the data collection of the skeletal remains. Radiographic imaging may visualize this condition in the skeletal remains, but as not every vertebrae could be radiographically imaged this was not included.



**Figure 3.14 Irregular end plates with sclerosis and Schmorl's nodes  
(RHSC, Edinburgh teaching archive)**

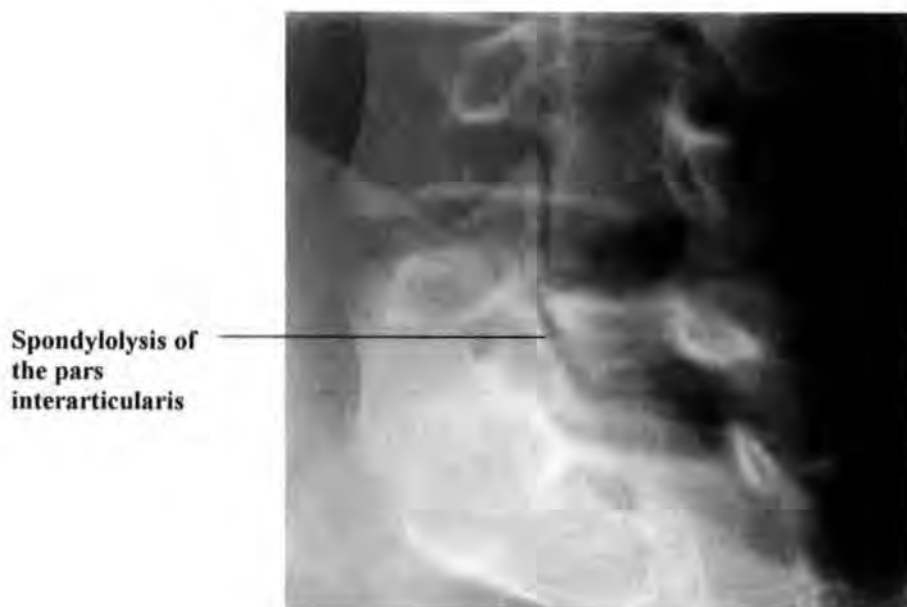
### **3.10 Loss of disc height**

Reduction of disc height was regularly reported in plain film imaging; this loss was observed but not measured (Renfrew, 2003: 74), and therefore reporting may have varied in detail from radiologist to radiologist. Loss of intervertebral disc height can only be measured accurately from weight bearing (erect) radiographic images where patients stand; these are only carried out as routine on patients suspected of having scoliosis, and those known to suffer from scoliosis who required accurate measurement of lateral curvature. Supine-non-load bearing images do not give an accurate indication of loss of disc height, nor of disc rupture or fracture. Loss of disc height was recorded in the clinical data but it was impossible to measure in the archaeological samples. Loss of disc height is often associated with Schmorl's nodes in clinical reports (Frymoyer *et*

*al.*, 1984; Jackson, 1979; Marchiori *et al.*, 1994); this intervertebral disc reduction will be studied using the radiographs and patient reports.

### 3.11 Posterior neural arch defect

This term has been used to cover the various disorders and diseases occurring within, or impinging upon, the posterior neural arch, with possible injurious effects on the spinal cord passing within, and protected by, the arch (Cyron and Hutton, 1978). Schmorl's nodes occurring within the posterior area of the vertebral body can cause reduction of the spinal canal space, or impingement upon the spinal cord, should partial or complete fracturing of the vertebral body's cortical bone occur. The clinical and archaeological samples will be studied to see if Schmorl's nodes causing posterior vertebral body fracturing are present.



**Figure 3.15 Spondylolysis of the fifth lumbar vertebra at the left pars interarticularis  
(from the RHSC, Edinburgh teaching archive)**

### 3.11.1 Spondylolysis

Spondylolysis is the fracturing of the pars interarticularis, the neck or bony area between the superior and inferior articular processes, usually of the 5<sup>th</sup> lumbar vertebra (Knüsel, 2000; Merbs, 1995:23-28). This fracture is best demonstrated in the oblique antero-posterior radiographic view (Fig. 3.15), imaging both oblique views to assess whether the spondylolysis is left sided, right sided, or bilateral. Historically this defect was thought to be the result of a congenital weakness (Hutson, 1993: 195), but following extensive medical research the consensus is that the most likely cause is repeated minor trauma where hyperextension is involved. Athletic pursuits such as gymnastics, hurdling and football cause loss of lordosis in the lumbar region of the vertebral column when hyperextension of the leg is performed, and the risk of spondylolysis increases if torsion of the trunk simultaneously occurs (Hellström *et al.*, 1990). Early return to exercise without modification of the asymmetric stresses of the affected area can cause new and aggravated injury to the stress area

### 3.11.2 Spondylolisthesis

Spondylolisthesis is a complication of spondylolysis caused by the loss of integrity of the superior and inferior articular facets of the affected side. Spondylolisthesis does occur in old age due to vertebral degeneration and loss of intervertebral disc elasticity, allowing the affected spondylolytic vertebra to slip forward (spondylolisthesis) (Hutson, 1993: 145-146; Alderston, *et.al.*, 1999: 840). It is often observed in conjunction with spondylolysis; the instability is caused by alteration of the mechanics between the vertebra with the fractured pars interarticularis and the superior and inferior vertebrae (Roberts and Manchester 1995:78-79). Spondylolisthesis occurs between the vertebra involved and the inferior vertebra, which is most commonly the fifth lumbar vertebra or first segment of the sacrum. Radiologists and orthopaedic surgeons (Meschan, 1976:

118) recognize four classes of anterior spondylolysis (Fig. 3.16) listed below (Lusted and Keats, 1972: 529).

- Class I: 25% anterior slippage by the 5<sup>th</sup> vertebra on the 1<sup>st</sup> sacral segment
- Class II: 50% anterior slippage by the 5<sup>th</sup> vertebra on the 1<sup>st</sup> sacral segment
- Class III: 75% anterior slippage by the 5<sup>th</sup> vertebra on the 1<sup>st</sup> sacral segment
- Class IV: 100% anterior slippage by the 5<sup>th</sup> vertebra on the 1<sup>st</sup> sacral segment

If the listhesis is not more than ten percent, closely monitored follow up radiographs show that there is rarely any further anterior slippage of the affected vertebra. Hard and sustained sport, and sports training such as athletics and gymnastics in the subadult age range make people very susceptible to spondylolysis and spondylolisthesis (Jackson, 1979: 364).

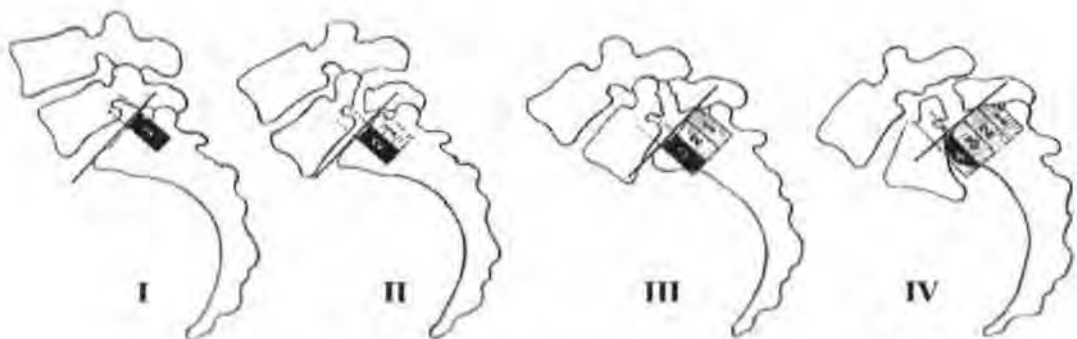


Figure 3.16 Classification of spondylolisthesis (Lusted and Keats, 1972)

### 3.11.3 Spina Bifida

Spina bifida is the non-union of the two halves of the spinous processes of the vertebral arches. The growth and development of the neural plate, which becomes the neural tube, is closely linked to the notochord (Menelaus and Broughton, 1998: 3). The notochord is the primary centre

around which the somites form, migrate and reform to become the centra and lamellae of the neural arches (Sture, 2002: 153). Closure of the cranial and caudal portions of the neural plate to form the neural tube is the last to happen, and is the most vulnerable to non-union (spina bifida) (Scheuer and Black, 2004). Spina bifida presents in two forms:

(i) Spina bifida occulta is a commonly occurring disorder of between 3% and 18% in the general population (Saluja, 1988), having slight flaring and smooth edges to the hemi-spinous processes of the vertebrae (Fig. 3.17) caused by pressure of the neural tube, without herniation of meninges. This most commonly occurs at the level of the fifth lumbar vertebra, but can present in several or any one of the vertebral arches (Scheuer and Black, 2004: 183).

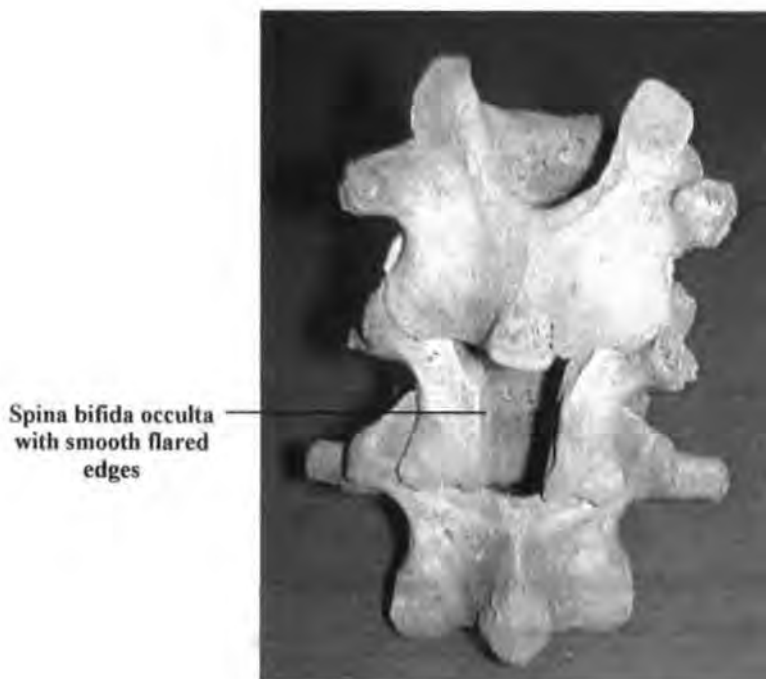


Figure 3.17 Spina bifida occulta (Hirsal skeleton No. 37)

A tuft of hair on the skin at the level of the defect is commonly observed during clinical examination of a neonate with spina bifida occulta (Moore and Persaud, 2003: 351). The majority of people having spina bifida occulta have no physical symptoms from this lesion and, it may only be discovered through radiographic imaging of an unlinked abdominal or pelvic problem.

(ii) Spina bifida cystica (Fig. 3.18) is a term encompassing several types of lesion, with the cyst like surface presentation giving rise to the name cystica (Clancy *et al.*, 2005). The sac or cyst on the surface of the skin can contain meninges or spinal cord and meninges. There are two types of spina bifida cystica:

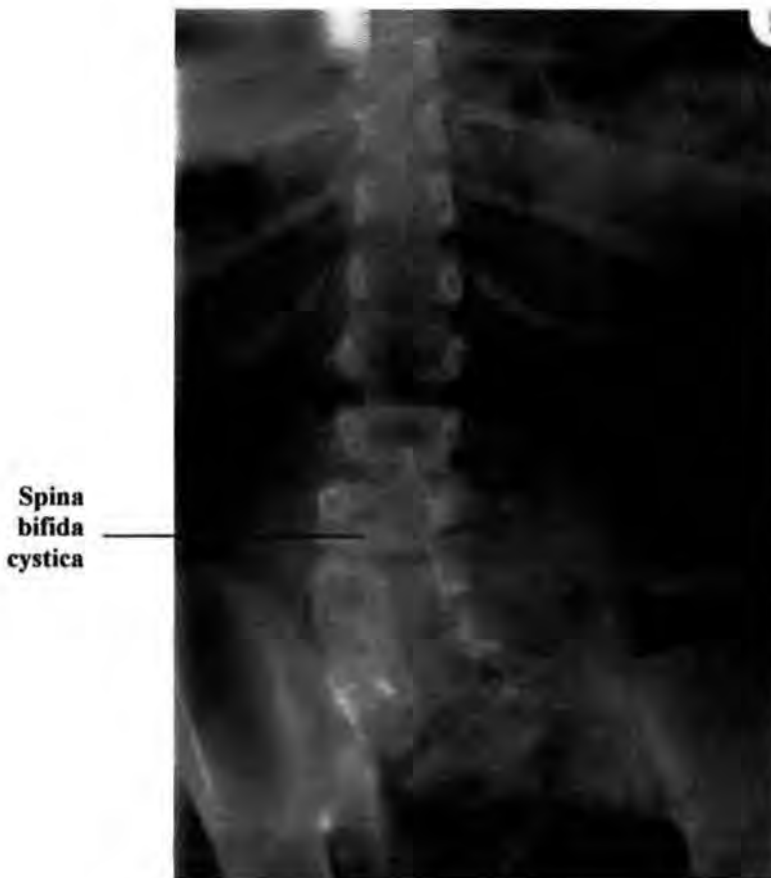

Figure 3.18 Spina bifida cystica (RHSC, Edinburgh teaching archive)

- Meningocele has only the meninges in the sac that is the sheath covering the axons and spinal cord within the sac; wherever possible the meninges are placed back within the spinal canal.
- Meningomyelocele has within the cyst or sac the meninges, spinal cord and axons at the level of the insult and can include several or many vertebrae. This disorder may present in the cervical or lumbar region, and the sac can be similar in size to a baby's head. In its severest form, anencephaly can be present where the calvarium is absent; in the less severe form, part of the brain will be absent and hydrocephalus can occur (Scheuer and Black, 2004: 180). Schmorl's nodes can affect the vertebral bodies where spina bifida occulta is observed; these Schmorl's nodes are often associated with altered primary and secondary curves, positioned towards the concave curve of the scoliosis or kyphosis.

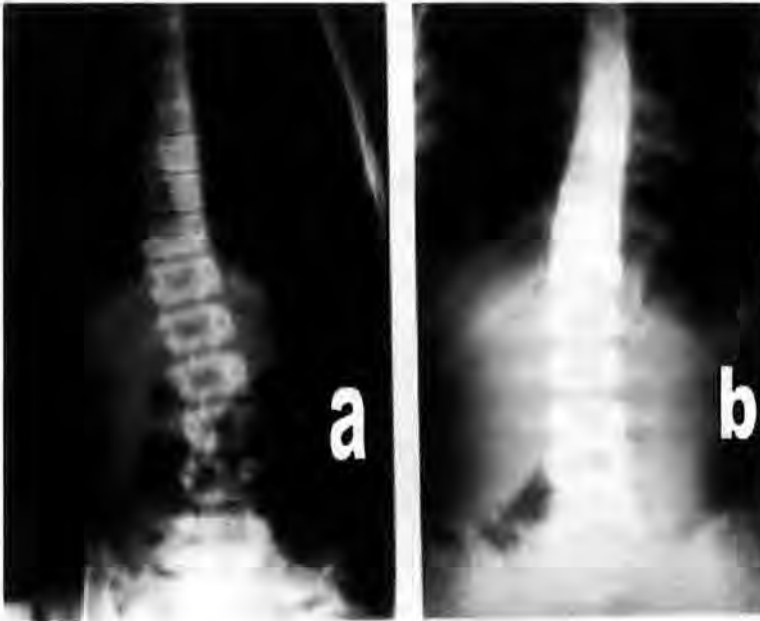
### **3.12 Associated conditions**

Associated conditions are conditions which can lead to worsening of another disorder or disease, or cause a disorder without being directly related to it. Asymmetry of leg length when untreated can lead to pelvic disruption and vertebral alteration to allow easier movement, and reactive spondylitis is often a precursor to ankylosing spondylitis, but has no direct involvement in this progressive spinal disease.

#### **3.12.1 Asymmetry of leg length**

Asymmetry of leg length is usually reported as 'bad posture', as if the patient, and not a leg length discrepancy, is the cause of the problem. Imaging for scoliosis is always undertaken in the antero-posterior position with the patient standing to allow accurate measurement of the spinal curve (Fig. 3.19a). Correction of the

curve in the subadult patient is easily attained by placing a wooden block of a height equal to that of the discrepancy under the foot of the affected side (Fig. 3.19b).



**Figure 3.19a Scoliosis due to asymmetry of leg length**      **Figure 3.19b Resolved scoliosis by placing a 6 mm block under the foot of the shorter leg**  
(from RHSC, Edinburgh teaching collection)

Surgically the femur, tibia and fibula can be broken, and a gap introduced to induce longitudinal growth by slowly expanding the external fixators; this over a considerable period of time reduces the asymmetry of leg length (Vogel, 1984). The sudden change of height from longer to the shorter limb produces sustained uneven pressure on the intervertebral discs. Continual abnormal gait leads to a scoliotic shift within the vertebral column as the vertebral column tries to return the torso to its correct anatomical position. In considering scoliotic disruption of the pelvis, unequal leg length should be noted (Fig, 3.19a). This condition was not recorded within the archaeological samples as

the majority of skeletons studied did not have all elements of the lower limbs present to give conclusive data.

Any or none of the preceding diseases and disorders of the vertebral column can be found where Schmorl's nodes are present, including spina bifida (Thompson, 1993). These disorders and diseases may have a relationship with Schmorl's nodes, and the disruption of the vertebral end plates and subchondral bone. At this time, only tenuous relationships have been presented (e.g. Taylor, 2000). Taylor (2000), explores a possible relationship between anterior Schmorl's nodes and adolescent / young adult kyphosis, which was reported in Schmorl and Junghanns (1971) work, but this has not been explored further.

In modern medicine the first step in assessing the patient's physical problems, pain levels suffered, and alterations to daily physical effort, is to produce a patient history. The doctor or nurse will ask leading questions such as "is the pain constant or intermittent", "is it more severe in certain areas or an all over ache". This question and answer method allows the patient to answer the question, and to expand where they want to, giving information which may seem to be irrelevant at the time of recording, but this information may prove invaluable at a later date. This personalized patient history may later help in the choice of diagnostic tests most likely to provide a diagnosis on which the medical team can act to control or cure the condition. Skeletal remains can provide information about disorders, diseases, and injuries suffered by our ancestors, but just as many may have suffered pain without bony alteration, or diseases of organs which have left not a trace in their skeletal remains. It is not always possible to find the cause of acute or chronic pain in the living, and in the skeletons of our ancestors, death may have precluded any bony alterations.

## CHAPTER 4: Material and methods I: Clinical

### 4.1 Introduction

This research was originally developed from observations and conversations within the Accident and Emergency department of Pinderfields Hospital, in Wakefield, West Yorkshire, where patients with acute back pain and back injury came seeking treatment and pain relief. Patients who had suffered no major spinal trauma, but had acute localised pain were sometimes found to have Schmorl's nodes at the levels of the indicated pain. No connection, or relevance, was given to the Schmorl's nodes, or to the localised pain, which seemed strange to the researcher; on questioning the Accident and Emergency Department Consultant, he said that Schmorl's nodes were asymptomatic and very common (*pers. comm.*, Dr. A. McGowan, October 1996). This comment did not appear to be borne out by the patients' case histories, so research was established as a tool to help solve this puzzle. Osteoarchaeologists have also reported Schmorl's nodes in skeletal reports of the many cemetery populations excavated and curated within the United Kingdom for example King, 2000; Proudfoot, 1996 and Anderson and Carter, 1994, and others, Brothwell, 2000, *pers comm.*, and Anderson, 18/07/2001, *pers. comm.*, have discussed the possibility of discovering the aetiology of this disorder. Combining data from the past and present allows the hypotheses presented in Chapter 1 to be tested, as well a gaining better understanding of the aetiology of Schmorl's nodes.

Clinical data will be compared and contrasted with the osteoarchaeological data, which dates from the early to late Medieval Periods, in order to determine whether industrial progress, the seeking of equality of the sexes and a modern lifestyle with all its accompanying home comforts has changed the frequency of Schmorl's nodes when past

and present populations are compared. Ultimately, does the effect of “living environment” alter the prevalence of Schmorl’s nodes through time?

#### 4.1.1 The relevance of clinical data

Clinical data brings together the extra dimensions of patient histories, examinations undertaken, radiographic images produced and written reports, as well as the recorded treatments and referrals, providing a wealth of information from each patient with Schmorl’s nodes. This clinical information may lead to a better understanding of the origins and significance of Schmorl’s nodes in human populations present and past.

#### 4.1.2 The choices of clinical samples

Clinical samples were chosen to include both sexes, a full range of ages, people employed in many different occupations (but often unrecorded), including rich and poor, and those leading healthy and unhealthy lifestyles, all of which were required to test the hypotheses proposed. The possibility of there being weak areas in the end plates of the vertebral bodies, and therefore the likelihood of the majority of Schmorl’s nodes being formed in the first two decades of life, also required the inclusion of children of all ages up to and including twenty-year olds. Clinical histories of patients of both sexes and all ages might help to prove or disprove the hypothesis that Schmorl’s nodes are asymptomatic. It was possible to also consider instability to the dynamics of the vertebral column caused by either eccentric Schmorl’s nodes and/or asymmetry of the lower limbs and altered pelvic angle where Schmorl’s nodes are present, providing sound data to test these hypotheses. Whether the levels and numbers of Schmorl’s nodes remain constant through time for both sexes of similar ages, and whether different types of work alter the levels of Schmorl’s nodes within the vertebral column, required a good range of ages for both males and females. The hypothesis proposing that the different

appearances of Schmorl's nodes have different origins and underlying causes could be more easily resolved with the use of the Computed Radiology Information System (CRIS) system. Logging of patient radiographic film packets produces evidence of the patient's progression through the hospital's clinics, wards, and physiotherapy department; it also highlights referrals to other specialists outside the hospital group.

Three considerations were most influential in the choice of clinical samples for this study in order to produce unbiased data sets:

- i. Would the Mid Yorkshire Hospitals NHS Trust (formerly the Pinderfields General Hospital) Wakefield, West Yorkshire ethics committee allow access to the material and information needed to complete this part of the study?
- ii. Would restrictions be placed on the use of specific age groups, sex, postal code areas, and patient's employment status, if known?
- iii. Was there a medical speciality, i.e. Orthopaedics or General Medicine where there would be enough relevant documentation to allow collection of unbiased data?

All three considerations were discussed with the Chairman of the ethics committee at Pinderfields Hospitals and the outcome was "access without restrictions" to the requested material, the choice of samples and collection of data.

#### **4.2 Clinical samples: selection criteria**

Each of the two clinical samples had to span a separate six month period. Every patient

in the group had to have at least one set of radiographic images of either the thoracic or the lumbar vertebrae taken within the chosen periods, and a computerised report available. The samples were reduced to those reported positive for Schmorl's nodes and those possibly suffering from Schmorl's nodes i.e. juvenile or senile idiopathic kyphosis, by reading the reports for every patient making up the total samples.

#### 4.2.1 Ethical Considerations (Appendix 1)

Collecting patient data was subject to ethical considerations which had to be addressed if the clinical research was to provide data which would be comparable to the archaeological data. The National Health Service has strict set guidelines produced by the Department of Health, (Anon. 3, 2005) to which all researchers must work. To allow this research to proceed, proof had to be available showing that no individual might be connected to a time or place either by reporting or imaging, or by any disorder or disease so uncommon as to make it impossible to separate the patient from that disorder or disease. In 1997 when this research first began, the then Chairman of the Ethics Committee, Pinderfields General Hospital, Wakefield, West Yorkshire, was contacted; at interview he decided that the work was for the greater part statistical and did not cross into personal patient profiling. Therefore, it did not require written permission by the Ethics Committee; this has since changed. The Head of Department in Radiology Imaging Services, Pinderfields General Hospital, Wakefield, West Yorkshire, gave oral consent, now supported by written permission to carry out collection of the clinical data. This year the Research and Ethics Group (RES), Mid Yorkshire Hospitals NHS Trust, Wakefield, West Yorkshire, which is given guidance by central government and specifically the Department of Health, has replaced the old type Ethics Committee. To ensure that no newly legislated guidelines have been breached it was necessary to apply to the new RES to acquire written approval for the now completed clinical research

undertaken at the Mid Yorkshire NHS Trust, and the Royal Hospital for Sick Children, Edinburgh.

The Computerised Radiology Information Services (CRIS) made collection gathering of all the clinical data necessary a straightforward analytical process. Using CRIS meant that access to confidential personal data would occur; therefore a means of cross-referencing the data, without any one person's right to privacy being breached when undertaking this work, had to be devised. Production of a group of non-recurring numbers and letters allowed cross-referencing to the source material without compromising the patients' privacy. Any radiographic images had not to contain any part of the reference normally carried on those films, which might lead a reader to the person whose images were viewed. Scanning the radiographs onto a computerised data disc (CD) allowed removal of all personal information by the simple expedient of covering the data with a removable label. Anonymity was observed throughout the collection of the clinical data in all of its forms.

Prior to visiting the Royal Hospital for Sick Children, Edinburgh, verbal permission was received from the Chief Radiologist and the Superintendent Radiographer to gather data from the CRIS system, and view relevant radiographic images, with an added permission to copy images which were of relevance to this thesis. The Superintendent Radiographer gave written permission retrospectively allowing access to patient records and radiographic images. A set of recording forms were sent to the Department, and paper information in the form of radiographic reports were forwarded by return to allow recording of where Schmorl's nodes were reported as present within the patients' vertebral columns. It is only now (*Anon.* 3, 2005) that the Scottish NHS has come under governance of the Department of Health where it was previously self-governing.

#### 4.2.2 Data selection

The Mid-Yorkshire NHS Hospital Trust has united several groups of hospitals within the West Yorkshire district, of which Pinderfields and Clayton hospitals are now a part (Ryan and Hurst, 1999). A large acute services hospital, Pinderfields General Hospital, has a national Burns Unit, Spinal Injuries Unit, Maxillary Facial Unit, and Prosthetics Department, as well as Surgical, Medical, and Orthopaedic departments, and a large Accident and Emergency Department. Clayton and Pinderfields Hospitals, carry out x-ray imaging by request of the General Practitioners throughout the district, and all requests, reports, and x-ray images are available on both sites. However, many departments have idiosyncrasies built into their systems, making those departments and specialities unsuitable for this research. For example, orthopaedic surgeons do not require their patients' radiographs to be reported; the same system works within the spinal injuries unit and many patients receive treatment, and further remedial surgery in distant specialist units, causing radiographic packets to become part of a distant hospital archive. Accident and Emergency reports are 'hot reported' directly onto the admissions sheets and are never recorded on computer (McConnell and Webster, 2000). The hypotheses set out in Chapter 1 required the gathering of specific data to be able to test those hypotheses i.e. age and sex distribution, position of Schmorl's nodes, levels of intrusion, absence or presence of pain, and associated disorders and diseases. Successful data collection required ease of access to relevant patient notes, radiologists' reports, and radiographic images for each patient used in the samples.

General Practices in the Wakefield area have an agreement with the Mid-Yorkshire Hospitals NHS Trust, giving them the right to order/request radiographic examination of their patients by appointment, at either Pinderfields or Clayton Hospitals. The agreement between the General Practitioners and Radiologists also requires a definitive

report for each patient to be sent out to the requesting General Practitioner within ten days of the radiographic examination's completion. This service between the General Practitioners and Radiologists stood out from the rest in that it provided a complete and comprehensive service. General Practitioner access to the Radiology Services on the Clayton and Pinderfields sites provides a readily available computed and written case history of patients who would be used for this study. Permanent hard copy films were easily accessible to view and record all positive Schmorl's node presentations, along with any previous images of the vertebral column contained within the same radiographic packet of the patient. This link with previous imaging allows the studying and recording of degeneration and regeneration of Schmorl's nodes, as well as any additional vertebral herniation and any other spinal disorders and related conditions.

The Royal Hospital for Sick Children, Edinburgh, had introduced a slightly different system of recording and reporting for all patients passing through the Radiology Department of the Hospital. Not only were the reports of the radiographic images computed onto the CRIS system, the reasons for requesting each patients radiographic examination were copied from the x-ray request card onto the report, making the gathering of required data for this research a straightforward task. All the radiographic packets were also stored within the X-Ray Department, allowing easy access and retrieval of films.

#### 4.2.3 Protocols

The National Institute of Clinical Excellence (NICE) produces clinical protocols and guidelines for the National Health Service for every aspect of its work, from hygiene to the conditions under which a radiographic examination of the vertebral column becomes a necessary part of diagnosis (Mueller *et al.*, 2000). There is no delay to radiographic

examination if loss of sensory feeling or motor co-ordination is ascertained immediately after a fall, impact injury or crushing incident (Brown, *et al.*, 2005). An accident and emergency department or, in more serious incidents, a spinal injuries unit, will be the point of referral. When no conclusive evidence of injury is ascertained, there may be a six-week delay between onset of pain and dysfunction and, only then, if observation and examination concludes that the patient does not present a noticeable reduction of debility, is a radiographic examination requested. This reduces the likelihood of observing Schmorl's nodes at their moment of inception if they occur due to normal activities carried out repetitively, or to extremes, rather than due to acute trauma. If the initial trauma has a relatively short acute pain period, no observation of the initial intrusion of the nucleus pulposus into the cancellous bone of the vertebral body will occur; only when further herniation of nuclear material exacerbates the condition, causing sclerotic changes around the node, will radiographic imaging record the condition. Occasionally the radiographs were from a follow-up examination where pain had not resolved after an earlier traumatic episode, allowing any vertebral changes to be observed. The practice of a patient having all radiographic examinations contained within one 'film packet' allows the same method of viewing all previous images, as discussed earlier. Doctors may also request imaging almost immediately if they feel that not to act may be detrimental to the patient's full recovery.

#### 4.2.4 The X-Ray Card and the relevance to this research

Every patient presenting for radiographic imaging from a General Practitioner source carries an X-Ray Card; this is an invaluable document as it carries a great amount of personal detail as well as a medical history leading to the requirement for a radiological investigation. Each card contains a moment in time personal to each clinical patient, which is retained once the examination and report have been completed. This card and

report are used as a cross reference should further examinations of the same area be requested at a later date. Information required is as follows:

- Surname (provides a guide to ethnic origin).
- Given name.
- Age/Date of Birth; not all countries have a birth registration requirement.
- Sex; this helps where the given name is not necessarily recognised.
- Address; this can suggest a person's personal circumstances, work pattern and lifestyle. Housing in a poor housing estate suggests low income, lower standard of living, lower educational level and less skilled worker. Exclusive, expensive accommodation suggests high income, better standard of living, better educated and more highly skilled.
- Reason for request; occasionally points to the person's type of work. It is the data concerning pain onset, location, duration and history, which help to build a picture of recurring abnormalities.
- The actual imaging request should be area specific to the perceived pain centre. Occasionally requests for imaging of areas of referred pain, as well as local vertebral images, give indicators to the levels where nerve compression and disc disruption may have occurred.

- Signature and paging number of the doctor completing the request form; this allows the radiographer to check any discrepancies between the clinical history and the request.
- The requesting doctor from the General Practice address must receive a written report within ten days of the radiographic examination's completion.

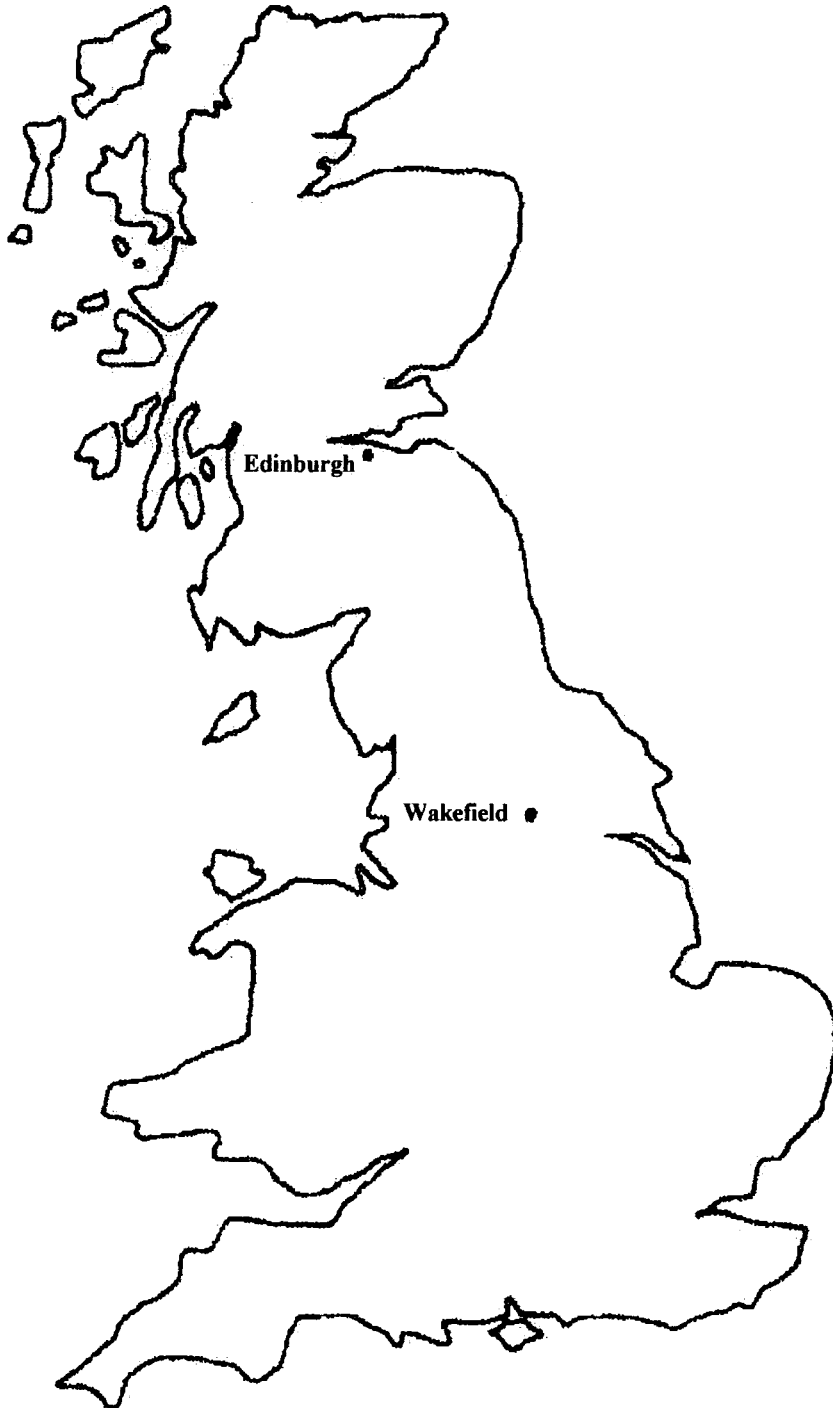The requirement of a definitive report for each set of radiographic images taken, which must reach the requesting General Practitioner within ten working days of the visit to the X-Ray Department, makes this service ideal for the data collection for this research. All reports are archived by CRIS and second copies of all reports are contained within the 'x-ray packet', allowing easy acquisition of a co-ordinated history for each patient.

#### **4.3 Pinderfields and Clayton Hospitals: Location and Environment**

These hospitals are situated within the city of Wakefield, and have a large catchment area, mainly on the south side of the M62 motorway, forming an imaginary semi-circle with a radius of approximately 20 miles. Every General Practitioner, practicing within this area has the right to send his or her patients for radiographic examination to these hospitals.

The city of Wakefield (Fig. 4.6) used to be an area surrounded by coalmines, heavy engineering and quarrying; today it is a computer and information technology region, heavily populated by people working along the M62 and M1 corridors (Anon. 4. 2004). The modern work ethic of travelling over great distances daily to reach a place of employment makes connection between employment type, the person's home location

and the patient's presentation of Schmorl's nodes speculative and not scientifically based.



**Figure 4.6 A map showing Edinburgh, site of the Royal Hospital for Sick Children, and Wakefield, site of Pinderfields and Clayton Hospitals (by R. B. McNaught)**

Two of the largest employers are the National Health Service, and the vast warehouse system (Anon. 5, 2006) for the main supermarkets, where constant loading and

unloading of large heavy loads is part of the daily routine; however, this is no longer manual but mechanised. The connection between work patterns and Schmorl's nodes would at best be speculative without a works injury indicated on the x-ray card. Work patterns change through time and these changes may be noticeable when comparing the number of older patients against those of the last ten years who have started work in a world where all employers must take health and safety seriously.

The outlying towns of Castleford, Pontefract, Featherstone, Normanton and many more have a common past employer in the National Coal Board. However, every type of work, from making lock gates to electrical engineering and meat processing, is still carried out in the towns surrounding Wakefield (Anon. 6, 2006). Large farming areas, also border the towns; arable, beef, dairy and sheep farms are all found in the West Yorkshire (Anon. 7, 2006). Thus people, past and present may have been involved in a variety of occupations.

#### 4.3.1 Pinderfields and Clayton Hospitals: Group I

#### 4.3.2 Materials

A six-month period of 'General Practice requesting' was chosen and, using CRIS, allowed a computer print-out of all requests for thoracic and lumbar spine radiographs using the departmental barcode as a reference point. This group of patients all had radiographic examinations, and had their radiographic images reported between the 1<sup>st</sup> of October 1994 and the 31<sup>st</sup> March 1995. Each one of the radiographic reports for the 1,461 patients were accessed through CRIS and read, before recording all diseases and disorders reported in conjunction with Schmorl's nodes for each of the positive patients. The recording sheets used for the collection and collation of relevant information were

altered slightly so that patient anonymity could be maintained, while allowing the patient record to be re-accessed if it should be required. Recording all positive Schmorl's node reports and using CRIS to trace each set of films within the hospital network made retrieval a simple task. Once located, a request for their return to a central point within the radiology department was issued, and the task of reviewing each set of films commenced. Reviewing all positive and probable Schmorl's node radiographic images required the collection from storage of 85 x-ray packets of which 70 patients were used in this study.

#### 4.3.3 Methods

Each patient had routinely undergone radiographic imaging in the antero-posterior and lateral positions. Lateral imaging of the lumbo-sacral joint gave a clear image of any skeletal changes and any joint reduction or "slippage" within the joint. Oblique views of the thoracic and lumbar spine gave detail of any intervertebral impingement or fracturing of the pars interarticularis; these additional x-ray images are necessary where doubt of continuity of the pars interarticularis is an observation noted during the reporting process. The reports of each General Practice patient were accessed and read to discover which patients, if any, were reported as having Schmorl's nodes present. Radiologists report the presence of Schmorl's nodes, and occasionally the vertebrae involved, but not whether the upper or lower end plate was affected. The first data-recording sheet was produced to allow all disorders present within the vertebral columns of patients with Schmorl's nodes to be recorded. Overall, fourteen disorders were reported for each patient, including Schmorl's nodes. Numbers of patients reported as normal and with other disorders and diseases were recorded, but only the patients with Schmorl's nodes were recorded in detail on the data sheets. The following were

recorded where reported because they might have an association with, or increase the risk of, Schmorl's nodes where they alter spinal stability and/or spinal curvature:

- Schmorl's nodes; herniation of the nucleus pulposus through the vertebral body end plates causing displacement and fracturing of the subchondral trabeculae.
- Posterior neural arch defect was considered present where fracturing or non-union was reported. Consultants consistently reported spondylolysis, spina bifida occulta, or spina bifida cystica when Schmorl's nodes were present.
- Spondylolisthesis; was recorded when forward displacement of one vertebra upon another was reported, usually caused by disruption within the posterior neural arch e.g. spondylolysis.
- Osteoarthritis; degeneration of the vertebral synovial joints; this is recognised in radiographic images by loss of joint space, sclerotic margins of the sub-chondral bone, osteophytes and ankylosis of the joint.
- Osteopenia and osteoporosis are conditions presenting with less than normal bone density. The gold standard is by dual x-ray energy absorptiometry (Sandrick, 1998) which provide bone mass measurement, using imaging of the antero-posterior and lateral lumbar spine, and of the antero-posterior hip view; these skeletal areas are considered to be the first to show measurable trabecular reduction when osteopenia or osteoporosis is suspected. The World Health Organisation classification of bone mass is scored as a deviation of the young population as a whole from normal (Rumancik *et al.*, 2005). The mean bone

mineral density and mean bone mass have been calculated from a reference population of young adults (Lane, 2006), and male and female bone mineral densities are calculated in separate tables (Lewiecki *et al.*, 2004) producing the following bandings for bone mineral loss:

- Greater than -1 = normal
- Between -1 and -2.5 = osteopenia
- Equal to -2.5 = osteoporosis
- More than -2.5 = severe (established) osteoporosis.

These results are not usually included in the radiographic reports, as they are not normally obtained until observations of osteopenia or osteoporosis have been recorded in the plain film, radiographic report.

- Mild osteochondritis is an inflammation of cartilage and bone in the adult vertebral column which causes small flakes of bone to break free, this shows on the radiographic images as a slightly roughened almost spotty (desiccated) surfaces to the end plates of the vertebral bodies.
- Juvenile osteochondritis is thought to be related to osteochondritis dessicans, with necrosis occurring due to intermittent obstruction (anastamosis) of the local blood vessels. The interrupted blood supply affects nutrient filtration to the vertebral bodies and intervertebral discs causing fragmentation of the end plates and/or annulus fibrosus of the disc with anterior wedging of the vertebral body at the level of the anastamosis (Fig. 3.7). Occasionally a wedge avulsion of the anterior cortical bone occurs; while healing can take place the avulsed bone

becomes necrotic (Swischuk, *et al.*, 1998). When juvenile osteochondritis is observed a radiological diagnosis may be offered of, 'possibly early Scheuermann's disease'.

- Loss of lordosis or straightening out of the primary and secondary curves; usually most clearly observed on the lateral or sagittal radiographic image.
- Scoliosis; lateral curvature away from the mid-line can be idiopathic, congenital or age related. The antero-posterior radiographic image is the view in which this is observed and, where required, measurements are taken.
- Sclerosis of the end plates, overgrowth of fibrous tissue on the vertebral body surfaces causing 'hardening'. This is visualised as a very bright white cortical bone on a radiographic image.
- Irregular end plates; separation of the end plate from the body producing a wave like appearance. This is most easily recognised when viewing a lateral radiographic image.
- Loss of disc height: less than the expected space between vertebral bodies, which can be caused by spinal degeneration or injury, nucleus pulposus damage and annulus fibrosus fracture.
- Retrolisthesis; a reversal of the natural curve may be caused by acute trauma/ or spondylolysis in association with altered pelvic angle; this reversal of curvature can occur in the primary or secondary curves.

- Spondylosis is degenerative disc disease, manifesting itself as reduced disc space with pitting and porosity of the vertebral end plates where osteochondrosis (osteoblastic regeneration) has taken place (Roberts and Manchester, 2005: 140). The dehydrated disc causes alterations to the zygapophyseal joints of the vertebra, reducing their mobility and allowing the superior joint to touch the caudal vertebra in extension. The reduction in joint space puts pressure upon the intervertebral disc of the motion segment involved causing posterior, lateral, or anterior bulging of the intervertebral disc (Chawda, 2000).
- Sixth lumbar vertebra
- Transitional vertebra
- Age was recorded to allow comparison with skeletal samples of the same age group.
- Sex was noted to allow comparison between males and females, and those of the same sex in clinical and archaeological samples.
- Absence or presence of back pain.
- Absence or presence of lower limb pain or weakness
- Annotation of anything thought to be relevant that is written in the data box of the patient's x-ray card.

Schmorl's nodes were recorded as follows on each vertebra, the position (anterior, central, posterior or lateral) and the type of node (rough, smooth or grape i.e. looking like a bunch of grapes). An example of the recording forms can be found in Appendix 2.

#### **4.4 Pinderfields and Clayton Hospitals: Group II**

A second group of patients chosen from the General Practitioner Requesting System

was studied to see if the number of patients requiring thoracic and lumbar spine would vary greatly from the first sample, and whether the disorders and diseases would produce widely differing data where Schmorl's nodes were present. Group II would also show if there was a noticeable bias in sex or age of the patients studied in the first sample. This group of patients, which numbered 1,374, attended for radiographic imaging between 1<sup>st</sup> August and 31<sup>st</sup> December 1995, and 40 cases of Schmorl's nodes were identified. Postal codes for every patient in this group were recorded allowing a geographical location to be mapped postal codes were not gathered from the first sample, as the possible relevance was not realised at the beginning of this research but, if the Ethics committee will allow further access to the CRIS system this omission will be rectified in future work.

Not everyone can be classed as an average inhabitant of a known poor, average or exclusive group of housing, but it is a positive indicator of income, as people tend to move up the housing ladder where circumstances allow. Due to modern work patterns, it may not be possible to associate specific spinal disorders and diseases to specific types of work, but it may be possible to associate people to skilled or unskilled labour by looking at the areas within which they live.

When radiologists report radiographs the word 'normal' is used when no bony disease or condition is visible. All patients used for this research and reported as normal will replace the negative group required in comparative studies. Many extremely painful episodes in the vertebral column originate from muscular spasms and disruptions making 'normal' an acceptable report which would only require further investigation if symptoms did not settle over several weeks from the original assessment.

Two thousand, eight hundred and thirty five patient reports formed the basis for the clinical data collection undertaken in the Pinderfields and Clayton Hospitals Radiology Departments. Regular reporting of all diseases and disorders, and the levels of vertebral involvement determined the layout of recording forms suited to the data gathering for all clinical groups (Appendix 2).

Recording of all other information thought to be of further relevance brought the number of spreadsheets to three (Appendix 2). Localised and referred pain, along with pain description was noted, as were any changes from the previous radiographs when compared to the most recent ones. The information was not categorised (constrained by narrow classifications) reducing the chances of eliminating important factors should they not fit into set criteria. Referrals to other departments for further treatment such as physiotherapy, back pain management or osteoporosis assessment are all CRIS recorded and form a history of patient 'film movements'.

#### **4.5 Royal Hospital for Sick Children, Edinburgh: Group III**

##### **4.5.1 Background information**

Founded in 1860 with only 12 cots, it doubled in size three years later, with one final addition of a seven bed surgical unit in 1887; the high mortality rate of children at that time, running at 33% of annual deaths, was hopefully to be reduced (Guthrie, 1960). The present hospital site was first built on in 1895 and has been extended and rebuilt over the years to allow for today's throughput of approximately 100,000 sick children from the east of Scotland annually. Edinburgh Royal Hospital for Sick Children's (Fig. 4.1) east of Scotland catchment area allows children with spinal problems to be sent out from the Lothians, Borders, and Fife to have their symptoms examined and tests carried

to try to reach a diagnosis and provide subsequent treatment.

#### 4.5.2 Materials

One group of people were almost completely absent from the samples chosen at Pinderfields and Clayton Hospitals, this group being paediatric patients. Paediatric patients as part of the clinical sample were required to help test several of the hypotheses presented in this research. Paediatric patients and subadults are the clinical and archaeological terminologies respectively, for individuals who have not yet reached maturity in terms of growth and hormonal alteration.

#### 4.5.3 Hypotheses requiring clinical paediatric materials

The first hypothesis was whether the perceived weak area in the vertebral end plates left by the notochord as it regressed from the centre of the immature vertebral bodies, allowing Schmorl's nodes to herniate the vertebral end plates with little or no resistance, did or did not exist. The second hypothesis centred on the immature vertebrae and the possibility that the greatest number of Schmorl's nodes occur in the first two decades of life due to the perceived vulnerability of the end plate during growth. A third hypothesis considered the ages of patients reported radiologically as having Schmorl's nodes to see whether they compared or contrasted to those of similar age within the archaeological samples studied. Specialist children's hospitals are now the preferred hospitals for General Practitioners to send their youngest patients to when requesting examinations of any type. Only a child suffering an accident and requiring transfer by ambulance arrives at the nearest accident and emergency hospital for primary care. Movement of children with spinal injuries, for example, to specialist paediatric hospitals is carried out once a specialist spinal injuries team flown in from the receiving hospital stabilizes the patient. This movement brings the paediatric patient with all medical notes, radiographic images

and reports into the specialist paediatric hospital where access is enabled through the CRIS system.

#### 4.5.4 Methods

Children's hospitals do not all have accident and emergency services, except in Scotland, so the Royal Hospital for Sick Children (RHSC), Edinburgh, provided the source of radiology information required to give the clinical groups a complete age range. The CRIS system implemented in the RHSC was similar to that of the Pinderfields Hospital system, allowing the same method of data collection to be employed. Four hundred and forty-two children of sixteen years and under had been radiographed for back injuries, back pain, or alterations to the primary and secondary spinal curves, in the two years since the implementation of the CRIS system. All of the four hundred and forty-two radiological reports were studied and data recorded. The age range of the paediatric patients was from neonatal to seventeen-years old, with an almost even number of male and female patients. Eleven boys and eleven girls between the ages of 6 and 16 were reported as having Schmorl's nodes from radiographic images taken during 1999 and 2000. Data was gathered from all radiologists' reports reading positive and probable for Schmorl's nodes, along with possible associated disorders and diseases. Viewing of all radiographs of patients reported positive and probable for Schmorl's nodes was carried out to allow the vertebral level and end plates affected to be recorded onto the data collection sheet (Appendix 2).

Computed records within the RHSC covered only 1999 and 2000, when this research was being carried out. These patients were divided into two groups, group I consisting of the 1999 patients, and group II the 2000 patients. Group I (1999) were merged with the 1994-5 Pinderfields Hospital sample, and group II (2000) were merged with the

1995 Pinderfields Hospital sample, to test several of the hypotheses. These amalgamated groups made it possible to compare the clinical groups with the archaeological samples where a complete cross-section of ages was required. The RHSC material, within groups I and II, is a useful indicator of differences between adult and paediatric rates of presentation of Schmorl's nodes. It is only with the use of every available set of indicators that a possible link between paediatric Schmorl's nodes, vertebral end plate weakness, and the formation of adult Schmorl's nodes, may be proved or disproved.

Paediatric Schmorl's node frequency, when compared to the adult population frequency can show whether Schmorl's nodes numbers, positions and types change or remain constant through the decades of life. Do the male to female, adult to children, rates of affected vertebral columns stay constant through time, or do different male and female life styles cause the bias to change through the decades of life? These and other age related relationships were studied.

#### 4.6 Comparisons between Hospital locations

##### 4.6.1 Wakefield and Edinburgh

The city of Wakefield and its catchment area may appear to have a very different background to the city of Edinburgh and district, but both were surrounded by coalfields and, where Wakefield provided engineering expertise, the port of Leith used these pieces of engineering to power their ships (Taylor, 1978). The hinterlands of Edinburgh are agriculturally diverse and rich. These cities and environs have many common denominators so to place them together in this study does not seem as anomalous as first thought.

#### 4.6.2 Rural and Urban areas

Professional people, working people, and the unemployed, from indigenous and incomer backgrounds, become a single patient group, defined only by the medical requirements of that group i.e., Urology, Surgery, Cardio-vascular, Neurology, or Radiology. Back injury and back pain were the common links between all the patients who used the General Practice, Radiology Access at the hospitals. The patients of Pinderfields Hospital and the Royal Hospital for Sick Children in Edinburgh represent towns with urban sprawl, that is, rural areas are drawn into the periphery of a town by that town's expansion of the built area (*Anon.* 8, 1998).

The sample of living people for this research represent people who live, work and relax in an area typical of many of today's cities which began as cities with definitive boundaries and green belt (cultivated farmland), or land separating them from the surrounding towns and villages. Through time, suburban sprawl slowly encroached upon the farmland as more housing was required and industrial units sprang up, until they amalgamated. The populations are a mixture of incomers and locals, who can trace their families back through many generations of local inhabitants.

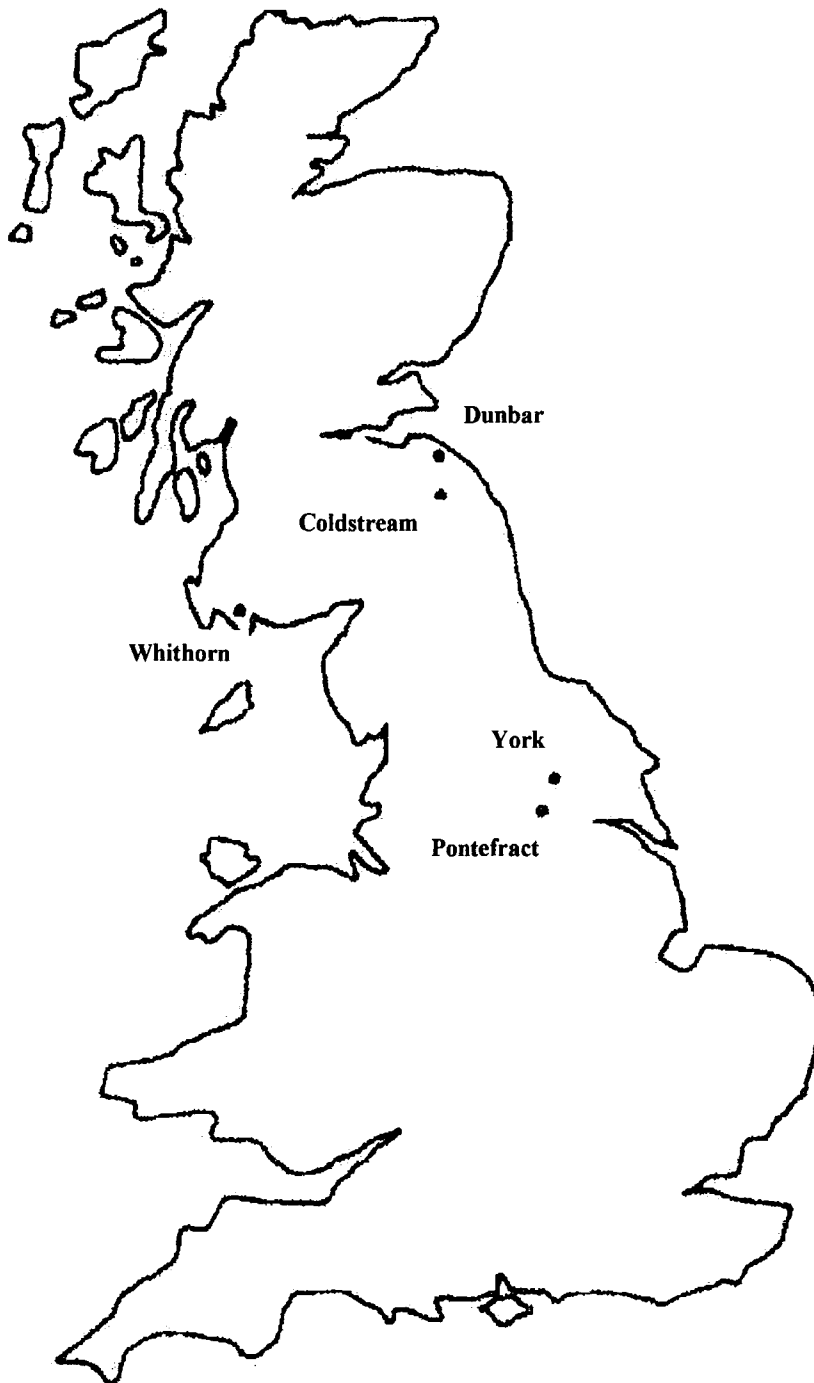
## CHAPTER 5: Material and Methods II: Archaeological

### 5.1 Materials

#### 5.1.1 Introduction

All the archaeologically derived cemetery populations chosen were from sites in the Scottish lowlands and the north of England (Fig. 5.1). Historically the Scottish regarded the geographical areas known as the lowlands and southern uplands of Scotland, as English (Barrow, 1994). During the early Medieval Period, the lowlands and southern uplands of Scotland were ruled by Northumbrian Kings, and the Church by the Northumbrian Bishops (Ross, 1998: 162-168). Dating from the Early Medieval Period to the Late Medieval Period, 600 AD to 1600 AD, the skeletal samples had one thing in common; a reasonable number of neo-natal, infant, juvenile and subadult remains, as well as adult remains, both male and female. This study required skeletons with the complete complement of thoracic and lumbar vertebrae to test the hypotheses posed. Reasonably sized cemetery populations with good preservation were therefore needed. Geographically positioned in coastal, rural and urban areas, these populations were dependent on their location for employment, food and housing, making each group used for this study individual in their lifestyle, health and culture. The human body is altered by, and adapts to, the individual's lifestyle, and thus those people leading an active life may well have healthy bones and a strong myology. However, the type of employment undertaken would have introduced hazards of injury, disease and death. Times of famine in childhood would potentially have left skeletal stress markers such as Harris lines, dental enamel hyperplasia and cribra orbitalia with the lowest levels of society suffering the greatest deprivation (McEwan *et al*, 2005). Culturally, the members of each population would have been influenced by their peers, superiors, and inferiors, within the communities. Each member of a hierarchical society would be judged by

material possessions, their standing within that society, and the authority they wielded, so the more useful and influential a person was the greater the chances of survival when adverse conditions prevailed (Ubelaker and Pap, 1998).



**Figure 5.1 Map showing the location of Captain's Cabin, Dunbar; the Hirsell, Coldstream; Whithorn Priory, Whithorn; Fishergate, York and Tanners Row, Pontefract (by R. B. McNaught, 2005)**

The five sites selected were:

- |   |  |
|---|--|
| 1) Captain's, Dunbar, East Lothian, Scotland        | 9 <sup>th</sup> to 12 <sup>th</sup> century  |
| 2) The Hirsell, Coldstream, Berwickshire, Scotland  | 10 <sup>th</sup> -14 <sup>th</sup> century   |
| 3) Whithorn, Dumfries and Galloway, Scotland        | 6 <sup>th</sup> to 10 <sup>th</sup> century  |
| 4) St. Andrew, Fishergate, York, Yorkshire, England | 10 <sup>th</sup> to 16 <sup>th</sup> century |
| 5) Tanners Row, Pontefract, Yorkshire, England      | 6 <sup>th</sup> to 9 <sup>th</sup> century   |

To test these hypotheses, skeletons from five British archaeological sites from the early to late Medieval periods were considered, and the associated life styles of these populations. Whithorn, Dunbar, and the Hirsell, are geographically placed in Scotland, but all three sites, came under Northumbrian influence from the Church and the Crown (Brooke, 1994). The population of the east coast defensive site of Dunbar, East Lothian and the monastic west coast site of Whithorn Priory, Dumfries and Galloway, both in Scotland had very different life styles and work patterns to compare and contrast, but with very similar environments. Dunbar was a fortified town, under military rule providing coastal defence from invasion (Moloney, 2001: 283-284). Whithorn was a monastic coastal site, providing for the religious and domestic wellbeing of monks, later becoming a mercantile centre providing every possible comfort to the large numbers of pilgrims passing through the ecclesiastic, and urban, districts, of the Borough of Whithorn (Hill, 1997). The Hirsell, Coldstream, a rural agricultural site with a church and estate, is situated close to the north bank of the river Tweed in East Lothian. Tanners Row, Pontefract, Yorkshire (Hinde, 1997: 310-312), was a prosperous rural settlement around a church which had similar work patterns, and different church influences, affecting lifestyle when compared to the Hirsell.

The fifth and largest population chosen is that of the Gilbertine Priory site of St. Andrew, Fishergate; this was a monastic site within the city of York, England. The cemetery was in use from the 7<sup>th</sup> century and survived through the Viking invasions and settlement, continuing in use as a burial site until the dissolution of the monasteries (Kemp & Graves, 1996). Fishergate does not sit easily among the other sites until used as a comparative study for the clinical populations of Pinderfields General Hospital, Wakefield in West Yorkshire (Tanners Row) and the Royal Hospital for Sick Children (RHSC), Edinburgh (Whithorn, Dunbar and the Hirsell). The sites have central trading areas and urban sprawl, and bring clinical and archaeological data together to help to resolve several of the hypotheses proposed.

The skeletal samples of Whithorn Priory, Dunbar, the Hirsell, Tanners Row, and Fishergate were chosen because:

- The human bone reports indicated good bone preservation
- Many of the skeletons in each collection had all of the thoracic, and lumbar, vertebrae present
- Both male, and female, adults were represented in each group
- Subadults were well represented
- A time span of nine hundred years is represented during which industrialisation occurred
- Diversity of work patterns
- The settlements are in geographically diverse areas
- The geology and topography for each settlement area require differing skills for continuous self-sufficiency to be maintained

The aim and of this research was to test the hypotheses set out in chapter I, with the ultimate objective of establishing the causes of Schmorl's nodes.

1. The point of regression of the notochord is the weakest point within the end plate of the vertebra, making it the most likely point of herniation of the nucleus pulposus, and the formation of Schmorl's nodes. This hypothesis required a reasonable number of subadult vertebral columns to be macroscopically examined to determine whether a weak area remained where the primordial notochord sitting anteriorly to the neural groove formed an axis around which the somites adhered to as they evolved (Pourquié, 2003).

2. Schmorl's nodes are asymptomatic. Whether or not Schmorl's nodes are asymptomatic was much more problematic when studying the skeletal samples because, unlike the clinical groups, no data existed indicating the symptoms, if any, suffered by any or all of the people. The clinical profiles produced from the radiographic image observations were compared with macroscopic data gathered for each of the skeletons studied. Schmorl's nodes rupturing the posterior wall, recorded as compression of the spinal cord, could have caused great segmental disturbance and limb weakness and/or organ impairment at the level of the posterior Schmorl's node.

3. Almost all Schmorl's occur in the first two decades of life has been an accepted truth (Stirland, 2005: 184 and Hamanishi, 1994) so, to prove or disprove this belief all subadult vertebrae were macroscopically studied for herniated vertebral end plates, irregular end plates, and any retracted end plates.

4. Schmorl's nodes, when not centrally, placed in the vertebral end plates, cause instability to the dynamics of the vertebral column. This required reassembling the

vertebral columns of the archaeological samples and viewing them from the antero-posterior and lateral positions. Excess curvature of the primary and secondary spinal curves was considered as well as scoliosis, loss of lordosis and retrolisthesis. Slight compression to the left or right lateral aspects of the vertebral bodies was noted as several consecutive vertebrae with same side loss of height can begin to form a slight curvature to the opposing side.

5. Different work patterns cause Schmorl's nodes at varying levels in the thoracic and lumbar spine. The study of coastal, urban and rural populations who were associated with military, a coastal monastic church community, a city monastery, an agricultural settlement and a country estate, might highlight those differences.

6. The distribution of Schmorl's nodes remains constant through time for males and females of a similar age at death in different archaeologically derived populations, and clinical groups of corresponding ages. Testing this hypothesis required a good mix of ages within each sample and populations from different periods of time, which was fulfilled by the chosen samples.

7. The different appearances of Schmorl's nodes have different origins and underlying causes. Using diagnostic radiography as a medium for this study allowed some of the possible different types of Schmorl's nodes to be radiographed and the results to be studied to classify them.

8. Underlying pathologies, deformities, and irregularities of the pelvis and variations of leg-length cause disruption to the dynamics of the vertebral column and Schmorl's nodes. This last hypothesis could not be fairly tested on the archaeological materials as

so few skeletons retained the full complement of pelvic and lower limb bones.

### 5.1.2 Captain's Cabin, Castle Park, Dunbar, East Lothian, Scotland

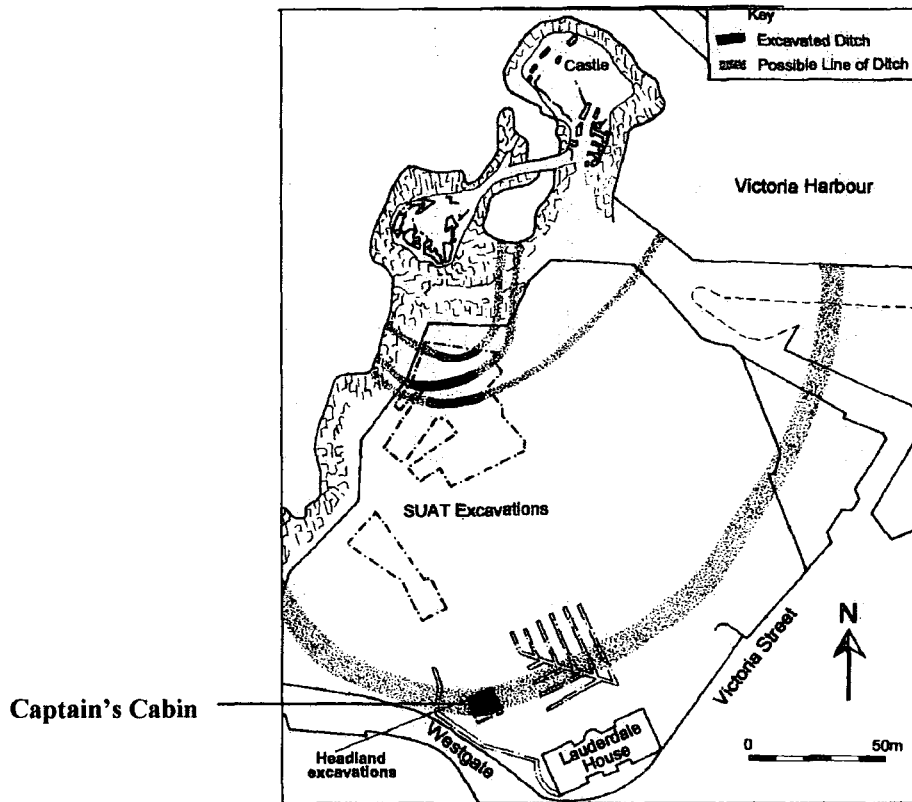


Figure 5.2 Map showing location of Captain's Cabin, Dunbar, East Lothian, Scotland (from Headland Archaeology Ltd.)

Dunbar was established in an area of geology consisting of cores or plugs of long dead volcanoes, shaped and smoothed by the receding ice and melt waters, carrying boulders, clay, sandstones and mudstones. This rocky promontory situated at NT678791 has been almost completely reclaimed by the waters which helped to form it during and after the last ice age (Anderson and Oliver, 1986; Xu and Tarling, 1987). Situated on a promontory at the mouth of the estuary of the river Forth on its southern bank where it meets the North Sea, Dunbar is a natural site of defence. Dunbar is recognised as being rich in archaeology from the Iron Age to English Civil War (Fig. 5.2). First mentioned as a place name in ecclesiastical documents by the Northumbrian Synod, Dunbar was the place of imprisonment of St. Wilfred in 680 AD (Miller, 1830). In 853 AD King

Kenneth I (McAlpin), the first king of Scotland to unite the Scots and Picts (Barrell, 2000), sacked and burned the town of Dunbar before withdrawing to his stronghold in Teviot Dale. This action of the 1<sup>st</sup> Scottish King as opposed to warlord, shows that he must have met with serious opposition to this union in Dunbar and the old area of 'March'.

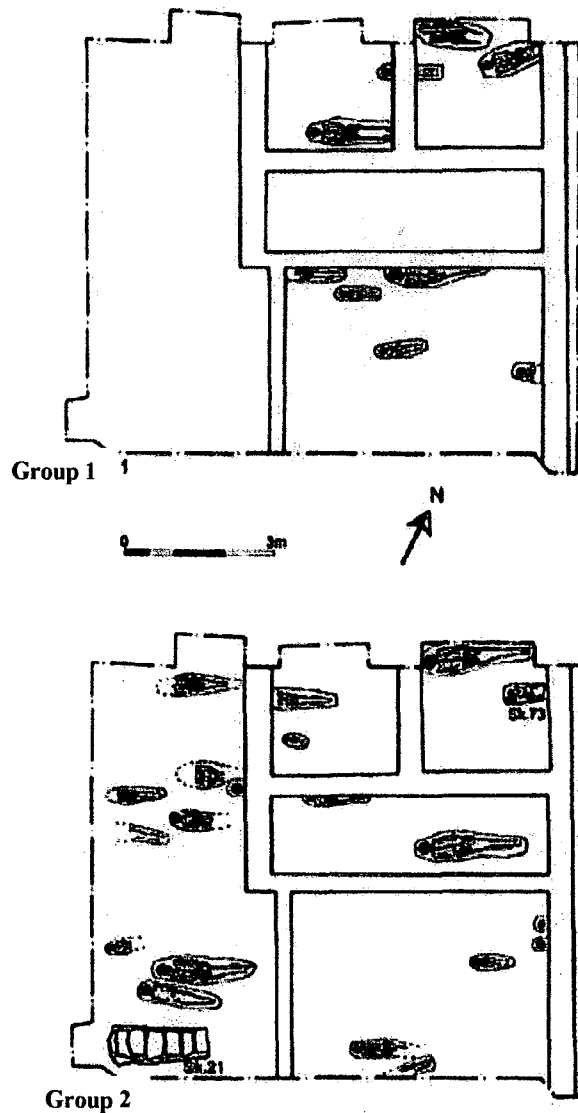
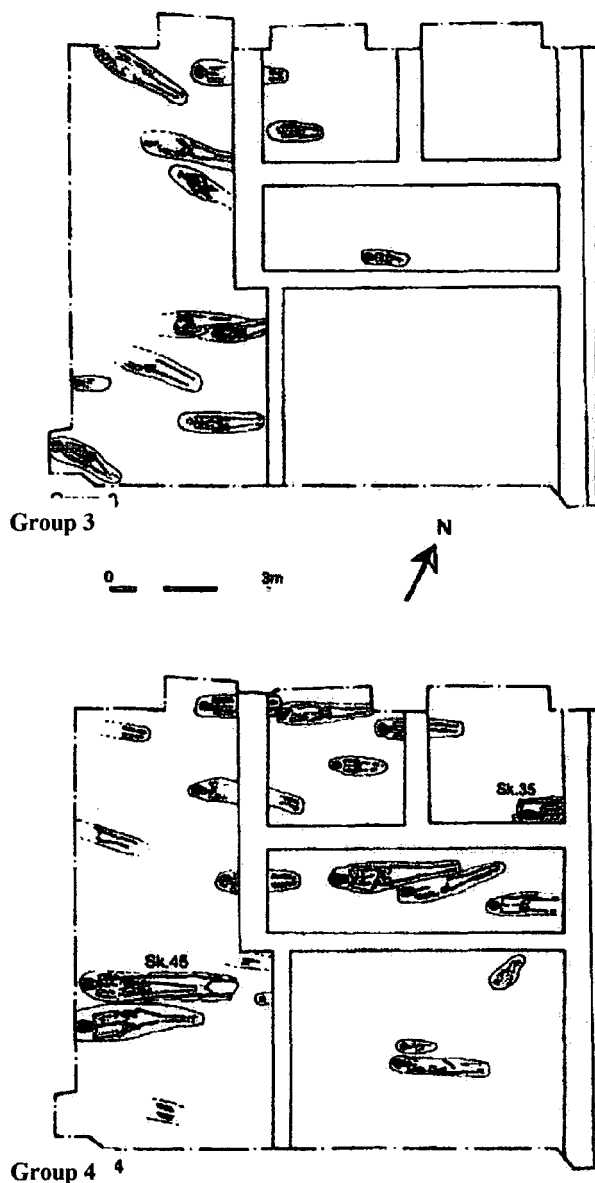


Figure 5.3 Captain's Cabin, Dunbar, burial plan for groups 1 and 2 (from Moloney, 2001)

The built environs of Dunbar commenced as an Iron Age hill fort, the same site being re-utilised as an *urbs regis* in the 8<sup>th</sup> and 9<sup>th</sup> centuries. This first re-build may well have been a peel tower around which the castle and its precincts evolved. During the English Civil War Oliver Cromwell defeated the Covenanters at Dunbar, and five years later

paid towards the rebuilding of this strategic defensive port which had been raised to the ground. The French then re-fortified the headland in the 16<sup>th</sup> century before the castle environs settled into a merchants' and traders' town. During the Crimean War, British troops re-occupied the site (Turner, Simpson & Stevenson, 1981).



**Figure 5.4 Captain's Cabin, Dunbar, burial plan for groups 3 and 4 (from Moloney, 2001)**

Captain's Cabin was originally built as the Lock House of the military barracks (Perry, 2000: 10-11), and after the closure of the military site it was turned into a gift shop and ice cream parlour and given its name of 'the Captain's Cabin'. The site was excavated

in 1998, ahead of a toilet block being built on the site. Possible inhumations were expected as previous excavations in 1989 and 1993 at nearby locations had uncovered human remains, but no cemetery boundaries had been defined. Seventy-six articulated skeletons (Tables 5.2 and 5.3) and fifty-one sets of disarticulated bones were recovered from this site, relating to the third phase of the excavation (Moloney, 2001). These were Christian burials orientated east-west, with the skeletons all in a supine position with their hands crossed on the pelvis and an absence of grave goods. Grave cuts were difficult to identify as several layers of bodies had been interred over several hundred years. Figures 5.3 and 5.4 each show two probable but not clearly delineated levels of interment within the excavated area. Simple shroud burials without coffins had taken place with many shroud pins being found, the exception to this being four cist burials, one of which had been used on four occasions with the previous skeletons all placed at the east end of the cist. Radiocarbon dating of eight skeletons places the cemetery's use between the 9<sup>th</sup> and 11<sup>th</sup> centuries AD.

Noticeable in this sample were the high number of immature remains (Table 5.2) at 48% (37 skeletons), which is much higher than observed for many Medieval populations (Roberts and Manchester, 1995). Two subadults had perimortem blade injuries to the skull; these were the only two injuries which probably resulted in death and only five further blade injuries of a non-life threatening type were reported. This unusually high mortality rate in subadults may be due to incomplete excavation, as the cemetery boundaries are not recorded, or to the excavation area being centred over an area reserved for child burials, a practice now recognised as occurring within many early Christian sites in Britain (Lewis, 2000; Roberts, 2001). Every skeleton containing the thoracic and lumbar vertebrae within this group was studied (Tables 5.2 and 5.3).

The National Museum of Scotland, curates the Captain's Cabin sample, in an outreach store in Leith, Midlothian.

	ADULT MALES	ADULT FEMALES	ADULT UNSEXED	SUB-ADULTS (<20 years)
Numbers excavated	13	21	9	37
Numbers studied	8	8	1	9

**Table 5.1 Gives the number of skeletons excavated at the Captain's Cabin site, and the number of skeletons studied**

PERI-NATAL	0-5	6-10	11-15	16-20
1	2	2	3	1

**Table 5. 2 The number of subadult vertebral columns studied from the Captain's Cabin sample by age group**

	21-25	26-35	36-45	45>
MALE	0	5	5	5
FEMALE	0	3	3	2
UNSEXED	0	0	3	0

**Table 5. 3 The number of adult vertebral columns studied from the Captain's Cabin sample by age group**

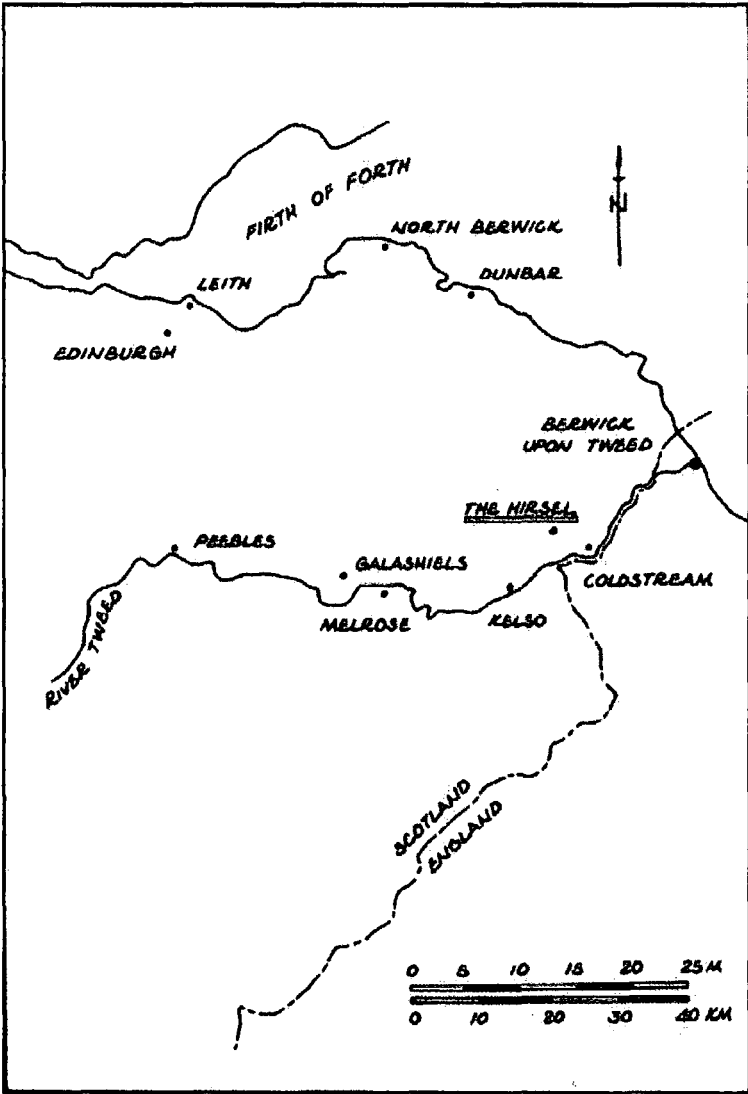
Environmentally this site was set in a harsh climate on a headland jutting out into the North Sea. The steep landward slope afforded little or no shelter from the ferocious landward winds and precipitation. The geology of this part of the coast is Silurian strata overlain by old red sandstone rocks with a thin covering of red boulder clays intermittently intruded upon by volcanic rock (Perry, 2000: 1-2). Erosion of topsoil and lack of shelter allows only subsistence farming augmented by inshore fishing.

Environmental sampling has shown a diet high in oats and barley, supplemented with small amounts of wheat. This small settlement is even today isolated and wind swept, and has not expanded far from its original castle precinct and ribbon settlement along the High Street of Dunbar (Electronic Scotland, 2005). Traditionally, the women and children undertook the cultivation of crops and animal husbandry, along with all household chores, leaving the men to maintain the fortifications and to harvest the inland waters during times of peace, and to take up arms in times of conflict (Crawford, 1987). The lives of the male, female, and subadult population would have been physically hard, and short lived, with the added risk of premature death during pregnancy and childbirth for the female (Bitel, 2002).

### 5.1.3 The Hirsell, Coldstream, Berwickshire, Scotland

Situated on the Merse, or March of Berwickshire, the geology of this area is a red-sandstone rock with intrusions of volcanic lavas sitting within a carboniferous fault of magnesian limestone (Whittow, 1977). The Hirsell site was situated in this fertile plain at NT830406 to the north of the river Tweed, bounded to the east by the River Leet, near to the town of Coldstream in the Scottish borders (Fig. 5.5), and within the present day estate of the late Lord Douglas Home in the county of Berwickshire (Cramp, 1979). This estate was part of the lands owned by the Dunbar family, who also held Bewick Estate and Old Bewick Church, in Alnwick, Northumberland (Cramp & Douglas-Home, 1977-8). The *Dial Knowe* or Low Field area of the cemetery was overlain by glacial gravel and sand, and lower down the hill red boulder clay sealed the clay subsoil (Cramp, 1981). This good alluvial land on a slightly raised, almost level, area within the flood plain of the River Tweed supported intense mixed farming. Extended and altered in the 12<sup>th</sup> century, this 10<sup>th</sup> century estate church of the Hirsell saw one further phase of growth in the 13<sup>th</sup> century when a bell tower was added at the west end of the church,

before re-dedication by the bishop of St. Andrews (Yeoman, 1995). By the 16<sup>th</sup> century, the Hirsal church was no longer mentioned in the *Coldstream Cartulary*, confirming the archaeological findings of radical alteration to the church to allow domestic habitation (Cramp, 1980). The Hirsal's connection to the Cistercian Nunnery of Coldstream may indicate a female house where an abbot and lay brothers managed farmed the lands around the Nunnery (Burton, 2002).



**Figure 5.5 Map showing location of The Hirsal, Coldstream, Berwickshire (by R. B. McNaught, 2006)**

Conclusive proof of a pattern of settlement is as yet still absent (Cramp, 1982) but, if the

theory of an early estate church is correct, then a landlord and retainers must have existed, and those people would have been the population interred within the Hirsell cemetery, along with the ecclesiastical incumbents. The Hirsell church, after final alterations, became domestic dwellings and storage areas during the 16<sup>th</sup> century, which may coincide with the dissolution of the monasteries or in a change of land management (Cramp, 1984). This was a Christian burial site with the grave cuts aligned east-west, lacking in grave goods and with many early grave markers ploughed out. The number of skeletons excavated was 331 (Table 5.4) with 45.3% (150 skeletons) aged from perinatal to subadult (Anderson, 1994). This high mortality rate in subadults (Table 5.5) cannot be accounted for by incomplete excavation as the cemetery boundaries were recognised and surveyed, with all inhumations recovered. However, acute infectious disease cannot be ruled out as the predominant cause of premature death, as no skeletal pathological markers would have developed if only a short period elapsed between the onset of illness and death (Roberts and Manchester, 1995: 9). Dyer (1989) describes the plight of the poorer members of the peasant population in rural settlements who suffered deprivations in their diet, with disease and periods of arrested growth in subadults. The Royal National Museum of Scotland curates the Hirsell sample, in an outreach store in South Queensferry, Midlothian.

	ADULT MALES	ADULT FEMALES	ADULTS UNSEXED	SUB-ADULTS (<20 years)
Numbers excavated	85	88	8	150
Numbers studied	33	25	0	26

**Table 5. 4 Gives the number of skeletons excavated at the Hirsell site, and the number of skeletons studied**

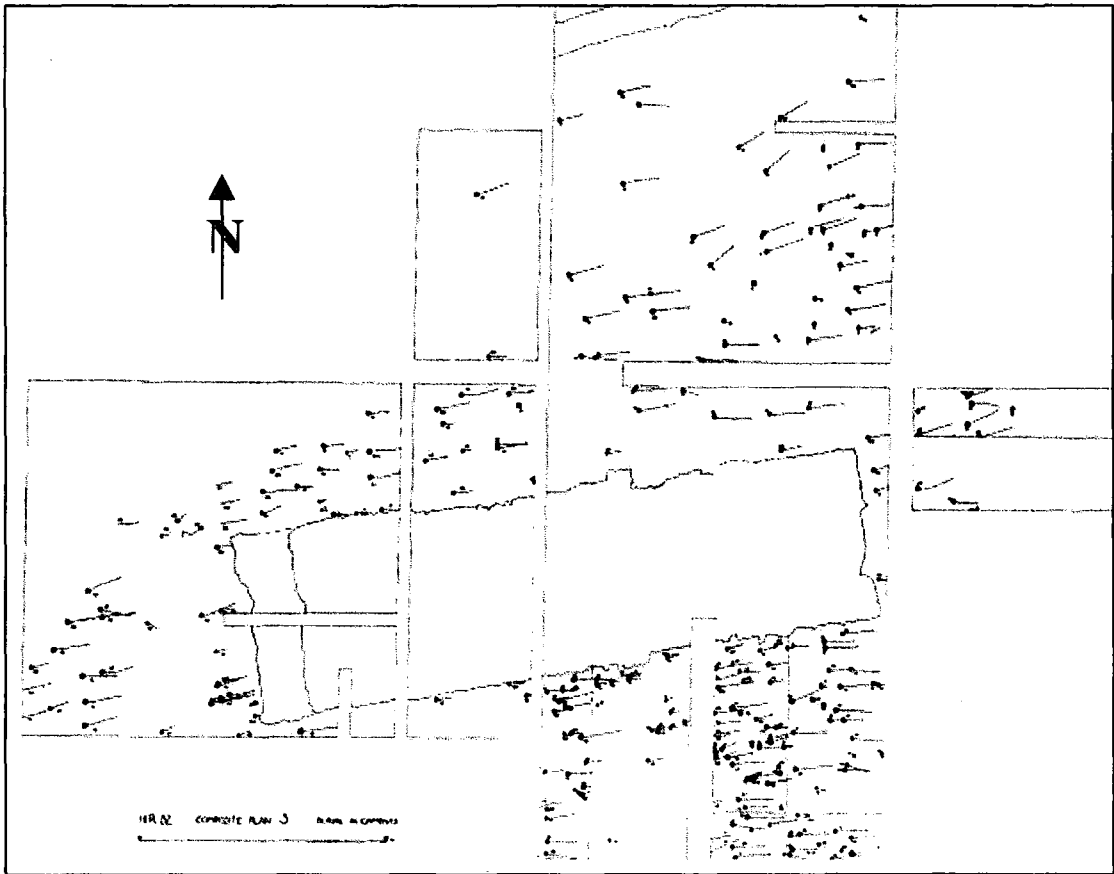
Peri-natal	0-5	6-10	11-55	16-20
2	3	10	2	3

**Table 5.5 The number of subadult vertebral columns studied from the Hirsell sample by age group**

	21-25	26-35	36-45	45>
MALE	2	8	8	12
FEMALE	6	7	5	3
UNSEXED	0	0	0	0

**Table 5.6 The number of adult vertebral columns studied from the Hirsell sample by age group**

Adult male and female skeletons recovered from the Hirsell cemetery were almost equal in number (Table 5.4), but the number of males living to more than forty-five years within the population as a whole (Anderson, 1994), and the number of skeletons studied, shows a much greater longevity for males compared to the females (Table 5.6). The results of environmental sampling and analysis are not yet available to give a definitive picture of the likely nutritional status of the Hirsell population. No adults died a violent death, but many had ankle trauma, which was not determined in the initial skeletal report as being work related or accidental (Anderson, 1994). Radiocarbon dating of any of these skeletons, if undertaken, has not yet been reported. The dating, if found to be closer to the thermoluminescence date of the 6<sup>th</sup> to 9<sup>th</sup> century AD the pottery sherds found within burial infills of sand and fine gravel, and the presence of many cist burials (Cramp, 1981), would place it in the earliest part of the Medieval Period. A date placing the site in the 6<sup>th</sup> to 9<sup>th</sup> century AD would make it the most complete Early Medieval burial site discovered in the borders of Scotland (Anderson, 1994).



**Figure 5.6 The Hirsell cemetery site plan, Coldstream (from Cramp, unpublished)**

No settlement is present on this site today, and no archaeological deposits later than the 16<sup>th</sup> century are recorded during the excavations undertaken by the University of Durham, under the supervision of Professor R. Cramp (1979-1984). At the time that this research was carried out no further information about the possible work patterns, and lifestyle of this isolated rural population close to the River Tweed was available.

#### 5.1.4 Whithorn Priory, Whithorn, Galloway, Scotland

The Isle of Whithorn, once separated from the mainland of Galloway, and now connected by a causeway constructed in the 1790s during the rebuilding and extension of the harbour, remains isolated on an isthmus of land protruding into the Irish Sea. Once thought to be the place of *Candida Casa*, founded by Ninian on his return from Rome and seen as the cradle of Christianity in the north; it became a place of great

learning, conversion and pilgrimage (Oram, 1990). One hundred years later, St. Cuthbert's Christian settlement of Iona overshadowed Whithorn and the miracles of St. Ninian as St. Columba, the warrior turned Christian and law maker of the church, gained accession to the routes of pilgrimage (Ross, 1998). Excavations by the Whithorn Trust rewrote the history of the original church, placing it on the mainland at NX479362 (Fig. 5.7), and relegating the island building to a place of retreat, and perhaps the first place where pilgrims brought by sea alighted and gave thanks before proceeding to the shrine/church of Whithorn (Hill, 1997: 5).

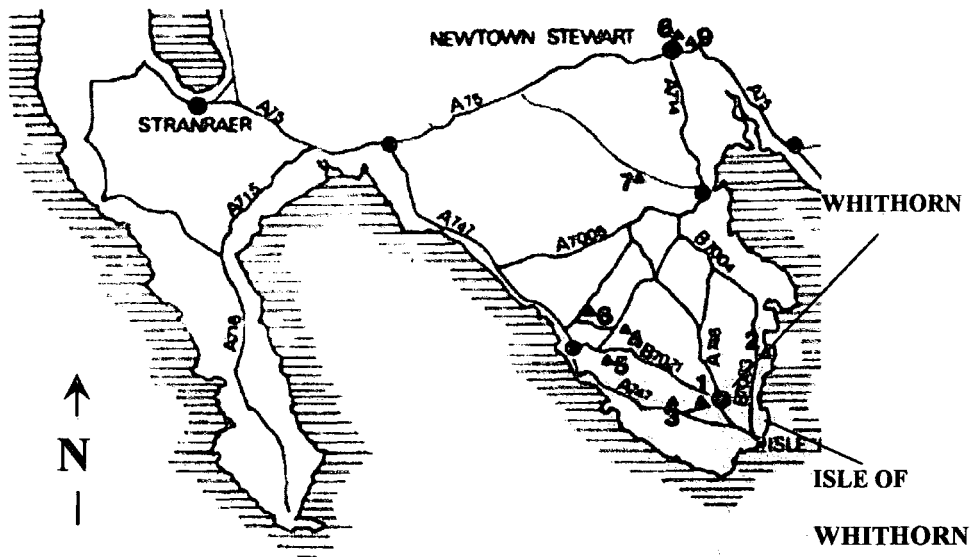


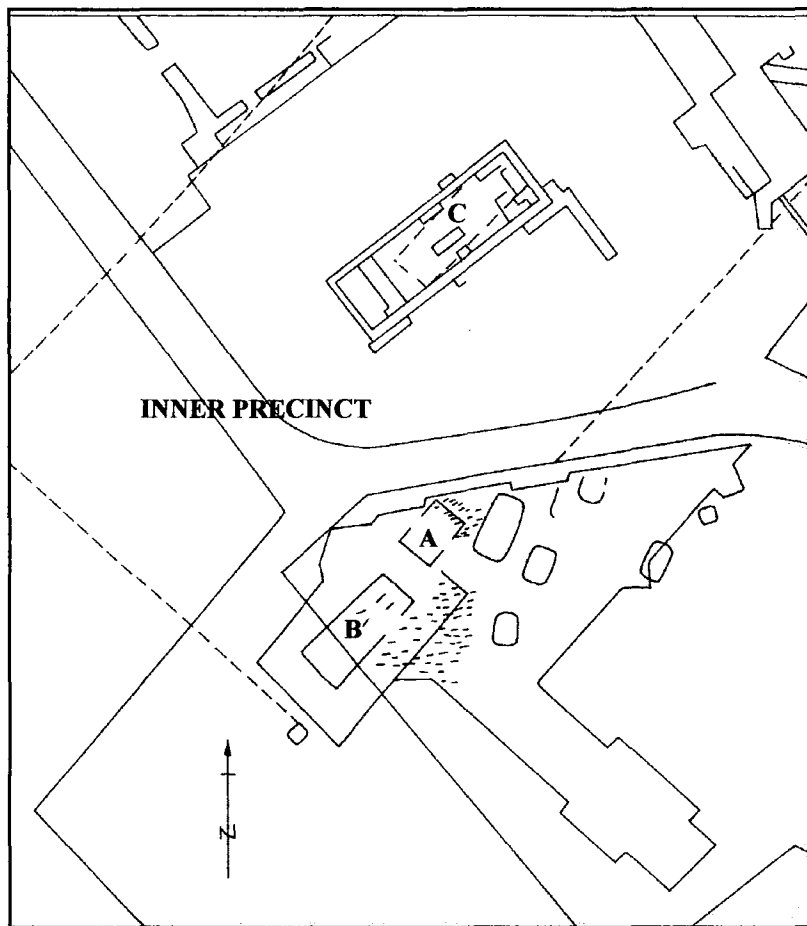
Figure 5.7 Map showing location of Whithorn and Isle of Whithorn, Galloway (from Oram, 1990 :1)

A main road crosses the earliest phase of the site, continuing down to the Isle of Whithorn showing a connection as early as the 5<sup>th</sup> century AD when a wattle and daub church may have predated the earliest stone church (mentioned by *Bede* in his *Ecclesiastical History of the English nation as, Candida Casa,* ) (Bede, 1859: 673-735; Dumville, 1987: 49-51). The priory of Whithorn sits on top of a glacial drumlin consisting of a mixture of greywackes used for flooring and walls, shales that split like

slate used for roofing, and mudstones carved to form spindle whorls and hones and other small tools. Greywackes are geologically immature sedimentary rocks formed on the seabed containing fine gravels, sand and quartz particles (Bennison and Wright, 1969). The priory of Whithorn was bounded to the north and east by the Ket burn, and may have been enclosed by a boundary ditch.

Around and within the church and later cathedral of Whithorn, the cemetery spans a period of five centuries. The earliest phase of burials sits within the 5<sup>th</sup> and 6<sup>th</sup> centuries, and the later phase represents the 13<sup>th</sup> to 15<sup>th</sup> centuries, with the earliest burials centred on three shrines, and the later phases of burials overlying the earlier burials, with all grave cuts aligned east-west with small seasonal variations. The alignments of grave cuts in the Early Medieval Period were made in relation to the position of the early morning sun, which alters not only its time of rising through the seasons, but also its position along the earth's horizon.

The skeletal remains studied for this thesis are those from Periods I and II (area B), and dated by radio-carbon dating to between the sixth and tenth centuries AD. The Period I and II skeletons are curated in the Department of Anatomy of Marischal College, Aberdeen. The peri-natal, neonatal and infant skeletons (area A) from the eastern end of the Northumbrian Minster (wooden church, 730 AD to 845 AD) of Whithorn are curated in the Stranraer Museum, Galloway, Scotland. At the request of the local inhabitants of the town of Whithorn, a large number of skeletons were re-interred on the priory site leaving us with an initial analysis of the bones and a lost research opportunity (*pers comm.*, Amanda Cardy, August 2004). One thousand, six hundred and five skeletons were excavated and, of those, only 19 % (305) were of fair or moderately good preservation.



**Figure 5.8** The Whithorn subadults are buried to the external east end of the wooden church (A) of the Northumbrian Period, and the adults are buried internally and externally to the early church (B). C is thought to be the principal church, with A and B set upon three earlier shrines (R. B. McNaught, 2006)

The subadult skeletons including peri-natal, infant and child made up 31.9 % (512) and, of these, many were in a very poor state of preservation. Skeletal preservation was poor due to the acidity of the shale within the grave cuts; only where cists and log coffins had been used for internment was preservation fair to good. The skeletons retained for research numbered one hundred and sixty seven of which only thirty-nine retained all or parts of the thoracic and lumbar vertebrae (Tables 5.7 and 5.8).

Peri-natal	0-5	6-10	11-15	16-20
0	0	7	7	8

**Table 5.7** The number of sub-adult vertebral columns studied from the Whithorn sample

	21-25	26-35	36-45	45>
MALE	1	0	2	3
FEMALE	1	0	3	2
UNSEXED	1	1	1	2

**Table 5.8 The number of adult vertebral columns studied from the Whithorn sample**

This wild south-western tip of Scotland where the Atlantic ocean and Irish sea meet has a very high rainfall and a short summer, making farming of arable crops very limited; as has been shown by Huntley (1997), barley and oats, with a few varieties of brassica, were the main staples. The incumbents of Whithorn Priory harvested the sea as a source of food providing a diet of salmon, cod, eel and plaice (Hamilton-Dyer, 1997). Cattle and pig were plentiful, but very few sheep bones were found within the environmental samples recovered from Whithorn priory's middens, which is not unusual for Scotland (McCormick and Murphy, 1997). Even today, scrub and ling, with few trees and large areas of peat bog, cover much of the land within the county of Galloway. Life expectancy in Whithorn at this period was not great with only 10% of the population living past 40 years of age (Cardy, 1997). Whether premature death was due to infections or other disease cannot be ruled out, but no bony markers were present to identify such episodes of ill health in the 40-50 year age category identified by Cardy (1997) in both males and females.

Evidence of workshops producing horn combs and needles, iron tools, leather, lead casting, silver and gold smithing were all present (Nicholson, 1997: 359-509). Sea-trade and rich pilgrims may have been the reason for skilled craftsmen setting up workshops around the perimeter of the monastic enclave. Many spindle whorls, and several loom weights, as well as a few possible weaving tablets, were found, representing at least domestic textile production within the Whithorn settlement (*ibid*, 1997). Dyer (2003:

69) refers to Whithorn as “too small to be called a town” and a place of craft working (*ibid*: 69), known especially for “fine bone combs”. Whithorn Priory would have been the biggest employer in the area, with the Bishop, monks and novices housed, fed, and clothed, by lay brothers and serfs. Healthy, sick, or infirm pilgrims would have needed shelter as well as spiritual and physical healing, all of which would have required a large number of staff. Grange farms would have provided meat, grain, wool, leather, tallow and dairy products, and the sea, fish for the Priory’s day-to-day requirements. The Northumbrian synod, placed their Bishops at Whithorn Priory, enforced Northumbrian ecclesiastical laws upon Whithorn’s monks from the 5<sup>th</sup> to 9<sup>th</sup> century, where previously a close alliance to the Irish Episcopate had existed (Yeoman, 1999: 44-45). This enforced alliance of Whithorn Priory to the Northumbrian Kings and synod came to an abrupt end in 845 AD when either Alpín, a Scottish warlord, burnt down the Northumbrian Church of Whithorn, or Viking raiding parties laid waste to the great monasteries of Ireland extinguished the wooden Church (Hill, 1997: 20-21).

#### 5.1.5 St. Andrew, Fishergate, York, England

The St. Andrew Fishergate site sits to the west of the Walmgate area of the city of York, close to the Roman road which passes through Walmgate Bar and heads directly for St. Peter’s Cathedral, which is built directly on top of the Roman administrative buildings of the Emperor Augustus. The Gilbertine Priory of St. Andrew, Fishergate is sited at SE606511 (Fig. 5.9); York has been an ecclesiastical city of importance since the 8<sup>th</sup> century when the Pope named the bishop of York primate of all England. Throughout the Medieval period, there was constant rivalry with the ecclesiastic court of Canterbury for the most senior position of Archbishop of all England (Hall, 1996). By the time of the earliest burials at Fishergate, York was a successful centre for crafts and industry as

well as a sea trading port with Europe and the Netherlands, having rich burgesses and traders as well as serfs and indentured workers.

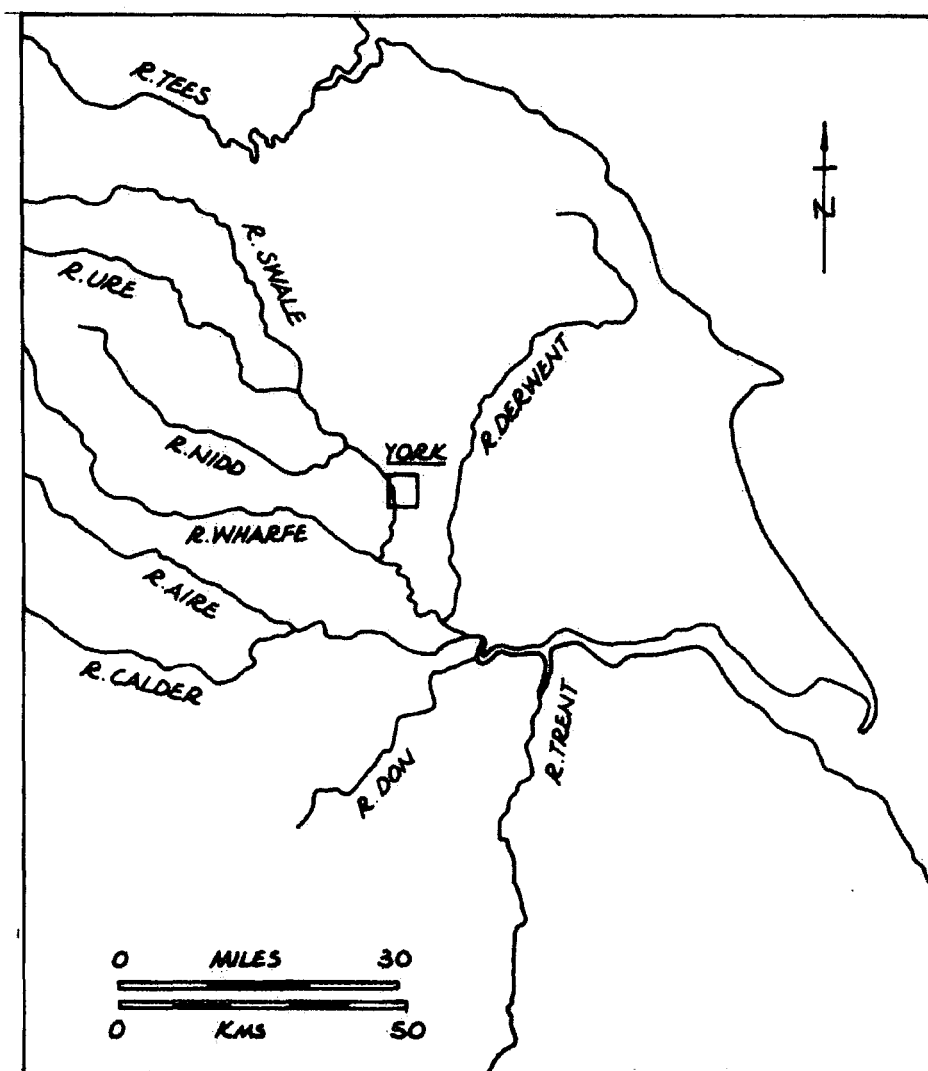


Figure 5.9 Map showing location of the city of York (R. B. McNaught, 2005)

Two previous churches stood on the Fishergate site before the Gilbertine Priory superseded them with its double house, allowing the entry of both nuns and monks to this order (Stroud and Kemp, 1993). Two phases of graves were excavated, each relating to a church's life span, with some intercutting and overlapping of grave cuts, making certain areas inseparable as grave goods were absent as dating evidence

	ADULT MALES	ADULT FEMALES	ADULT UNSEXED	SUB-ADULTS (<20 years)
Numbers excavated	220	89	3	90
Numbers studied	117	39	2	36

**Table 5.9 Gives the number of skeletons excavated at the Fishergate site, and the number of skeletons studied**

Peri-natal	0-5	6-10	11-15	16-20
0	13	11	8	4

**Table 5.10 The number of sub-adult vertebral columns for each age group studied from the Fishergate sample by age group**

	21-25	26-35	36-45	45>
MALE	26	24	38	29
FEMALE	5	8	18	8
UN-SEXED	1	0	1	0

**Table 5. 11 The number of adult vertebral columns by age group studied from the Fishergate sample by age group**

Four hundred and twelve skeletons were located and 402 were excavated, as were 37 charnel deposits (Table. 5.10). The burials in this cemetery were Christian in orientation with the skeletons interred with feet to the east and heads to the west, and the hands crossed on the pelvis or chest (Kemp & Graves, 1996). The number of individuals studied was 199 (Table 5.9), these were grouped by age, sex and maturity (Tables 5.10 and 5.11). Two burials were distinctly different, the first being a prone burial and the second with the head to the east and feet to the west; these could have been positioning or orientation errors rather than deliberate burial practices (Stroud and Kemp, 1993). Two distinct phases of burial exist, those of the parishioners worshipping within the

earlier churches of the 11<sup>th</sup> and 12<sup>th</sup> centuries, and the 13<sup>th</sup> to 16<sup>th</sup> century canons and their rich merchant and lordly benefactors of the Gilbertine priory (Kemp and Graves, 1993).

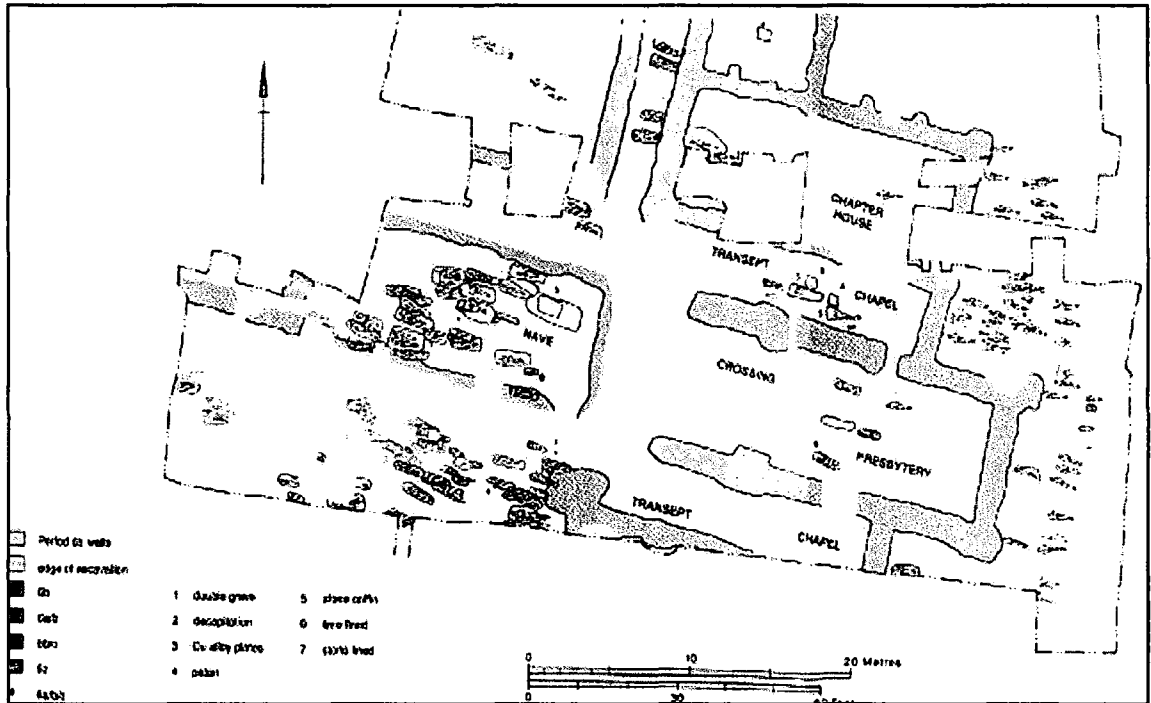


Figure 5.10 Cemetery plan of St Andrew, Fishergate (from Stroud & Kemp, 1993: 128-129)

Environmental sampling showed consumption of relatively high quantities of wheat, beef, salt-water fish and fresh water fish, as well as fruit. This population included people from every level of society, living in a city already densely occupied by religious houses and relying on food brought in from the surrounding area, as the plots allocated to each religious house could not sustain those living within, and those living without would not have space to grow their own food. Dyer (1998: 192-3) discusses how the bones of the individuals of St. Helen's on the Walls, displayed many Harris lines and ridging of tooth enamel, providing evidence of diet deficiencies and disease within part of this urban population. However, the individuals interred in the cemetery of the Gilbertine priory of St. Andrew, Fishergate were not observed as suffering from poor diet or crowded living conditions. The environmental samples analysed may be

biased to those members of the Gilbertine community of the priory rather than the population as a whole, and this appears to be confirmed by the number of males suffering from diffuse idiopathic skeletal hyperostosis discovered in the area to the east of the church. Diffuse idiopathic hyperostosis has, as mentioned previously, been associated with monastic communities (Rogers and Waldron, 2001). The area to the east had been identified by the grave goods of pattens and goblets, as the preferred burial site of the Gilbertine monks of high status (Stroud & Kemp, 1993).

#### 5.1.6 Tanners Row, Pontefract, West Yorkshire, England

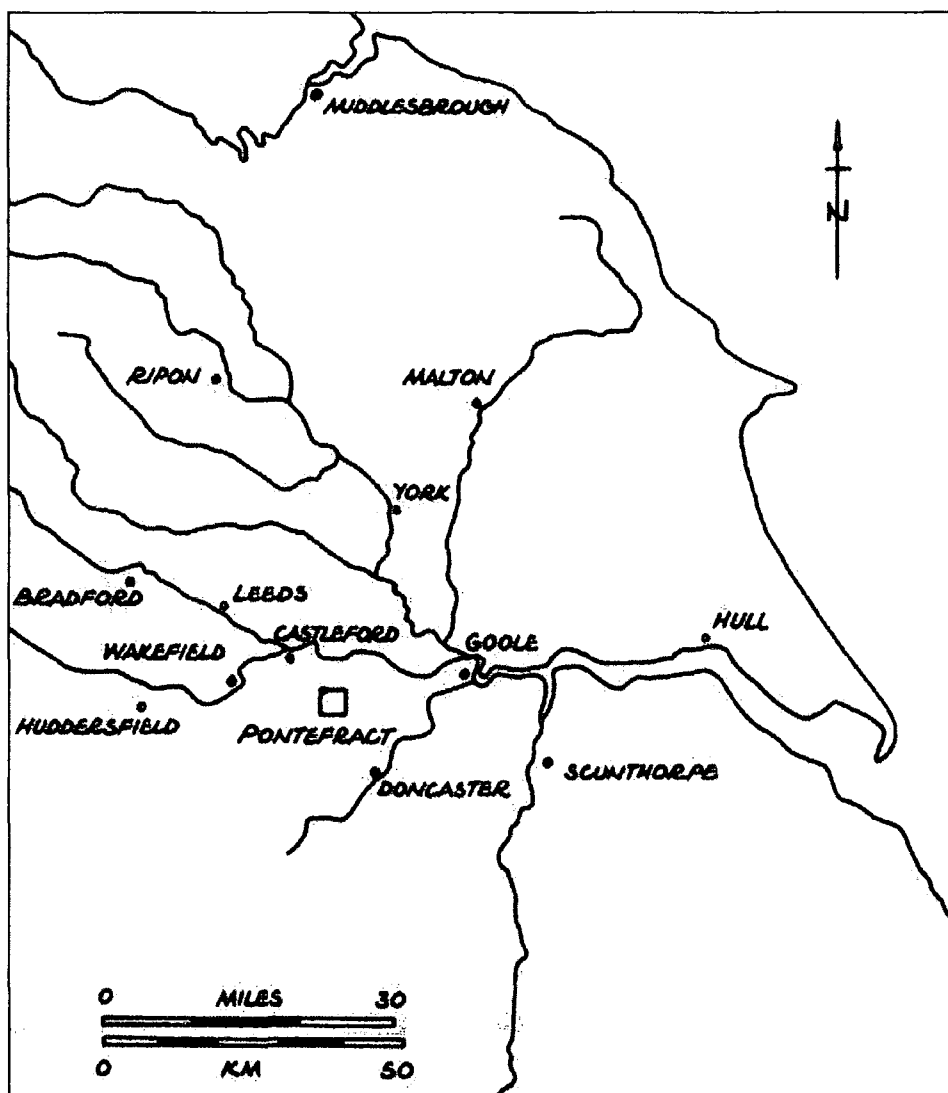
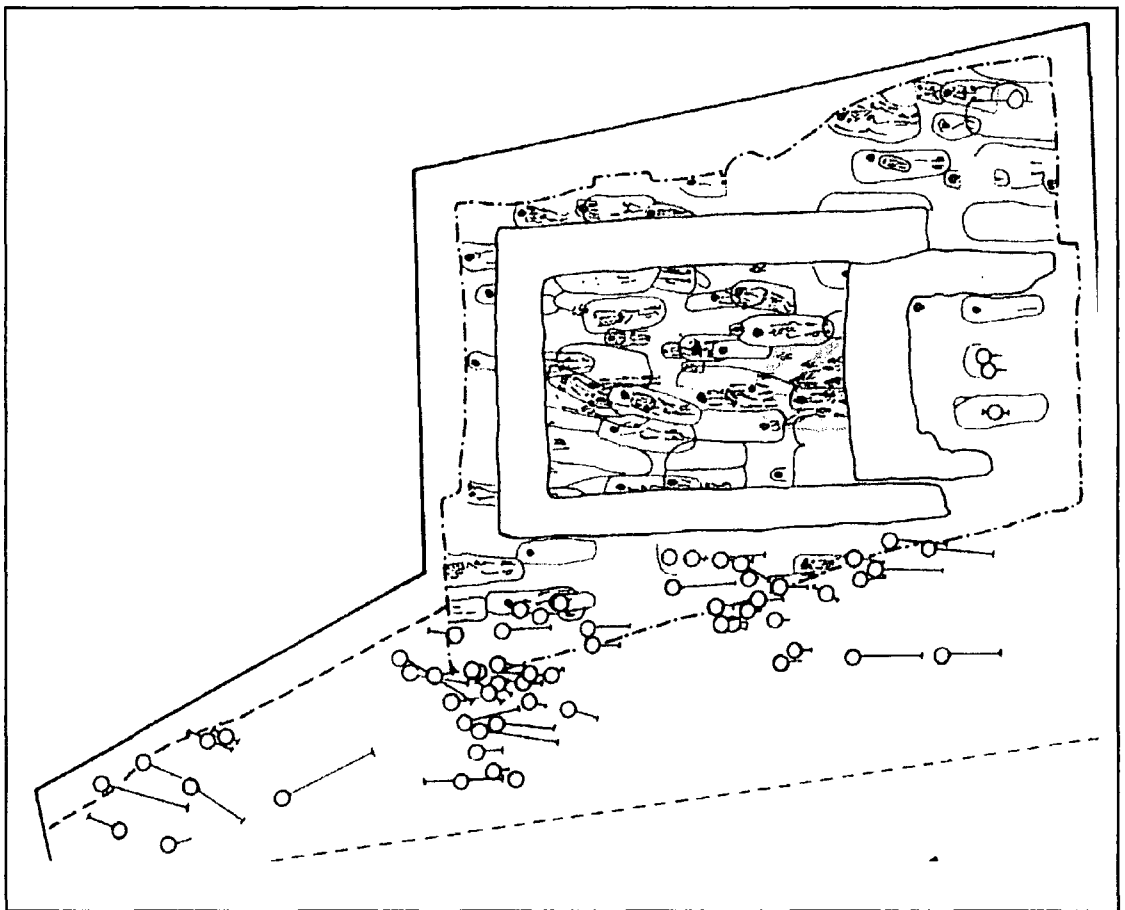


Figure 5.11 Map showing location of Pontefract (by R. B. McNaught, 2005)

This cemetery sits within an area of Pontefract between the medieval castle and church, on the eastern edge of the modern day town (Fig. 5.11). First known by the name of Pontefract in the 11<sup>th</sup> century, Simeon of Durham first mentions the area as *Kirkebi, Taddenessclyf* and it is here that King Eadred accepted the allegiance of the Northumbrians and Archbishop Wolfe in 948 AD (Ingram, 1912). Named in the Domesday book as *Tateshalle* it was already a thriving town with 60 burgesses, sitting comfortably alongside York as a place of wealth and commerce.



**Figure 5.12 Tanners Row Anglo Saxon cemetery with the subadult burials shaded in blue  
(West Yorkshire Archaeology Service, unpublished)**

The cemetery of Tateshalla or Tanshelf was cut into a red sandstone and a shale shelf, and sat within predominantly magnesian limestone geology, forming an acid

environment (*pers comm.*, Tony Wilmott 09/09/2002) at SE464213. The skeletons were aligned east to west with their hands either resting on the pelvis or by their sides, heads to the west and feet to the east. No grave goods were found; one small fragment of cloth was found within a grave cut and photographed but, due to its fragility, it did not survive excavation. The skeletal remains of this Christian cemetery were placed by radiocarbon dating within the range of 600 AD to 900 AD.

Excavation of approximately 178 burials (Table 5.12) took place in less than ideal conditions of snow and frost during one weekend in advance of a road widening and realignment scheme. Adult grave cuts reached through the red sandstone into the shale layers, which resulted in poor bone preservation, and in some instances sand shadows were all that remained. The infant burials at a shallow level did not suffer the same levels of erosion as they sat above the shale layers within the red sandstone. Further deterioration of the skeletal remains occurred when they were stored damp within large plastic sacks awaiting processing, this being a rescue excavation undertaken without the time usually taken to plan and underpin all aspects of an excavation. It was only at the end of the excavation that the first glimpses of the finely tooled ashlar blocks of the Anglo-Saxon Chapel of Kirkebi were uncovered, the infant burials could be firmly assigned to the nave at the east end of the church (Fig. 5.12).

	ADULT MALES	ADULT FEMALES	ADULTS UN- SEXED	SUB-ADULTS (<20 years)
Numbers excavated	39	23	18	98
Numbers studied	4	10	1	15

**Table 5.12 The number of skeletons excavated at the Tanners Row site, and the number of skeletons studied**

PERI-NATAL	0-5	6-10	11-15	16-20
0	9	2	3	2

**Table 5.13 The number of subadult vertebral columns studied from the Tanners Row sample by age group**

	21-25	26-35	36-45	45>
MALE	0	0	1	1
FEMALE	4	2	0	1
UNSEXED	0	0	1	0

**Table 5.14 The number of adult vertebral columns studied from the Tanners Row sample by age group**

Only 78 skeletons of the 178 excavated were of a condition fit for analysis in the initial report and, of those, only 30 had sufficient elements of the vertebral column to allow inclusion for this research (Table 5.12). Age and sex determination was extremely difficult due to the fragmentary nature of the skull and pelvis of each skeleton as well as the separation of cortical bone from cancellous bone at many joints and in the vertebrae (Lee, 1988). Life expectancy in the group was very low, with 56% (98) dying before maturity (Table 5.12), and 16% of the deaths occurring in the peri-natal and neonatal periods; a special area against the east wall and within the nave was reserved for these premature deaths. A second rise in infant deaths occurred at around one year when weaning might have occurred due to adult hunger causing cessation of lactation, or the need to feed a new born child (Fuller *et al*, 2006). This death rate is high even for a pre-industrial age population and, whether it is due to lack of hygiene, the presence of disease, or crop failure it is impossible to say as no skeletal stress indicators are present (Lewis and Roberts, 1997). Adults did not fare much better, with the majority of the 44% (80) reaching no more than 40-45 years of age (Lee, 1988).

The environmental picture of this site was fragmentary as a civil war siege ditch [recorded by Nathan Drake in his diaries of *The Three Sieges of Pontefract Castle* (Fox, 1987)] cut through the cesspits and Saxon ditches. Small numbers of freshwater fish bones, and eel bones were identified, as were oats, barley and wheat, although not enough data to be a representative sample. Ample fresh water was supplied by the tributaries of the Wash Beck, which ran to the north and south of Tanners Row, meeting to the east of the site (*pers com* Tony Wilmott, 01/01/06). Crops would grow well on this well drained loamy soil, and by the time of the Domesday Survey, the land supported nine ploughs, three mills and a fishpond (Williams and Martin, 1992; Roberts, 2002).

Table 5.15 summarises the characteristics of the five archaeological sites.

SITE	OS LOCATION	CENTURY AD	SETTLEMENT TYPE
Captain's Cabin	NT678791	9 -12	Coastal/Military site Defence/Farming/Fishing
The Hirsell	NT830406	10 -14	Rural estate with church Farming/fishing
Whithorn Priory	NX479362	6 - 9	Coastal, Monastic settlement Trade/Farming/Fishing/Pilgrimage 'Miracles' and Healing
Fishergate	SE606511	10-16	Urban, Monastic settlement Industry/Trade/Defence/Religion
Tanners Row	SE464213	6 -9	Rural estate with church Burgesses/farmers

**Table 5.15 The Medieval archaeological cemetery populations, their Ordnance Survey positions, the centuries they encompass, and the types of settlement**

## 5.2 Methods

### 5.2.1 Adapting clinical methods to archaeological recording

Changing from 2D data collection from clinical material to that of 3D visual data

gathered for the archaeological samples needed to be considered if the data were to be compared and contrasted to produce meaningful results. Clinical radiology protocols allowed the confident collection of data on disorders and diseases, as reported by qualified clinicians. Collecting skeletal data macroscopically was the responsibility of the author using work related knowledge, and suitable osteological methods (Roberts and Connell, 2004; Buikstra and Ubelaker, 1994). Three spreadsheets were developed for data collection for all clinical material (as discussed and illustrated in Chapter 4), and, with adaptations, were suitable for the osteological recording. The three archaeological sample forms that were adapted from the clinical recording forms were:

- i). Skeletal record (i.e. presence or absence of vertebra were now recorded)
- ii). Disorder record (i.e. a reduced number of disorders were recorded only macroscopically)
- iii). Other relevant information (i.e. calcified spinal ligaments, extra foraminae and deviation of posterior and lateral pedicles)

In addition to the three adapted forms, the use of radiographic imaging was felt to be a key recording medium for the skeletal material. Radiography was only undertaken where permissions had been received from curators, and movement of human remains were felt to be secure when stored and radiographed distantly from their places of curation. Photography was used to record both normal variants and unusual bony alterations to vertebral anatomy.

### 5.2.2 Macroscopic recording

#### (i) Age and sex determination

Analyzing skeletal remains requires age at death to be estimated as carefully as possible, but this is an area fraught with difficulties, as no two people will age in the same manner (Jones, 2005). Children, as they grow, have clearly defined maturation stages for the bones of the skeleton and, the development and eruption of the teeth, but even these can vary due to diet and illness (Scheuer and Black, 2004; Cox and Mays, 2000: 2). Most of the archaeological sites selected for this research did not have a published report of the excavation findings, but each site did have a human bone report, either published or ready for publication. Any estimations of age or sex varying significantly from the original were recorded within the 'other relevant information' for each skeleton, as this could have affected analysis. The methods used for maturity, age and sex estimation were those described in Buikstra and Ubelaker (1994), Bass (1987 and 2005), Scheuer and Black (2004) and Brothwell (1981). Lusted and Keats (1972), was also a useful reference tool as it covered subadult bony growth patterns in detail with many charts giving expected parameters of maturation, and acceptable deviations in maturation, in fusion data, and detailed anatomical drawings for each stage of maturation.

Subadult age estimation was dependent upon the state of preservation of the elements of each skeleton in the sample. If the mandible, maxilla and dentition survived then tooth bud presence, the stages of deciduous tooth eruption including cusp, crown and root formation, and tooth shedding, were all used as age indicators (Buikstra and Ubelaker, 1994: 50-51). The vertebral columns from the first cervical vertebra to the fifth sacral segment were assessed for fusion of the centra to the hemi-neural arches, and the union of the hemi-neural arches to form the posterior pedicles (Scheuer and Black, 2004). Stages of growth and fusion of the innominate bones where present, were assessed for stages of fusion of the ischium and pubis and ilium (Bass, 2005). Where diaphyses and

epiphyses of long bones where conserved and, depending upon the stage of epiphyseal and diaphyseal growth and union (if it had commenced), were used to age subadult skeletons (Scheuer and Black, 2004; McKern and Stewart, 1957). Adult skeletons were sexed where possible by analysis of the skull, mandible, and pelvis as described by Buikstra and Ubelaker (1994: 15-38). The supra-orbital ridge's prominence and thickness, the size of the mastoid process and the prominence of the nuchal crest were all used to determine sex. Presence or absence of the mental eminence along with mandible's breadth and angle were recorded and analysed. The greater sciatic notch's depth and the sub-pubic angles were recorded in the ilea and added to the other results. Due to the variations in preservation, sometimes only one or none of the three previously mentioned skeletal areas were present. Even with all three parts of the skeleton present and well preserved it was occasionally impossible to attribute sex to a skeleton. Where sexing was not possible, 'unsexed' was attributed to the skeleton, whereas if the majority of observations were male or female, but no definite attribution of sex was possible, a question mark preceded the male or female attribution.

(ii) Recording of vertebrae: vertebrae present and Schmorl's nodes

This first recording form for clinical data (Appendix 2) was produced to record data collected from the viewing of each set of radiographic images in the clinical setting; these carried a left hand column for cross-referencing as the original patient identity barcode was removed to protect the patient's identity, as agreed with the hospital's research co-ordinator. This form was used for the archaeological data and a further twenty-one columns were used to record the presence of each thoracic and lumbar vertebra, any sixth lumbar vertebra, spina bifida occulta, and the first sacral segment (Fig. 5.13), as the patients sex and age. All thoracic and lumbar vertebrae, as well as the first sacral segment were recorded for this research as the majority of Schmorl's nodes



was recorded as superior or inferior and, where both surfaces were affected, this was also indicated. Only variations in the normal number of thoracic or lumbar vertebrae e.g. six lumbar vertebrae instead of the usual five (Fig. 5.13) were recorded along with the positions of Schmorl's nodes. An explanation of the short codes used when recording the vertebrae and any Schmorl's nodes on the archaeological data collection sheet follows:

- T = Thoracic vertebra
- L = Lumbar vertebra
- S = Sacrum
- S = Superior vertebral end plate Schmorl's node
- I = Inferior vertebral end plate Schmorl's node
- S/I = Superior and Inferior vertebral end plate Schmorl's nodes
- SBO = Spina bifida occulta presenting in any or all segments of the sacrum
- An empty box represents no Schmorl's node, and no 6<sup>th</sup> lumbar vertebra

The unique clinical cross reference was replaced by each skeleton's individual reference, and the short code for imputing each separate vertebra was as follows:

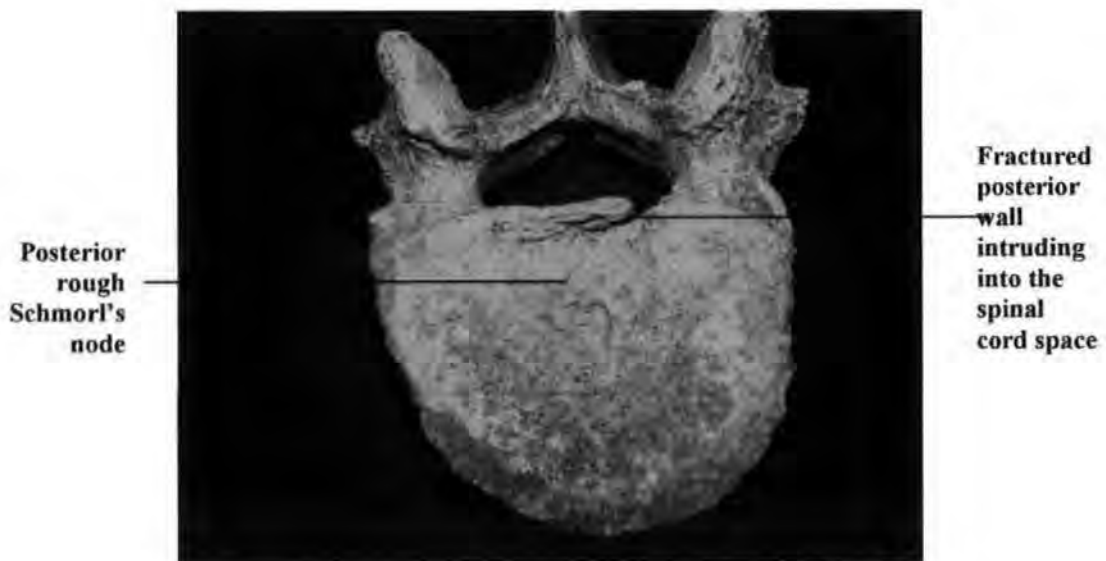
- P = Present
- A = Absent
- # = fractured vertebral body, but all pieces present

The adapted spreadsheet for the collection of archaeological data needed no further alterations. Every vertebral column for each cemetery population was studied and records completed. Incomplete vertebral column data was retained for use in future

research, and only included in this study in relation to the first hypothesis that, ‘the point of regression of the notochord is the weakest point within the end plate of the vertebra’.

(iii) Recording of diseases and disorders

Spreadsheets produced at the beginning of the clinical data gathering were altered only slightly as the archaeological data collection progressed. The adaptations were better suited to the recording of the macroscopically gathered archaeological data. Every radiographic report for a patient with definite or possible Schmorl’s node provided further detailed information of any other diseases and disorders noted for that person. The column headings carried the diseases and disorders recorded from the radiological reports, with the first column containing an altered reference to the patient’s barcode. This clinical spreadsheet was adapted for archaeological purposes to record a reduced number of diseases and disorders within the skeletal material, as discussed in Chapter 3.



**Figure 5.15 Schmorl’s node causing posterior vertebral body fracturing (Whithorn Priory skeleton No. 552)**

Diseases and disorders recorded were: posterior neural arch defects, osteoarthritis, osteopenia, osteophyte formation (where no other spinal osteoarthritic changes were present), mild osteochondritis, loss of lordosis, scoliosis, irregular end plates, retrolisthesis, spondylolysis and spondylolisthesis. Schmorl's nodes were viewed and recorded as smooth or rough, shallow or deep, and positioned within the end plates as anterior, central or posterior and, if lateral placed, this too was noted (Appendix 2).

(a) Recognition of diseases and disorders of the spine in archaeological materials

- Posterior neural arch
  - a) Schmorl's node impinging into the neural canal space by fracturing the posterior vertebral body wall (Fig. 5.15)
  - b) Projecting bony growths due to degenerative joint disease
  - c) Spina bifida occulta, posterior spine/pedicle absent, leaving an open neural arch
  - d) Narrow cord space
- Osteoarthritis
  - Eburnation, surface pitting, alteration of the joint contours and osteophytic changes
- Osteopenia/osteoporosis
  - Wedged and fractured vertebrae with incomplete trabecular structure
- Osteophytes
  - Horizontal osteoblastic formation of bone around the periphery of the vertebral end plates, becoming vertical in the extreme stages (recorded separately even when observed as

one of the bony alteration indicating osteoarthritis)

- Mild osteochondritis/spondylosis

Flaking of the vertebral end plates shown as roughened raised areas on the end plates, reported as mild osteochondritis in radiology reports, and known as spondylosis by osteologists (Rogers and Waldron, 1995)

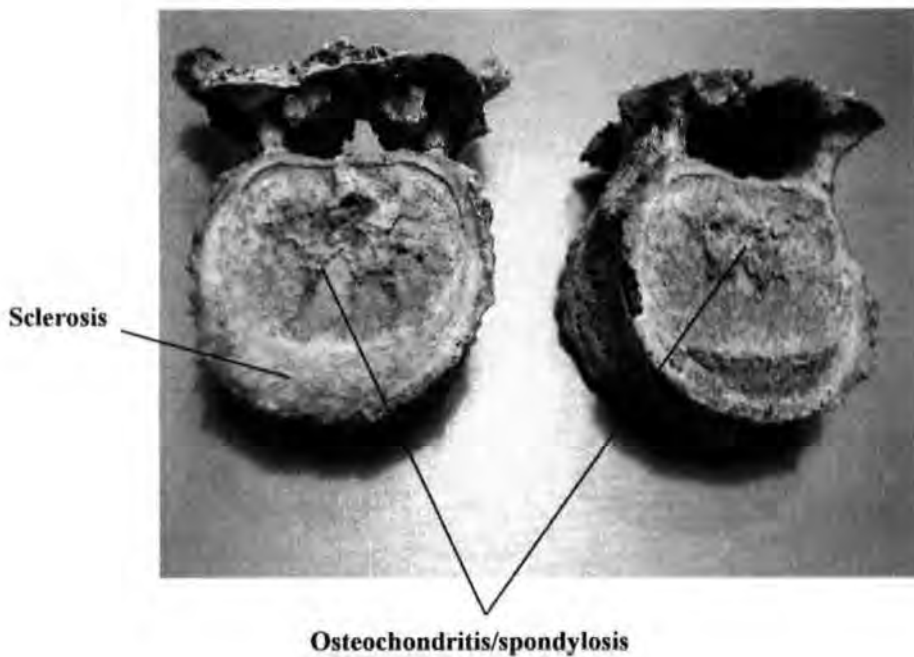
- Loss of lordosis
- Scoliosis

Straightening out of the secondary curve

Lateral and rotational movement of the vertebrae from the mid-line when viewed anteriorly

- Sclerotic end plates

Thickening slightly rough/fluffy surface (Fig. 5.16)



**Figure 5.16 Thoracic vertebrae showing osteochondritis/spondylosis and sclerosis (St. Andrew, Fishergate skeleton No.136)**



Barco de	Age	Sex	PNAD	OA	OS	OF	MO	JO	LO	SC	SEP	IEP	D↓	R	SP	S	TYPE	POS P/M
BA170	15	F	—	—	—	—	—	—	✓	—	—	—	—	—	—	—	R	M
CB132	19	F	—	✓	—	✓	—	—	—	—	—	—	✓	—	—	—	R	P

**Figure 5.18 Example of a clinical diseases and disorders data collection sheet**

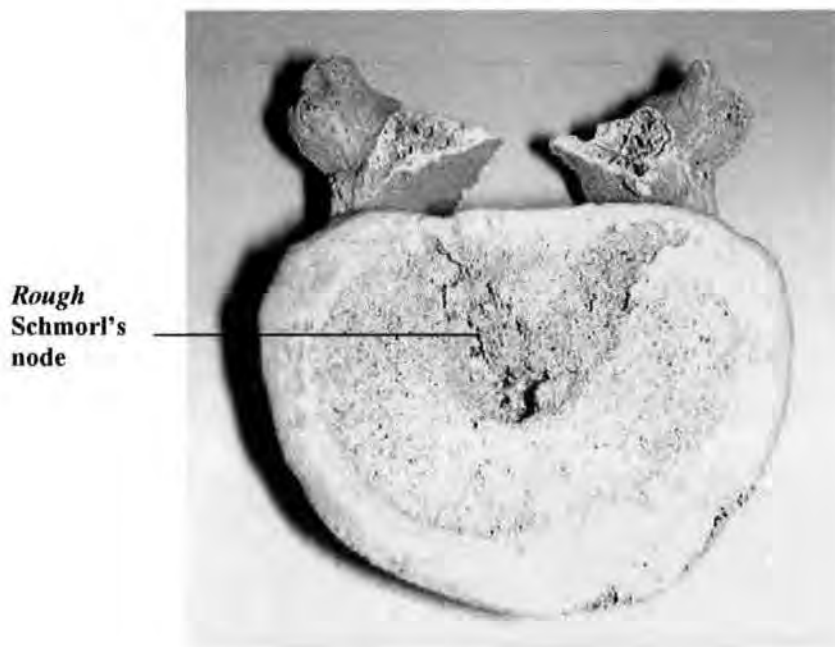
Skele No	Age	Sex	PNAD	OA	OS	OF	MO	LO	SC	SEP	IEP	R	SP	S	Type	A	M	P
383	40>	M	✓	✓	—	✓	—	—	—	—	—	—	—	—	R	—	—	✓
389	45>	M	—	—	—	✓	✓	—	—	—	—	—	—	—	R	✓	—	—

**Figure 5.19 Example of an archaeological diseases and disorders data collection sheet**

The meaning of the abbreviated terms used in the collection grids (Figs. 5.18 and 5.19) are as follows:

- Unique number            a cross reference code for each individual patient
- Sk No                        unique site/archive code for each skeleton
- PNAD                        post neural arch defect
- OA                            osteoarthritis
- OS                            osteopenia and osteoporosis
- OF                            osteophyte formation
- MO                            mild osteochondritis
- JO                            juvenile osteochondritis
- LO                            loss of lordosis
- SC                            scoliosis
- SEP                            sclerotic end plates

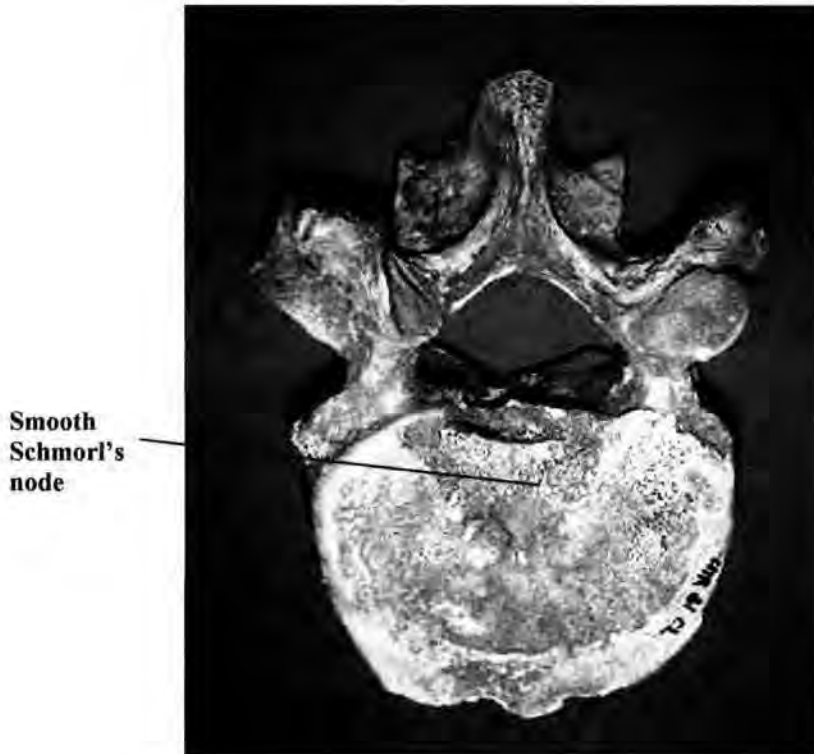- IEP irregular end plates
- D↓ loss of intervertebral disc height
- R retrolysthesis
- SP spondylolisthesis
- S spondylolysis
- Type rough (Fig. 5.20), smooth (Fig. 5.21) or grape (the appearance of the Schmorl's node)



**Figure 5.20 Inferior end plate *rough* Schmorl's node (Whithorn Priory skeleton No. 539)**

- POS position of the Schmorl's node within the end plate
- A anteriorly placed Schmorl's node
- M centrally placed Schmorl's node
- P posteriorly placed Schmorl's node

Reduction of the fifteen disorders recorded during the clinical data gathering (Fig. 5.18) to eleven for the skeletal data collection (Fig. 5.19) removed those diseases that were not possible to diagnose from the skeletal remains alone. The reasoning behind inclusion and exclusion of certain reported clinical disorders and diseases from the skeletal material data recording are discussed in Chapter 3.



**Figure 5.21 Smooth Schmorl's node  
(The Hirsler, skeleton No. 12)**

(iv) Relevant information

When studying the skeletal material, any visual information that might prove useful later was recorded on a data sheet which required no alteration from the clinical version (Appendix 2). If any anatomical variation was observed, for example, a 6<sup>th</sup> lumbar vertebra, the absence of a posterior arch, signs of fracturing of the pars interarticularis, pars interarticularis remodelled to articulate with first sacral segment, they were recorded. Anything unusual about the disposal of the body/skeleton or closely related small finds (grave goods) were also recorded.

(v) Diagrammatic recording

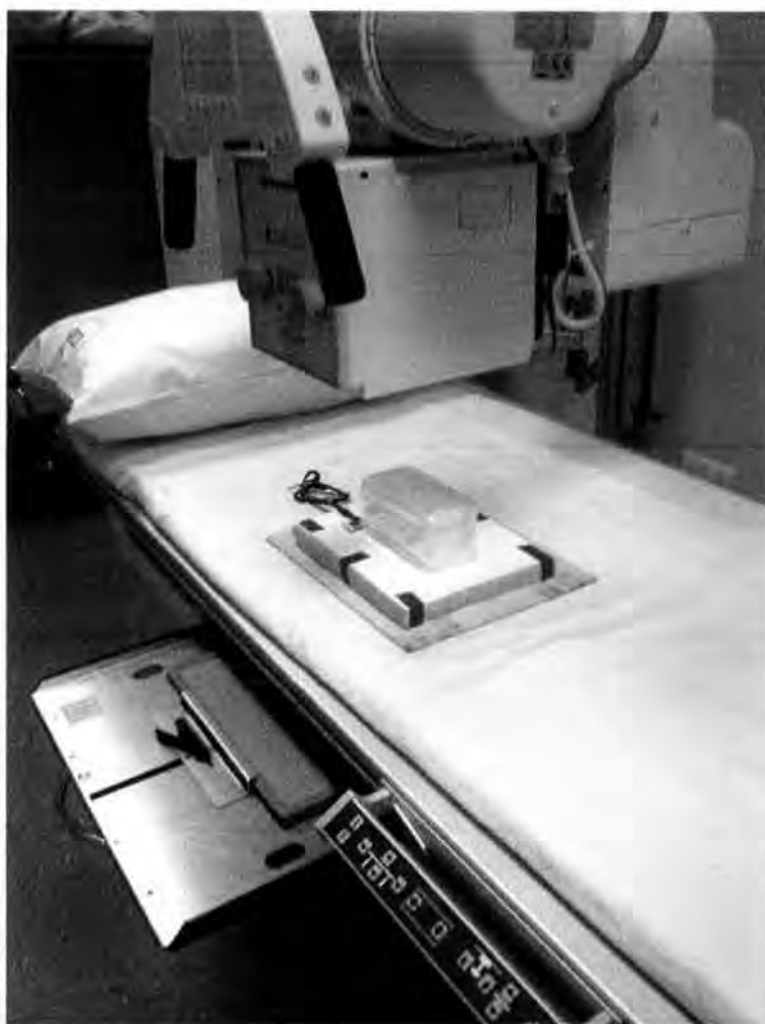Diagrams of thoracic and a lumbar vertebra (Appendix 2) were produced to allow accurate recording of the positions of Schmorl's nodes, osteophyte formation, and any displacement of bone fragments into the posterior neural arch. The diagrams of superior and inferior vertebral surfaces had a cross superimposed upon them, dividing the surface into quadrants. Right and left lateral views were drawn to allow alterations to the vertebral profile to be recorded, and a tangential view gave access to the posterior neural arch to allow altered structures to be positioned correctly. This method of collecting macroscopically observed bony alterations might show a recurring sequence when viewed in relation to Schmorl's nodes. If recurring relationships did exist, they might be lost if only presence/absence were to be recorded.

5.2.3 Radiographic imaging

A question posed by the researcher early in this research, "Do we see what we think we see?" needed ratification. Osteologists observing skeletal remains have commented on slightly eroded areas or depressions on adult vertebrae and have immediately categorise them as Schmorl's nodes, where no intrusion into the vertebral end plates was visible. In an effort to establish a definitive correlation between visual end plate alterations and Schmorl's nodes, plain film radiography was used. A conventional Philips diagnostic x-ray machine, with oscillating bucky and an ampliamatt, provided a radiation source suitable for this work.

Agfa-Gevaert blue emulsion film placed in cassettes containing fast screen combinations gave good contrast and density, producing good quality radiographic images. Imaging was constrained by the permissions laid

down in the agreements allowing access to the chosen skeletal materials. Each curating body has its own rules and regulations, some not allowing the removal of human remains from the place of storage, and some allowing movement only if the correct paperwork is completed and no risk of loss is assured.



**Figure 5.22** An example of how the archaeological samples were radiographed, contained in a sealed crystal box, resting on a rubber mat and an aluminium filter. The tube is centred to the bucky tray containing the cassette at a height of 110 cms.

At other times, distance from place of storage to the place designated for radiographic imaging made this an impractical operation. Those vertebrae selected for radiography were pre-packed in crystal boxes, wrapped in acid free tissue, and separated by acid free packaging to represent the intervertebral disc spaces. This method of packaging allowed

manipulation of the vertebrae into antero-posterior and lateral positions by the turning of the crystal box containing the vertebrae through 90° along its longitudinal axis, thus replicating the views taken when clinical patients were radiographed.

Without soft tissues it is difficult to produce an image of comparable density to conventional clinical x-ray images; to overcome this problem a 2mm aluminium filter, combined with a 2.5mm rubber solution mat, was used with a considerable degree of success (Fig. 5.22). The radiographic equipment used was situated in the clinical x-ray department of Pinderfields General Hospital, Wakefield, where elimination of cross-infection and contamination of any sort was of paramount importance, as any bone or soil dust transferred to a patient from an archaeological sample could potentially act as an irritant or source of cross infection.

Controlled introduction of skeletal material to the clinical environment needed careful consideration. Crystal boxes, polyurethane packing and acid free paper allowed x-ray imaging to occur without the necessity of opening or unpacking the boxes. The sealed box was placed on the rubber solution mat, and both were placed on the aluminium filter directly on the x-ray couch, with the cassette in the bucky tray (Fig. 5.23). After several trial exposures had been made using a group of adult lumbar vertebrae, the radiographic images were compared for density and contrast so that an optimum exposure could be chosen. Average exposures of 55kv (kilo volts) and 12 mAs (milliampere seconds) were used with the exception of upper thoracic imaging for which the kilo voltage was reduced by 5kv and 2 mAs, due to the reduced mass of the vertebrae. Subadults only needed a small reduction in dose, but neo-natal and infants required detail (slow) screens, with direct table top imaging using a finger exposure of 44kv and 4 mAs. The potential kilo voltage determines the average energy and therefore

the penetrating power of the x-rays, and the milli-ampere seconds determines the total dose produced, i.e.  $mAs \times 2 =$  twice the dose. A patient identity area was used to imprint the skeleton's number on the radiograph along with, the site name and the year of excavation. In addition, the levels of the thoracic or lumbar vertebrae were included in this permanent "on film" identification, for reference.

### **5.3 Data analysis**

The method of data analysis varied depending on the hypothesis to be tested, but for all samples, whether clinical or archaeological, the same methods were used wherever possible to allow comparative analysis. Where percentages have been used to show the results of the analysis graphically, the total number of individuals in each sample being analysed =  $N$ , and the number affected by Schmorl's nodes =  $n$ . Chi squared will be used to look at the actual numbers of males and females affected by Schmorl's nodes in each of the archaeological samples to deduce whether the null hypothesis (Schmorl's nodes for both males and females are equally likely) is proved. One degree of freedom will be applied to the samples tested, in this way.

1) In determining whether a possible weak area in the end plate of the vertebra existed, all subadult clinical data recorded from the radiographs and subadult archaeological diagrammatic evidence were analysed.

(i) Radiographic images of all subadults and young adults to the age of twenty-five in the clinical samples were analysed to see if any central Schmorl's nodes, central fissures, or any possible central cortical gaps were visible. Three possible cases of centrally positioned Schmorl's nodes were observed, each of these three subadults bone suffered either genetic or congenital abnormalities, all of which either caused reduced

mineral content or spina bifida cystica.

(ii) Macroscopic studies of the end plates of each vertebra in each subadult vertebral column for all the archaeological samples were undertaken to ascertain whether a centrally positioned Schmorl's node, a small fissure, or absence of cortex was visible. Five possible instances of weakened area on the vertebral end plates were observed, and each of the vertebrae of the vertebral columns were re-examined using a magnification of 20:1 to allow the intrusions, their edges and the subchondral bone immediately beneath to be clearly visualized. Each in turn was eliminated; the first (Sk.71) had three small circular apertures through the inferior end plate of the tenth thoracic vertebra which, when magnified, continued through the subchondral bone, the diameter decreasing with depth, which may well have been taphonomic alteration. The next vertebral column (Sk. 460) was affected by Schmorl's nodes from the twelfth thoracic to the third lumbar vertebra with the positions of the Schmorl's nodes varying from central/posterior to posterior the lower they sat in the vertebral column. These Schmorl's nodes were not fine centrally positioned nodes; they appeared to conform to the clinical trauma model and not to a weakened central area of the end plate. St. Andrew, Fishergate produced three possible centrally weakened areas, but each in turn was eliminated as the macroscopic and microscopic information was compared and placed in context, with the superior and inferior vertebral Schmorl's node positions of each of the vertebral columns.

2) Proving Schmorl's nodes to be asymptomatic or symptomatic in the clinical samples was carried out by reviewing the data gathered from the x-ray request cards (see Appendix 8). Sixty-nine percent (91) of patients gave a history of back pain, often centred on the levels at which Schmorl's nodes were observed and reported when

radiographs had been taken. Only 8% (11) individuals complained of sided or bi-lateral leg pain and only one did not have accompanying back pain.

(i) Several individuals in the archaeological samples had fractures in the posterior vertebral wall where Schmorl's nodes had ruptured the trabeculae and cortex (see Fig. 5.15); this may have caused impingement on the spinal cord and caused acute pain, but this cannot be proved. Although all the archaeological vertebrae were studied macroscopically, assigning acute or chronic pain in relation to Schmorl's nodes was not attempted, as at best it would have been speculative.

3) Almost all Schmorl's nodes occur within the first two decades of life.

From the data sheets (see Appendix 6), the subadult individuals affected by Schmorl's nodes were placed into the age ranges as set out in appendix 4, Tables 6.4. Each adult vertebra column affected by Schmorl's nodes was placed in an age range as set out in Appendix 3.

(i) The Pinderfields Hospital samples and the RHSC, Edinburgh sample were placed together to artificially introduce subadult age groups to the Pinderfields Hospital samples. The first eleven of the twenty-two RHSC, Edinburgh subadults were placed with the 1994-5 Pinderfields sample, and the remaining RHSC, Edinburgh subadults were united with the 1995 Pinderfields sample. This union of RHSC, Edinburgh subadults was undertaken before the data was rearranged to place the subadults in age order as in Appendix 6.

(ii) The archaeological samples were placed in age groups corresponding to the clinical

age groups. The percentages were arrived at using  $n$  as the number of vertebral columns in each age range and  $N$  as the total number of vertebral columns affected by Schmorl's nodes in each sample; using these known numbers, percentages were produced for each age range in each sample.

4) Schmorl's nodes not centrally formed within the vertebral bodies, cause instability to the dynamics of the vertebral column.

(i) Clinical evidence for scoliosis, where Schmorl's nodes were present was analysed from the data produced from the radiographs and placed in Appendix 7 and the data recorded in the relevant information sheets (see Appendix 8).

(ii) Archaeological analysis made use of the information recorded on the diagrammatic collection sheets; these allowed discrepancies in height in the anterior and lateral aspects of the vertebral body to be recorded as well as the eccentric and/or anterior positions of the Schmorl's nodes. The rebuilding of the thoracic and lumbar vertebral columns confirmed the alterations deduced on analysis of the diagrammatic information.

The results of this analysis are produced in Appendix 3. The percentages are arrived at by using  $n$  as the number of males, females or subadults affected by scoliosis and/or kyphosis and  $N$  as the total number of males, females or subadults affected by Schmorl's nodes.

5) Different work patterns cause Schmorl's nodes at varying levels in the thoracic and lumbar spine.

Age groups were used again to help determine whether the levels at which vertebrae are affected by Schmorl's nodes altered with age within a sample, and whether these age group changes were reflective of other samples of differing demography, geography, work patterns. Clinical and archaeological samples were analysed using the same method of age grouping, with each superior and inferior end plate affected by a Schmorl's node treated as a separate incident. The total number of individuals affected by Schmorl's nodes =  $N$ , the number of superior end plates affected by Schmorl's nodes at each single level =  $n$ , and the inferior end plates affected by Schmorl's nodes =  $-n$ . Each age group for each sample is shown graphically in appendix 5.

#### 6) Schmorl's nodes and their relationship to sex.

Clinical and archaeological samples were analysed using the data collected and presented in the tables of appendix 6. Analysis of the data was performed to provide two different presentations of the relationship between Schmorl's nodes and sexes. The initial analysis set out to prove whether the males and females were affected equally at the same vertebral levels, counting each level as one incident, for example if the third lumbar vertebra was affected by Schmorl's nodes on the superior and inferior end plate it would count as one incident. The results of this analysis are presented graphically in Appendix 4. The percentages were arrived at by  $n$  = the number of vertebra at each level for males and females, and  $N$  = the total number of male or female vertebral columns affected by Schmorl's nodes. The second method of analysis used deduced whether Schmorl's nodes rates are constantly found to be greater in the males of the samples, or whether rates alter in favour of the females in different samples. ( $N$  = the total number of vertebral columns affected by Schmorl's nodes for each sample, where  $n$  = the number of males or females in each sample). The RHSC, Edinburgh sample also analysed using the same methods, as the sex of each subadult was known.

7) Different Schmorl's nodes have different origins and underlying causes required careful macroscopic analysis of the radiographic images and reports for the clinical samples, and the diagrammatic collection sheets, along with any radiographic images, disorders and diseases data, and other relevant information for the archaeological samples.

8) Asymmetry of the pelvis and lower limbs cause disruption to the dynamics of the vertebral column and Schmorl's nodes was a clinical analysis only, as the archaeological samples studied had insufficient elements of pelvis and lower limbs to allow an unbiased study. Each individual's x-ray request card and report were referred to as the spinal, pelvic and limb-length radiographs were studied. Spinal scoliosis and/or kyphosis were recorded, as were left or right sided development dysplasia, and left or right sided discrepancies in limb length. Schmorl's node positions were analysed for position within the vertebrae forming the altered curve.

Macroscopically viewing the individual archaeological vertebrae in 3D has brought a much more sensitive dimension to the collection of early bony changes to this study, which are not always clearly defined on plain films in diagnostic radiography. Schmorl brought roentgenograms into his research and although technology and engineering have refined the technology, they still do not tell the complete story. The results from this analysis of both clinical and archaeological samples brings a different interpretation to several parts of Schmorl's research (1971), and others provide opposing results to those of modern researcher

